

# Histology mid exam 021



لجان الترفعات

1. We have a skin sample, what type of convenient special stain do we use to stain proteins?

- A) Immunofluorescence
- B) Immunohistochemical
- C) H&E
- D) A+b
- E) silver staining

Ans: B\*

---

2. What is incorrect about white adipose tissue?

- A) Multilocular
- B) Unilocular

Ans: A

---

3. What is the direct precursor of macrophages?

- A) Monocyte
- B) Mdp
- C) Hsc
- D) Histiocyte

Ans: A

---

4. Childhood obesity involves which of the following processes?

- A) hypertrophy of white adipocyte
- B) Hypertrophy of brown adipocyte
- C) Differentiated of mesenchymal into preadipocyte
- E) a+c
- F) a+b+c

Ans:E

---

5.Simple squamous epithelium is found in all, except:

- A) endothelium
- B) pleural
- C) peritoneum
- D) endocardium
- E) none of the above

Ans:E

---

6.Simple columnar is found in of the following except ?

- A) Lining of all the large intestine
- B) Lining of all the small intestine
- C) Stomach
- D) Gallbladder
- E) None of the above

Ans:A

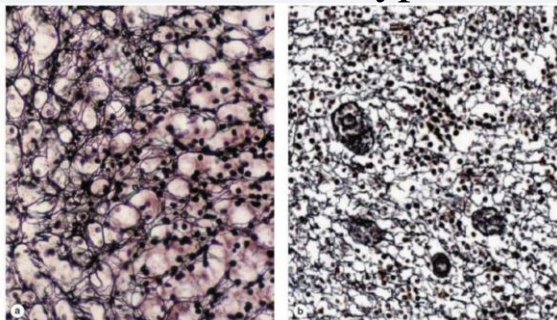
---

7.what is not true about electron microscope?

-Visualize tissue

---

8.We can find this type of tissues in all of the following except?



- A) Lymph nodes
- B) Liver
- C) Spleen
- D) Brain
- E) Adrenal gland

Ans:D

---

9.You are a researcher interested in the framework of spleen .  
Which of the following stains would you use ?

- A) silver salts
- B) H&E
- C) orcein
- D) aldehyde fuchsin
- E) alacian blue

Ans:A

---

10.You can find irregular connective tissue in which of the  
following :

- A) dermis
- B) tendons
- C) ligaments
- D) muscle

Ans:A

---

11.Which of the following is mismatched :

- A) tight junction – seals adjacent cells
- B) adherens junction – strengthen nearby tight junction

- C) hemidesmosome – anchors cytoskeleton to the basal lamina  
D) gap junctions – allow direct transfer of medium molecules

Ans:

---

12. Which of the following is classified as sheet-forming collagen ?

-Type IV

---

13. The lining of the upper respiratory tract is :

-Ciliated pseudostratified columnar with goblet cells

---

14. The incorrect characteristic about cilia :

-Have 9+0 in the core

---

15. The incorrect answer about transitional epithelium :

-All cells are binucleated

---

16. You can find simple columnar epithelium in : pic

-stomach and gallbladder

---

17. You are researcher interested in keratin sulfate which of the following you will study.

- A) dense regular connective tissue
- B) skin
- C) blood vessel
- D) cartilage
- E) umbilical cord

Ans:D

---

18.Stratified squamous epithelium is found in all, except:

- A) vagina
- B) oral cavity
- C) ureter
- D) pharynx
- E) none of the above

Ans:C

---

19.All happens in the intracellular except?

- Covalent bond formation between collagen molecules
- 

20.One of the following is correct about the characteristics of Basement Membrane ?

- Support EP tissue
- 

21.what supports the core of the microvilli?

- Actin filaments
- 

22.Stratified columnar epithelium lines what ?

- Conjunctiva
-

23. Effect the adjacent cell?

- A) Paracrine
- B) Apocrine

Ans:A

---

24. if you're a researcher and you want to make a vaccine for COVID-19 what cell would you expect to form antibodies?

-Plasma cells

---

25. Branched tubular is found in?

- A) Uterine gland
- B) Urethra
- C) Lieberkühn
- D) Brunner

Ans:A

---

26. Apocrine secretion is found in?

- A) Mammary gland
- B) Sebaceous gland
- C) Pancreatic acinar

Ans:A

---

27. Macrophages you would find in the liver

-Kupffer cells

---

28. Cells involved in wound healing ?  
-myofibroblast

---

29. All of these are from the characteristics of protein-active synthesizing cells stained with H&E except:

-Heterochromatin

---

30. Epidermolysis bullosa is a disorder caused by mutations in genes that participate in hemidesmosomes, leading the epithelial cells to be strongly attached to the underlying basement membrane

- A) The first sentence is true the second isn't
- B) The second is true the first isn't
- C) both sentences are correct
- D) none of them is correct

Ans:A

---

31. You are a researcher interested in studying keratan sulfate which of the following would you study?

- A) Skin
- B) Blood vessels
- C) Cartilage
- D) Umbilical cord
- E) Dense regular connective tissue

Ans:C

---

32. The main reason for fixation?

-To prevent autolysis

---



33.The covering of ovaries?

- A) simple cuboidal
- B) simple columnar
- c) stratified cuboidal
- d) simple squamous

Ans:A

34.One of the following is from the fixed cells in the connective tissue:

- A) Adipocyte
- B) Plasma
- C) Goblet
- D) Mast

Ans:A

---

---

35. What type of tissue immediately surrounds the BV?

-brown adipose tissue

