

# Neoplasia 2022/23

## Lecture 2: benign vs malignant, and dysplasia vs carcinoma in situ

*Heyam Awad, MD, FRCPath*

[h\\_awad@ju.edu.jo](mailto:h_awad@ju.edu.jo)

# ILOS

- 1. List the differences between benign and malignant tumors.
- 2. Recognize the histological features of malignancy.
- 3. Define dysplasia and understand its behavior.
- 4. Define carcinoma in situ and understand its difference from micro invasive carcinoma.

# Intro

- In the last lecture, we agreed that neoplasms are new growths with specific genetic mutations that allow them to grow autonomously.
- We also said that neoplasms can be benign or malignant.
- In this lecture we will discuss the characteristics of malignant neoplasms and how they differ from benign ones.

# Characteristics of malignant neoplasms

- 1. Differentiation and anaplasia
- 2. Increased rate of growth
- 3. Local invasion
- 4. Metastasis

# 1. Differentiation and anaplasia

- **Differentiation**: the extent to which neoplastic cells resemble the cells they originated from, both morphologically and functionally.
- In general, benign tumours resemble their cells of origin, both morphologically and functionally, whereas malignant ones differ from their parent cells.
- The more the difference, the more the de-differentiation. which means the worse the behaviour of the tumour.

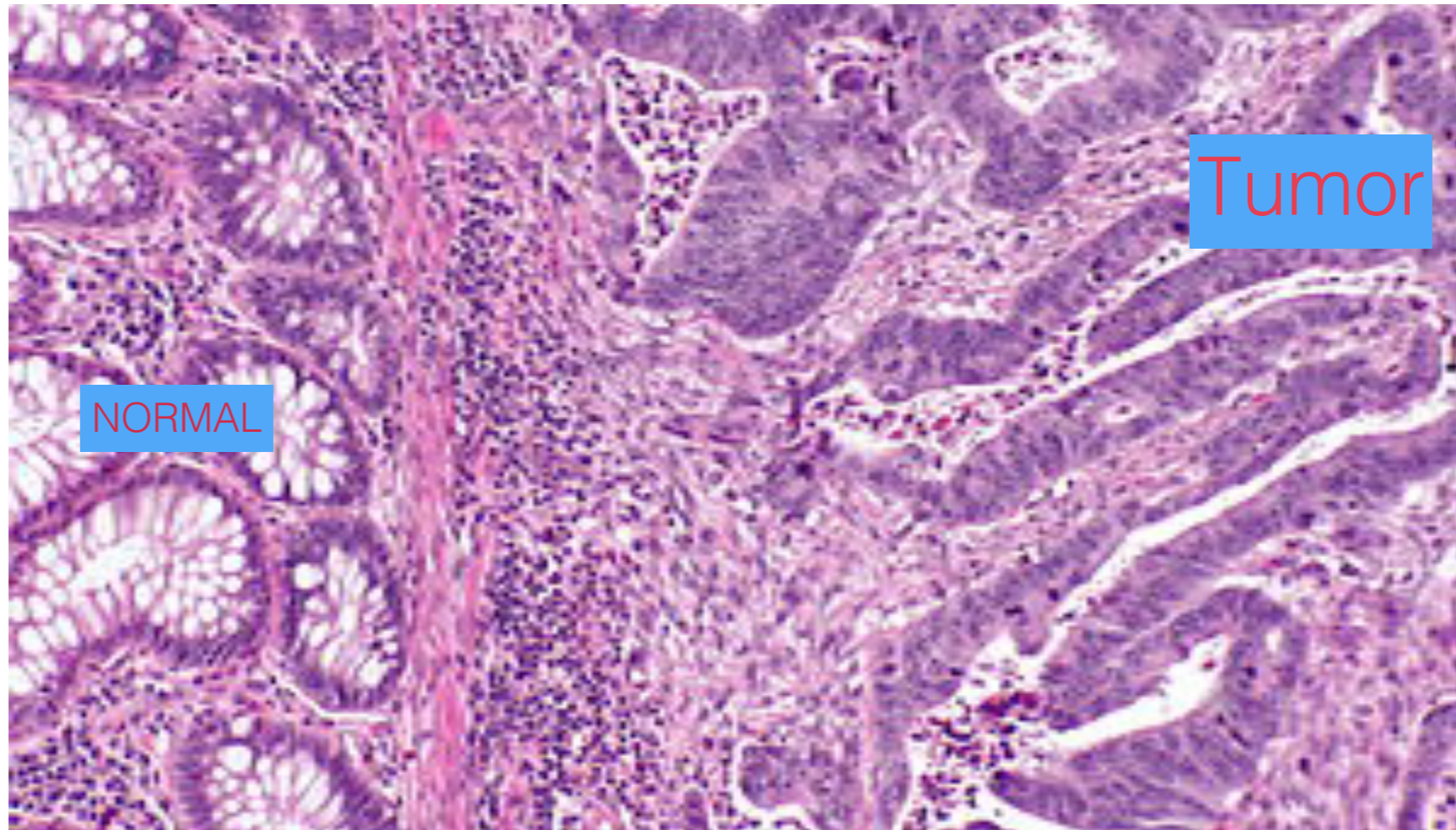
# Benign tumors : well differentiated

- Benign tumors resemble their parent cells
- Example: Pituitary adenoma can look exactly like normal pituitary gland and can secrete hormones secreted from that gland

# Malignant neoplasms: less differentiated

- Malignant neoplasms have a wide range of differentiation.. From well to poorly differentiated.
- Well differentiated tumours still have some similarity with their cell of origin.
- Moderately differentiated: less resemblance to cell of origin
- Poorly diff: almost no similarity to cell of origin
- These stages of differentiation are referred to as: tumour grades. well is grade 1, moderate is grade 2, poor is grade 3.

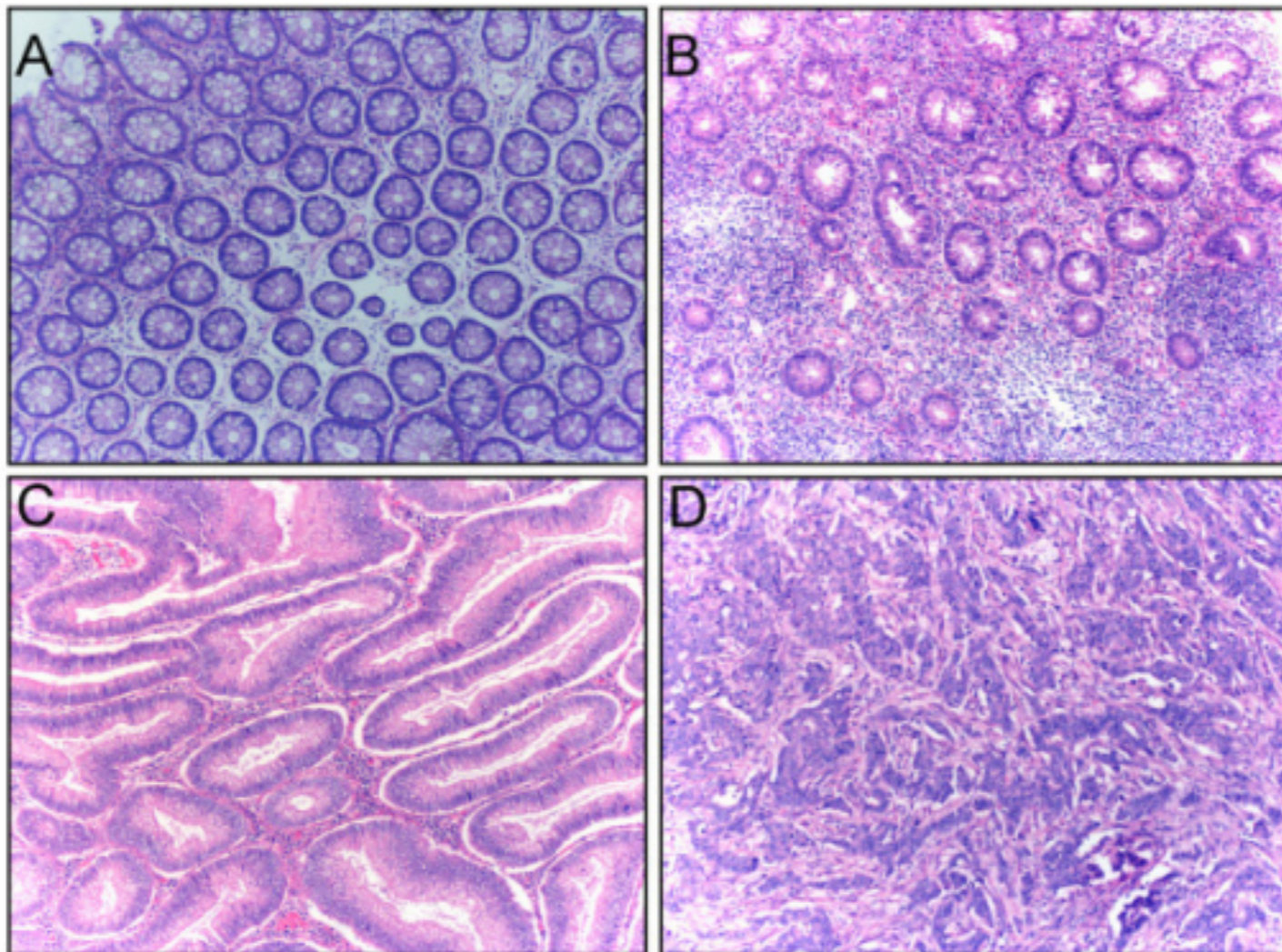
Malignant tumours are de-differentiated. In the pic below, note the difference between the tumour and its normal counterpart.





# Tumour grades ( differentiation)

- In this picture: A: normal colonic mucosa. B: grade 1 tumour ( well differentiated) C: moderately diff ( grade 2), D: poorly diff ( grade 3).. note how the higher the grade the more the differences between tumour and normal.



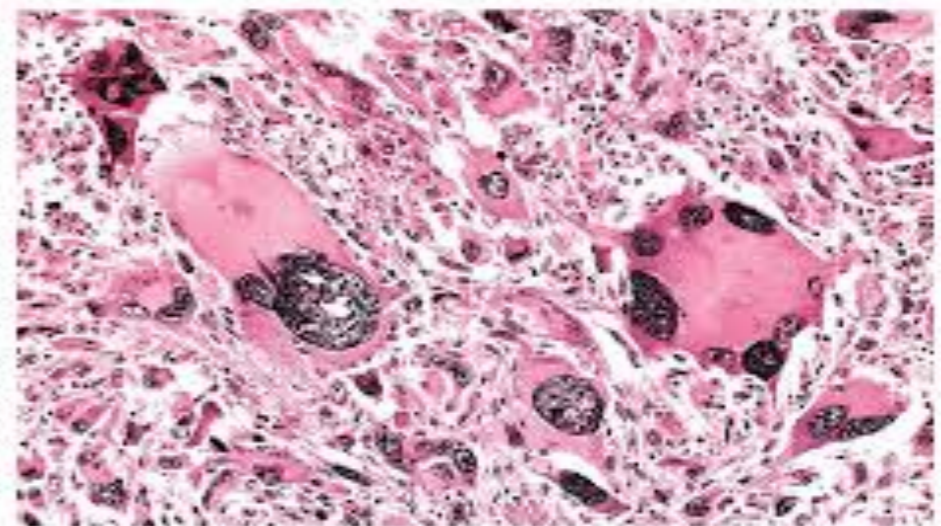
# Important note

- For each tumour there is a grade and a stage.
- Grade: refers to the morphology: to what we see under the microscope
- Stage: refers to extent of tumour spread: presence of metastasis.
- Both grade and stage are important for prognosis. BUT stage is much more important.
- Tumour stage is the single most important prognostic factor.

# Anaplasia

- Anaplasia = lack of differentiation. so we have almost complete loss of differentiation.
- Anaplasia is a hallmark (سمة مميزة) of cancer. [Hallmark means a distinctive characteristic].

Neoplasm of skeletal muscle

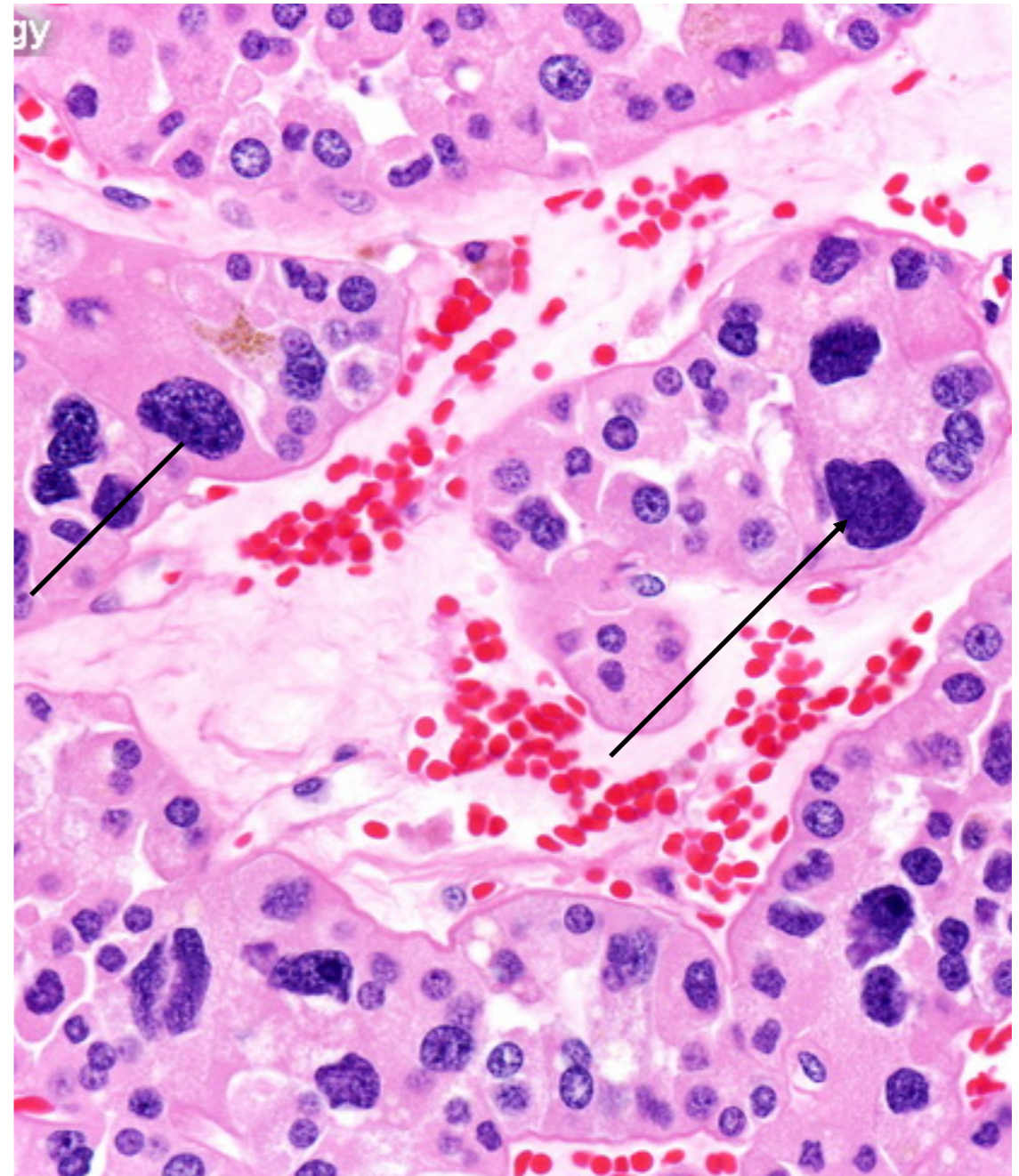


# Features of anaplastic cells

- Pleomorphism: variation in size and shape
- Hyperchromatic, dark nuclei
- Bizarre abnormal nuclei with coarse chromatin
- Large nuclei with high nucleo-cytoplasmic ratio (N/C ratio). Note: normal N/C ratio is 1:4 or 1:6
- Presence of large giant cells, with multiple nuclei
- Prominent nucleoli.
- Increased mitotic activity with abnormal appearance: tripolar or quadripolar
- Cells abnormally oriented with loss of polarity

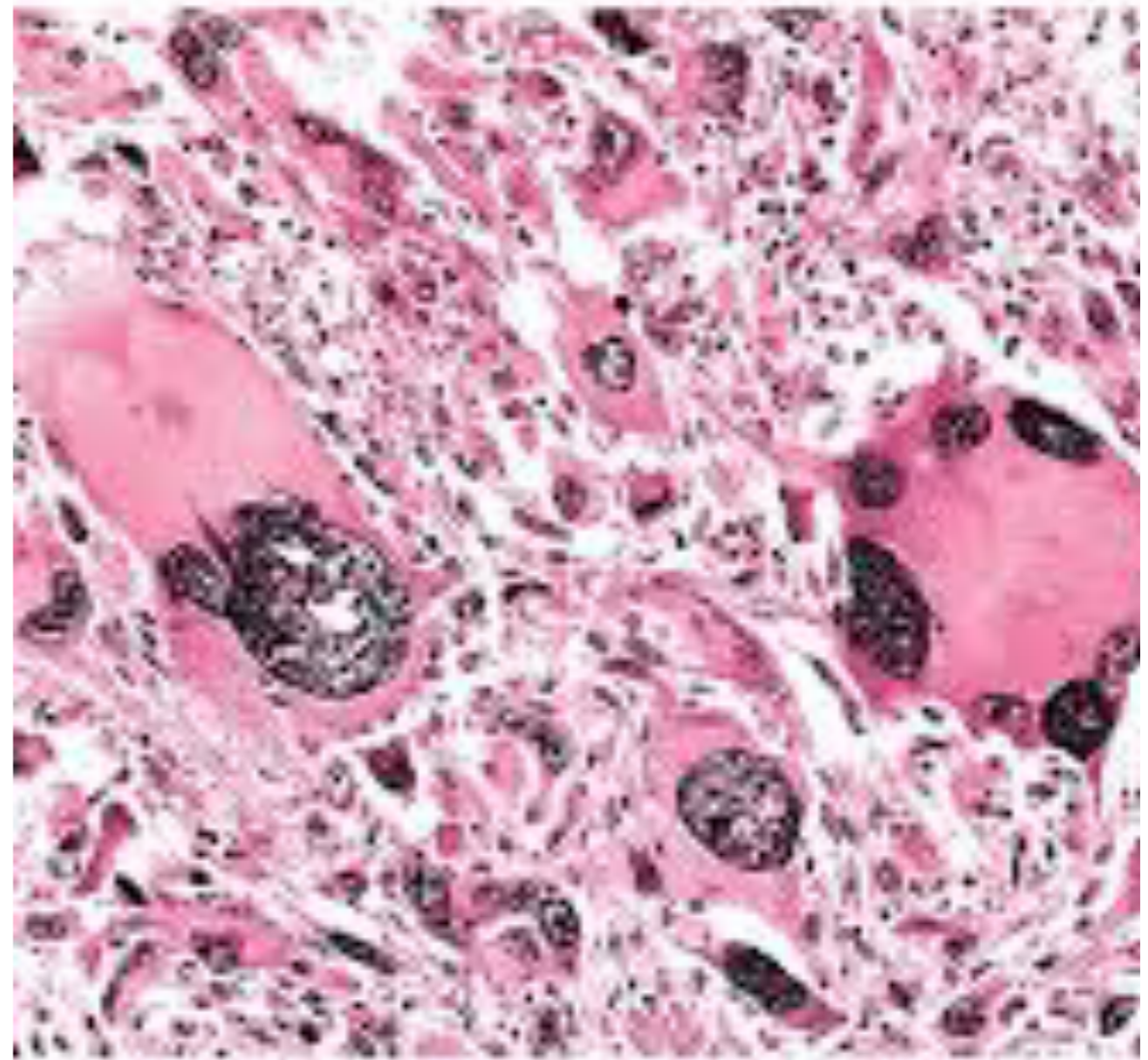
# Features of anaplasia

- This pic shows several features of anaplasia:
- 1. large nuclei ( high N/C ratio)
- 2. hyperchromasia ( very dark nuclei)
- 3. Pleomorphism: variation in nuclear size and shape.



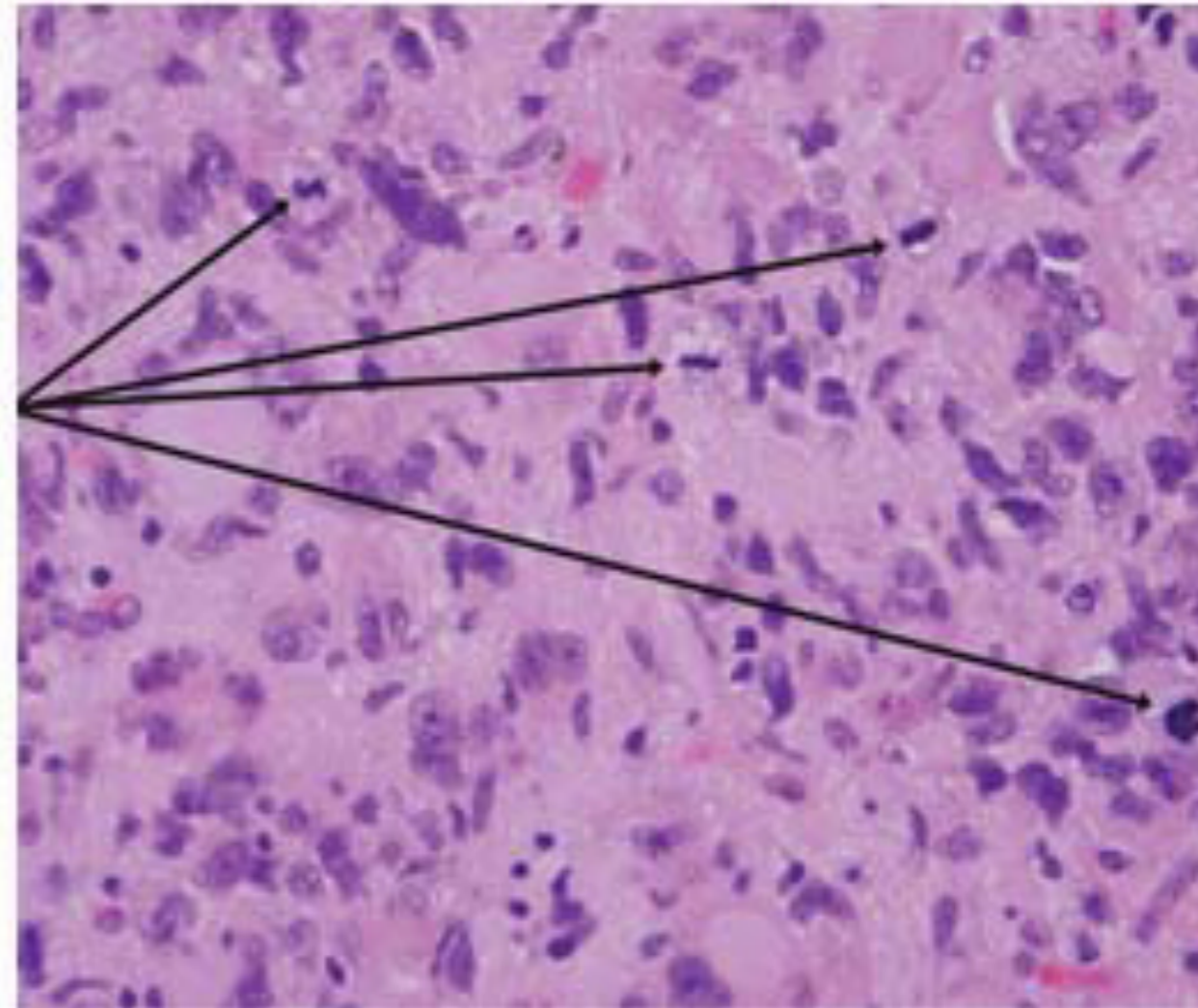
# Anaplasia

- This pic shows the multi-nucleation and the large bizarre shaped nuclei.

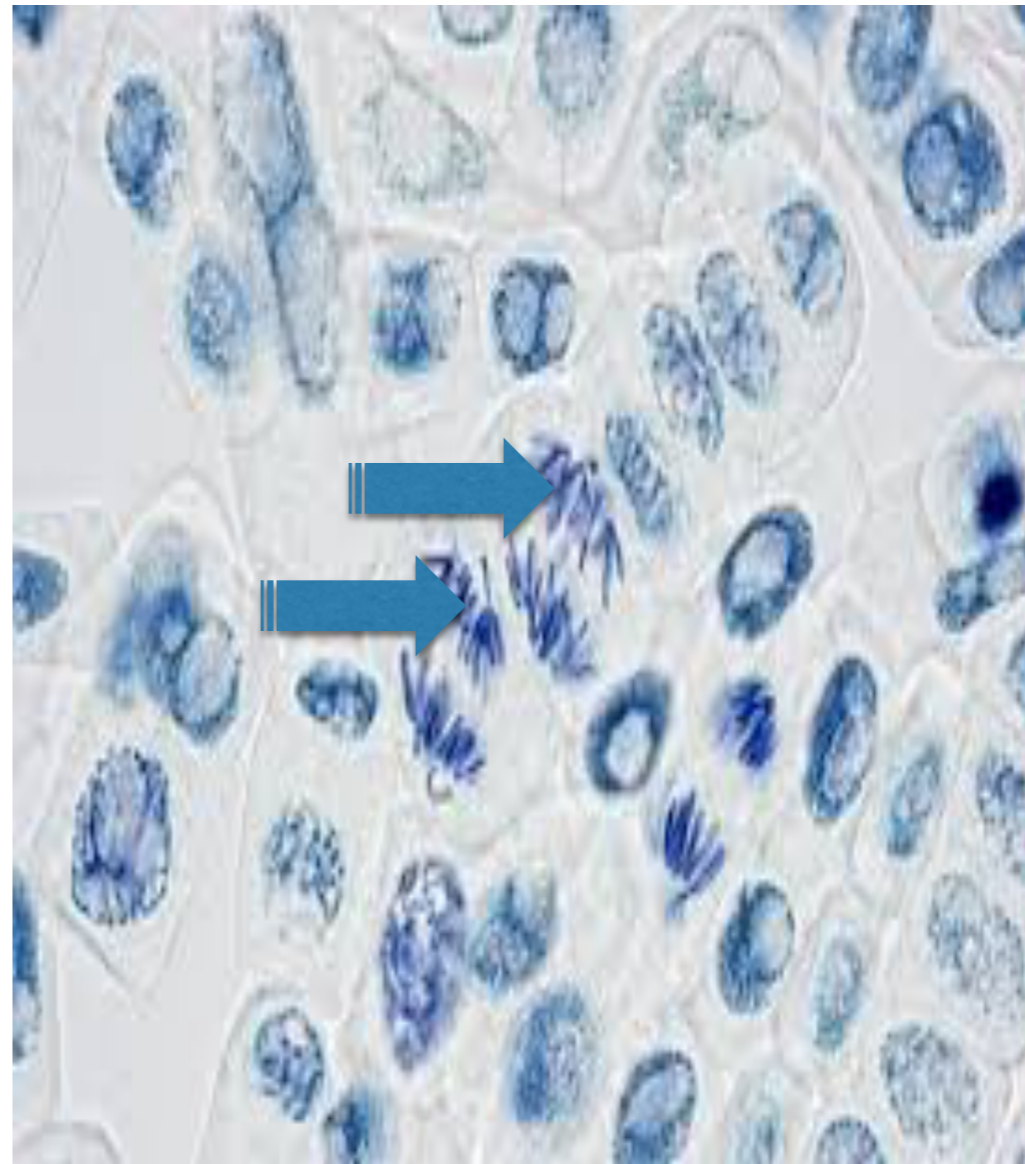


# Features of anaplasia: increased mitosis

- This pic shows multiple mitoses ( **Mitoses** arrows)
- This means the rate of growth is high.

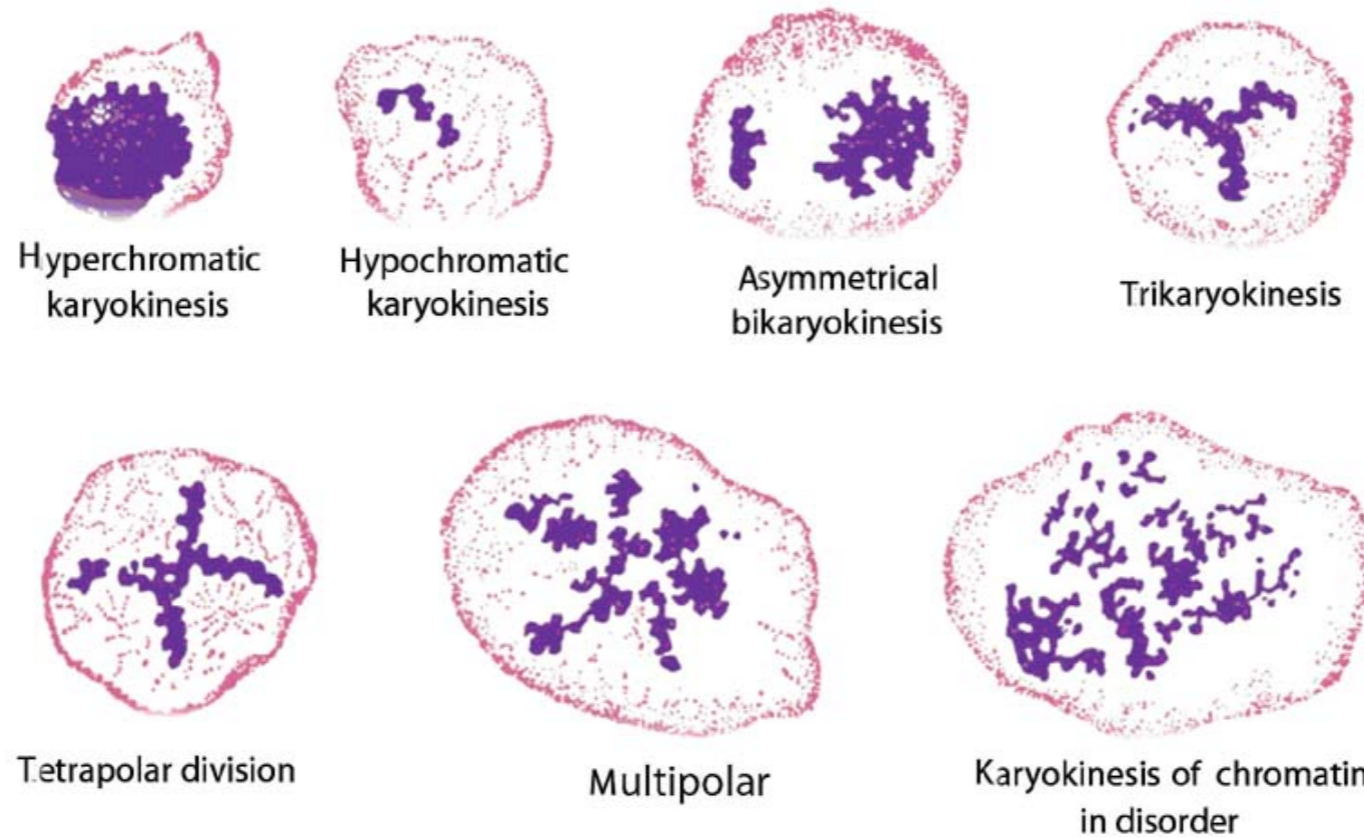


- Normal mitotic figures.



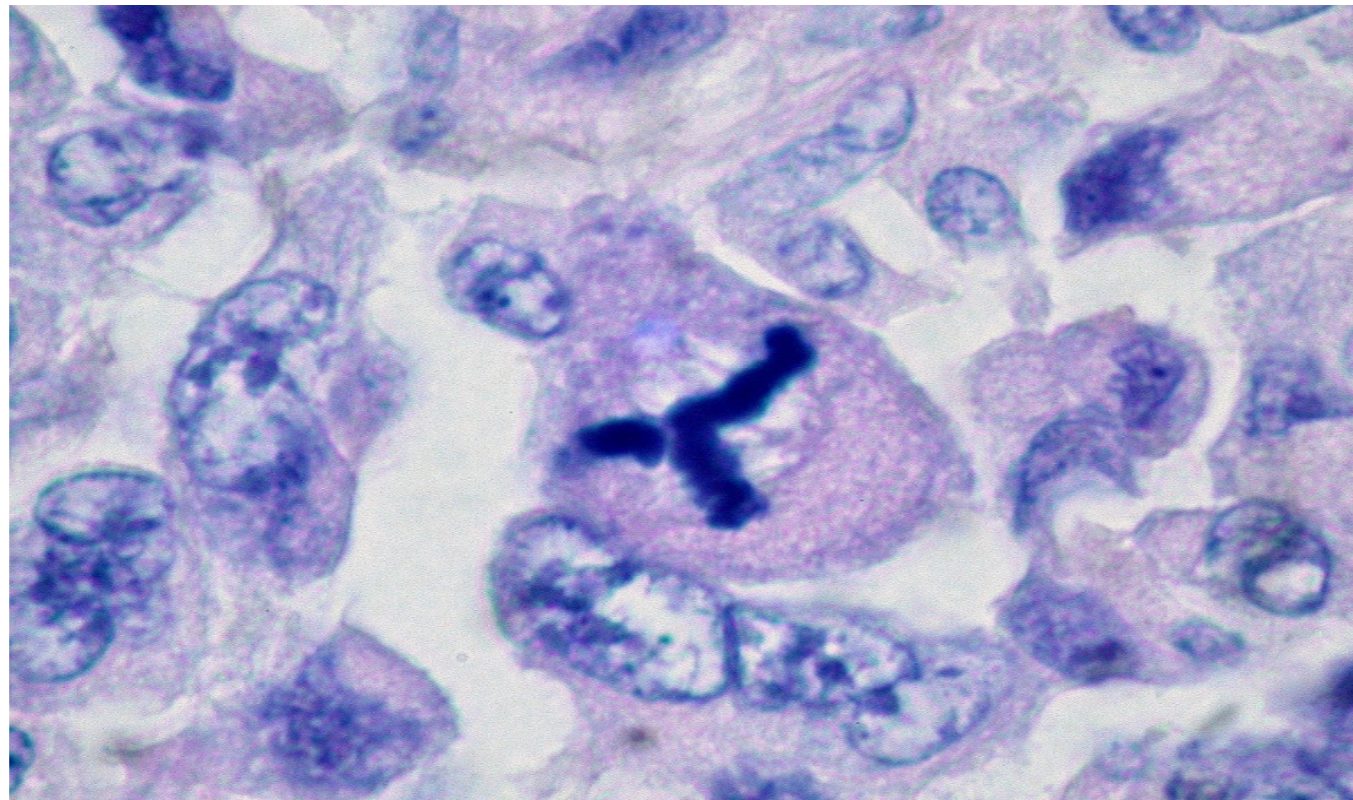


# Abnormal mitoses are also a feature of anaplasia

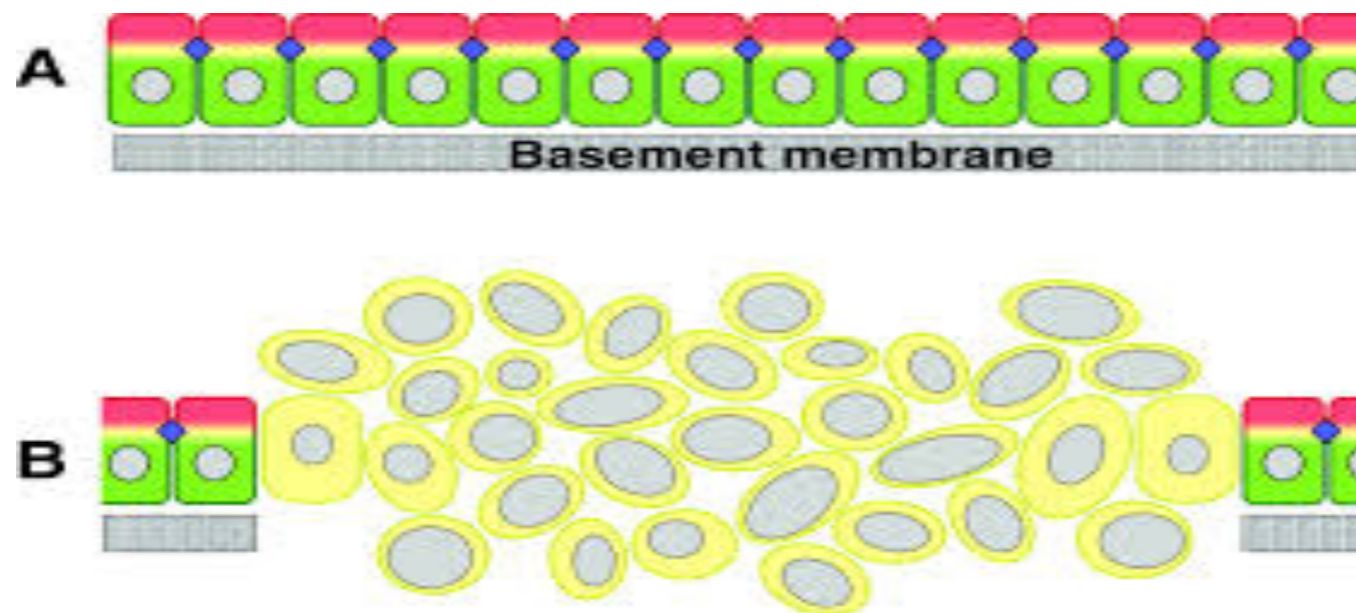


abnormal mitotic figures in malignant tumors

Tripolar mitosis = Mercedes sign! This is also an example of abnormal mitosis.



Loss of polarity= loss of normal organization.  
Also a feature of anaplasia



## 2. Rate of growth

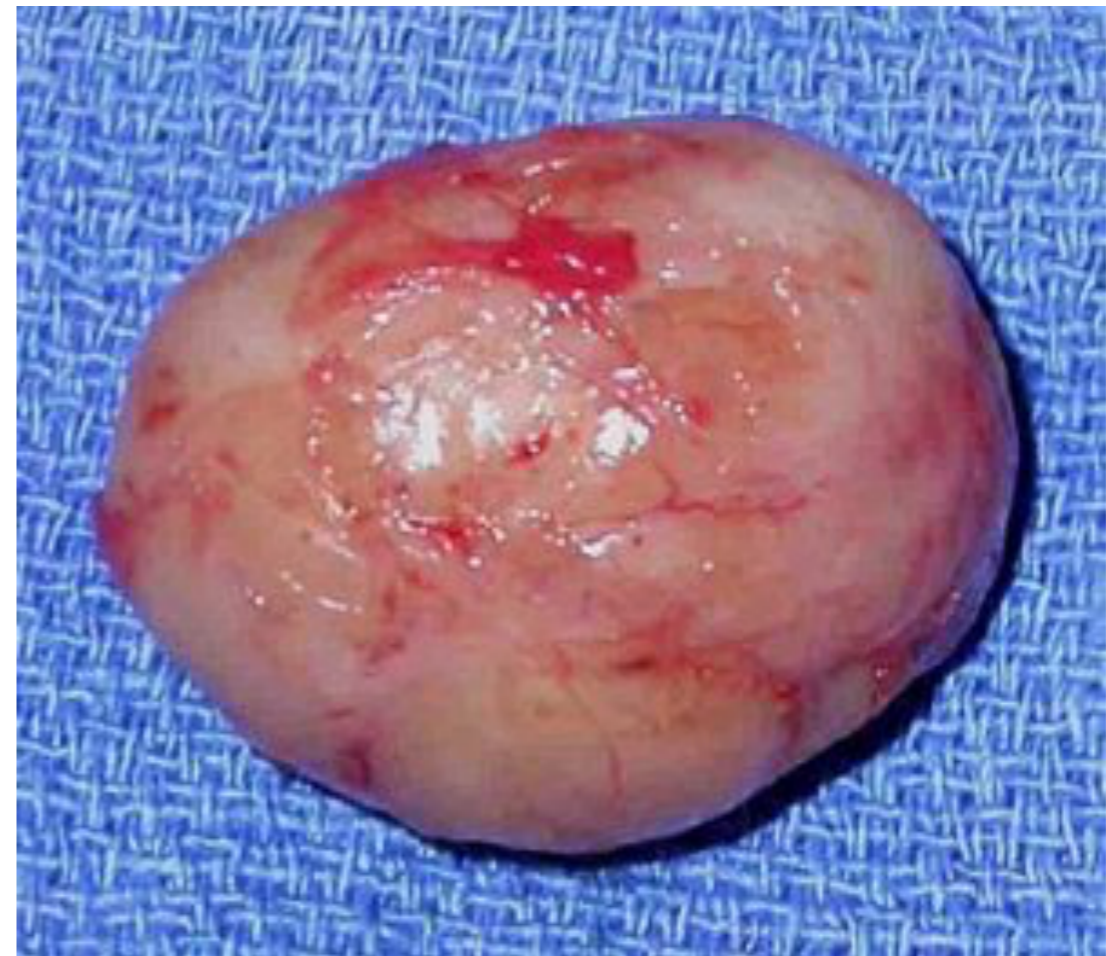- Most benign tumors: slow growing
- Most malignant: fast growing, more mitotically active

### 3. Local invasion

- Benign neoplasms: remain localized and do not invade.
- this is because they are encapsulated: the capsule is derived from 1. **stroma** of the host tissue and 2. **parenchymal cell atrophy** under the pressure of the expanding tumor.
- However, not all benign tumors are encapsulated but even the un-encapsulated ones have a line of cleavage in the majority of cases ( e:g uterine leiomyoma)

# Lack of invasion in benign tumour

- This pic shows a benign encapsulated tumour.
- Because of this capsule, these tumours do not invade the surrounding tissue
- And that's why they can be easily removed surgically.

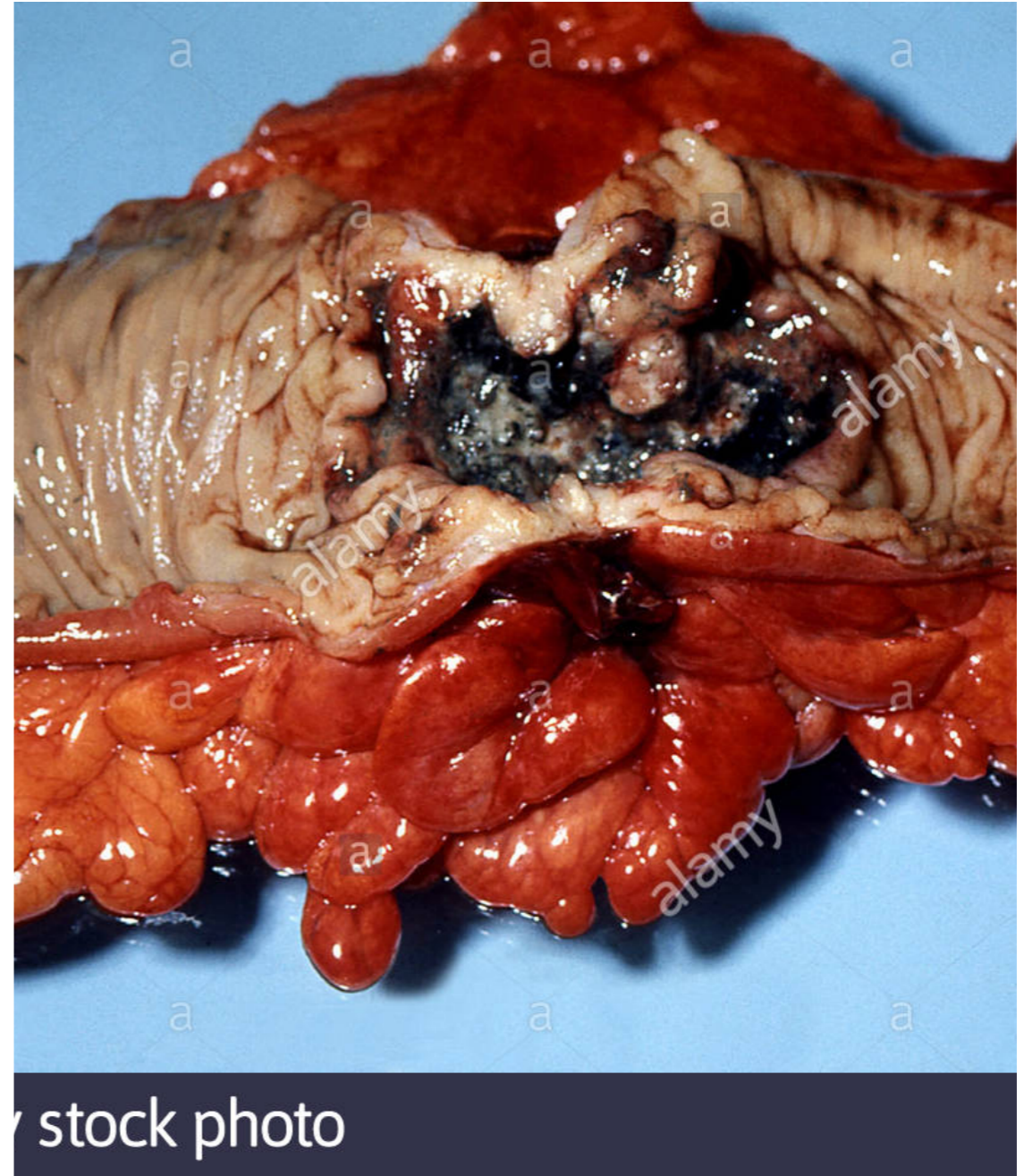


# Invasion In malignant tumors

- Cancer: progressive infiltration and invasion
- Usually **no** well defined capsule
- So must be removed with a wide margin
- **Local invasion is the second most important feature to differentiate benign from malignant neoplasms; metastasis is the most important feature.**

# Malignant tumours invade surrounding tissue

- This pic shows a malignant adenocarcinoma of the colon.
- There is no capsule and the tumour is invading surrounding tissue.

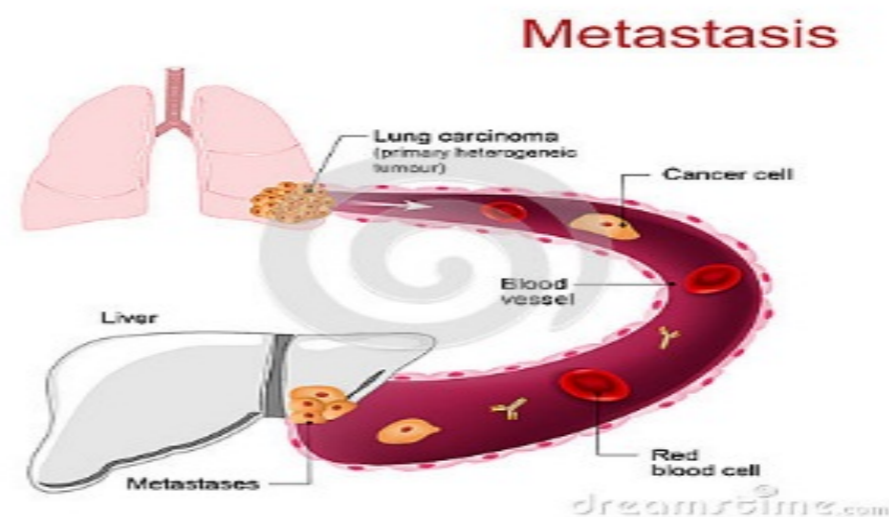


stock photo



## 4. Metastasis (mets)

- Metastasis= secondary implants of the tumor which are discontinuous with the primary tumor and located in distant sites.
- Metastasis is **the most important** feature of malignancy.



# mets

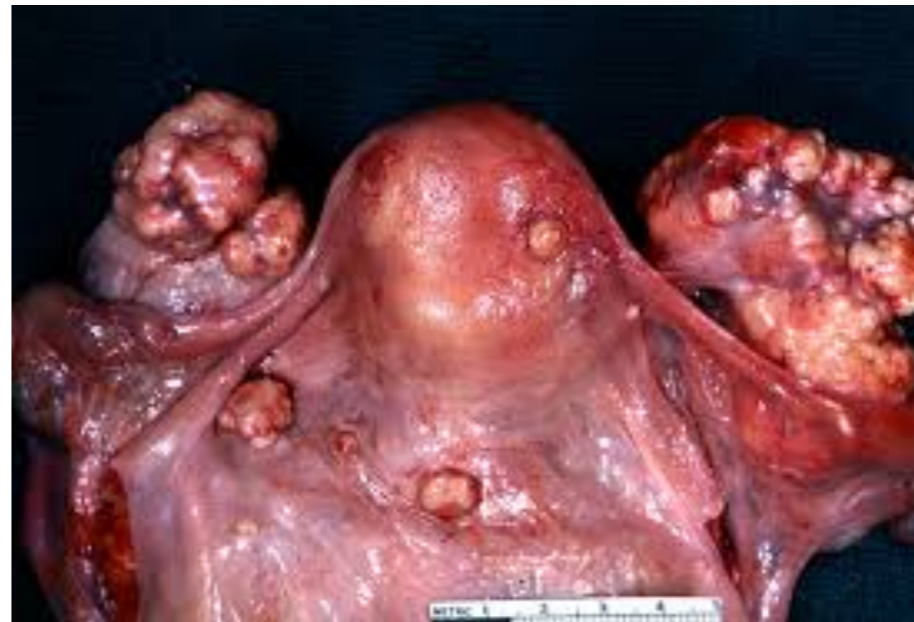- Cancers differ in their ability to metastasize
- Basal cell carcinoma of skin doesn't metastasize
- CNS tumors rarely metastasize
- Bone =osteogenic sarcoma usually found to be metastasized before discovering the primary tumor

# Routes of metastatic spread

- 1. seeding within body cavities
- 2. lymphatic spread
- 3. hematogenous spread

# Seeding through body cavities

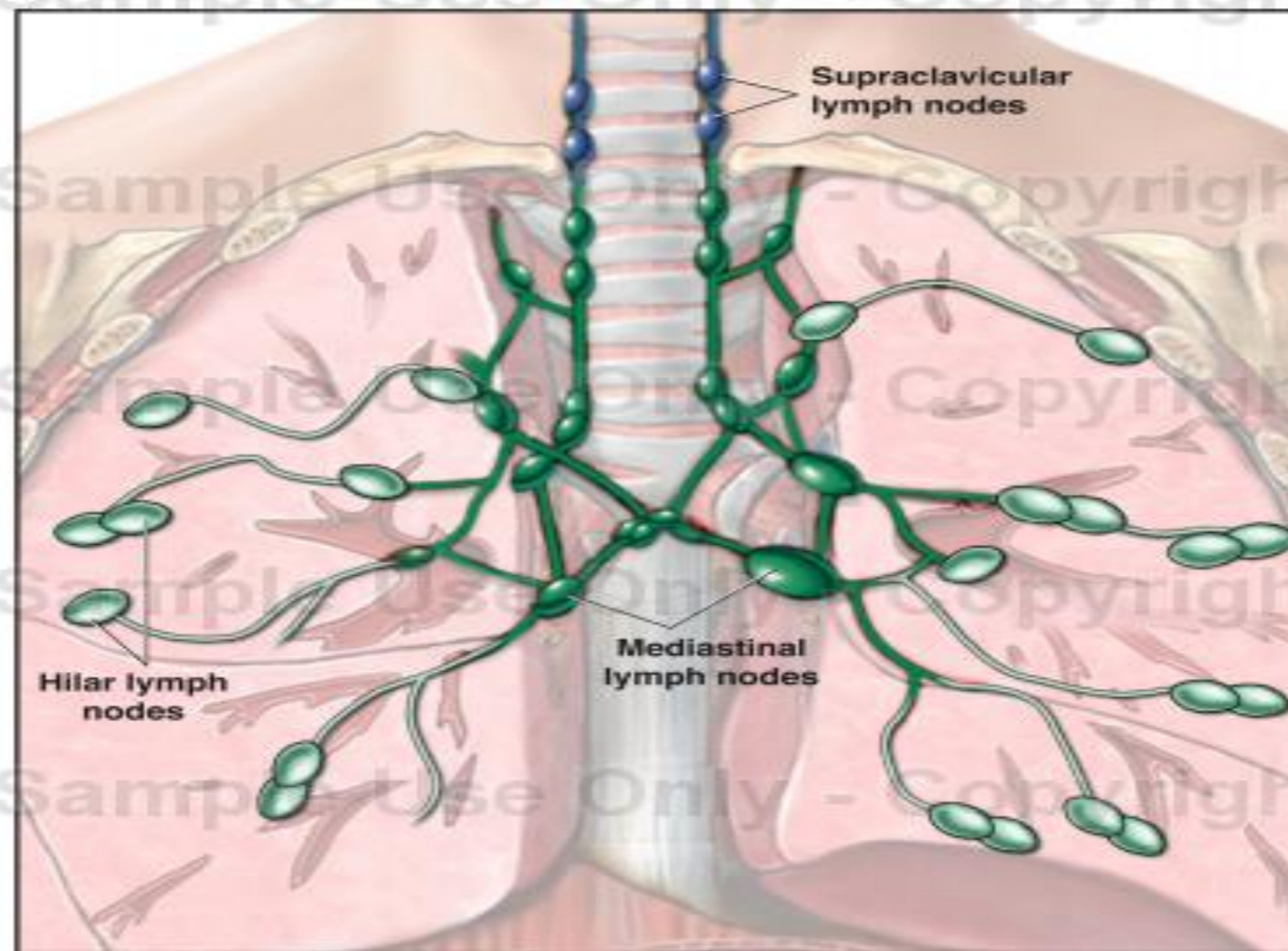
- example: Ovarian cancer.. tumour cells move through the peritoneal cavity and fill it with metastatic deposits.



# Lymphatic spread

- More in carcinoma , rare in sarcoma
- Pattern of lymph nodes affected depends on the site of primary tumor
- Tumors metastasize to **regional lymph nodes first**, however skip metastases can occur
- **Regional nodes**= nodes naturally draining that area
- **Skip mets**: spread to distant nodes skipping the regional ones!

## Lymph Nodes of the Thorax



Anterior Cut-away View

# Hematogenous spread

- Sarcomas spread mainly by hematogenous route
- Carcinomas also spread by this route but they metastasize to lymph nodes first ( via lymphatic route)
- Liver and lungs are the most common sites of spread ( most common recipients), because they receive a large amount of blood so metastatic deposits can colonize these sites.

# Benign vs malignant neoplasms

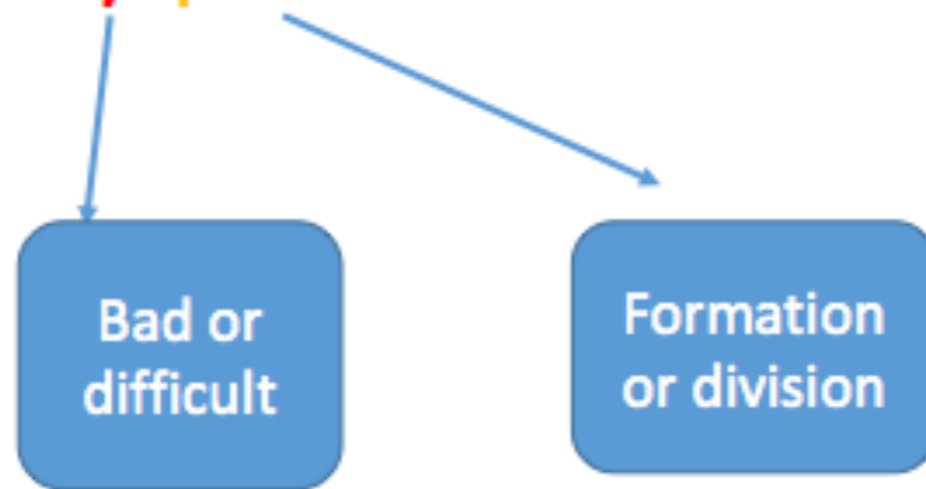
	Benign	malignant
genetics	Few mutations, clonal but genetically more stable	Genetically unstable
Macroscopic/ gross appearance	Soft, mobile, encapsulated	Hard, fixed, infiltrative
differentiation	Well differentiated	Well or poor , anaplastic
Mitosis/ rate of growth	low	High, abnormal mitoses
Local invasion	localized	invasive
metastasis	no	yes



- So: we now know the differences between benign and malignant tumours.
- Let's now discuss two important terms: dysplasia and carcinoma in situ.
- These two are precancerous lesions, occurring mainly on mucosal surfaces.. they are preneoplastic and with time they can progress to neoplasia.

# Dysplasia = خَلَلُ النِّسْجِ

- **Dysplasia** = from Greek word

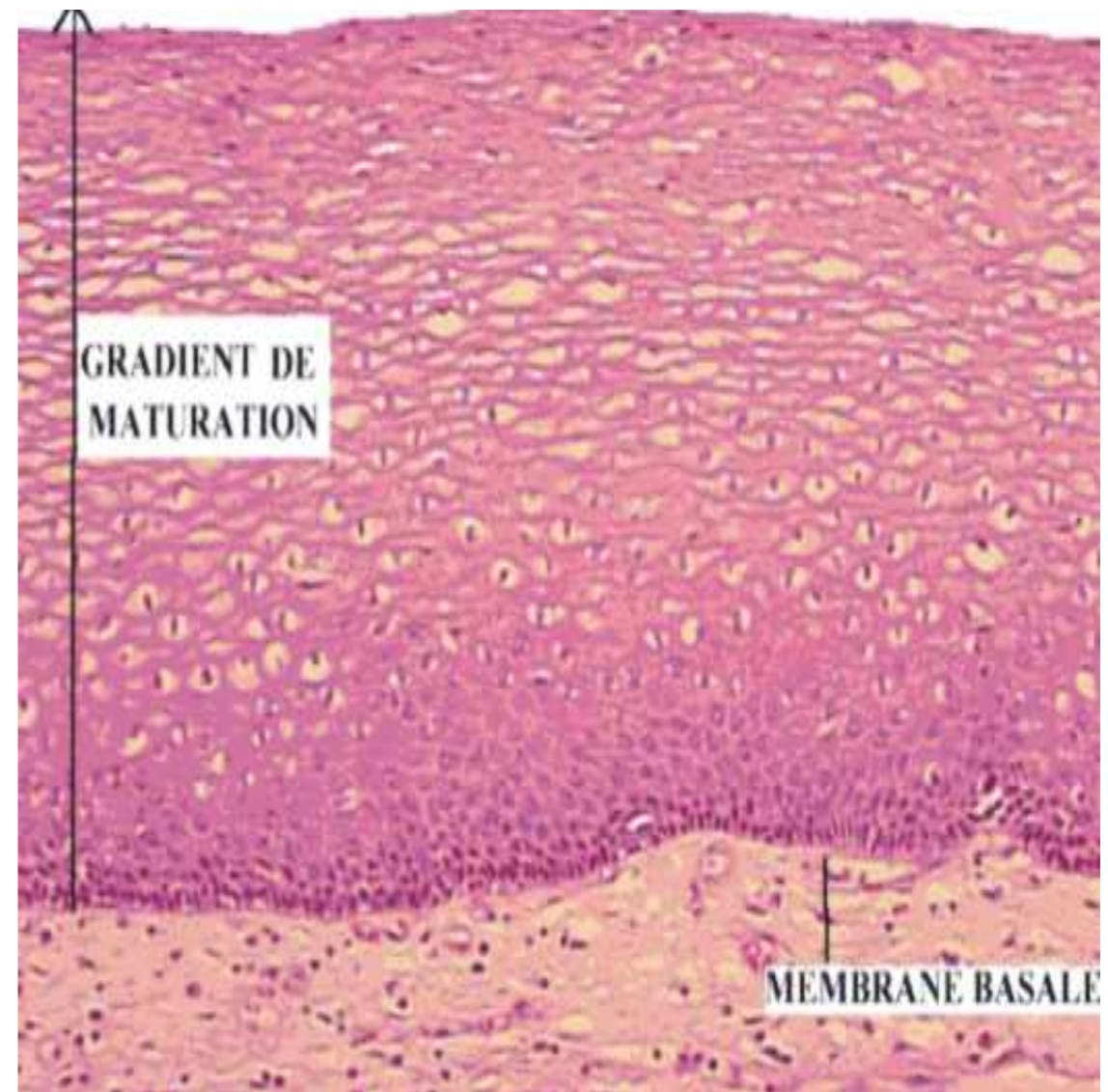


# Normal epithelium

- Normal epithelium is well organized.
- It is composed of layers of cells that mature as we go up: towards the surface.
- Epithelial tissue regenerates all the time, so cells originate from the base of the epithelium and grow upwards.
- During this growth they mature.. and when they reach the surface they spend the rest of their lifespan as fully mature cells then they die by apoptosis.

# Normal epithelium

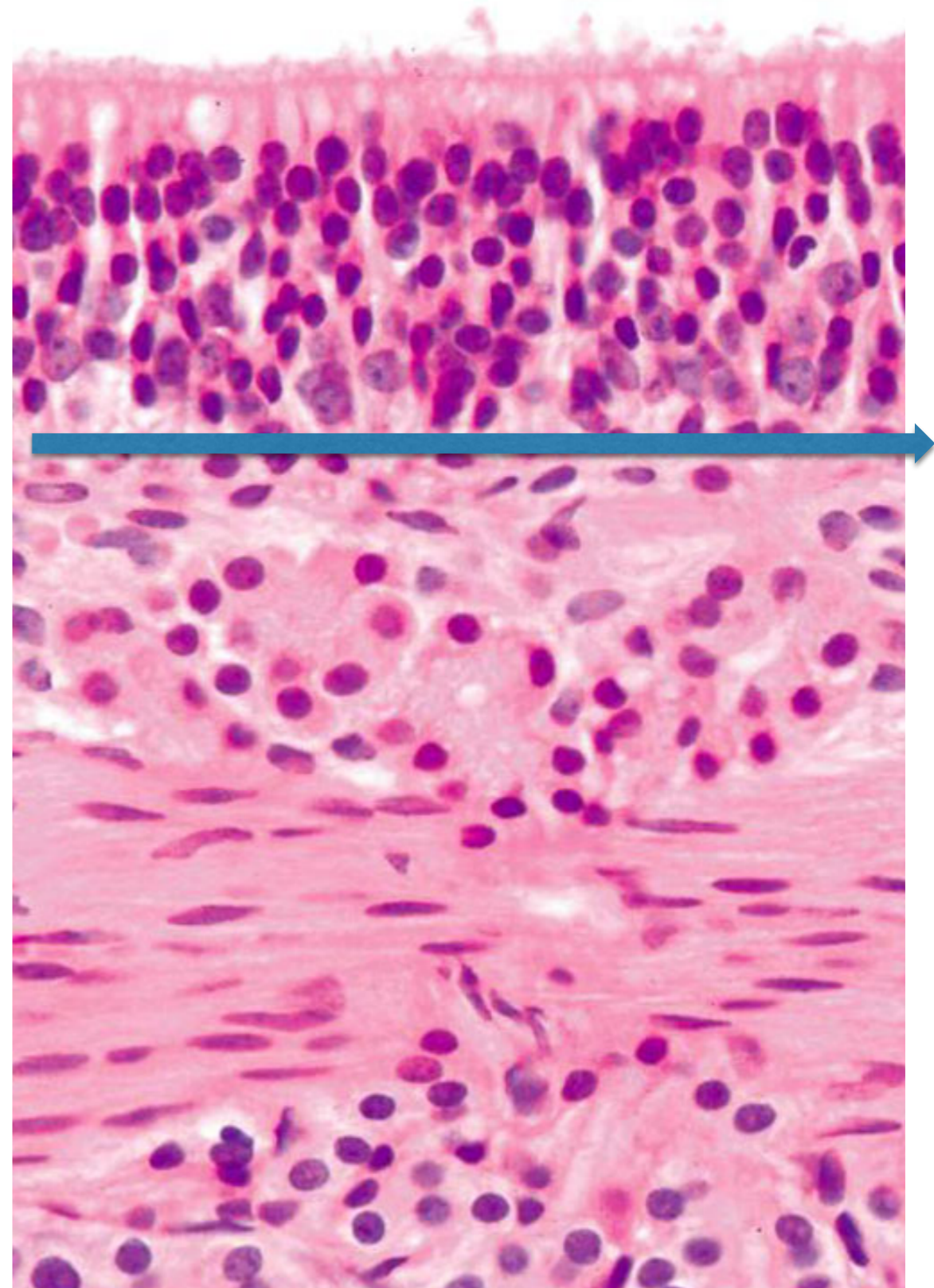
- Note that this epithelium is composed of several layers of squamous cells.
- They are all organized
- The cells look similar with slight differences; they mature towards the top.
- There is an intact, non invaded, basement membrane.



# Normal Respiratory epithelium

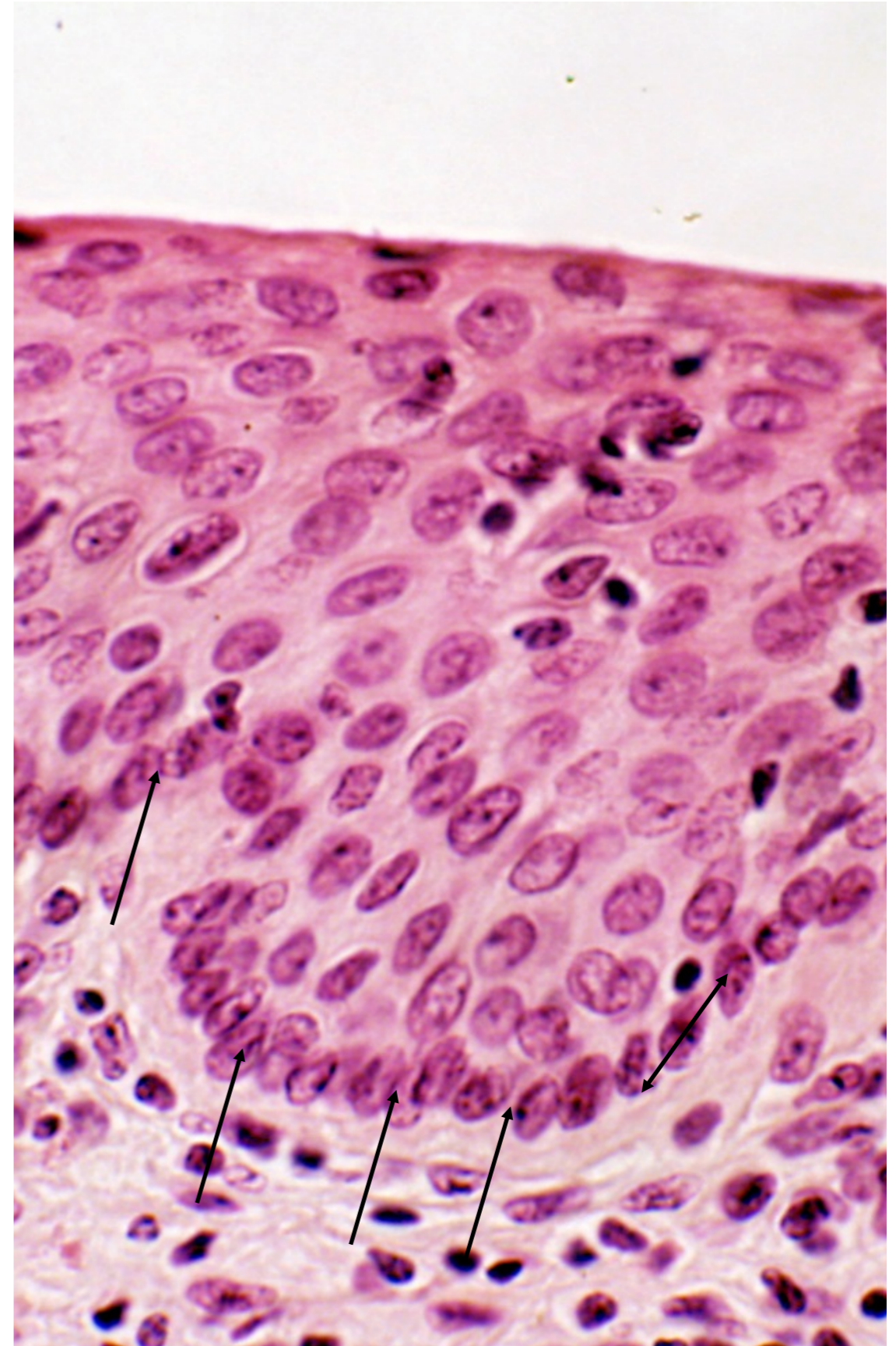
This is another example of normal epithelium

Note that we can draw a line at the base.. This resembles the cells at the base forming the basal layer which is intact in dysplasia ( because dysplasia is confined to the epithelium)



# Basal layer in normal epithelium

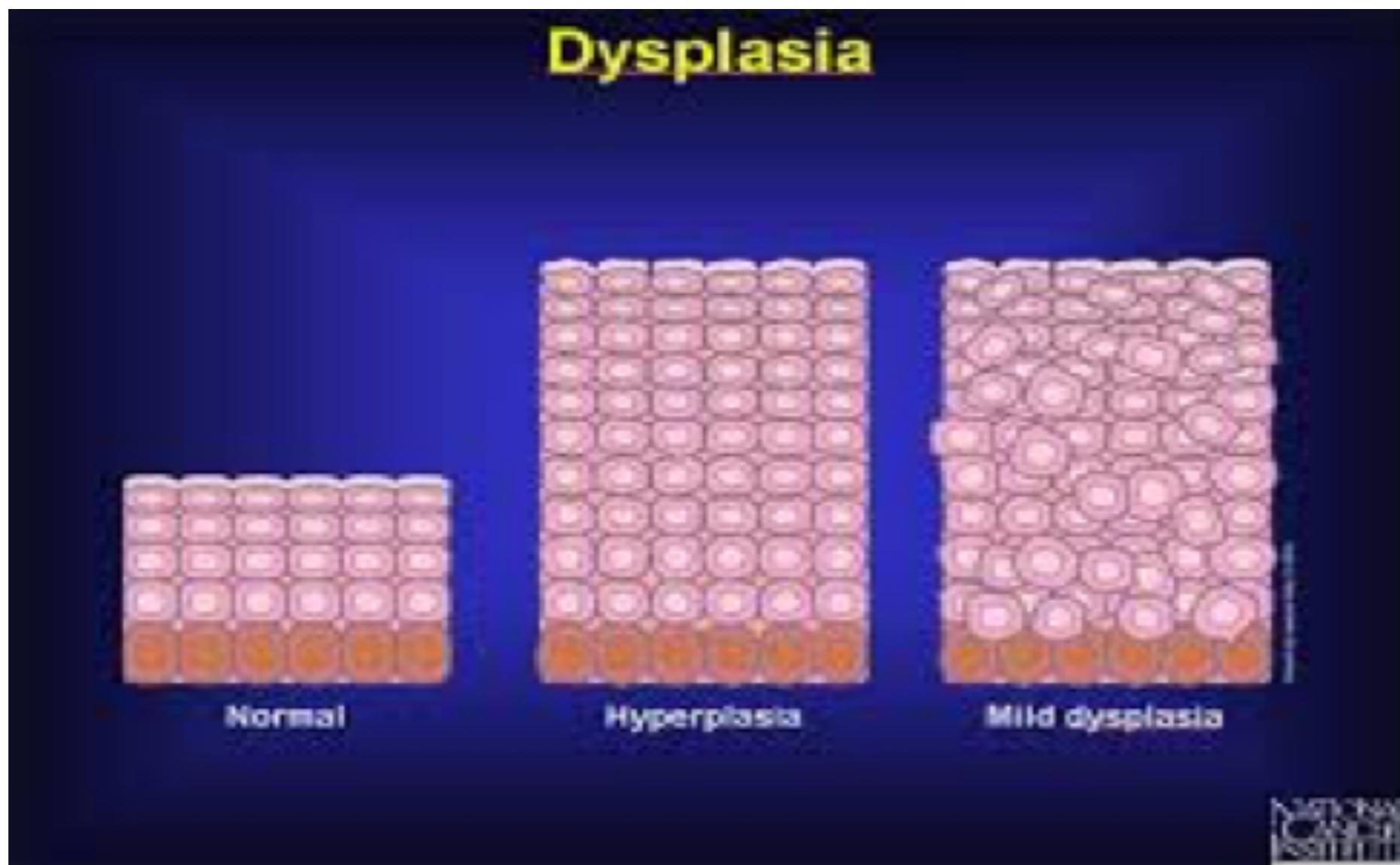
Note the cells with arrows at the base of this epithelium  
They are nice and intact and form a continuous, undisturbed layer



# Dysplasia

- Disordered but **non-neoplastic** proliferation confined to the mucosa without affecting the underlying tissue.
- Loss of uniformity of individual cells and in their architectural orientation
- Expansion of immature cells
- Seen mainly in epithelial lesions

Note the ordered organised layers in the normal epithelium. this organisation is maintained in hyperplasia but lost in dysplasia.





# histologic features of dysplasia

.Loss of orientation

- Pleomorphis
- Large cells
- Hyperchromatic nuclei
- More mitoses than normal
- Mitosis in an abnormal location ( normal location is at the basal layers of epithelium...  
abnormal: mitosis seen in more superficial layers)

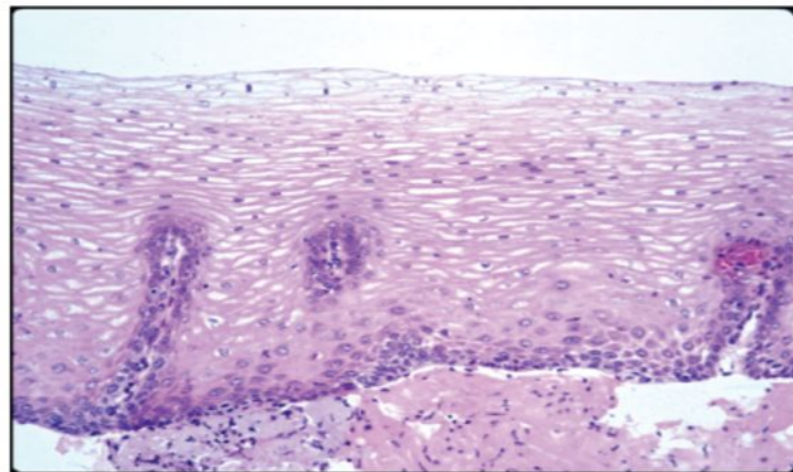
**NOTE:** many of these features are similar to those we discussed in anaplasia.. but here these changes are seen only within the epithelium without invading the basement membrane that separates the epithelium from the underlying tissue.

# Grades of dysplasia

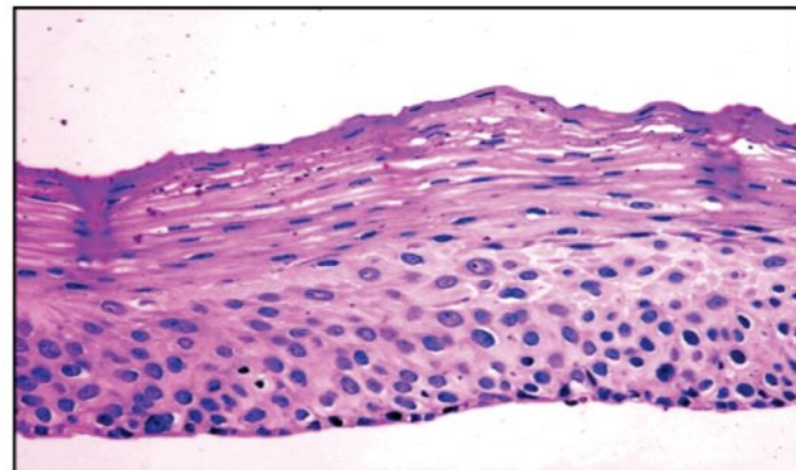
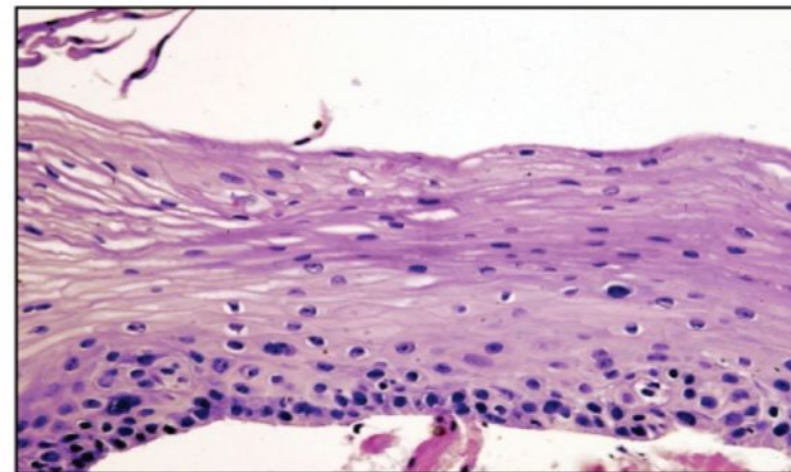
- Dysplasia is divided into mild , moderate and severe
- This depends on the extent of epithelial involvement.
- If only the lower third of the epithelium affected: mild
- Two thirds: moderate
- Full thickness: severe

This pic compares normal to dysplasia of several grades. Note that in all the basement membrane is intact as evidenced by the continuous basal cells.

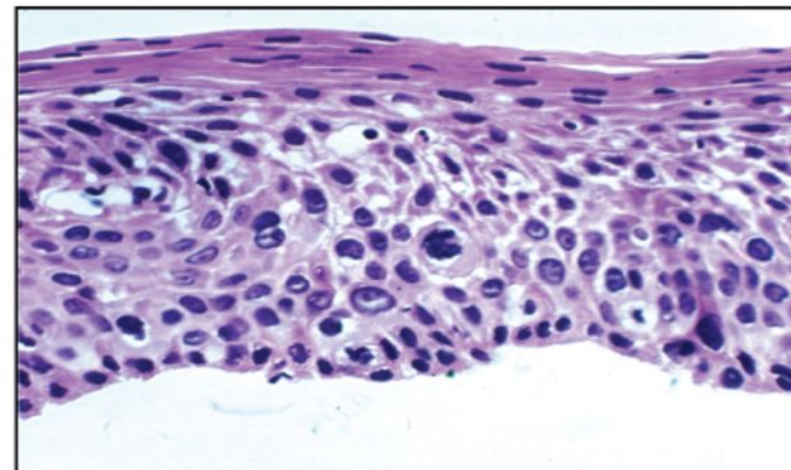
Normal



Mild dysplasia



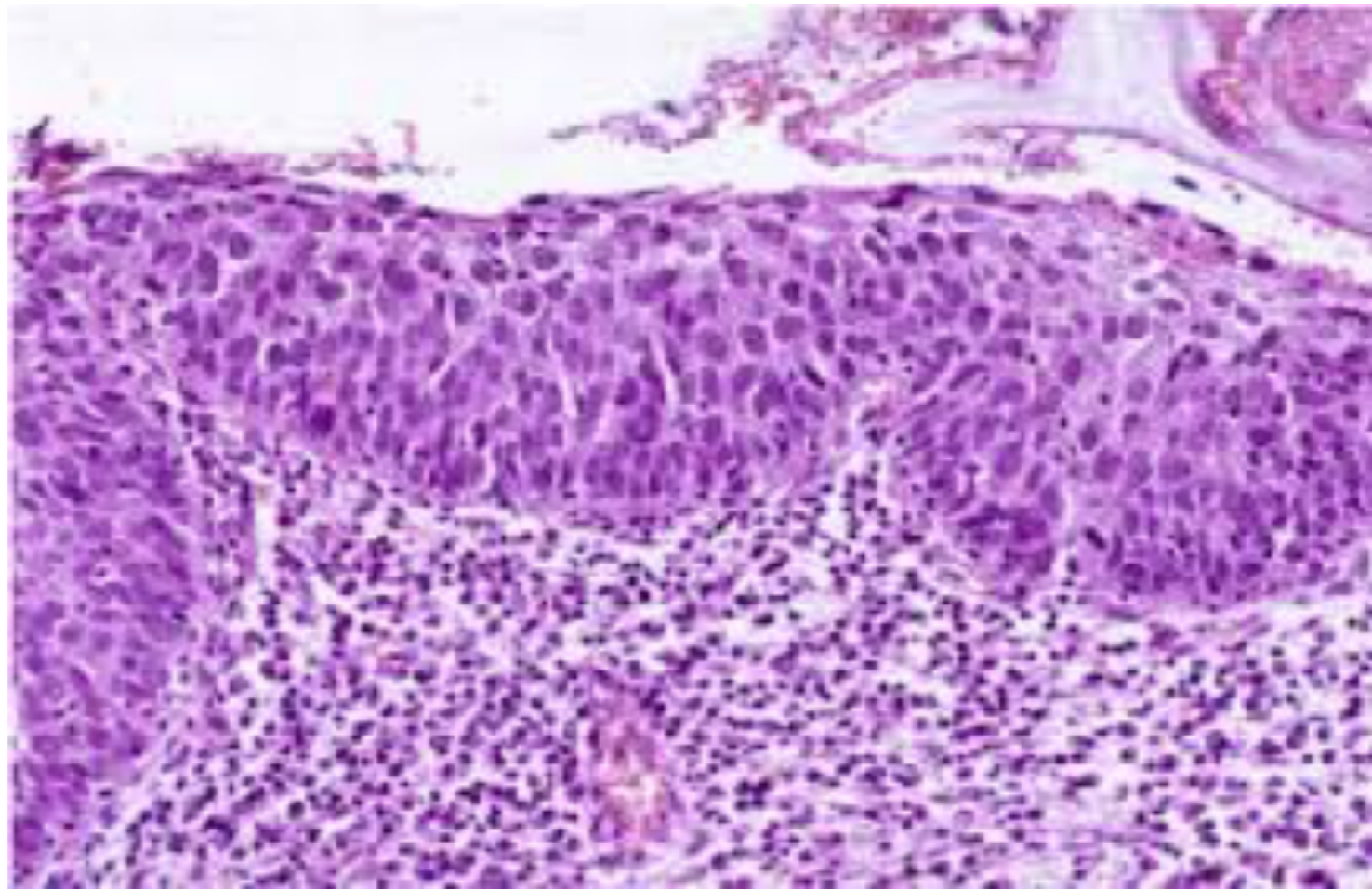
Moderate dysplasia



Severe dysplasia

- Pics

Severe dysplasia. This is the worst grade affecting almost all layers of the epithelium. The basement membrane is still intact.



# Behavior of dysplasia

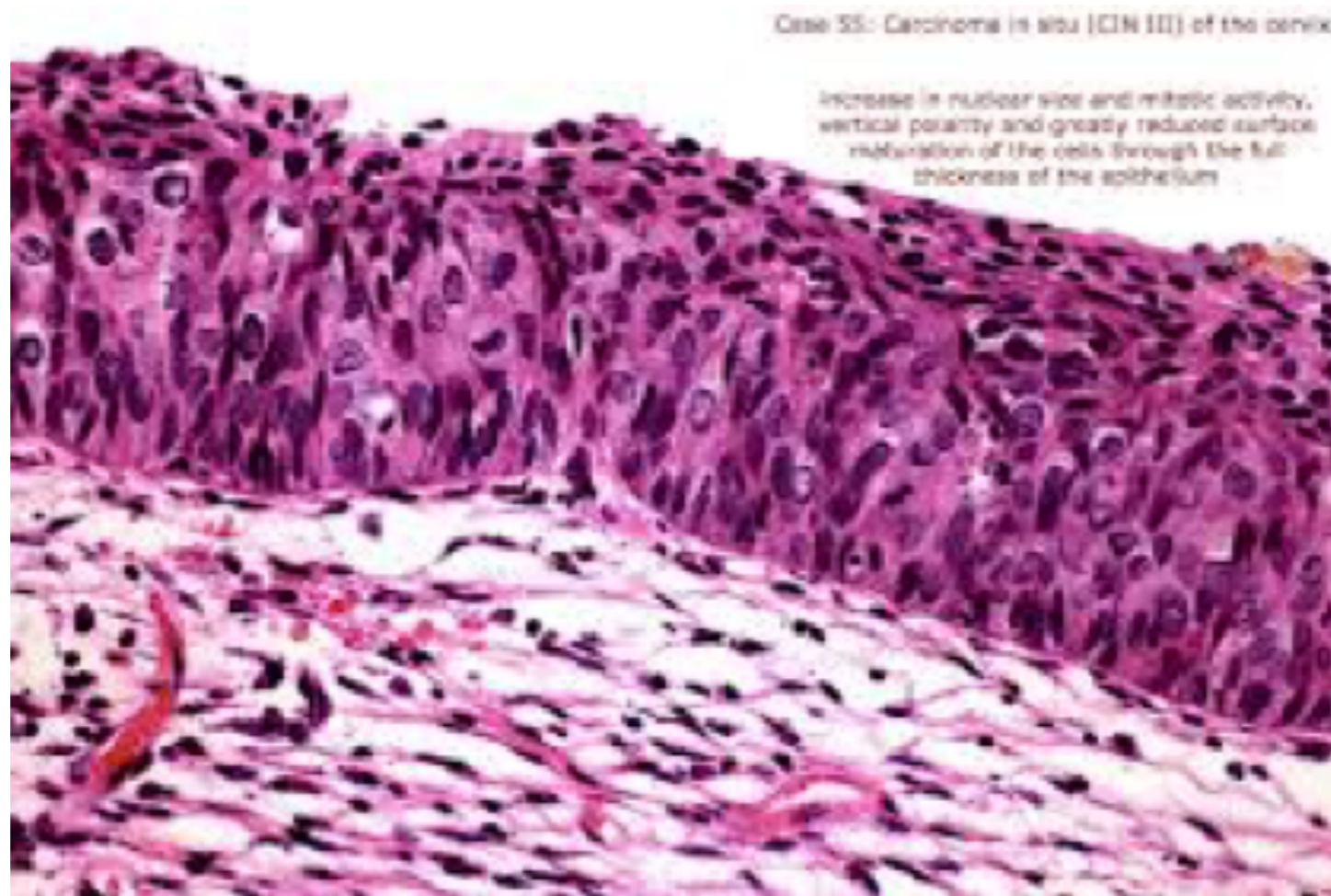- Although non neoplastic, dysplastic cells can accumulate mutations and transform to malignant lesions.. But not always and not commonly.
- Dysplasia is a precursor of malignancy.
- However, mild and even moderate dysplasia Can regress if initial insult removed

# In situ carcinoma

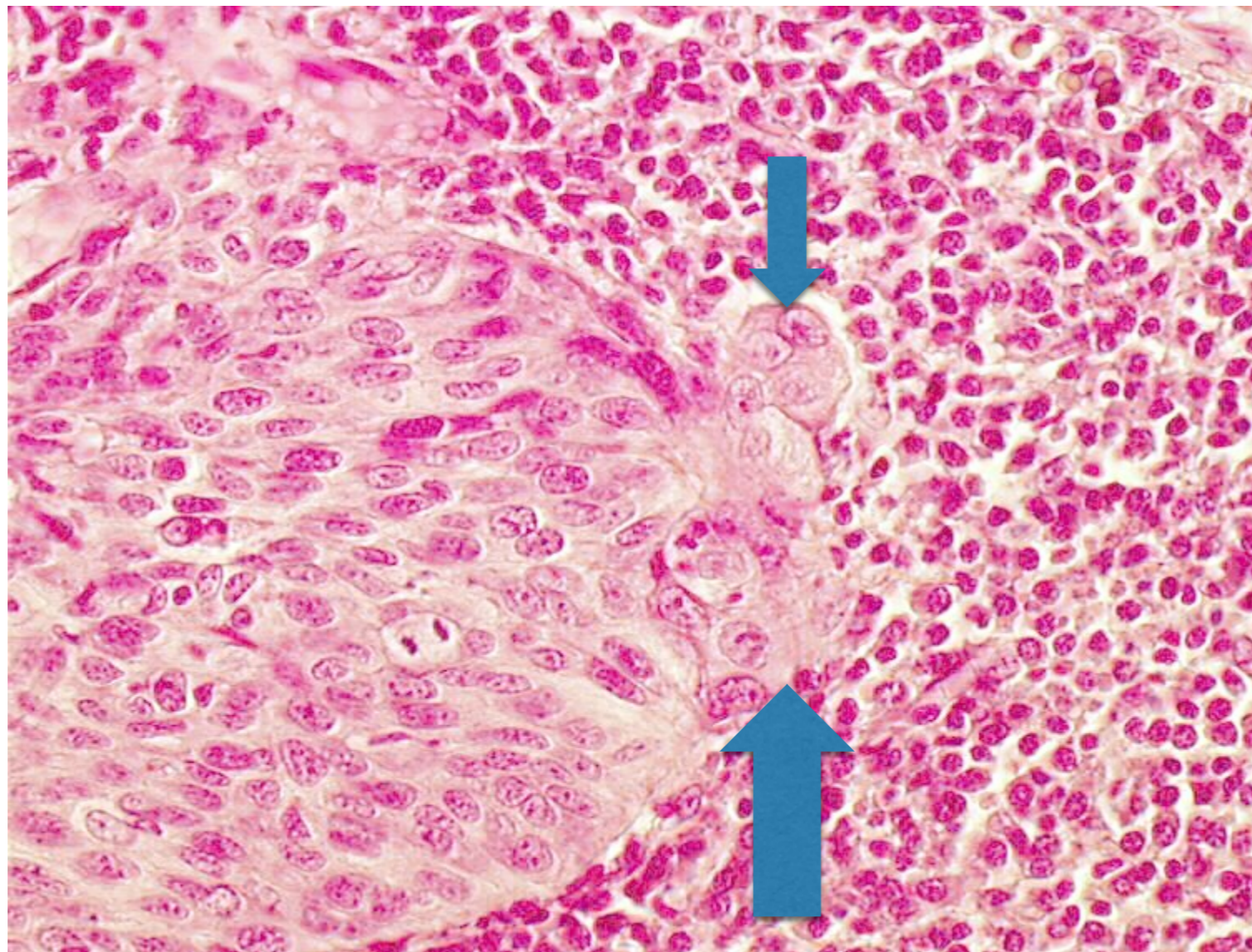
- Means= severe dysplasia involving the **whole thickness** of the epithelium

Again: basement membrane intact... that's why it is “in situ”

# Carcinoma in situ



Look at this now: there is dysplasia but it is invading the basement membrane (arrows). This is a microinvasive carcinoma





# recap

- There are certain changes that can affect epithelial tissue before it gets fully carcinomatous.
- Abnormal organization of abnormal cells confined to the mucosa; this is dysplasia
- Dysplasia can be divided to three grades: mild, moderate and severe.
- Mild dysplasia affects the lower third of the epithelium
- Moderate: affects the lower two thirds
- Severe: involves almost the full thickness.
- Carcinoma in site is the worst, severest form of dysplasia. It involves the entire thickness, and the individual cells are very pleomorphic and anaplastic.
- The basement membrane is intact in all these stages
- If the abnormal cells invade the basement membrane, then the lesion has transformed to micro-invasive carcinoma.
- Microinvasive carcinoma can spread further to become an invasive carcinoma.

# Summary 1/2

Benign tumors tend to be well differentiated, encapsulated, non-invasive, slowly growing and they do not metastasize.

Malignant tumours are anaplastic, rapidly growing, invading masses and they do metastasize.

. Metastasis occurs via three routes:

1. lymphatic spread where the tumour cells invade lymphatics and colonize lymph nodes. Carcinomas spread first by this route. Sarcomas rarely spread by lymphatics.
2. Hematogenous : tumour cells invade blood vessels and reach distant organs. Sarcomas spread by this route. Carcinomas also use it.
3. Peritoneal seeding: occurs when a tumour in a site in close proximity to a peritoneal surface, usually the ovary or appendix, seeds the surface.

# Summary 2/2

- Dysplasia means disorganized growth confined to a mucosal surface. It is not neoplastic but can progress to neoplasia.
- Carcinoma in situ is full thickness atypia not invading the underlying tissue.
- Microinvasive carcinoma occurs when the carcinoma in situ cells penetrate the basement membrane.

These are microscopic descriptions of certain lesions. Decide if they are benign, malignant, dysplastic, in situ or microinvasive:

- 1. A mass composed of squamous epithelial cells with a high mitotic rate and atypical mitoses. There is nuclear pleomorphism, hyperchromasia and prominent nucleoli.
- 2. A well circumscribed lesion composed of proliferation of smooth muscle cells with occasional mitotic figures. There is no cellular atypia or pleomorphism.
- 3. Cervical biopsy showing loss of maturation of the lower two thirds of the epithelium with several basal mitoses. There is superficial maturation, and the basement membrane is intact
- 4. Cervical biopsy showing full thickness atypia and superficial mitoses. Occasional atypical cells are seen within the submucosa.

# Answers

- 1. A mass composed of squamous epithelial cells with a high mitotic rate and atypical mitoses. There is nuclear pleomorphism, hyperchromasia and prominent nucleoli. **malignant**
- 2. A well circumscribed lesion composed of proliferation of smooth muscle cells with occasional mitotic figures. There is no cellular atypia or pleomorphism. **benign**
- 3. Cervical biopsy showing loss of maturation of the lower two thirds of the epithelium with several basal mitoses. There is superficial maturation, and the basement membrane is intact. **dysplasia**
- 4. Cervical biopsy showing full thickness atypia and superficial mitoses. Occasional atypical cells are seen within the submucosa. **microinvasive**

