



# Cranial cavity

Dr. Heba Kalbouneh

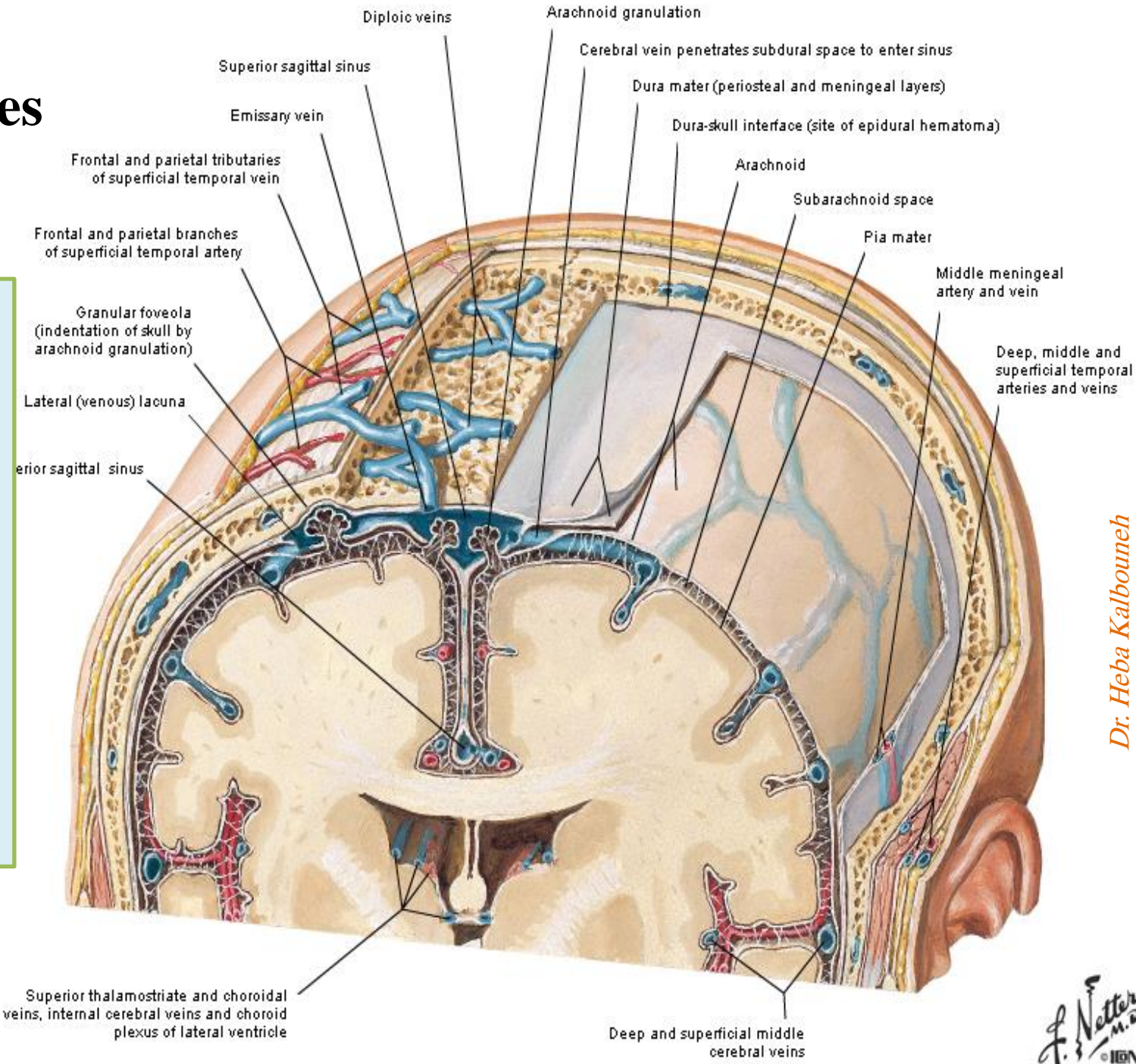
DDS, MSc, DMD/PhD

Professor of Anatomy, Histology and Embryology

# The Meninges

The brain in the skull is surrounded by three membranes or meninges:

- Dura mater**
- Arachnoid mater**
- Pia mater**



Dr. Heba Kalbouneh

F. Netter M.D.

# 1-Dura mater

Made of two layers:

- a- The periosteal layer
- b- The meningeal layer

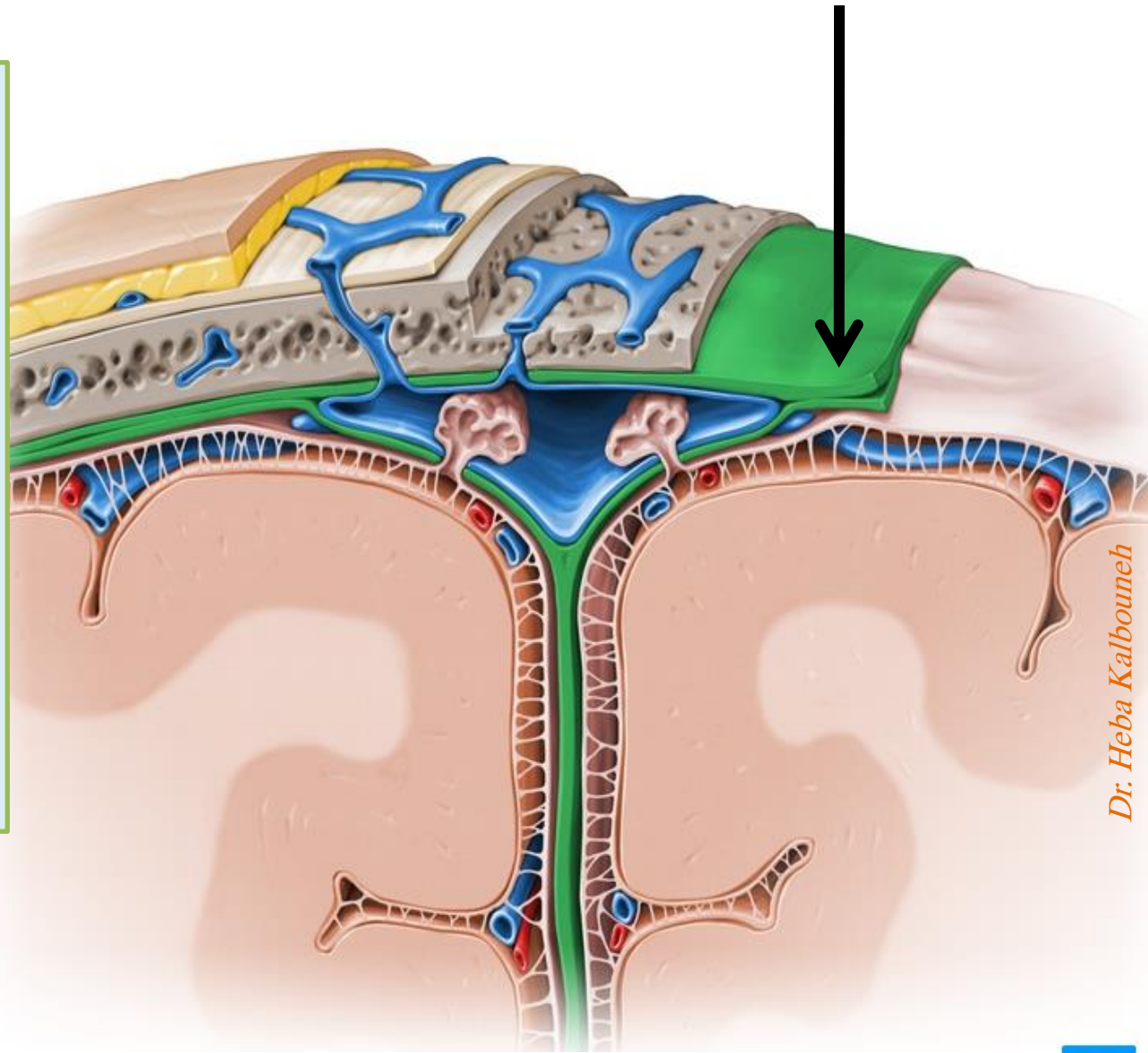
These are closely united except along where they separate to form



1- VENOUS SINUSES

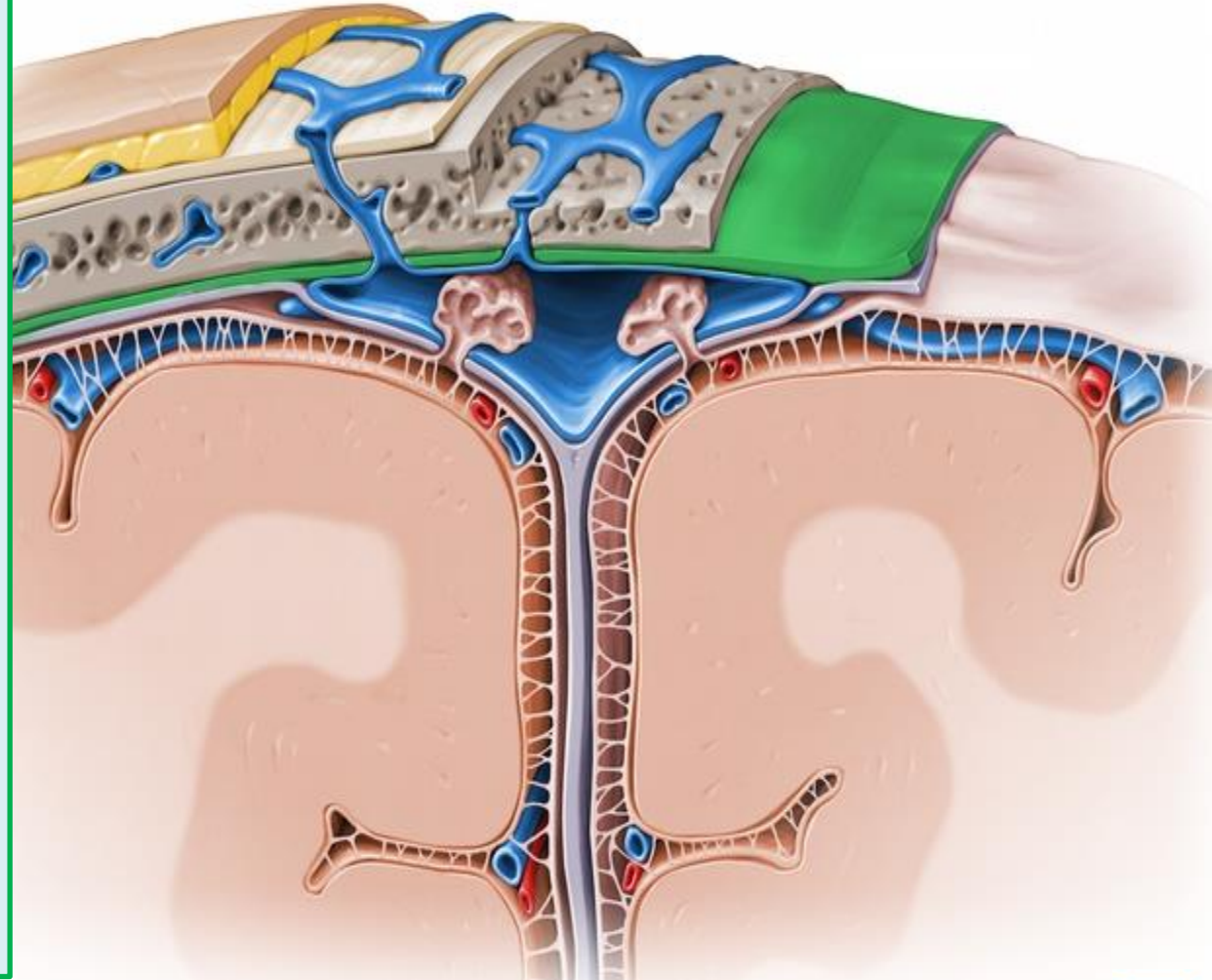
2- DURAL FOLDS

Contains meningeal arteries



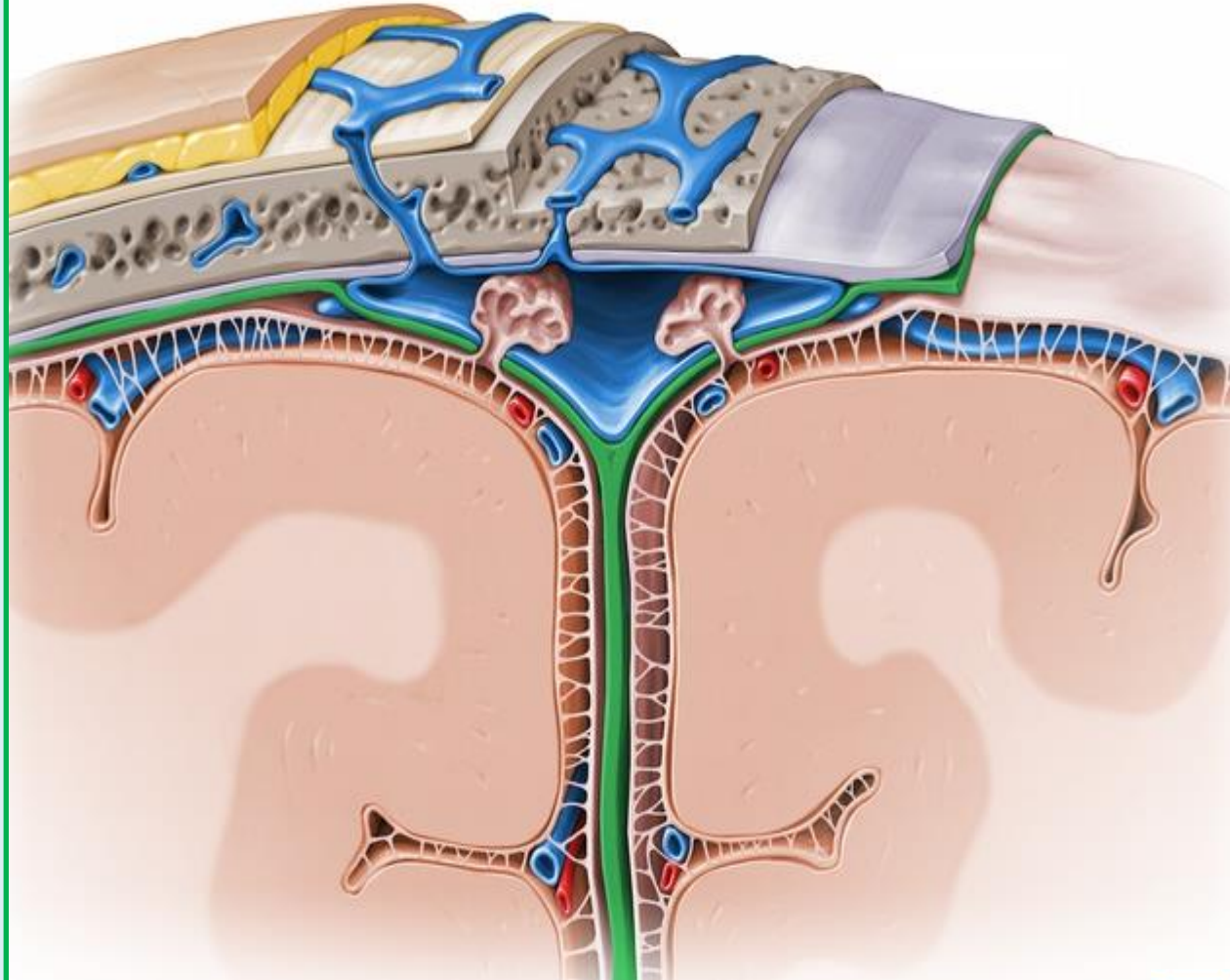
## A-The periosteal (endosteal) layer

- Is the ordinary periosteum covering the inner surface of the skull bones
- It **does not extend** through the foramen magnum
- Around the margins of all the foramina in the skull it becomes continuous with the periosteum on the outside of the skull bones
- At the sutures it is continuous with the sutural ligaments.



## B-The meningeal layer


- Is the dura mater proper
  - It is a dense, strong, fibrous membrane
- Covers the brain and is **continuous** through the foramen magnum with the dura mater of the spinal cord
- It provides tubular sheaths for the cranial nerves as they pass through the foramina in the Skull
- Outside the skull the sheaths fuse with the epineurium of the nerves



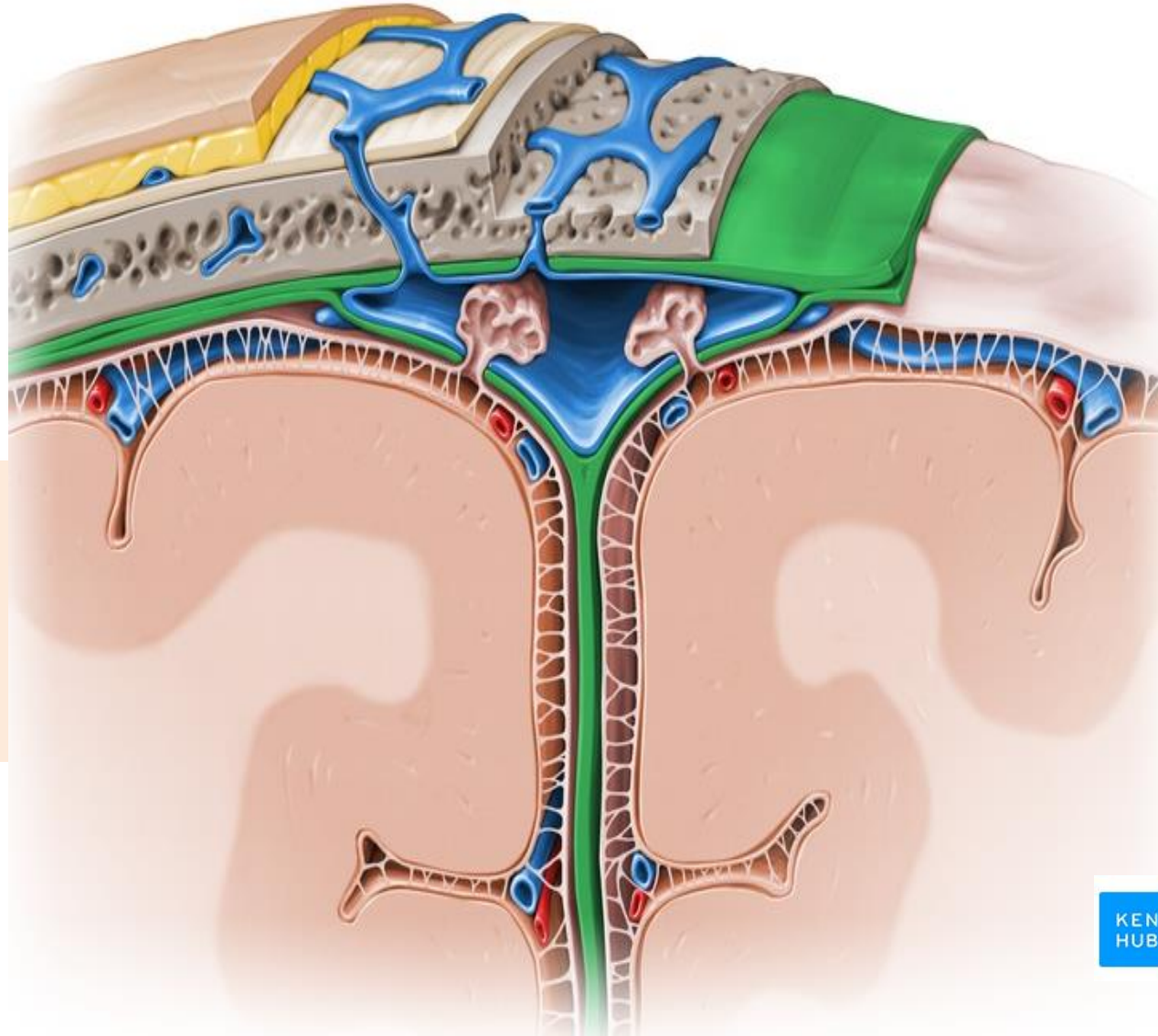
The two layers of dura separate from each other at numerous locations to form two unique types of structures:

- 1- **Dural folds (partitions):** incompletely separates parts of the brain
- 2- **Venous sinuses:** Intracranial (dural) venous sinuses

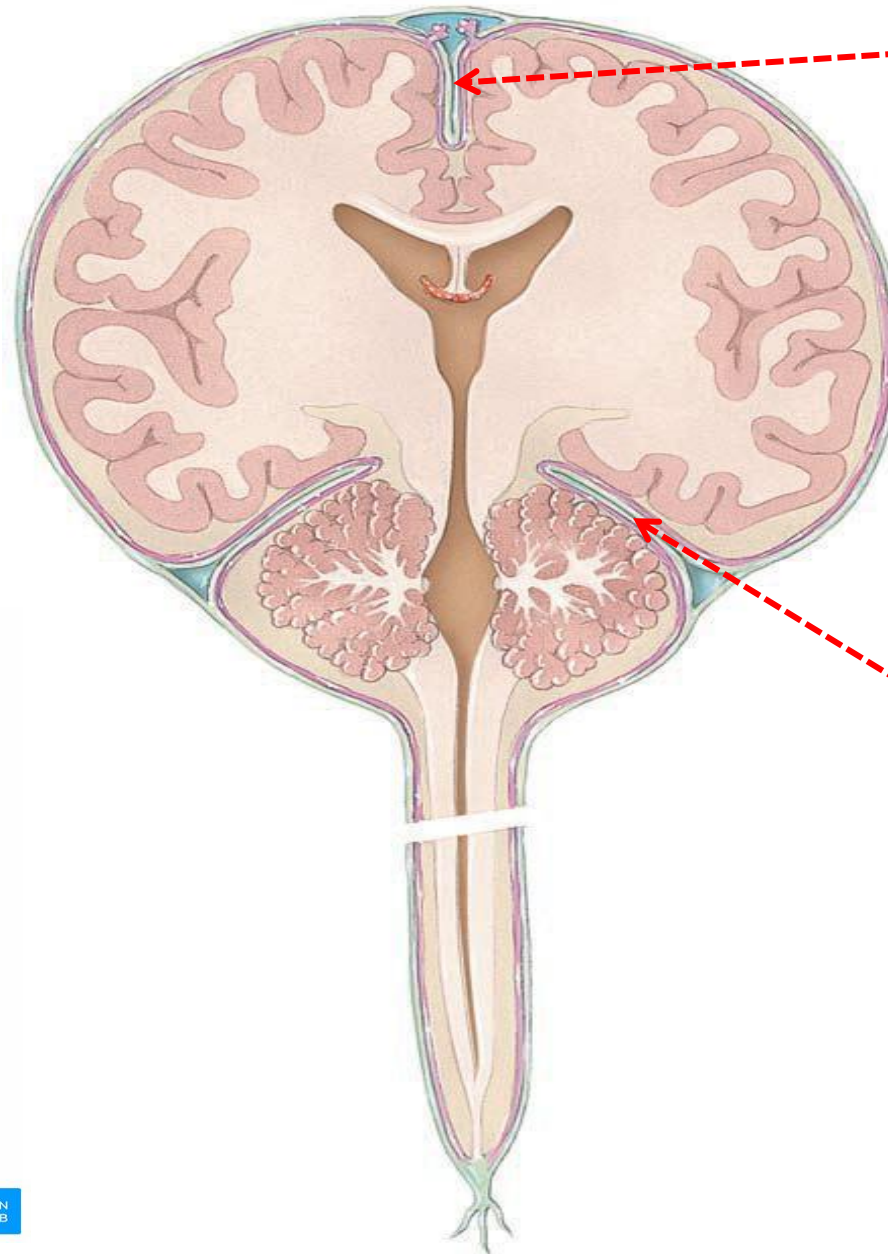
The meningeal layer  
sends inward  
**FOUR SEPTA**



- 1- Falx cerebri
- 2- Falx cerebelli
- 3- Tentorium cerebelli
- 4- Diaphragma sellae

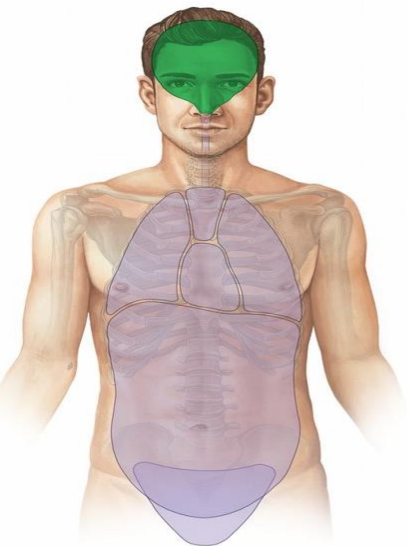


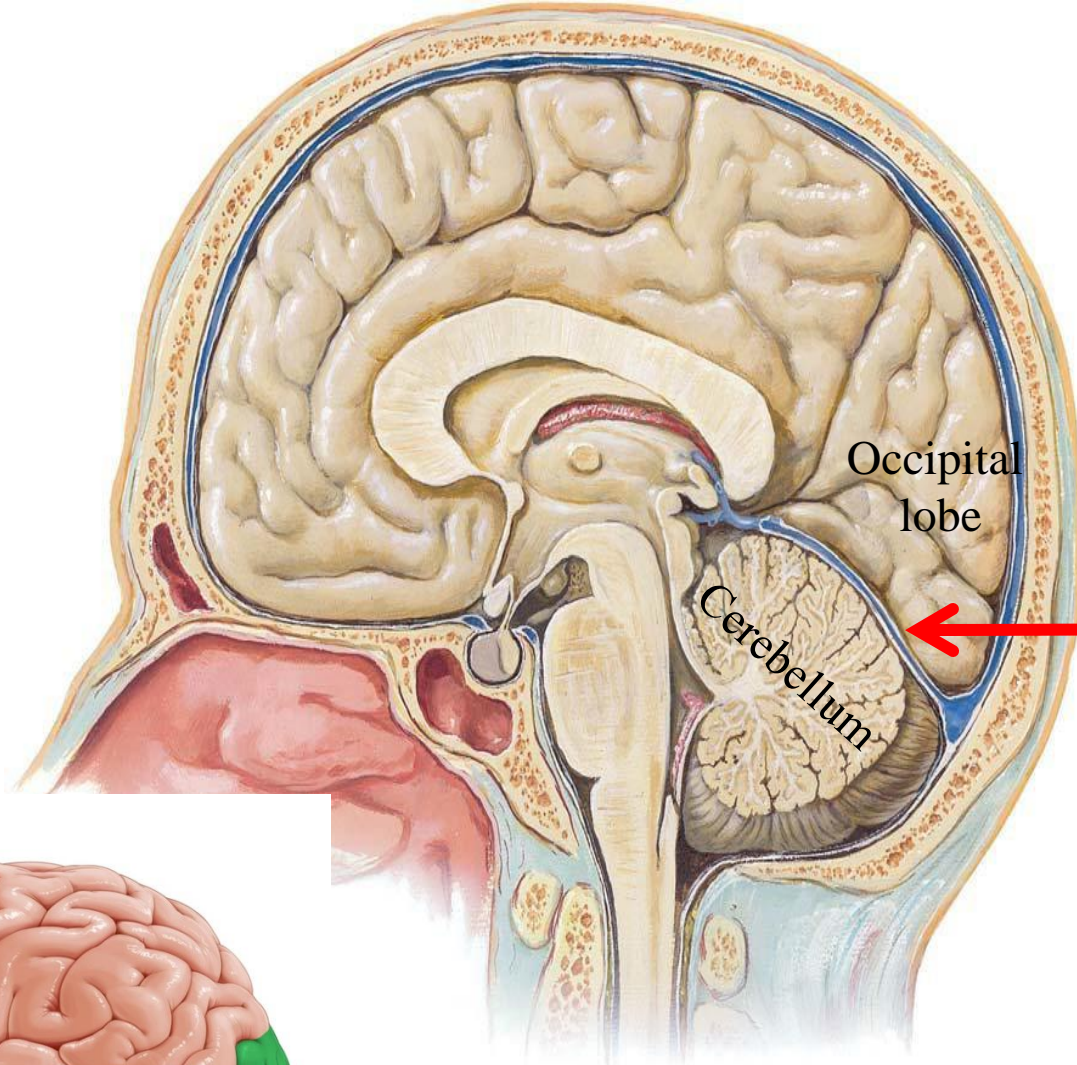
The meningeal layer sends inward **SEPTA**



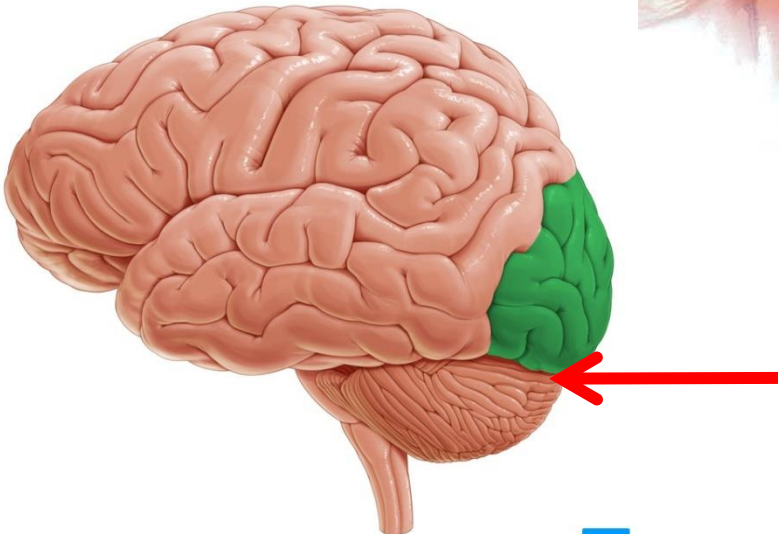
Vertical fold of dura

Horizontal fold of dura





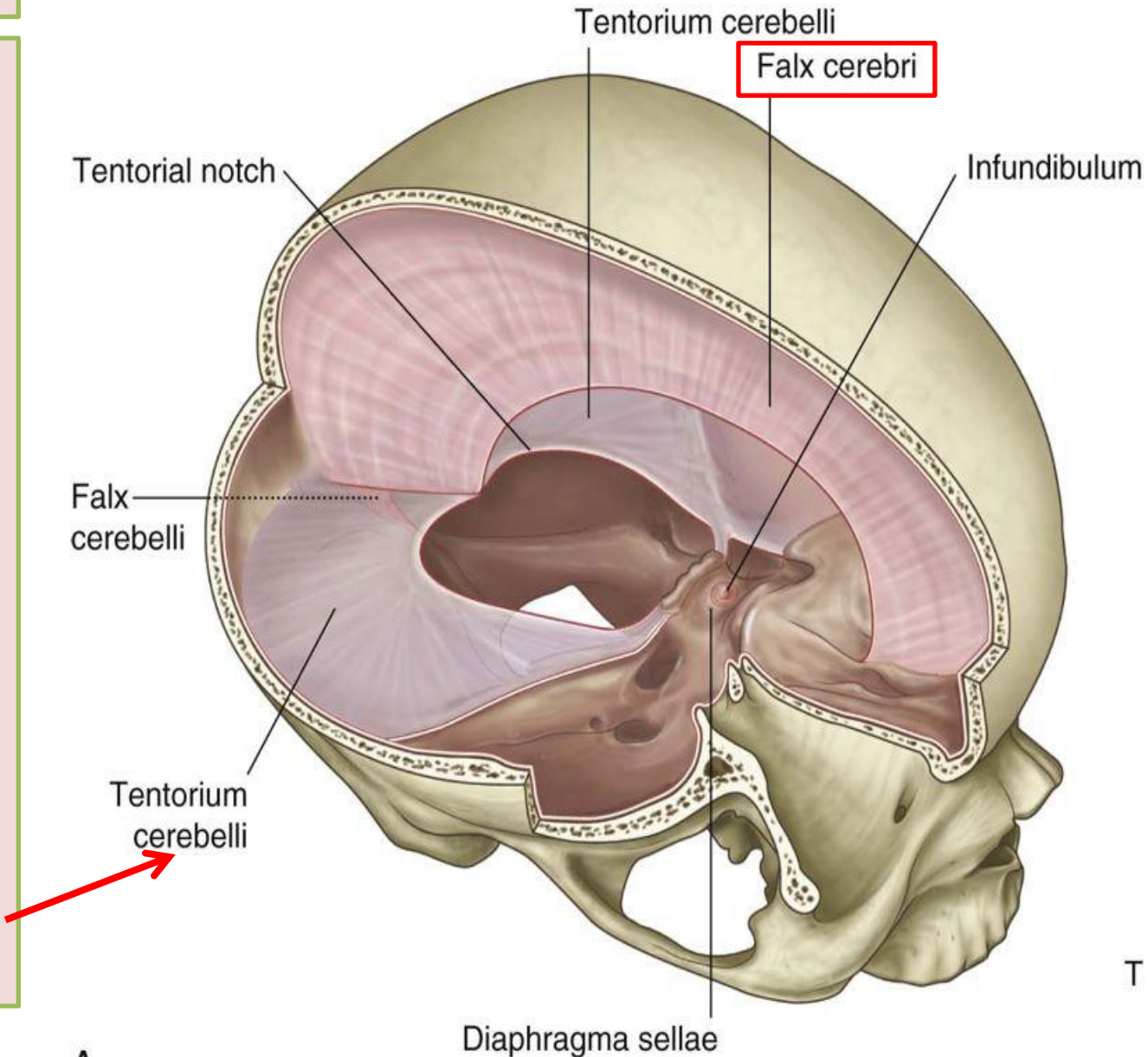
Horizontal fold of dura





# 1-Falx cerebri

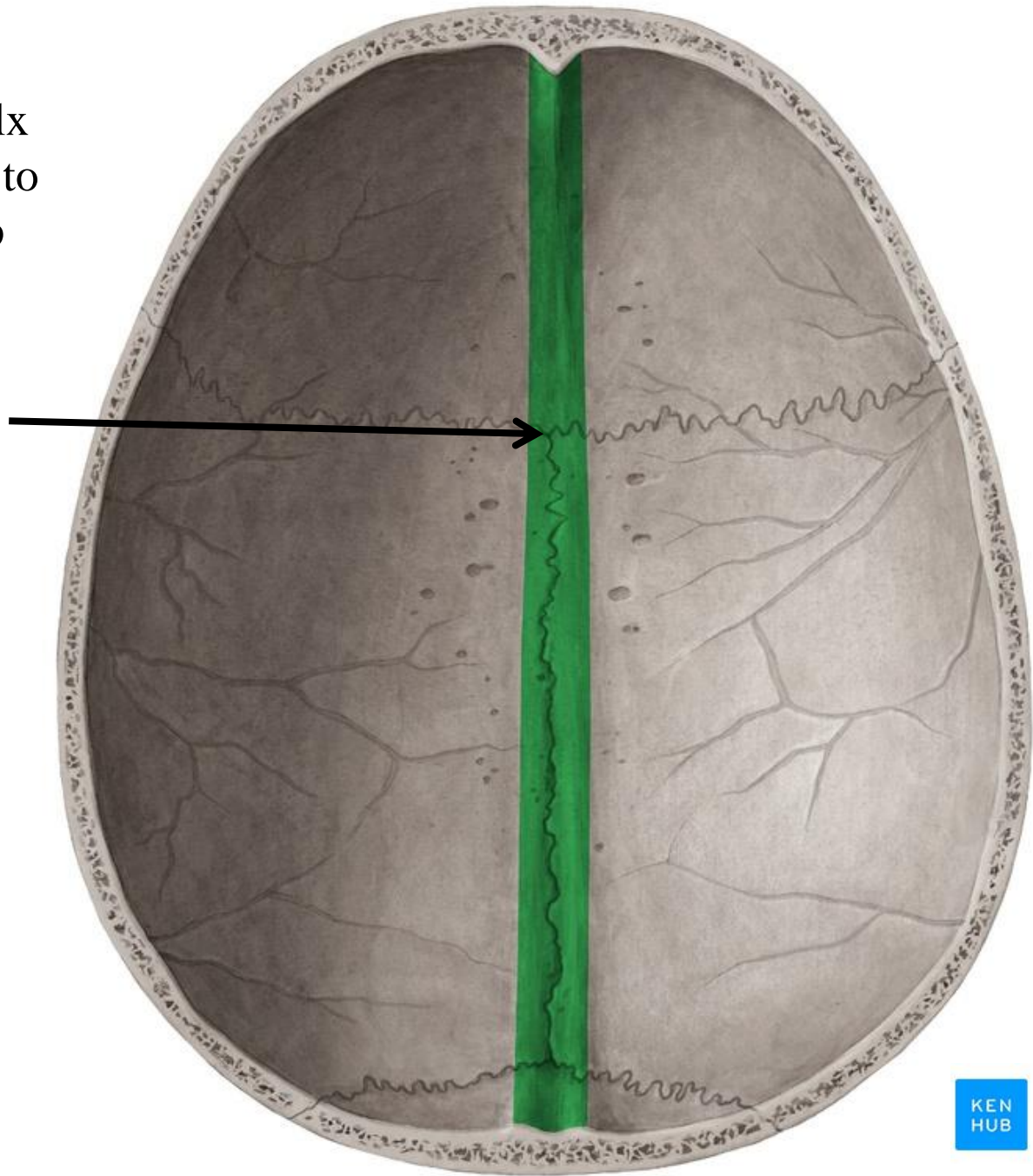
- Is a sickle-shaped fold of dura mater
  - Lies in the midline between the two cerebral hemispheres
  - In front: it is attached to the **crista galli and frontal crest**
  - Its posterior part blends in the midline with the upper surface of the **Tentorium cerebelli**



A

T

The upper fixed border of falx cerebri is attached at midline to internal surface of skull cap



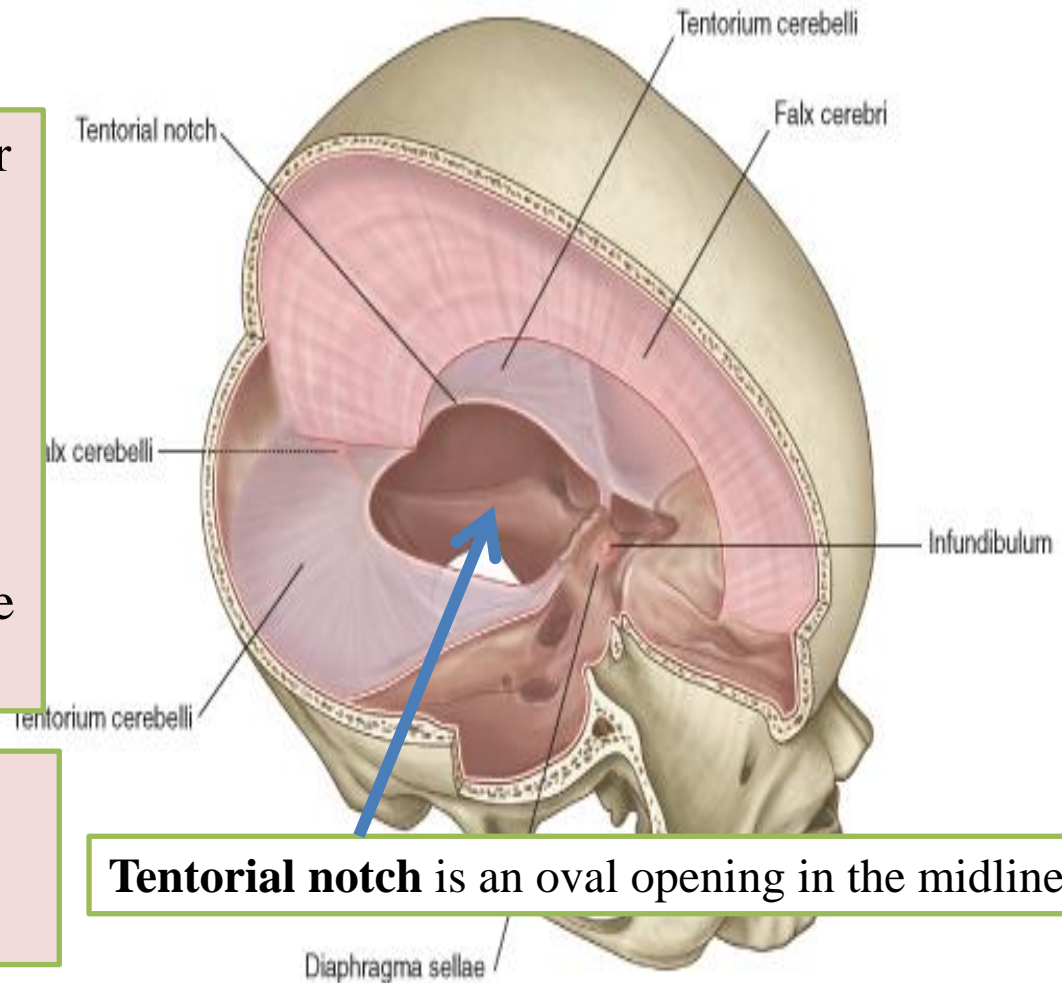
# Tentorium cerebelli

- Is a tent-shaped fold of dura mater (horizontal projection)
- Roofs over the posterior cranial fossa
- Divides the cranial cavity into:  
**1-SUPRATENTORIAL**  
**2-INFRATENTORIAL**
- Separates the cerebellum from the occipital lobes

Ends anteriorly at the anterior and posterior clinoid processes

It is attached by its convex border:

- behind:** to the occipital bone along the grooves for the transverse sinuses
- in front:** to the superior border of the petrous part of the temporal bone on either side, enclosing the superior petrosal sinuses



**Tentorial notch** is an oval opening in the midline

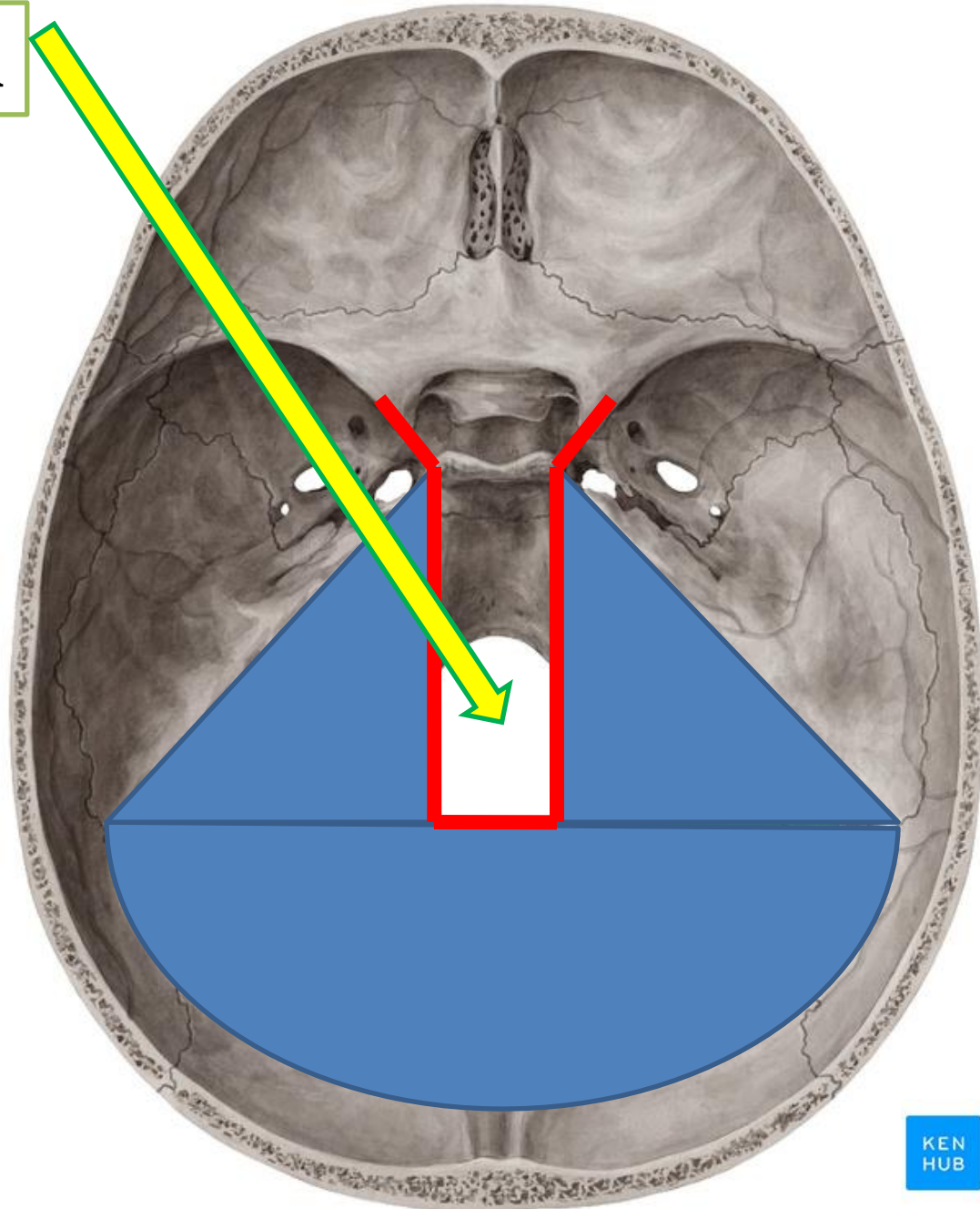
# Tentorial notch

Tentorium cerebelli attachments

Anterior and posterior clinoid processes

Superior borders of the petrous part of the temporal bone (enclosing the superior petrosal sinuses)

Occipital bone (Grooves for the transverse sinuses)



### 3- Falx Cerebelli

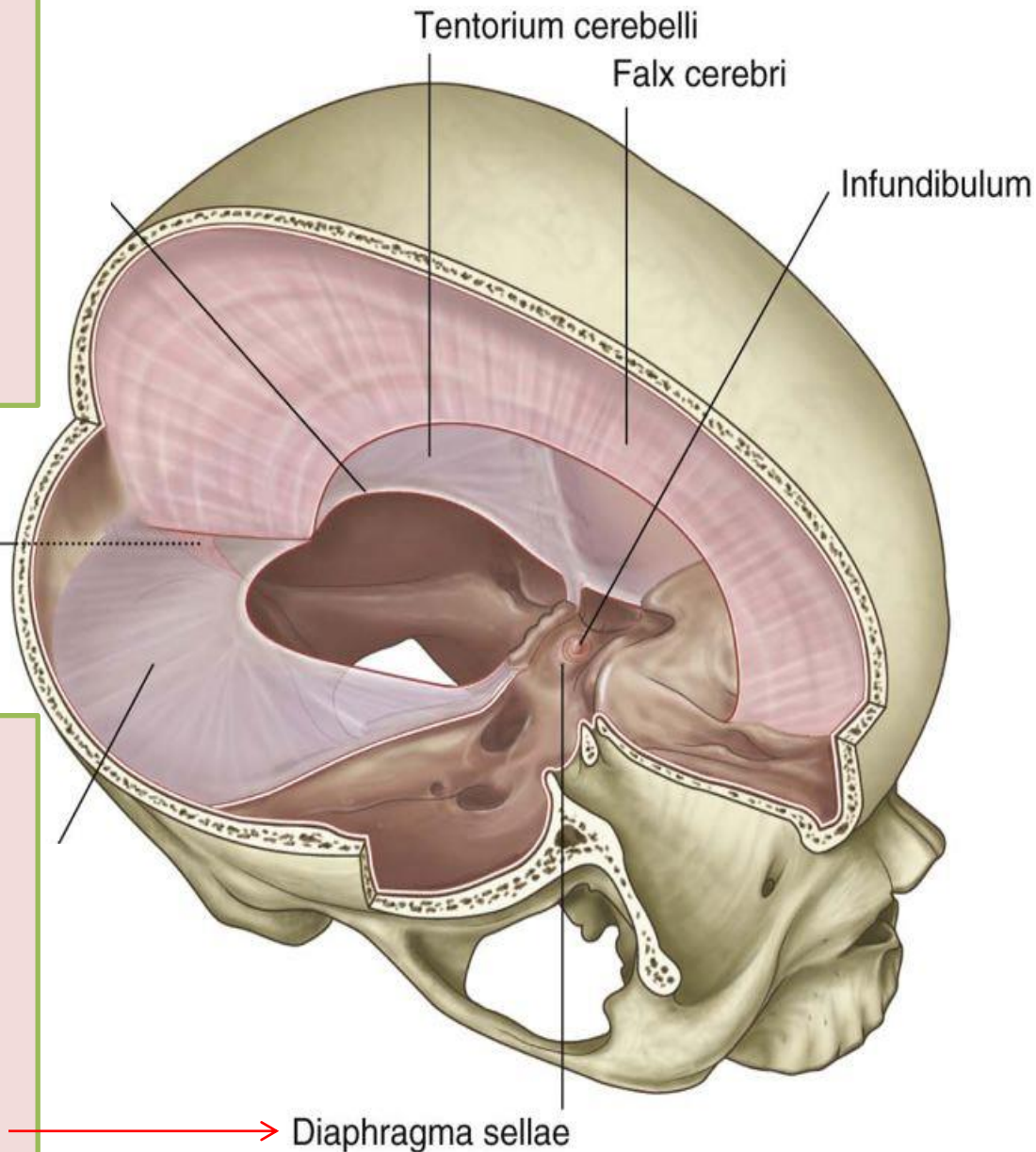
- Is a small vertical fold of dura mater
- Attached:
  - Posteriorly** to internal occipital crest
  - Superiorly** to tentorium cerebelli
- Lies in the midline between the two cerebellar hemispheres

Falx cerebelli

### 4-Diaphragma sellae

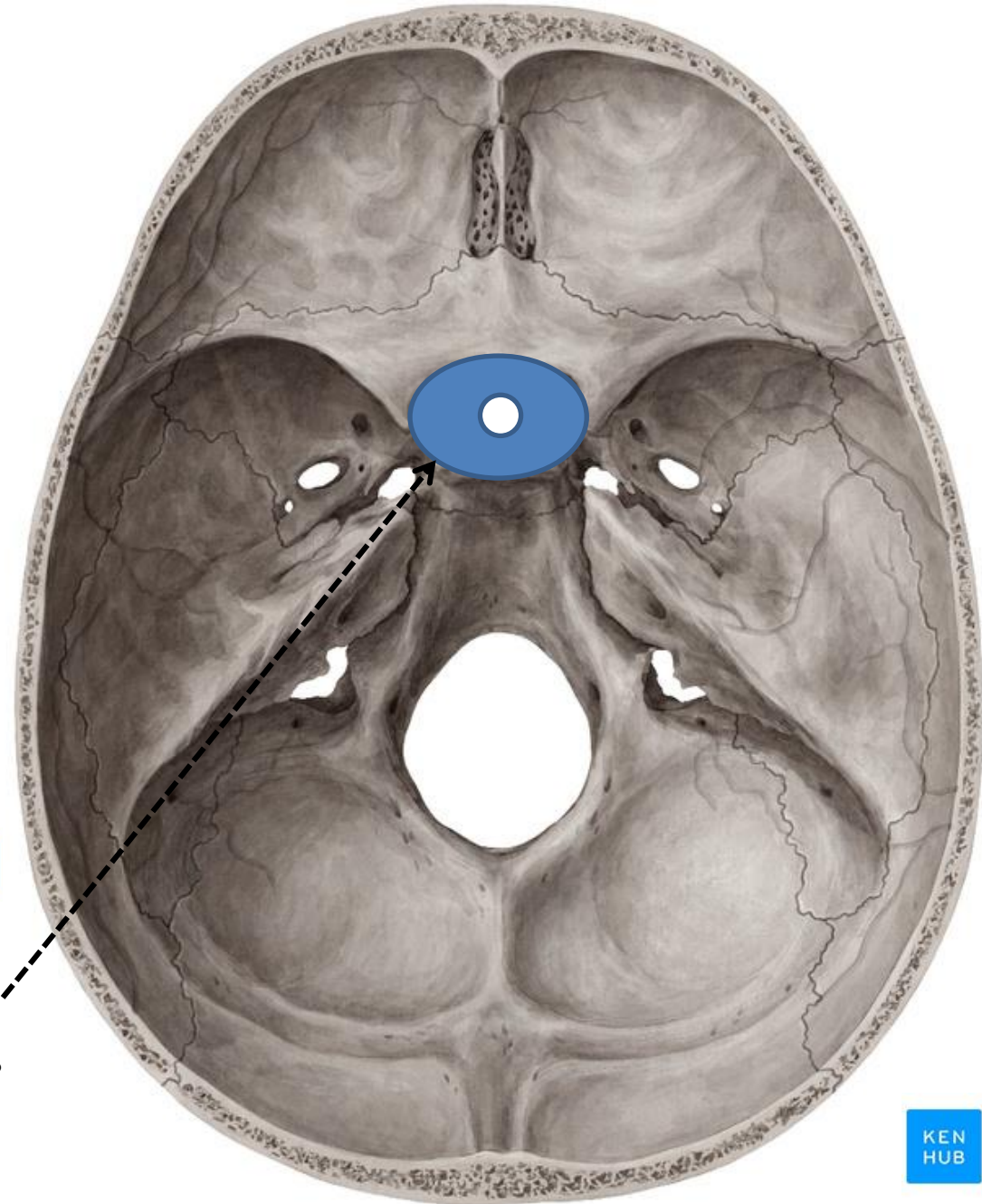
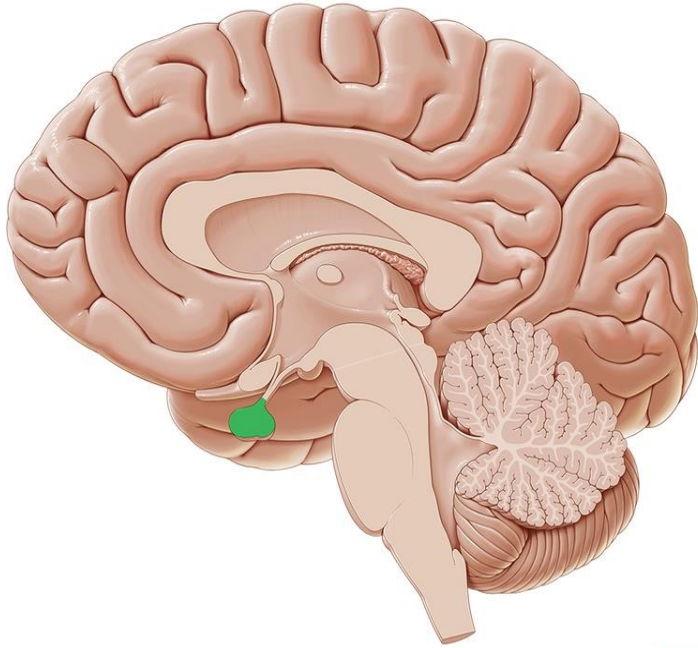
- Is a small horizontal fold of dura mater that forms the roof for **the sella turcica**
- A small opening in its center allows passage of the **stalk of the pituitary gland** (connecting the pituitary gland with the base of the brain)

Diaphragma sellae



# Sella turcica

## Hypophyseal fossa



## Diaphragma sellae

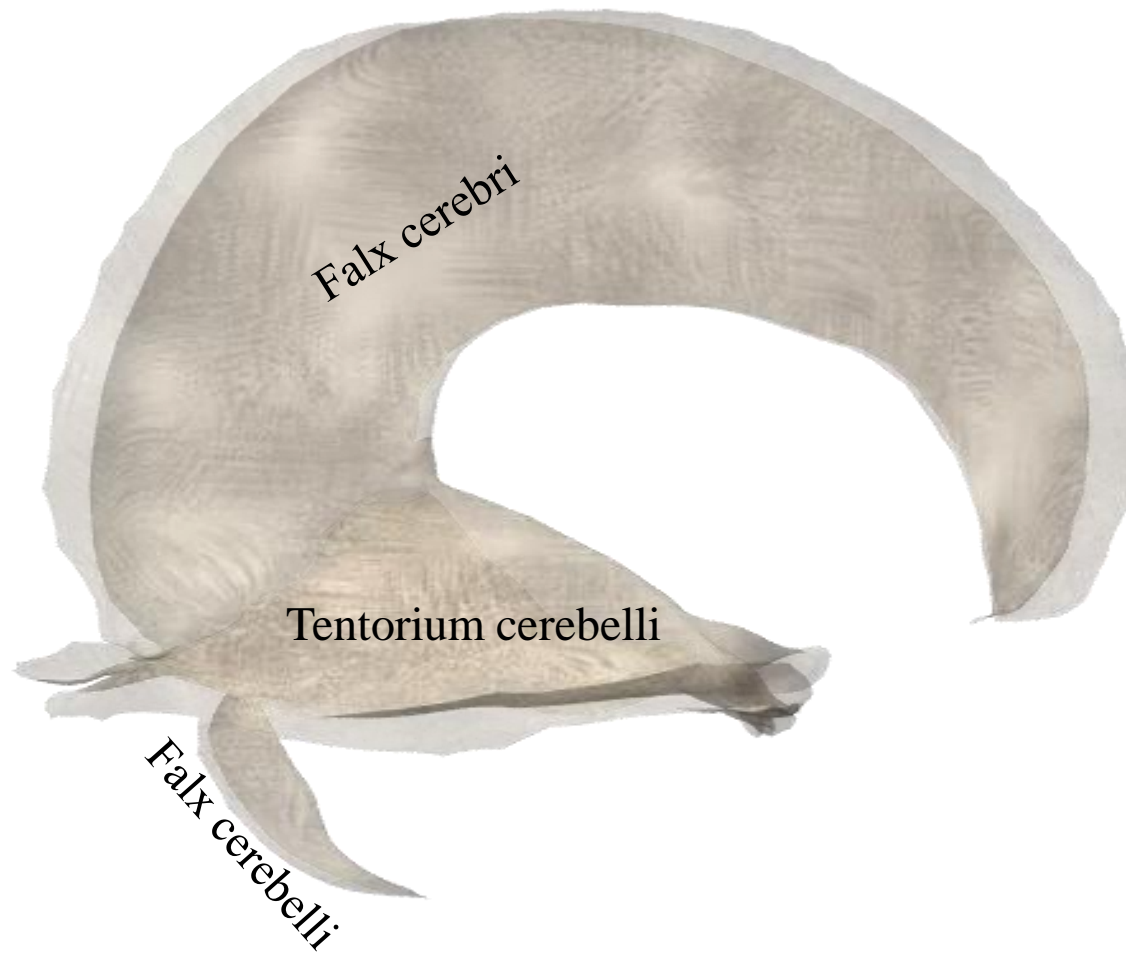
Is attached to the 4 clinoid processes

© www.kenhub.com

KEN  
HUB

KEN  
HUB

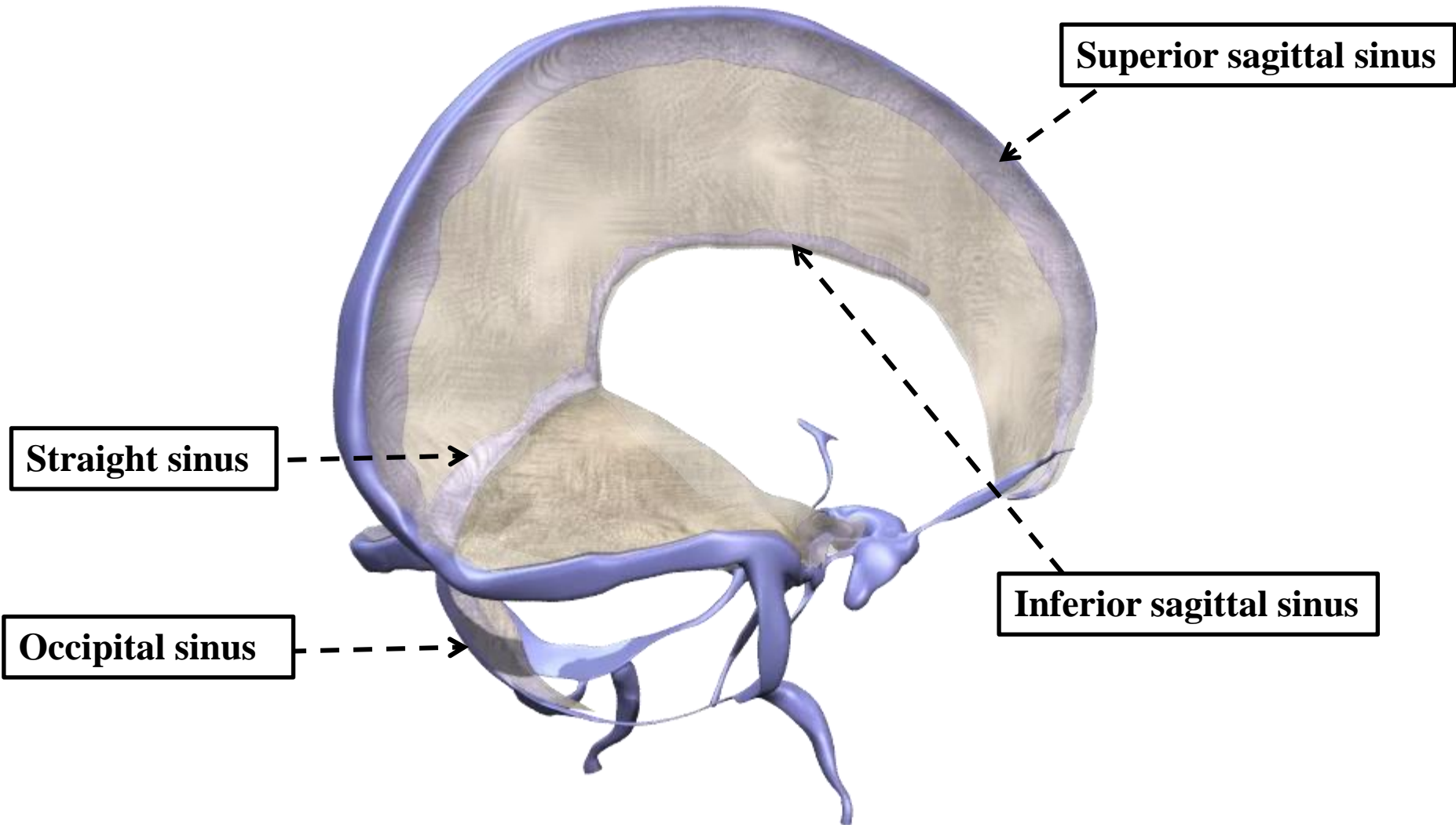
© www.kenhub.com



PRIMAL PICTURES



The falx cerebri and the falx cerebelli are attached to the upper and lower surfaces of the tentorium, respectively

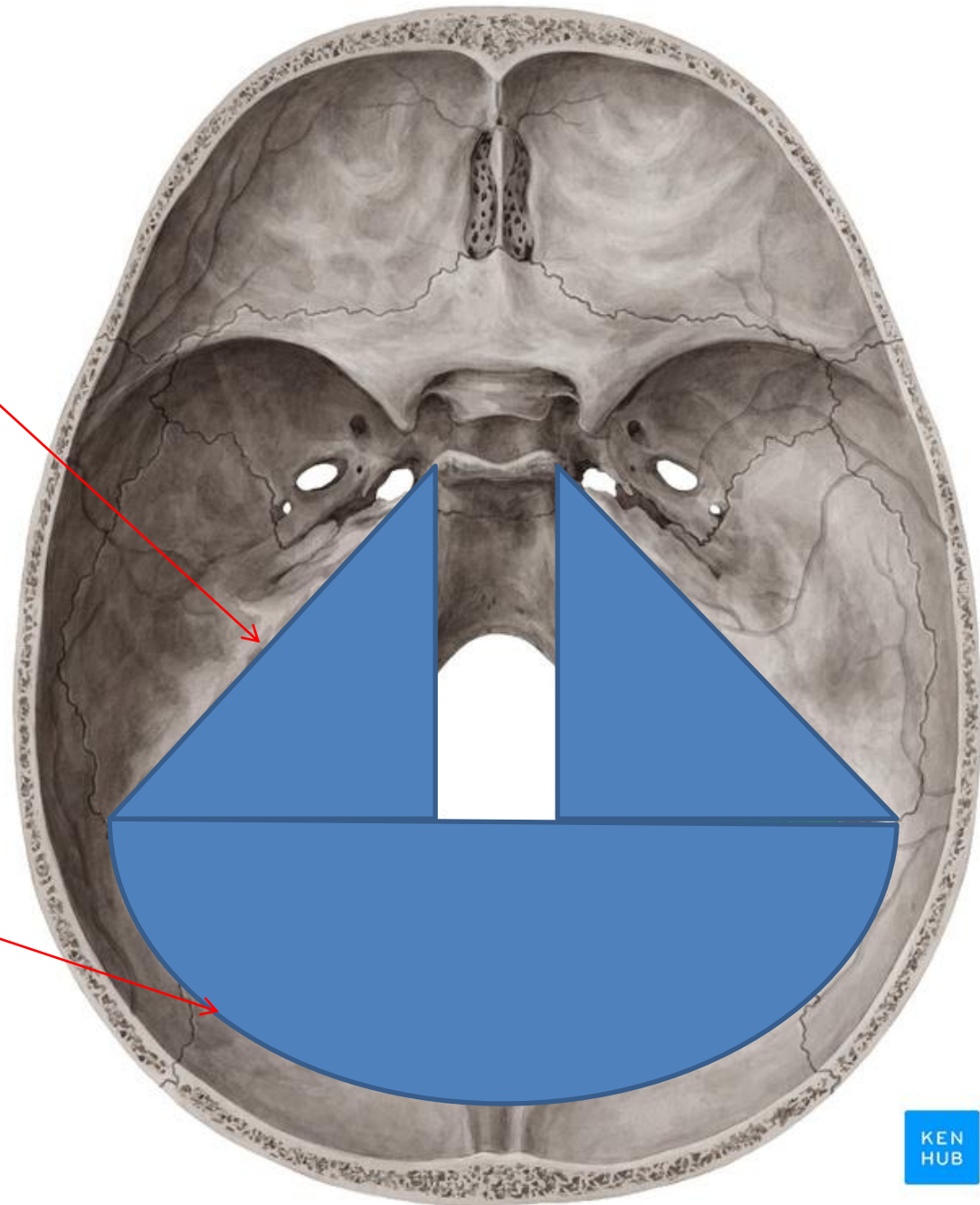


PRIMAL PICTURES 

*Dr. Heba Kalbouneh*

- The **superior sagittal sinus** runs in the **upper margin of falx cerebri**
- The **inferior sagittal sinus** runs in the **lower margin of falx cerebri**
- The **straight sinus** runs along the **falx cerebri attachment to the tentorium cerebelli**
- The **occipital sinus** runs along the **falx cerebelli attachment to internal occipital crest**



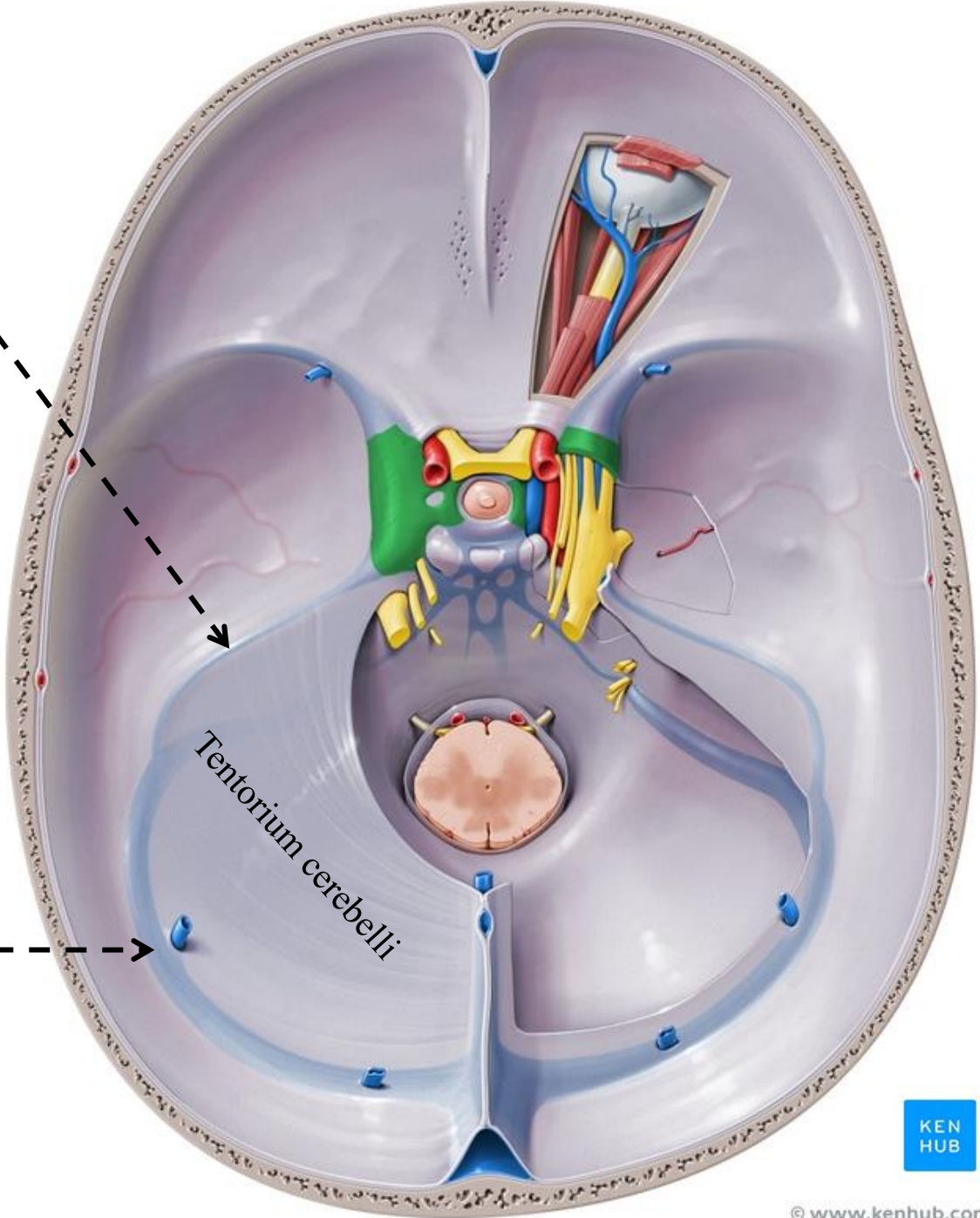


The **superior petrosal sinus** runs along the attachment of tentorium cerebelli to the superior border of petrous bone

The **transverse sinus** runs along the attachment of tentorium cerebelli to the occipital bone

**Superior petrosal sinus**

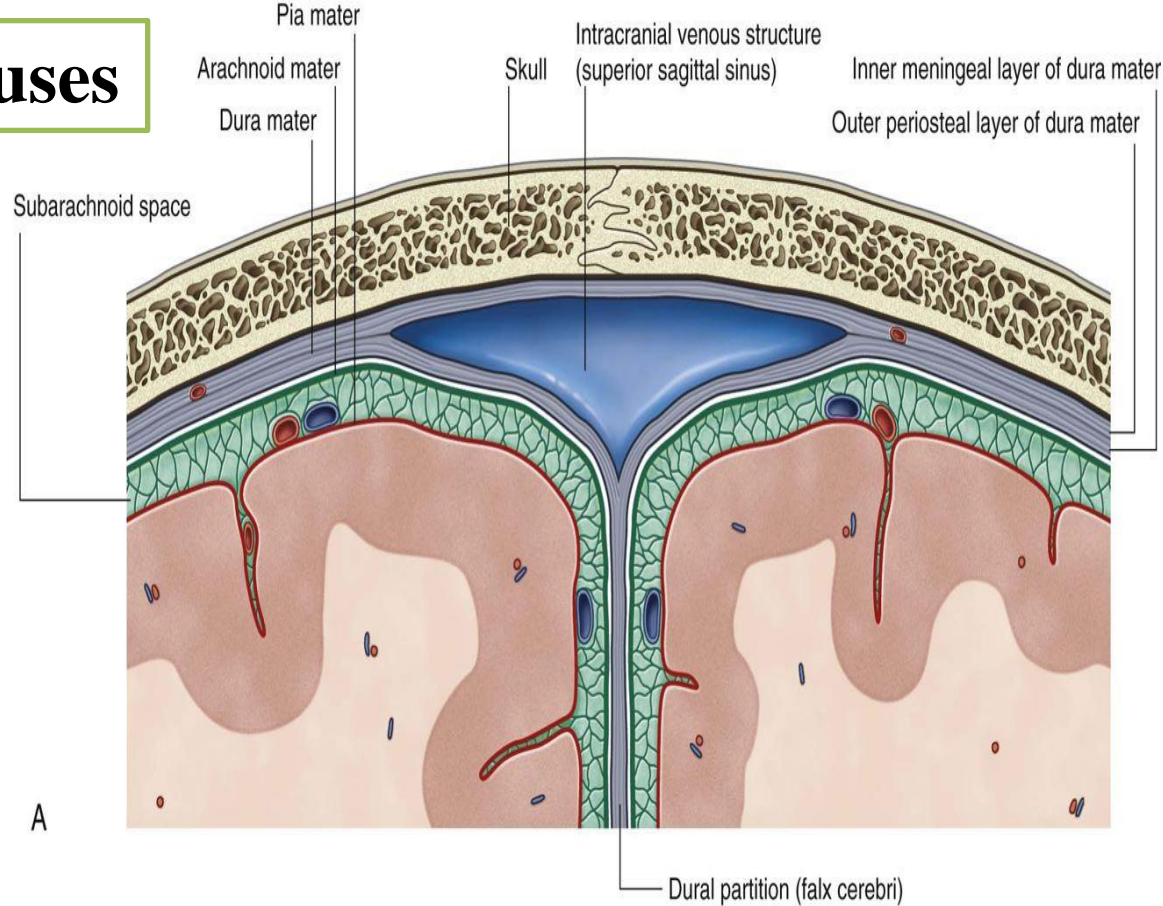
**Transverse sinus**



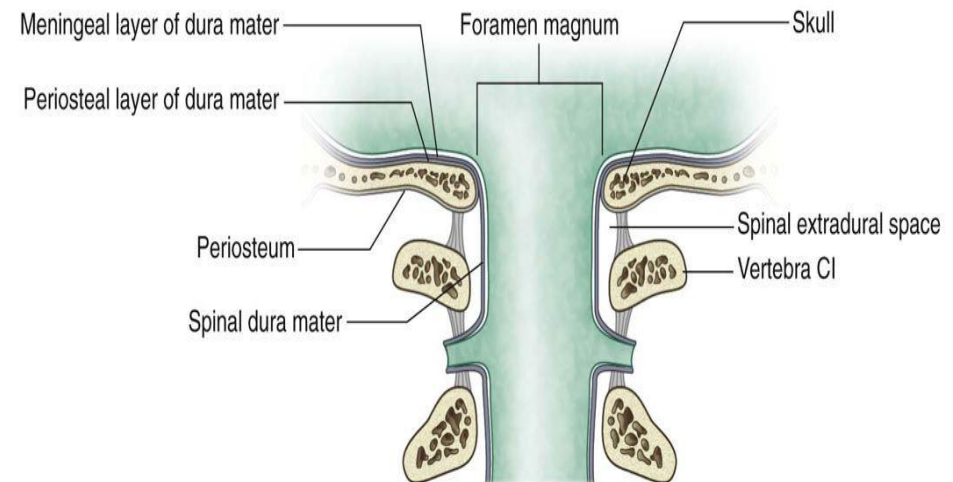
Tentorium cerebelli

# The Venous Blood Sinuses

- They are intracranial blood filled spaces
- Run between the layers of the dura mater or the dural fold
- They are lined by endothelium
  - Their walls are thick and composed of fibrous tissue
  - Valveless
- They have no muscular tissue
- They receive tributaries from the brain, the diploe of the skull, Emissary veins, meninges, the orbit, and the internal ear
- Eventually lead to **internal jugular vein**

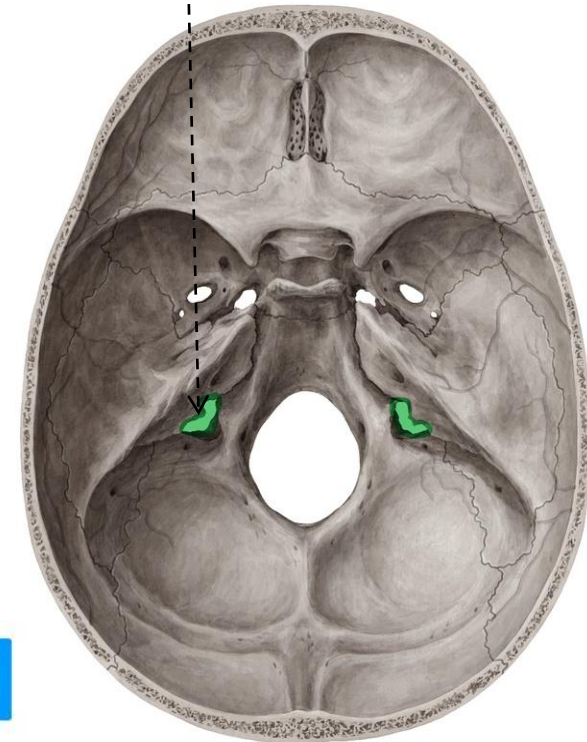
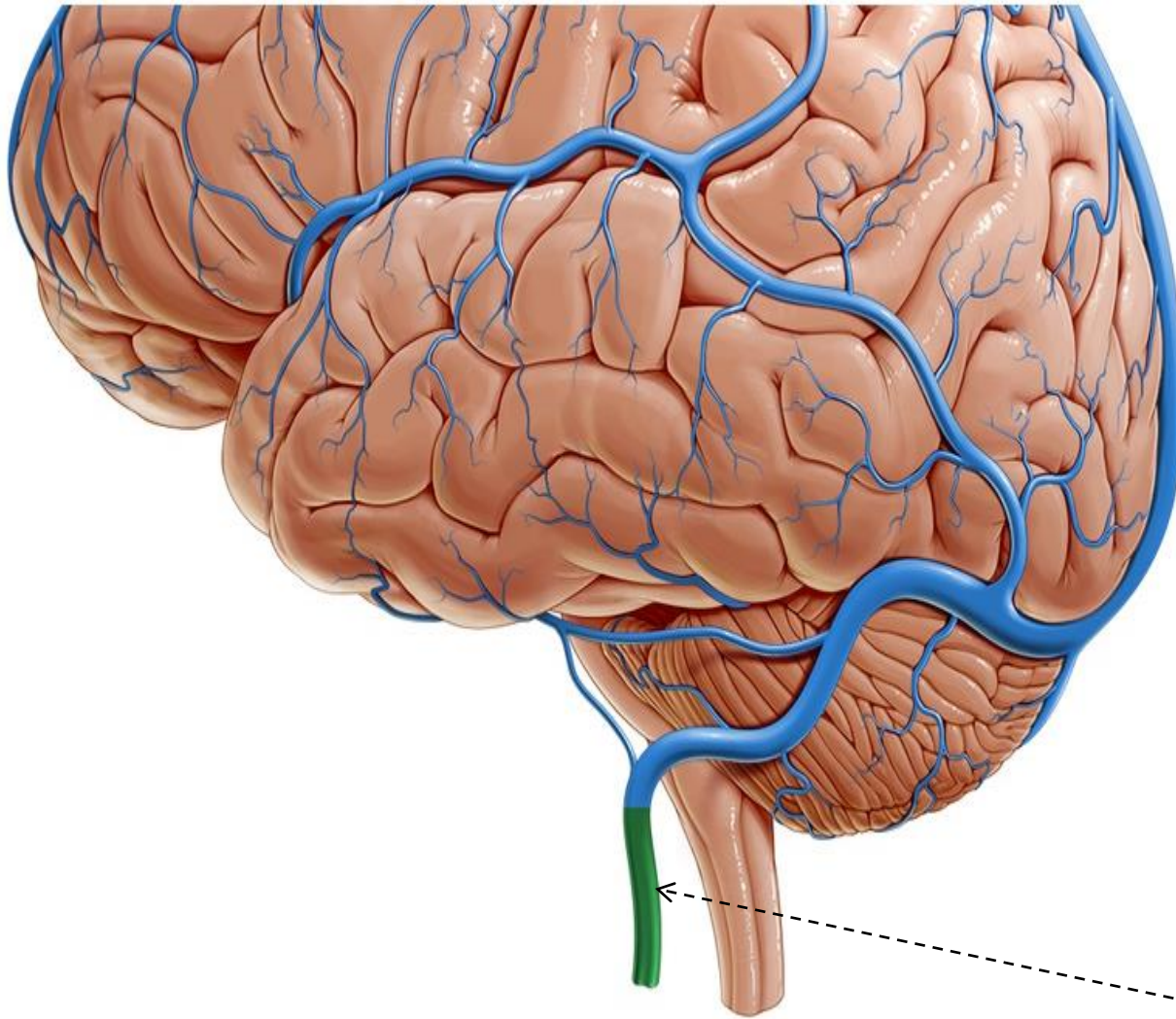


A



B

**The internal jugular vein leaves the skull by passing through jugular foramen**



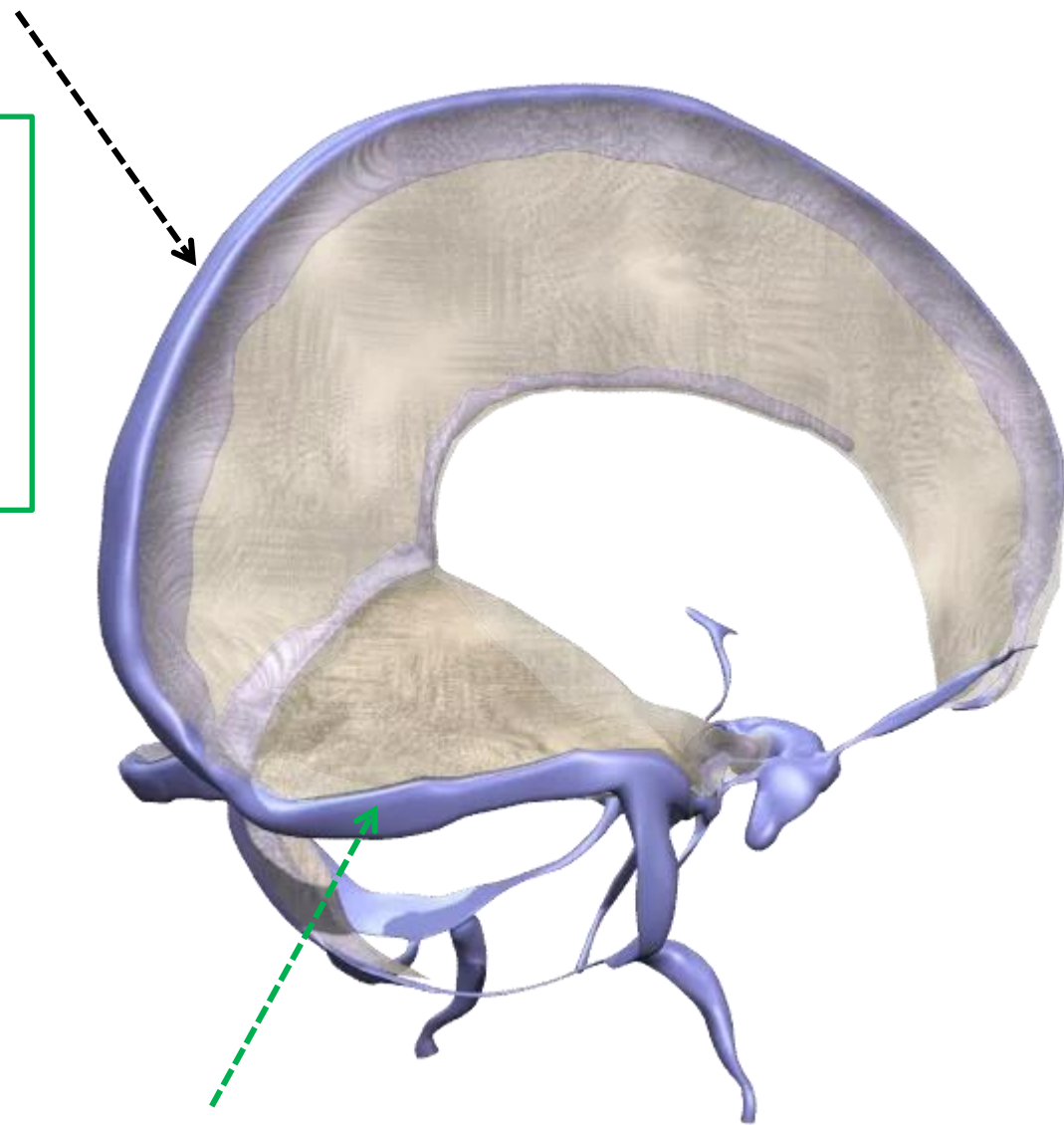
KEN HUB

**The internal jugular vein**

© www.kenhub.com

## The superior sagittal sinus

- Lies in the upper fixed border of the falx cerebri
- It becomes continuous with the right transverse sinus.

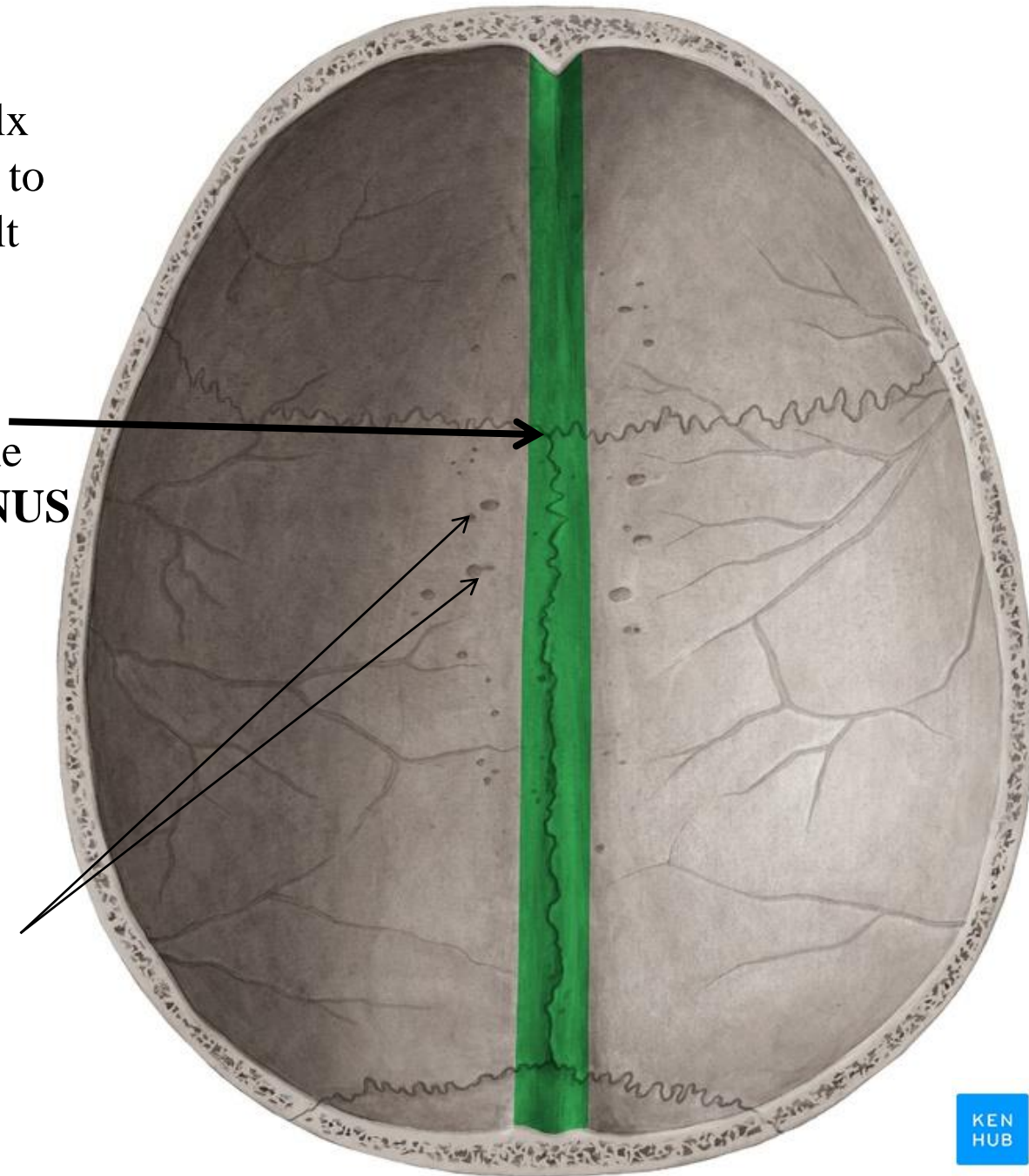


**Right transverse sinus**

The upper fixed border of falx cerebri is attached at midline to internal surface of skull vault

In the midline is a shallow sagittal groove containing the **SUPERIOR SAGITTAL SINUS**

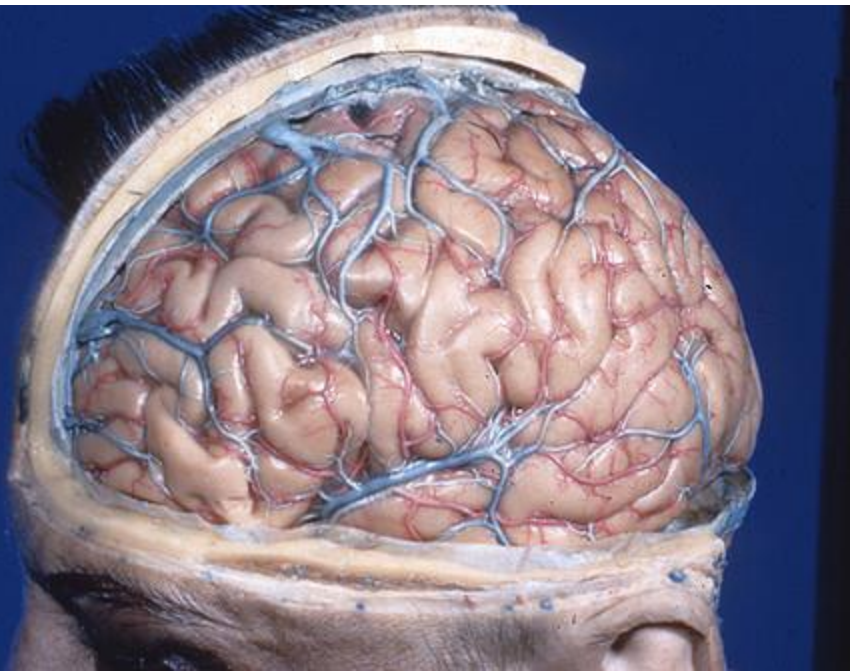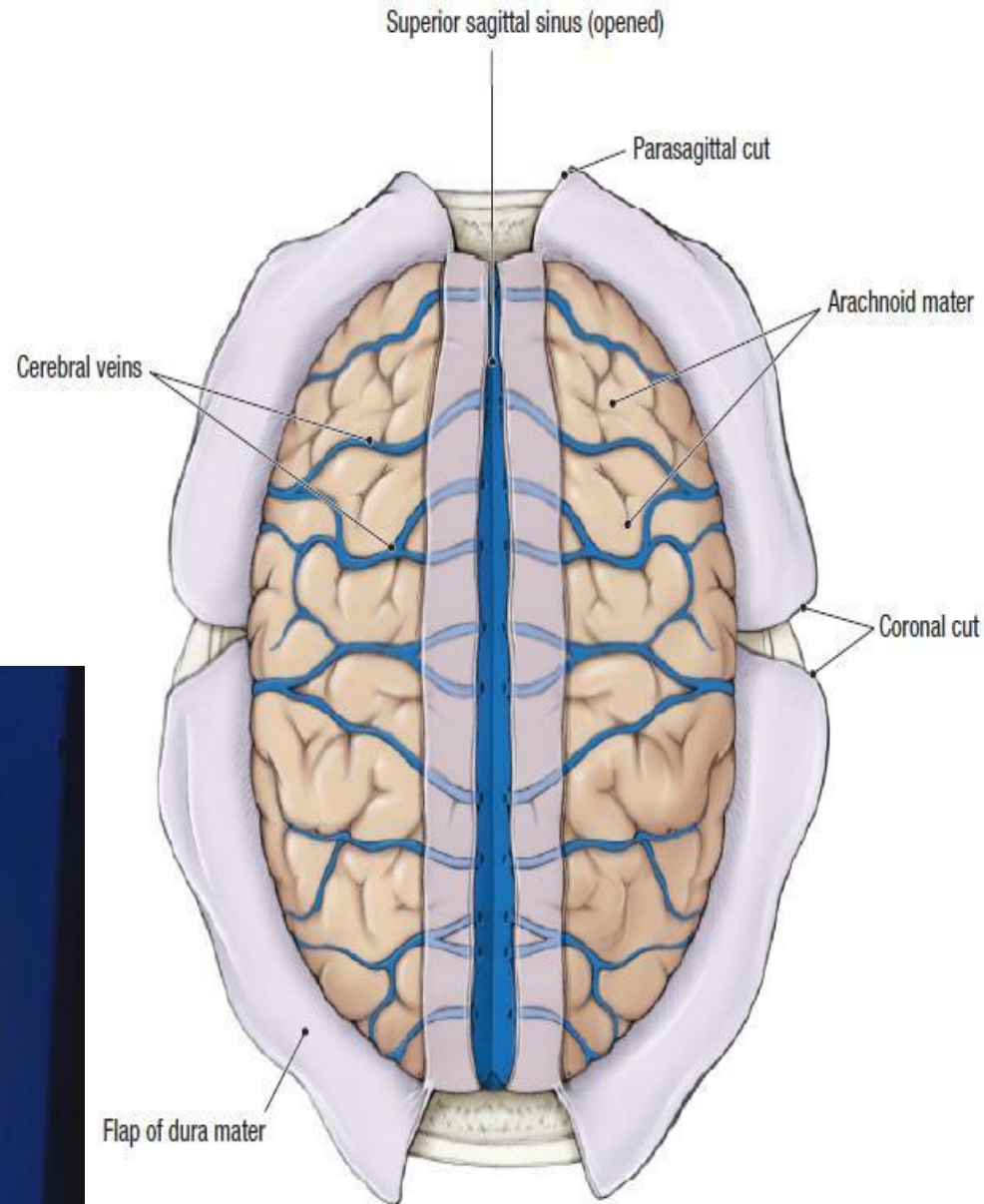
On each side of the groove are several small pits, called **GRANULAR PITS**



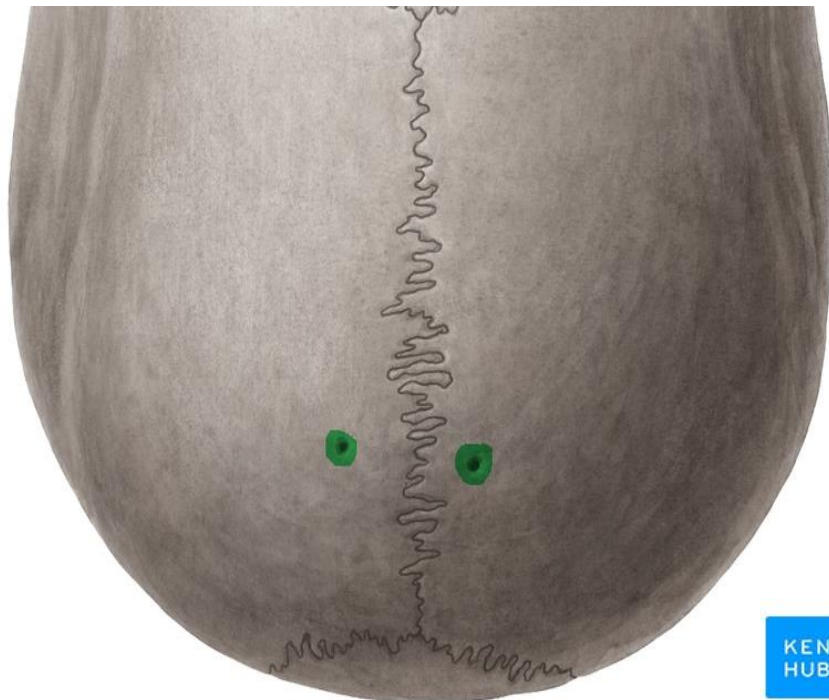The superior sagittal sinus

Receives blood from:

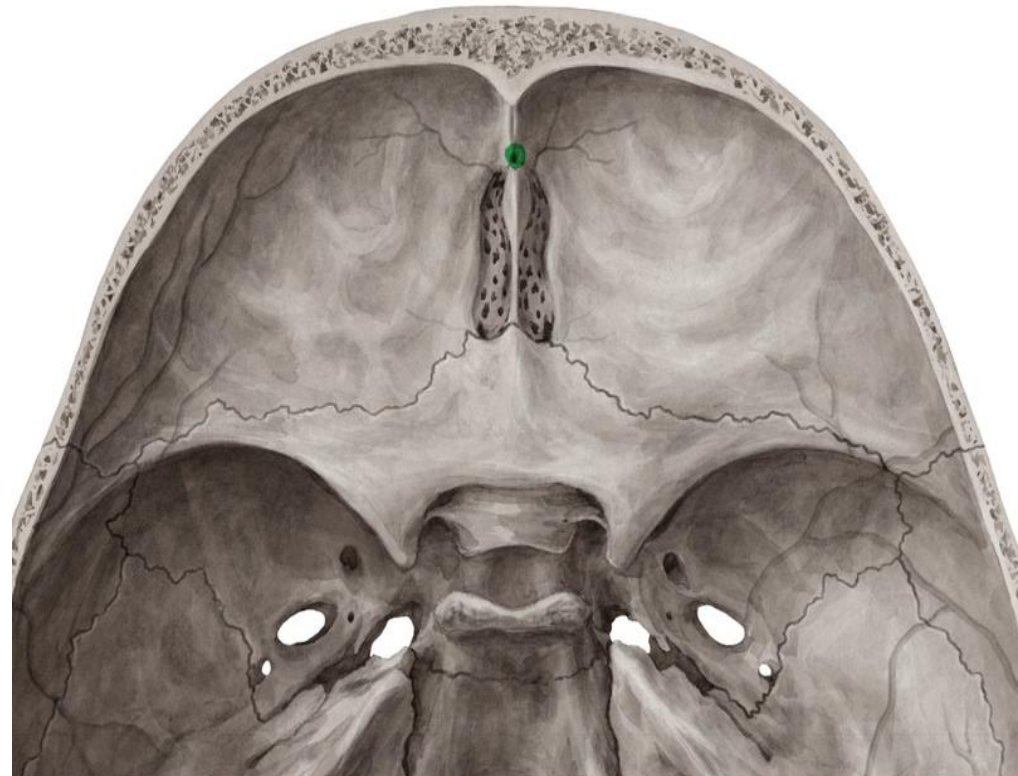
- 1- Superior cerebral veins
- 2- Meningeal veins
- 3- Two parietal emissary veins
- 4- Emissary vein through foramen cecum
- 4- Arachnoid villi



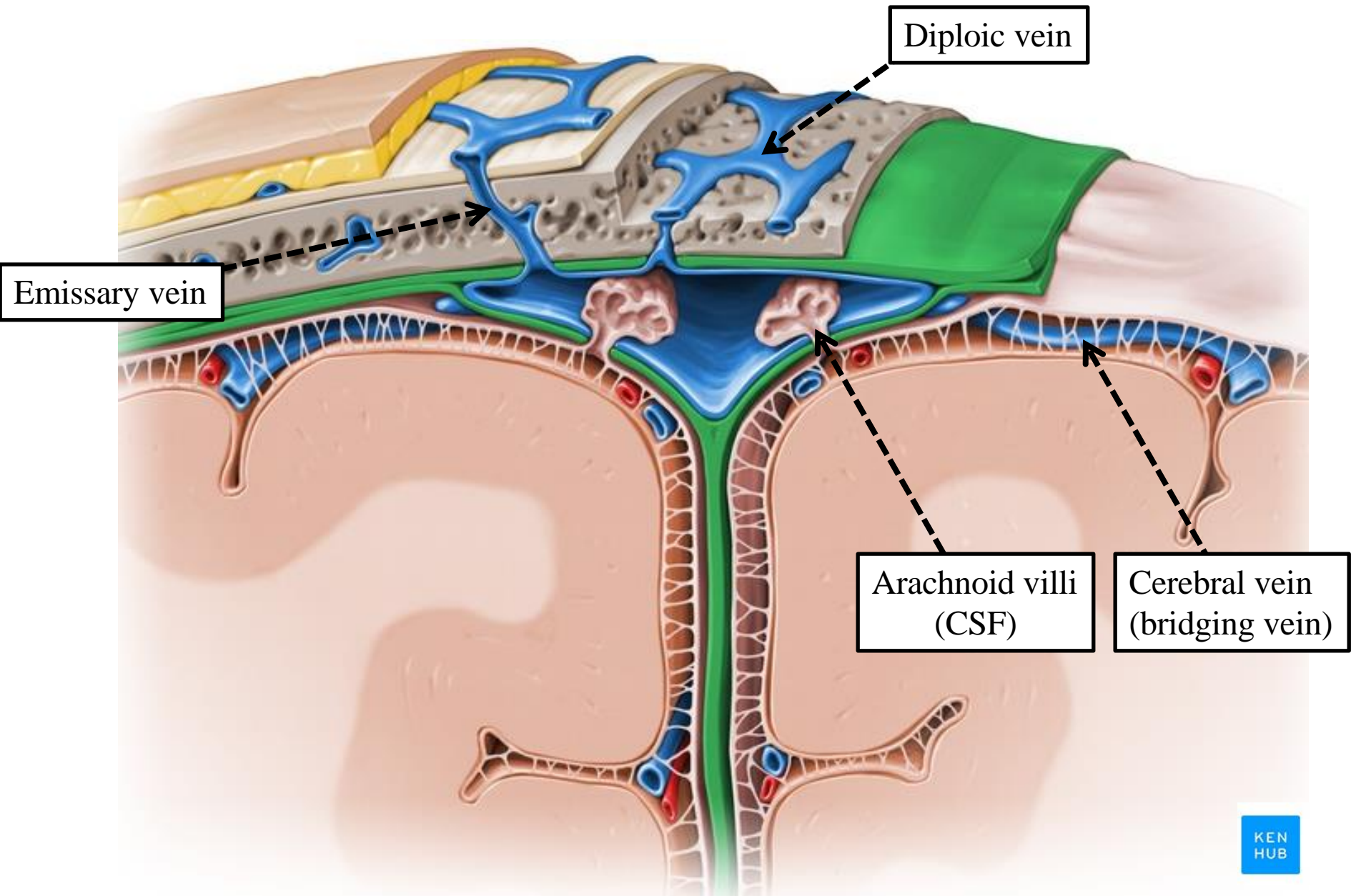
**Parietal foramina** transmit emissary veins from scalp to the superior sagittal sinus



**Foramen caecum:** may transmit emissary vein from the nose to the superior sagittal sinus (Cecum: blind)

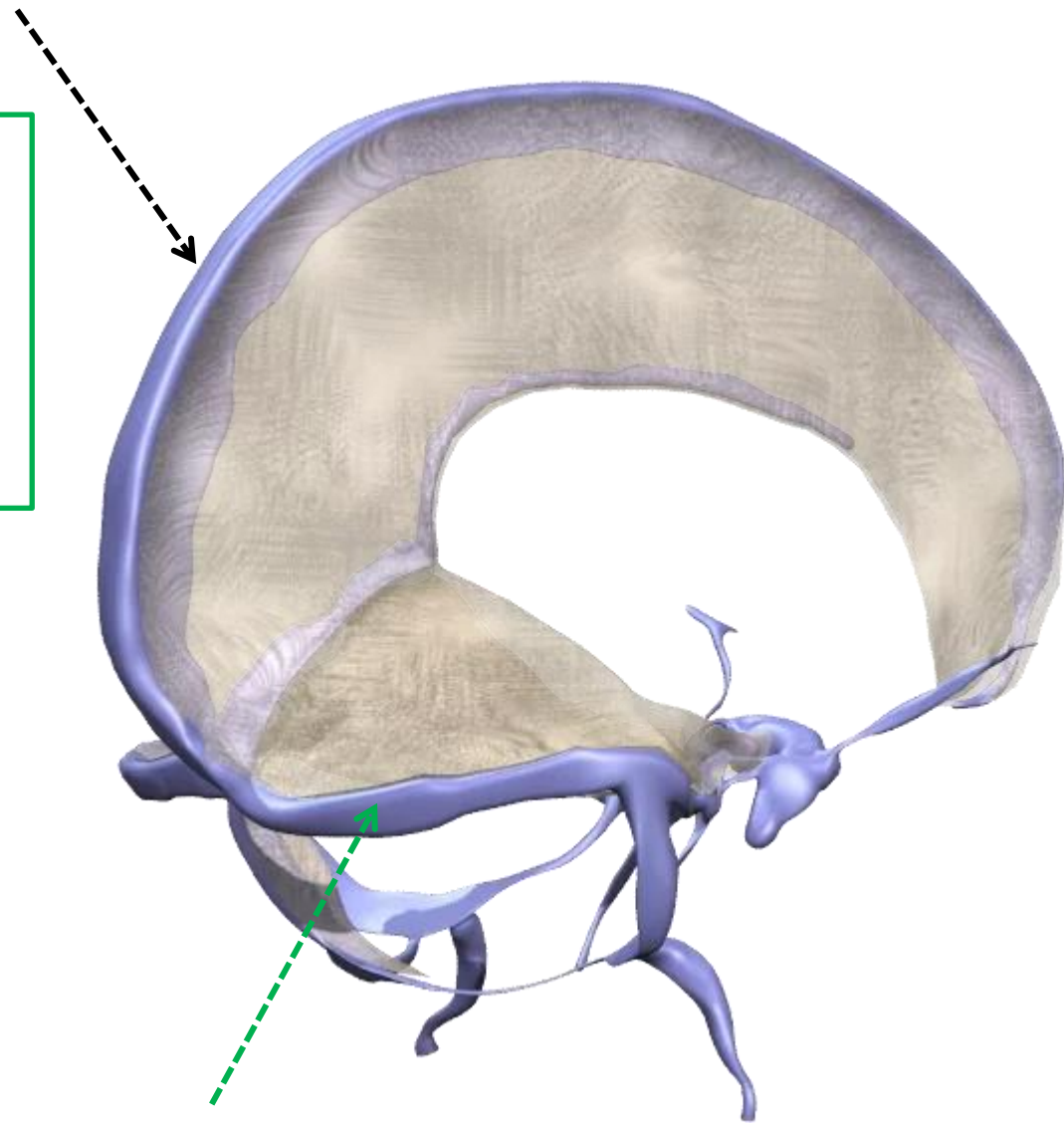






## The superior sagittal sinus

- Lies in the upper fixed border of the falx cerebri
- It becomes continuous with the right transverse sinus.

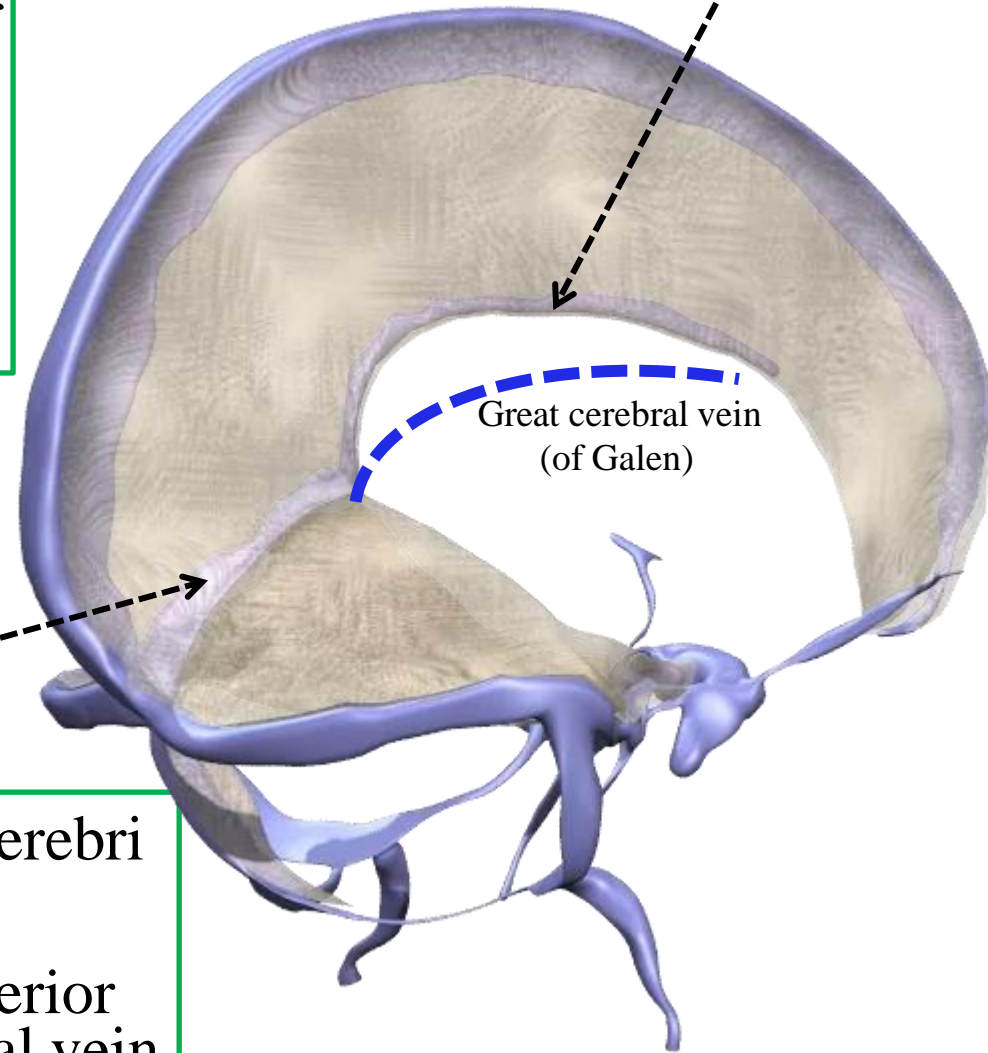


**Right transverse sinus**

## The inferior sagittal sinus

- Lies in the free lower margin of the falx cerebri
- It runs backward and joins the great cerebral vein to form the straight sinus

Inferior sagittal sinus



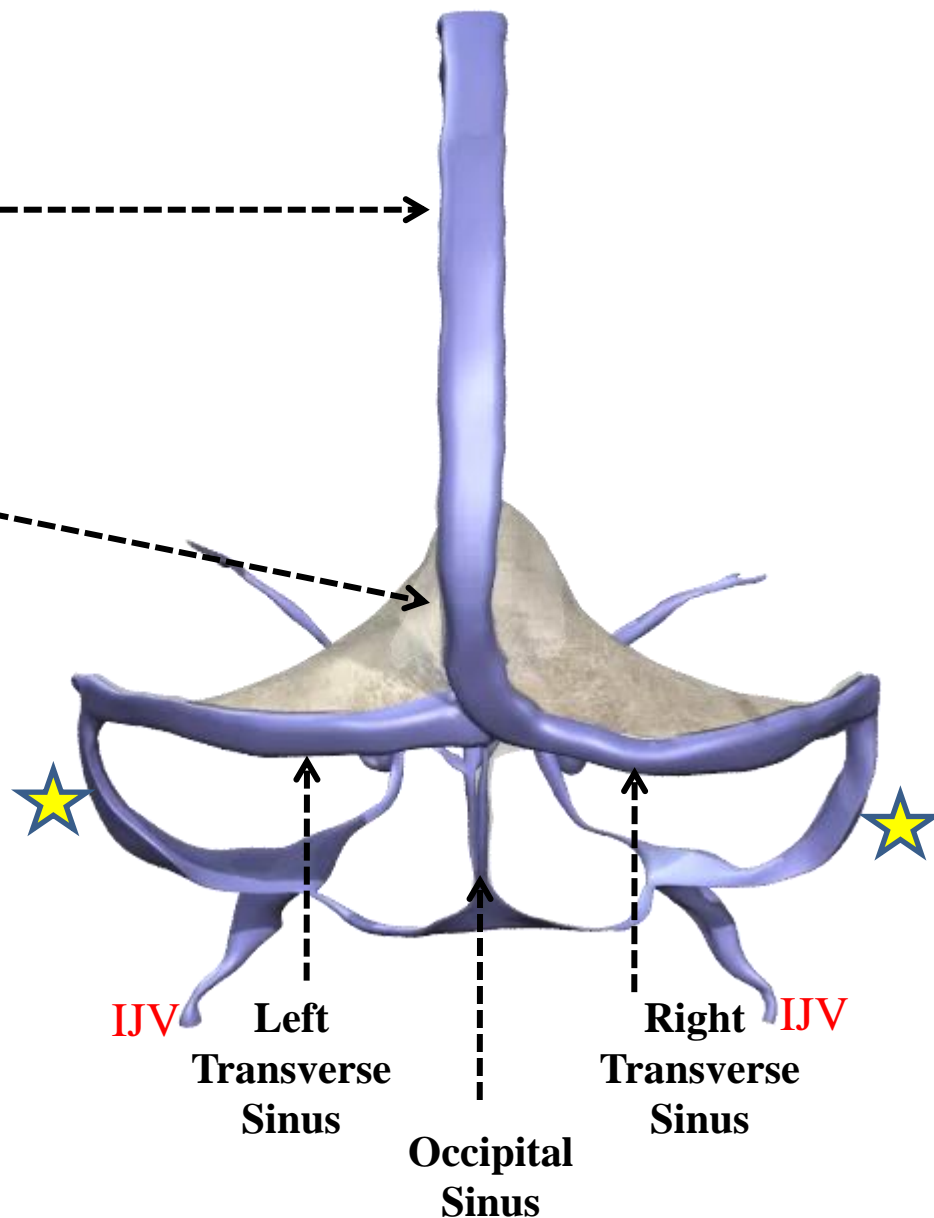
Great cerebral vein  
(of Galen)

## The straight sinus

- Lies at the junction of the falx cerebri with the tentorium cerebelli
- Formed by the union of the inferior sagittal sinus with the great cerebral vein
- It drains into the left transverse sinus


# The transverse sinus

- The **right transverse sinus** is usually a continuation of **superior sagittal sinus**
- The **left transverse sinus** is usually a continuation of the **straight sinus**
- Each transverse sinus lies along the attachment of tentorium cerebelli to the occipital bone
- Each sinus ends by becoming **★ the sigmoid sinus**



# Posterior view

Superior sagittal sinus



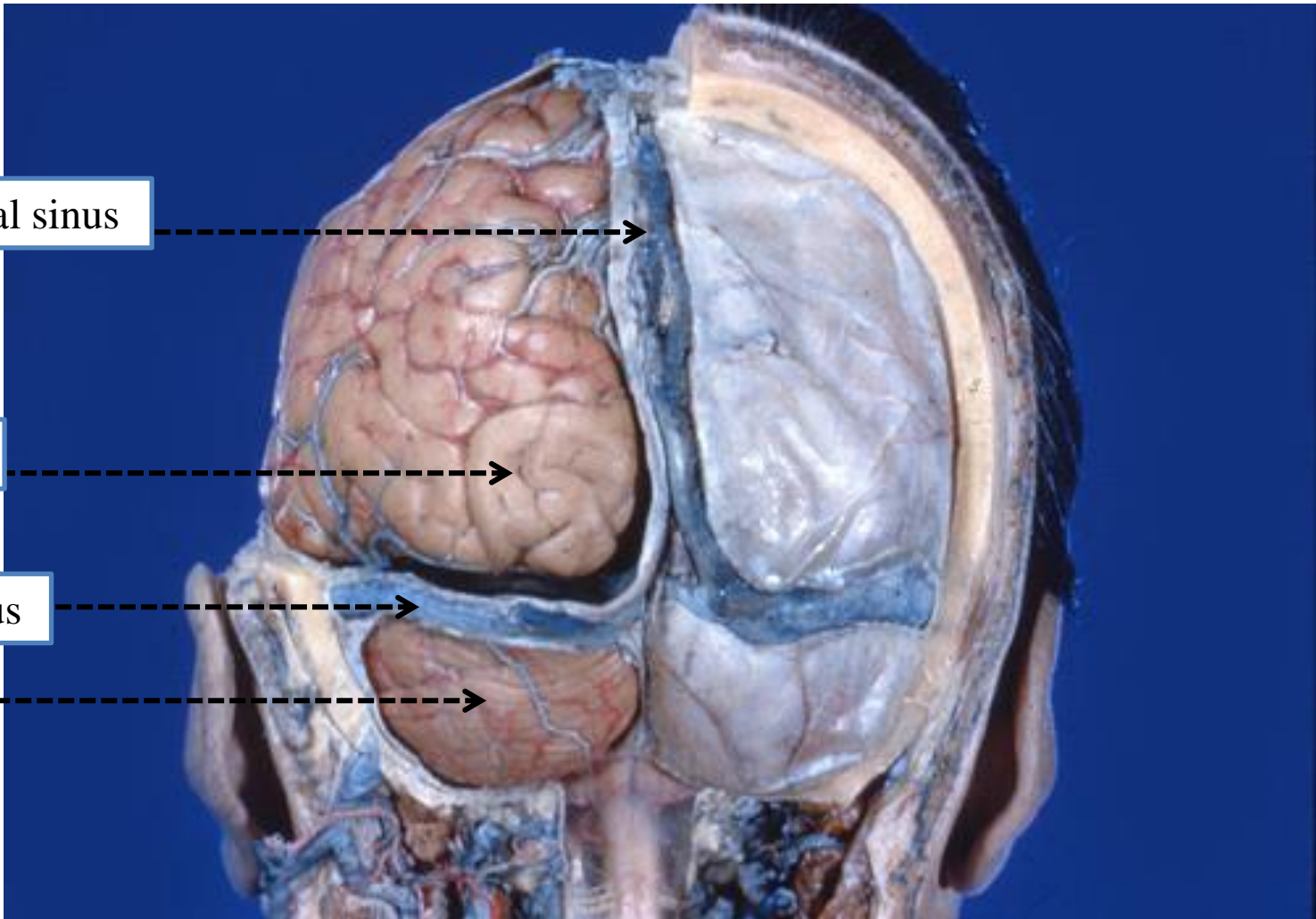
Occipital lobe



Transverse sinus



Cerebellum

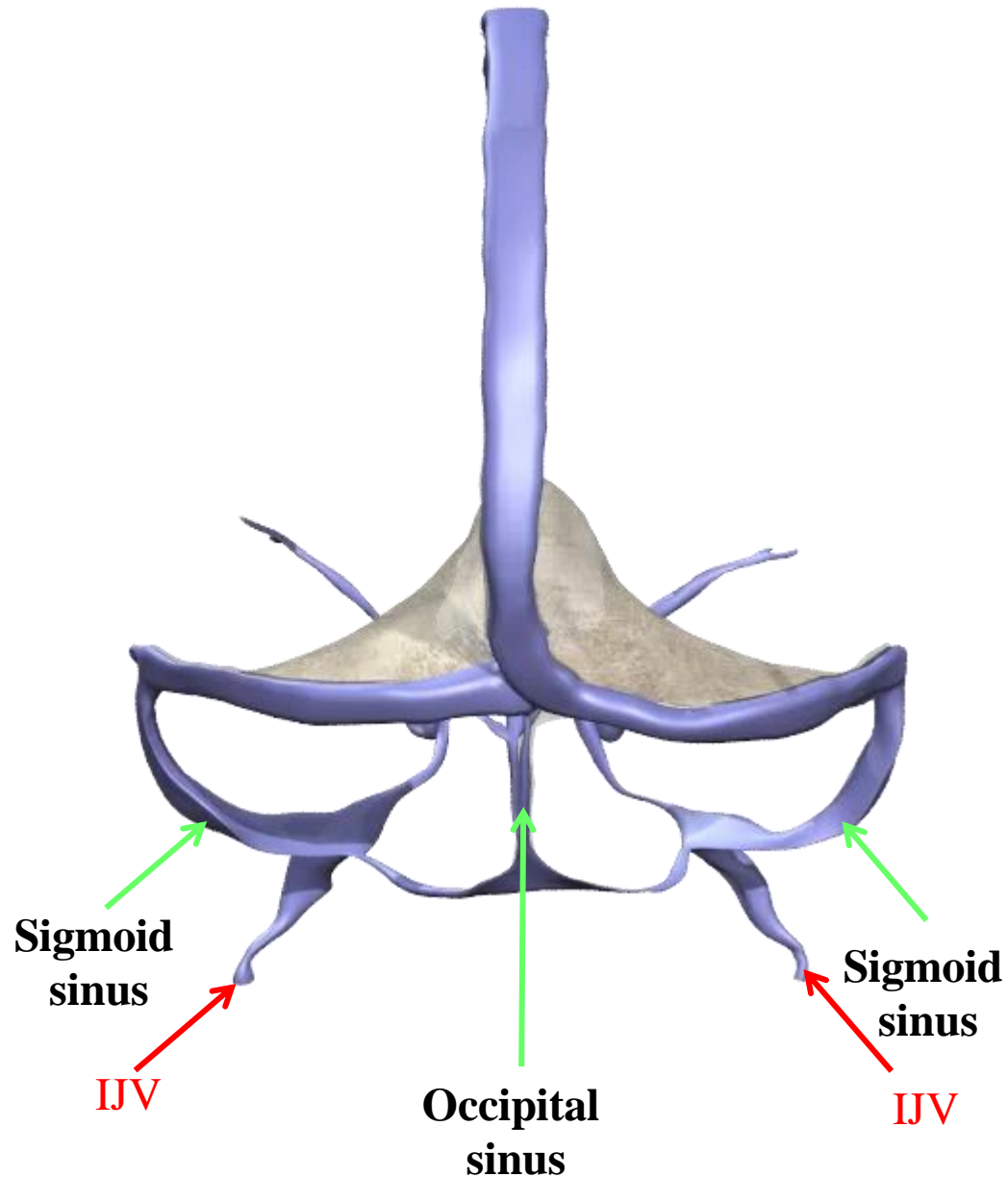


## The sigmoid sinus

- Left & Right
- Drains from the transverse sinus and superior petrosal sinus and continues as **internal jugular vein (IJV)**

## The occipital sinus

Lies in the attached margin of the falx cerebelli



**Sulcus for the Inf. Petrosal sinus**

(Inferior border of petrous bone)

**Sulcus for the Sup. Petrosal sinus**

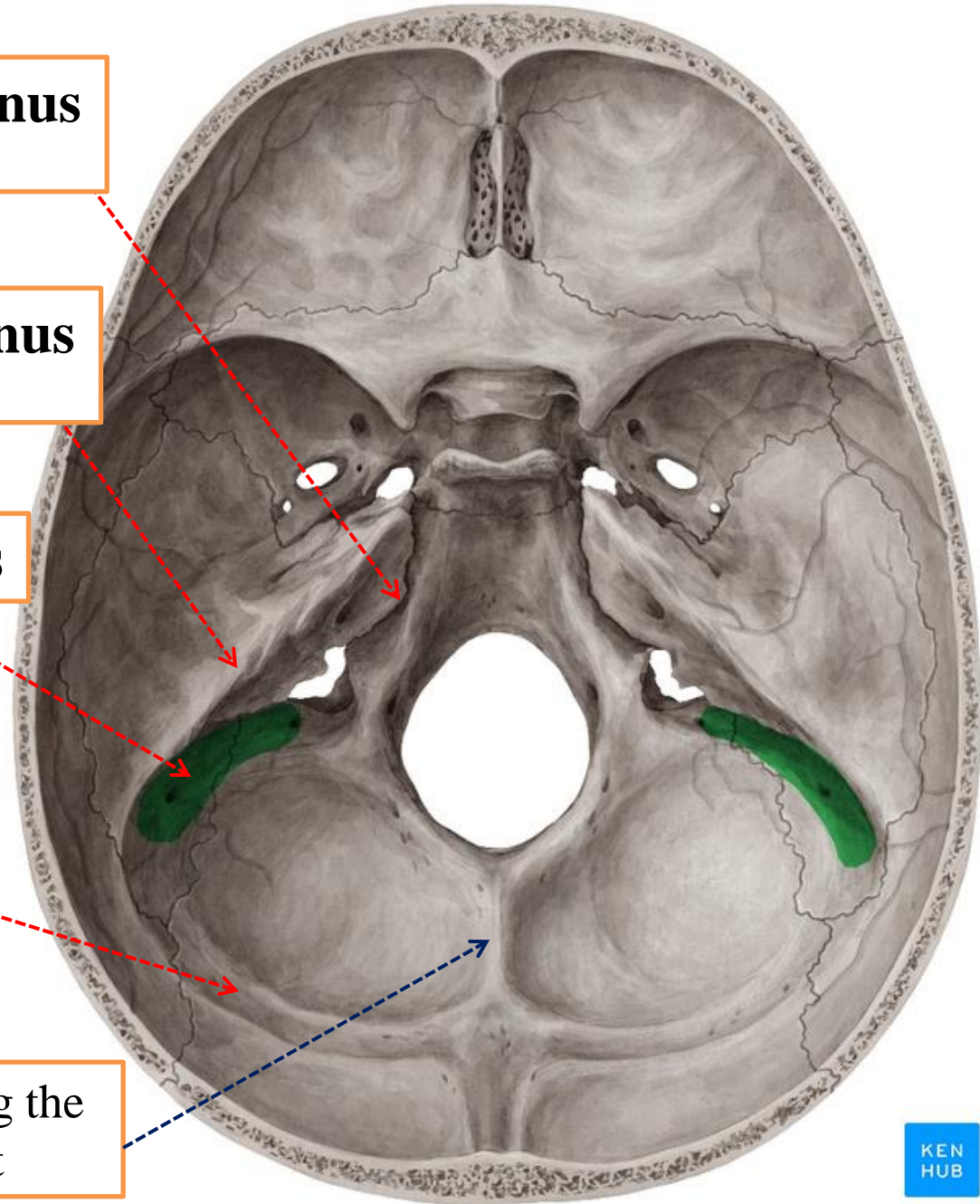
(Superior border of petrous bone)

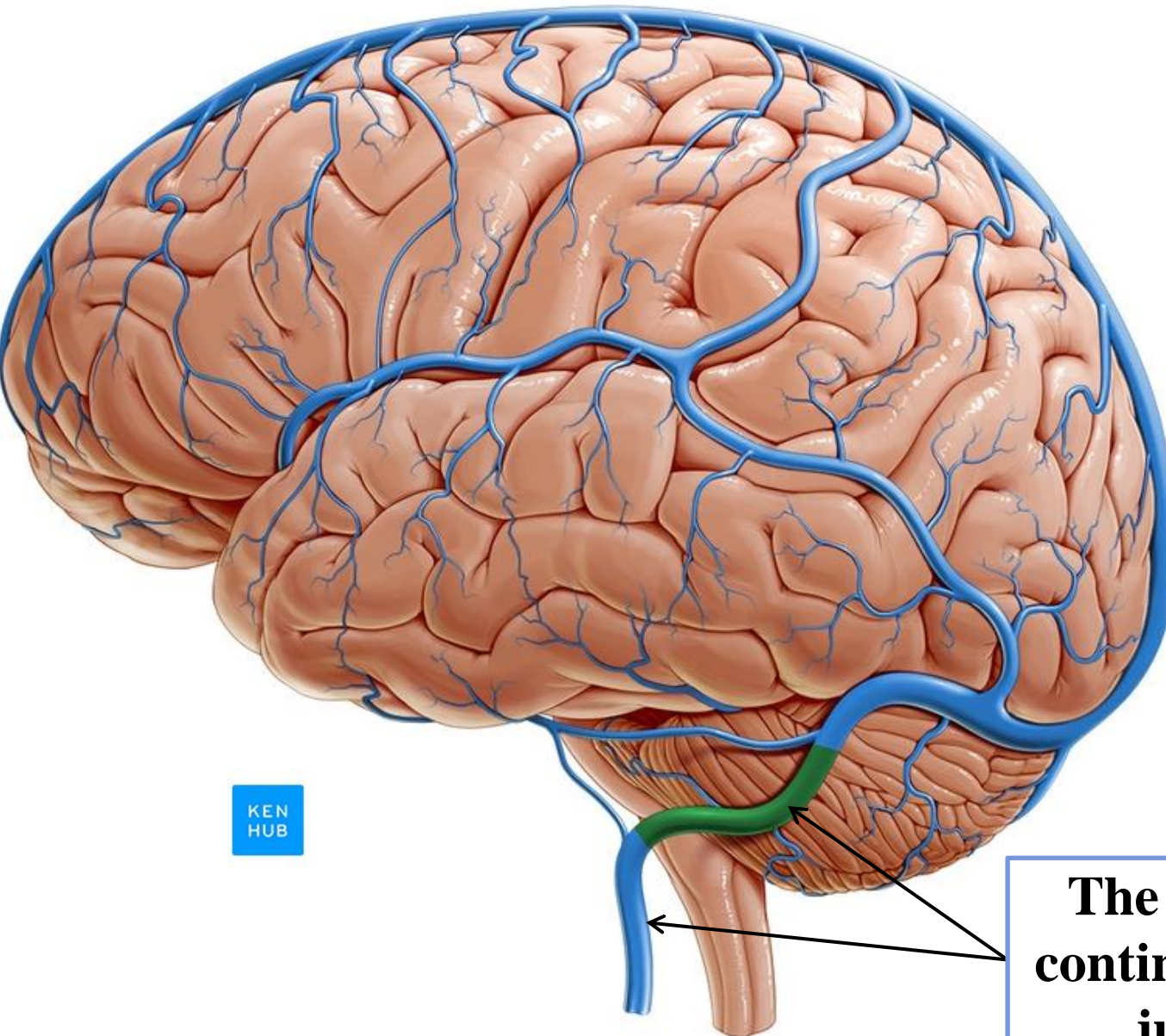
**Groove for the sigmoid sinus**

**Groove for the transverse sinus**

(On each side of the internal occipital protuberance)

**Occipital sinus** runs along the internal occipital crest





KEN  
HUB

- Superior sagittal sinus----right transverse sinus
- Inferior sagittal sinus--straight sinus---- left transverse sinus
- Transverse sinus + superior petrosal sinus= sigmoid sinus
- Inferior petrosal sinus drains directly into internal jugular vein

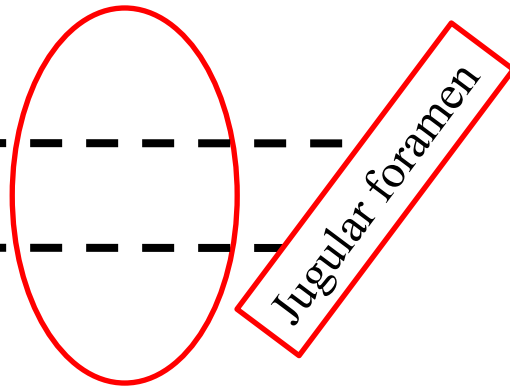
**The sigmoid sinus continues as internal jugular vein**



Anterior compartment

Middle compartment

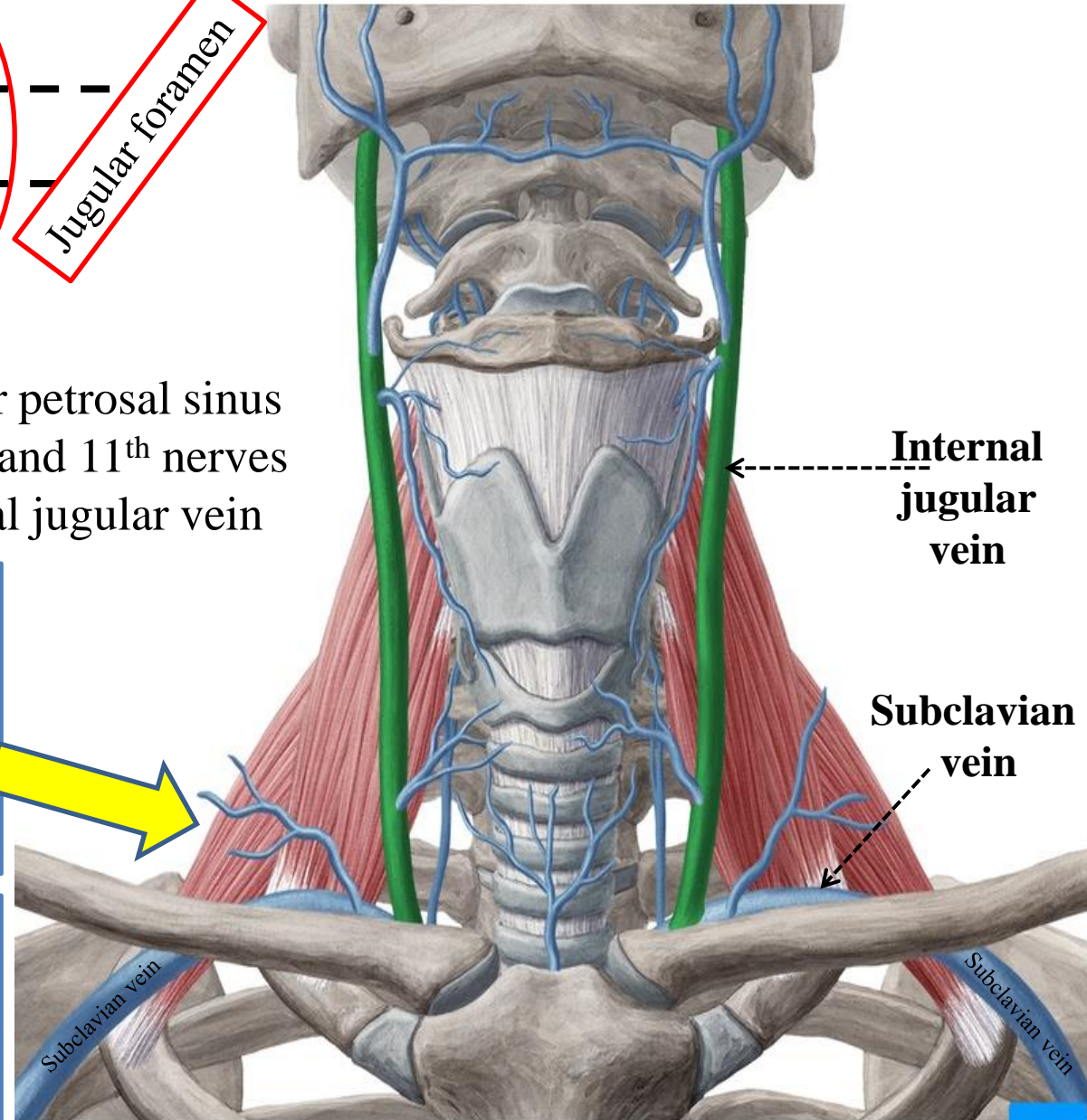
Posterior compartment

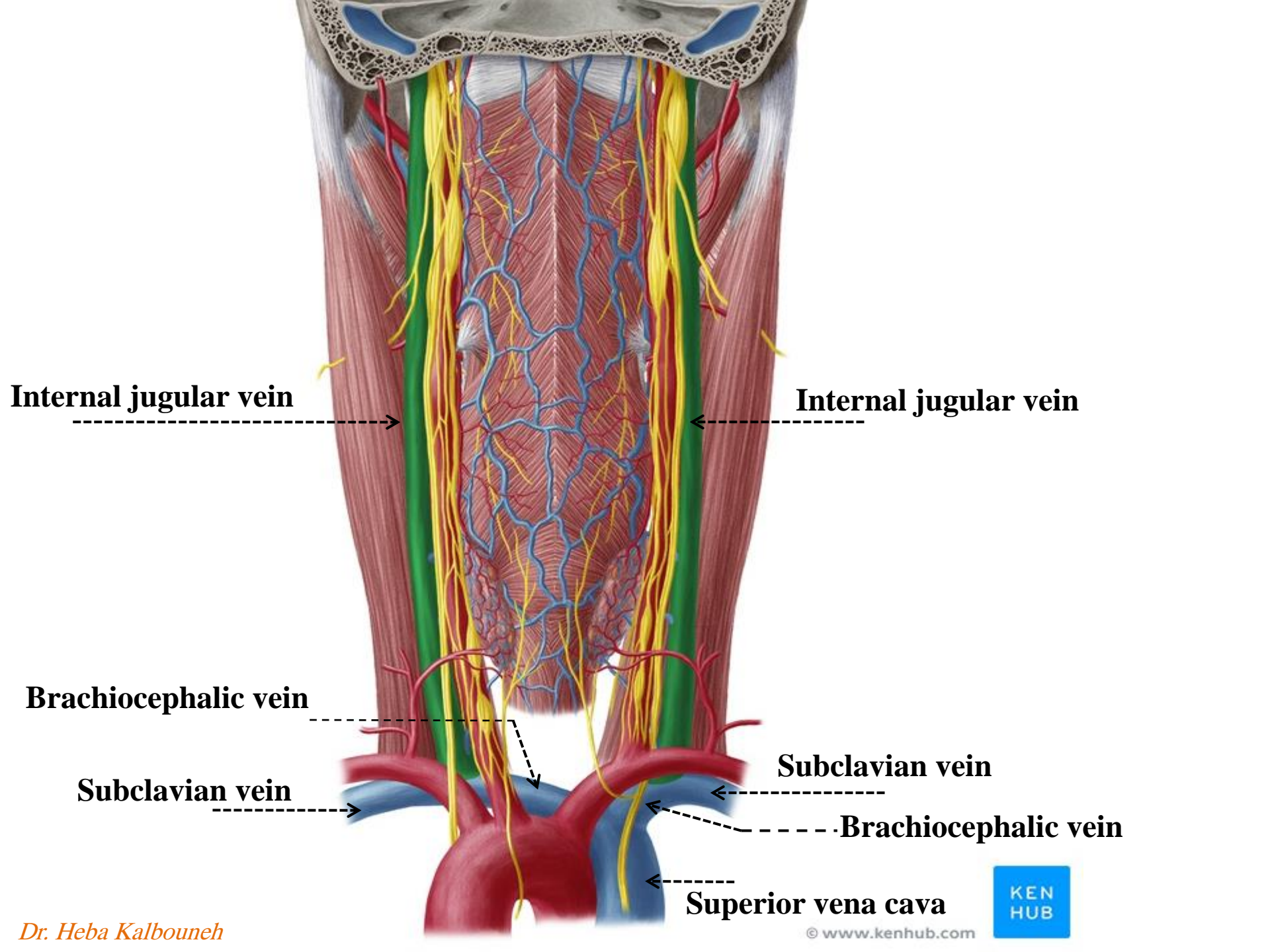


Anterior compartment: inferior petrosal sinus  
Middle compartment: 9<sup>th</sup>, 10<sup>th</sup> and 11<sup>th</sup> nerves  
Posterior compartment: internal jugular vein

At the root of the neck,  
internal jugular vein unites  
with the subclavian vein to  
form the **brachiocephalic  
vein**

Right and left  
brachiocephalic veins unite  
to form the **superior vena  
cava**





**Internal jugular vein**

**Internal jugular vein**

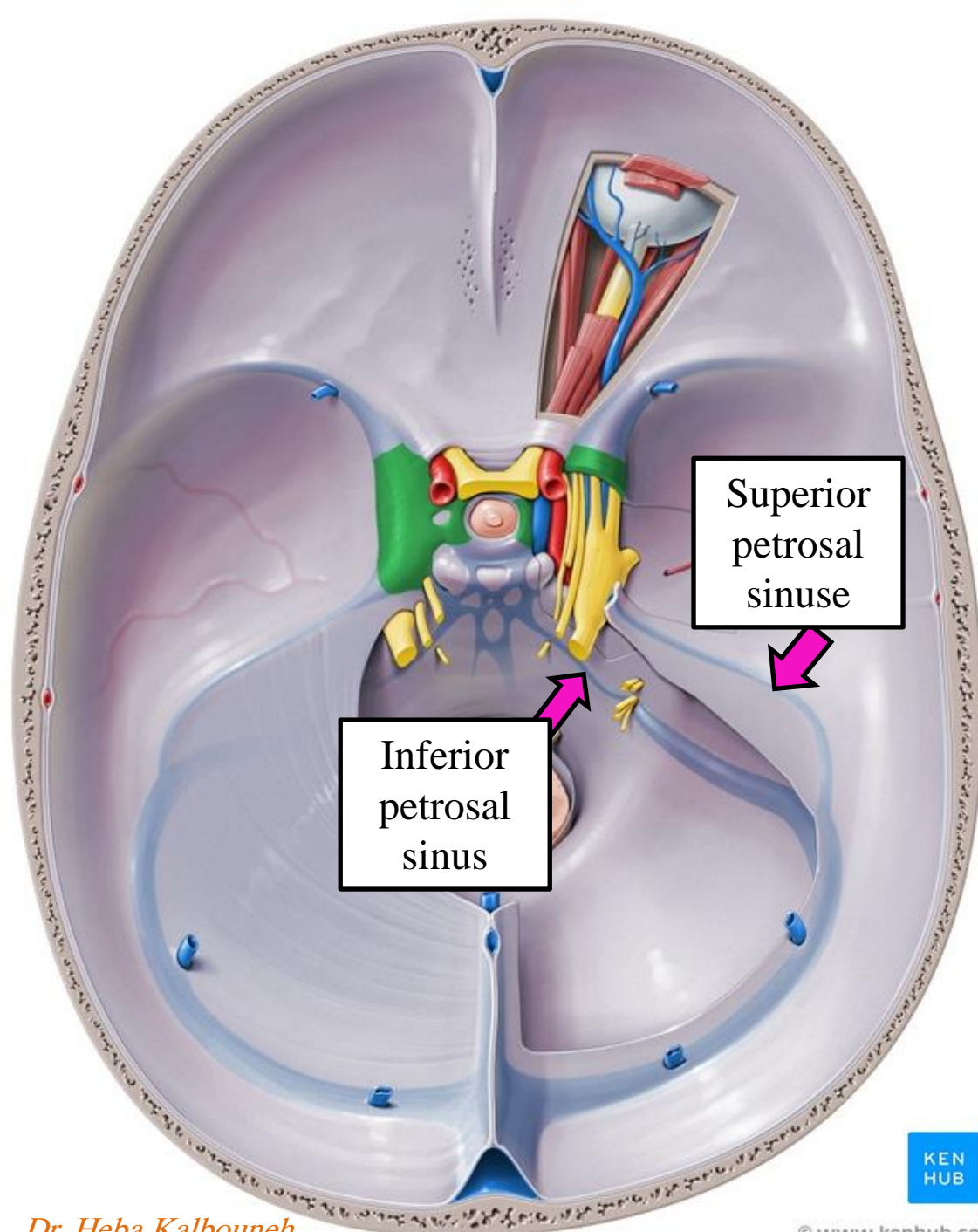
**Brachiocephalic vein**

**Subclavian vein**

**Subclavian vein**

**Brachiocephalic vein**

**Superior vena cava**



### Note

-The **superior petrosal sinus** runs along the upper border of the petrous part of the temporal bone

- The **inferior petrosal sinus** runs along the lower border of the petrous part of the temporal bone

# Cavernous sinuses

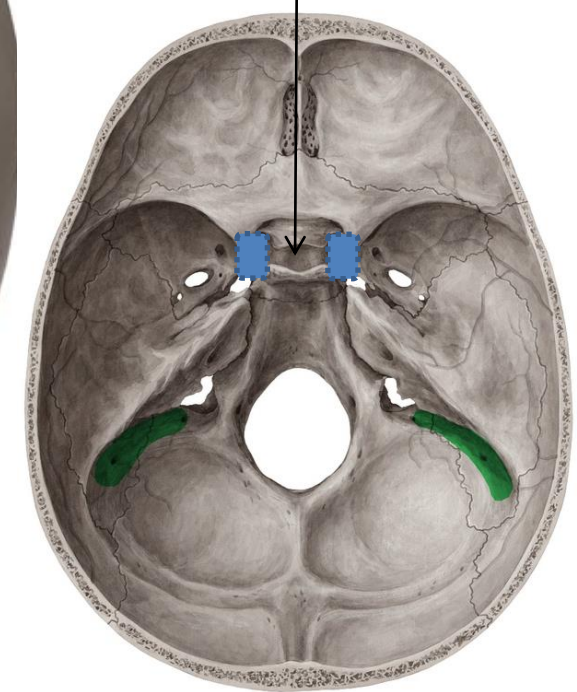
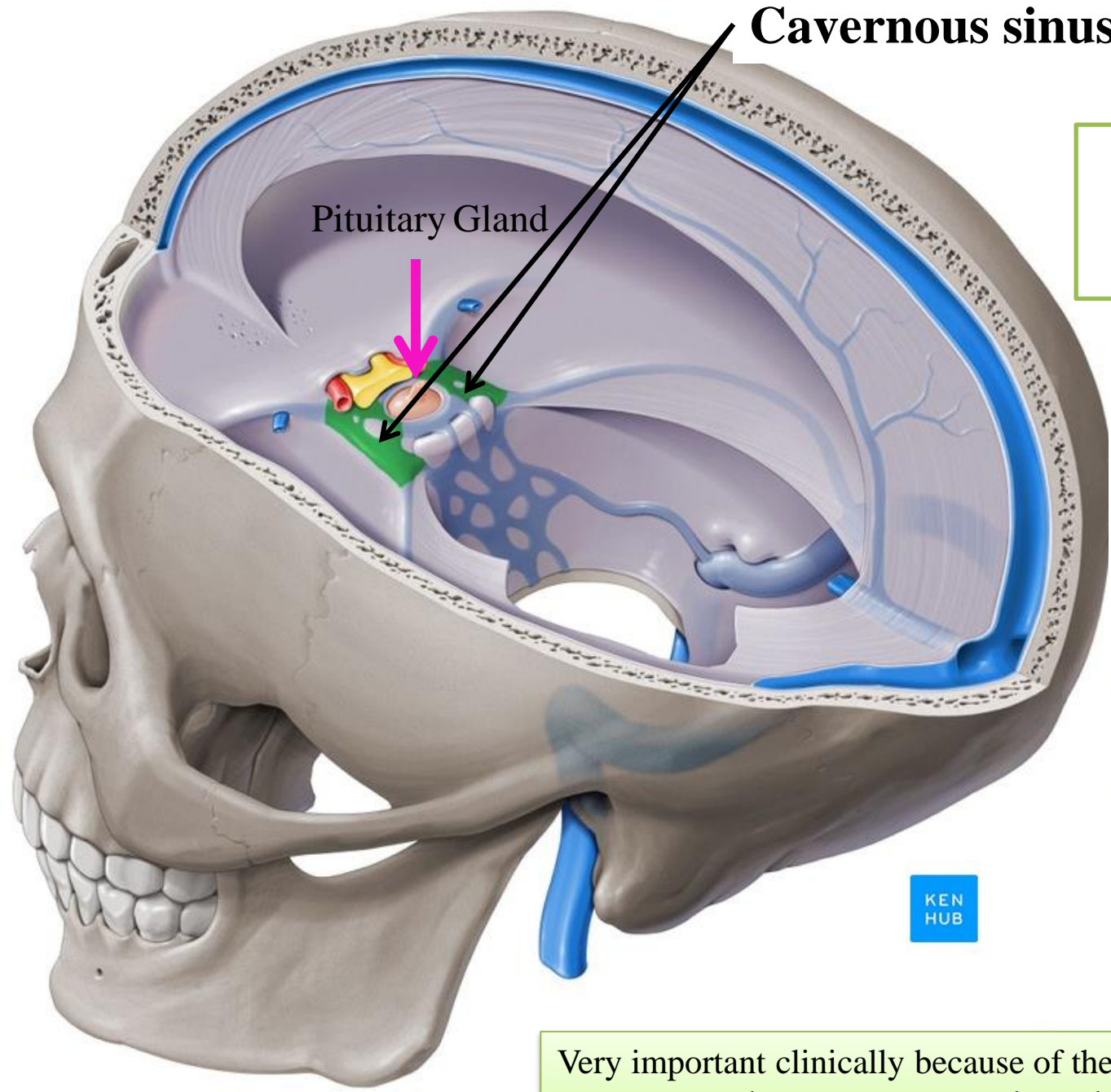
Pituitary Gland

Lies on the lateral side of the **body of the sphenoid bone**

KEN HUB

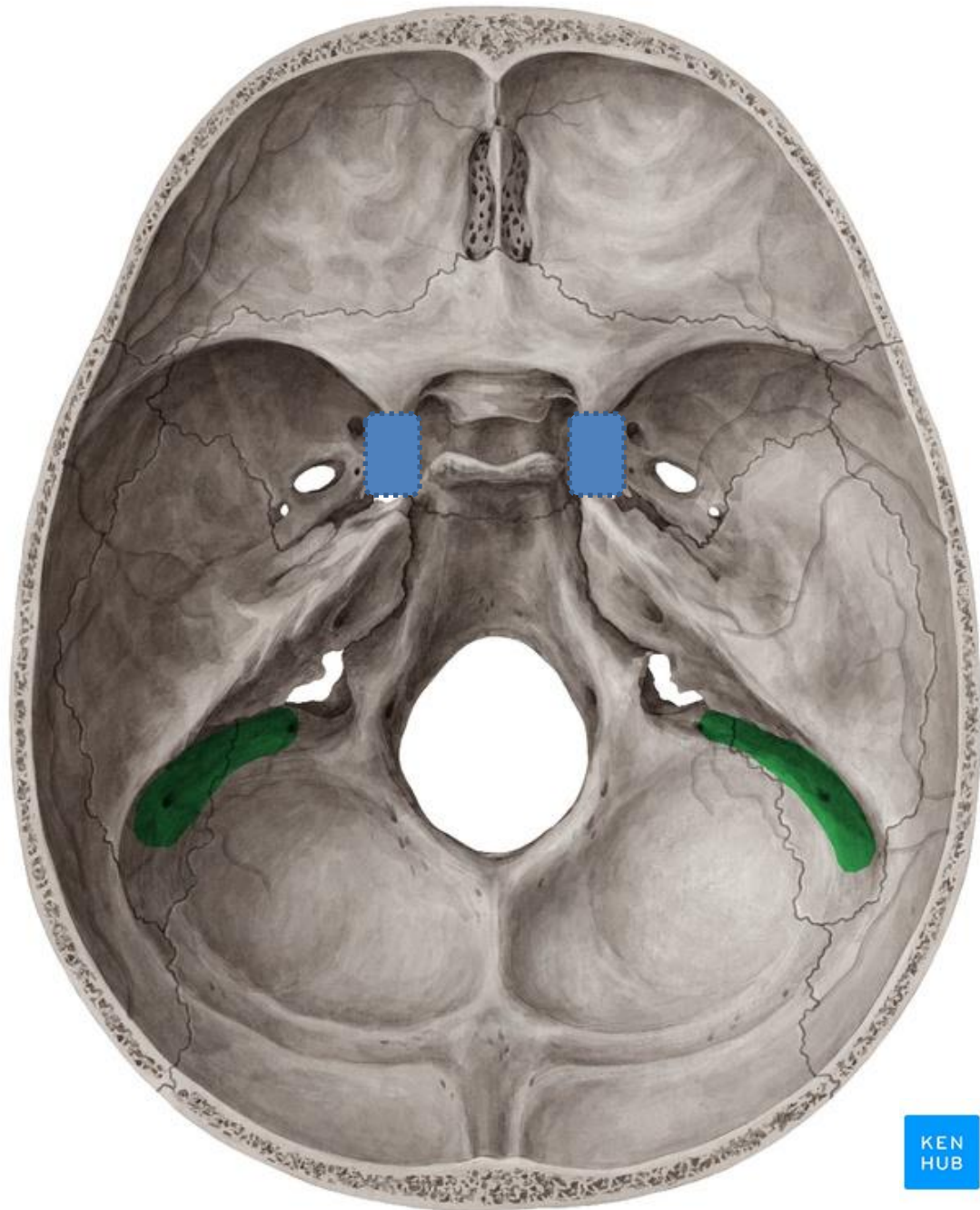
Very important clinically because of their connections and the structures pass through them

*Dr. Heba Kalbouneh*

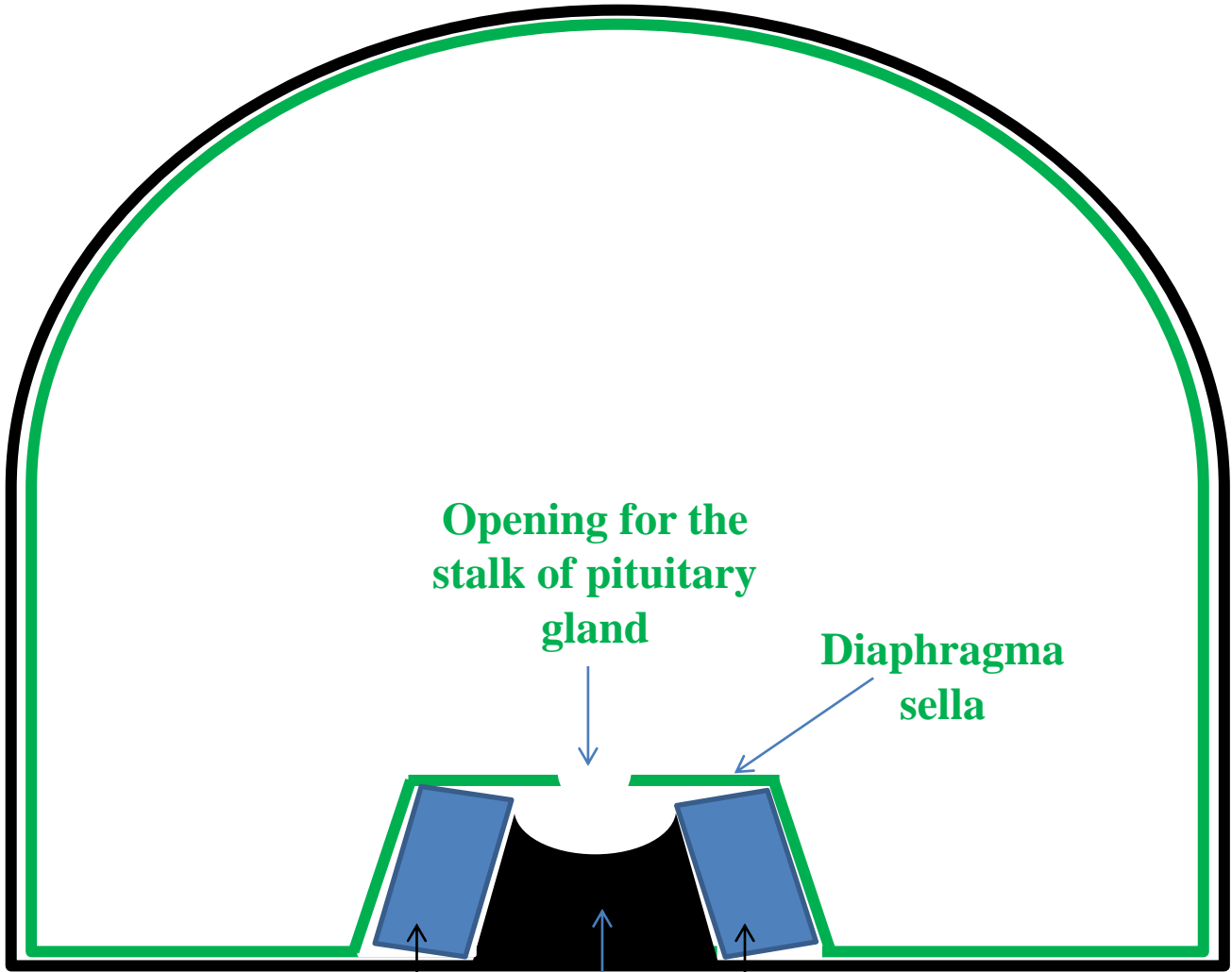


© www.kenhub.com

**Cavernous sinuses** lie on the lateral side of the body of the sphenoid bone



**Meningeal  
layer of  
dura mater**

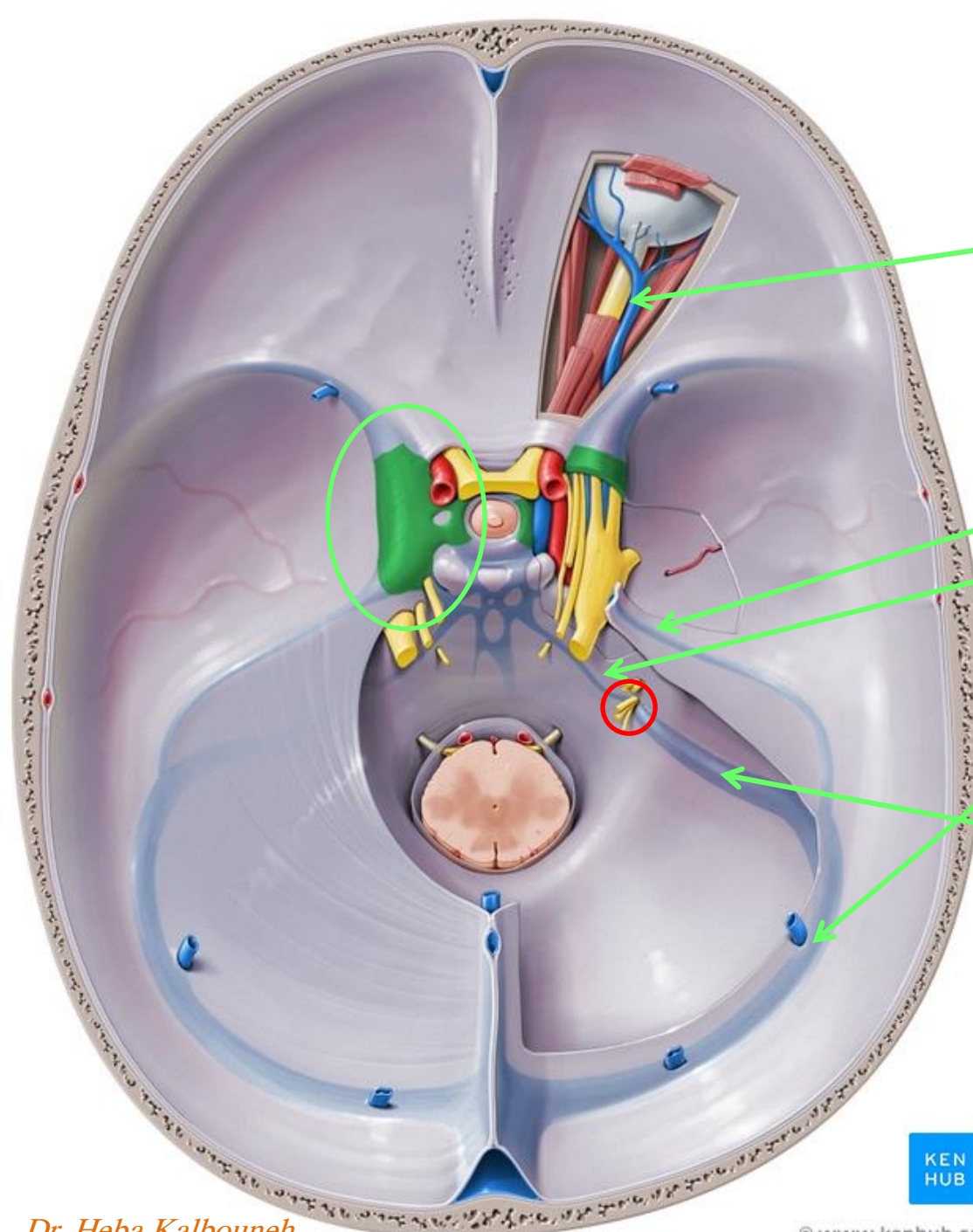


**Opening for the  
stalk of pituitary  
gland**

**Diaphragma  
sella**

**Body of sphenoid  
with sella turcica**

**Cavernous sinuses**



Anteriorly, the sinus receives

- 1-Ophthalmic veins**
- 2-Central vein of retina**

The sinus drains posteriorly into:

- Superior petrosal sinus**
- Inferior petrosal sinus**

then

- Superior petrosal sinus**
- and

**Transverse sinus** drain into  
**sigmoid sinus**

Inferior petrosal sinus passes through  
jugular foramen to drain directly into  
**Internal jugular vein**



**Intercavernous sinuses**

# CONNECTIONS OF CAVERNOUS SINUS

These two connections are an important route for the spread of infection from the face

1- **Ophthalmic veins** connect cavernous sinus with the facial vein

2- **Emissary veins** connect cavernous sinus with pterygoid plexus of veins in the infratemporal fossa

Facial vein

deep facial vein

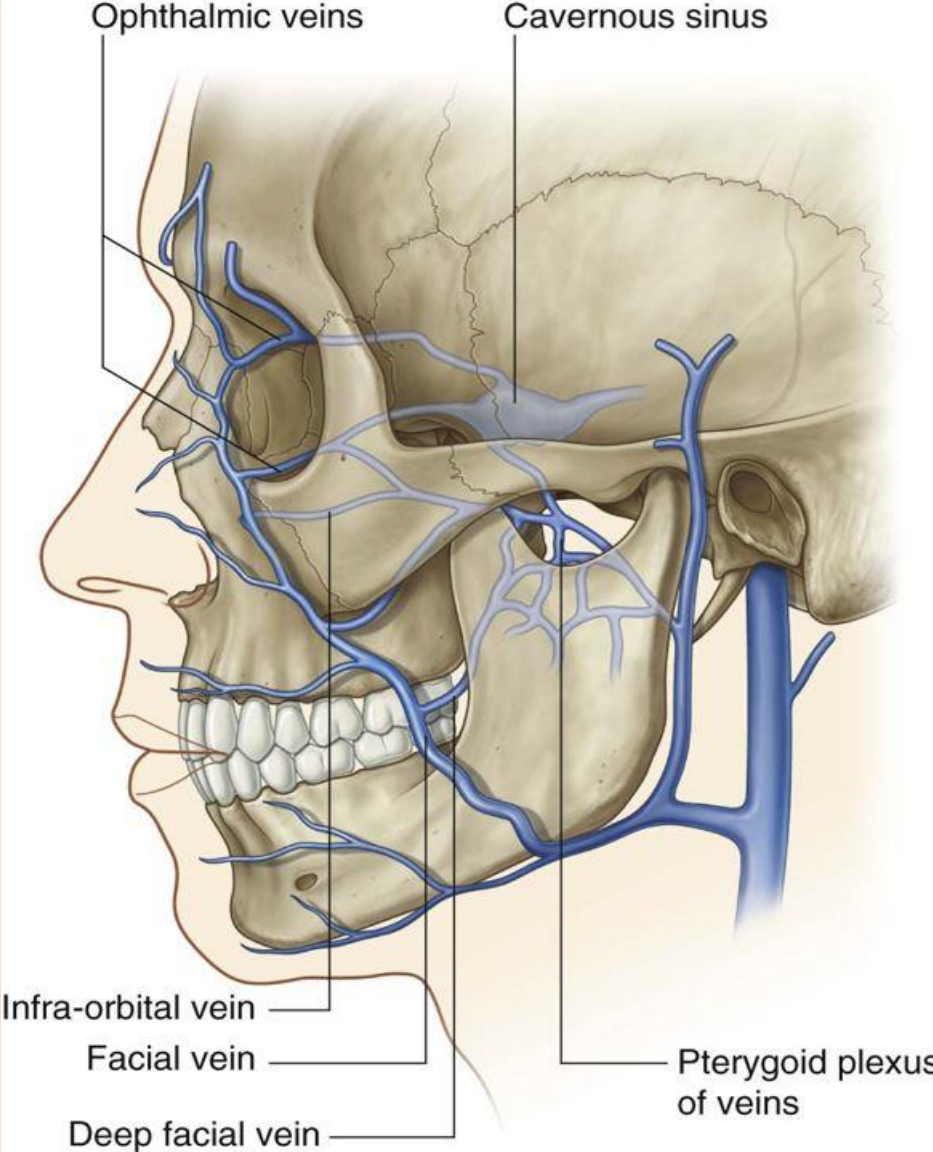
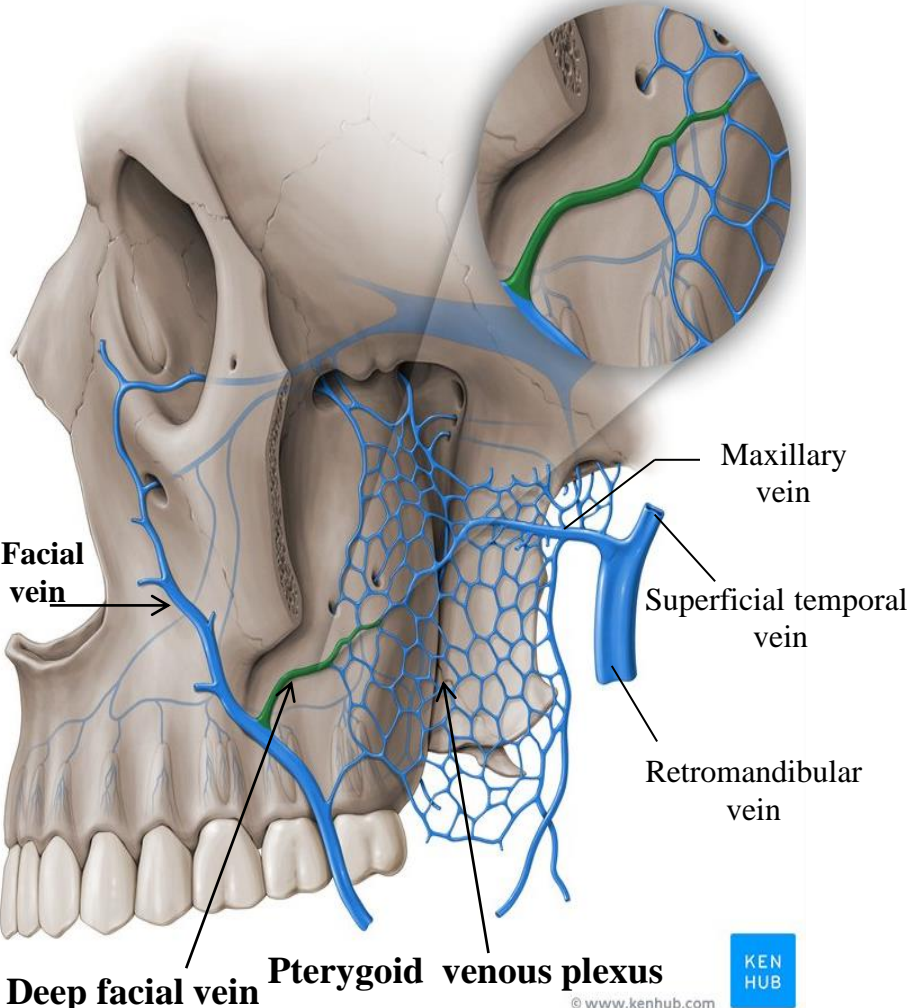
Emissary vein

Pterygoid plexus



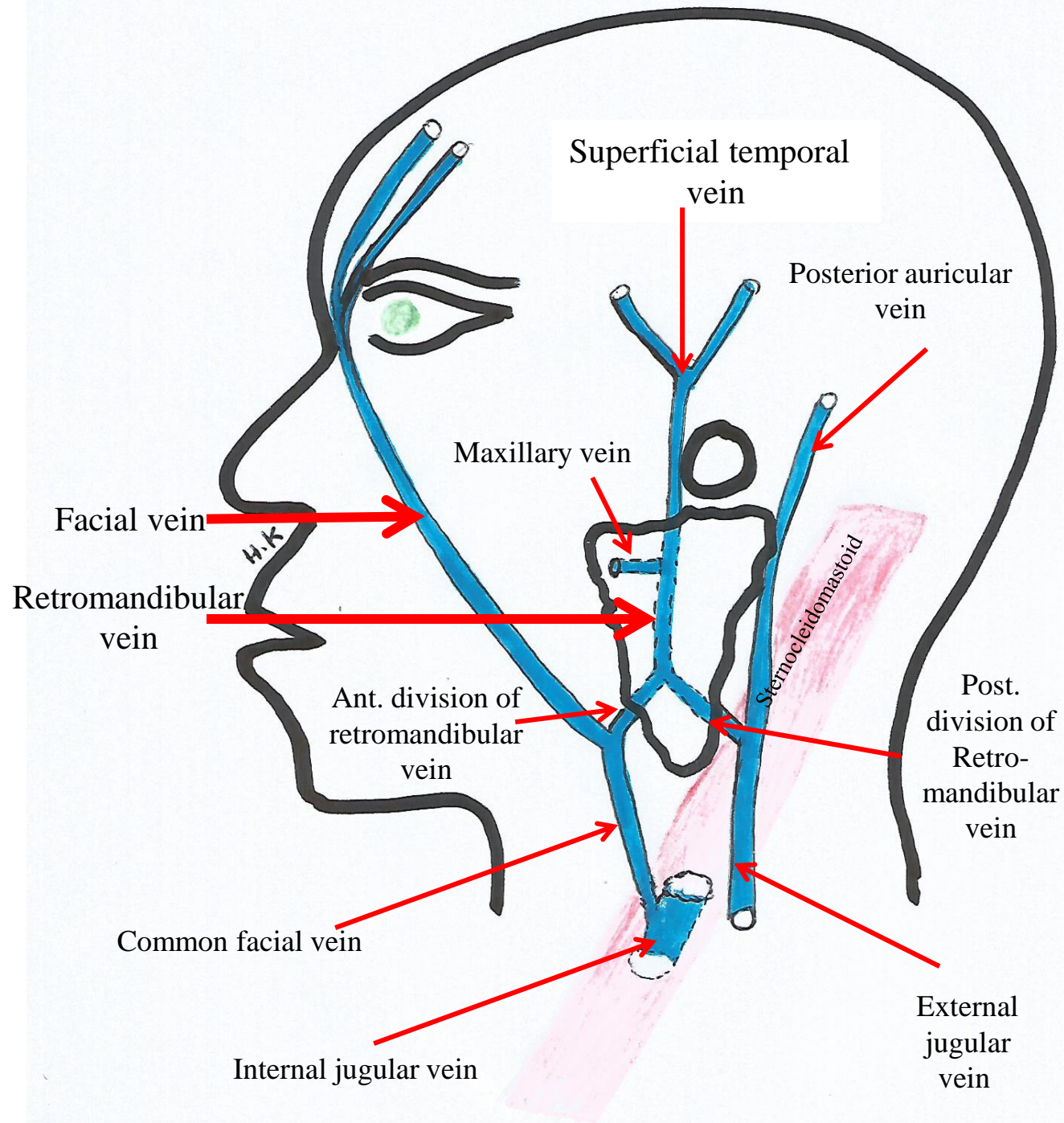
**Pterygoid venous plexus** forms the maxillary vein

Maxillary vein unites with superficial temporal vein to form retromandibular vein within the parotid gland



*The deep facial vein connects the facial vein with the pterygoid venous plexus.*

What are the structures within parotid gland?



## Important Structures Associated With the Cavernous Sinuses

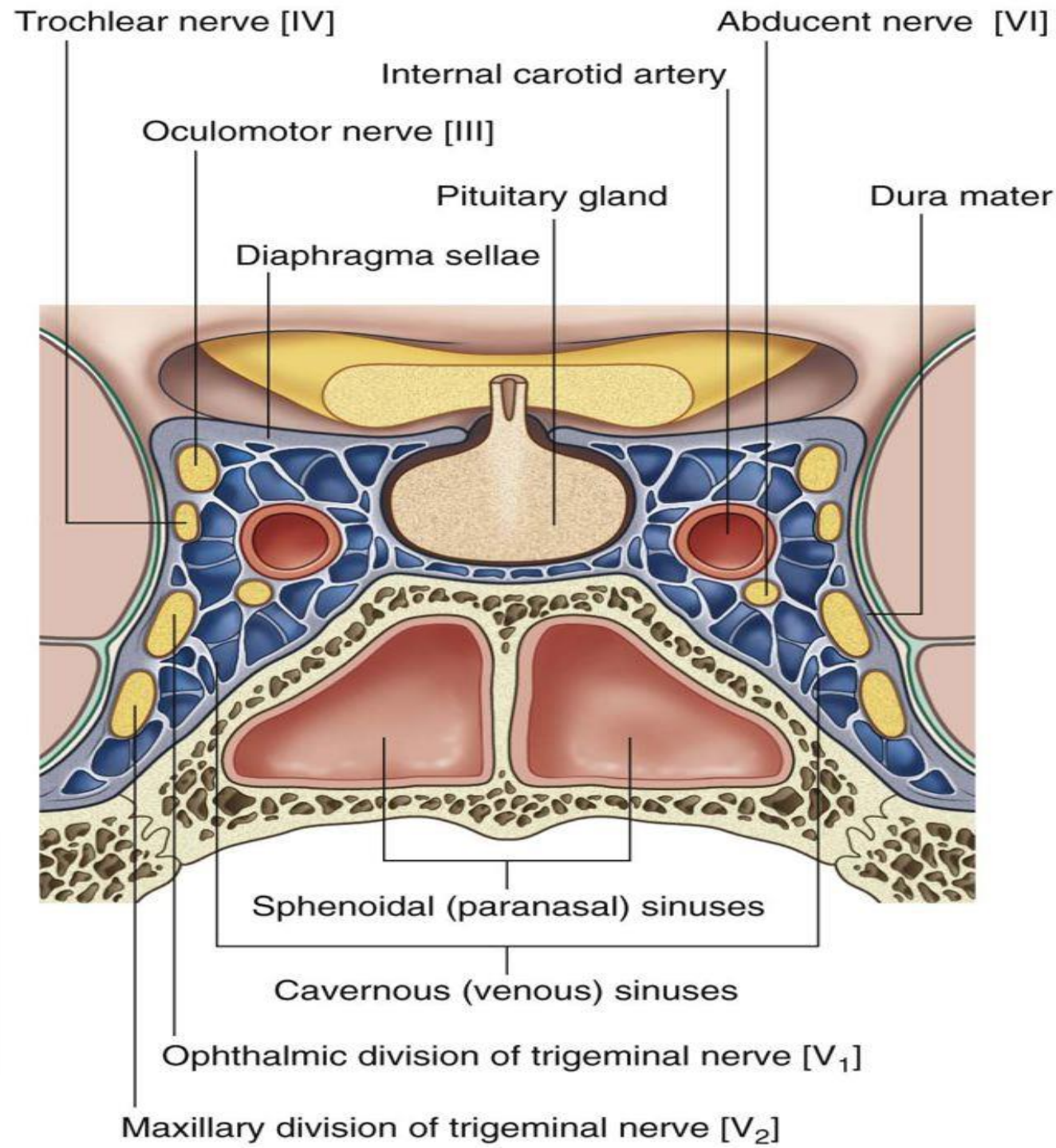
- 1-Internal carotid artery
- 2-Sixth cranial nerve

### In the lateral wall

- 1- Third cranial nerve
- 2- Fourth cranial nerve
- 3- Ophthalmic and maxillary divisions of the fifth cranial nerve
- 4-The pituitary gland, which lies medially in the sella turcica

Note:

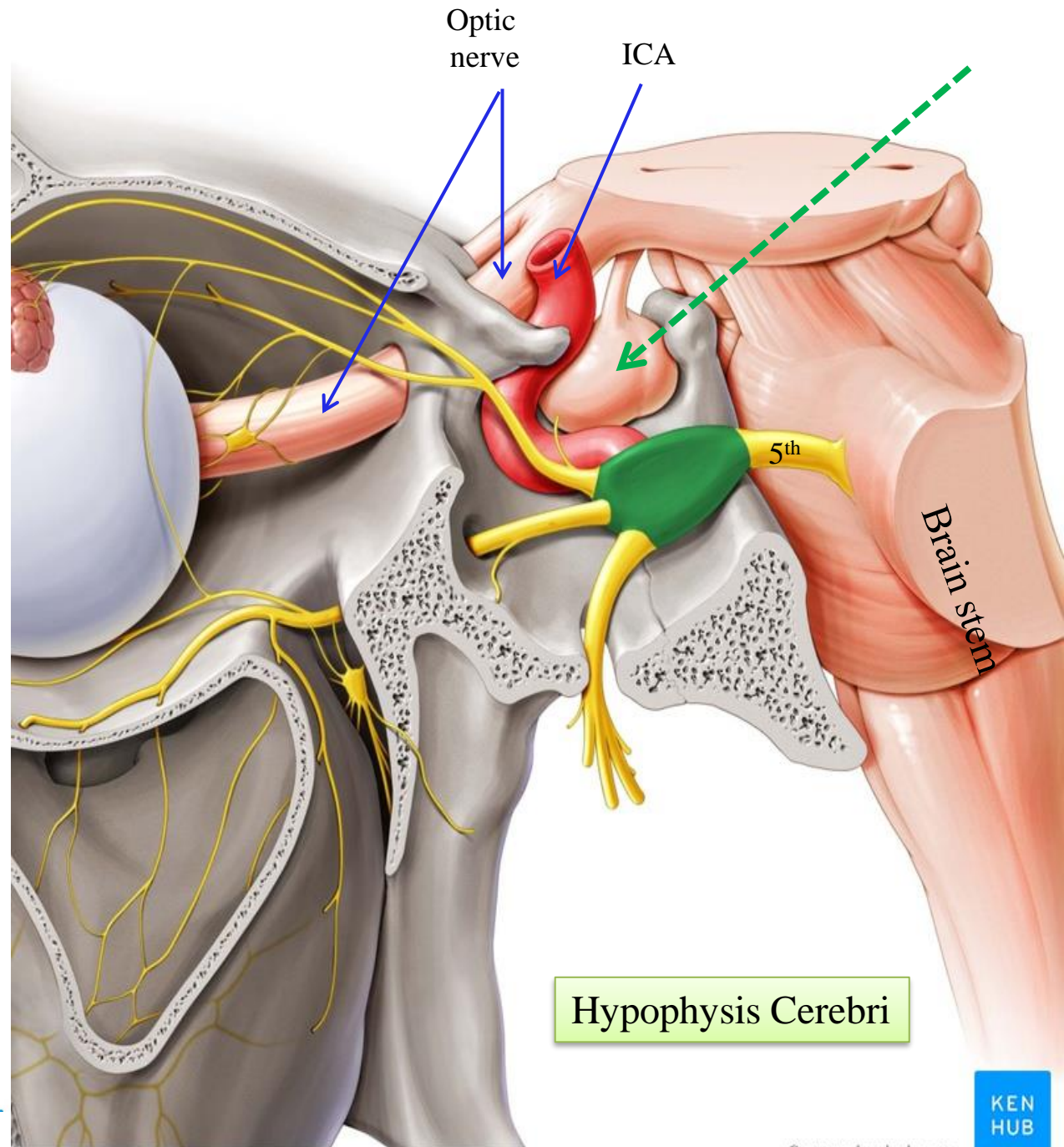
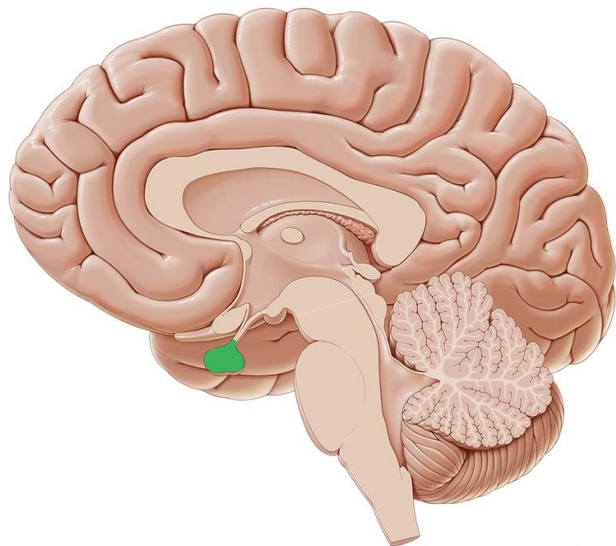
The mandibular division is not associated with cavernous sinus  
 !!!!!!!!!!!!!!!!!!!!!!!



# Pituitary Gland

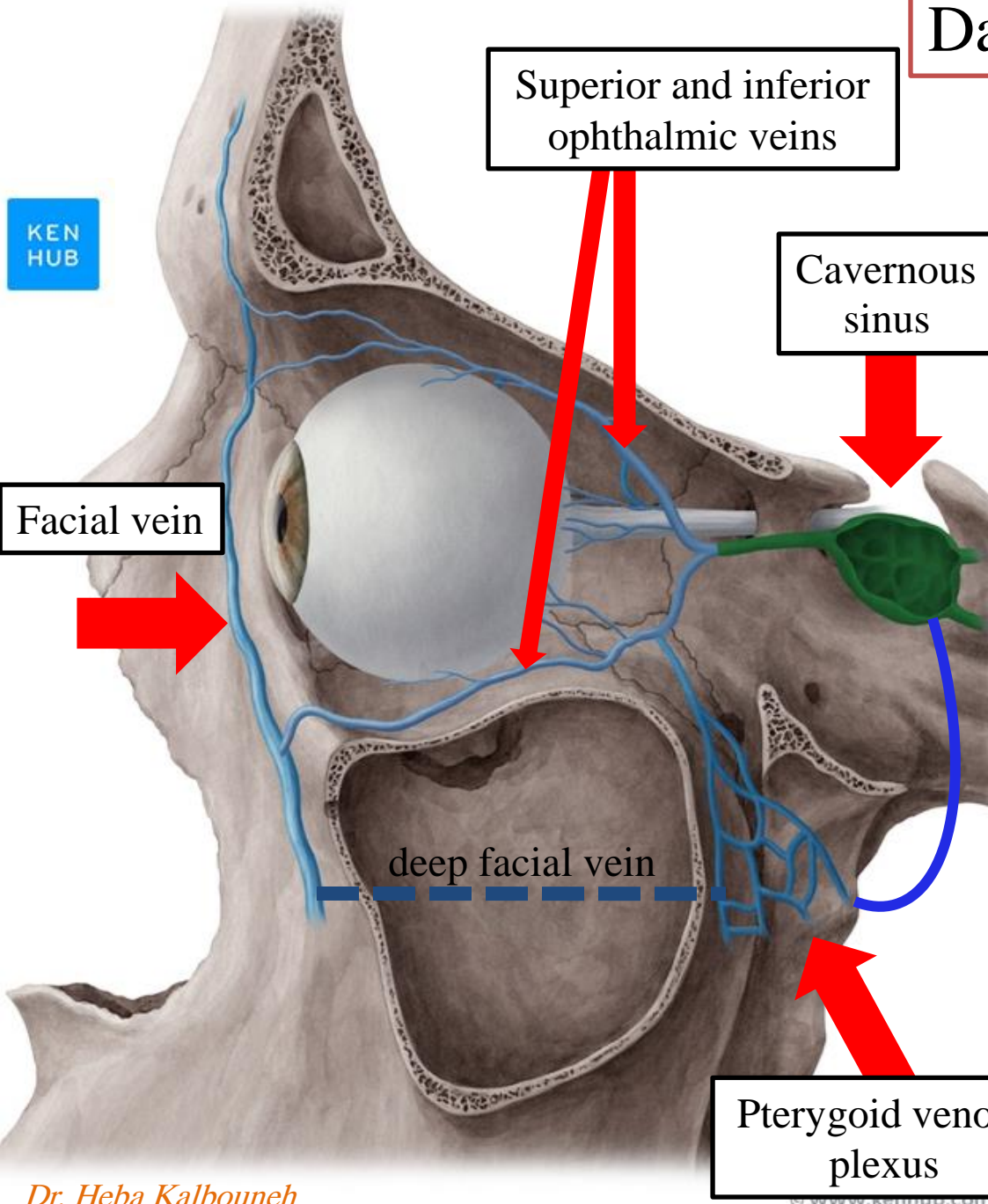
The pituitary gland is a small, oval structure attached to the undersurface of the brain by the **Infundibulum**

The gland is well protected in the sella turcica of the sphenoid bone

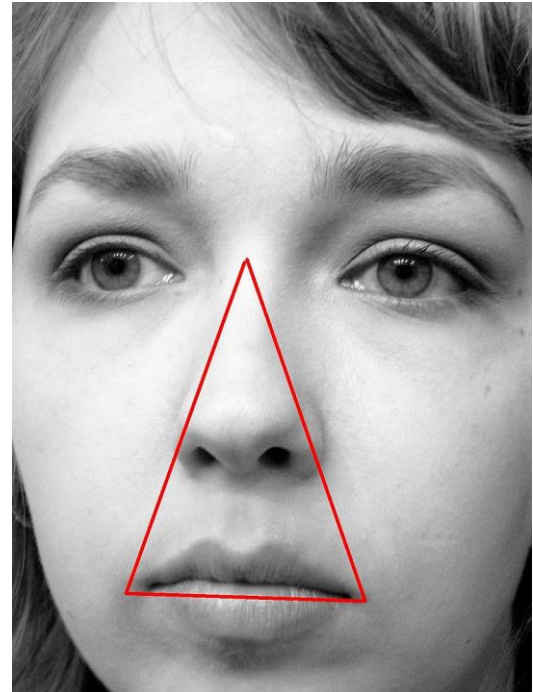


# Danger triangle of the face

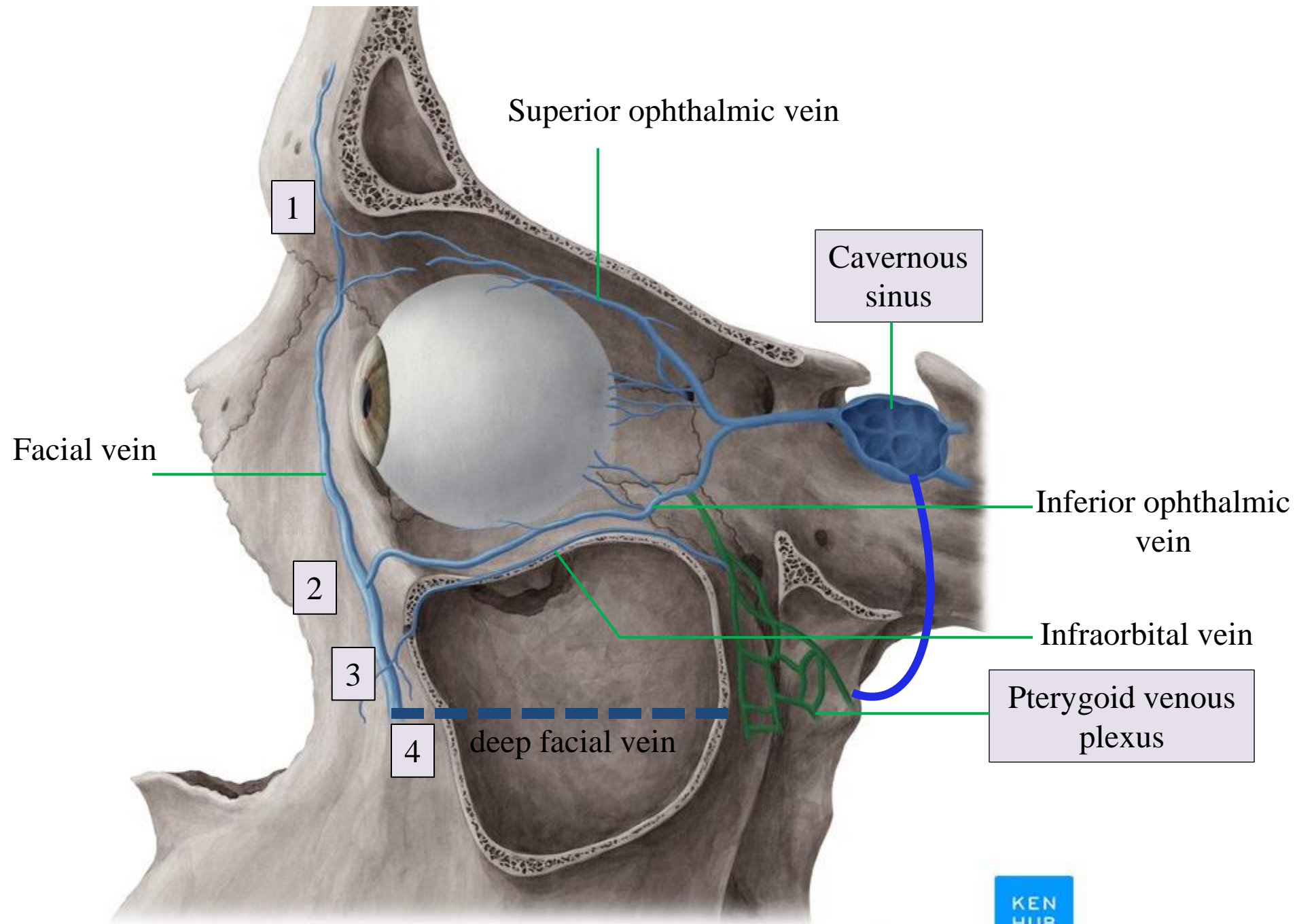
KEN HUB



Note: venous communication (via the ophthalmic veins) between the facial vein and the cavernous sinus



Cavernous sinus syndrome



# Danger area of the face

Remember that pterygoid venous plexus drains also nasal sinuses, teeth, ears, nose and deep structures

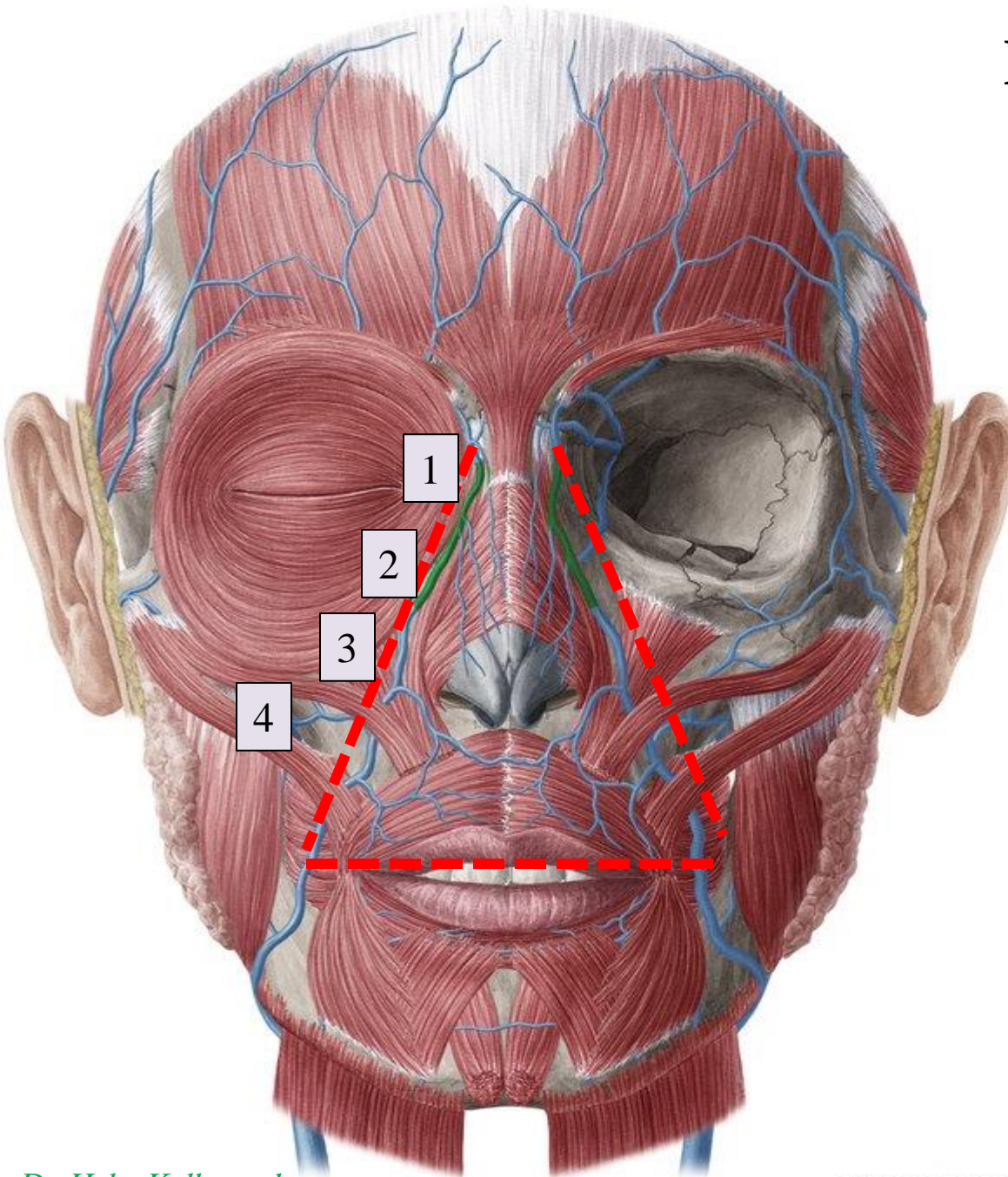
Infection spreading from the nose, sinuses, ears, or teeth

May cause



Septic cavernous sinus thrombosis (the formation of a blood clot within the cavernous sinus)

*Staphylococcus aureus* and *Streptococcus* are often the associated bacteria.

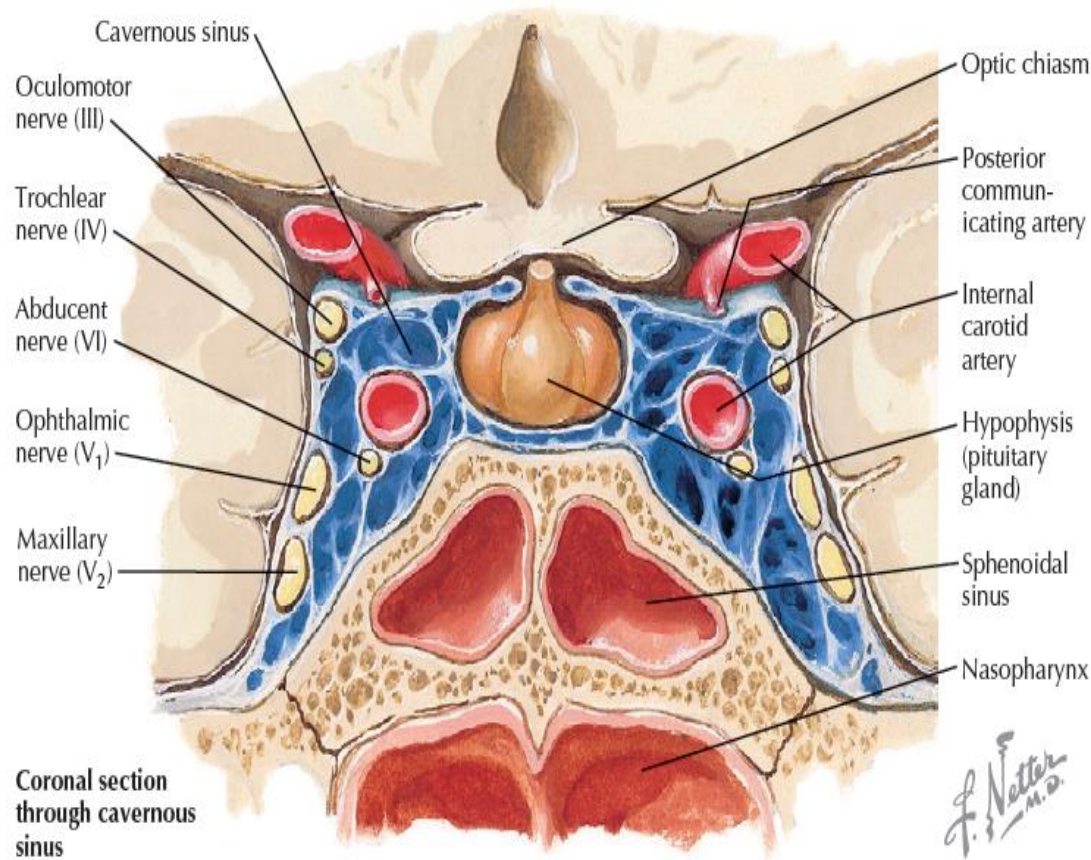


# Cavernous sinus syndrome

Can result from sepsis from the central portion of the face, teeth, nose or paranasal sinuses

## Clinical manifestations:

- Ophthalmoplegia with diminished pupillary light reflexes
- Venous congestion leading to periorbital edema
- Exophthalmos
- Pain or numbness of the face

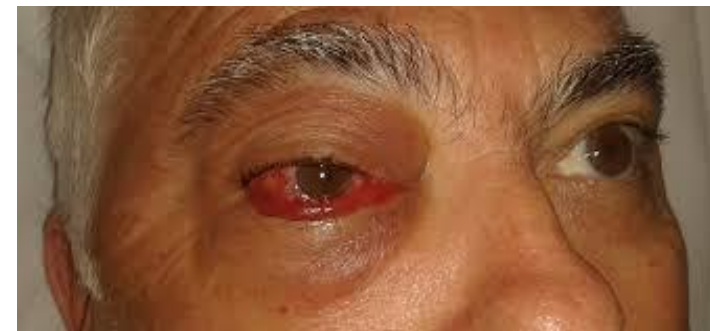

Subsequent infection or inflammation in the cavernous sinus can result in damage to any of the cranial nerves that pass through it

**Exophthalmos** is a bulging of the eye anteriorly out of the orbit

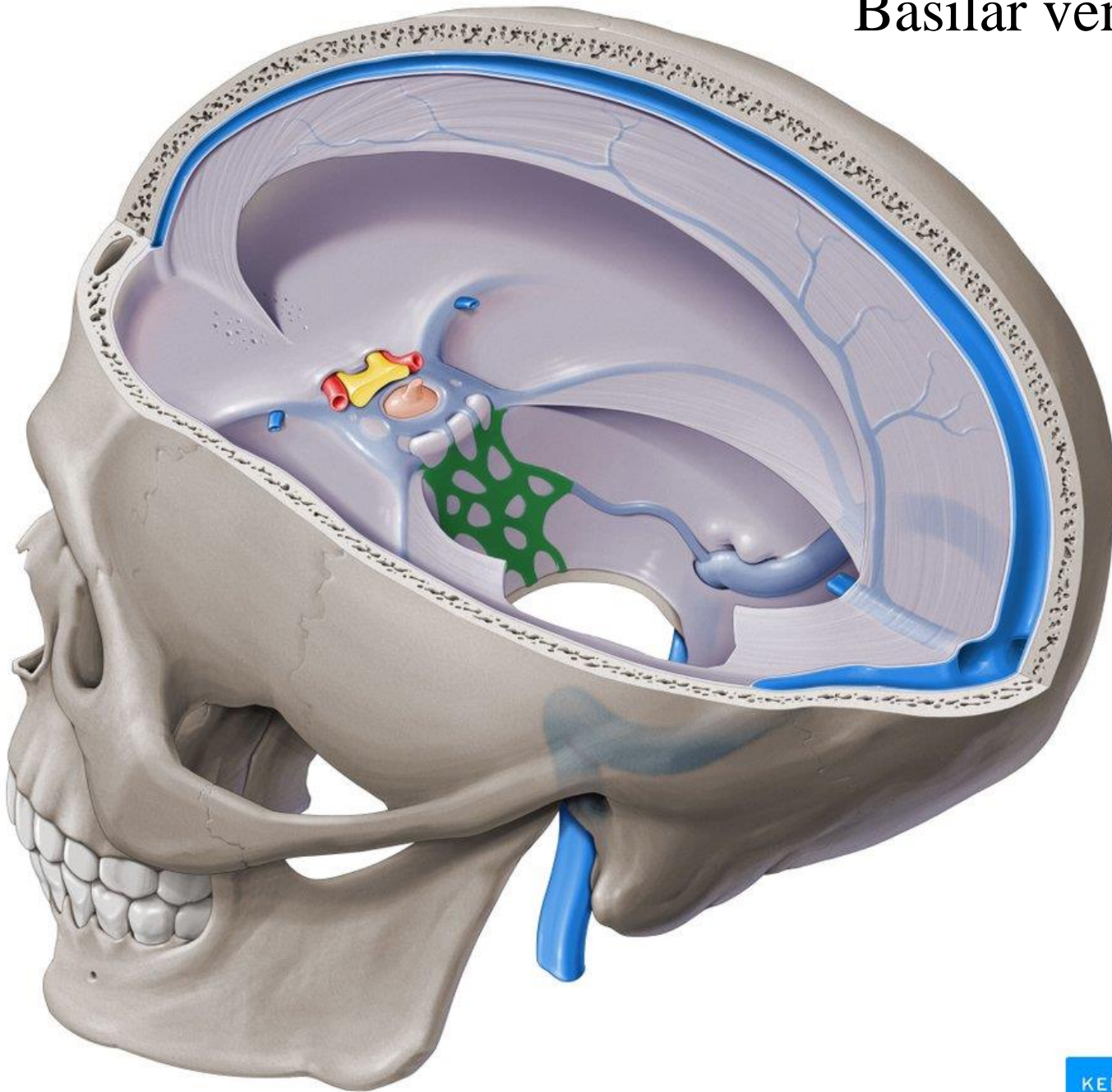
**Ophthalmoplegia** is the paralysis or weakness of the eye muscles

This infection is life-threatening and requires immediate treatment, which usually includes antibiotics and sometimes surgical drainage





# Basilar venous plexus

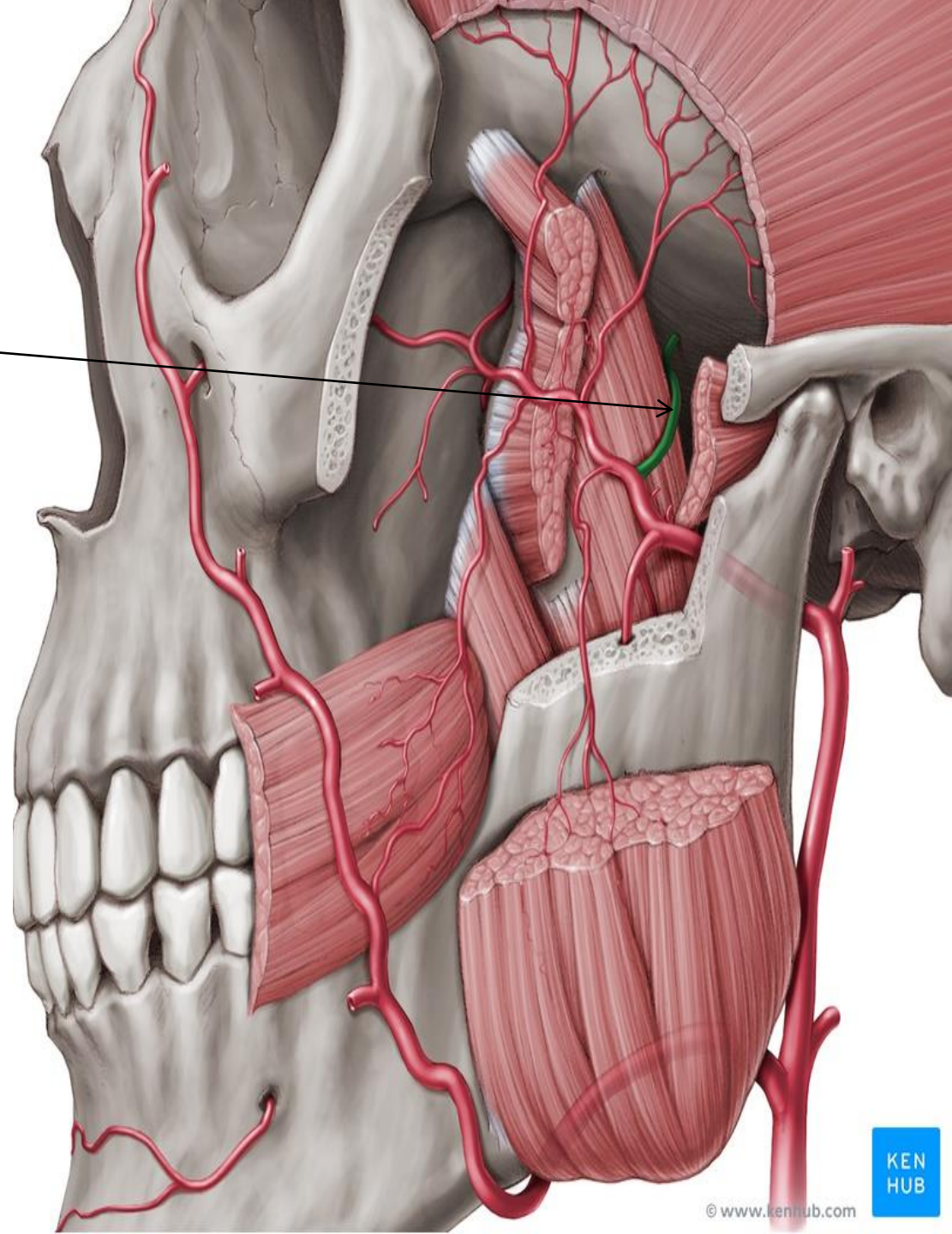


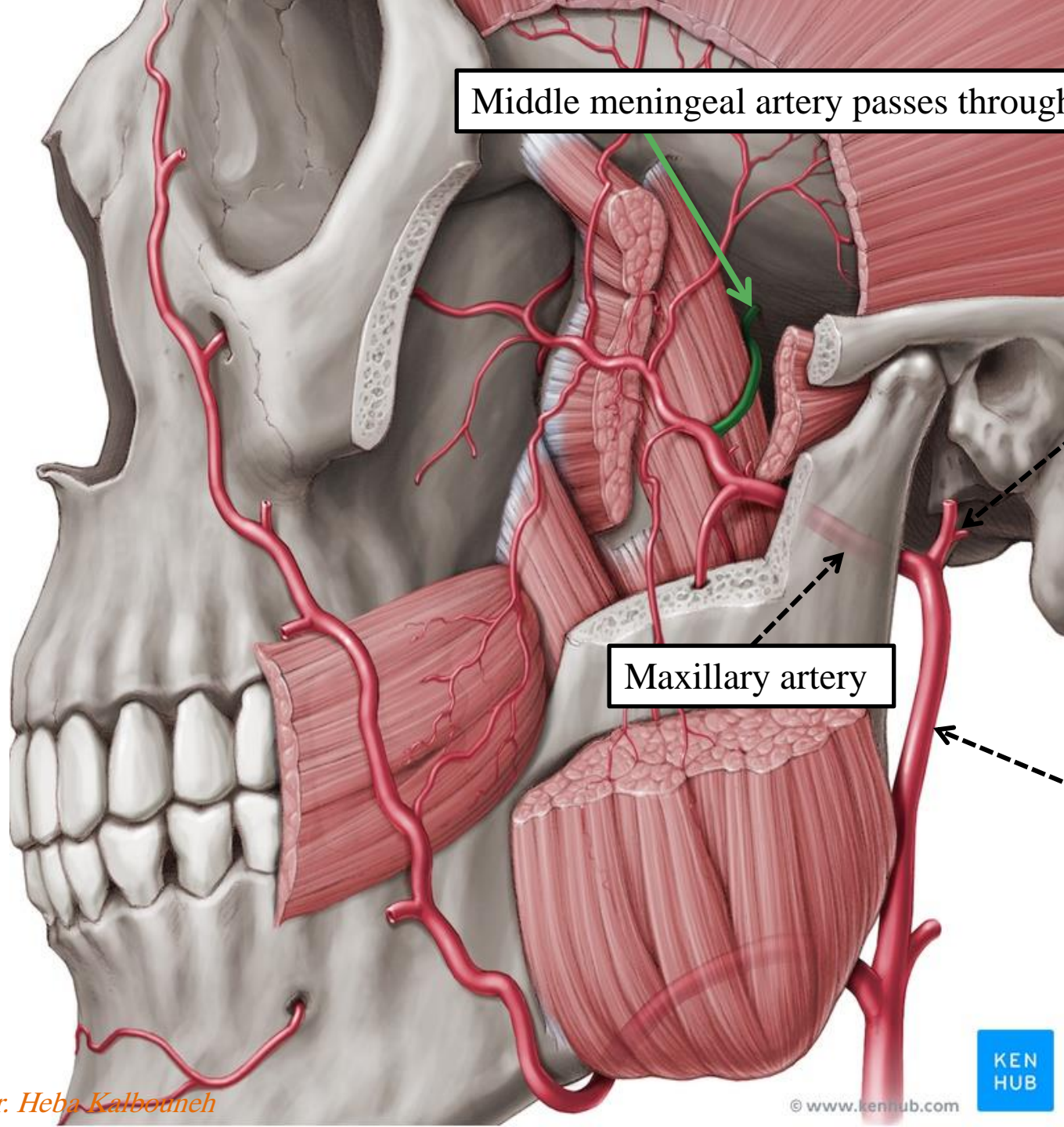
Note  
The **basilar venous plexus** lies between the two layers of the dura on the inner surface of the clivus (over the basilar part of the occipital bone) and connects the two inferior petrosal sinuses. And numerous regional venous structures

# Dural Arterial Supply

Mainly from the **middle meningeal artery**

- Arises from the maxillary artery in the infratemporal fossa it passes through the foramen spinosum to lie between the meningeal and periosteal layers of dura





Middle meningeal artery passes through foramen spinosum

Superficial temporal artery

Maxillary artery

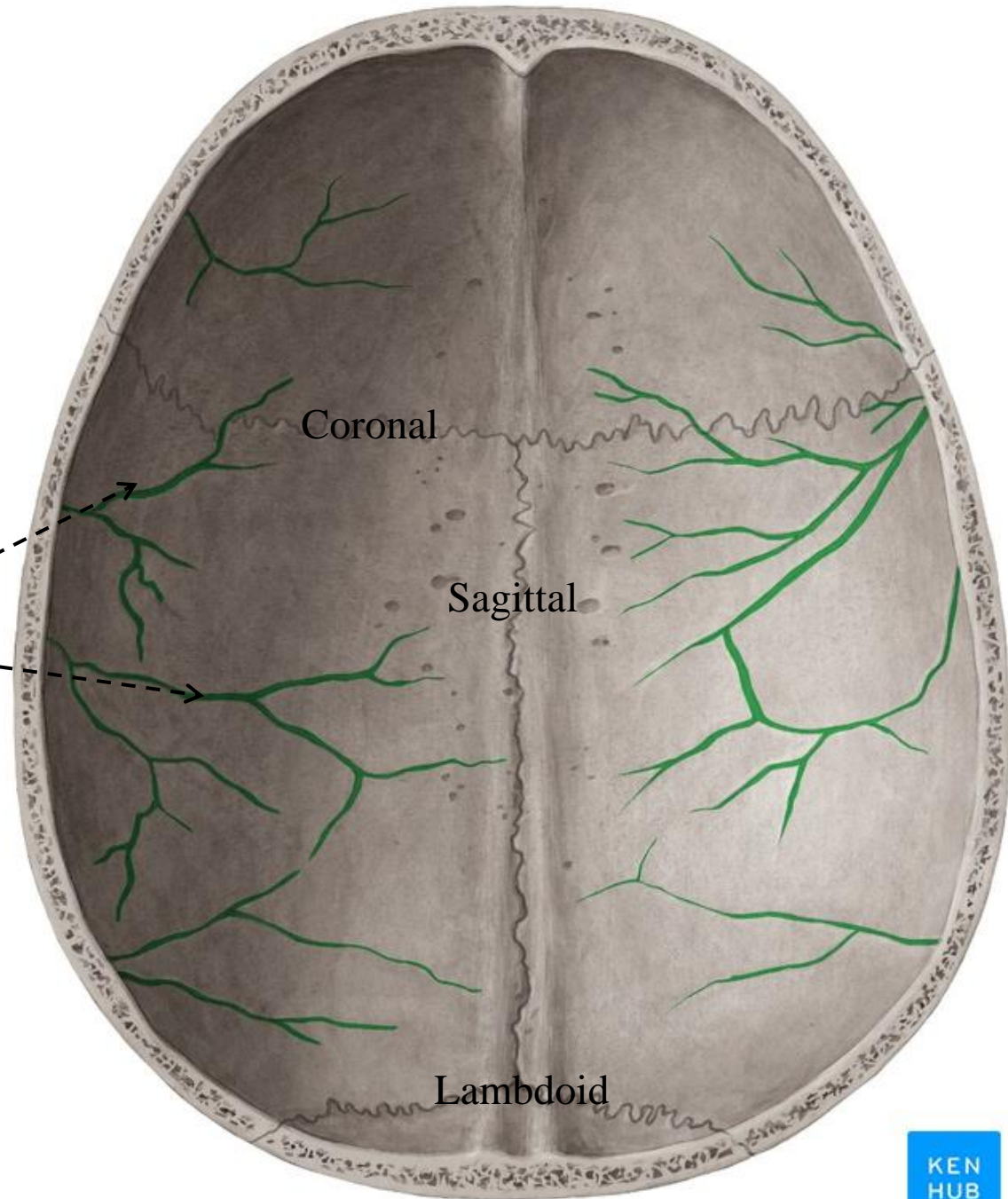
External carotid artery

# VAULT OF THE SKULL

## Inferior view

The internal surface of the vault presents:

**Grooves for the middle meningeal artery**



Middle meningeal artery passes through the foramen spinosum

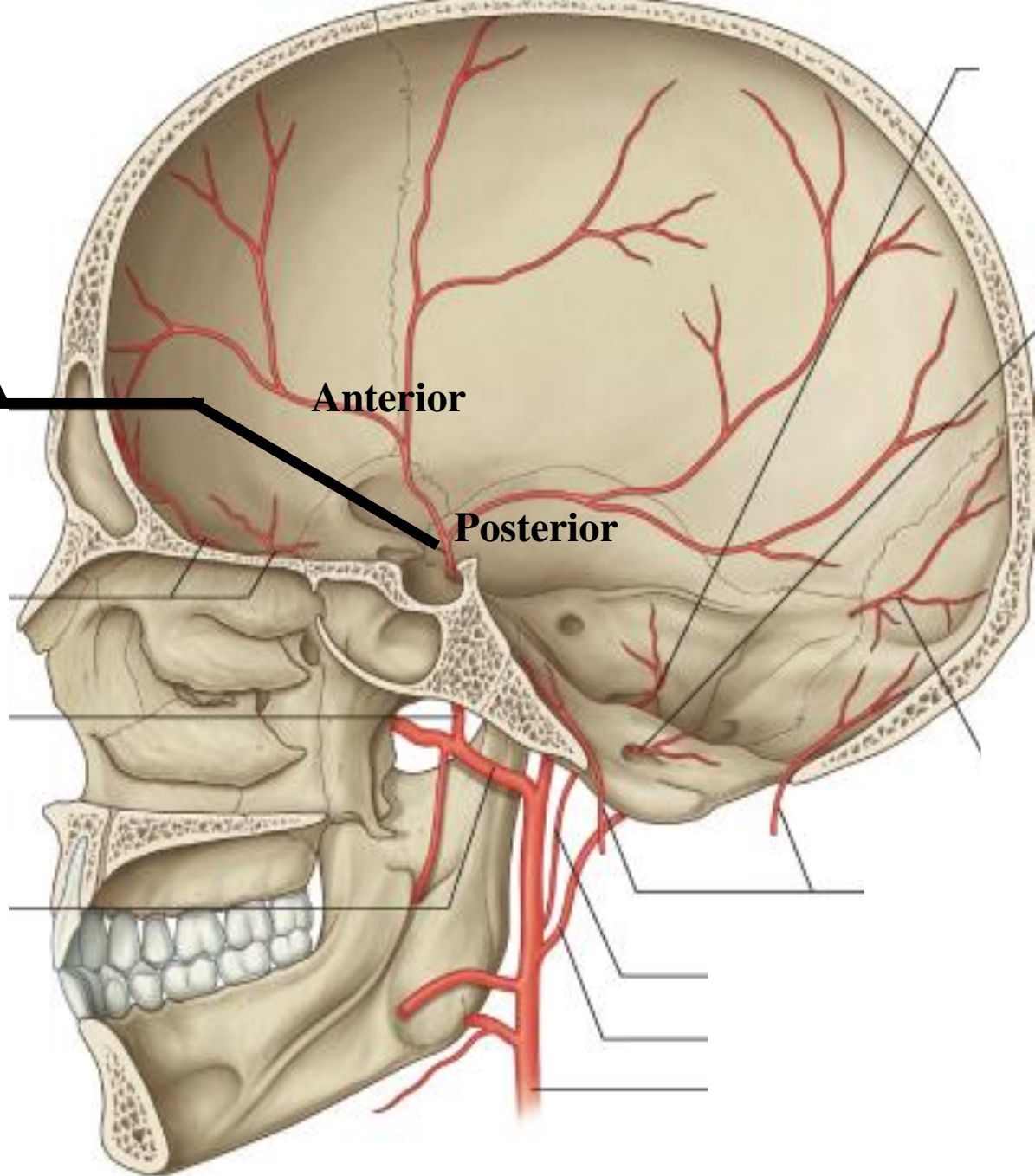
Branches of Middle Meningeal Artery:

**The anterior (frontal)**

- ✓ Passes in an almost vertical direction to reach the vertex of skull
- ✓ Crosses the pterion during its course

**The posterior (parietal)**

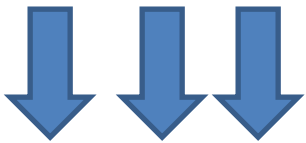
- ✓ Passes in a posterosuperior direction



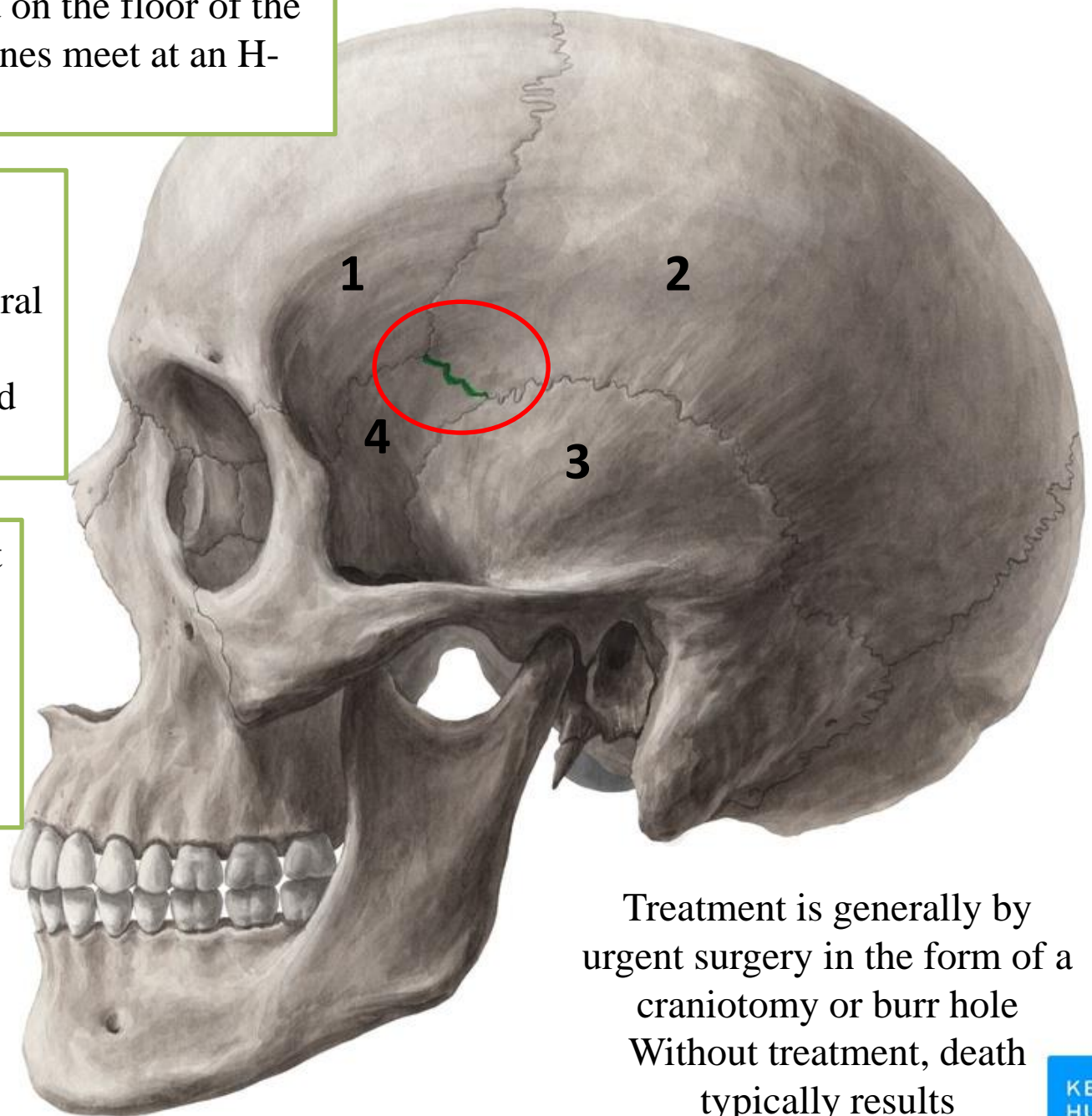
**Pterion:** is an area located on the floor of the temporal fossa where 4 bones meet at an H-shaped structure

- 1- Frontal
- 2- Parietal
- 3- Squamous part of temporal bone
- 4- Greater wing of sphenoid

The pterion is the thinnest part of the lateral wall of the skull. It overlies the anterior division of The middle meningeal artery and vein

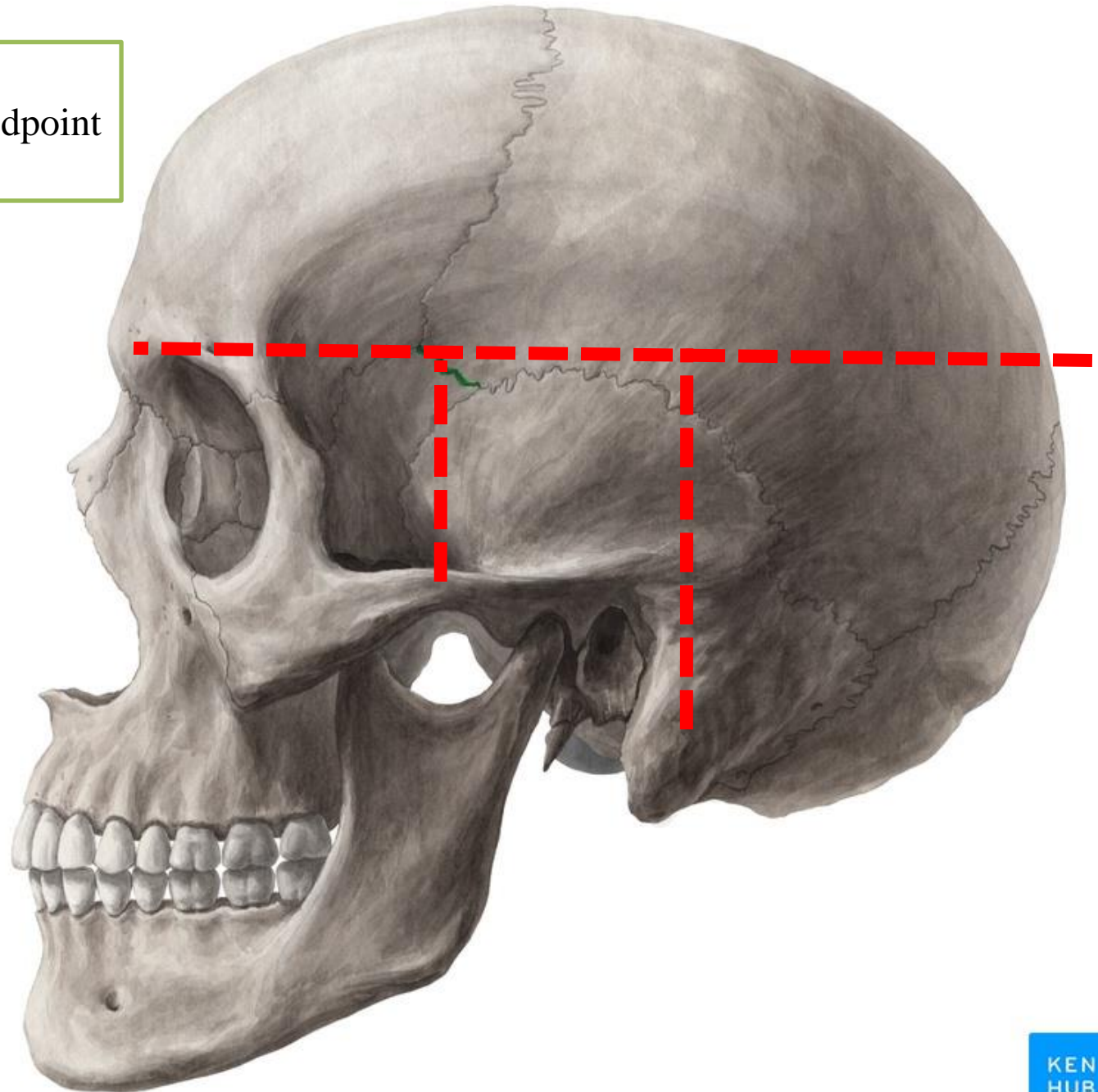


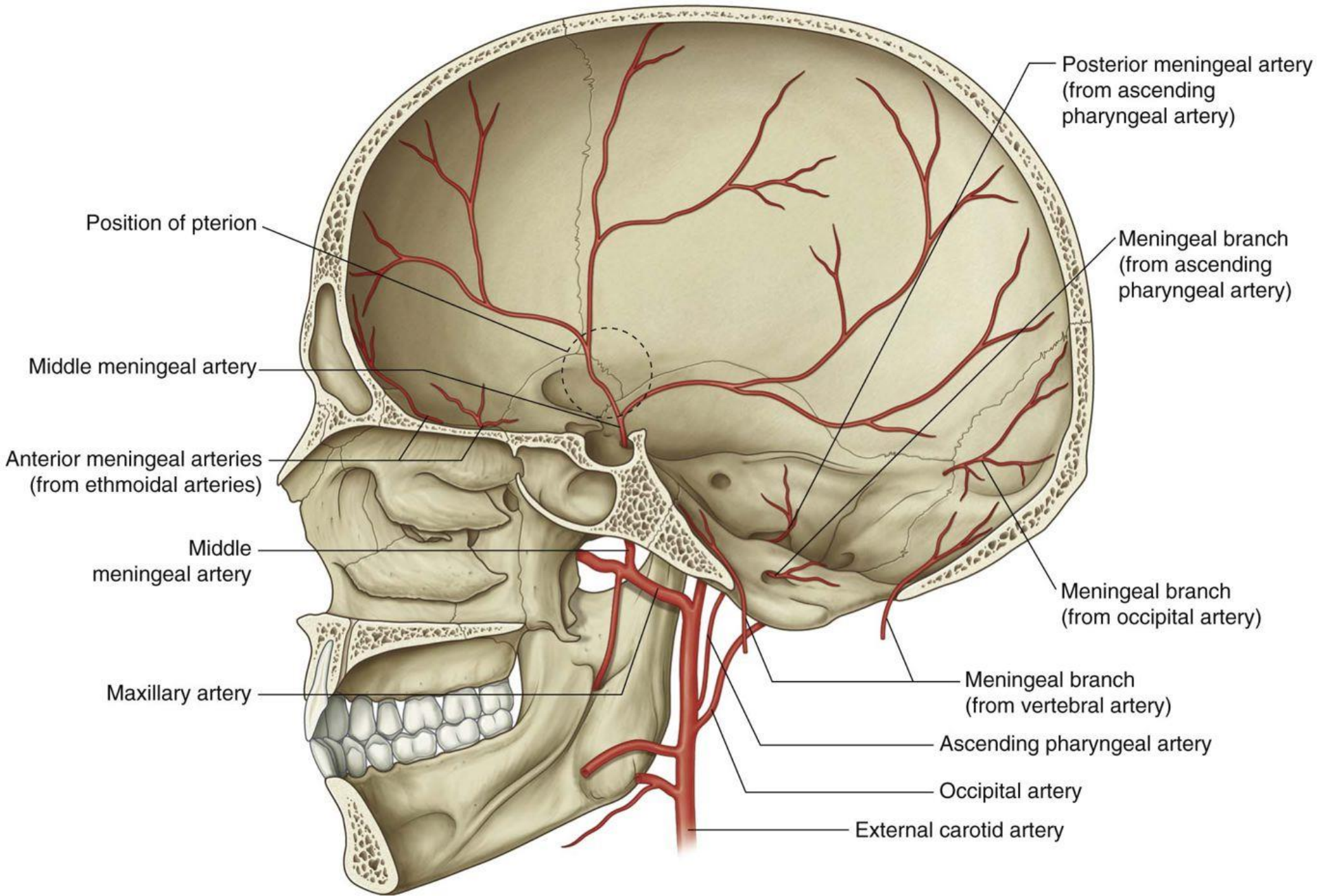
Epidural bleeding



Treatment is generally by urgent surgery in the form of a craniotomy or burr hole Without treatment, death typically results

**Pterion surface marking**  
(2.5 to 4 cm) above the midpoint  
of the zygomatic arch







## Dural Nerve Supply

Branches of the trigeminal, vagus, and upper cervical nerves

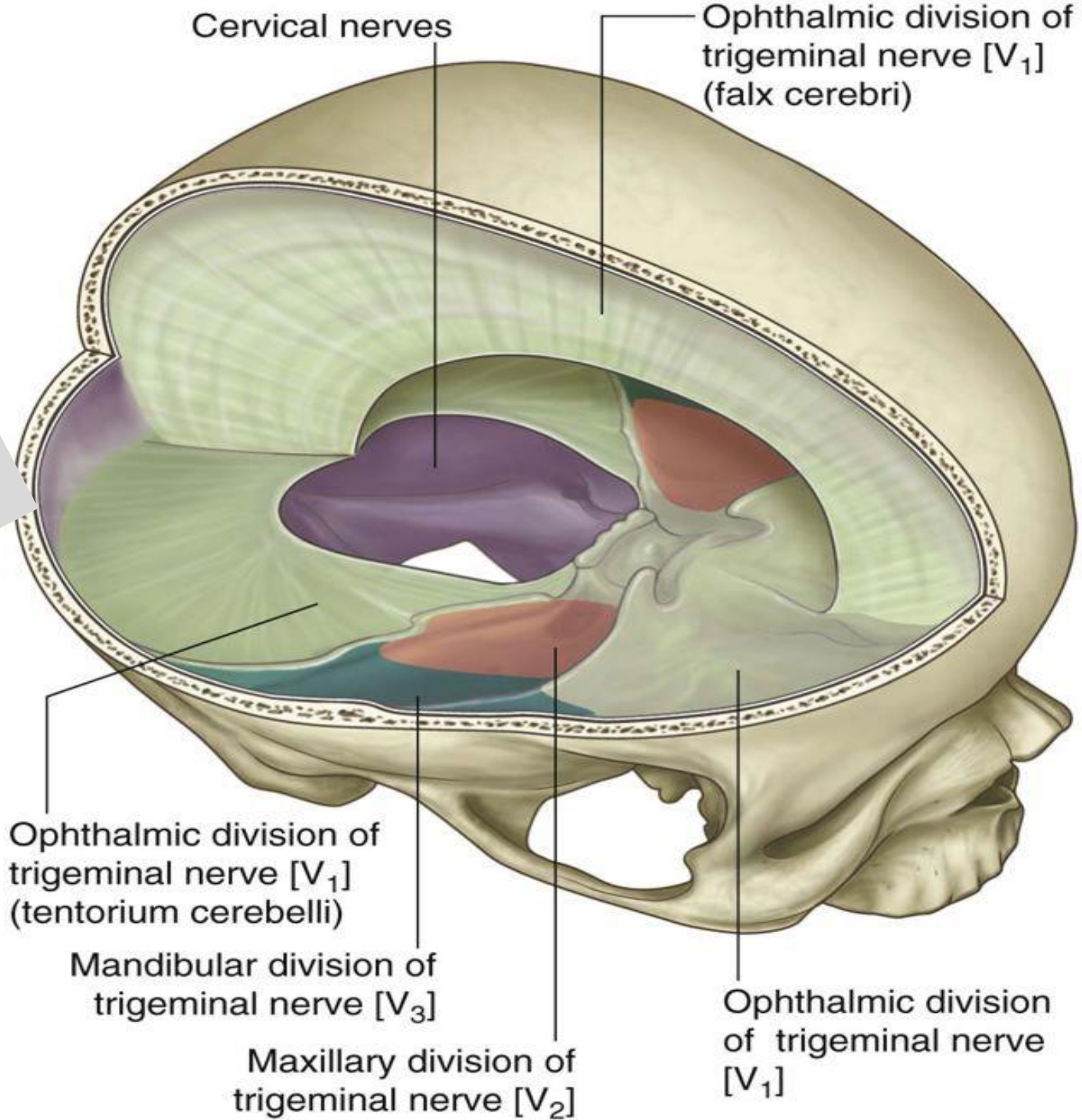
The dura is sensitive to stretching, which produces the sensation of headache.

Stimulation of the sensory endings of the trigeminal nerve above the level of the tentorium cerebelli produces **referred pain to an area of skin on the same side of the head (trigeminal distribution)**.

Stimulation of the dural endings below the level of the tentorium cerebelli (posterior cranial fossa) produces **referred pain to the back of the neck and back of the scalp along the distribution of the greater occipital nerve**

**Meningitis and stiff neck**

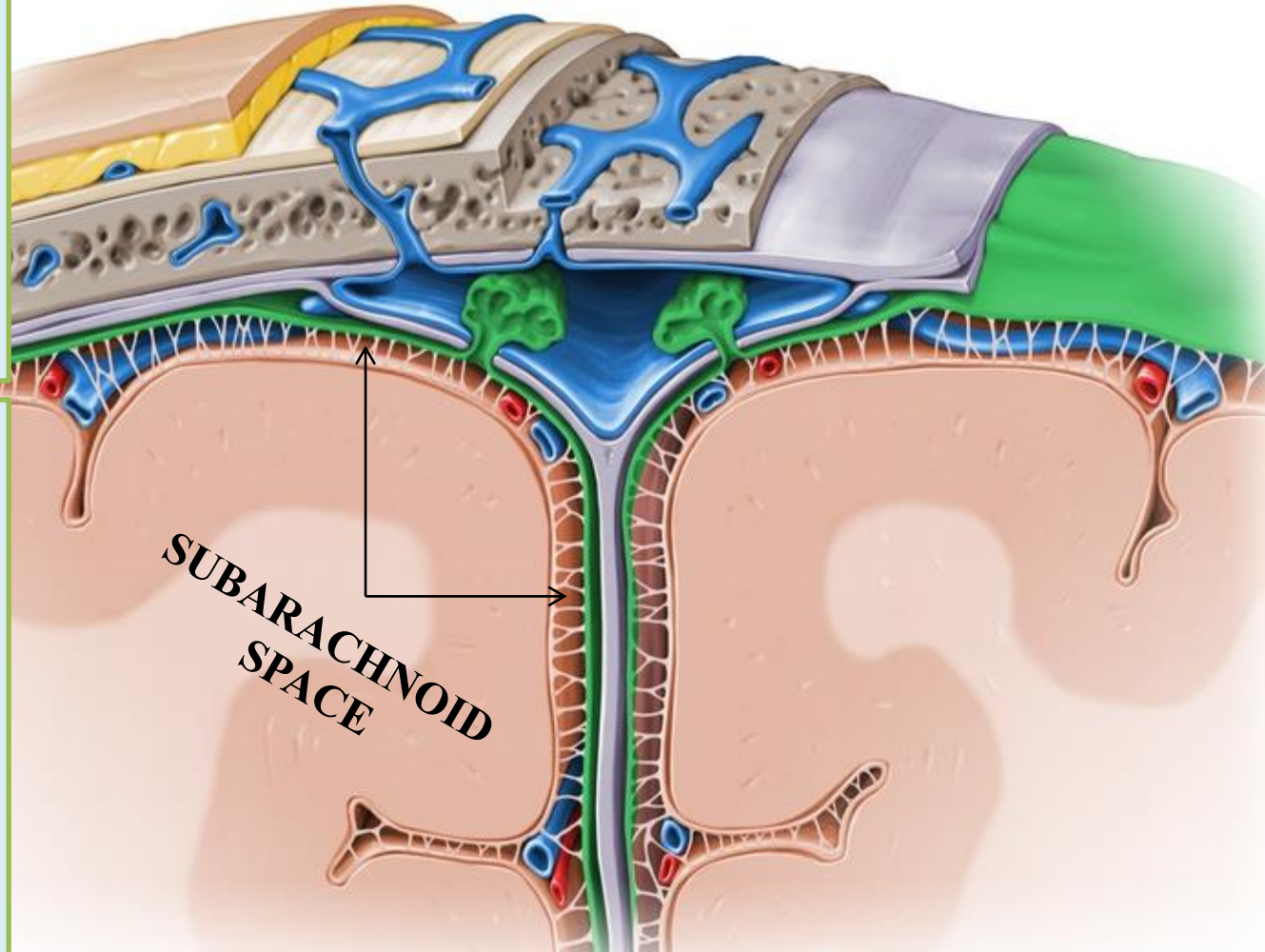
**Remember**  
Referred pain refers to the phenomenon of feeling pain in a region that is not actually the source of the pain



# Arachnoid Mater of the Brain

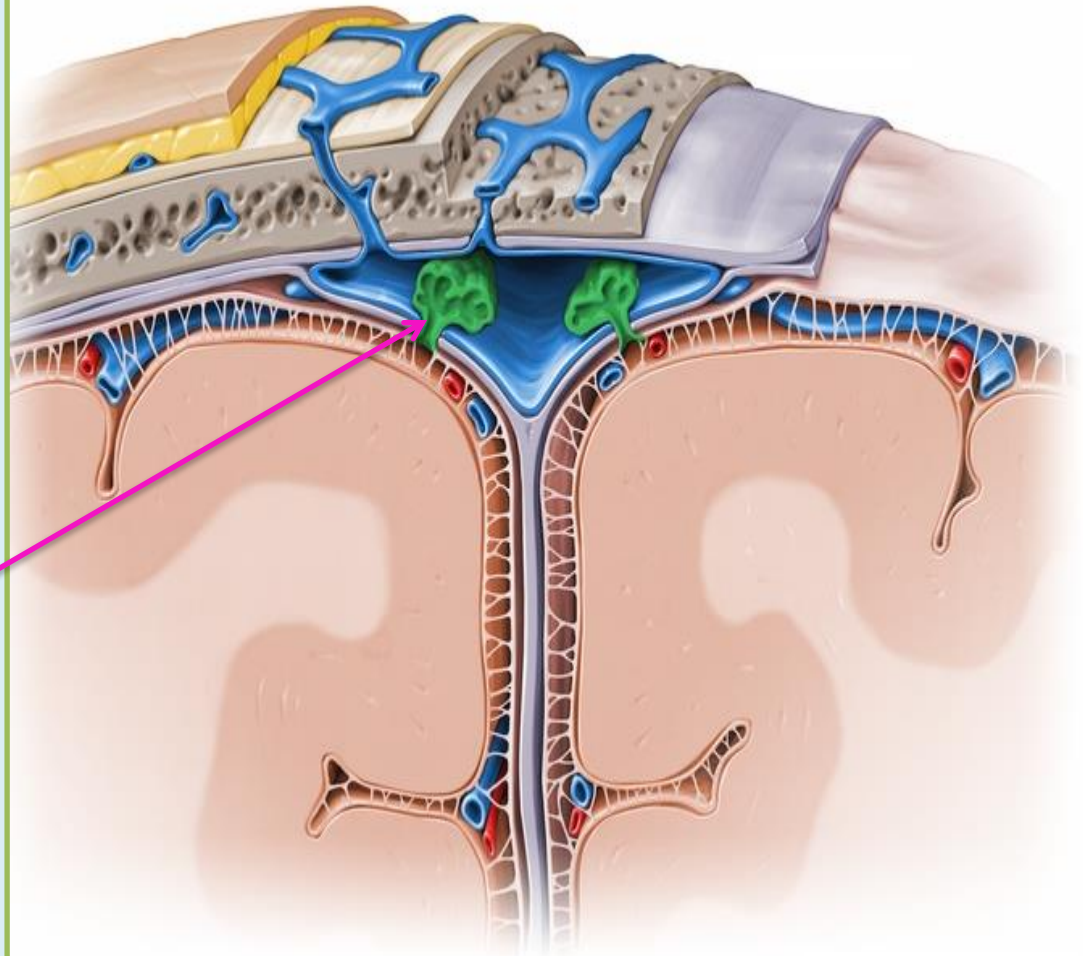
➤ The arachnoid mater is a delicate membrane covering the brain and lying between **THE PIA MATER INTERNALLY** and **THE DURA MATER EXTERNALLY**

It is separated from the dura by a potential space **THE SUBDURAL SPACE** and from the pia by **THE SUBARACHNOID SPACE** which is filled with **cerebrospinal fluid**

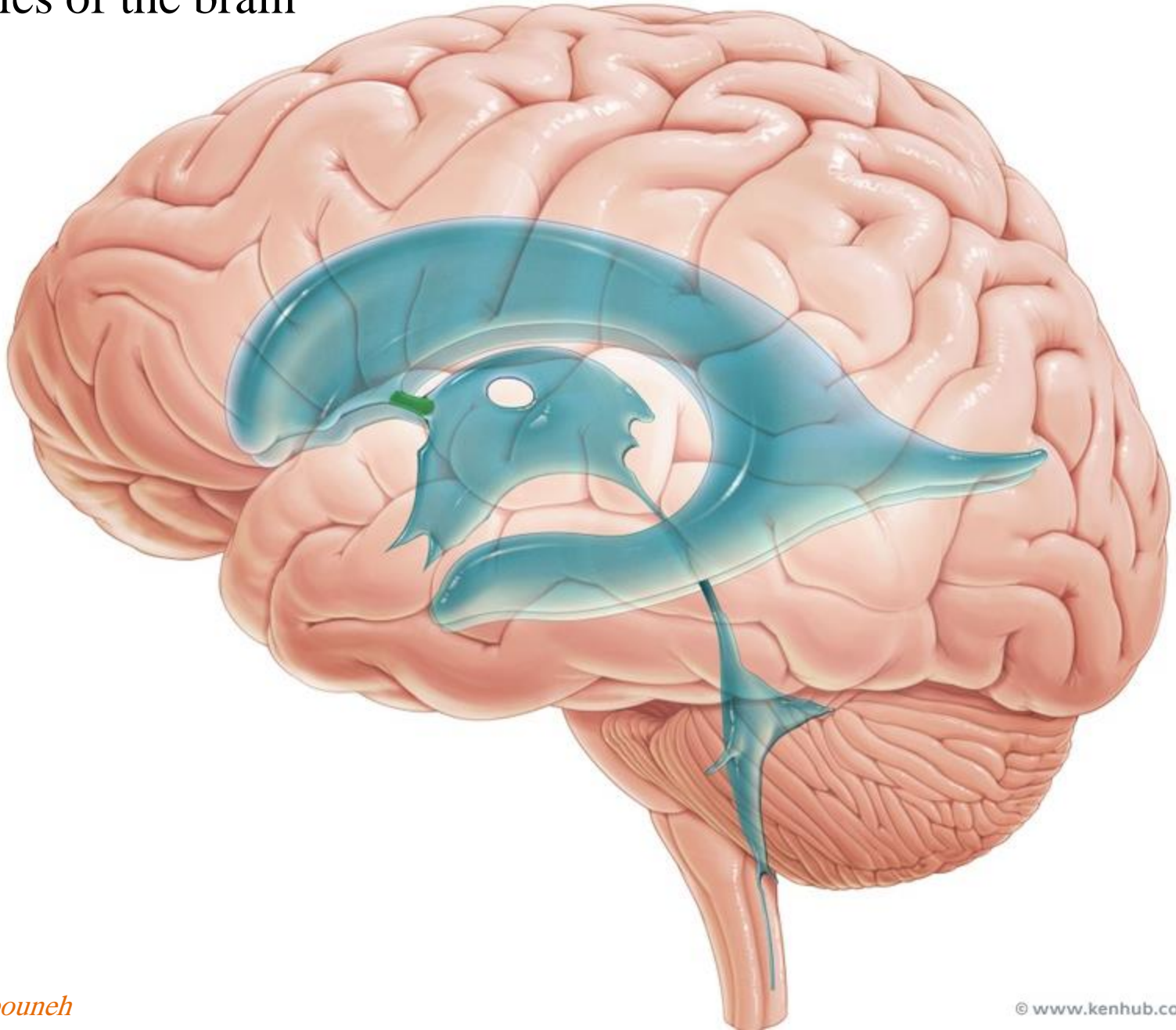


# Arachnoid Mater of the Brain

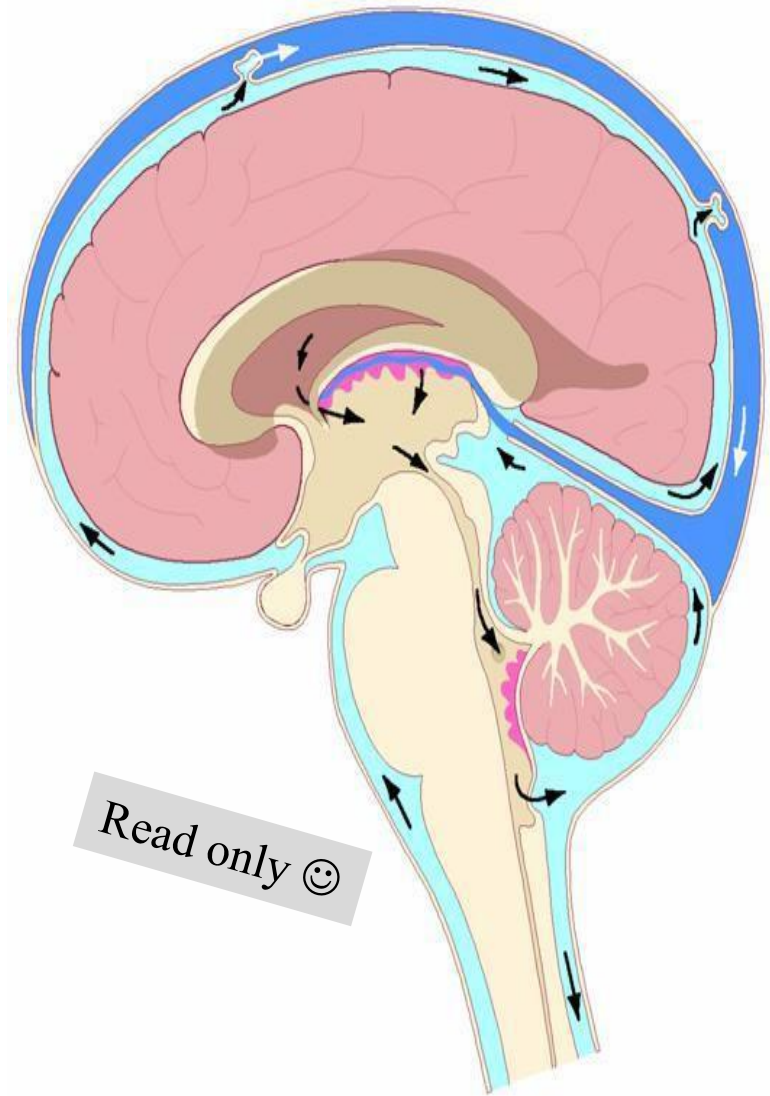
- In certain areas the arachnoid projects into the venous sinuses to form arachnoid villi.
- The arachnoid villi are most numerous along the superior sagittal sinus
- Aggregations of arachnoid villi are referred to as **arachnoid granulations**
- Arachnoid villi serve as sites where the cerebrospinal fluid diffuses into the bloodstream



# Ventricles of the brain

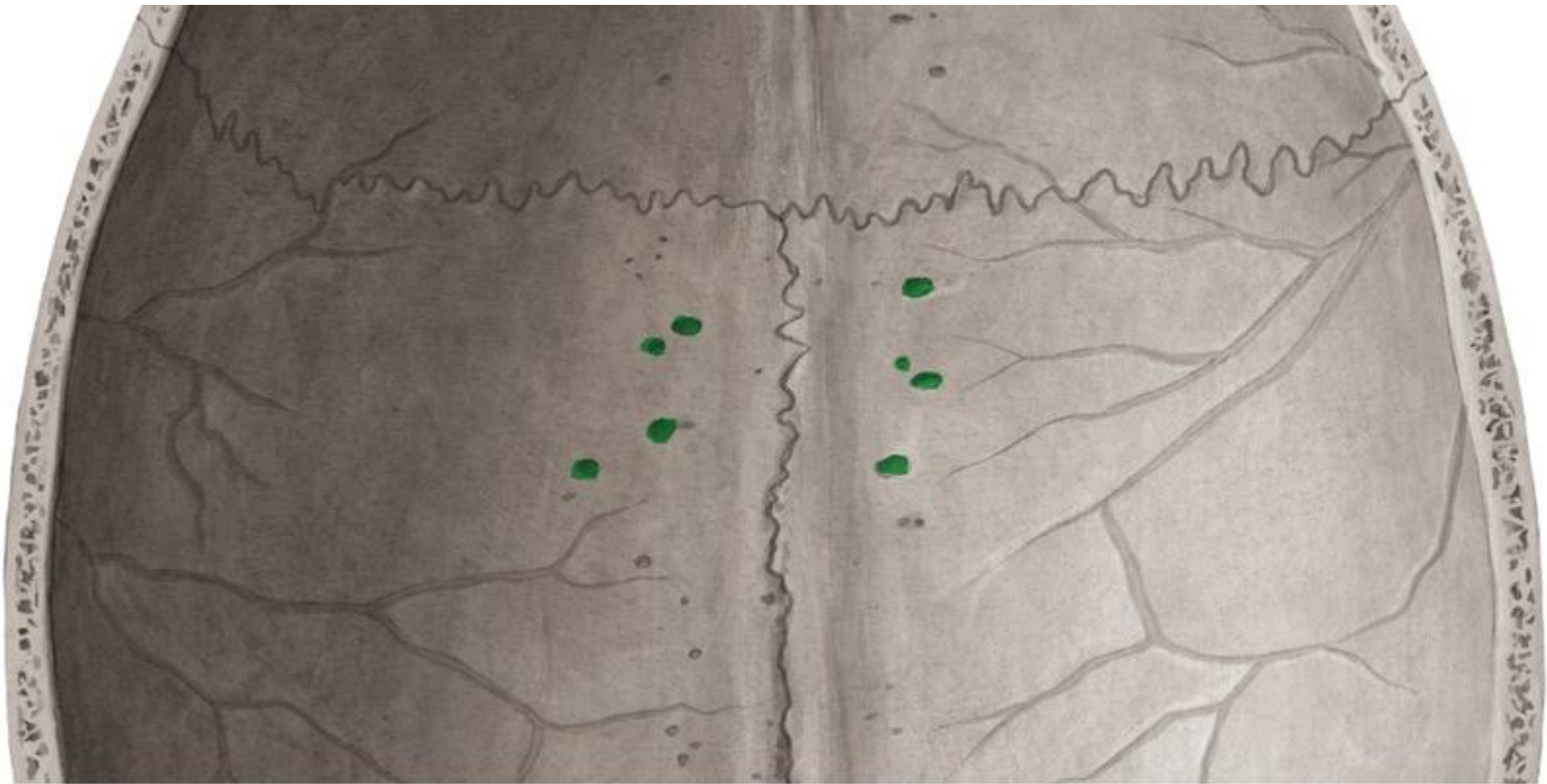


- The cerebrospinal fluid (CSF) is produced within the ventricles of the brain.
- It escapes from the ventricular system of the brain through the three foramina and so enters the subarachnoid space
- It now circulates both upward over the surfaces of the cerebral hemispheres and downward around the spinal cord
- Eventually, the fluid enters the bloodstream by passing into the arachnoid villi and diffusing through their walls

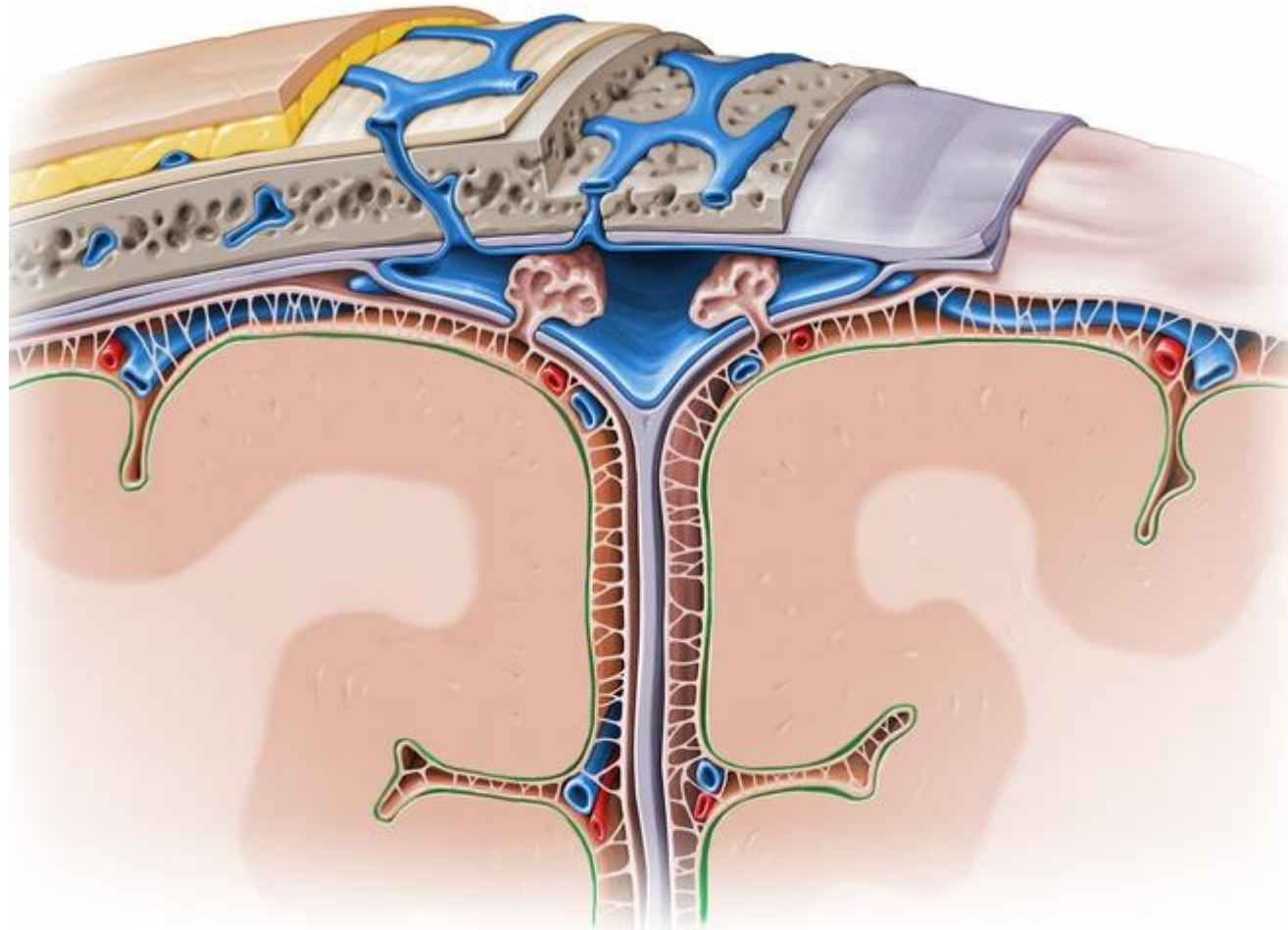


The spinal subarachnoid space extends down as far as the second sacral vertebra

On each side of the superior sagittal groove are  
several small pits, called  
**GRANULAR PITS (Foveolae)**  
**GRANULAR PITS** are indentation of the  
skull formed by arachnoid granulations



# Pia Mater



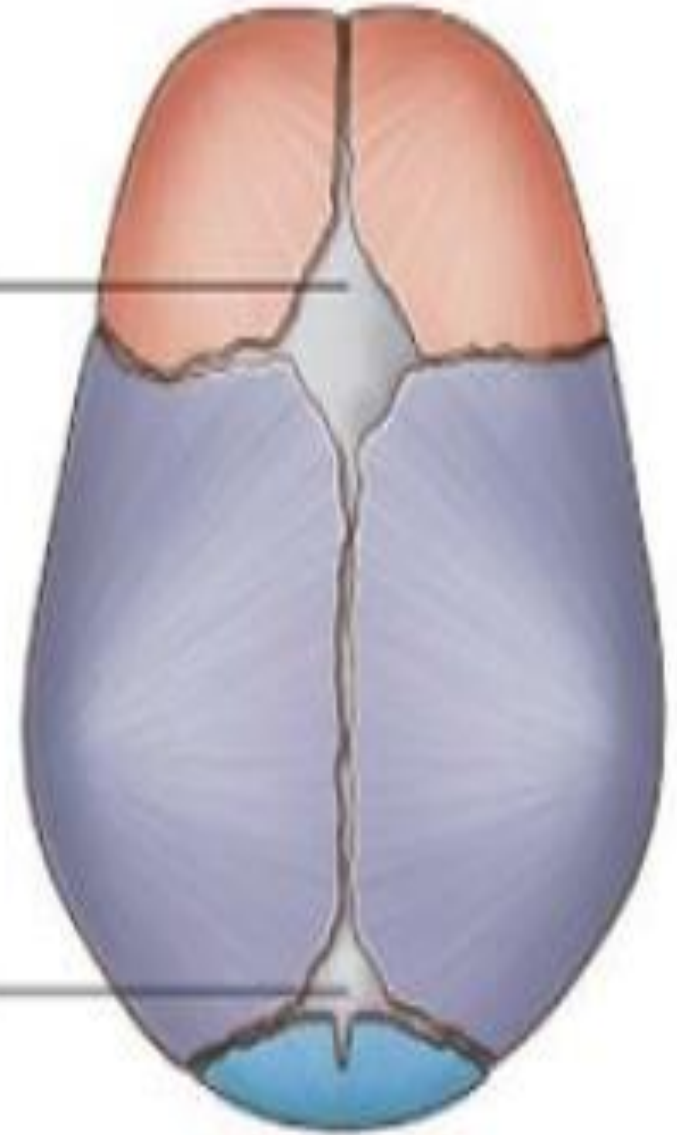


# Neonatal Skull

- **Fontanelles:** unossified membranous intervals
- **Anterior fontanelle:** (diamond) closed by 18 months
- **Posterior fontanelle:** (triangular) closed by 12 months
- Important clinically, *why?*

Anterior fontanelle

Posterior fontanelle



# Clinical Features of the Neonatal Skull

## FONTANELLES

Palpation of the fontanelles enables the physician to determine

1-The progress of growth in the surrounding bones

2-the degree of hydration of the baby

*For example*

if the fontanelles are depressed below the surface

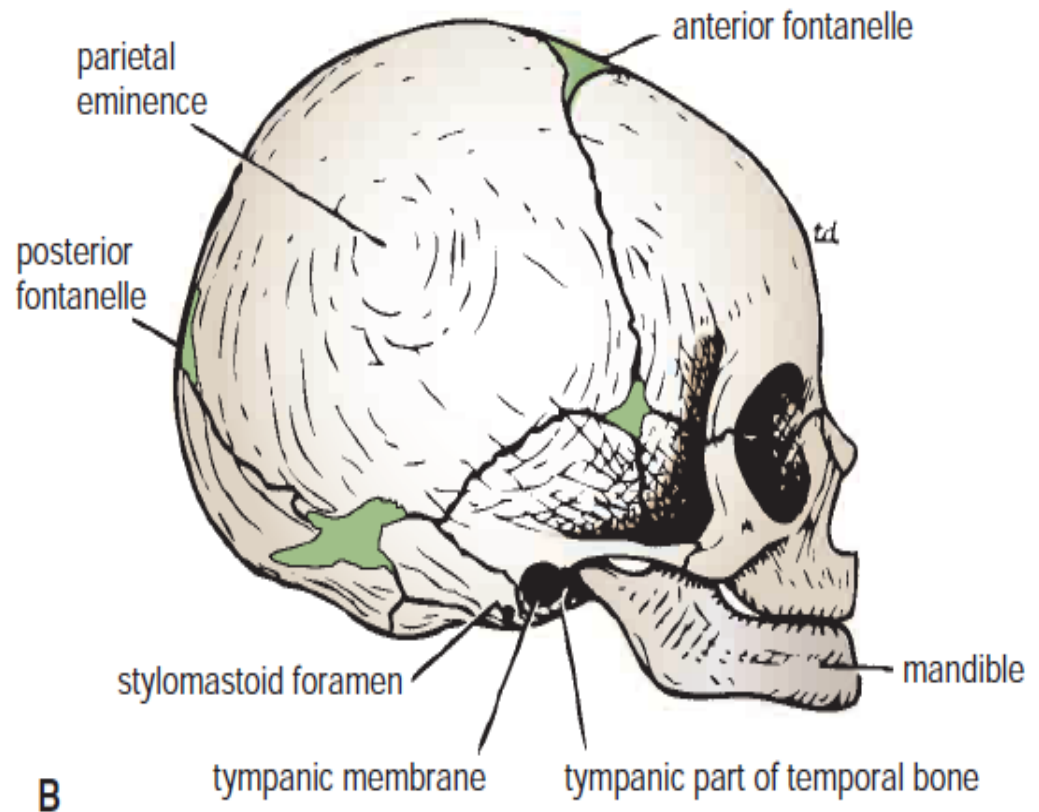


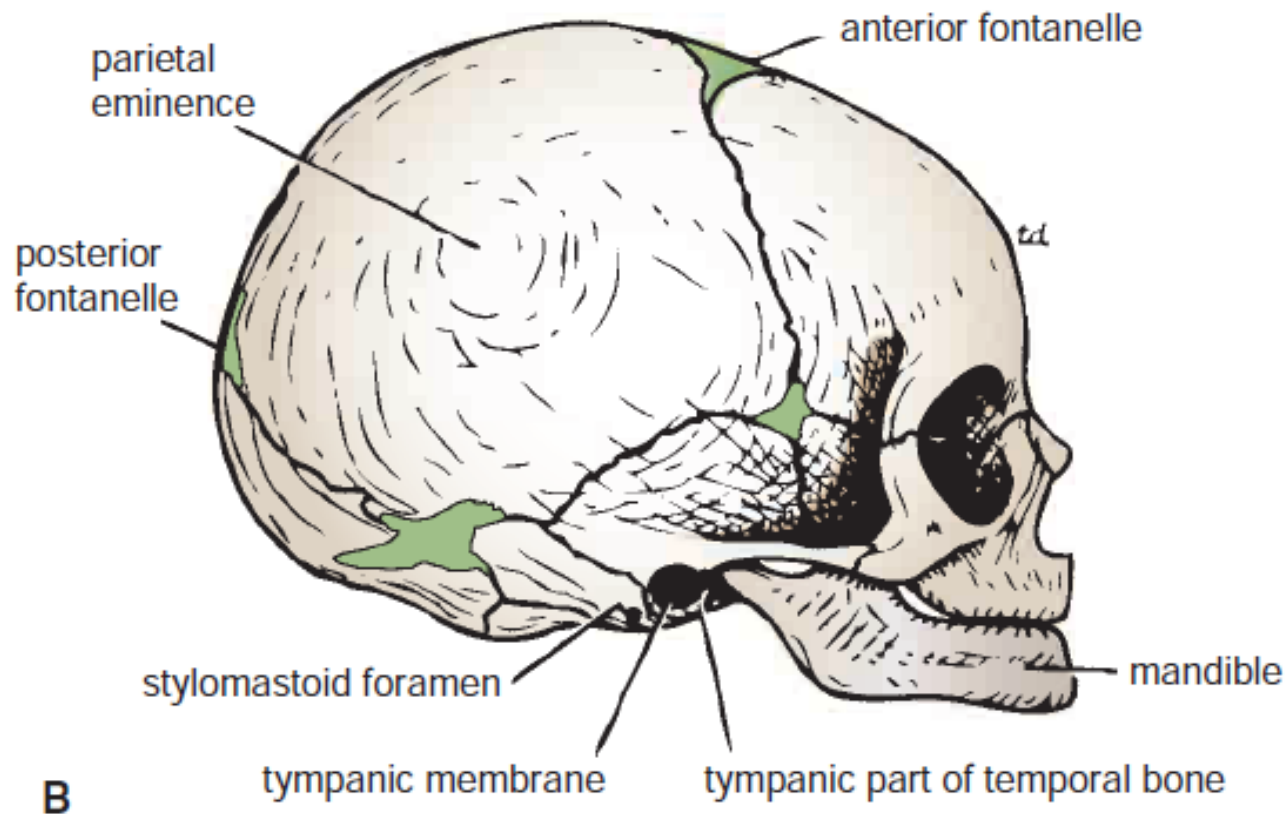
**THE BABY IS DEHYDRATED**

A bulging fontanelle indicates



**RAISED INTRACRANIAL PRESSURE**

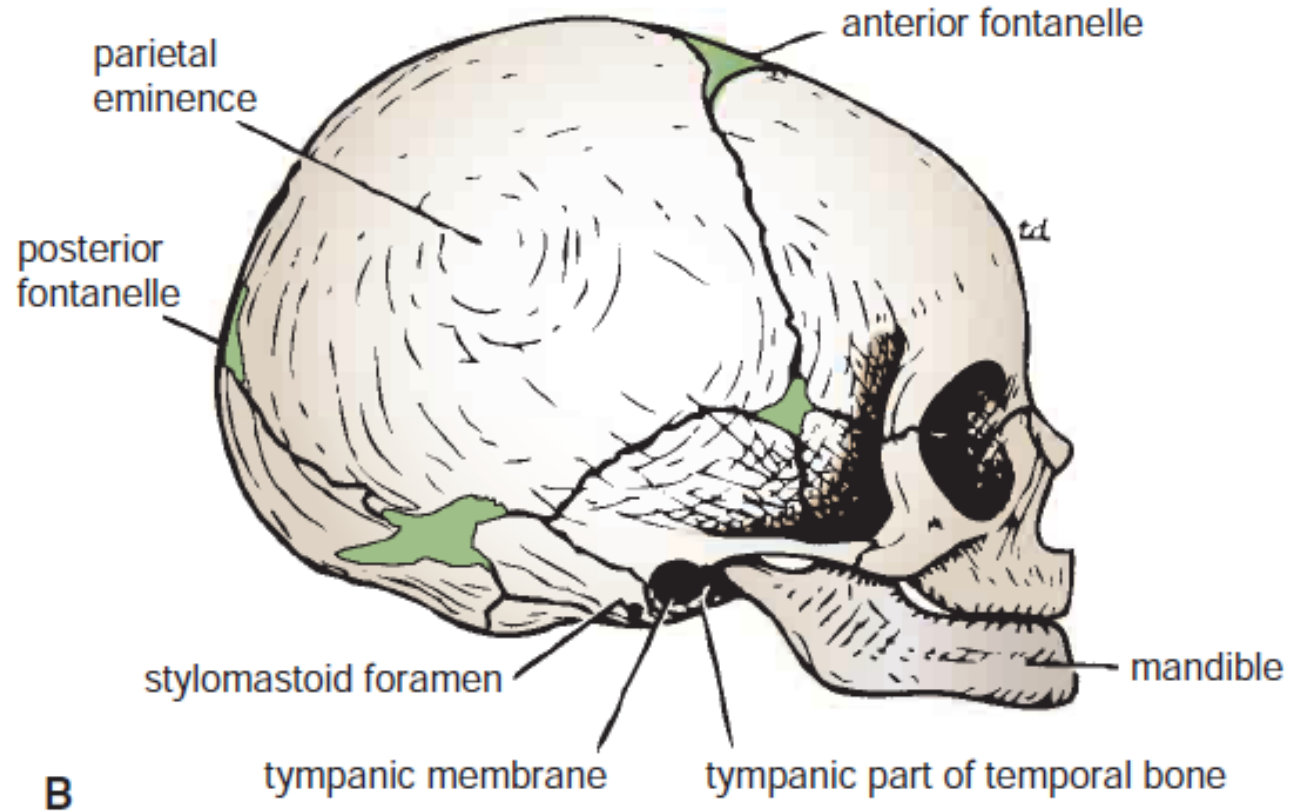




Clinical note: Samples of cerebrospinal fluid can be obtained by passing a long needle obliquely through the anterior fontanelle into the subarachnoid space

# Neonatal Skull

- Large cranium relative to the face
- No mastoid process
- Angle of the mandible is obtuse

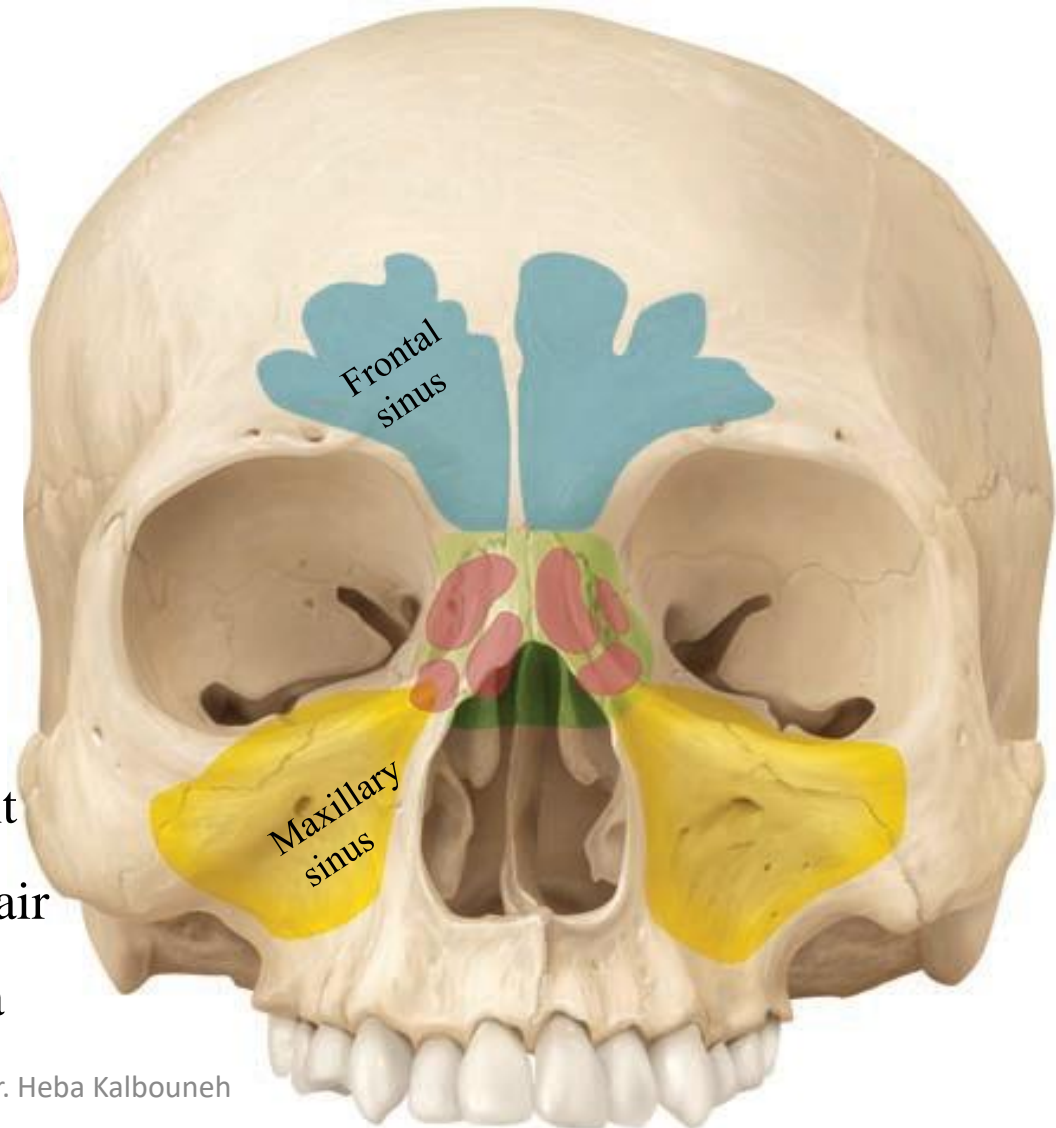
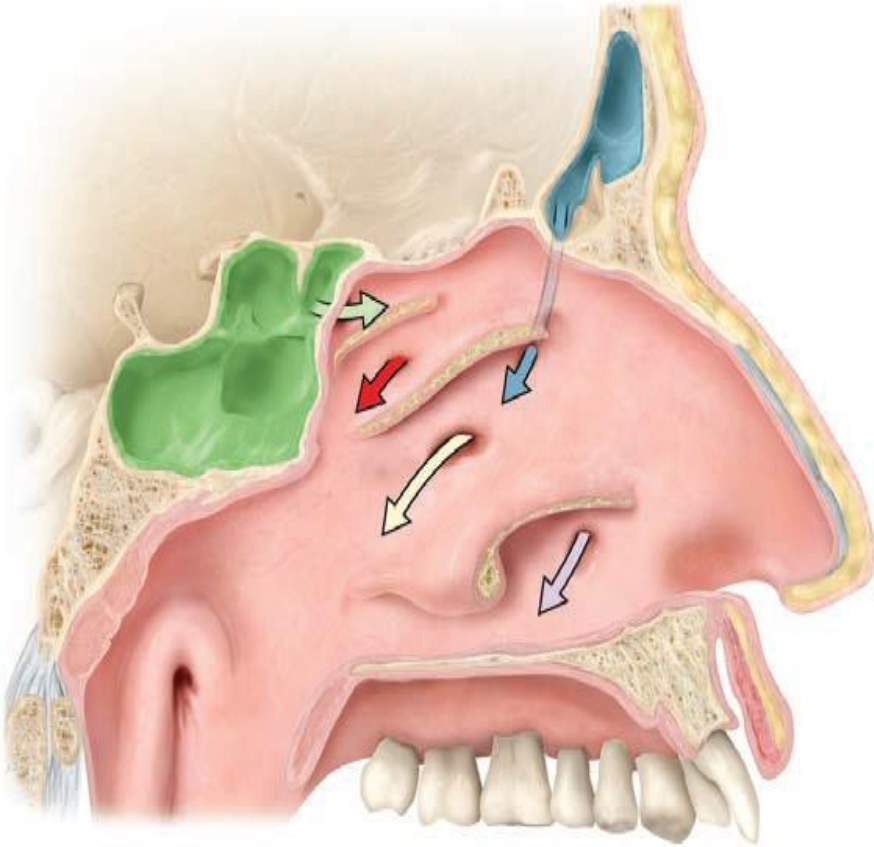


Clinical note:

Facial nerve can be damaged by forceps in a difficult delivery. **Why?**

In the newborn infant, the mastoid process is not developed, and the facial nerve, as it emerges from the stylomastoid foramen, is close to the surface. Thus, it can be damaged by forceps in a difficult delivery.

# The Paranasal Sinuses



## Functions:

1. Resonators of the voice
2. They also reduce the skull weight
3. Help warm and moisten inhaled air
4. Act as shock absorbers in trauma

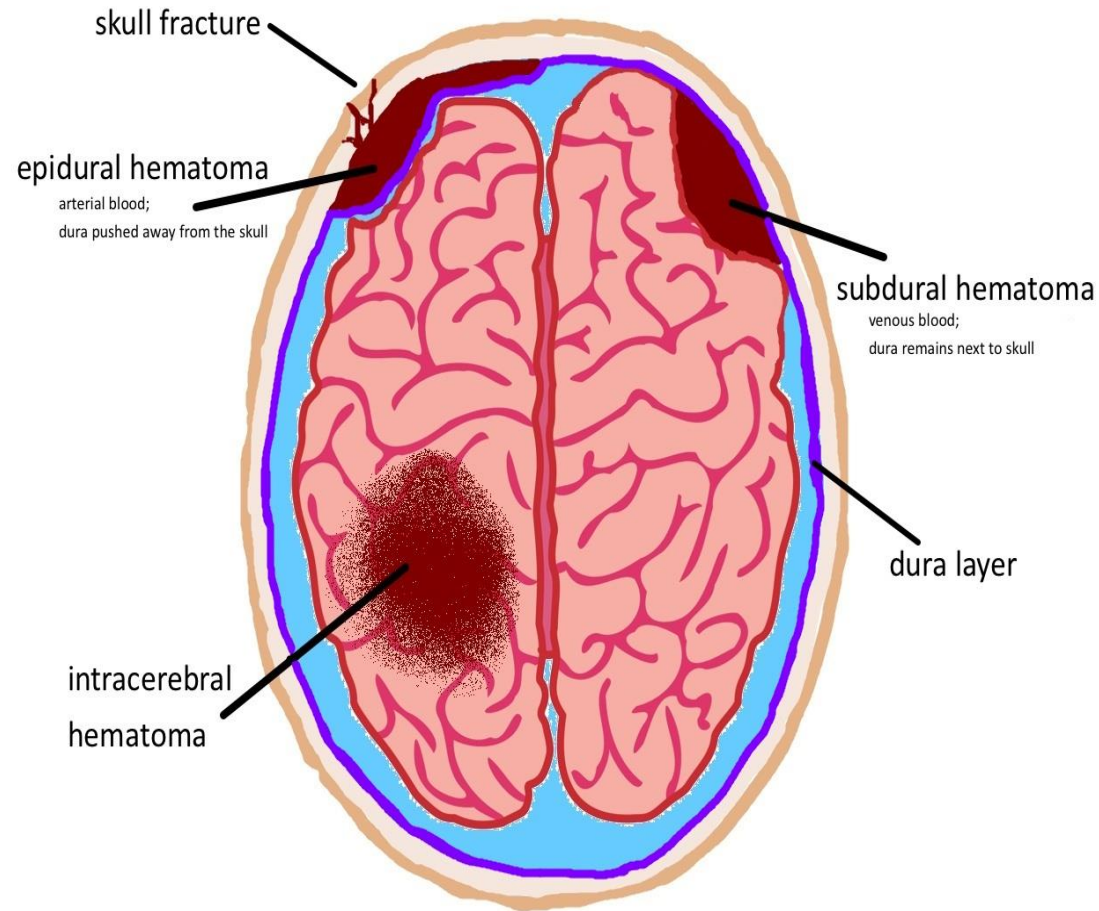
# Intracranial Hemorrhage

Epidural hemorrhage

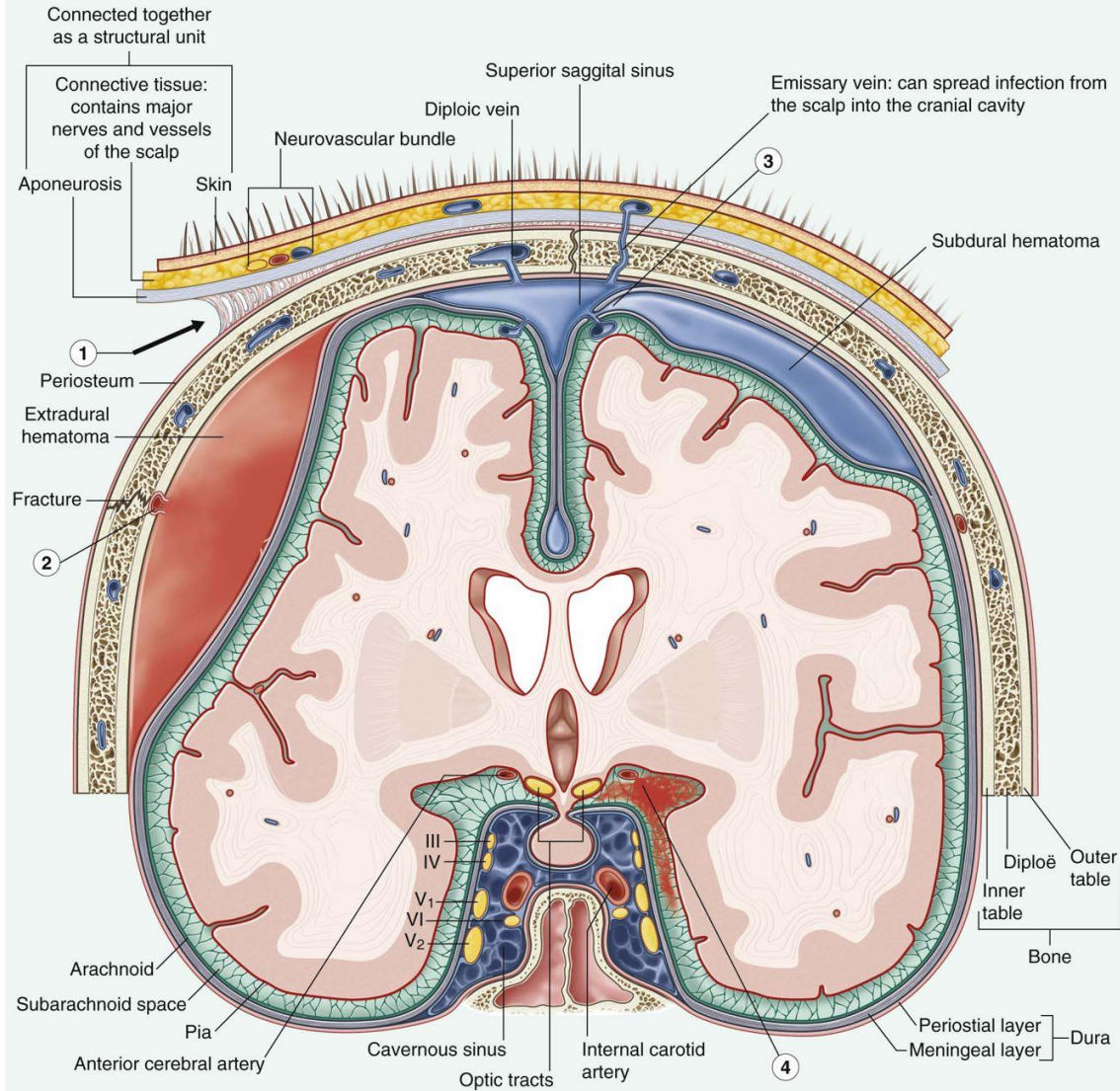
Subdural hemorrhage

Subarachnoid hemorrhage

Intracerebral hemorrhage



Read only



1 Loose connective tissue (danger area)

- In scalping injuries, this is the layer in which separation occurs.
- Infection can easily spread in this layer.
- Blunt trauma can result in hemorrhage in this layer (blood can spread forward into the face, resulting in "black eyes").

2 Rupture of the middle meningeal artery (branches) by fracture of the inner table of bone results in extradural hematoma. Under pressure, the blood progressively separates dura from the bone.

3 Tear to cerebral vein where it crosses dura to enter cranial venous sinus can result in subdural hematoma. The tear separates a thin layer of meningeal dura from that which remains attached to the periosteal layer. As a result, the hematoma is covered by an inner limiting membrane derived from part of the meningeal dura.

4 Aneurysm

- Ruptured aneurysms of vessels of the cerebral arterial circle hemorrhage directly into the subarachnoid space and CSF.

## Extradural hemorrhage/ epidural

The most common artery to be damaged is anterior division of **middle meningeal artery**

Results from a blow to the side of the head, resulting in fracture of the skull in the region of **Pterion**

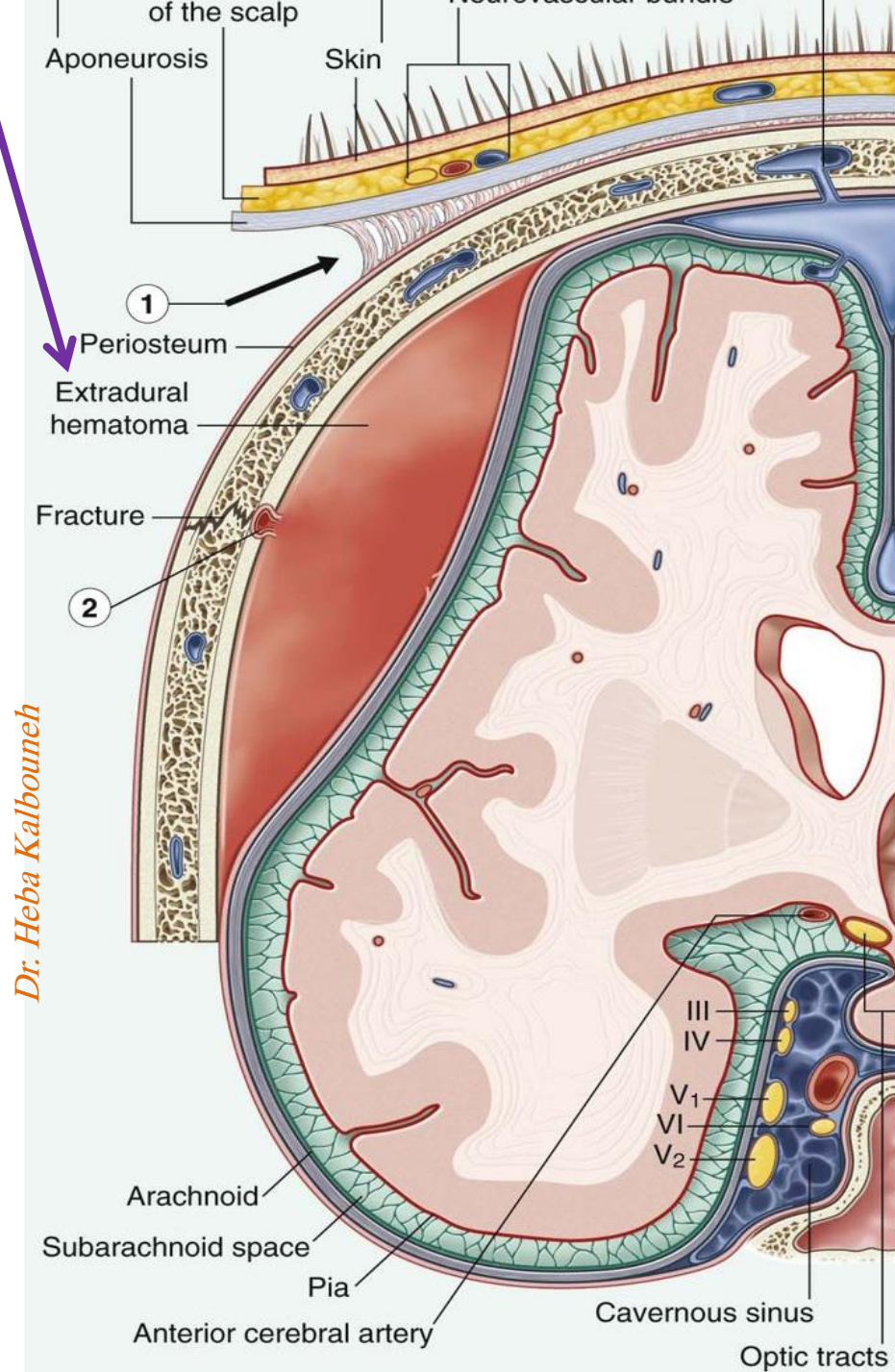
Trauma (blow on skull, car accidents, falls....)

Bleeding occurs and strips up the dura from the skull bone

As the hematoma expands, it strips the dura from the inside of the skull, causing an intense **headache**

The intracranial pressure rises, causing the brain to shift, to be crushed against the skull, or **herniate.**

↓ ↓  
can quickly compress the brainstem, causing **unconsciousness**





The enlarging blood clot exerts local pressure on the underlying motor area

↓ ↓ ↓  
*weakness of the extremities on the opposite side from the lesion*

### **Hallmark of epidural hematoma**

*Often there is loss of consciousness following a head injury, a brief regaining of consciousness (appear completely normal), and then loss of consciousness again*

#### **Lucid interval**

- Lucid interval is a temporary improvement in a patient's condition after a traumatic brain injury, after which the condition deteriorates
- It occurs after the patient is knocked out by the initial concussive force of the trauma, then lapses into unconsciousness again after recovery when bleeding causes the hematoma to expand past the point at which the body can no longer compensate

A lucid interval is especially indicative of an epidural hematoma.

**An estimated 20 to 50%** of patients with epidural hematoma experience such a lucid interval.

It can last minutes or hours

Read only

lucid interval (no symptoms) for a few hours followed by death  
**(“talk and die syndrome”)**

To stop the hemorrhage, the torn artery or vein must be ligated or plugged. The burr hole through the skull wall should be placed about 1 to 1.5 in. (2.5 to 4 cm) above the midpoint of the zygomatic arch.

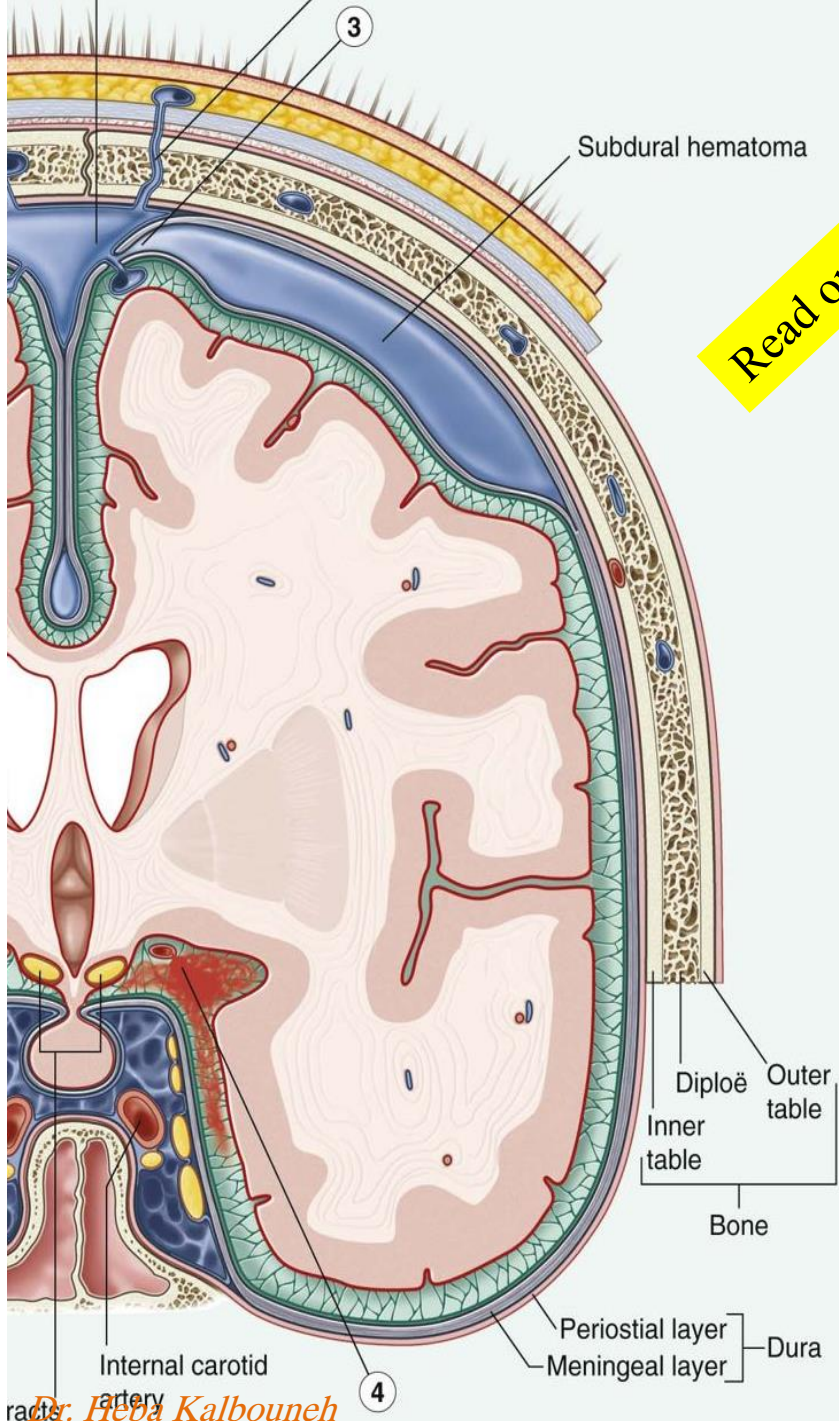
# Subdural hemorrhage

Results from tearing of the cerebral veins at their point of entrance into the superior sagittal sinus (**bridging veins**)

The cause is usually excessive anteroposterior displacement of the brain within the skull.

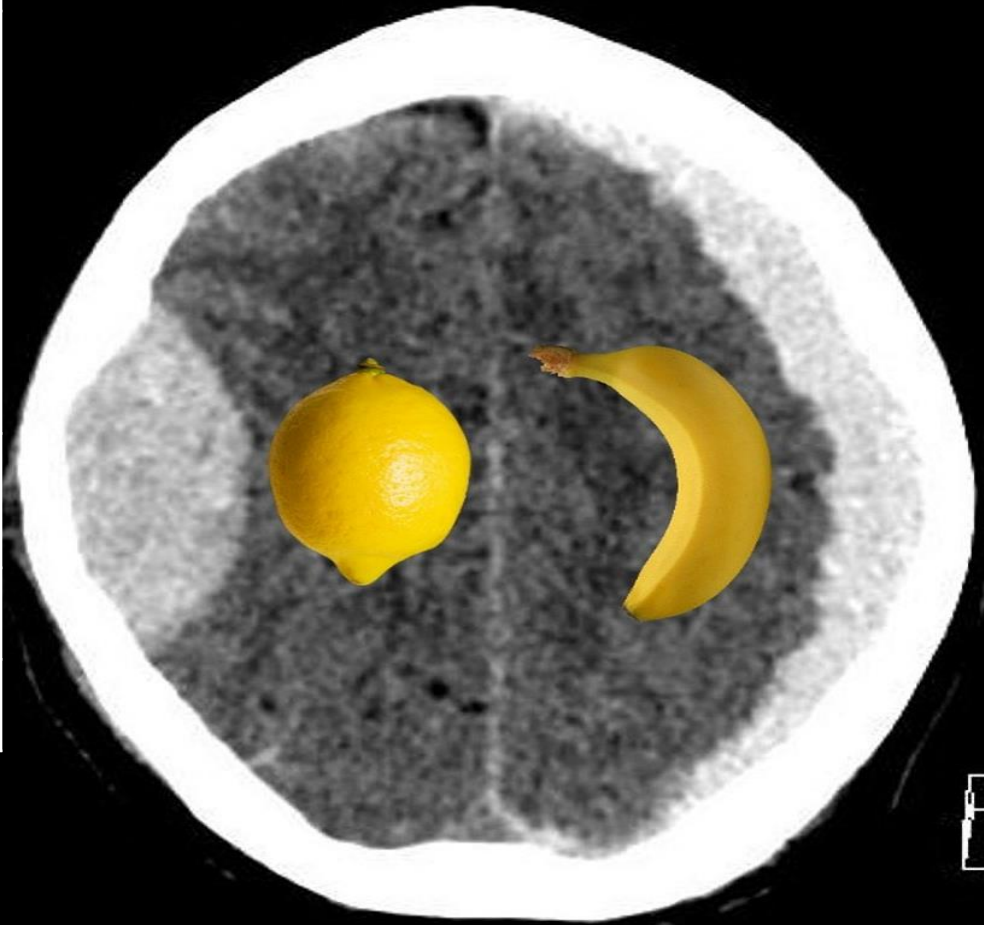
**A violent shaking** of the head (e.g., child abuse or car accident) and commonly occurs in alcoholics and elderly.

Blood accumulates in the potential space between the dura and the arachnoid



Epidural	Subdural
Between the skull and dura matter	Between dura and arachnoid matter
Rupture to meningeal vessels ( <b>middle meningeal A</b> )	Rupture to cerebral veins ( <b>bridging veins</b> ) while approaching the venous sinus (superior cerebral veins)
Lense shaped (Biconvex)	Crescent shaped
Well localized	Poorly localized
Mostly arterial	Mostly venous

Note: Epidural hematomas usually appear convex in shape because their expansion stops at the skull's sutures, where the dura mater is tightly attached to the skull



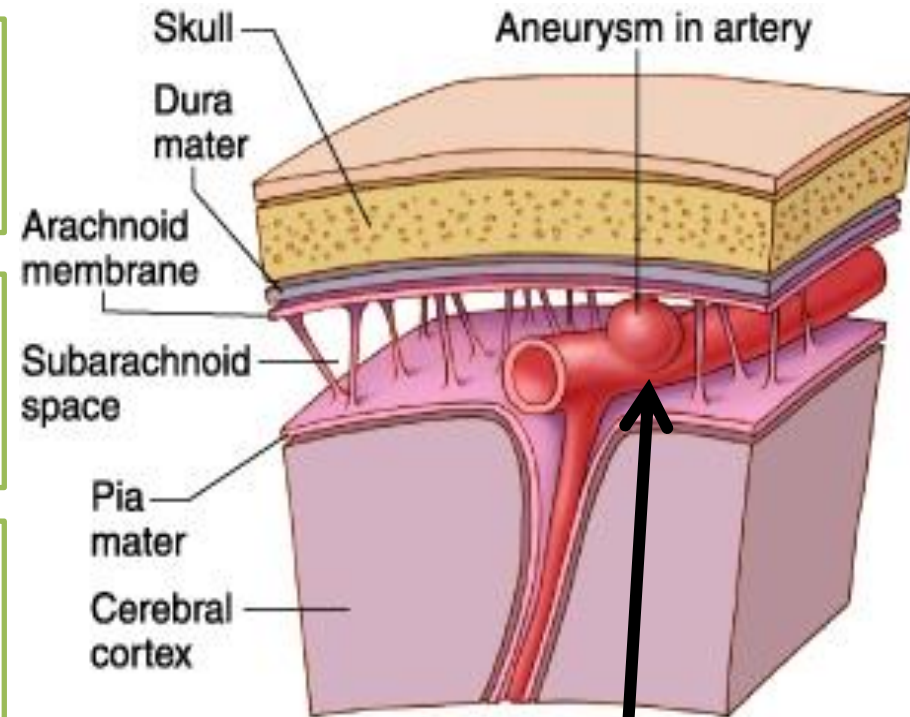
Read only

# Subarachnoid hemorrhage

Extravasation of blood into the subarachnoid space between the pia and arachnoid

Occurs in the setting of a ruptured cerebral aneurysm or arteriovenous malformation

The diagnosis is established by withdrawing heavily blood-stained cerebrospinal fluid through a lumbar puncture (spinal tap).



Note: cerebral arteries, veins and cranial nerves pass through the subarachnoid space

# Cerebral hemorrhage

Read only

- Caused by bleeding within the brain tissue itself
  - Most commonly caused by hypertension

