Skin Histology

Dr. Heba Kalbouneh
DDS, MSc, DMD/PhD
Professor of Anatomy, Histology and Embryology

Integumentary system

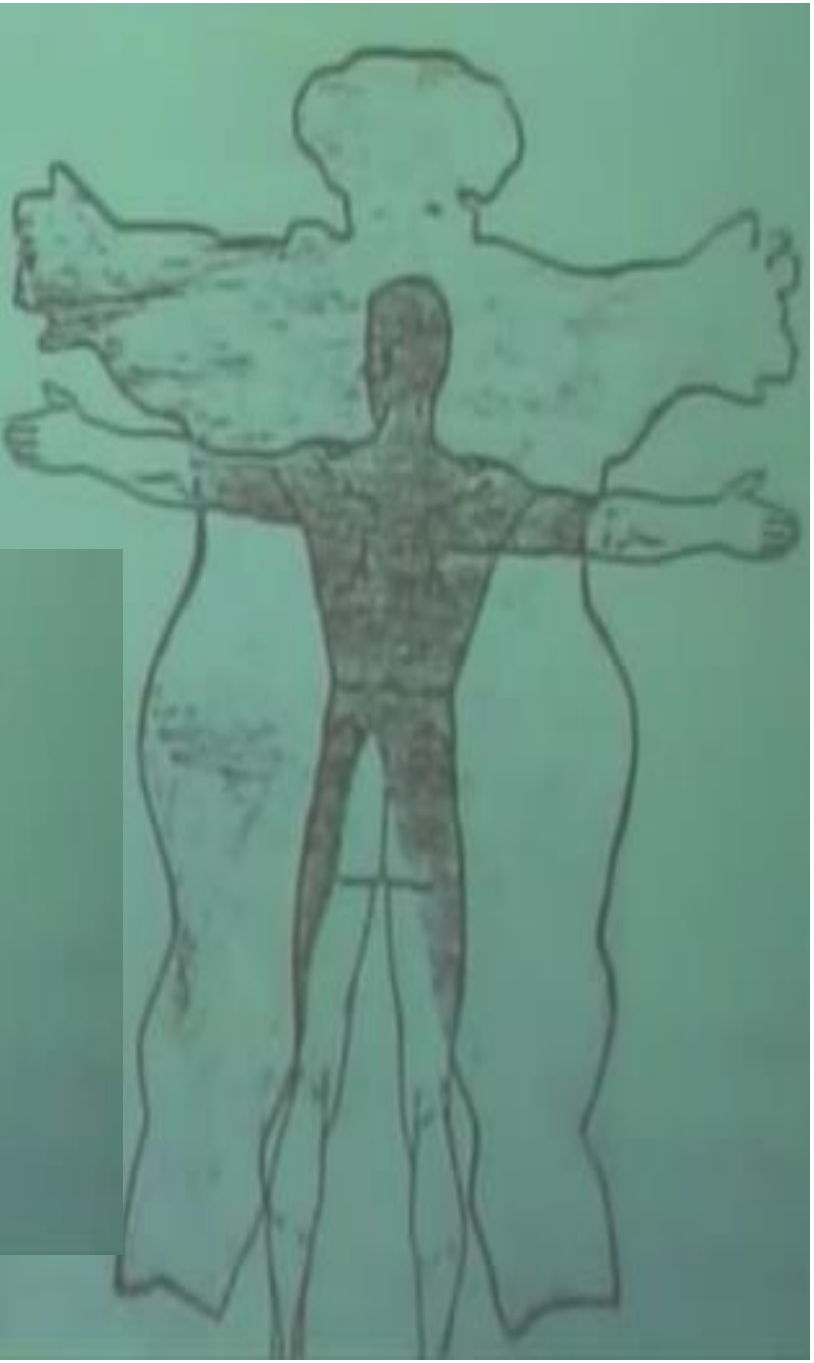

The skin is considered the largest organ of the body

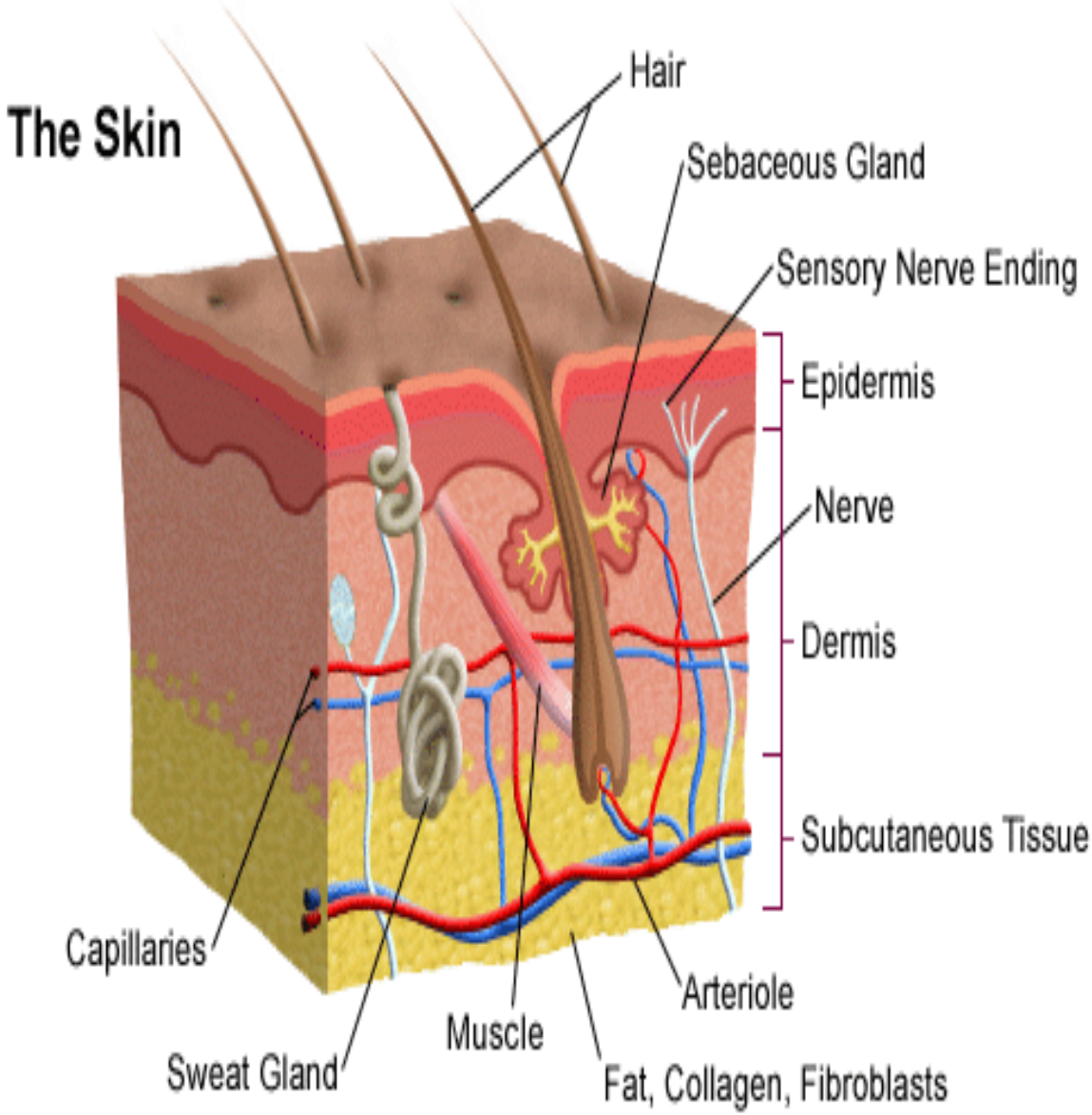

Dr. Heba Kalbouneh

Basic Skin Histology

The skin is composed of two layers: the outer epidermis and the deeper dermis
Rests on the hypodermis.

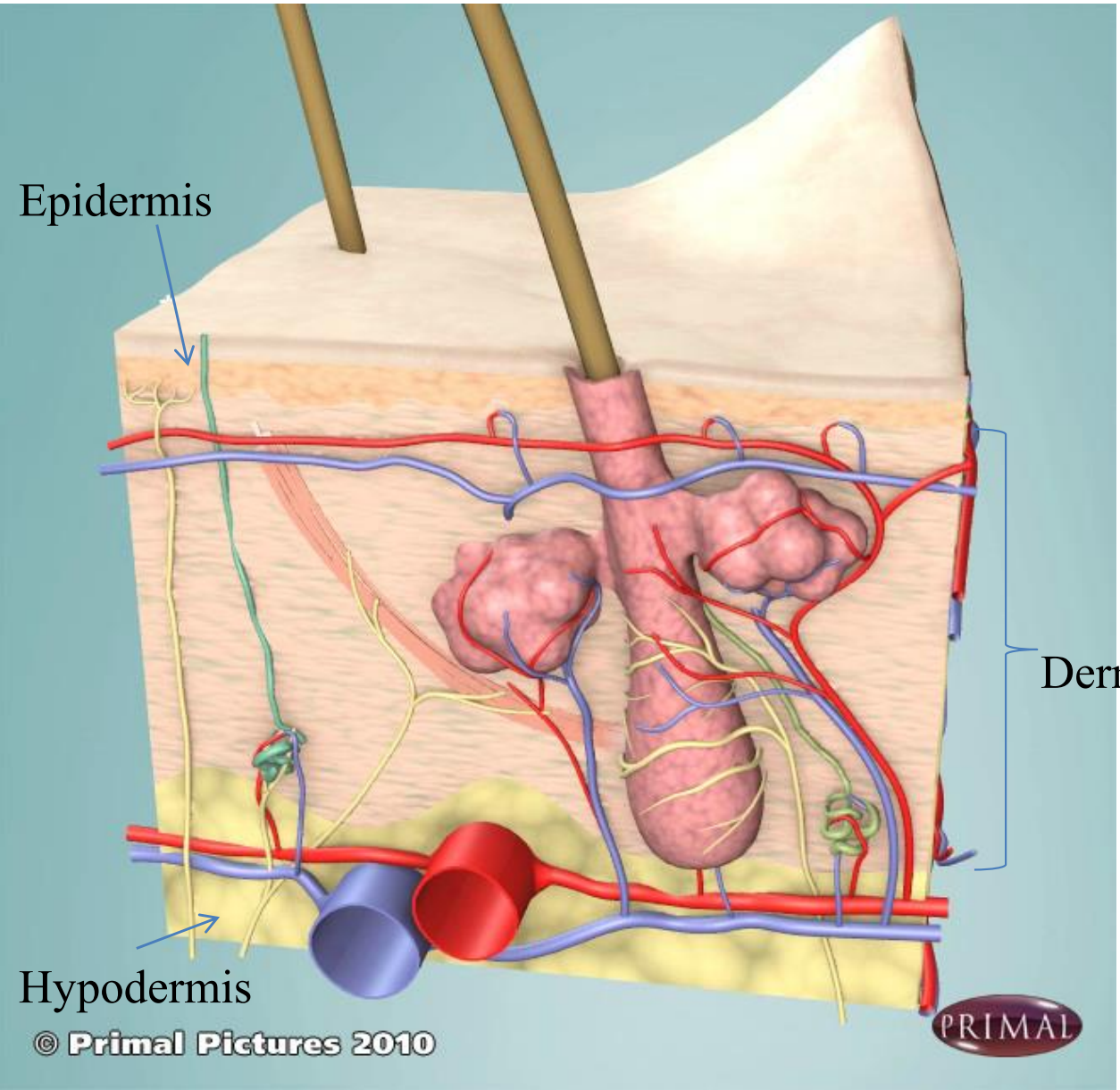

Skin is an important subject to know no matter what clinical field you want get into

Major Skin Functions
- Protection
- Sensory Perception
- Temperature Regulation
- Excretion
- Formation of Vitamin D

Dr. Heba Kalbouneh

Epidermis

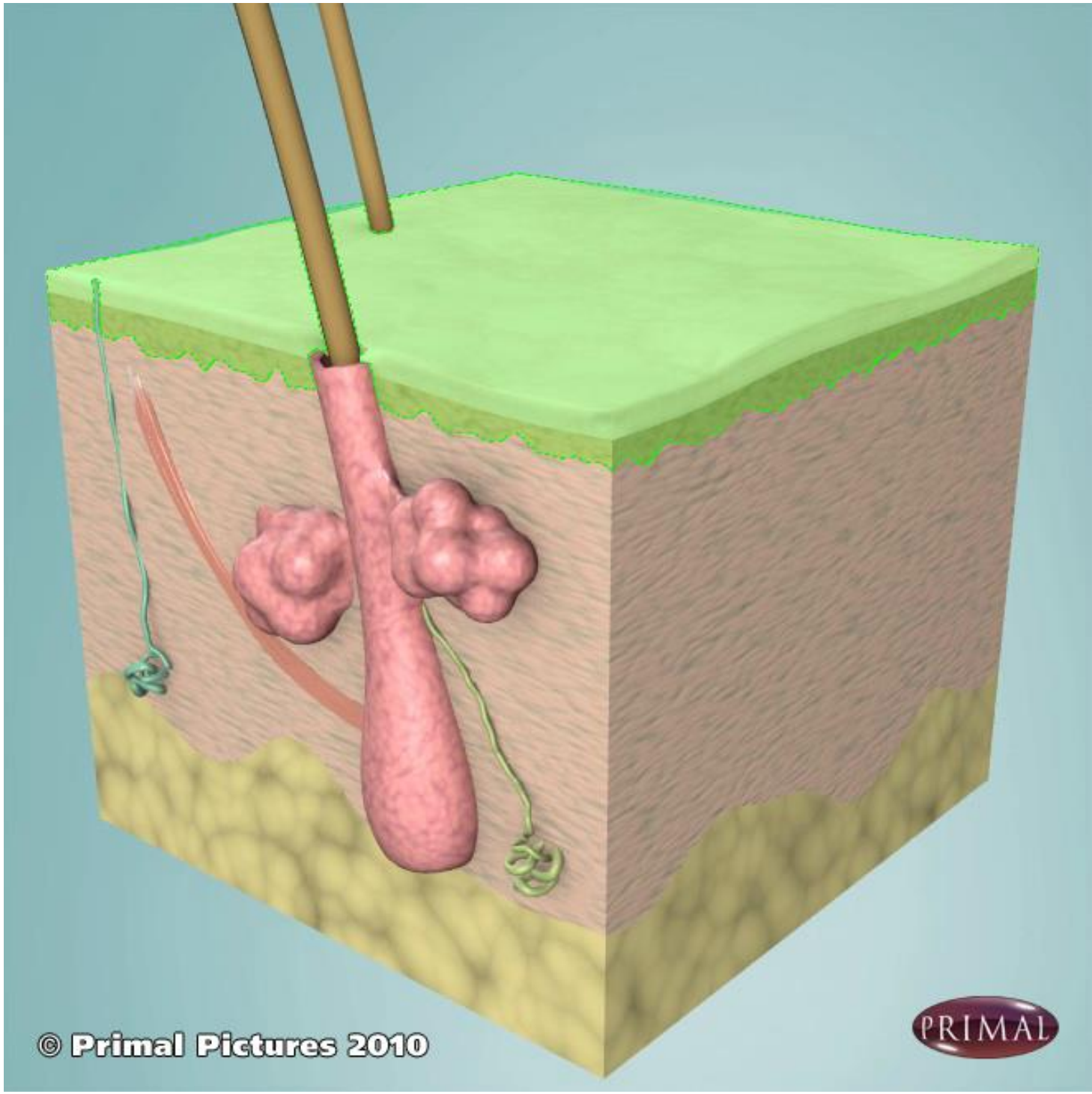

Dr. Heba Kalbouneh

Dermis

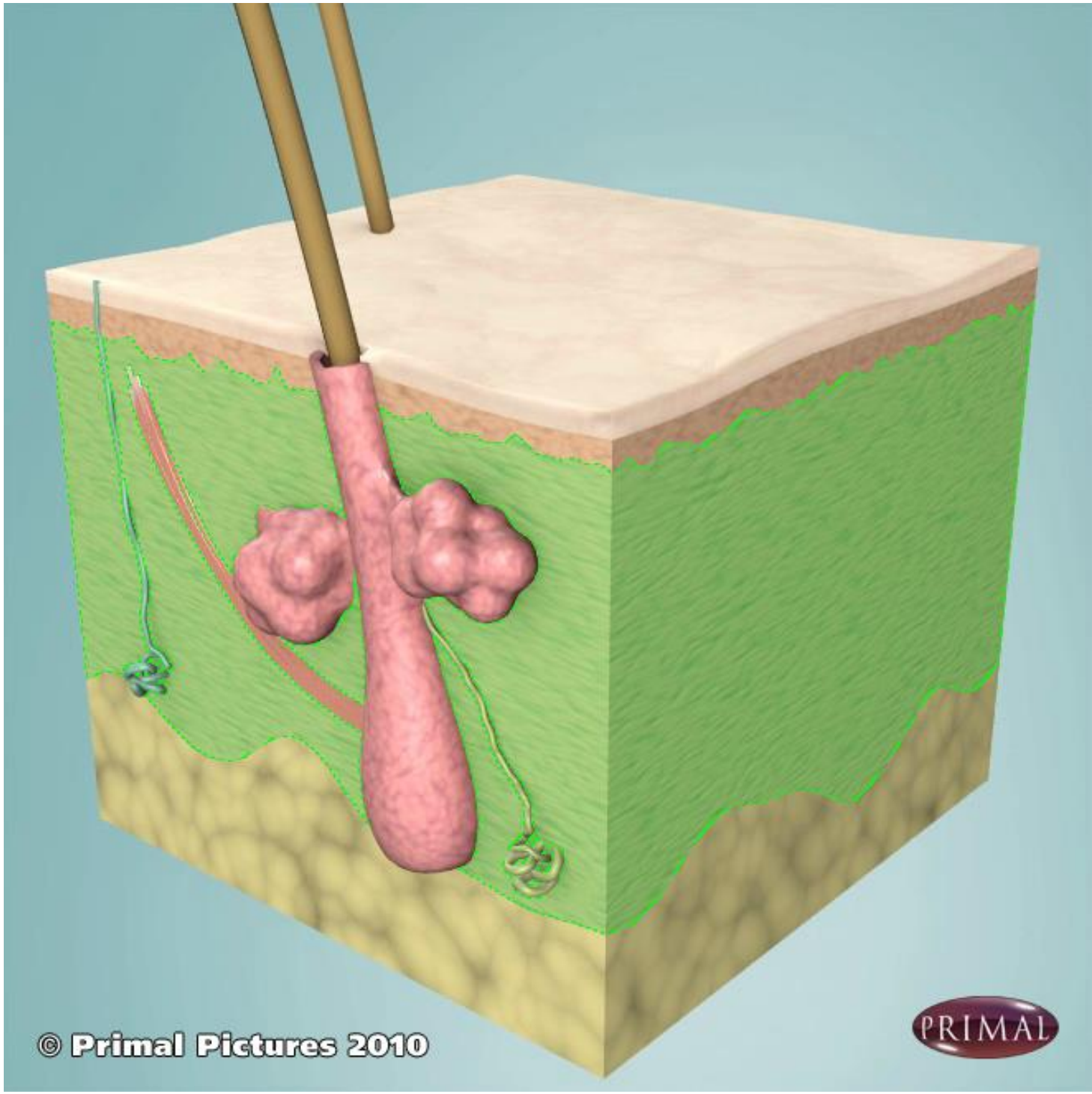

Dr. Heba Kalbouneh

Hypodermis
Superficial fascia
Subcutanous tissue
Subdermal fat

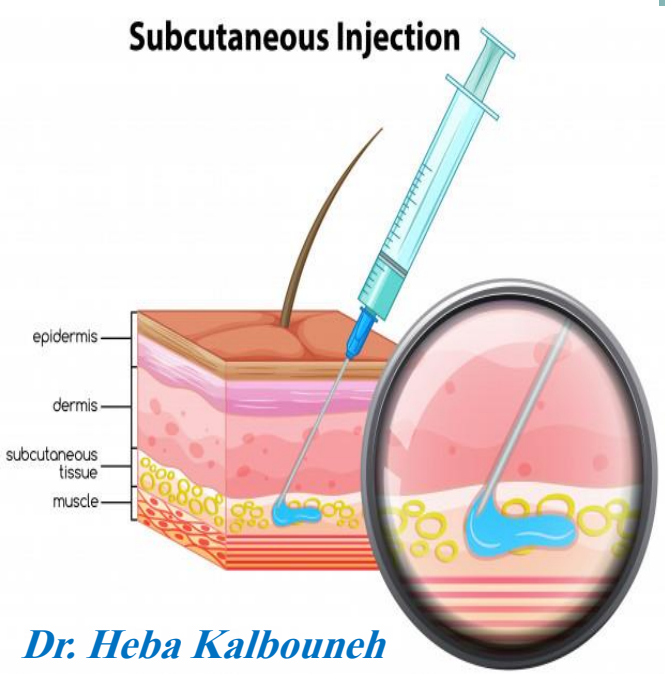

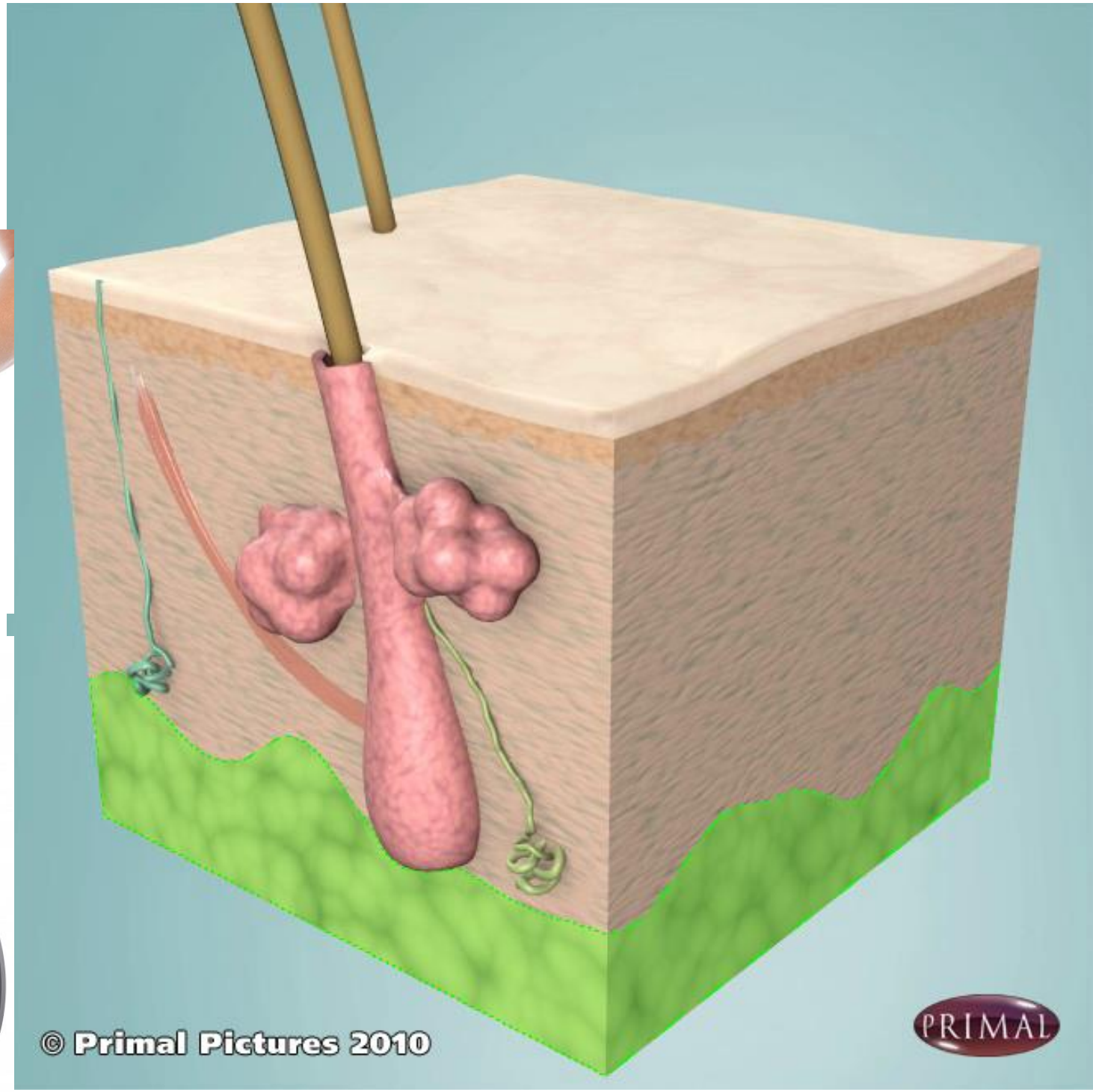

Dr. Heba Kalbouneh

The **dermal papillae** are nipple-like extensions of the dermis into the epidermis

The epidermis conforms to the contours of the underlying dermal papillae forming **epidermal ridges**

Note: the basement membrane follows the contour of the interdigitations between epidermis and dermis

Epidermal-dermal junction

Prevents the two layers of skin from separating

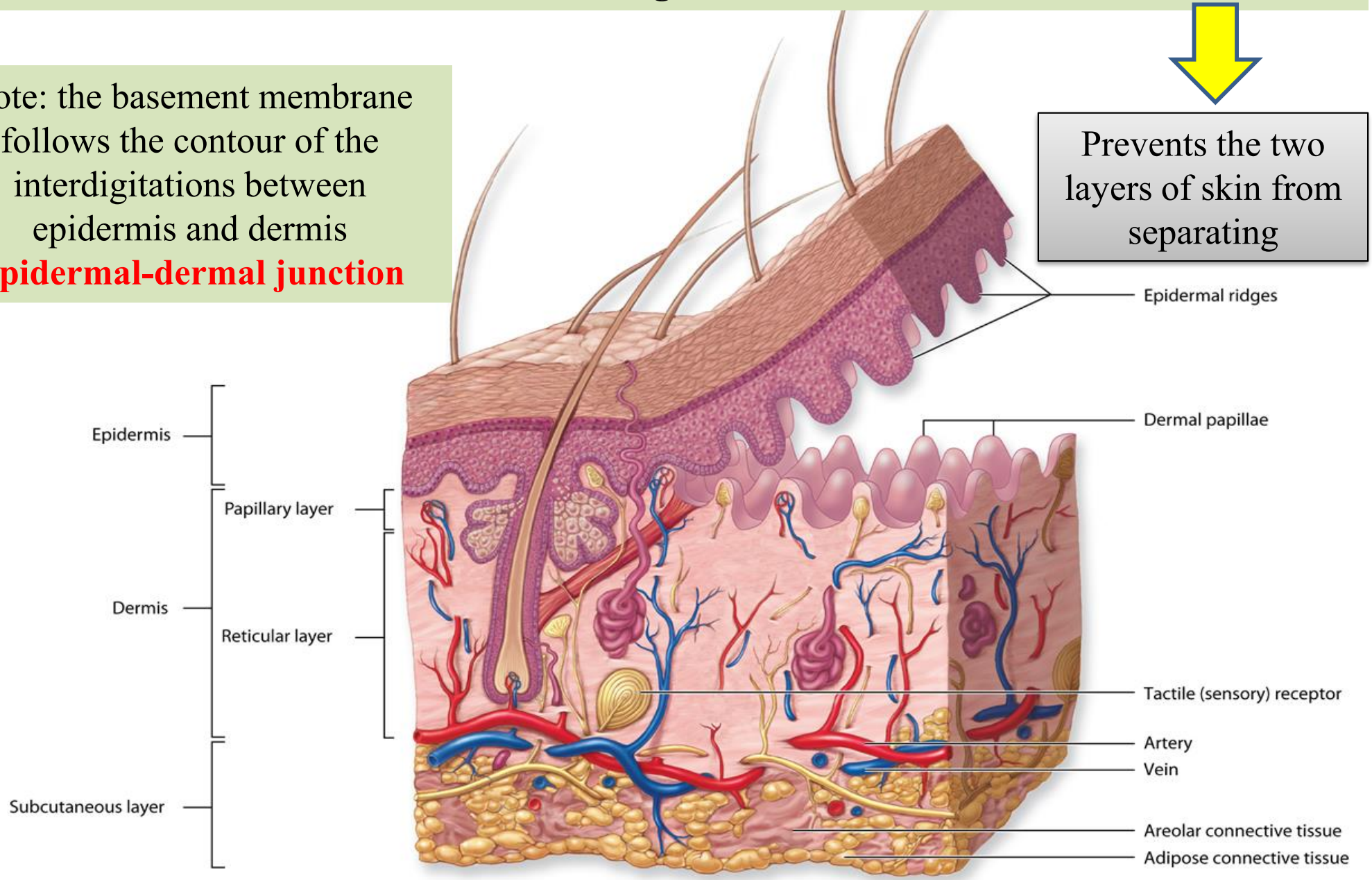

Dr. Heba Kalbouneh

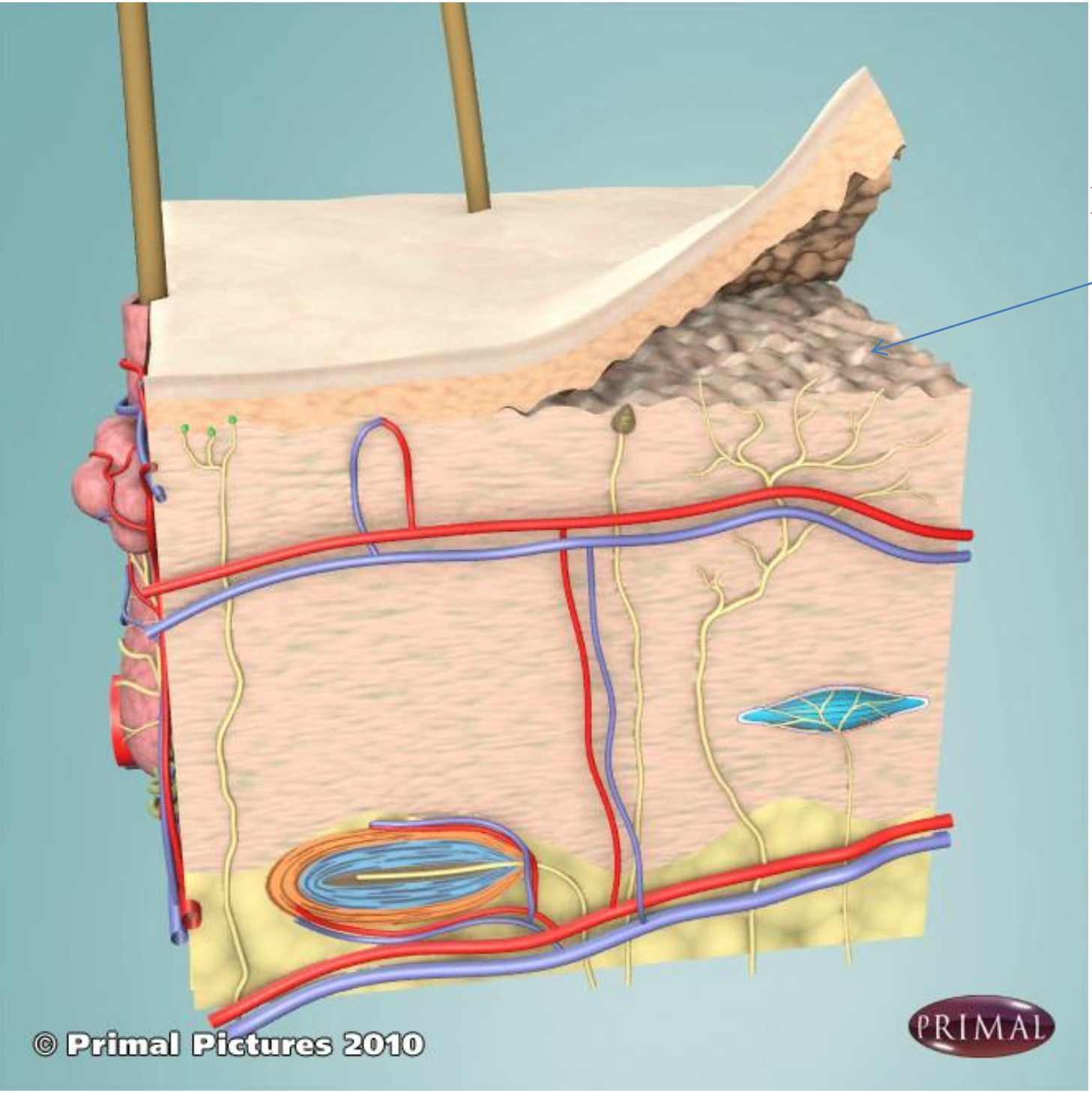

Epidermal-dermal junction

More prominent in palms and soles

Dr. Heba Kalbouneh

These interdigitations form distinctive patterns unique for each individual (fingerprints and footprints)

Blisters

These interdigitations are called **friction ridges**
For grasping with our hands
And for walking barefoot

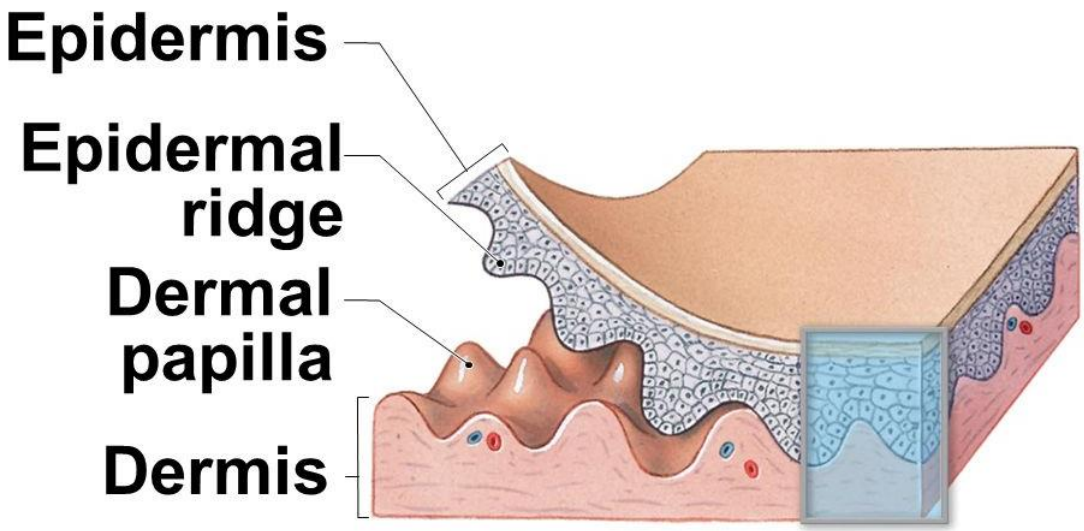

Figure 4.1 1

Dr. Heba Kalbouneh

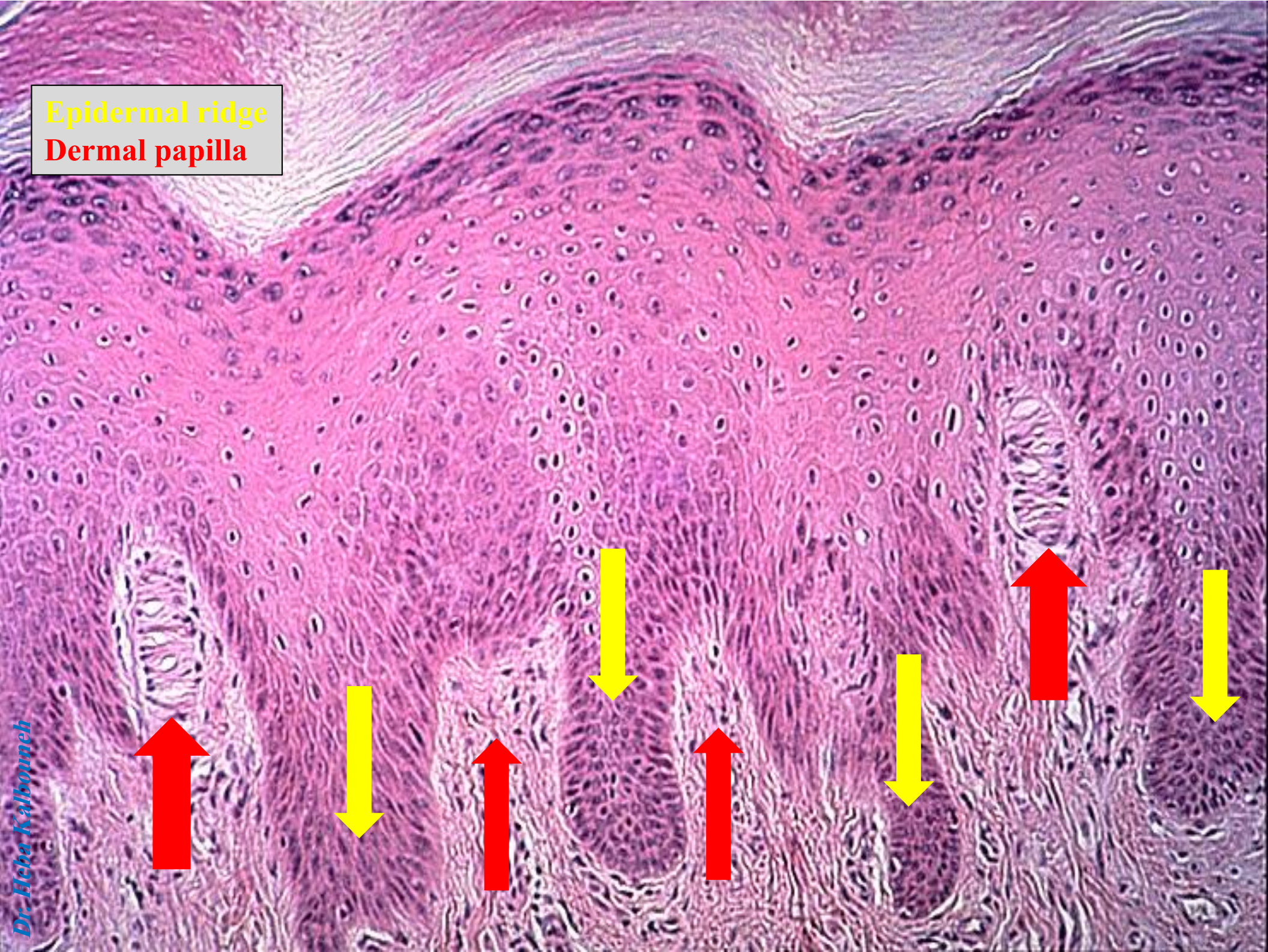
Epidermal ridge
Dermal papilla
Dr. Heba Kalbouneh

Epidermis

- Is the outermost layer of the skin
- It is composed of four or five layers, depending on the type of skin.
- It is rich in a tough protein called keratin
- Contains four different cell types:

Keratinocytes
Melanocytes
Langerhans cells
Merkel cells

- Avascular
- The epidermis forms a waterproof barrier between the body and the external environment, which resists friction and microbial invasion and prevents water loss
- Is derived from ectoderm

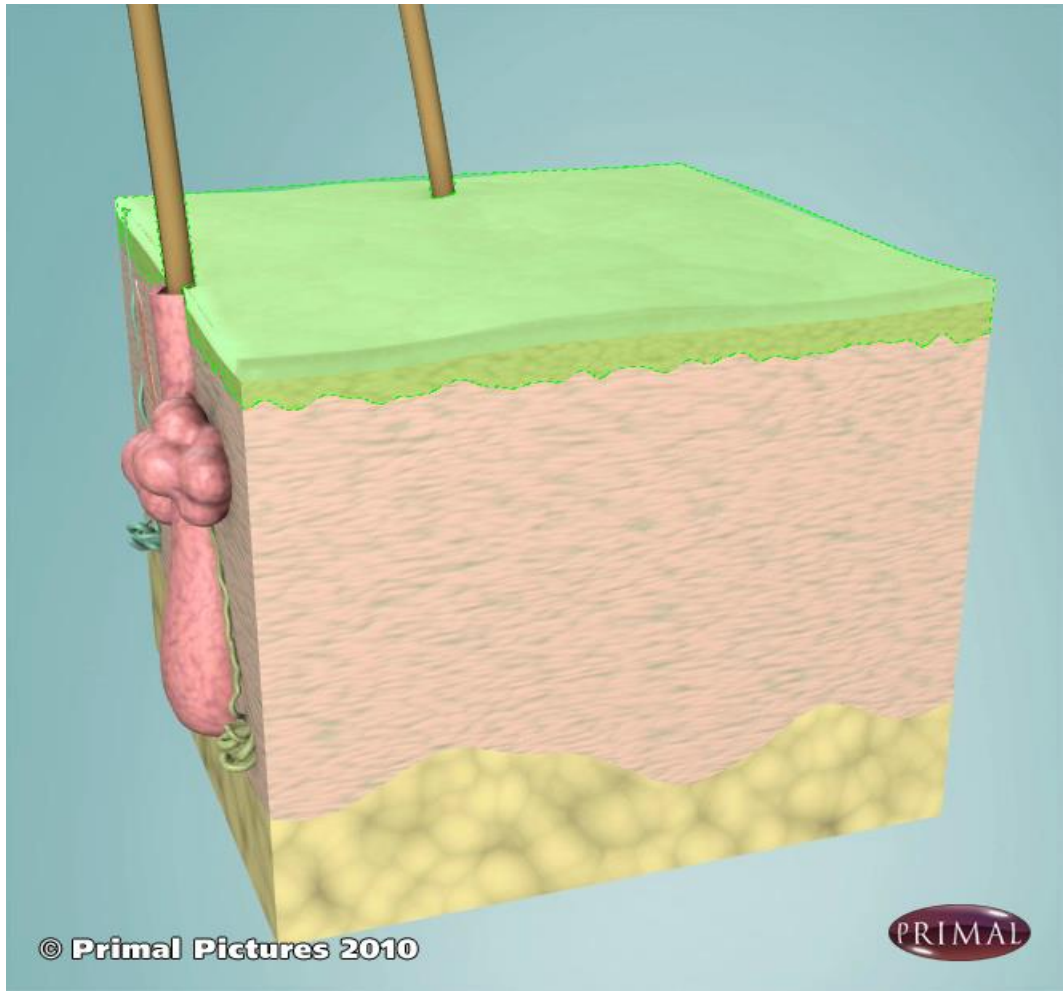

Keratinized stratified squamous epithelium

Dr. Heba Kalbouneh

(1) Stratum basale

- Is the deepest layer in the epidermis.
- Consists of a single layer of basophilic columnar to cuboidal cells that rest on a basement membrane
- The cells are attached to one another by desmosomes, and to the underlying basement membrane by hemidesmosomes.
- Cells are characterized by intense mitotic activity

As cells of the outer surface of the epidermis are continually being sloughed off, some cells in the stratum basale divide continuously, replenishing the epidermis.

Dr. Heba Kalbouneh

(2)Stratum spinosum

- Is the layer above the stratum basale
- Consists of 8-10 rows of cells
- Cells synthesize keratin filaments that become assembled into tonofilaments
- During histologic preparation, cells shrink and intercellular spaces appear as spines
- Spines represent sites of desmosome attachments to keratin tonofibrils

Dr. Heba Kalbouneh



Stratum basale along with the deepest part of stratum spinosum is called
Stratum germinativum

Dr: Heba Kalbouneh

(3)Stratum granulosum

- Cells above the stratum spinosum
- Consists of 3-5 cell layers of flattened cells
- Cells filled with dense basophilic keratohyalin granules and membrane- bound lamellar granules

Dr. Heba Kalbouneh

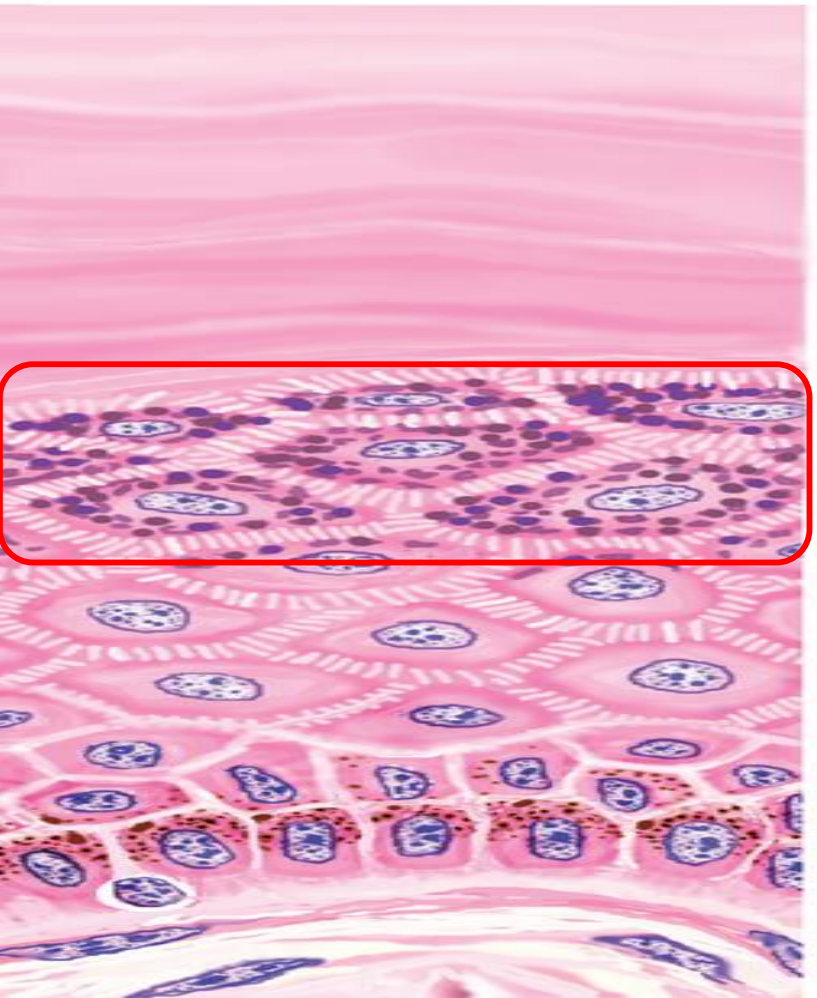

Keratohyalin granules are intensely basophilic, non membranous bound masses of filaggrin cross-links with keratin tonofibrils

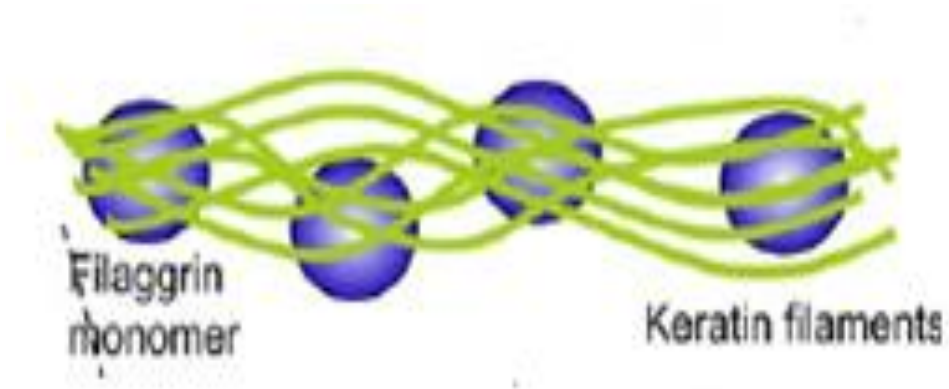

Tonofibrils



Intermediate filaments= keratin

Tonofilaments

Lamellar granules discharge lipid material between cells and waterproof the skin

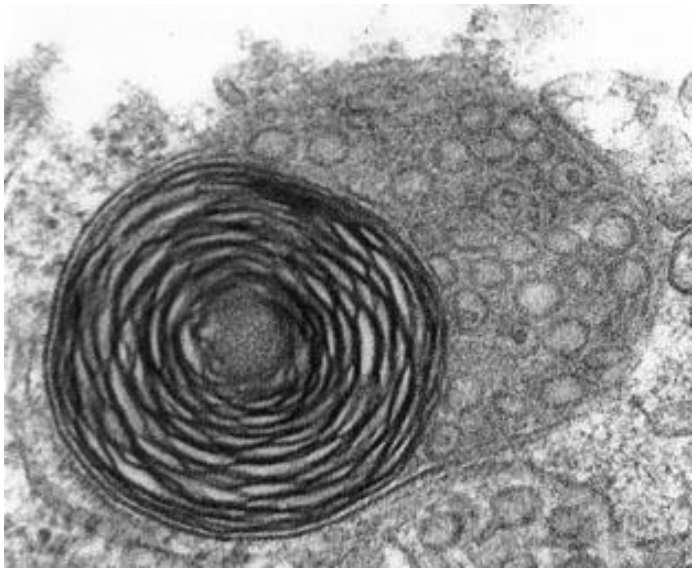

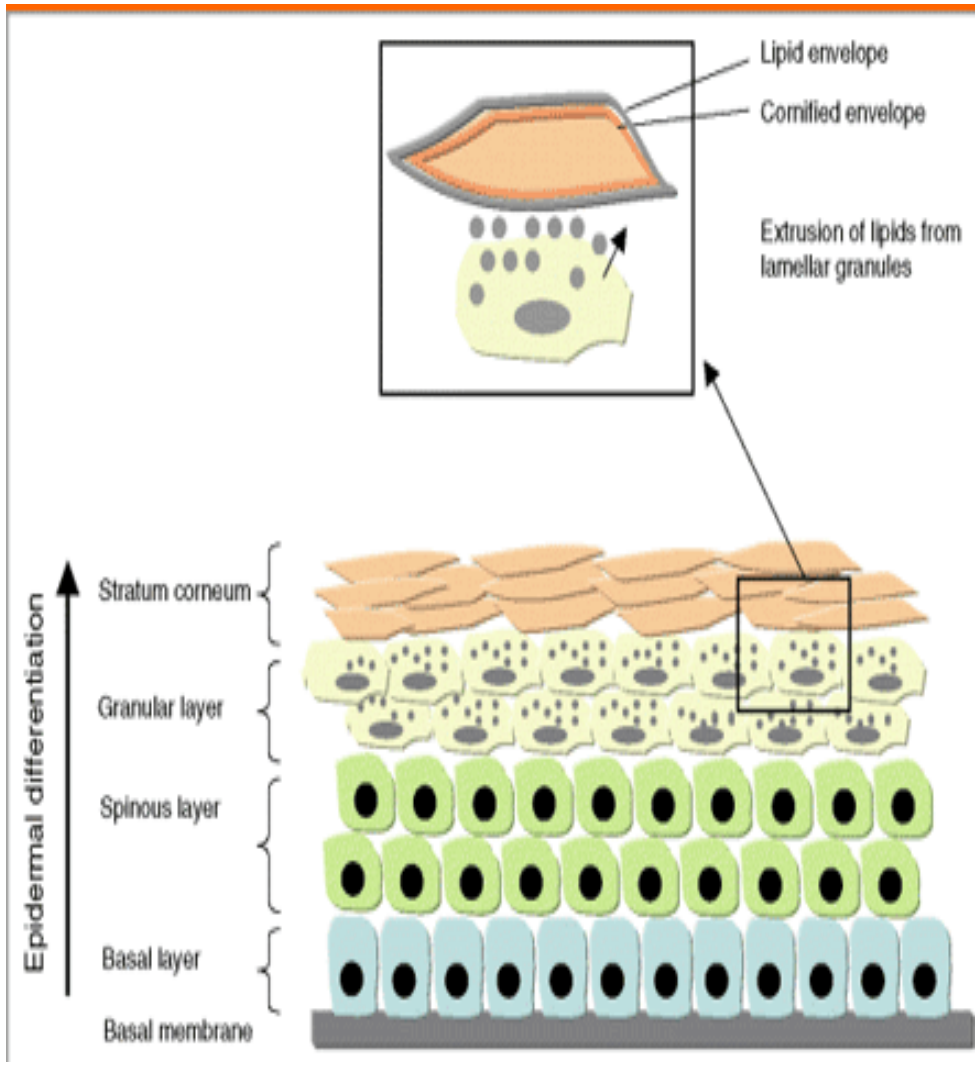

(4)Stratum Lucidum

- In thick skin only
- Is translucent and barely visible
- The tightly packed cells (desmosomes) lack nuclei or organelles and are dead.

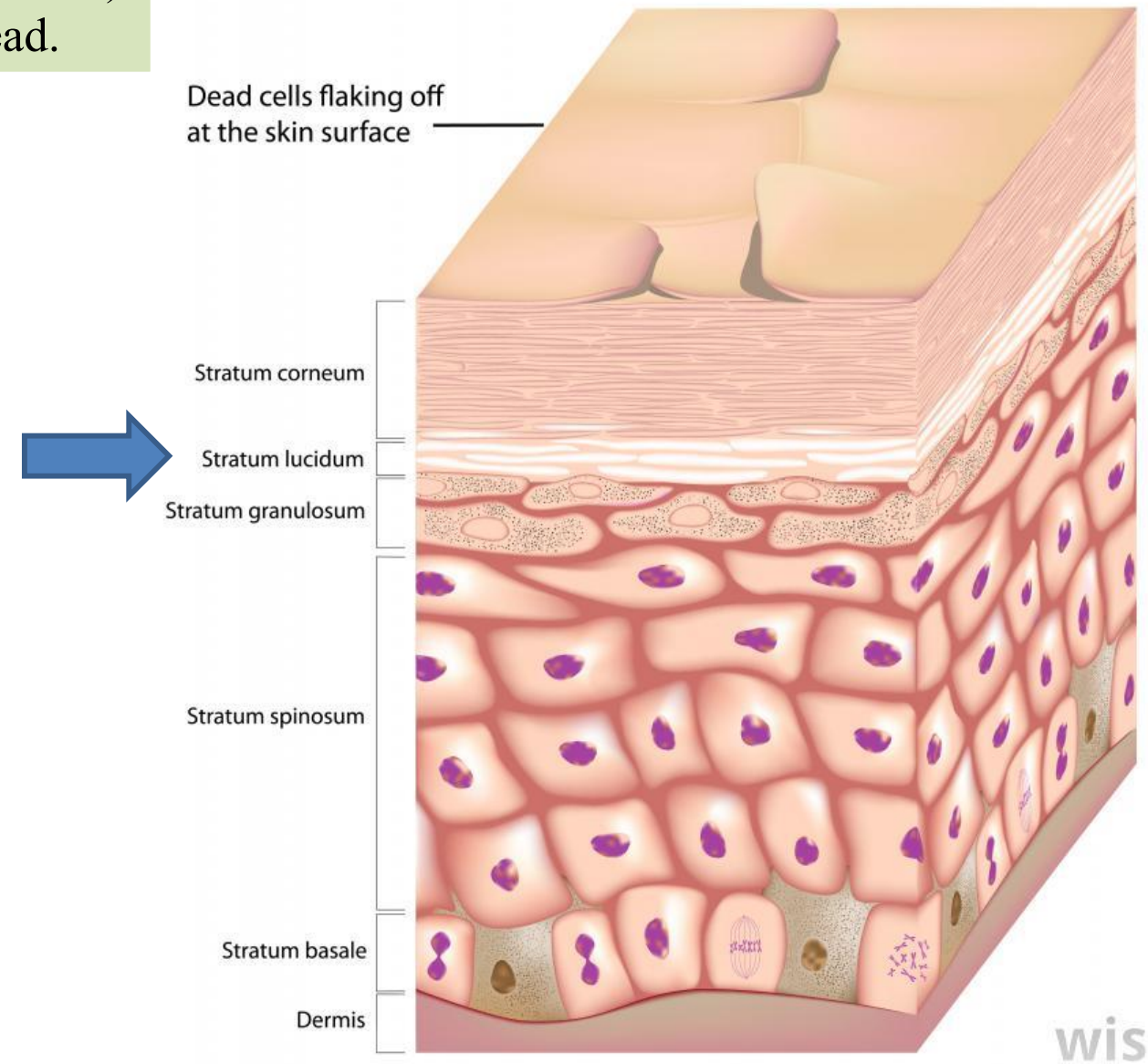

(5)Stratum corneum

- Most superficial layer of the skin.
- Consists of dead, flattened cells with no nuclei and cell organelles
- The dead cells contain much keratin filaments with plasma membranes surrounded by lipid-rich layer
- The cells from this layer are continually shed, or desquamated, and are replaced by new cells arising from the deep stratum basale.
- During the keratinization process, the hydrolytic enzymes disrupt the nucleus and all cytoplasmic organelles, which disappear as the cells fill with keratin.

Dr. Heba Kalbouneh

This layer acts to waterproof the skin surface

Keratin is a tough and fibrous protein that serves to protect the skin.

Calluses and corns

Dr. Heba Kalbouneh

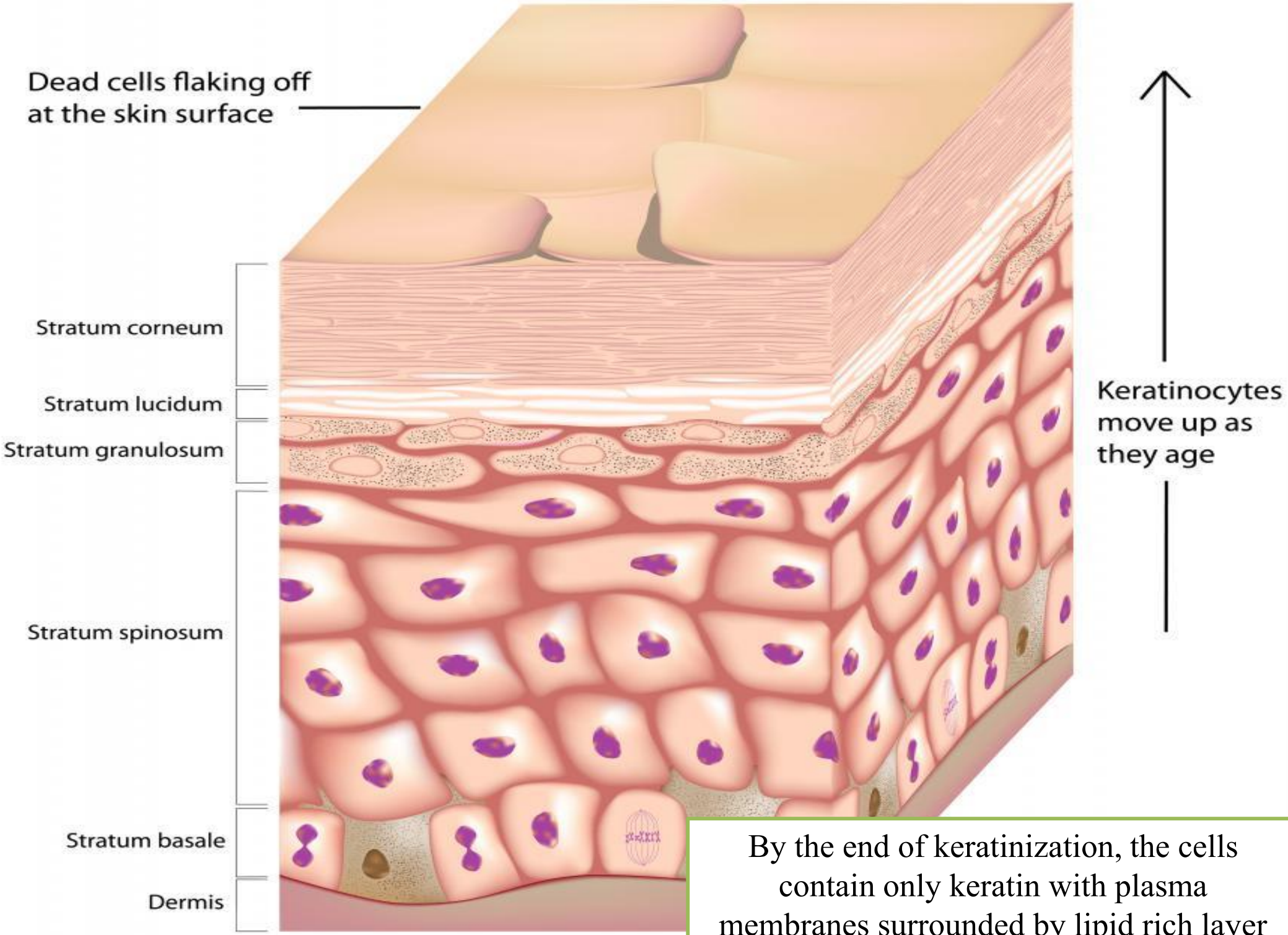

By the end of keratinization, the cells contain only keratin with plasma membranes surrounded by lipid rich layer

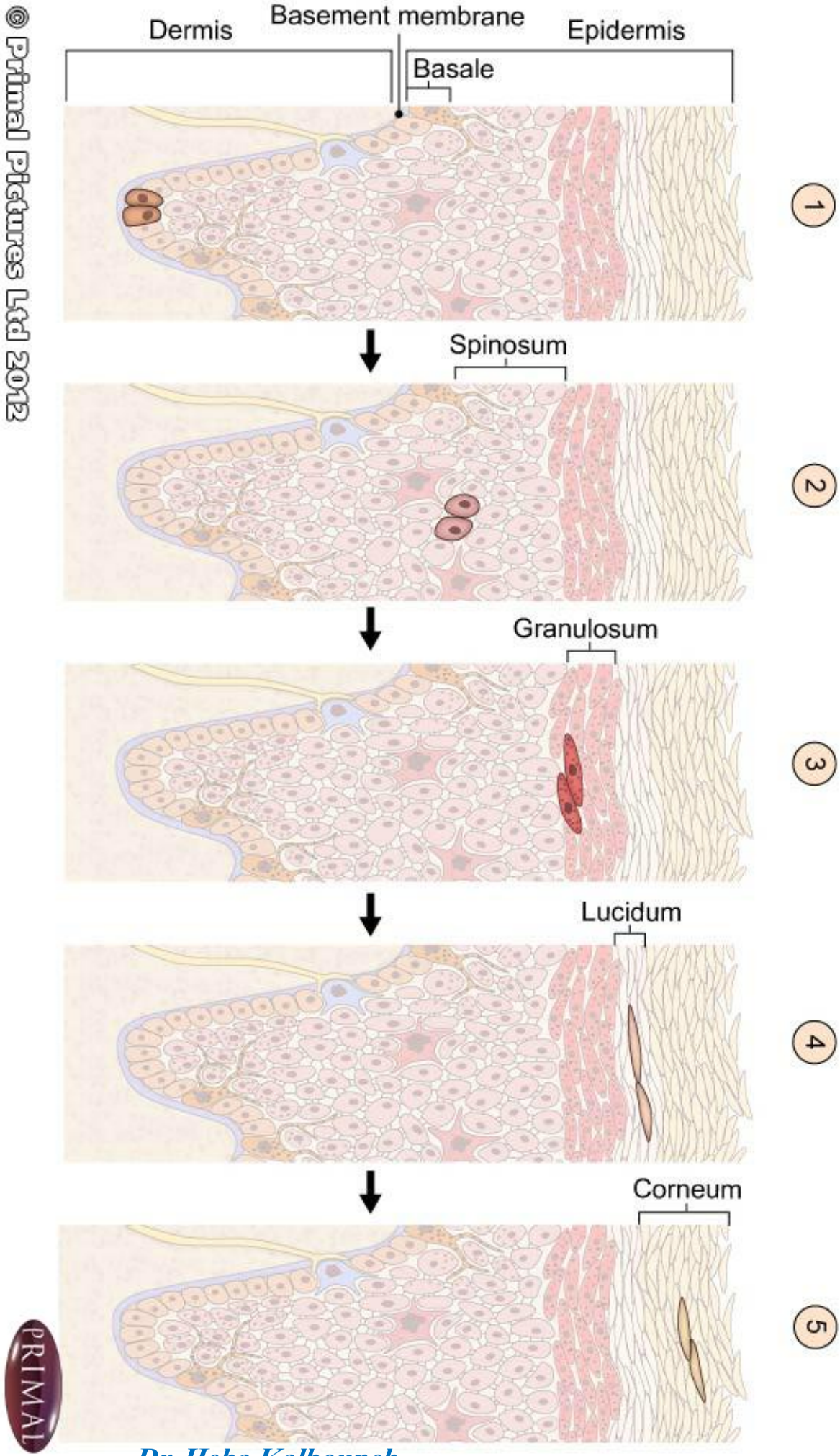

Dr. Heba Kalbouneh

Psoriasis: is a common skin condition that speeds up the life cycle of skin cells. It causes cells to build up rabidly on the surface of the skin. The extra skin cells from scales and red patches that are itchy and sometimes painfull

Dr: Heba Kalbouneh

Types of skin

Thin skin

Thick skin

Dr. Heba Kalbouneh

*** Dominant and lines most of the body surface**

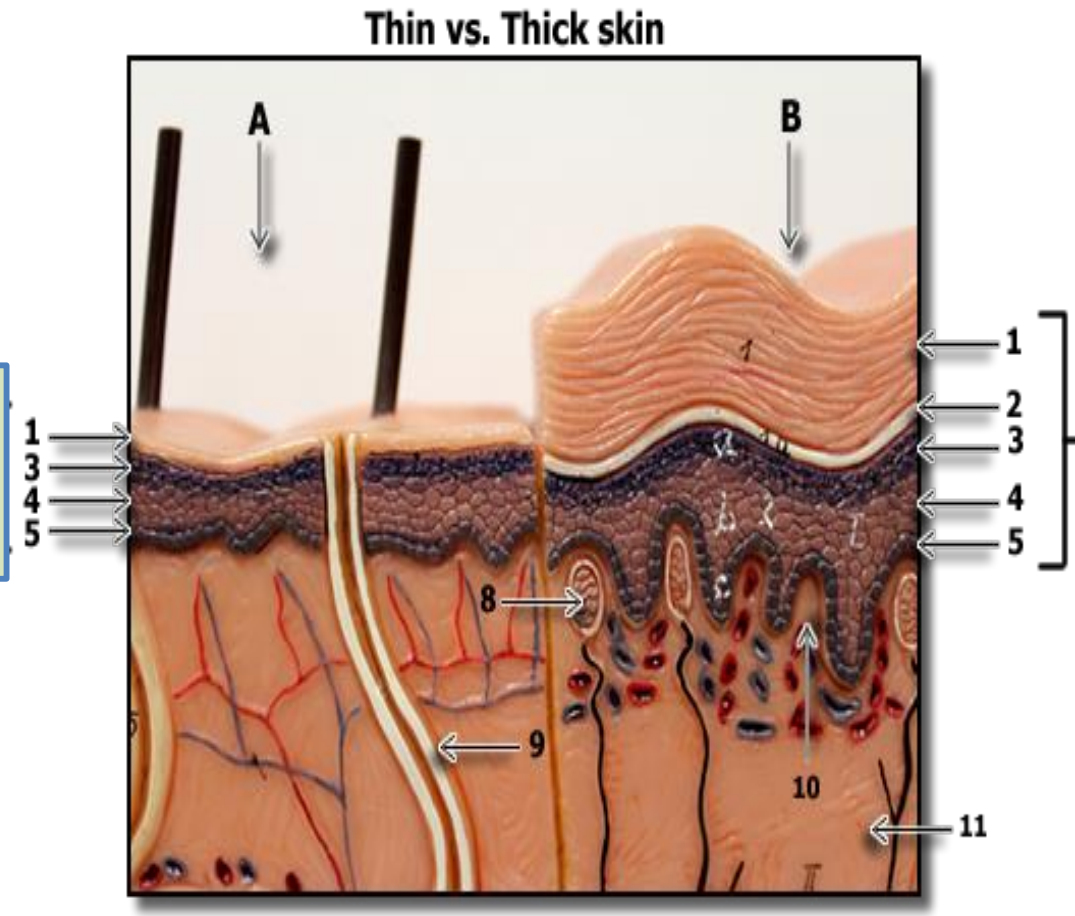

*** Palms of the hands and soles of the feet**

The skin of the back is thin…..The skin of the eyelids is thin too!!!

Thick skin resists the abrasion and friction

Note: that the thin and thick refer to the thickness of epidermal layer

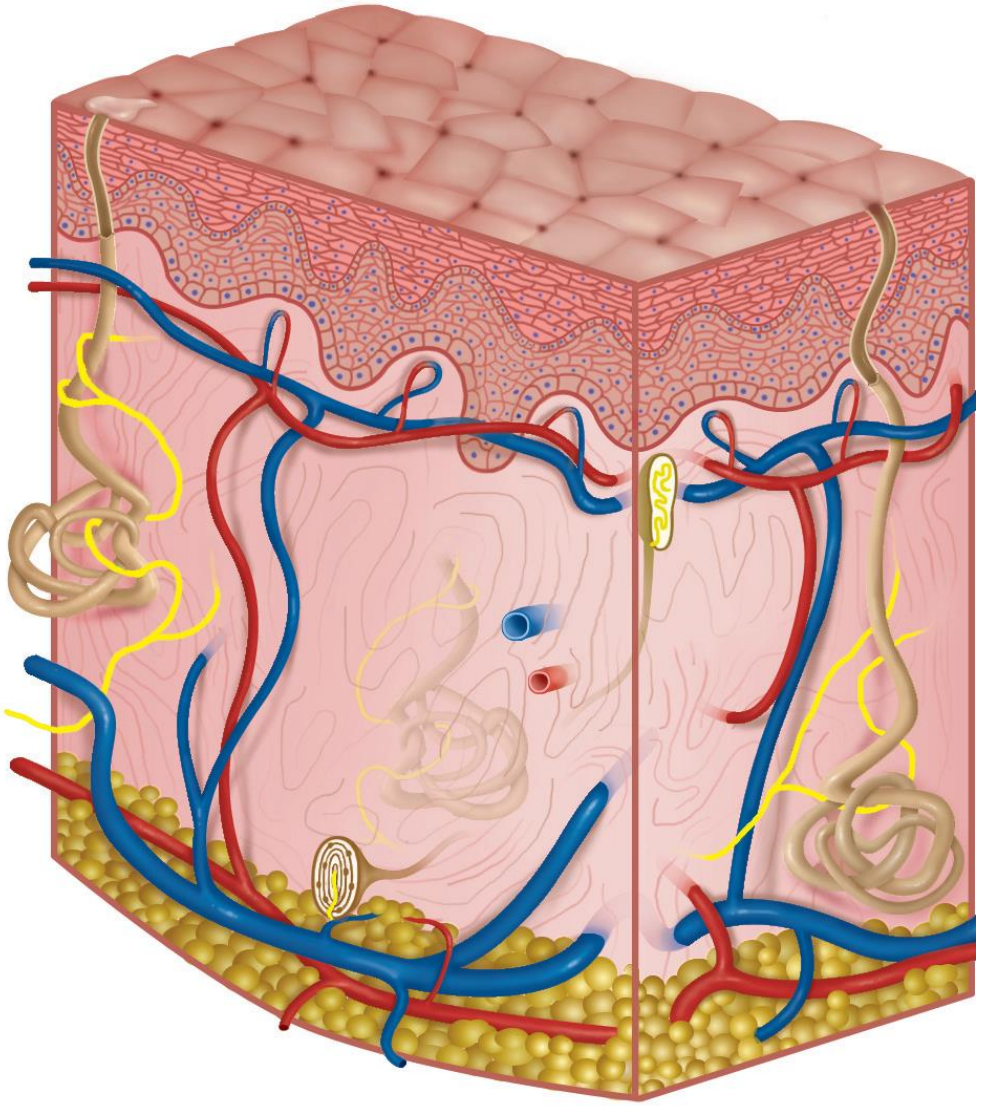

Thick skin

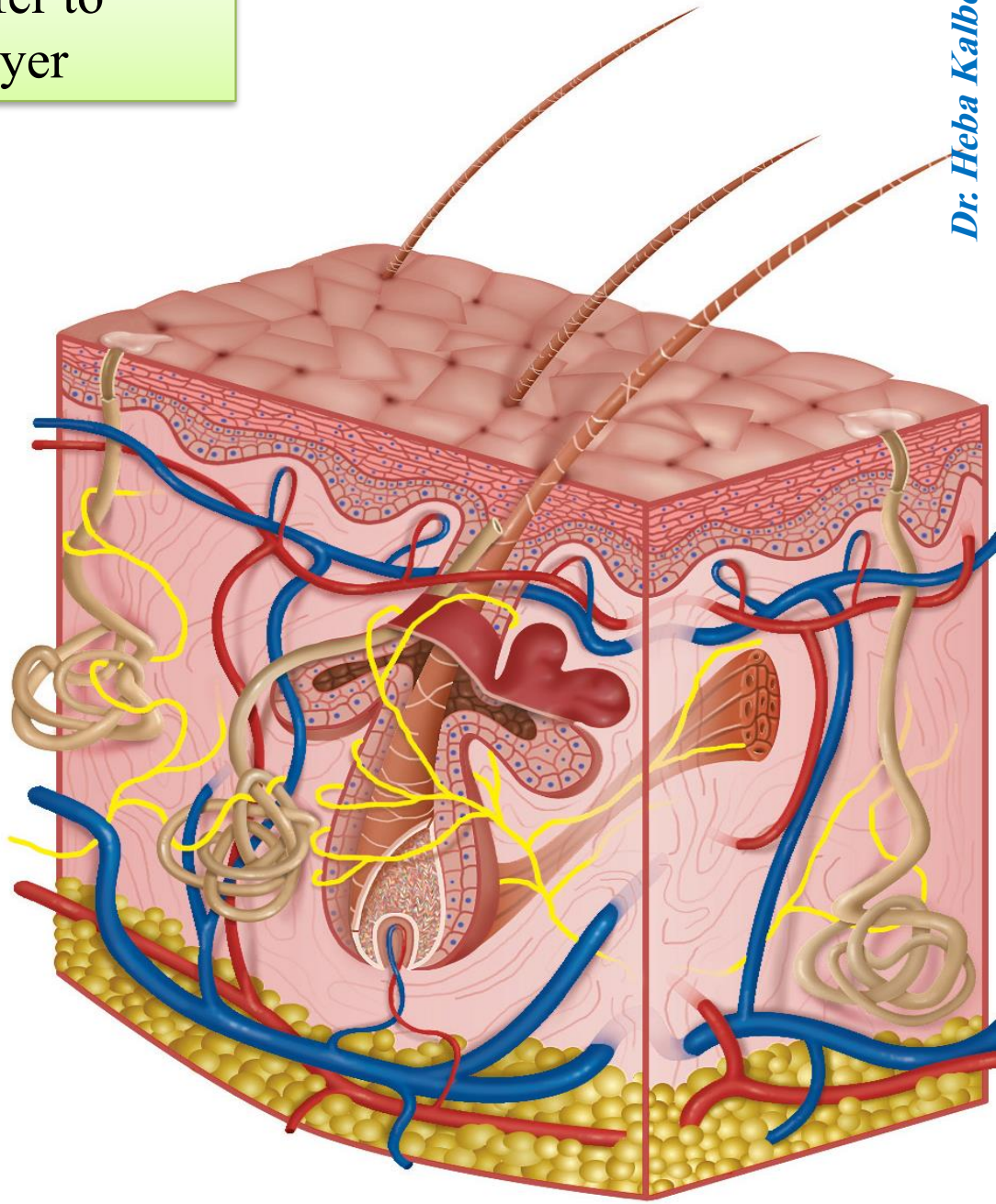

Thin skin

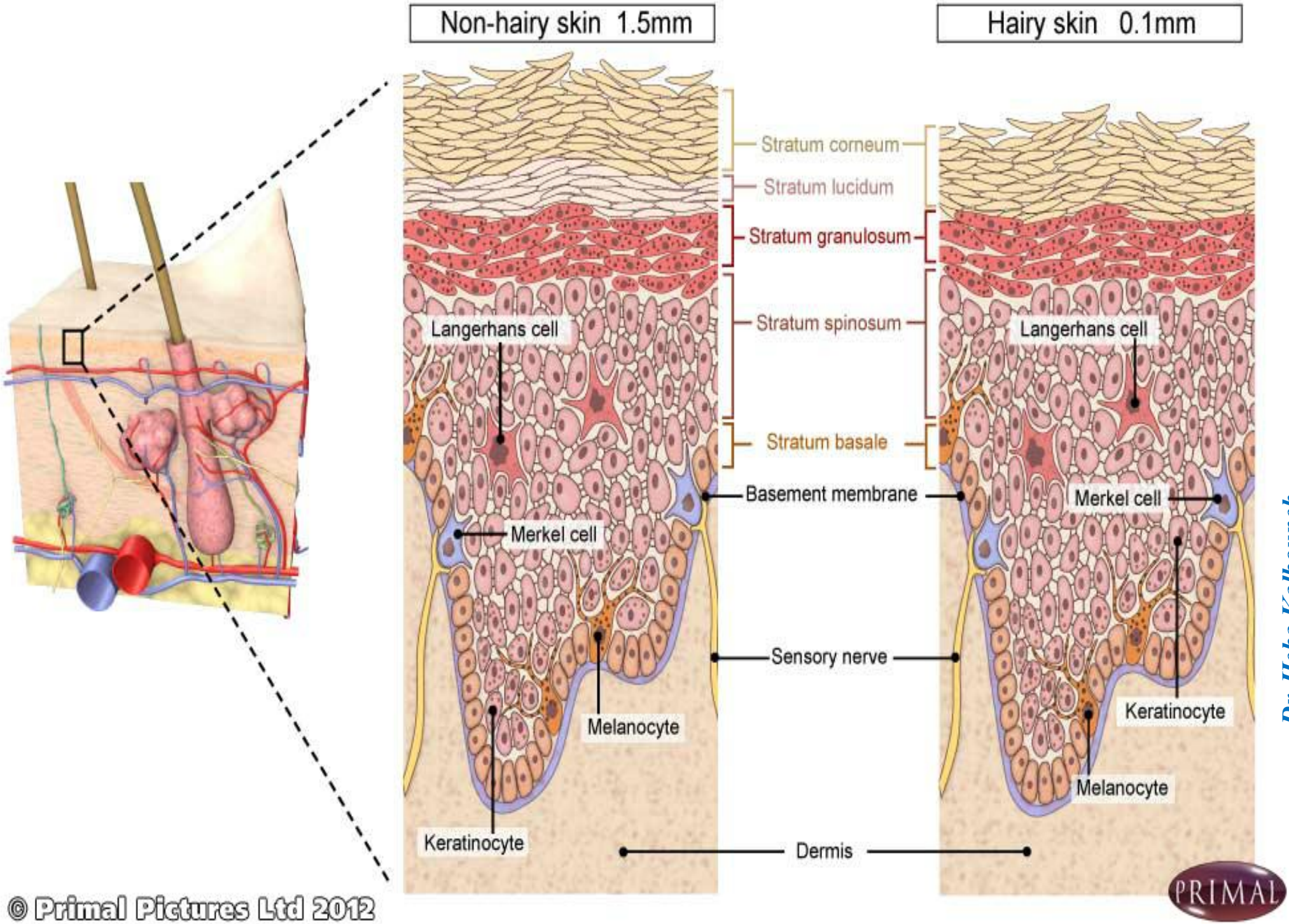

Dr. Heba Kalbouneh

Types of skin

Thin skin

Thick skin

Dr. Heba Kalbouneh

*4 layers
*less Prominent stratum corneum
* Less developed stratum granulosum
* Dominant and lines most of the body surface
* Thicker dermis
* hair and sebaceous glands

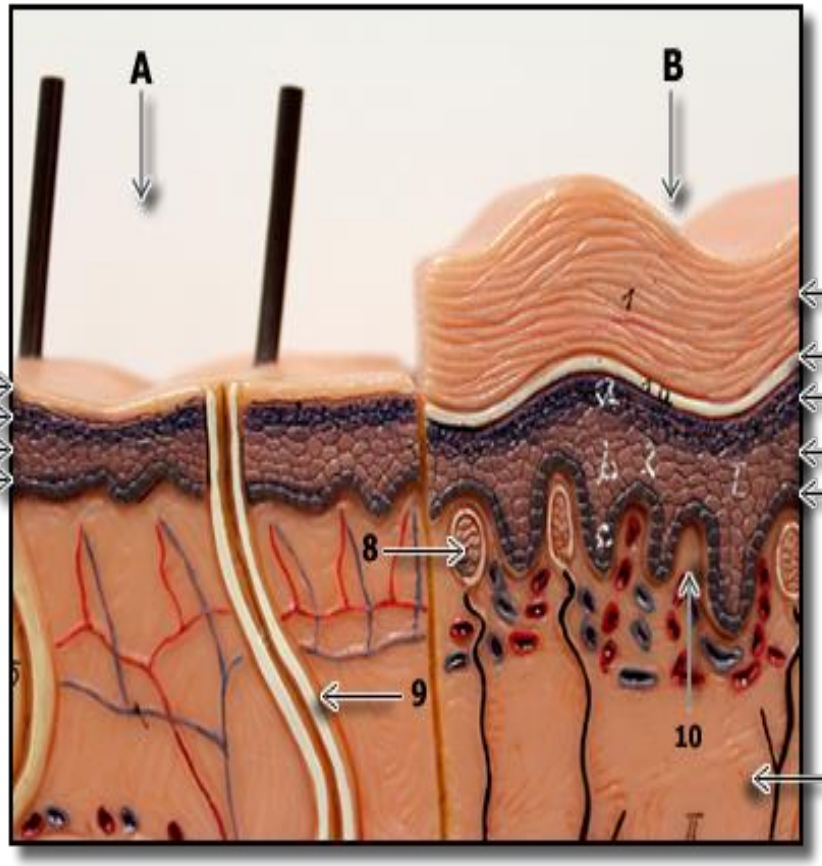

*5 layers
* Prominent stratum corneum
* Well developed stratum granulosum
* Palms of the hands and soles of the feet
* Thinner dermis
* No hair and sebaceous glands

TYPES OF EPIDERMAL CELLS

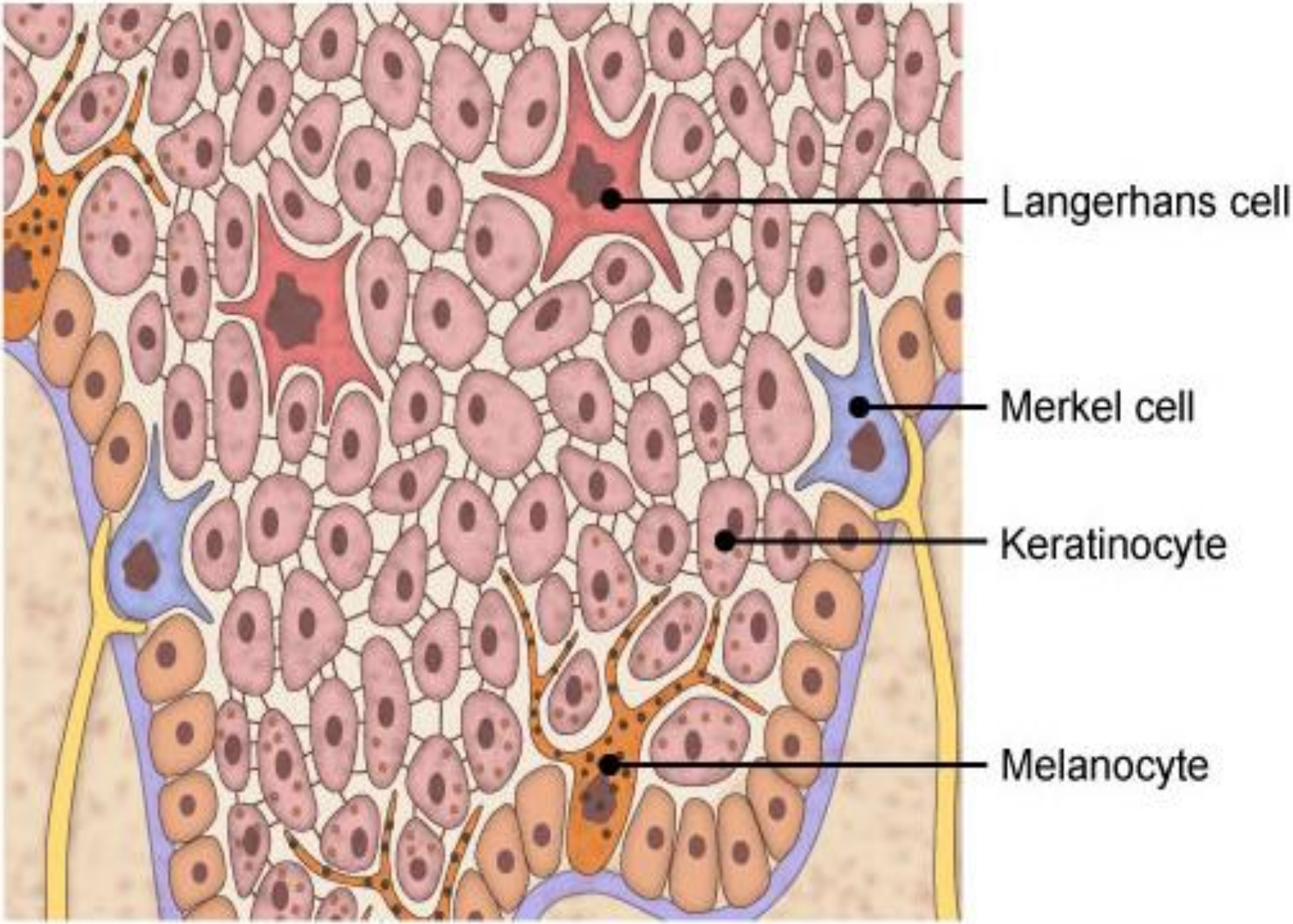

Dr. Heba Kalbouneh

(1)-keratinocytes:

- Approximately 90% of epidermal cells are keratinocytes.
- Produce **keratin**
- Produce **lamellar granules** that helps waterproof the skin

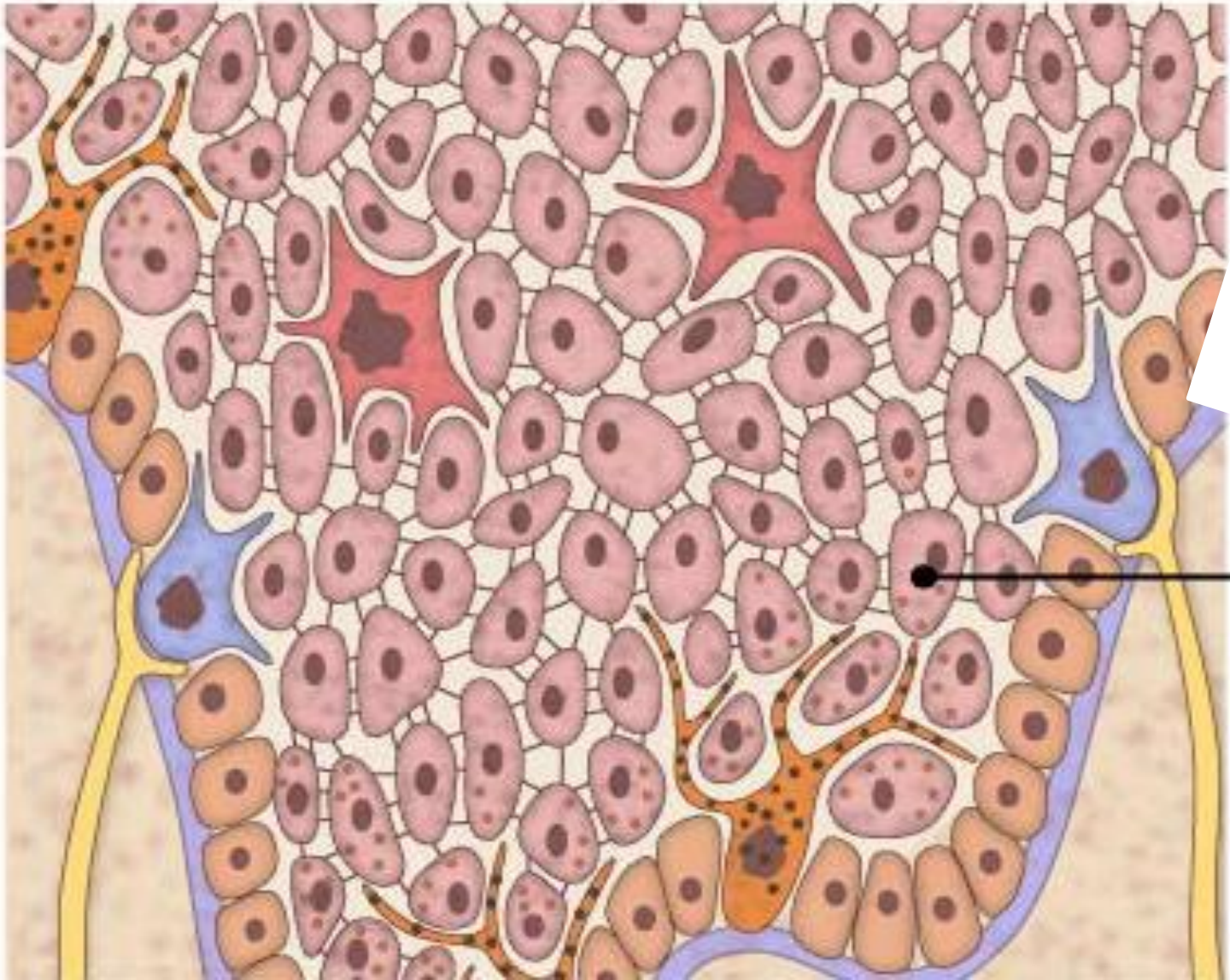

keratinocytes continuously shed and regenerate every 2-4 weeks

Keratinocyte

Dr: Heba Kalbouneh

NOTE: The structure of keratinocytes changes dramatically as they mature: they change from square-shaped cells to flat cells.

Throughout their life they become engorged with keratin before eventually dying, losing all of their internal structures.

(2)-Melanocytes:

Melanocytes are our natural **SPF**

- Are derived from the neural crest cells.
- Have protrusions that transfer melanin granules to the keratinocytes
- Are located in the stratum basale
- Synthesize the dark brown pigment melanin
- Melanin protects the skin from the damaging effects of ultraviolet radiation

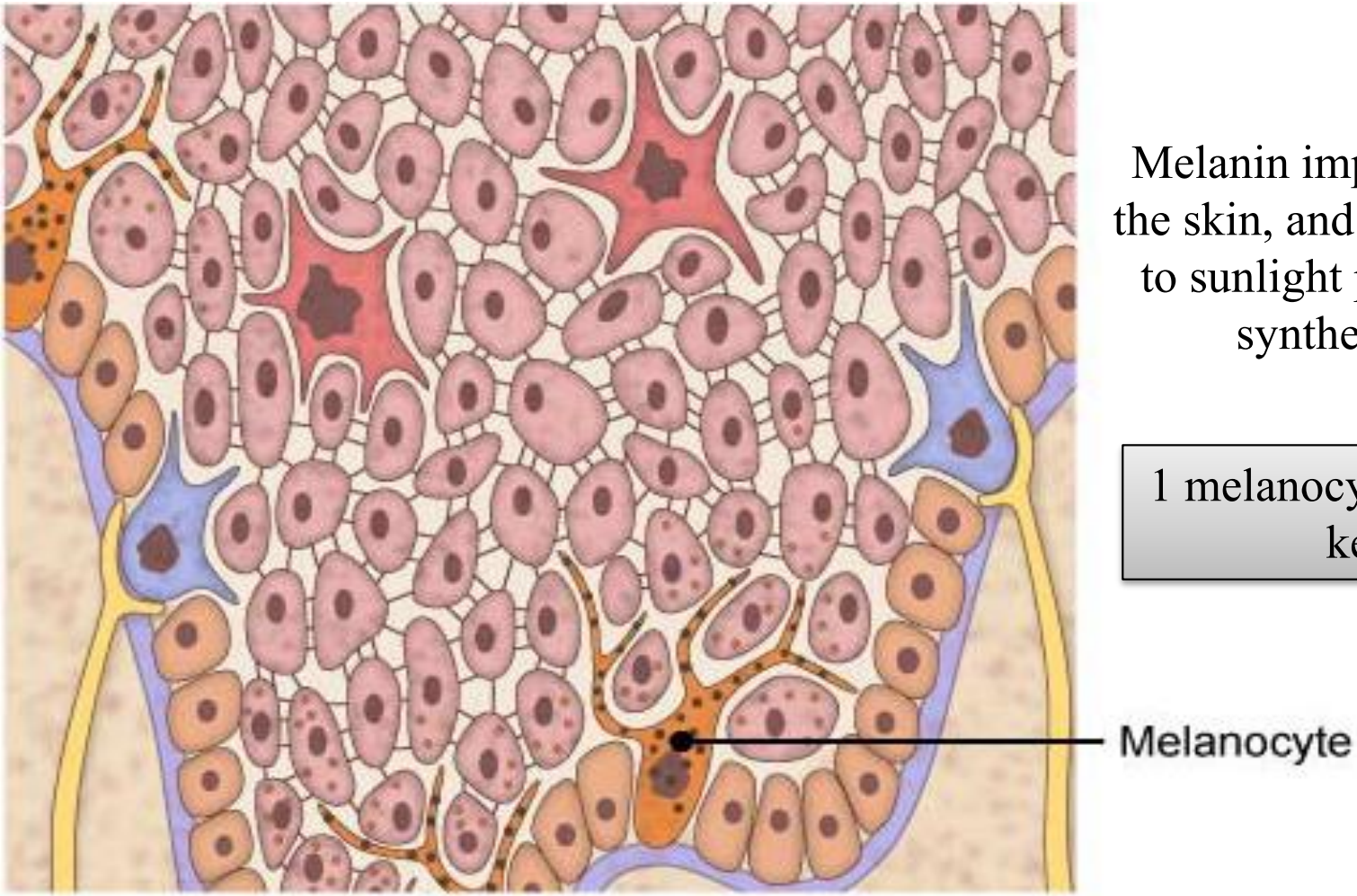

Melanin imparts a dark color to the skin, and exposure of the skin to sunlight promotes increased synthesis of melanin

1 melanocyte for every 10 basal keratinocytes

Dr. Heba Kalbouneh

Albinism

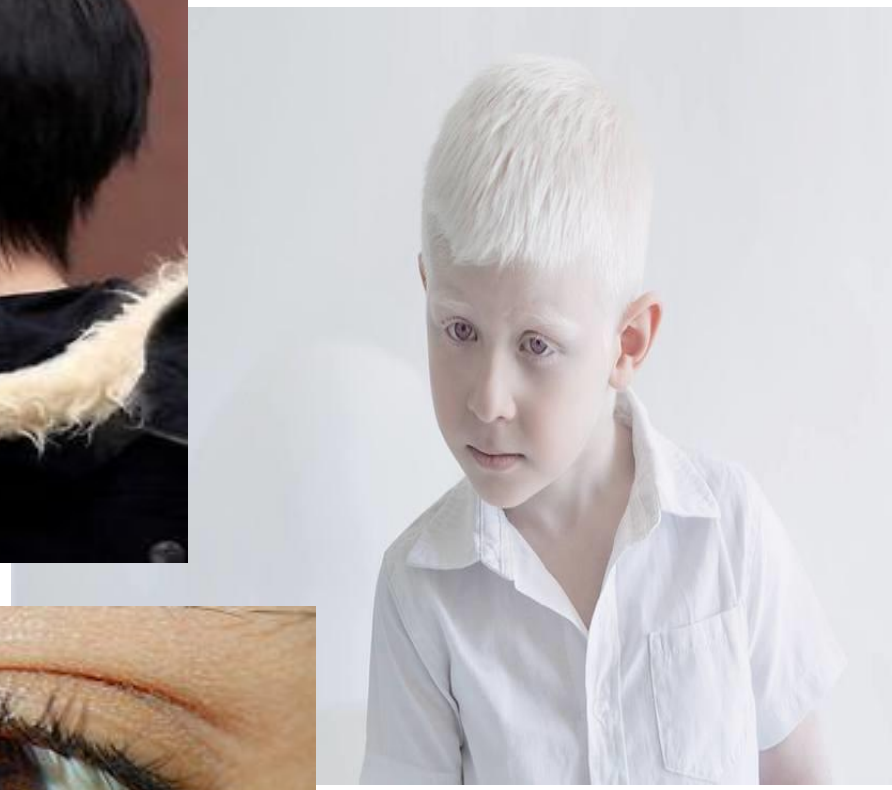

Dr. Heba Kalbouneh

(3)- Langerhans cells:

- Originate from bone marrow (monocytes)
- Mainly in the stratum spinosum
- Langerhans cells recognize, phagocytose, and process foreign antigens
- Represent 2-8% of epidermal Cells

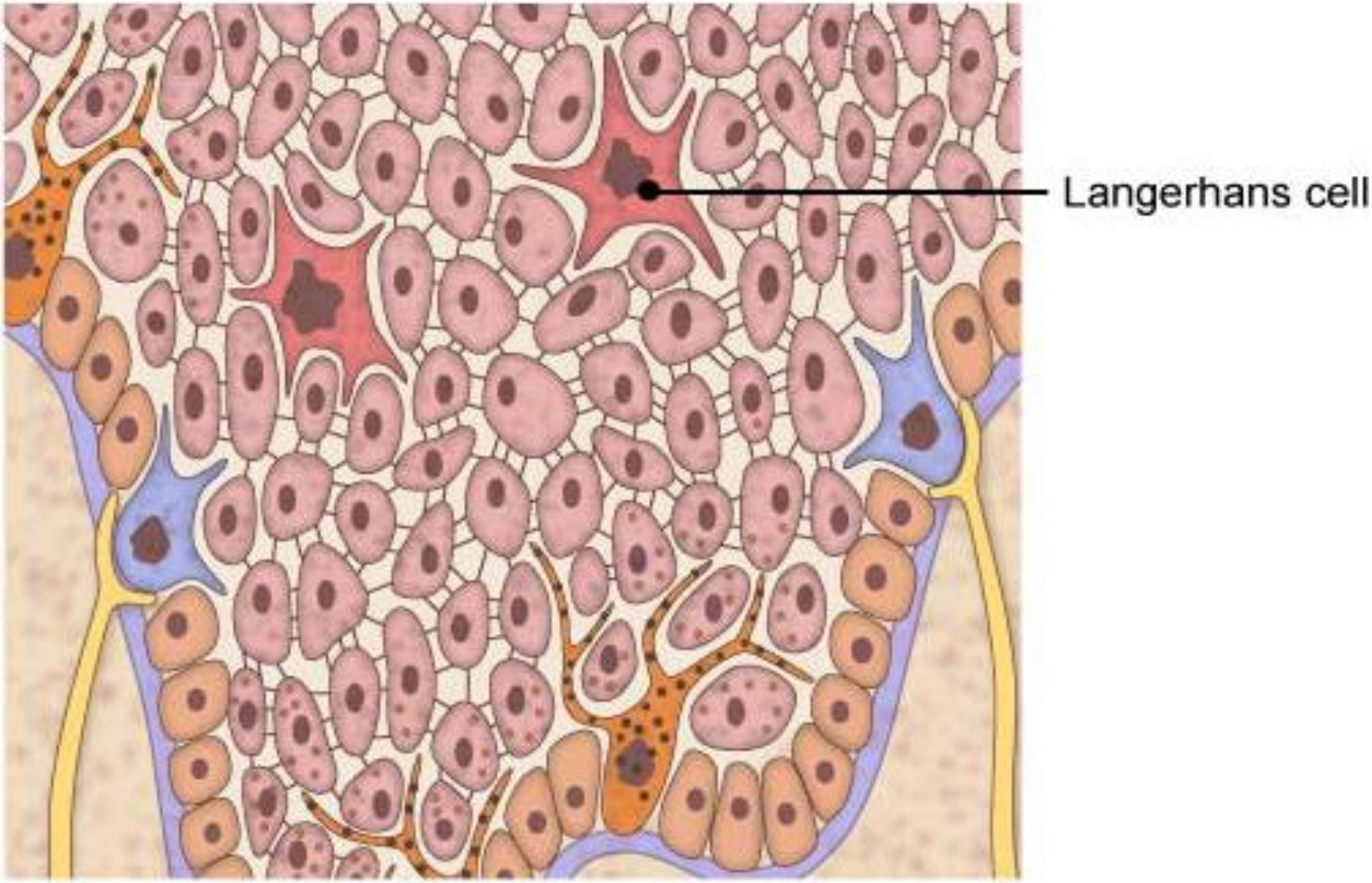

Dr. Heba Kalbouneh

(4)- Merkel cells:

- Are found in the stratum basale
- Are most abundant in the fingertips
- Are closely associated with afferent (sensory) unmyelinated Axons
- Function as light touch receptors (mechanoreceptors)

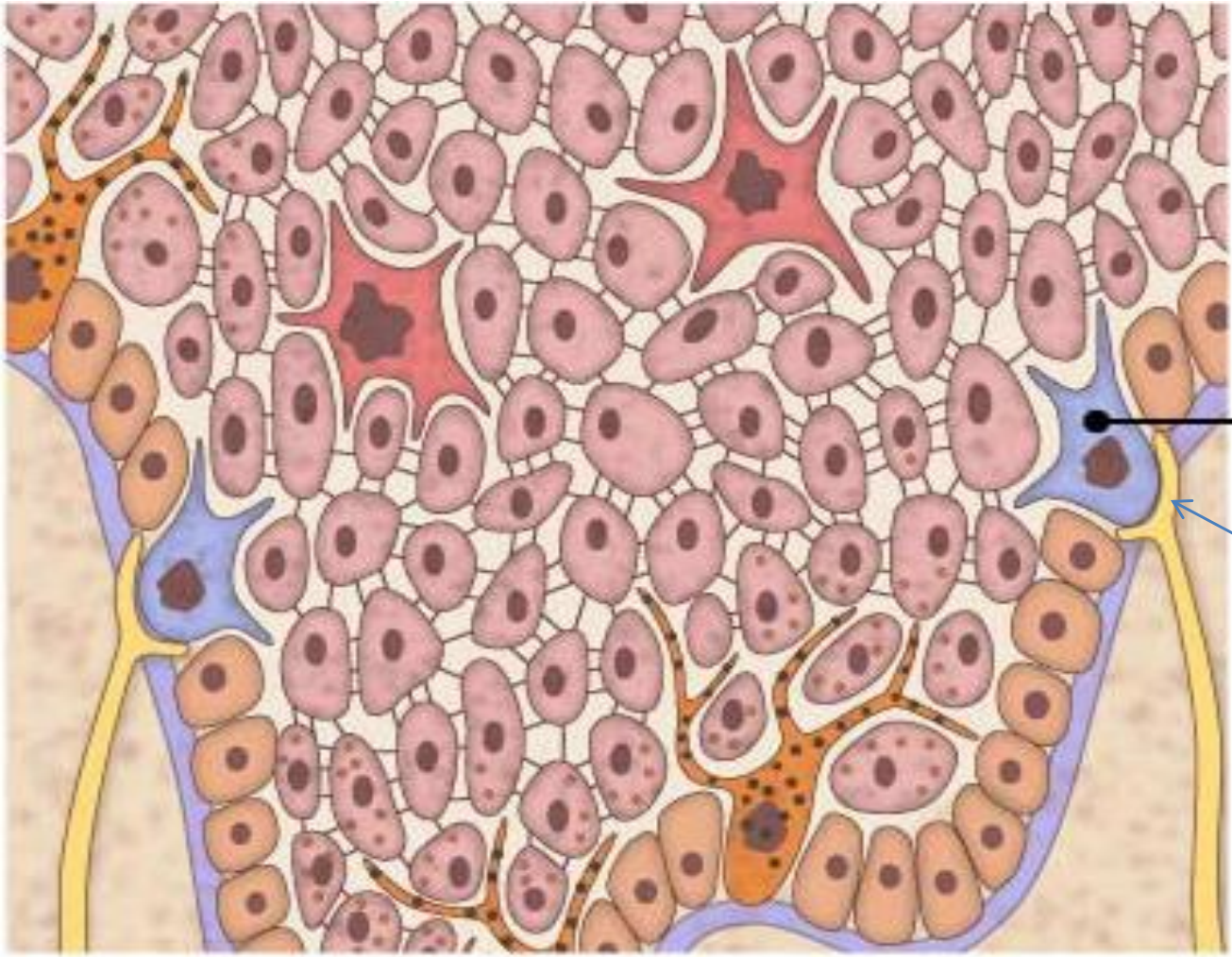

NOTE: Sensory neurons form terminal disk under Merkels cells

Dr. Heba Kalbouneh

Dermis

- The dermis lies immediately beneath the epidermis and is much thicker.
- It is responsible for the elasticity and strength of skin
- Contains blood vessels and nerve supply

It supplies the epidermis with nutrients,
and plays an important role in thermoregulation

- Is derived from mesoderm

The dermis can be divided into two sub-layers:

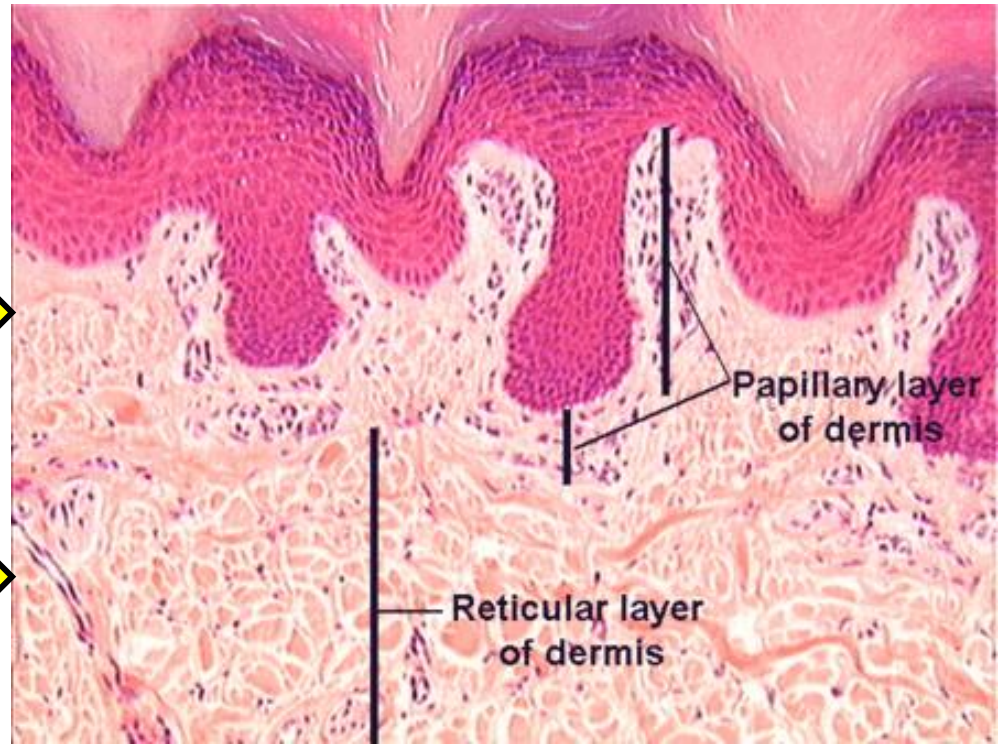

Dr. Heba Kalbouneh

(1) Papillary layer of dermis

Loose connective tissue

(2)Reticular layer of dermis

Dense irregular connective tissue

Is important in giving the skin it overall strength (collagen1) and elasticity (elastic fibers),

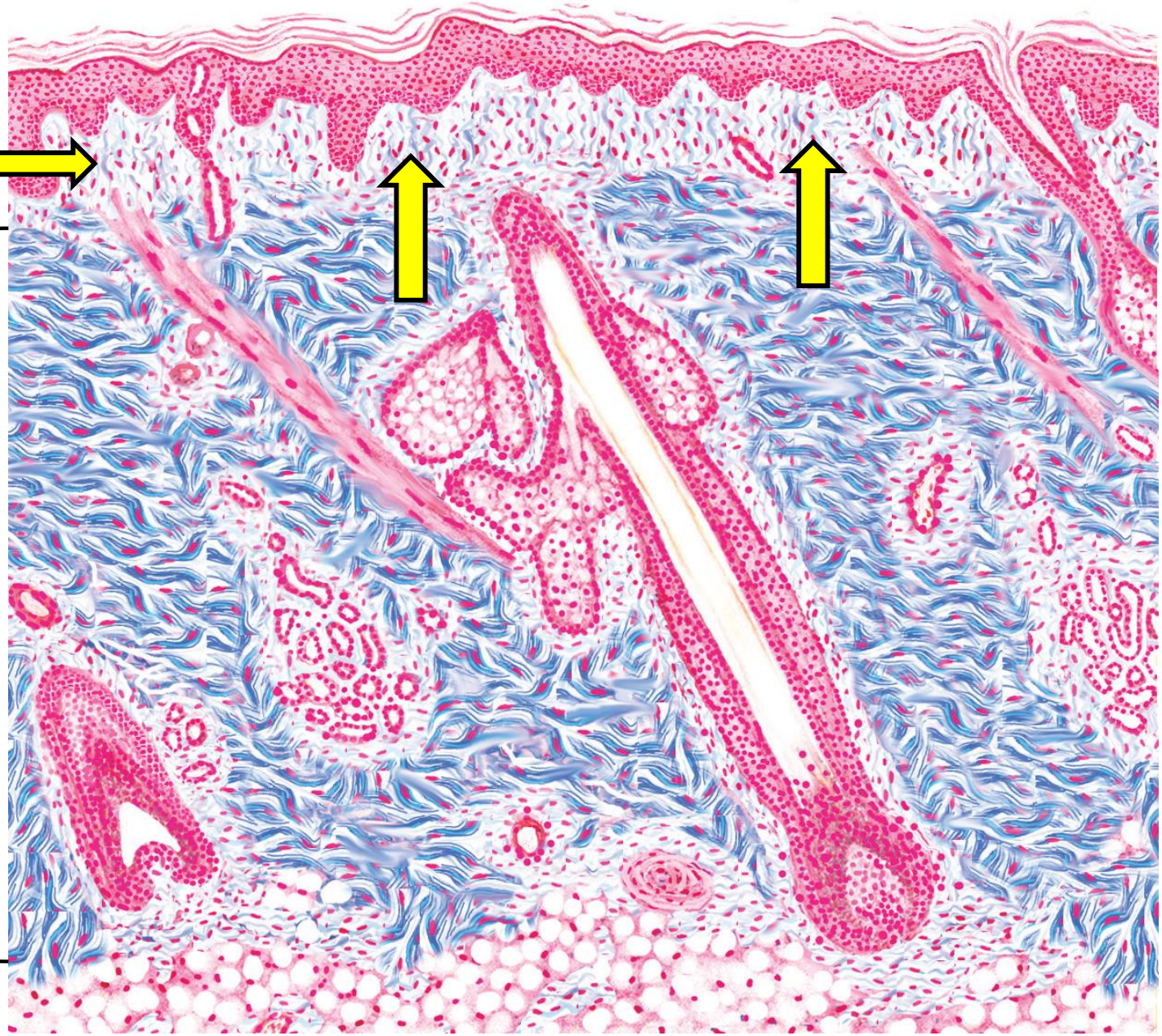

Dr. Heba Kalbouneh

The blood vessels form two major plexuses:

Subpapillary plexus

Thermoregulation

Subdermal plexus

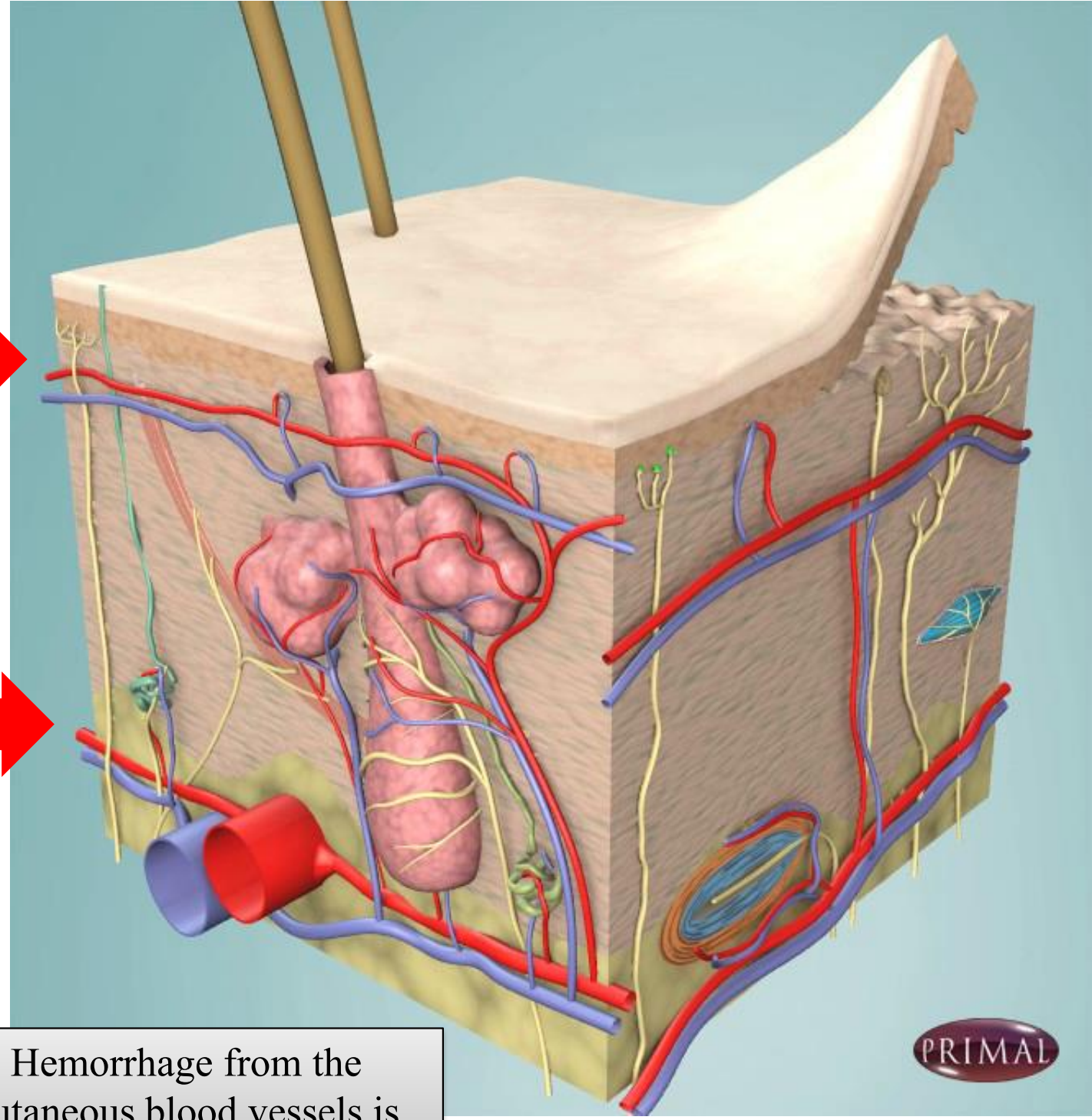

Hemorrhage from the cutaneous blood vessels is called **ecchymosis** (bruise)

Dr. Heba Kalbouneh

The **acid mantle** is a very fine, slightly acidic film on the surface of human skin

Is made up of natural oils, sweat, and dead skin cells, and is slightly more acidic in nature to prevent harmful (naturally alkaline) contaminants from penetrating and damaging the skin

The **acid mantle** adds protection from bacteria, environmental pollutants, and moisture loss.

Ph: 5.5

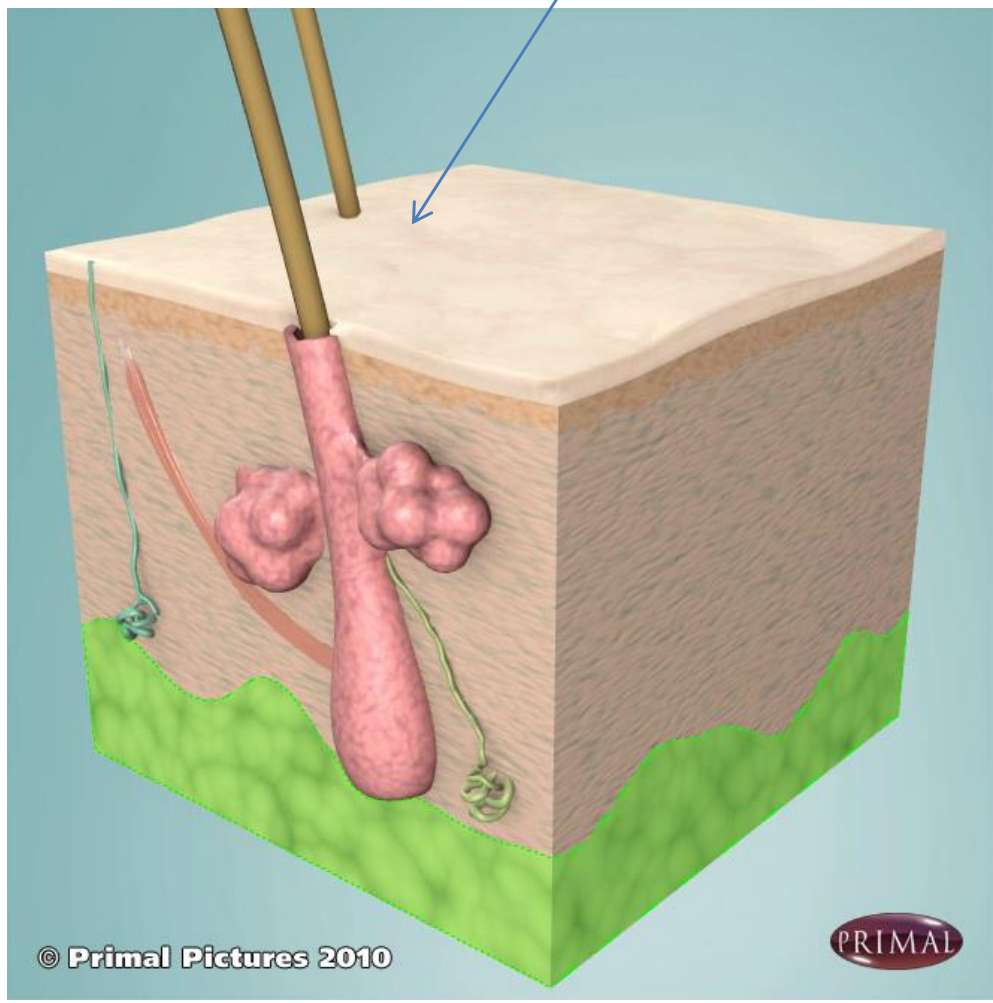

Sensory receptors

Unencapsulated receptors

Encapsulated receptors

Unencapsulated nerve receptors

1- Merkel disc
- for light touch and sensing an object texture
- expanded nerve endings associated with merkel cell

2- Free nerve endings
- In papillary dermis
- Temperature, pain, itching, tactile sensation

3- Root hair plexuses
- Surround the bases of hair follicles in reticular dermis
- Detect movements of hair

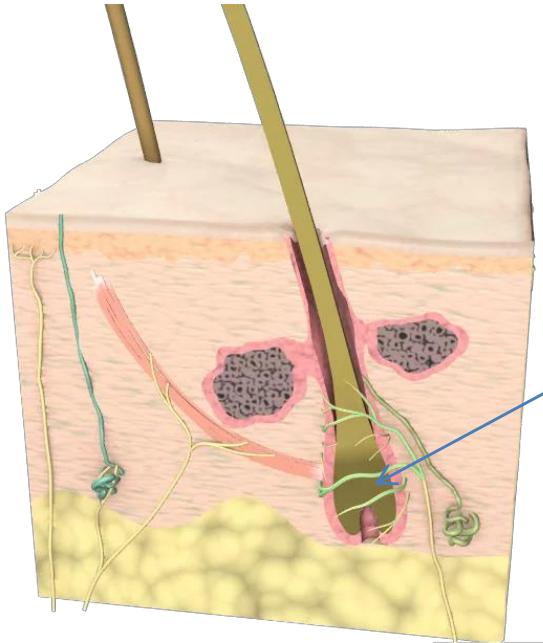

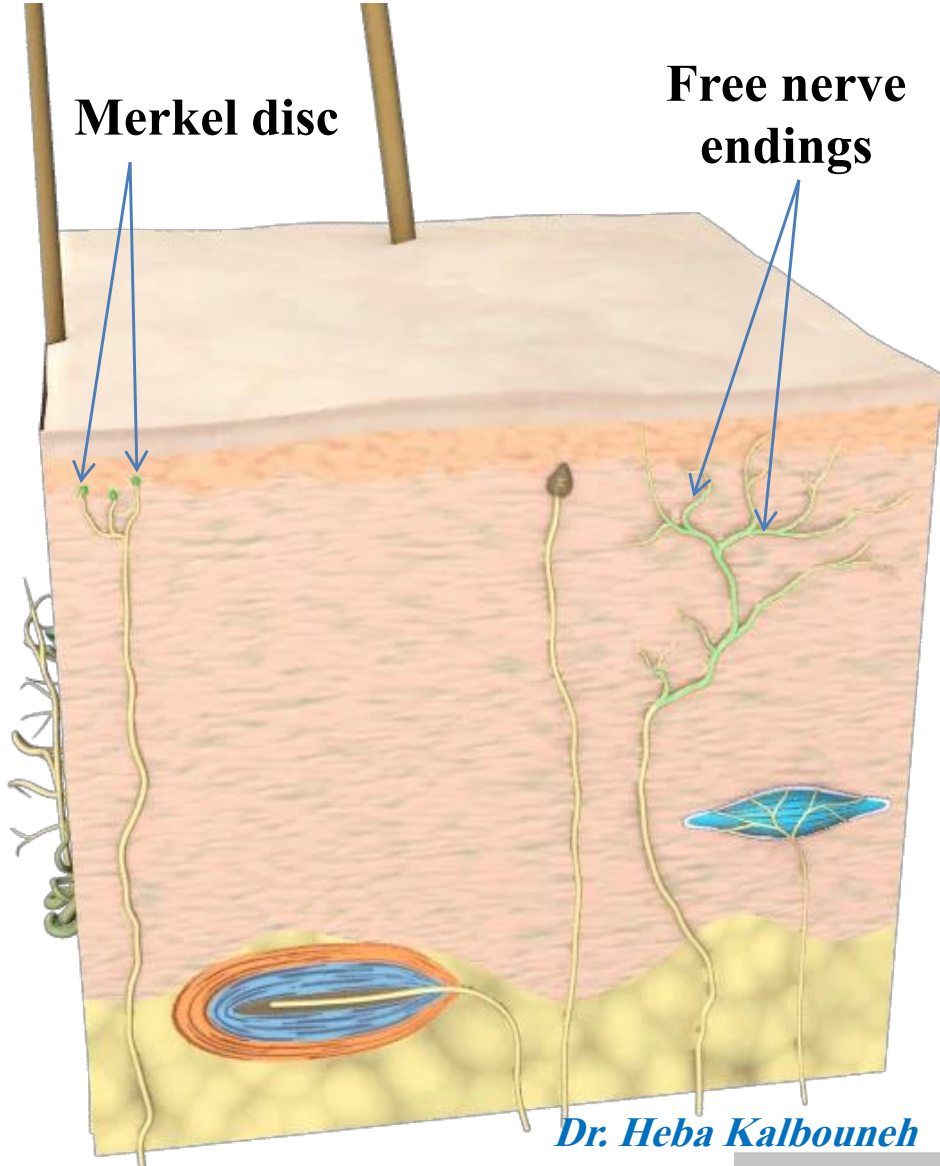

Dr. Heba Kalbouneh

Meissner corpuscles:

- Encapsulated
- In the dermal papilla
- Light touch
- Are numerous in fingertips, palms and soles
- Decline in number with aging

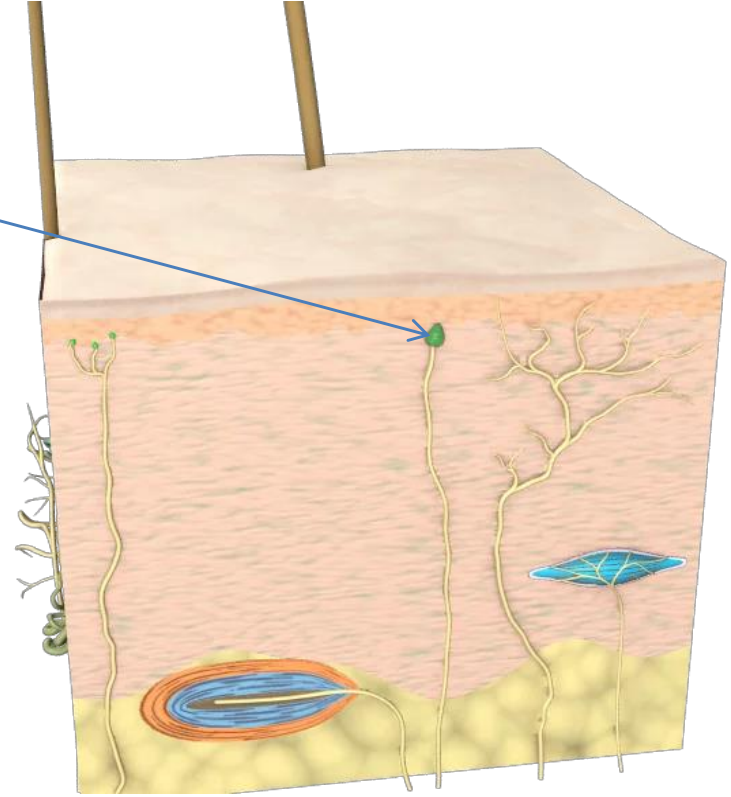

Pacinian corpuscles

- Encapsulated
- Found deep in reticular dermis and hypodermis
- Coarse touch, pressure (sustained touch) and vibrations

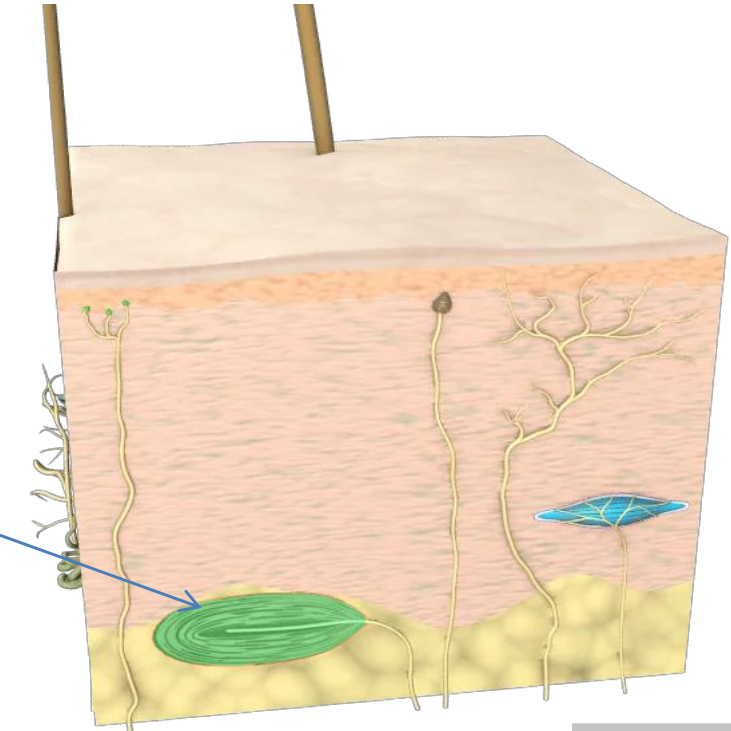

Dr. Heba Kalbouneh

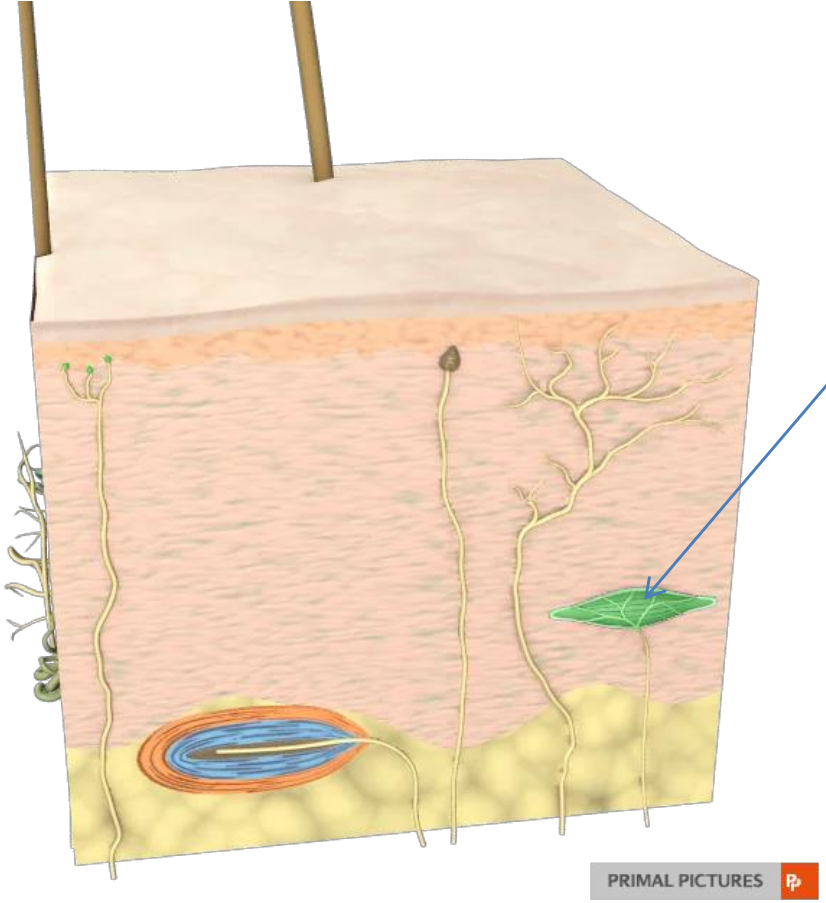

Ruffini corpuscles:

- Encapsulated
- Stretch (tension) and twisting (torque)

Skin Appendages

Hair Follicles and hair

Sweat glands

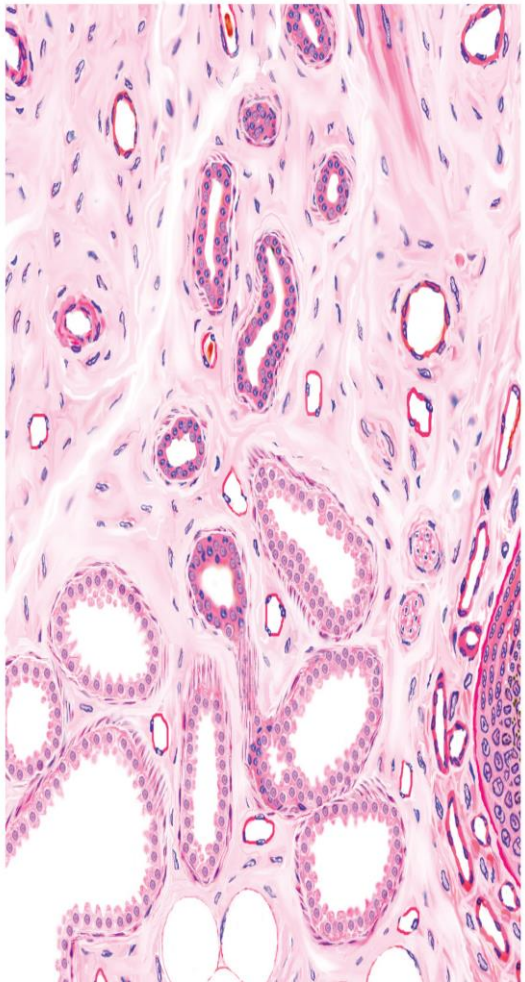

Sebaceous glands

Nails

Dr. Heba Kalbouneh

Hairs are elongated keratinized structures that form within epidermal invaginations (hair follicles)

Types of hair:
1- Lanugo: fetal hair
2- Down hair: light colored hair of child
3- Terminal (adult) hair: thicker, darker hair that begins to grow at puberty

Hair shaft: The part of a hair extending beyond the skin surface (visible part)

Hair root: The part of a hair below the skin surface (embedded part)

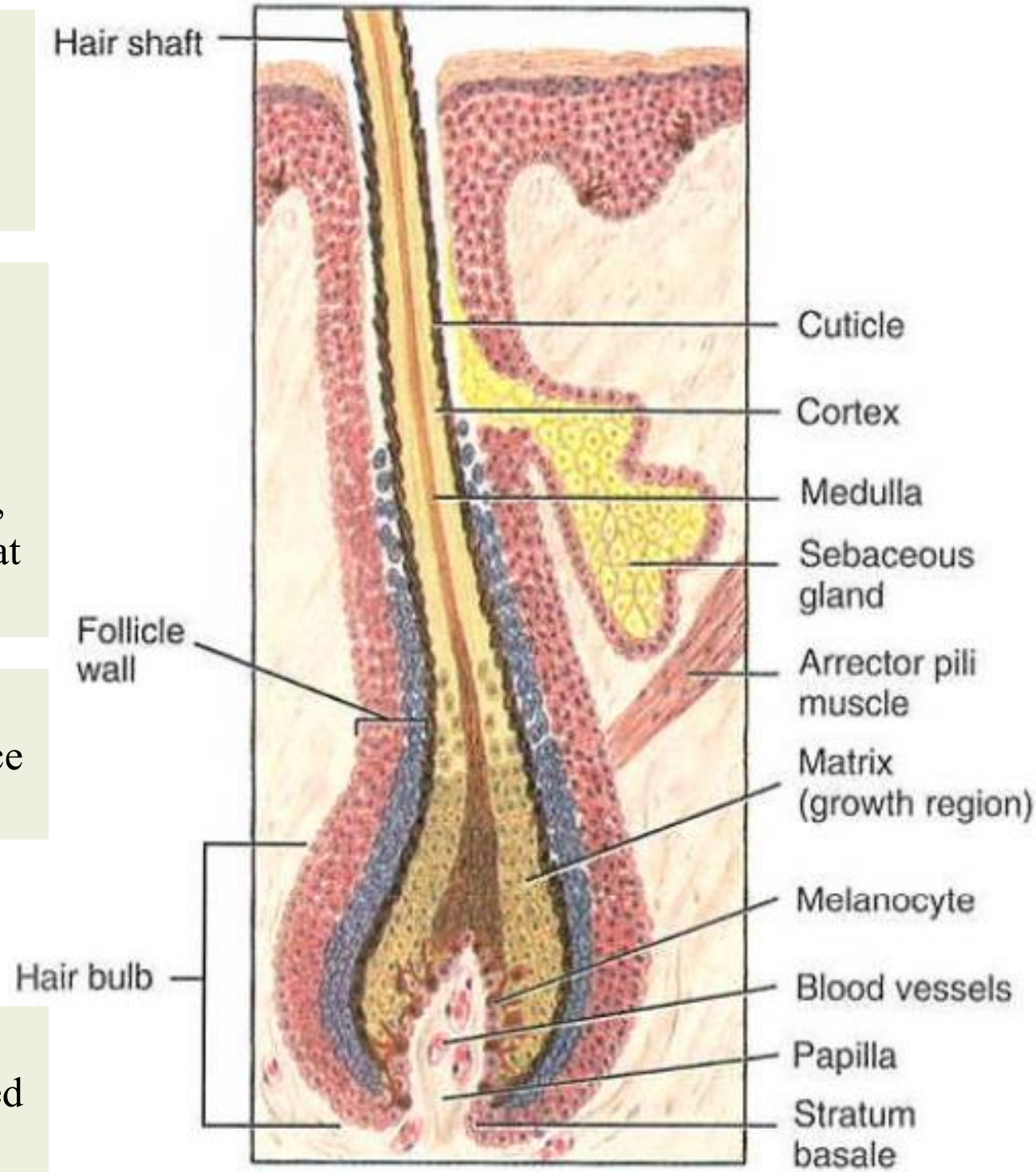

Dr. Heba Kalbouneh

Hair follicle is a tube of stratified squamous epithelium, invaginated into the dermis

INNER ROOT SHEATH
Disintegrates at the level of the sebaceous gland

OUTER ROOT SHEATH
- Is continuous with the epidermis
- It does not take part in hair formation
- Surrounded by a glassy basement membrane
- Basement membrane is surrounded by a connective tissue sheath.

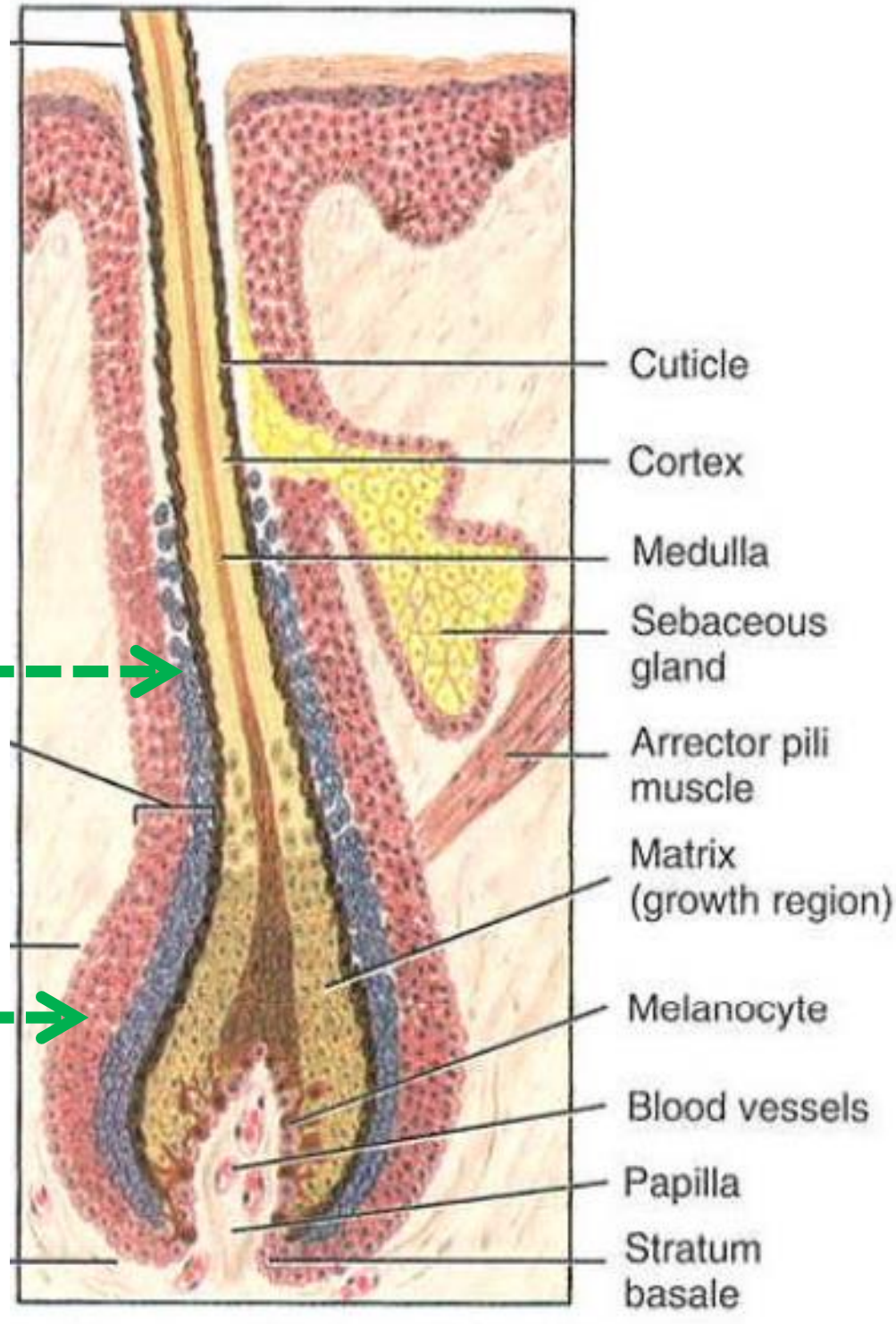

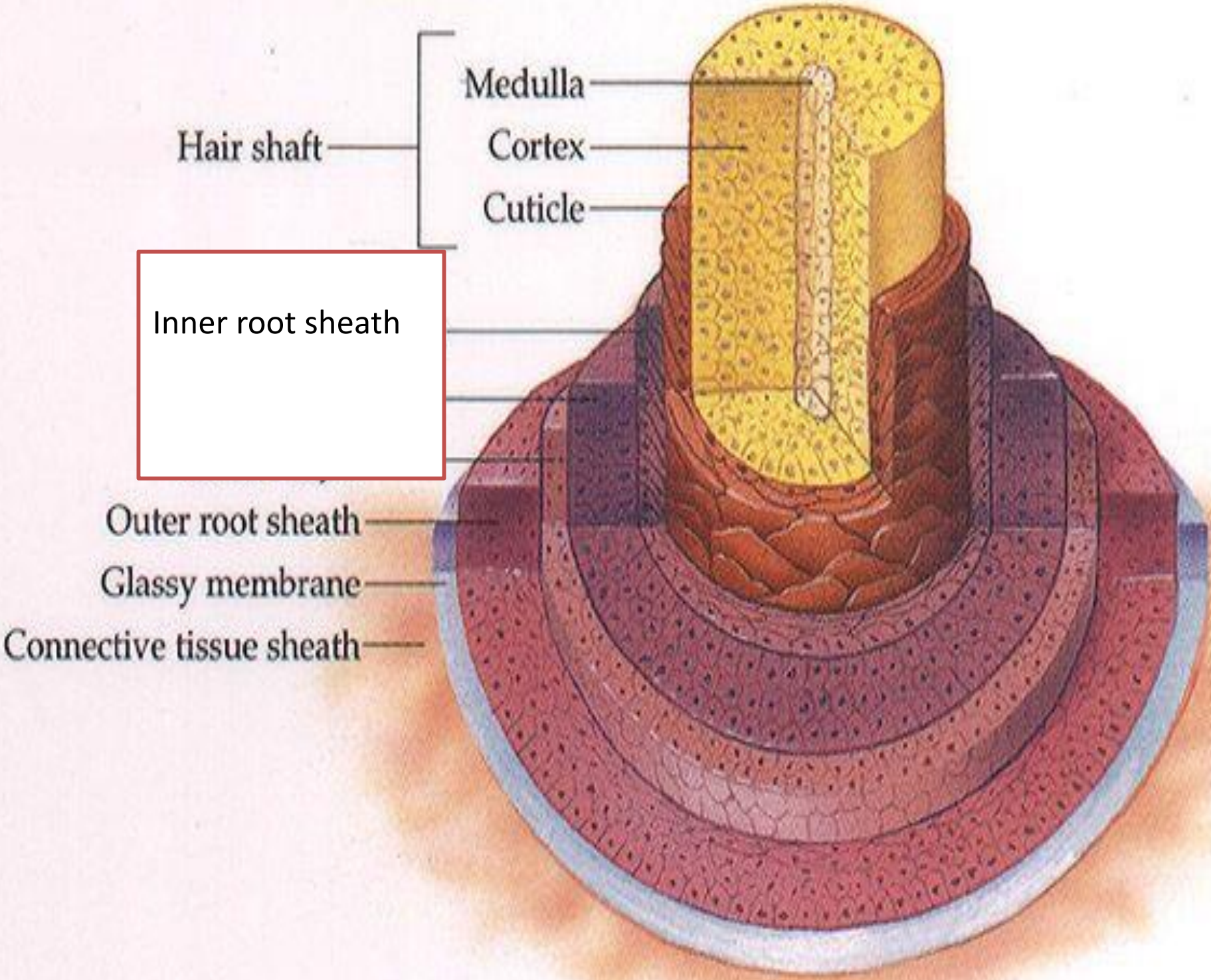
Hair shaft
Medulla
Cortex
Cuticle
Inner root sheath
Outer root sheath
Glassy membrane
Connective tissue sheath

Hair matrix

- Contains the proliferating cells that generate the hair and the internal root sheath

- Located just above the dermal papilla

- Melanocytes located in the matrix produce hair color.

The cells in the hair matrix proliferate and move upwards, gradually becoming keratinized to produce the hair.

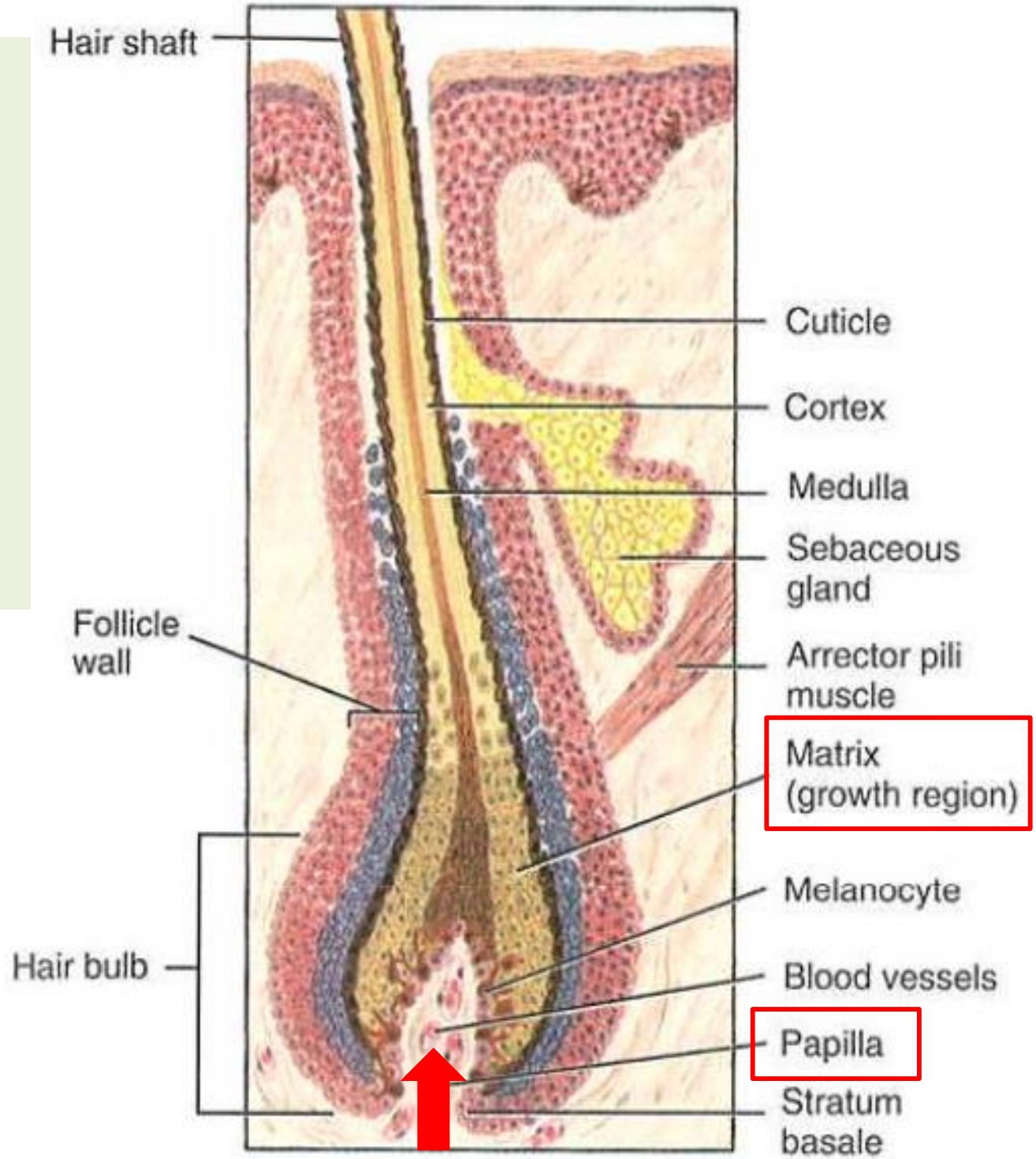

Sebaceous glands

- secrete an oily or waxy matter, called **sebum**, to lubricate and waterproof the skin and hair

- Secrete by holocrine mode of secretion

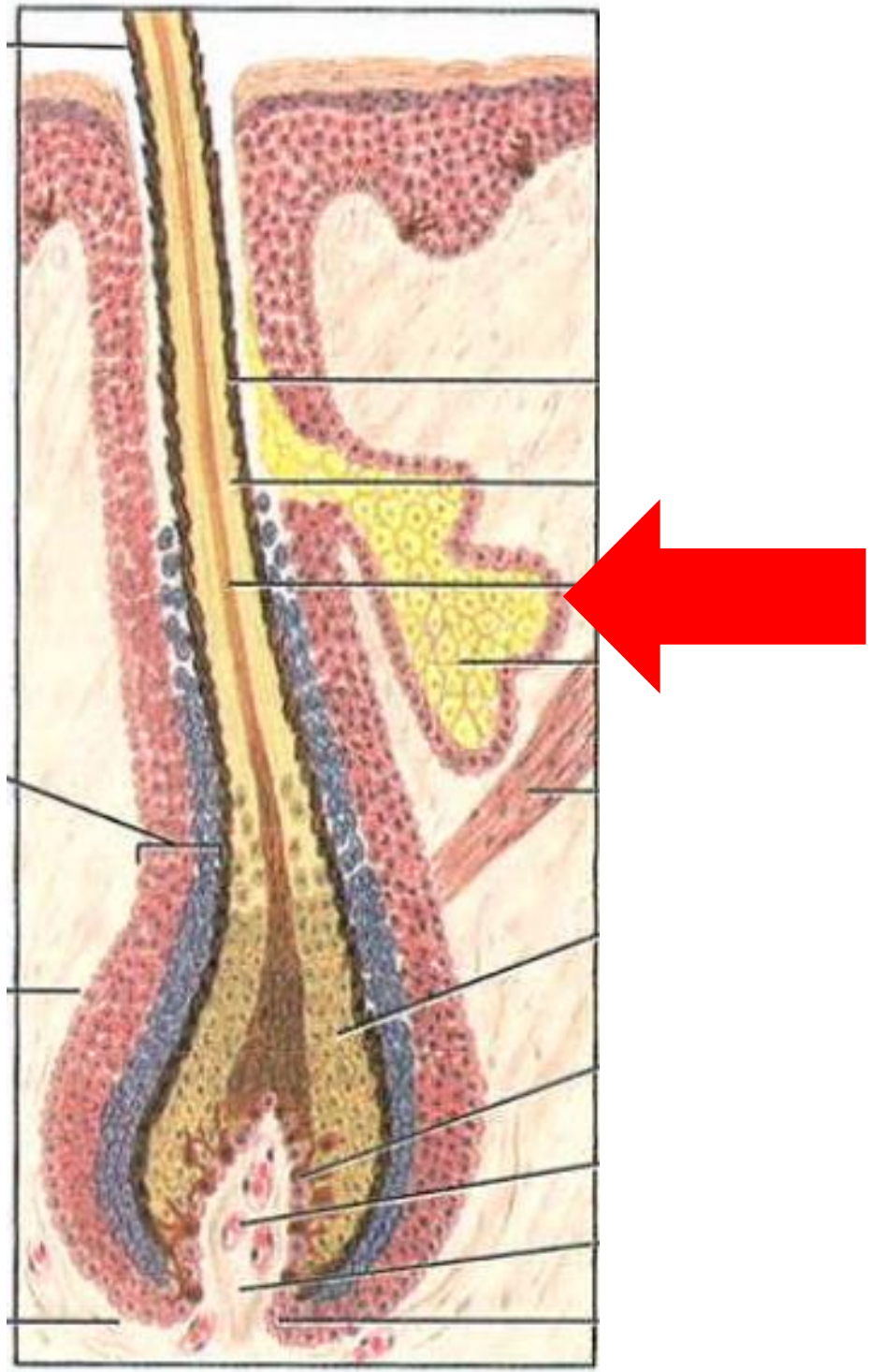

Dr. Heba Kalbouneh

Dr. Heba Kalbouneh

A **comedo** is a clogged hair follicle (pore) in the skin. Keratin combines with oil to block the follicle

Arrector pili muscles are small muscles extend from hair follicles to the dermal papilla

- Contraction of these muscles causes the hairs to stand on end (goose bumps)

- Innervated by the autonomic nervous system (sympathetic)

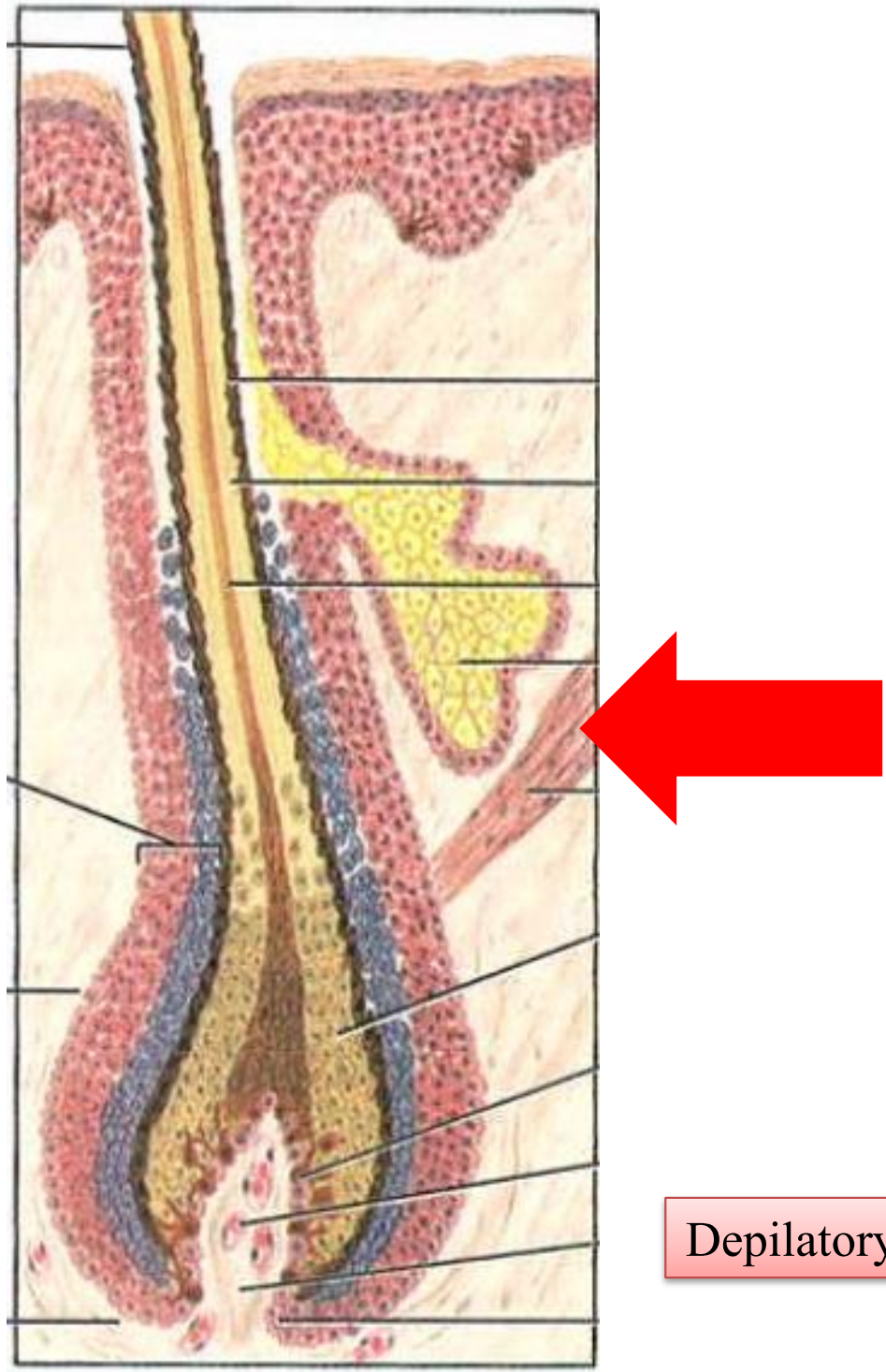

Depilatory

Dr. Heba Kalbouneh

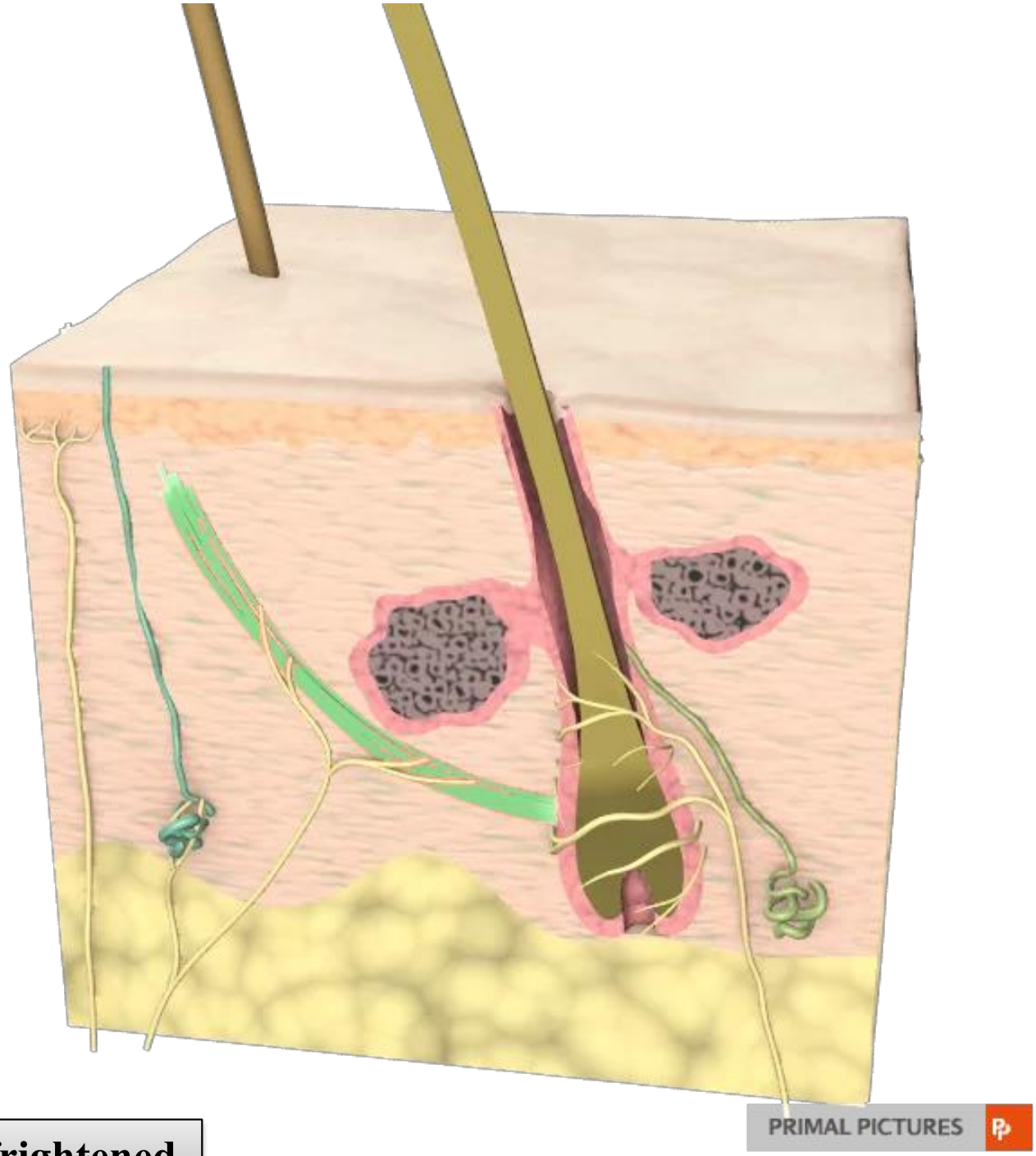

Pulls hairs upright when cold or frightened

Structure of the hair shaft

Medulla: large vacuolated and moderately keratinized cells

Cortex: heavily keratinized and densely packed cells

Cuticle: thin layer heavily keratinized squamous cells covering the cortex

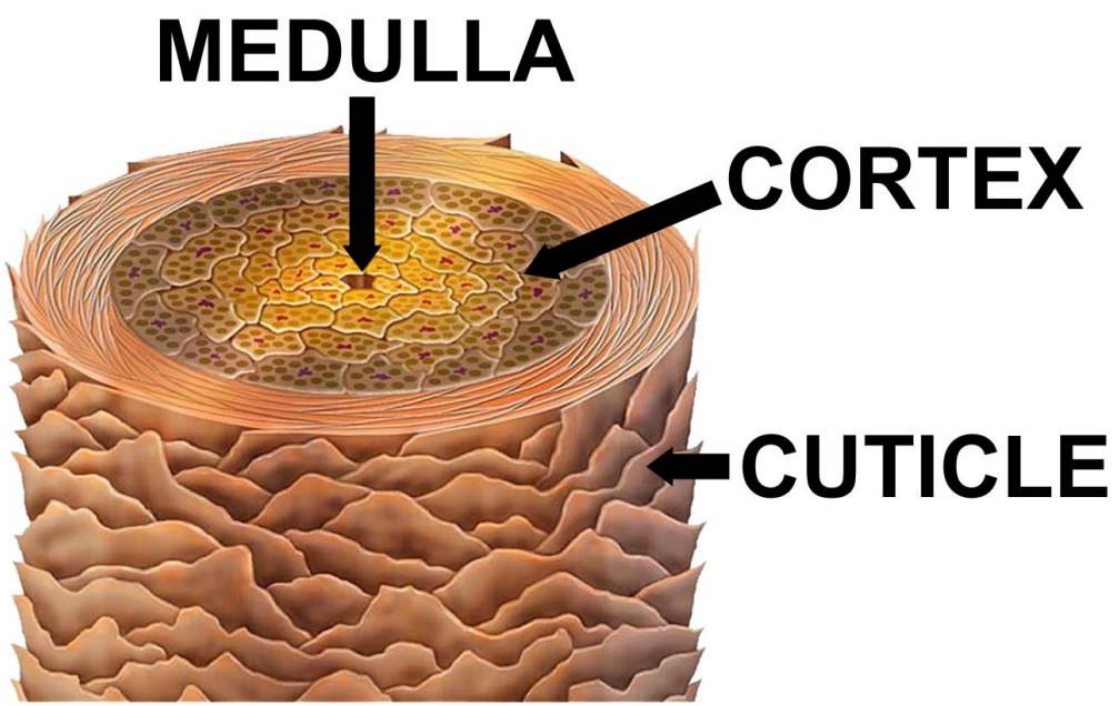

Hairs grow discontinuously, with periods of growth followed by periods of rest and this growth does not occur synchronously in all regions of the body or even in the same area

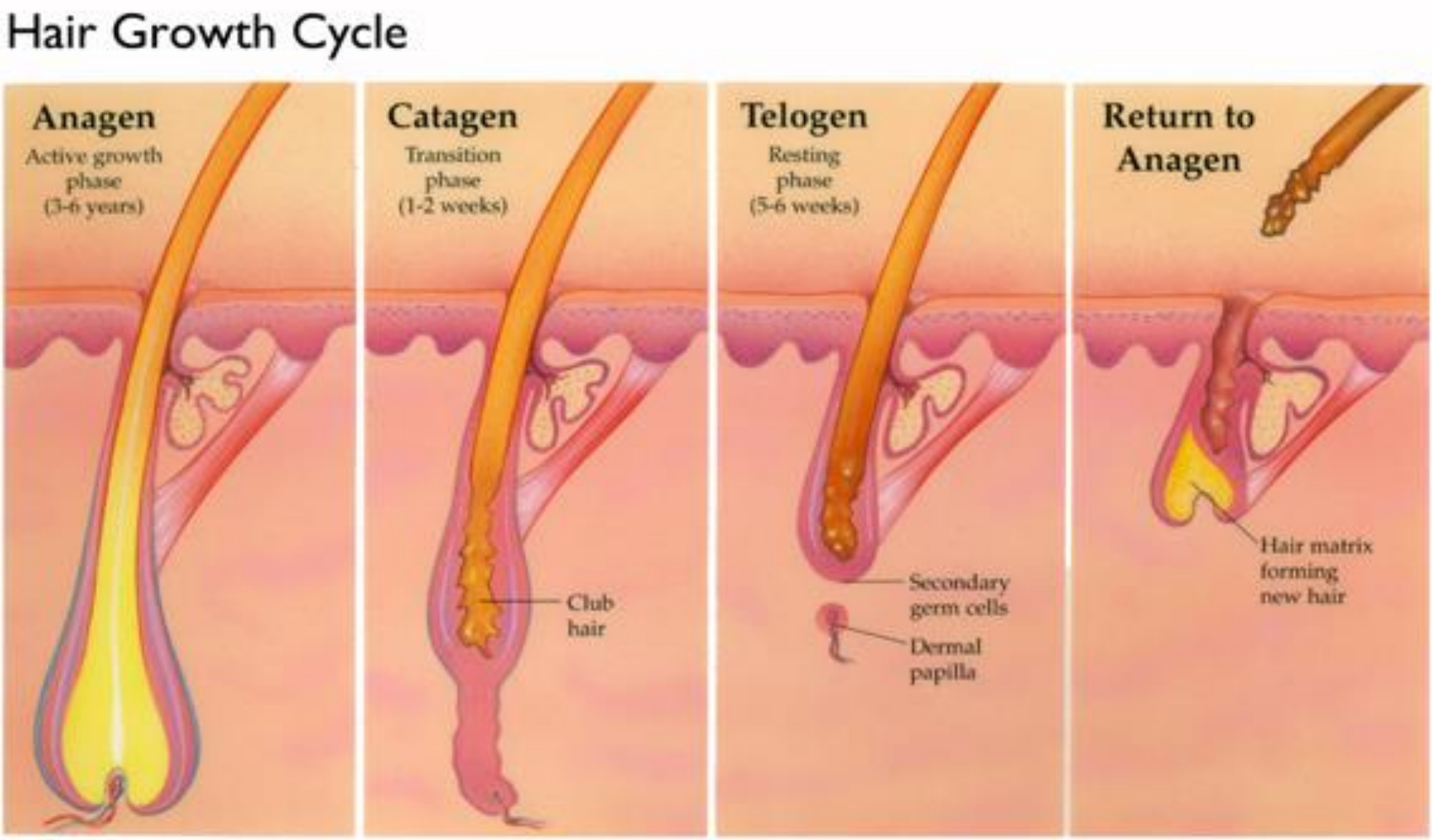

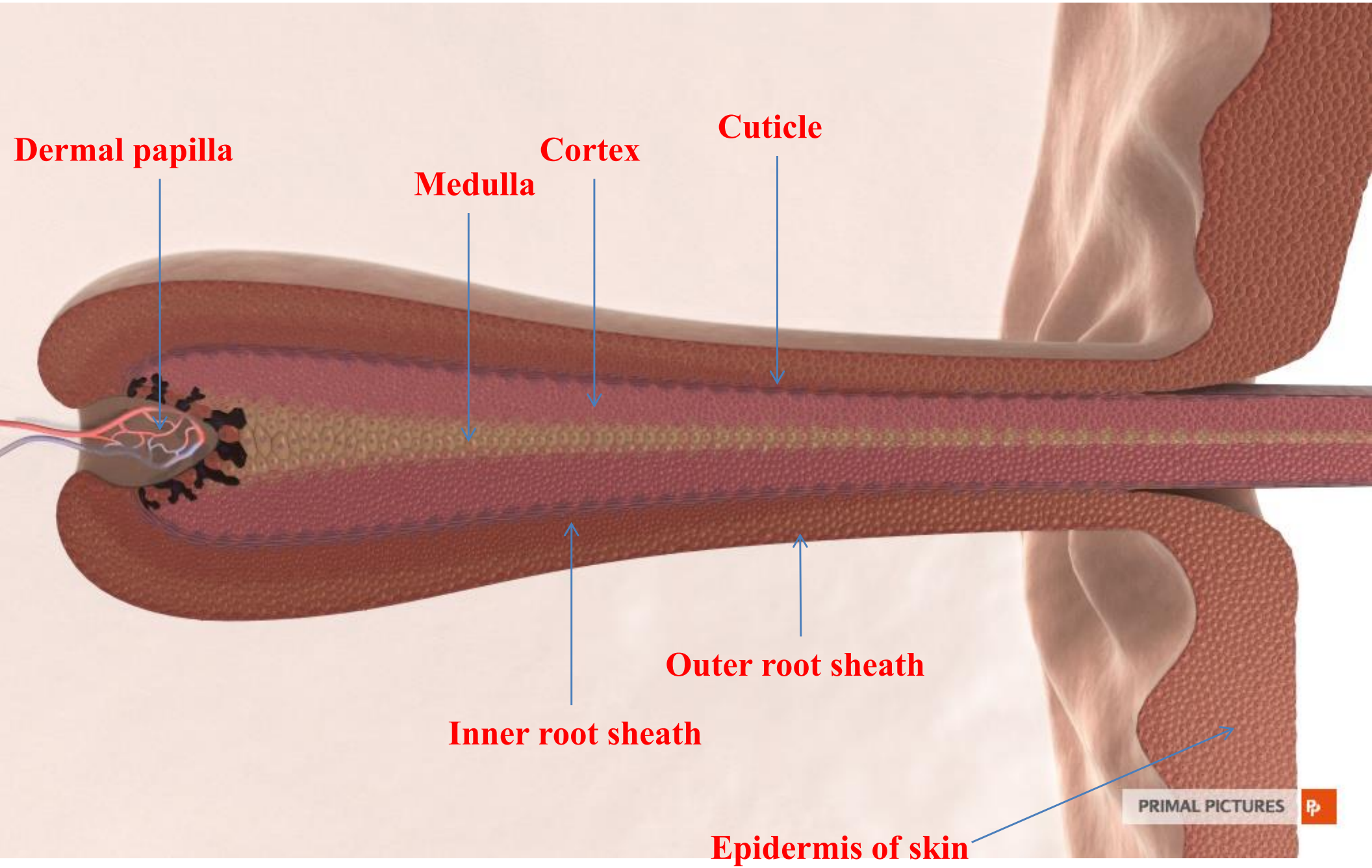

Dr. Heba Kalbouneh

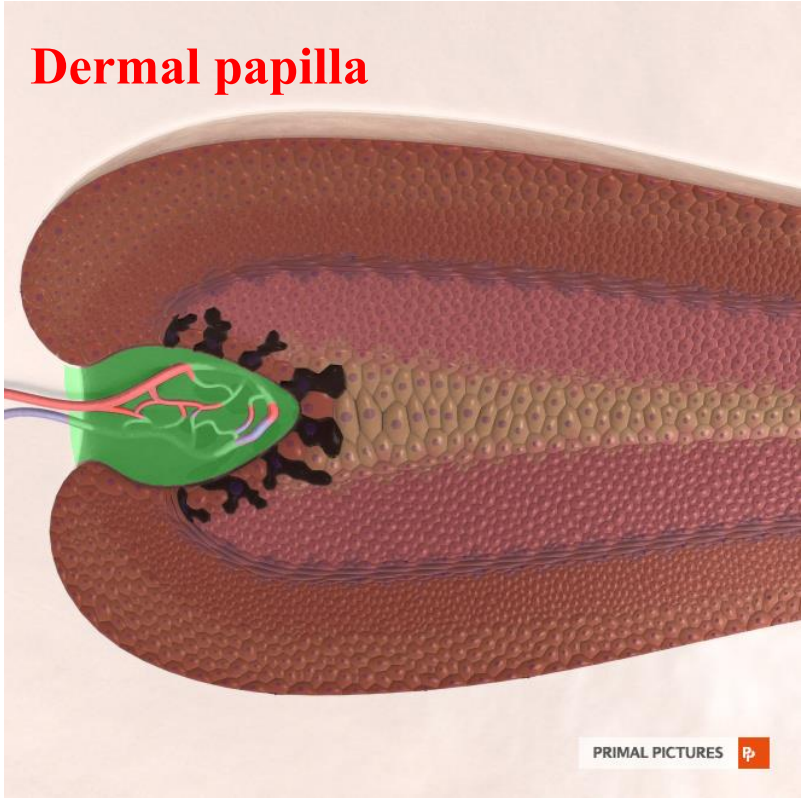

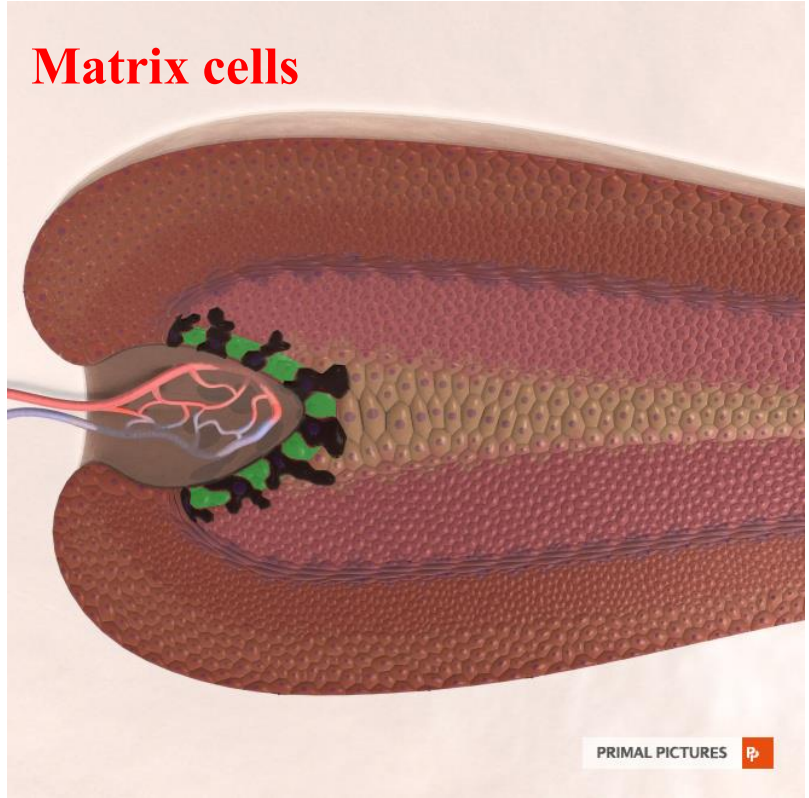

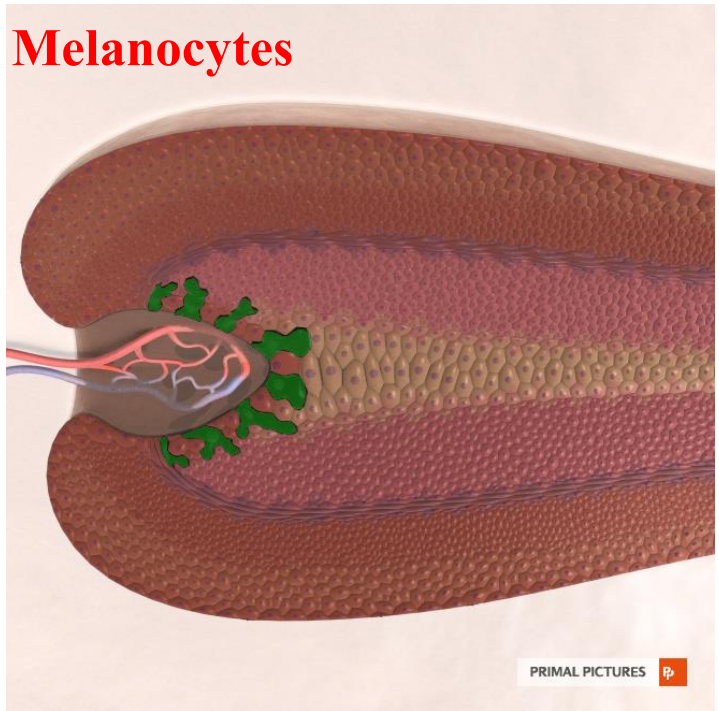

Dr. Heba Kalbouneh

Sweat glands

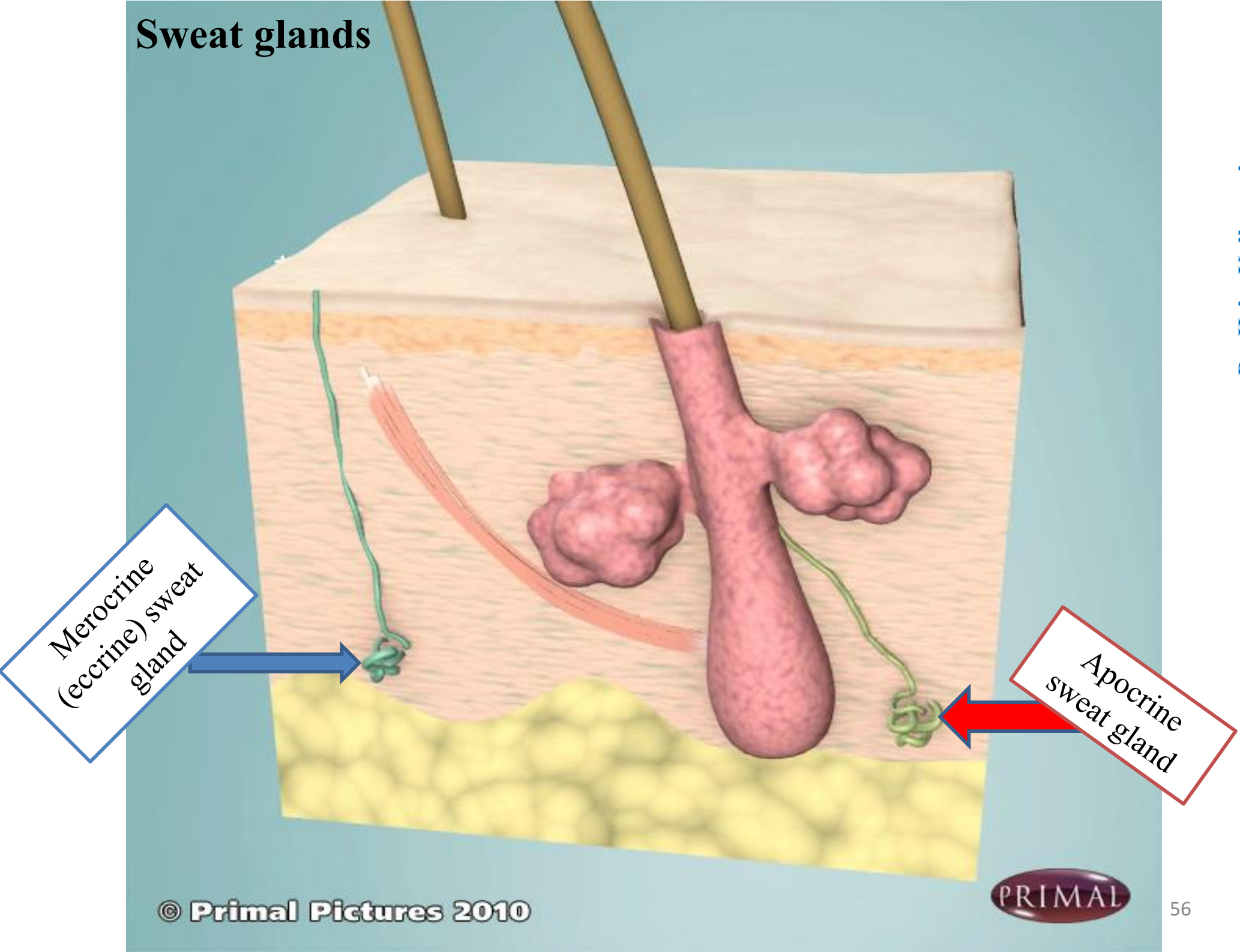

Dr. Heba Kalbouneh

Sweat Glands

Eccrine sweat gland

- Merocrine secretion
- Empty directly onto skin surface
- Location: most all over body (esp. abundant on palms & soles: ~ 500/cm^2)
- Clear, watery secretion (99% H_2O; rest NaCl + some waste products

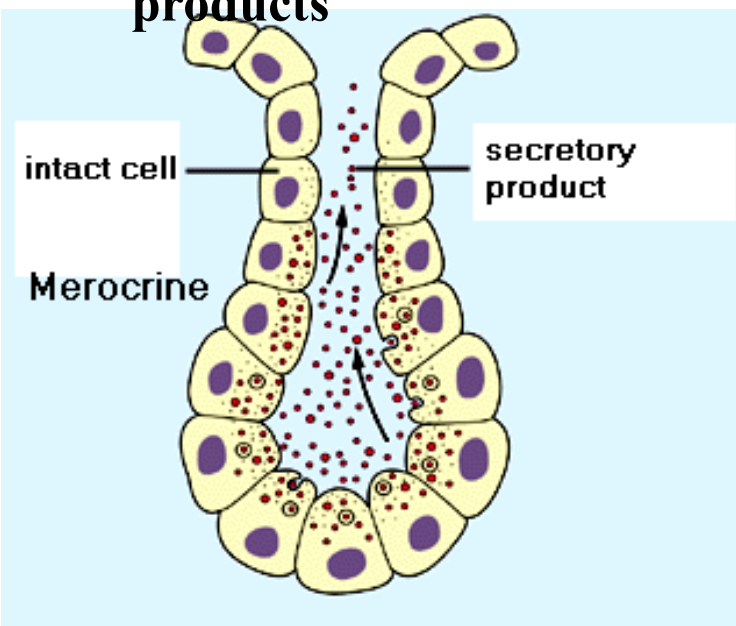

Apocrine sweat gland

- Empty into hair follicle
- Location: armpits, groin, nipples
- Viscous, cloudy secretion → good nutrient source for bacteria (odor !!)
- Secretion may contain Pheromones
- Secretion begins at puberty and is stimulated during emotional distress

Scent glands

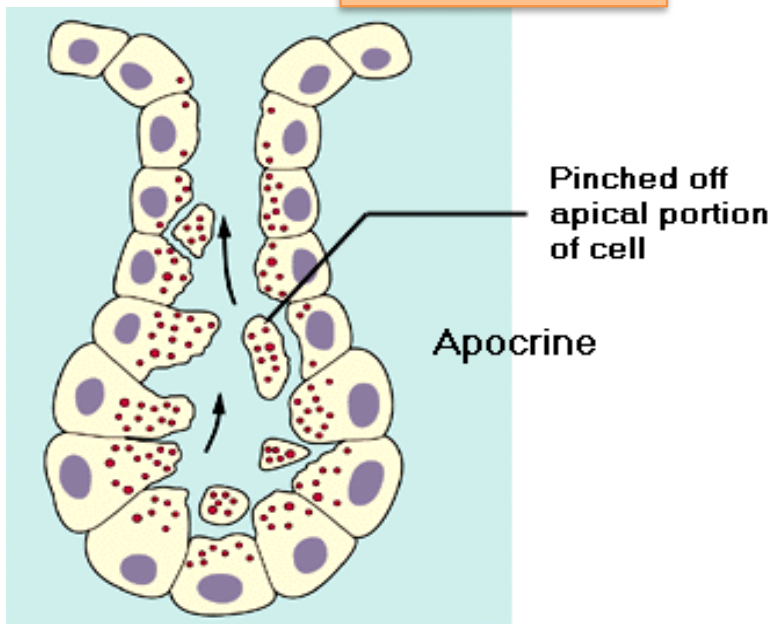

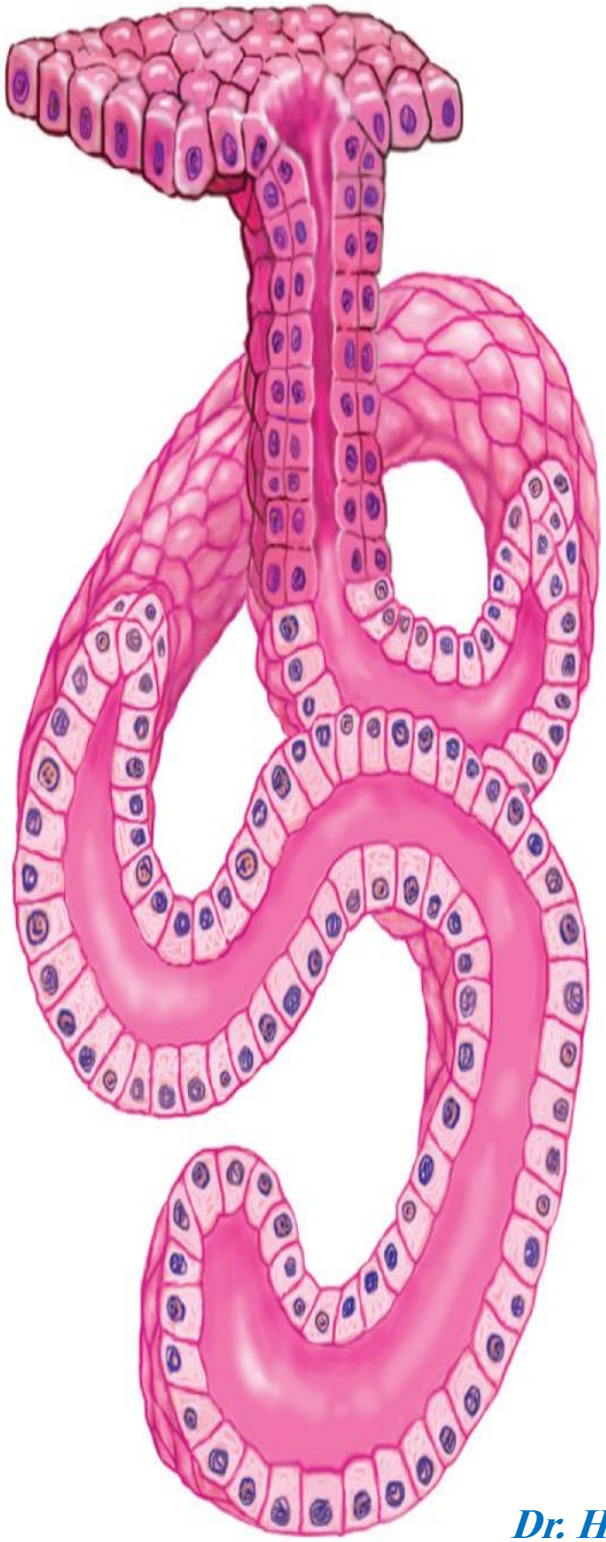

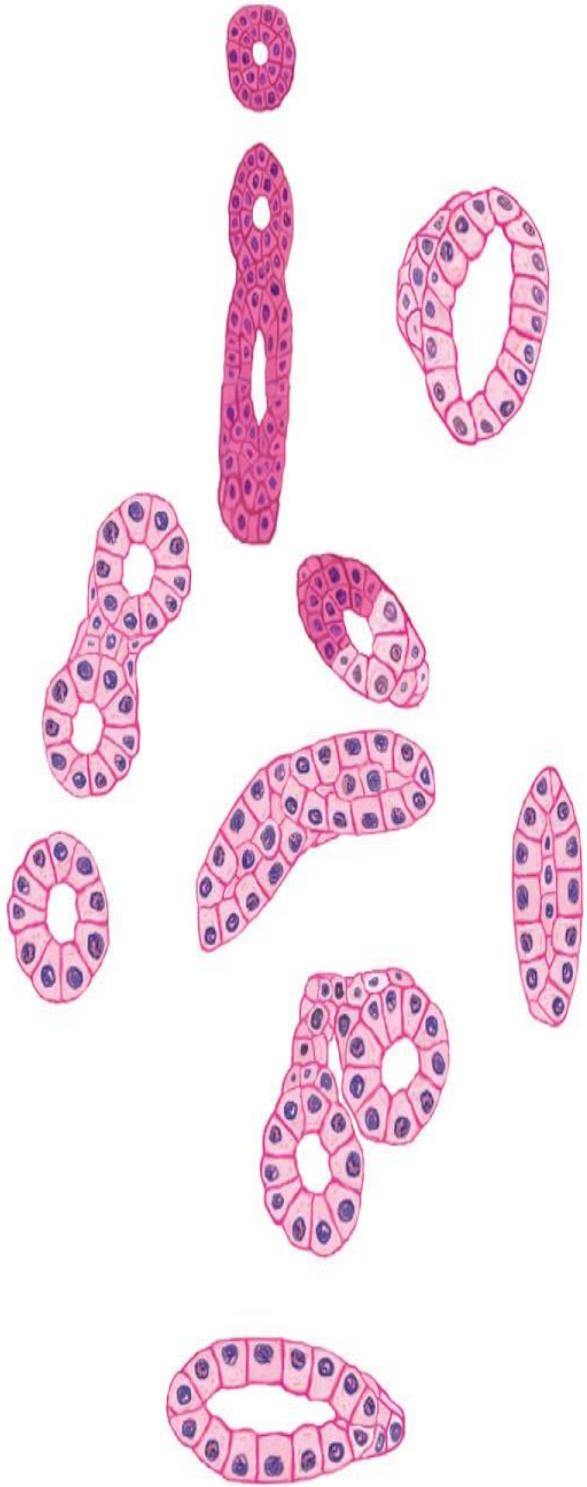

Dr. Heba Kalbouneh

Apocrine sweat glands

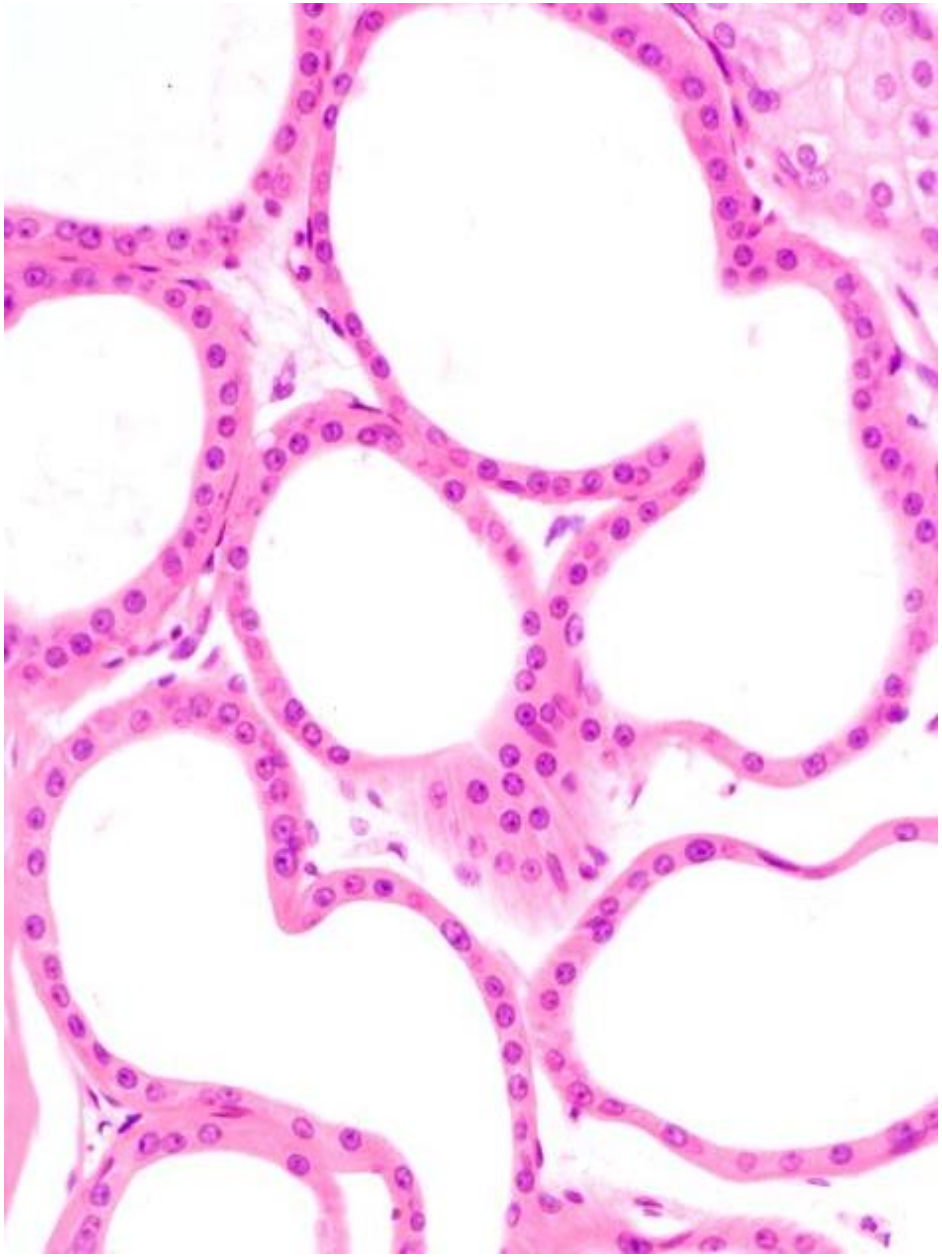

Eccrine (merocrine) sweat glands

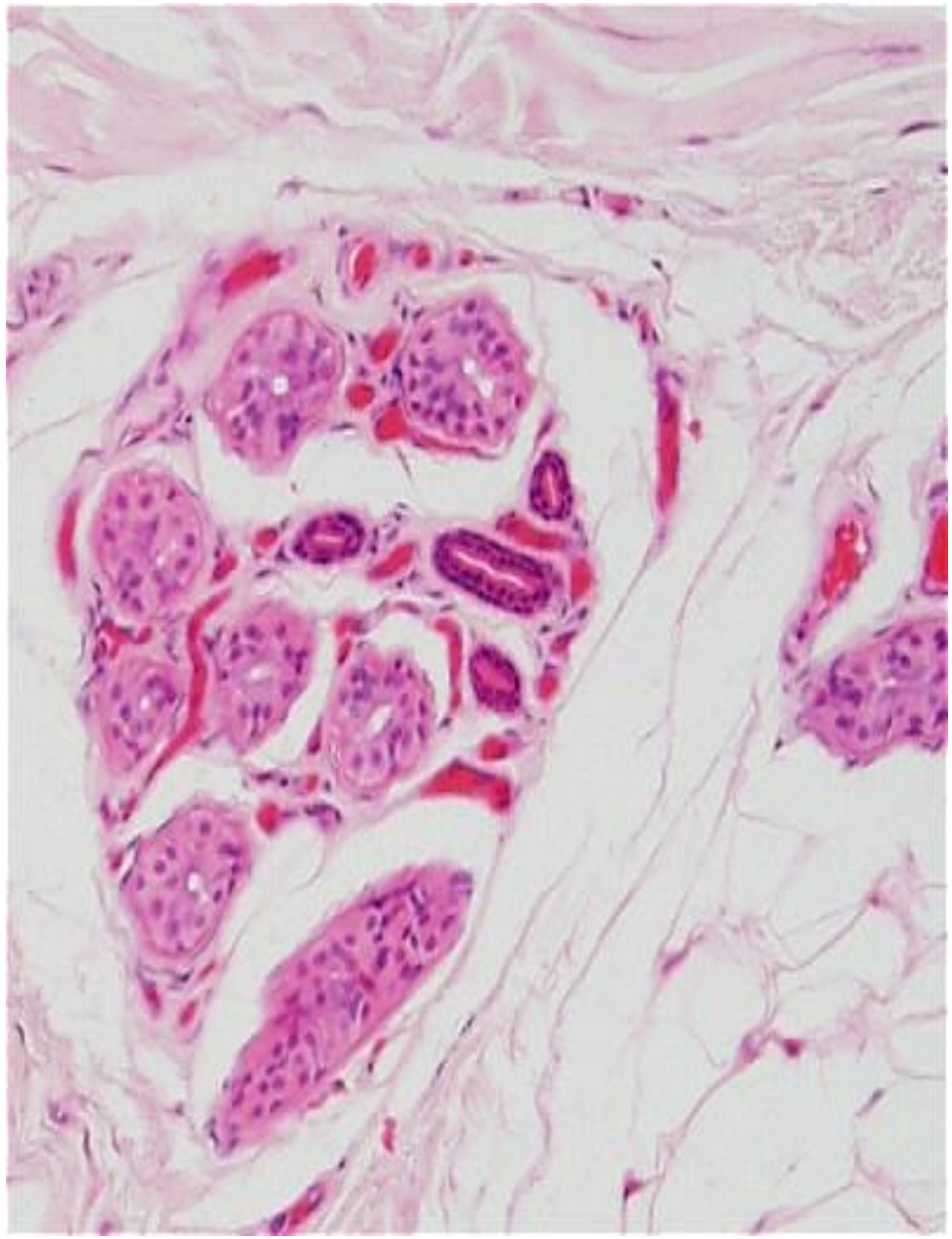

Nails

Hard plates of keratin on the dorsal surface of each distal phalanx
Lack of pigment makes them colorless

Nail parts

1. Free edge: the part you cut
2. Body: pink part
3. Lunula: white semicircle area
4. Eponychium: proximal nail fold (cuticle)
5. Hyponychium: under the free edge where dirt accumulates
6. Nail bed: directly under the pink part
7. Nail matrix: growth

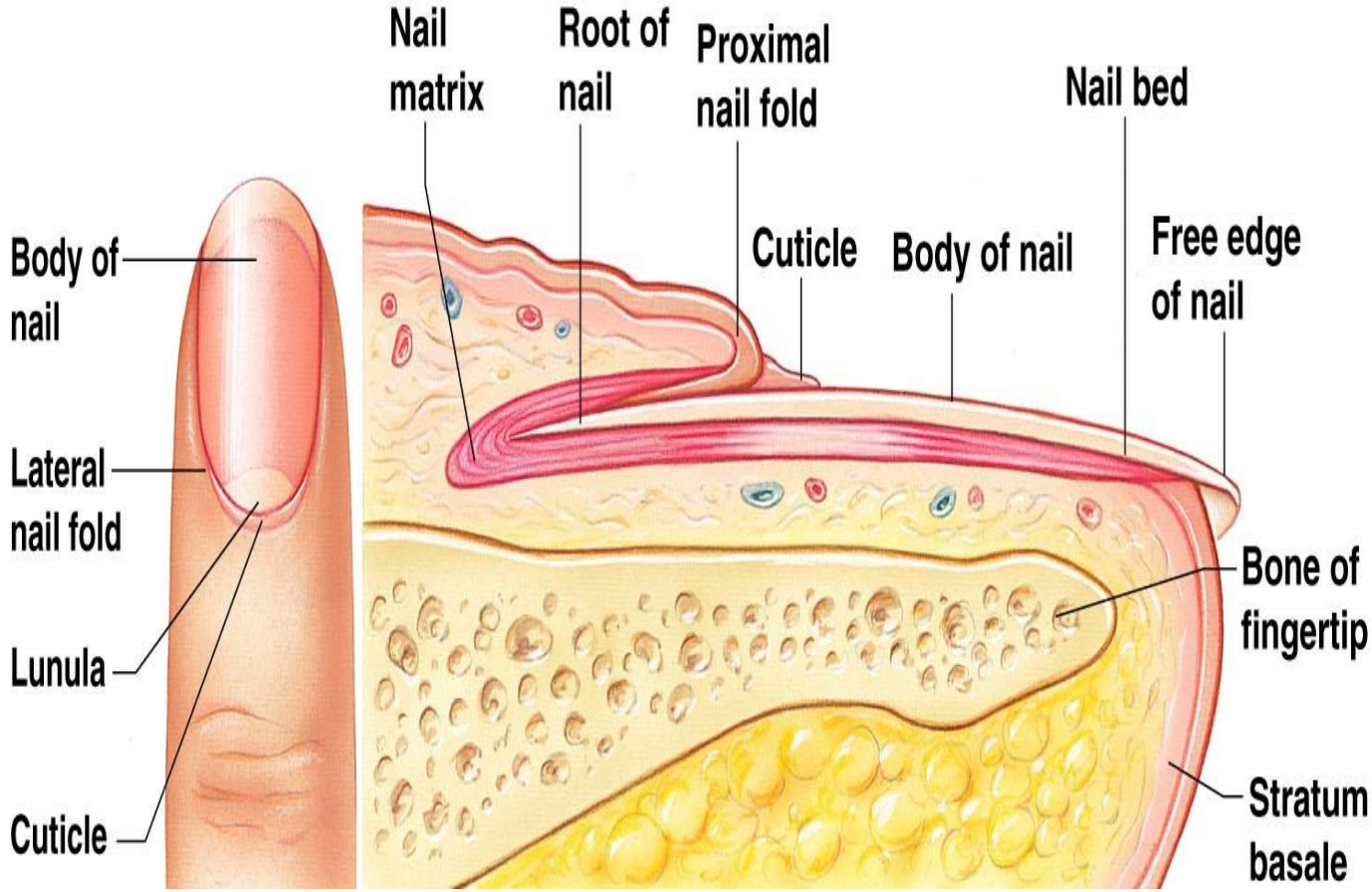

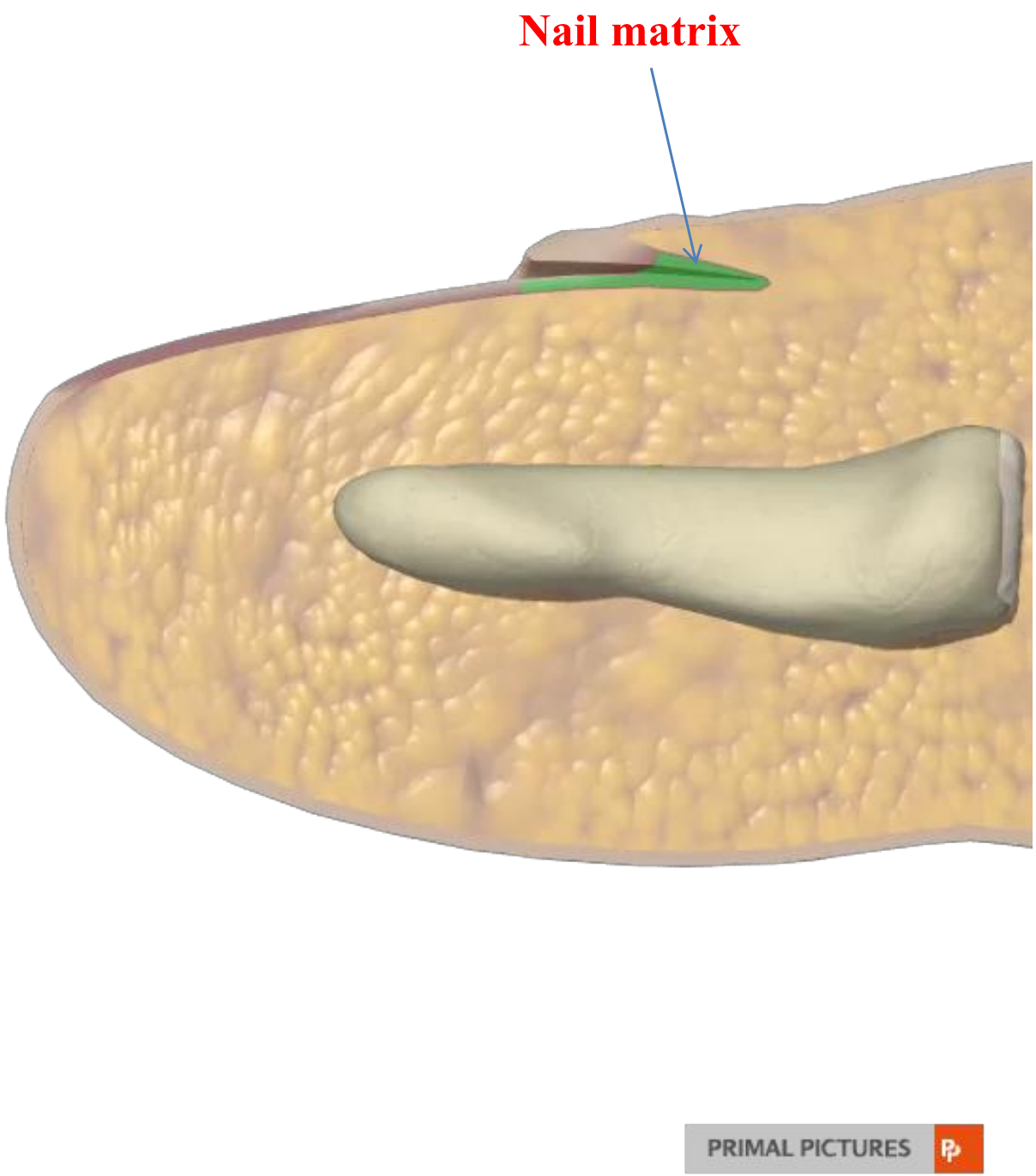

Dr. Heba Kalbouneh

Practical sections for the exam

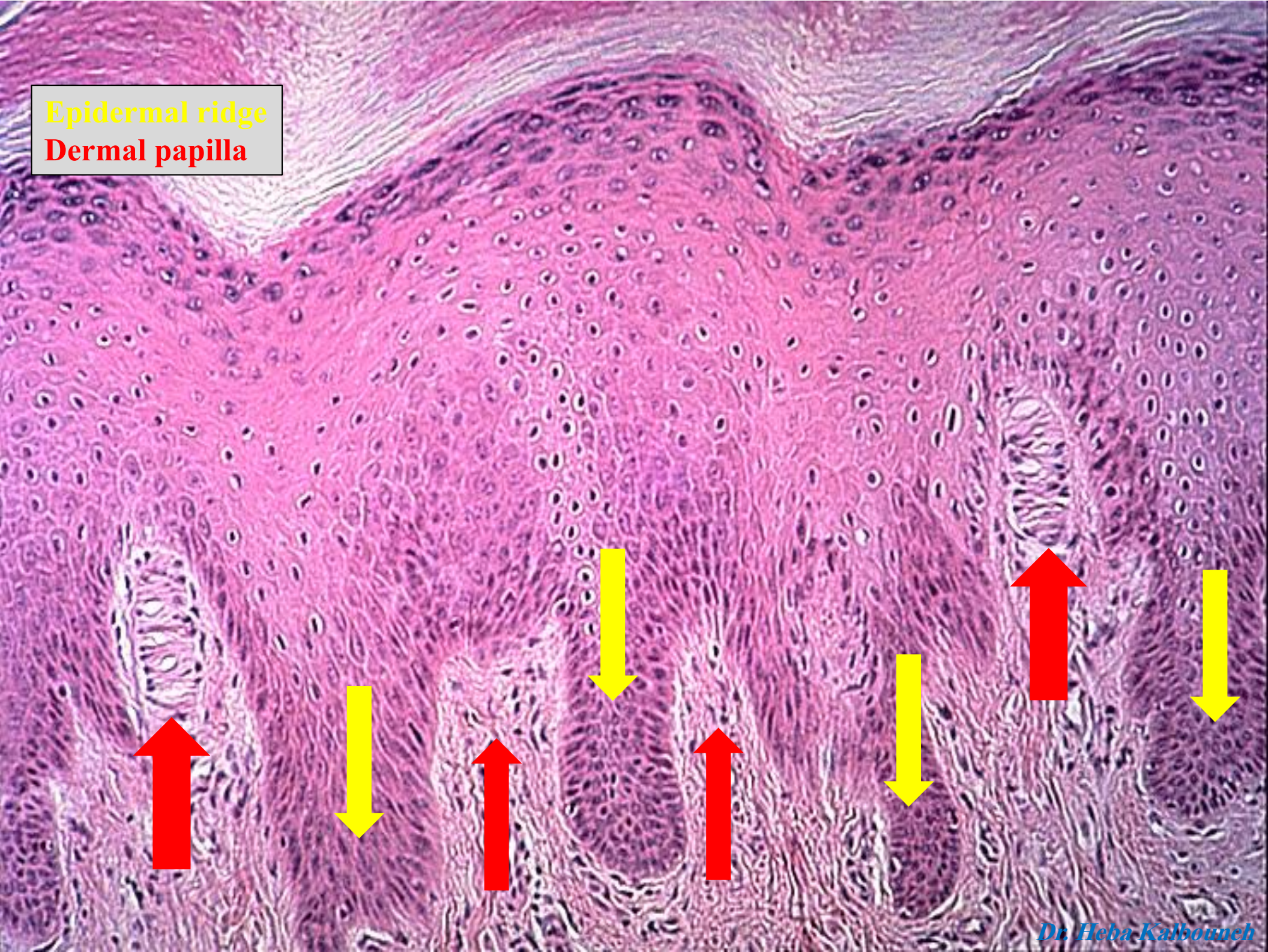
Epidermal ridge
Dermal papilla
Dr. Heba Kalbouneh

Dr. Heba Kalbouneh

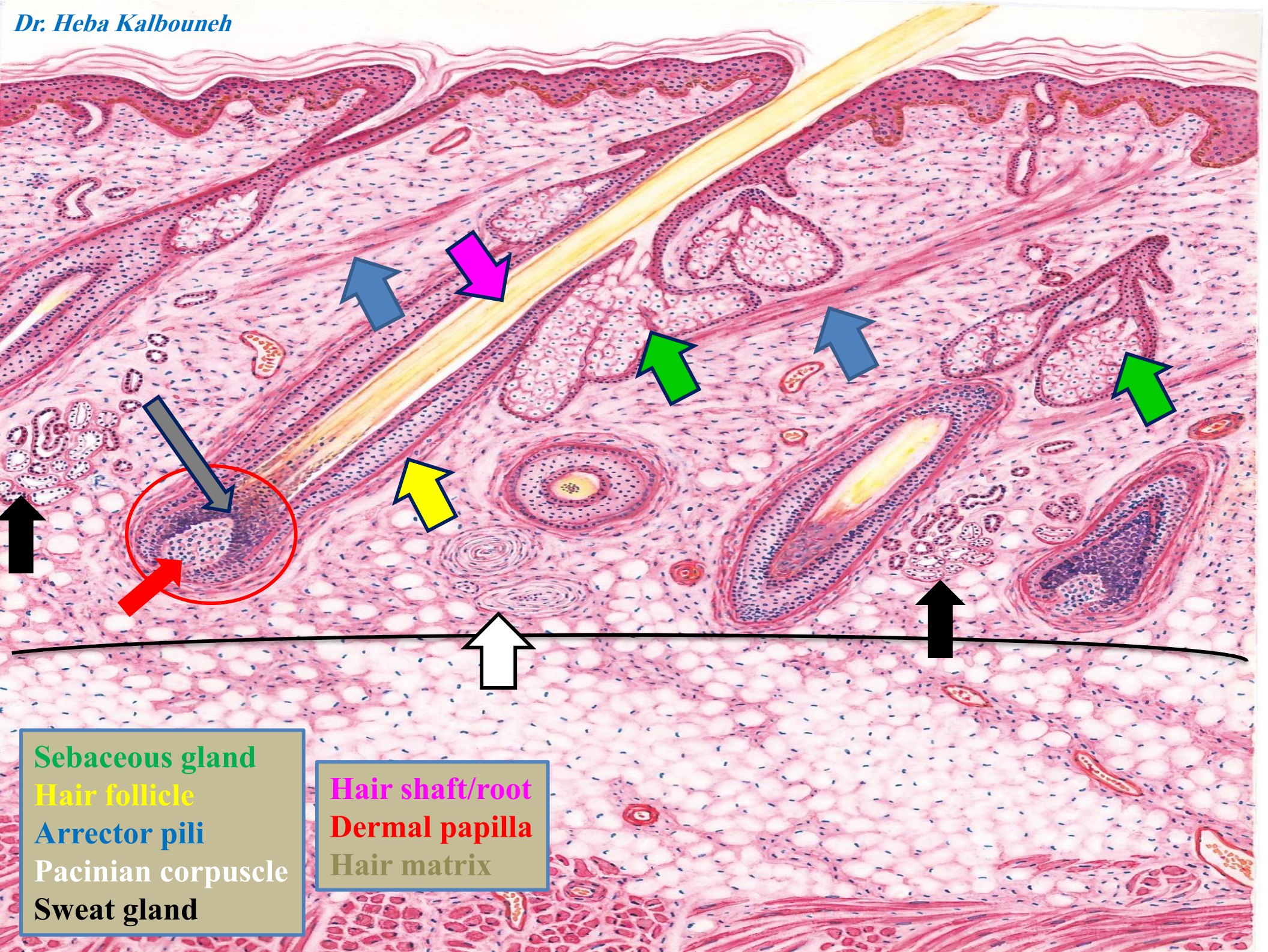

Meissner corpuscle

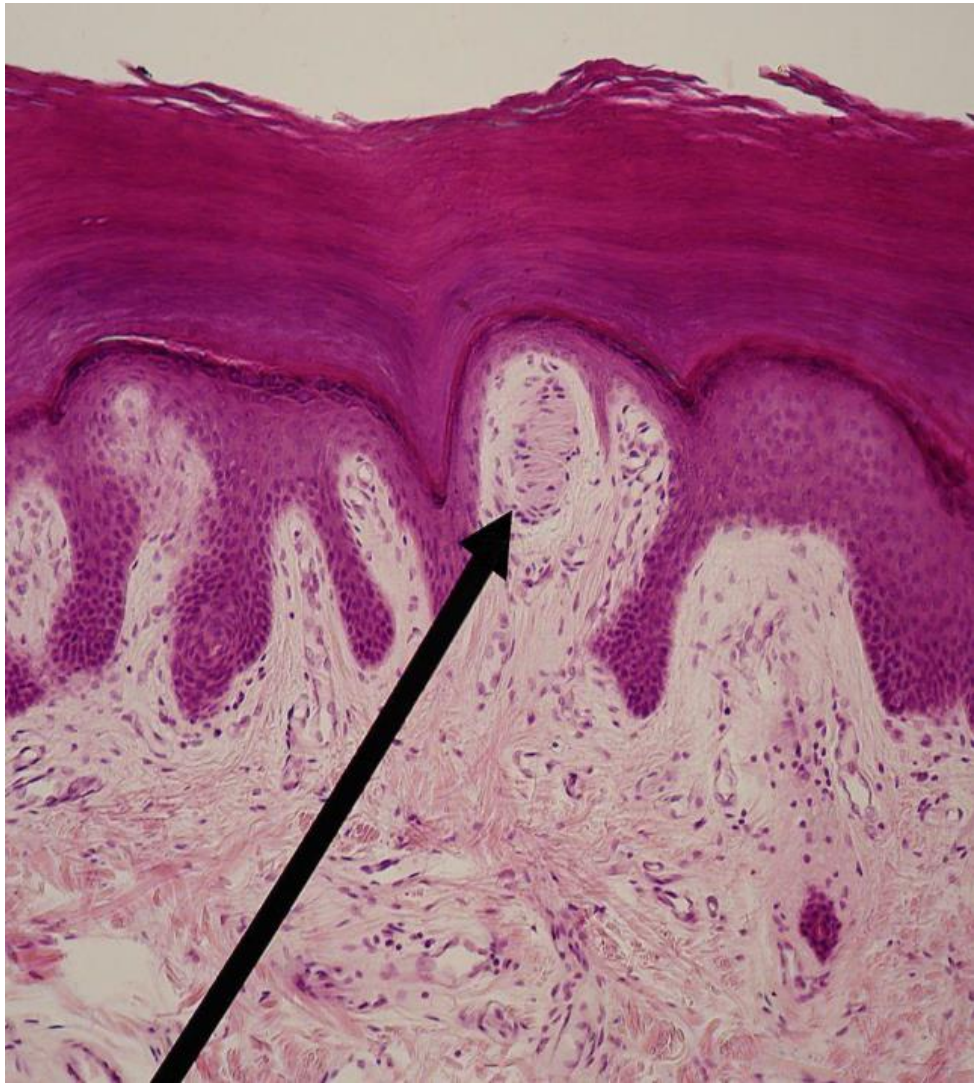

Pacinian corpuscles

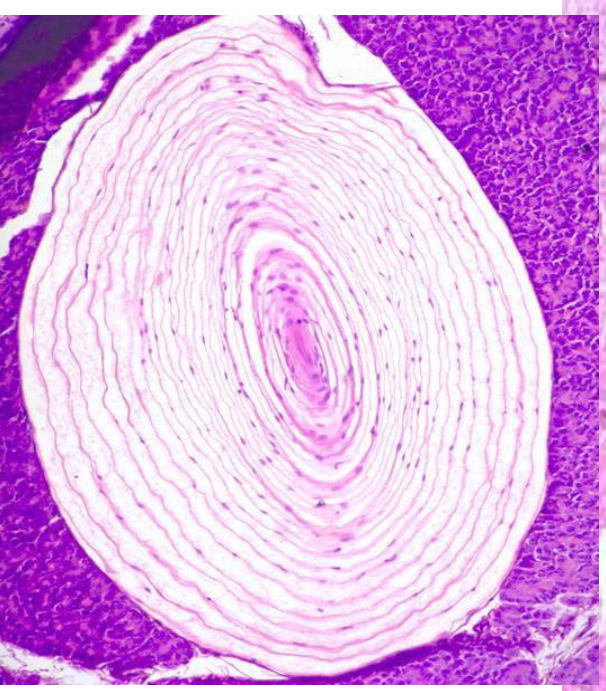

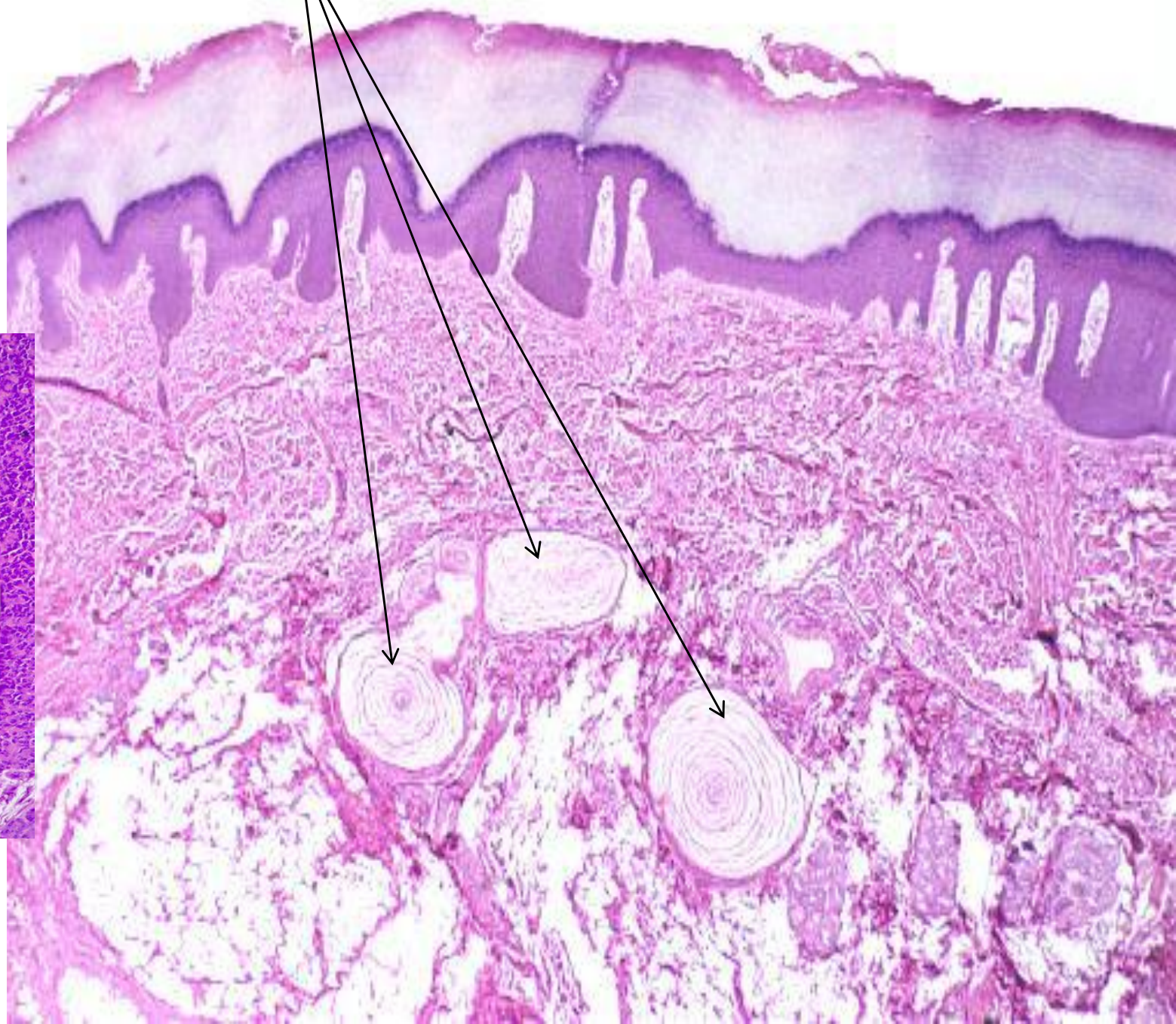

Dr. Heba Kalbouneh

Dr. Heba Kalbouneh

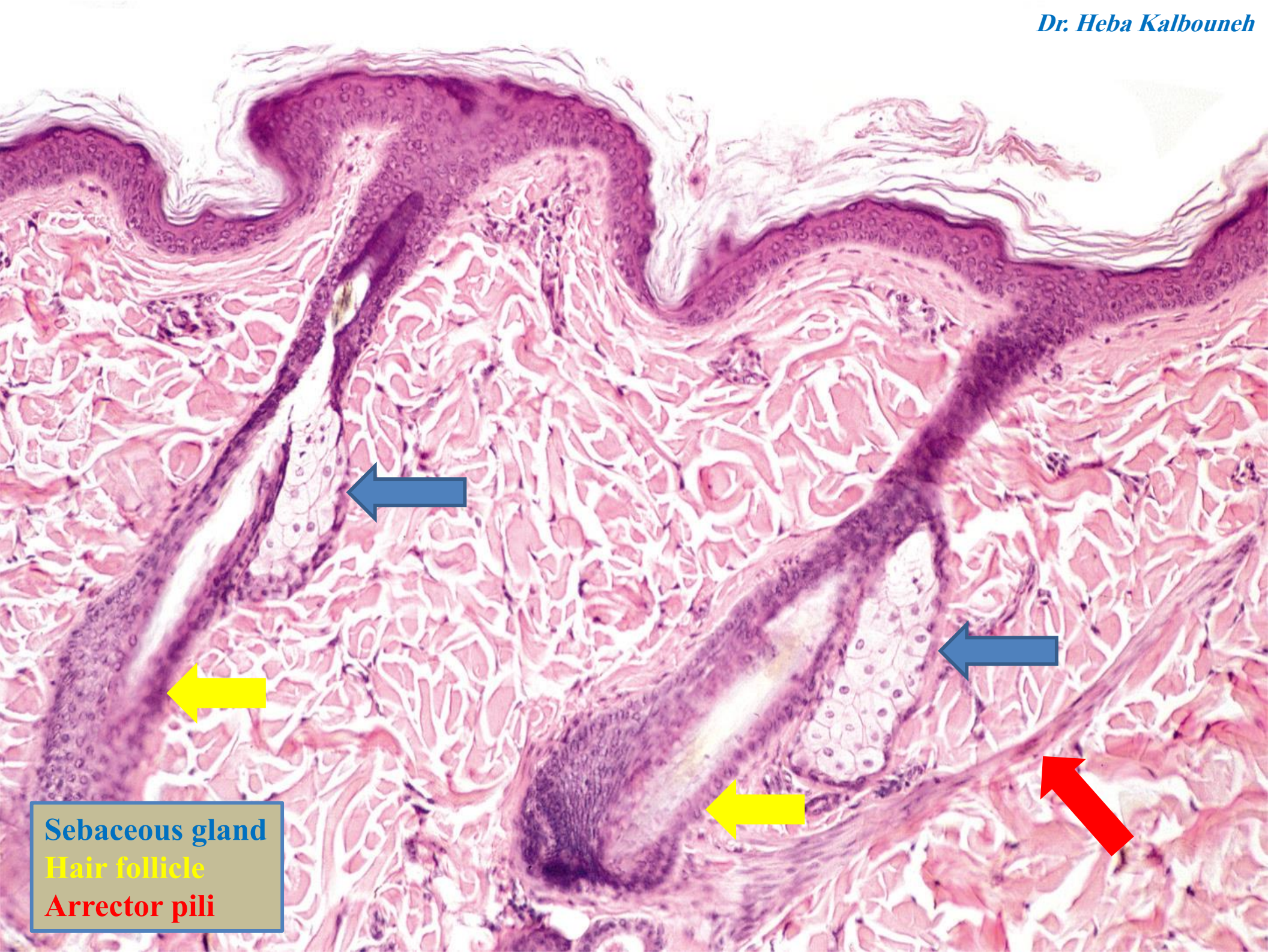

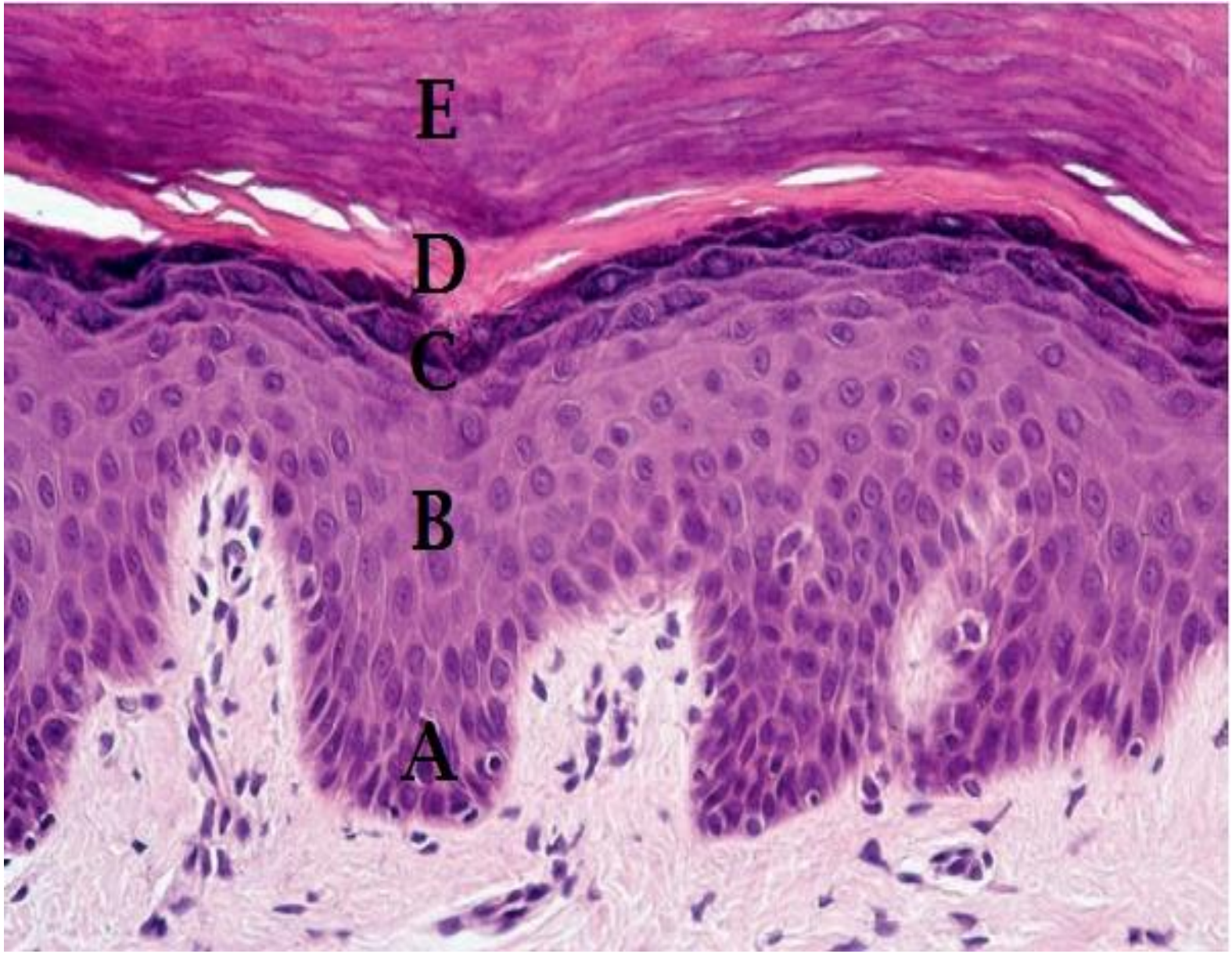
E
D
C
B
A

THICK OR THIN SKIN ????