
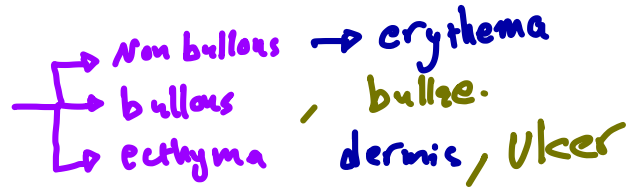


Impetigo

- honey/golden crust
 - staph. aure. , β -hemolytic. strpt.
 - pus
 - dx: clinical
 - epiderm.
 - mupirocin
- culture, gram stain



Folliculitis

- S. aureus , P. aeruginosa
 - pus
 - erythema
 - ترؤز لعللہ
 - dx: clinical , culture
- نقد رنوی

Skin abscess

- staph. MRSA , \downarrow strept
- dermis and deeper layers.

- dx: clinical , culture
- herpetic whitlow
- ruptured epiderm. cyst.

Treat: Ins. and drain.

Antibiotic : \rightarrow MASA

systemic infection , cellulitis , Multiple abscess , facial , Immunocompromised , cavernous

ersipelas

- β -hemolytic strep (group A strep)
- \uparrow \downarrow \downarrow
- acute on set with systemic manifest.
- super. dermis
- not purulent
- well demarcated

- erythema, edema, worm with
- superfic. bullae
- systemic / Unilateral / lower extremity

dx: clinical

Treat: culture before antibiotic:

1. history of recurrent infection, Multiple.
2. failure first antibiotic.
3. extreme ages.
4. systemic signs
5. severe local infec.
6. co morbidities, tumor, diabetic, Immune def.

specialway

cellulitis

- β -hemolytic strep. / staph. aure (MRSA)
- with abscess) most common.

- \uparrow \downarrow \downarrow
- Indolent course
- deep dermis ^{IV: cephalosporin}
- purulent or not _{Lo cephalosporin}
- not well demarc.

skin trauma
skin inflammation (eczema)
skin break
skin infection
Immune suppression
obesity
edema

Necrotising fasciitis

- systemic signs, severe, morbidity

- diagnosis: skin can seem to be not affected.

- Anaerobes: bacteroids, clostridium, peptostreptoc.

aerobacter: E. coli, enterobacter, klebsiella, proteus streptococ.

- lower extremity
- systemic toxicity

acute, erythema, edema, severe pain

fever, crepitus, bullae, necrosis, ecchymosis.

dx: surgical

Intraoperative specimens.

Radiographic [gas].



- four gangrene

- GI, Vrethral

- Abdominal wall, gluteal muscles.

- GAS ↓ staph

- 1/2 no portal of entry

- hematogenous translocation
انتقال الدم

- M protein [M_{1,3} strept. toxic shock synd?]
50%

predisposing factors:

1. Trauma

2 surgery, Mucosal breach

3. Immuno suppre. [diabets]

Tr: debridement, antibiotic, hemodynamic supp.

clostridial myonecrosis

- gas gangrene



- endospores

→ Trauma → most common cause
C. perfringens most = bacteria.

→ ①, these toxins → shock → Mortality

dx: gas, crepitus, systemic pain, Radiographic, blood culture.

Treat: debridement



antibiotic, supportive,

- tetanus vaccine

- hyperbaric O₂

bacteremia
Intravascular
hemolytic } → shock

Pyomyositis

Trauma فجوة

- purulent, abscess, hematogenous فبره

- Immuno supp., Trauma, Injection drug use, ^{concomitant} Infection, Malnutrition.

- Staph. aureus.

→ Temperate
→ Topical

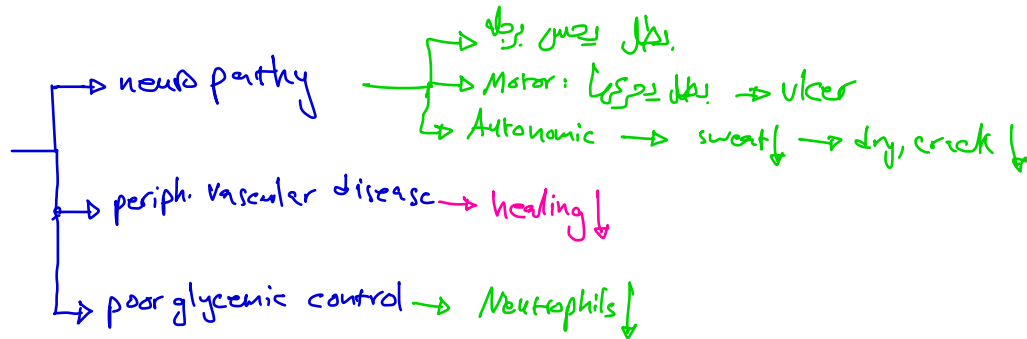
- fever, pain,

dx: Radiograph, culture
- stage 1 can be treated by antibiotic

cramping single muscle group.

stage
→ 1 crampy
→ 2 fever, tenderness, edema
→ 3 systemic, fluctuant.

diabetic foot infection



naive antibiotic →
 - superficial diabetic f. → G^+ car.
 - Deep, chronic → polymicro.
 - potential → anaerobes
 extensive M. Flan., Metastor
 necrosis
 Bacteroids, strep., clostrid.

signs
 → inflammation manifest.
 → pus

- osteomyelitis

uninfected: No inflam, No pus
 Mild: 2 < , No systemic, skin
 cellulitis, super. f. f.
 Moderate: 2 > , No systemic, lymph., abscess, gangrene, muscle
 severe systemic bone

Treat:
 → debridement, clean, ↓ pressure
 → abs → aspirate abscess, curettage from the ulcer.
 → Antimicrobial → empiric, surgery → فجوة

Viral exanthems

Erythema infectiosum
5th dis.

Roseola infantum
(exanthema subitum)
6th dis.

chickenpox
(varicella)

Virus

parvovirus B19

P.H. herpes 6,7

VZV

Type

1 strand DNA
non-enveloped.

// strand DNA

// strand DNA
enveloped

انتقال

Respi. sec.

R.S

R.S

character

fever, slapped
cheek
rash

high grade fever,
pink rose
rash

fever, itchy
rash

Dx:

IgM, real time
PCR

real time
PCR

IgM, real time
PCR

Tr:

suppurative, self-
limited

suppurative, self-
limited

suppurative, self-
limited
with
pneumonia → Meningitis

Vacc:

No

No

Live-attenuated

Done by Ayham Alhmaid

الفرح ما كان لولا قبله حزنٌ
والسر ما طال إلا بعده علنٌ

والطفل مهما له قدمت من أكلٍ
يضل أطيب شيءٍ عنده اللبنُ