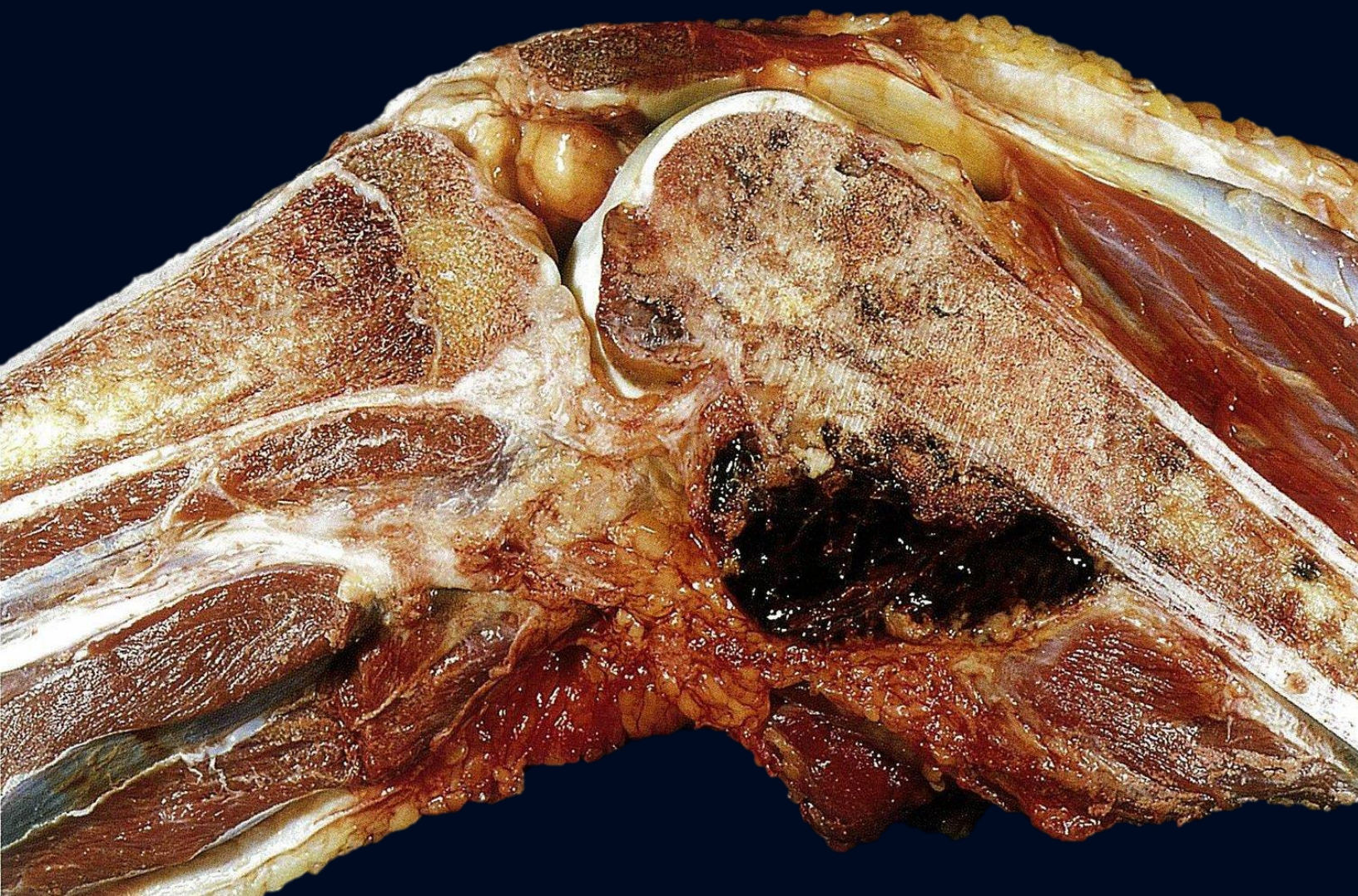


PATHOLOGY

MCQ



AHMED AL-LEIMON

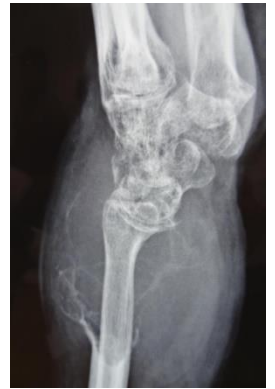OBADA SALEM

2022

JU.

Question 1

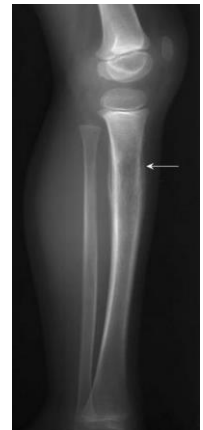A 23-year-old man comes to the emergency department because of a 10-month history of gradual painful swelling of his wrist. His temperature is 37.9°C (100.2°F), pulse is 82/min, respirations are 16/min, and blood pressure is 120/77 mm Hg. An X-ray is obtained and is shown below. Which of the following is the most likely diagnosis?



- A. Giant-cell tumor of bone
- B. Chondroblastoma
- C. Enchondroma
- D. Aneurysmal bone cyst
- E. Ewing sarcoma

Question 2

A 10-year-old boy is brought to his pediatrician's office by his parents because of worsening pain over his left lower leg for the past 2 months. He denies any recent trauma to his leg within the past year and has been generally healthy. Physical examination shows a discrete, hard, and exquisitely tender mass over the anterior aspect of the right tibia about 3 inches below the knee. ESR today is 20mm/hr. An X-ray of this patient's left leg is shown.



- A. Stress fracture
- B. Osteosarcoma
- C. Ewing's sarcoma
- D. Osgood-Schlatter disease
- E. Osteomyelitis

Question 3

A 15-year-old man comes to his pediatrician's office because of pain in his right humerus for the past 3 months. He also reports a recent low grade fever. Further examination reveals midshaft swelling on his right humerus. The patient denies any recent history of trauma. Genetic analysis shows an 11;22 translocation. An x-ray of his right arm is taken. Which of the following answer choices will most likely show up on imaging for this patient?

- A. Necrosis surrounded by sclerosis of bone
 - B. Punched-out lytic lesions
 - C. Spiral fracture
 - D. Codman triangle
 - E. small blue cells with high NC ratio
-

Question 4

A 7-year-old girl comes to the emergency department after falling on her wrist at the playground at school. She has a history of fractures, and expresses pain of her left wrist. Physical examination shows visible scoliosis and large light brown segmental patches of hyperpigmentation with jagged borders across her left upper chest that does not cross the midline. Which of the following is the most likely diagnosis?

- A. Tuberous sclerosis
 - B. McCune-Albright syndrome
 - C. Neurofibromatosis Type 2
 - D. Addison disease
 - E. Neurofibromatosis Type 1
-

Question 5

A 8-year-old boy is brought to the emergency room after a severe fall from a tree during a family vacation. His mother reports a history of recurrent fractures. Physical examination shows visible scoliosis and large areas of light brown hyperpigmentation with jagged borders on the right side of his back. Armpit hair and facial hair is also noted. His voice is noticeably deeper than most young boys his age. Which of the following gene mutations is most likely the cause of his condition?

- A. FBN1
 - B. GNAS1
 - C. MEN-1
 - D. NF
 - E. RET
-

Question 6

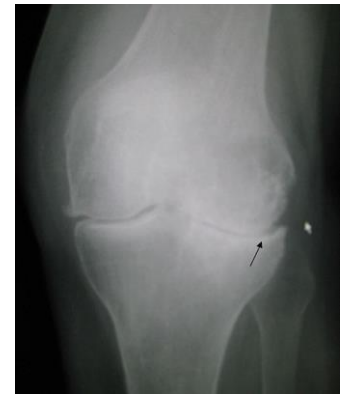A 65-year-old woman comes to the clinic because of gradual onset of pain in her right hand for several months that has become unbearable. She describes the pain surrounding the distal inter-phalangeal joint of her right second digit and her first carpo-metacarpal joint of the same hand. Her temperature is 37.1°C (98.8°F), pulse is 76/min, respirations are 16/min, and blood pressure is 136/72 mm Hg. Physical examination shows a limited range of motion at these joints, bony enlargement, and non-erythematous (no inflammation) swelling present. Her pain and stiffness seem to worsen throughout the day. Which of the following is the most likely etiology of her pain?

- A. Acute trauma
 - B. Disruption of bone remodeling
 - C. Extracellular matrix breakdown
 - D. Joint Inflammation
 - E. Local infection
-

Question 7

A 68-year-old woman reports to her primary care physician with a complaint of right knee pain that has been progressively worsening for the past 2 years. Her temperature is 37.3°C (99.2°F), pulse is 64/min, respirations are 14/min, and blood pressure is 130/76 mm Hg. A radiograph of the knee is obtained and displayed below. Which of the following is the most likely diagnosis?

- A. Osteoarthritis
 - B. Normal Aging
 - C. Osteopetrosis
 - D. Paget's Disease
 - E. Rheumatoid Arthritis
-



Question 8

A 59-year-old man comes to the clinic because of right-sided groin pain. He notes that the pain prevented him from playing golf over the past several months. He expresses he is able to stand upright, but flexion of his right lower extremity is uncomfortable. He adds it has become increasingly difficult for him to put on his socks and shoes. The pain is generally worse in the mornings for 30 minutes and after periods of activity. He denies any trauma. His temperature is 37.1°C (98.8°F), pulse is 90/min, respirations are 16/min, and blood pressure is 136/72 mm Hg. Physical examination shows no motor deficits and no gross abnormalities on visualization. Some pain with manipulation of the right hip in flexion, internal rotation, and Abduction is noted. Which of the following is the most likely diagnosis?

- A. Deep vein thrombosis
- B. Femoral hernia
- C. Hip osteoarthritis
- D. Inguinal hernia
- E. Lumbar spinal stenosis

Question 9

A 55-year-old woman that is post-menopausal comes to the clinic because of persistent right knee pain. She reports stiffness in the morning of the right knee more than the left with resolution after about 30 minutes. She also states that the pain is worst at night just before bed. Her temperature is 37.1°C (98.8°F), pulse is 66/min, respirations are 14/min, and blood pressure is 128/78 mm Hg. A radiograph is obtained of both knees and shows osteophyte formation, asymmetric joint space narrowing, and sclerosis of the right knee with only asymmetric joint space narrowing of the left knee. Which of the following is most likely degraded initially in the pathogenesis of this condition?

- A. nothing
 - B. Mineralized bone
 - C. Non-collagenous proteins
 - D. Type I collagen
 - E. Type II collagen
-

Question 10

A 52-year-old Caucasian man comes to the office because of a 3-week history of coughing and shortness of breath. The patient is originally from Maine and works as a mountaintop coal miner in the Appalachian Mountains. His medical history is relevant for occasional smoking and type II diabetes mellitus. Upon further interrogation, the patient reports morning stiffness on both hands, that fades away with hand warmers or physical activity. Physical exam shows slightly deformed and swollen proximal interphalangeal joints on both hands. Auscultatory findings reveal late inspiratory crackles. His temperature is 36.7°C (98.2°F), pulse is 81/min, respirations are 16/min, blood pressure is 120/71 mmHg, oximetry on room air shows an oxygen saturation of 95%. Which of the following findings is most likely to be found in this patient?

- A. ulnar deviation
 - B. Pleural effusion
 - C. Pulmonary cavitation
 - D. Emphysema
 - E. Pulmonary abscess
-

Question 11

A 45-year-old woman comes to the office because of pain, stiffness, and swelling of the small joints of the hands and feet for 3 months. She also has increasing fatigue that has caused her to miss work at least 1 day per week. She has no other medical problems. Physical examination shows the vital signs are within the normal range. A photograph of one of her hands is shown. Complete blood count, serum chemistries, and urinalysis are all normal. Erythrocyte sedimentation rate is elevated at 44 mm/h and there is a nonsuppurative & proliferative inflammation. Which of the following is the most likely diagnosis?

- A. Osteoarthritis
 - B. Psoriatic arthritis
 - C. Rheumatoid arthritis
 - D. Systemic lupus erythematosus
 - E. Gout
-

Question 12

A 7-year-old girl comes to the office because of spiking fevers that, as her mother describes, would "come and go". Her mother also shows a "salmon-pink" rash that is most prominent during her daughter's fevers. A complete blood count shows significantly increased numbers of white blood cells. However, an infection was later ruled out, and she is diagnosed with juvenile idiopathic arthritis. A diagnosis of juvenile idiopathic arthritis includes all of the following criteria except:

- A. Arthritis in at least one joint
 - B. Arthritis lasting for at least 6 weeks
 - C. Exclusion of other causes of arthritis (unknown cause)
 - D. Onset before age 16
 - E. usually Positive rheumatoid factor
-

Question 13

A 19-year-old man comes to the emergency room because of difficulty breathing for 6 hours. He reports that earlier that day, he was doing laundry and suddenly became short of breath. He also reports back pain for a year that is worst after waking up in the morning. He reports that his morning stiffness typically lasts for approximately an hour. Over the past few months, he has noticed pain in his hips intermittently but did not have insurance to see a doctor so he ignored it. Chest and spine X-rays are obtained and show a damage of sacroiliac joint (Ankylosing spondylitis). Which of the following is associated with the most likely diagnosis?

- A. HLA-B27 positivity
 - B. HLA-DR3 positivity
 - C. Positive ANA
 - D. Positive cyclic citrullinated peptide
 - E. Positive rheumatoid factor
-

Question 14

A 55 year-old man comes to the emergency department because of a three-day history of pain, erythema, and swelling in the first metatarsophalangeal joint of his right foot. He is unable to sleep at night because he has severe pain whenever his bed sheet touches the joint. He admits to smoking one pack per day and drinking three to four beers nightly. He denies any previous episodes of pain in this joint and denies trauma to the area. He denies pain in any other joint. His only medication is hydrochlorothiazide for hypertension, and the dose of this medication was recently increased by his primary care provider. Physical examination shows a tender, warm, erythematous right toe. Synovial fluid is removed from the joint, and crystals are seen on microscopy. Which of the following substances is most likely to be seen on analysis?

- A. Calcium oxalate
 - B. Calcium pyrophosphate dihydrate
 - C. Cholesterol
 - D. Monosodium urate
 - E. Uric acid
-

Question 15

A 55 year-old man comes to the emergency department because of a three-day history of pain, erythema, and swelling in the first metatarsophalangeal joint of his right foot. He is unable to sleep at night because he has severe pain whenever his bed sheet touches the joint. He admits to smoking one pack per day and drinking three to four beers nightly. Last night he reports having a few extra beers. He denies any previous episodes of pain in this joint and denies trauma to the area. He denies pain in any other joint. His only medication is hydrochlorothiazide for hypertension. His temperature is 37.1°C (98.8°F), pulse is 90/min, respirations are 16/min, and blood pressure is 136/72 mm Hg. Which of the following is most likely to be seen on joint aspiration?

- A. Elevated PMNs only
 - B. Gram positive cocci in clusters
 - C. Linear and rhomboidally-shaped crystals
 - D. Negatively birefringent crystals
 - E. Positively birefringent crystals
-


Question 16

A 67-year-old man comes to the emergency department at 3:00am because of extreme pain in his left foot. He had been sleeping but a sudden pain in his left big toe woke him up. Earlier that evening he had attended his granddaughter's wedding and after the lobster and steak dinner, he "drank excessively." He then danced with his wife, but denied any trauma to his left toe. He has a history of hypertension, diabetes, and obesity. His medications include hydrochlorothiazide and metformin. His temperature is 37.3°C (99.2°F), pulse is 90/min, respirations are 16/min, and blood pressure is 136/72 mm Hg. Physical examination shows the left first tarsometatarsal joint is warm, red, and exquisitely tender. Which of the following is the most likely diagnosis?

- A. Gout
 - B. Osteoarthritis
 - C. Pseudogout
 - D. Rheumatoid arthritis
 - E. Septic joint
-

Question 17

A 54-year-old man comes to the emergency department because of a one day history of acute onset pain of the right knee. The patient states he has had similar episodes in the past in his metatarsophalangeal joints, which were less severe and relieved by ibuprofen. He denies any recent trauma or fever. Pertinent history includes consumption of 4-5 beers per day, sexual activity with multiple female partners over the past year, and two hospitalizations for nephrolithiasis. Physical examination shows a tender, mildly swollen, and erythematous right knee with limited range of motion. Joint aspiration (image) shows yellow crystals in parallel to the polarization filter, and 24,200 leukocytes/ μ L (normal <200). Which of the following is the most likely diagnosis?



- A. Gout
 - B. Osteochondritis dissecans
 - C. Prepatellar bursitis
 - D. Pseudogout
 - E. Septic arthritis
-

Question 18

A 49-year-old man comes to the clinic because of recurrent episodes of acute pain and swelling of his left big toe. He is a lawyer and notes that these episodes usually occur after entertaining clients at elaborate dinners with alcohol. His temperature is 37.3°C (99.2°F), pulse is 90/min, respirations are 20/min, and blood pressure is 140/80 mm Hg. Physical examination shows his left big toe is erythematous, edematous, and exceedingly tender to palpation. Analysis of synovial fluid from the joint reveals needle-shaped crystals that appear yellow when viewed with parallel light. Which of the following is the most likely etiology of his condition?

- A. Rheumatic disease
 - B. Calcium pyrophosphate dehydrate crystal deposition
 - C. Mechanical injury
 - D. Monosodium urate monohydrate crystal deposition
 - E. Neisseria gonorrhoeae infection
-

Question 19

A 40-year-old male comes to the emergency department because of foot pain. He states that since he awoke this morning his right big toe has been exquisitely painful and swollen. He denies any trauma to the area, fevers, or chills. He has a past medical history of diabetes mellitus type 2. Physical examination shows erythema and swelling of the right metatarsophalangeal joint. After initial treatment, he is given a medication to prevent this problem in the future. Which of the following is the most likely site of action of this medication?

- A. Binding and stabilization of tubulin
 - B. Inhibition of COX1
 - C. Inhibition of COX2
 - D. Inhibition of ribonucleotide reductase
 - E. Inhibition of xanthine oxidase
-

Question 20

A 52-year-old man comes to the emergency department because of joint swelling, pain, and trouble walking. Physical examination shows his right knee is swollen and tender to palpation. An aspiration of the joint shows calcium pyrophosphate crystal accumulation. Which of the following findings will most likely be found upon microscopic examination of the synovial fluid?

- A. Elevated eosinophils
 - B. Envelope-shaped crystals
 - C. Less than 1,000/uL white blood cells
 - D. Negatively birefringent needle shaped crystals
 - E. Positively birefringent rhomboid crystals
-

Question 21

A 23-year-old man complains of stiffness and pain in his lower back that causes him to awaken at night. He first noticed morning stiffness in his lower back during his college years. He also describes occasional pain in his right eye and sensitivity to light. An X-ray of the sacroiliac region shows fusion of the small joint spaces in the posterior spine and ossification of the intervertebral discs. Serologic tests for rheumatoid factor and antinuclear antibodies are negative. This patient most likely expresses which of the following human leukocyte antigen (HLA) haplotypes?

- A. B15
 - B. B19
 - C. B27
 - D. B31
 - E. B9
-

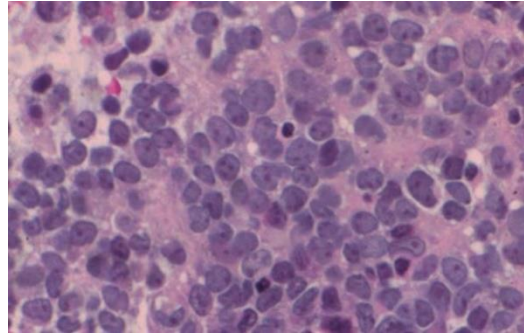
Question 22

A 28-year-old man complains of burning pain on urination, as well as pain in his fingers and left eye. He also relates a recent episode of bacillary diarrhea contracted during a visit to Mexico. Physical examination confirms arthritis and conjunctivitis. The patient responds well to treatment with NSAIDs. Which of the following is the most likely diagnosis?

- A. Ankylosing spondylitis
 - B. Infectious arthritis
 - C. Osteomyelitis
 - D. Reiter syndrome
 - E. Rheumatoid arthritis
-

Question 23

A 16-year-old boy presents with a swelling on his left tibia. An X-ray of the leg shows a destructive process, with indistinct borders and an “onion-skin” pattern of periosteal bone. Histologic examination of a biopsy reveals uniform small cells with round, dark blue nuclei (shown in the image). A PAS stain demonstrates abundant intracellular glycogen. Immunohistochemistry for leukocyte common antigen is negative. Which of the following is the most likely chromosomal abnormality in this tumor?



- A. t(11;22)
 - B. t(14;18)
 - C. t(8;14)
 - D. t(9;22)
 - E. t(3;16)
-

Question 24

A 74-year-old, obese woman (BMI = 33 kg/m²) complains of chronic pain in her back, knees, and fingers. The pain typically subsides at rest. On physical examination, the distal interphalangeal joints are enlarged and tender. Which of the following best describes the pathogenesis of joint pain in this patient?

- A. Acute inflammation of the ligaments
 - B. Degeneration of articular cartilage
 - C. Degenerative changes of cortical bone
 - D. Inflammatory synovium with pannus formation
 - E. Reduction of the volume of synovial fluid
-

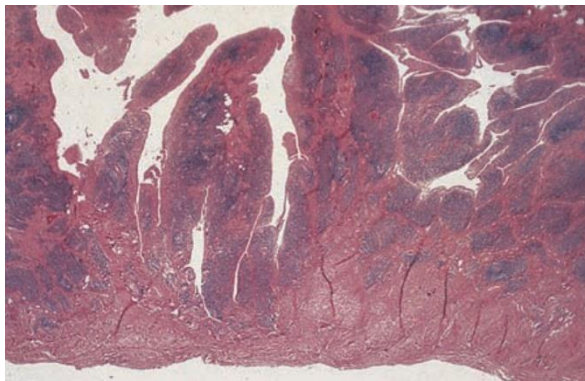
Question 25

A 60-year-old woman with arthritis suffers a massive stroke and expires. At autopsy, the proximal phalangeal joint tissue shows pannus, synovial cell hyperplasia, and lymphoid follicles. Which of the following best describes the pathogenesis of pannus formation in this patient?

- A. Calcification of the synovium
 - B. Chronic inflammation of synovium
 - C. Degeneration of cartilage
 - D. Dislocation of a portion of bone
 - E. Necrosis of fibroadipose tissue
-

Question 26

A 40-year-old woman complains of morning stiffness in her hands. On physical examination, her finger joints are painful, swollen, and warm. X-ray examination of the hands shows narrowing of the joint spaces and erosion of joint surfaces of the metacarpal/phalangeal joints. The adjacent bones show osteoporosis. A synovial biopsy reveals prominent lymphoid follicles, synovial hyperplasia, and villous folds (shown in the image). Laboratory studies conducted on a blood sample from this patient will most likely show polyclonal antibodies directed against which of the following proteins?



- A. Double-stranded DNA
 - B. Fab2 portion of IgM
 - C. Fc portion of IgG
 - D. Ribonucleoprotein
 - E. Topoisomerase I
-

Question 27

An 85-year-old man presents with a 3-week history of painful swelling of his right knee. Aspiration of joint fluid returns numerous neutrophils and crystals, which are described as rhomboid and "coffin like." Chemical analysis shows that these crystals are composed of calcium pyrophosphate. Which of the following is the most likely diagnosis?

- A. Ankylosing spondylitis
 - B. Gout
 - C. Infectious arthritis
 - D. Pseudogout
 - E. Rheumatoid arthritis
-

Question 28

A 10-year-old boy complains of pain in his hands and feet. His temperature is 38°C (101°F). Physical examination reveals a faint pericardial friction rub. His spleen, liver, and axillary lymph nodes are enlarged. Which of the following is the most likely diagnosis?

- A. Gaucher disease
 - B. Gout
 - C. Juvenile arthritis
 - D. Psoriatic arthritis
 - E. Reiter syndrome
-

Question 29

Which part of a joint does osteoarthritis usually affect?

- A. Bone
 - B. Cartilage
 - C. Tendon
 - D. All of the above
-

Question 30

Which of these makes it more likely to get osteoarthritis?

- A. Young age
 - B. Excess body weight
 - C. Too little body weight
 - D. Back pain
 - E. None of the above
-

Question 31

When a person gets osteoarthritis of the hip, where else might the pain show up?

- A. Arm
 - B. Groin
 - C. Feet
 - D. Shoulders
 - E. All of the above
-

Question 32

How can an X-ray help a healthcare provider diagnose osteoarthritis?

- A. It can show cartilage loss
 - B. It can show bone damage
 - C. It can show bone spurs
 - D. All of the above
-

Question 33

Which of these medicines is used to treat osteoarthritis?

- A. Aspirin
 - B. Acetaminophen
 - C. Corticosteroid injections
 - D. All of the above
-

Question 34

Which of these can help prevent osteoarthritis?

- A. Maintain a healthy weight
 - B. Use good posture
 - C. Start new activities slowly
 - D. All of the above
-

Question 35

Surgery can sometimes be done to treat arthritis.

- A. True
 - B. False
-

Answers

- | | | | | | |
|------|-------|-------|-------|-------|-------|
| 1) A | 7) A | 13) A | 19) E | 25) B | 31) B |
| 2) C | 8) C | 14) D | 20) E | 26) C | 32) D |
| 3) D | 9) E | 15) D | 21) C | 27) D | 33) D |
| 4) B | 10) A | 16) A | 22) D | 28) C | 34) D |
| 5) B | 11) C | 17) A | 23) A | 29) B | 35) A |
| 6) C | 12) E | 18) D | 24) B | 30) B | |
-

V2

Q7: Ans: A
*not B