



# The Eyeball

Dr. Heba Kalbouneh

DDS, MSc, DMD/PhD

Professor of Anatomy, Histology and Embryology

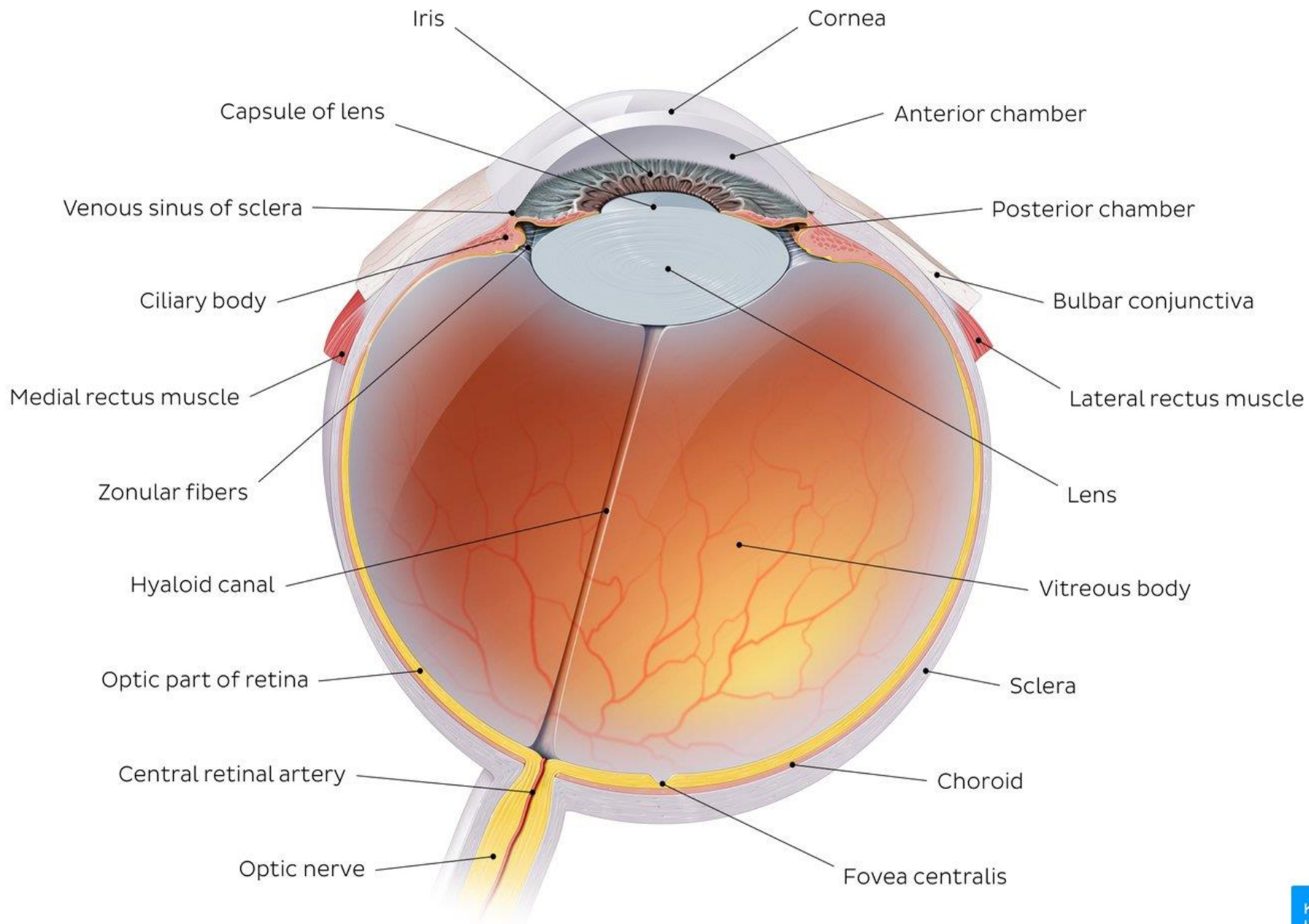
# Coats of the Eyeball

- 1- Outer fibrous coat**
- 2- Middle vascular coat**
- 3- Inner nervous coat**

Each eyeball consists externally of a tough, fibrous globe that maintains its overall shape.

Internally the eye contains transparent tissues that refract light to focus the image, a layer of photosensitive cells, and a system of neurons that collect, process, and transmit visual information to the brain.





# Outer fibrous coat

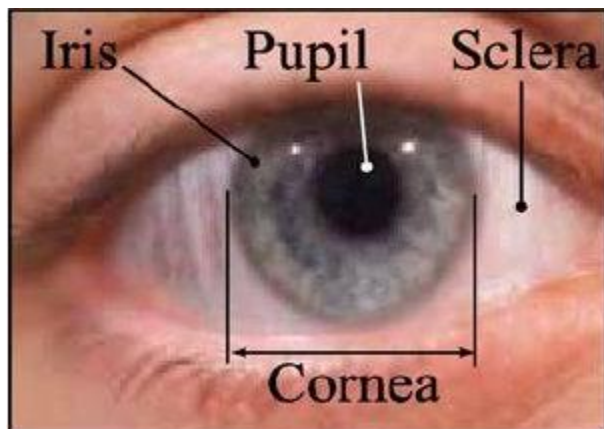
The white posterior five-sixths of the outer fibrous layer is **the sclera**

## The Sclera

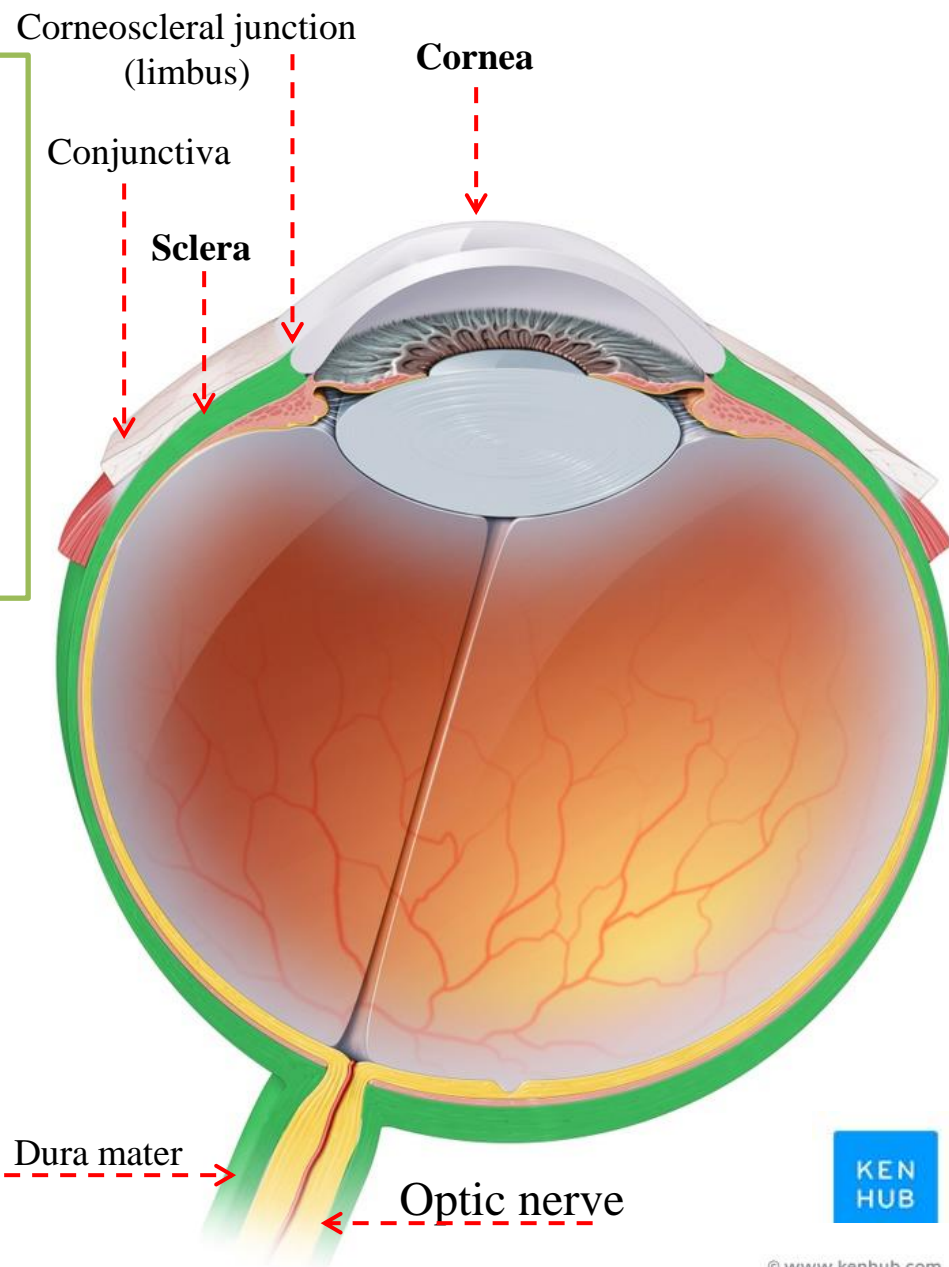
- The sclera is composed of dense fibrous tissue and is white.
- Posteriorly, it is pierced by the optic nerve
- It is continuous posteriorly with the **dura mater of optic nerve**
- ✓ It is continuous in front with the **cornea at the corneoscleral junction, or limbus**
- ✓ The sclera is also pierced by the ciliary arteries and nerves and their associated veins

### Functions:

- ✓ Supports eye shape
- ✓ Protects delicate internal structures
- ✓ Extrinsic eye muscle attachment site



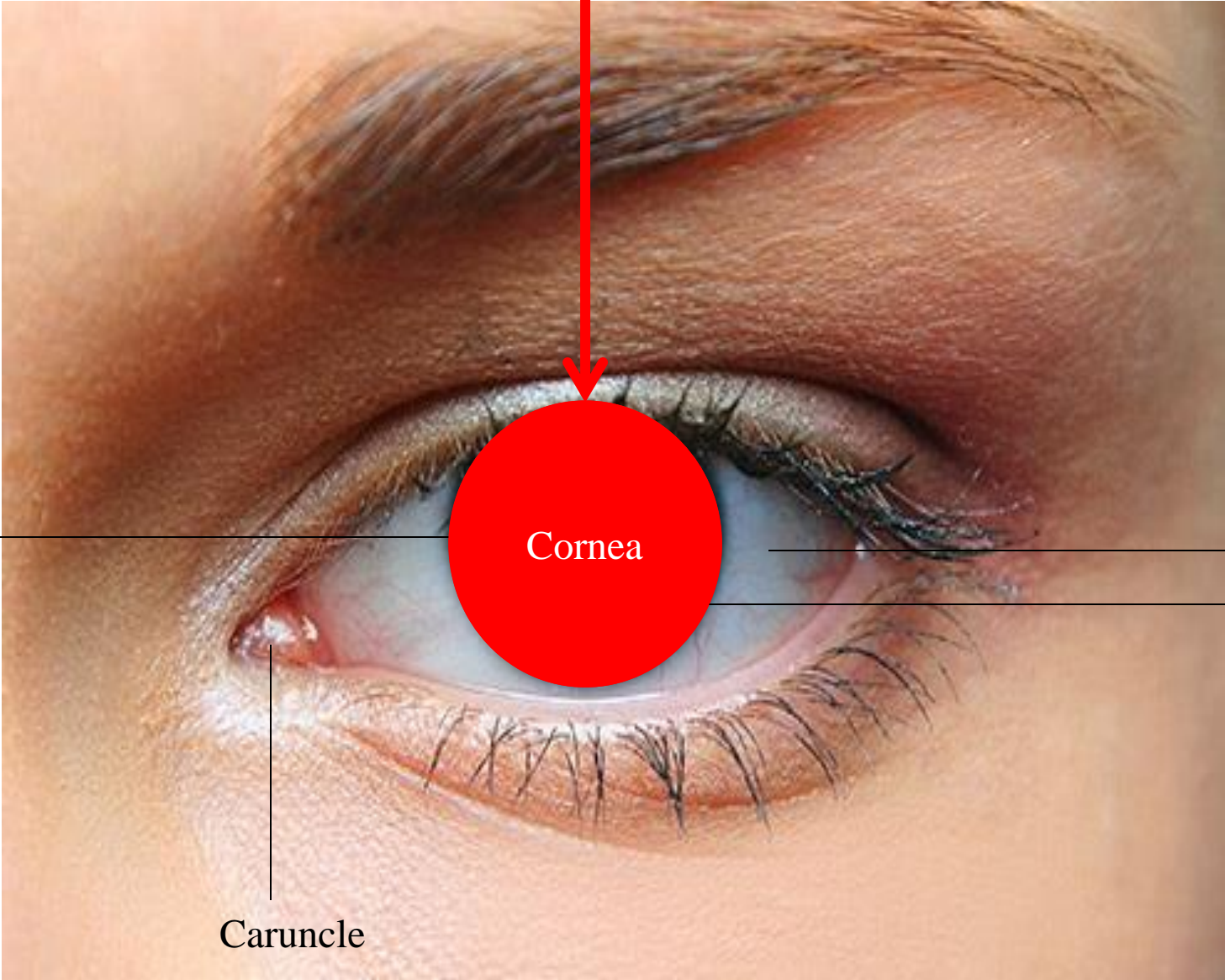
Sclera is the dense white part





Corneoscleral junction (limbus)

*Dr. Heba Kalbouneh*



Pupil

Cornea

Sclera

Iris

Caruncle

# Outer fibrous coat

## The Cornea

*The transparent anterior one-sixth of the outer fibrous layer is **the cornea***

- ✓ It is transparent
- ✓ It is in contact posteriorly with the aqueous humor.

### Blood Supply

- ✓ The cornea is avascular and devoid of lymphatic drainage
- ✓ It is nourished by diffusion from aqueous humor, tears, and from the capillaries at its edge (limbus)

*Why avascular??*

*Blood vessels may cloud the cornea, which may prevent it from refracting light properly and may adversely affect vision*

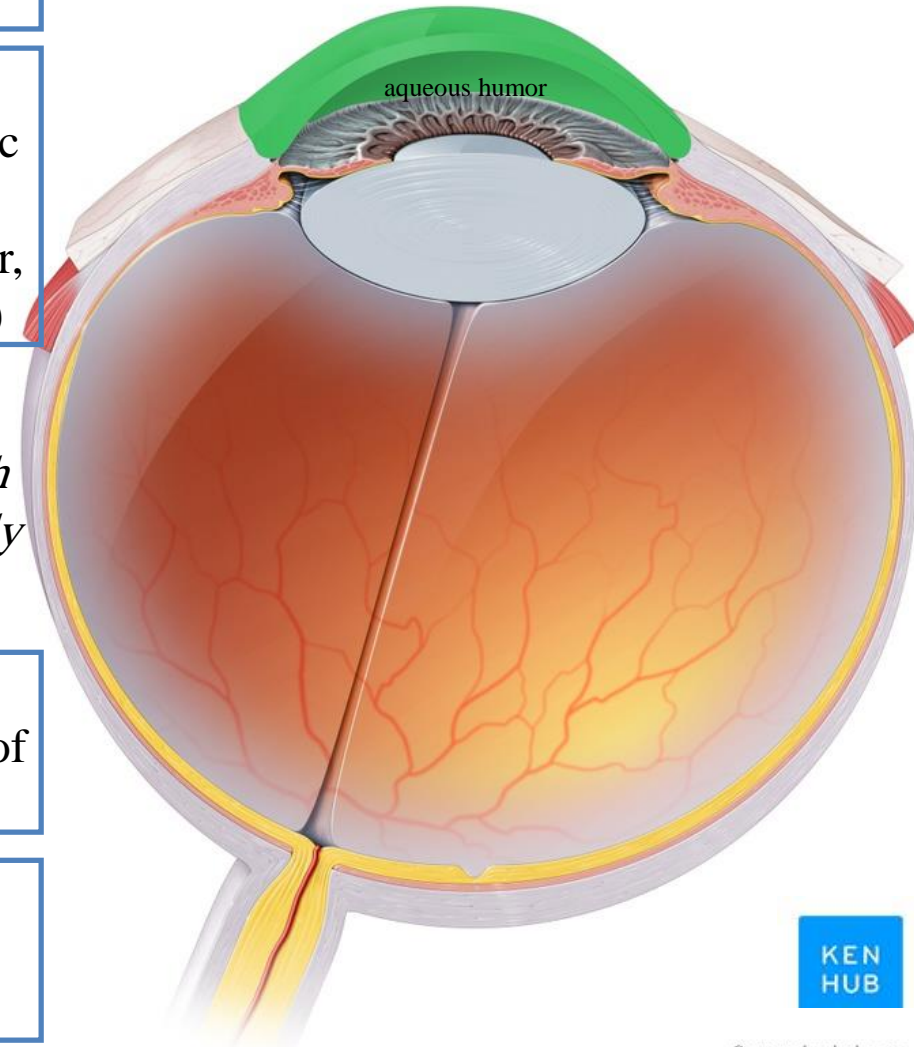
### Nerve Supply

Long ciliary nerves from the ophthalmic division of the trigeminal nerve (nasociliary branch)

### Function of the Cornea

The cornea is the most important refractive medium of the eye.

The cornea is one of the most sensitive tissues of the body (has one of the richest sensory nerve supplies of any tissue)

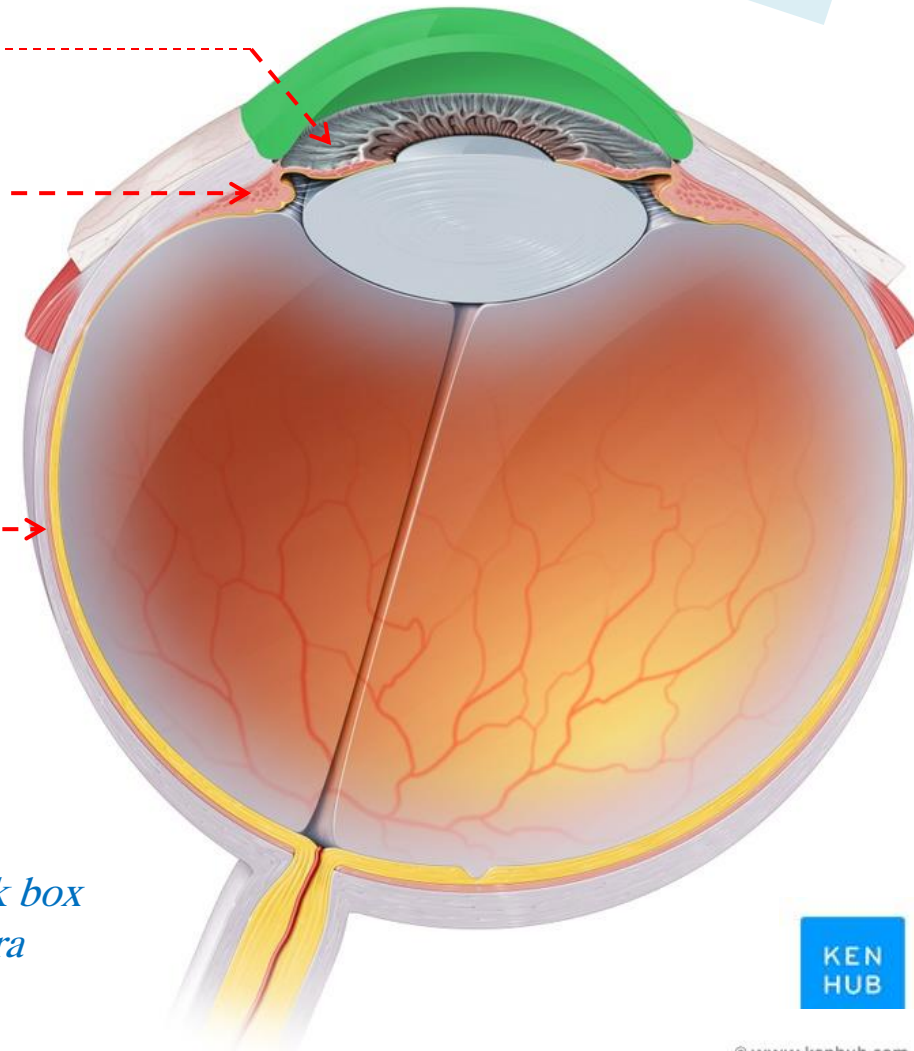


# MIDDLE VASCULAR PIGMENTED COAT

Uvea: iris, ciliary body and choroid

This coat is vascular and pigmented

Iris  
Ciliary body  
Choroid



THE VASCULAR COAT CONSISTS OF:  
FROM BEHIND FORWARD

- 1- THE CHOROID
- 2- THE CILIARY BODY
- 3- THE IRIS

*Act as the black box of the camera*



## MIDDLE VASCULAR PIGMENTED COAT

### 1- Choroid

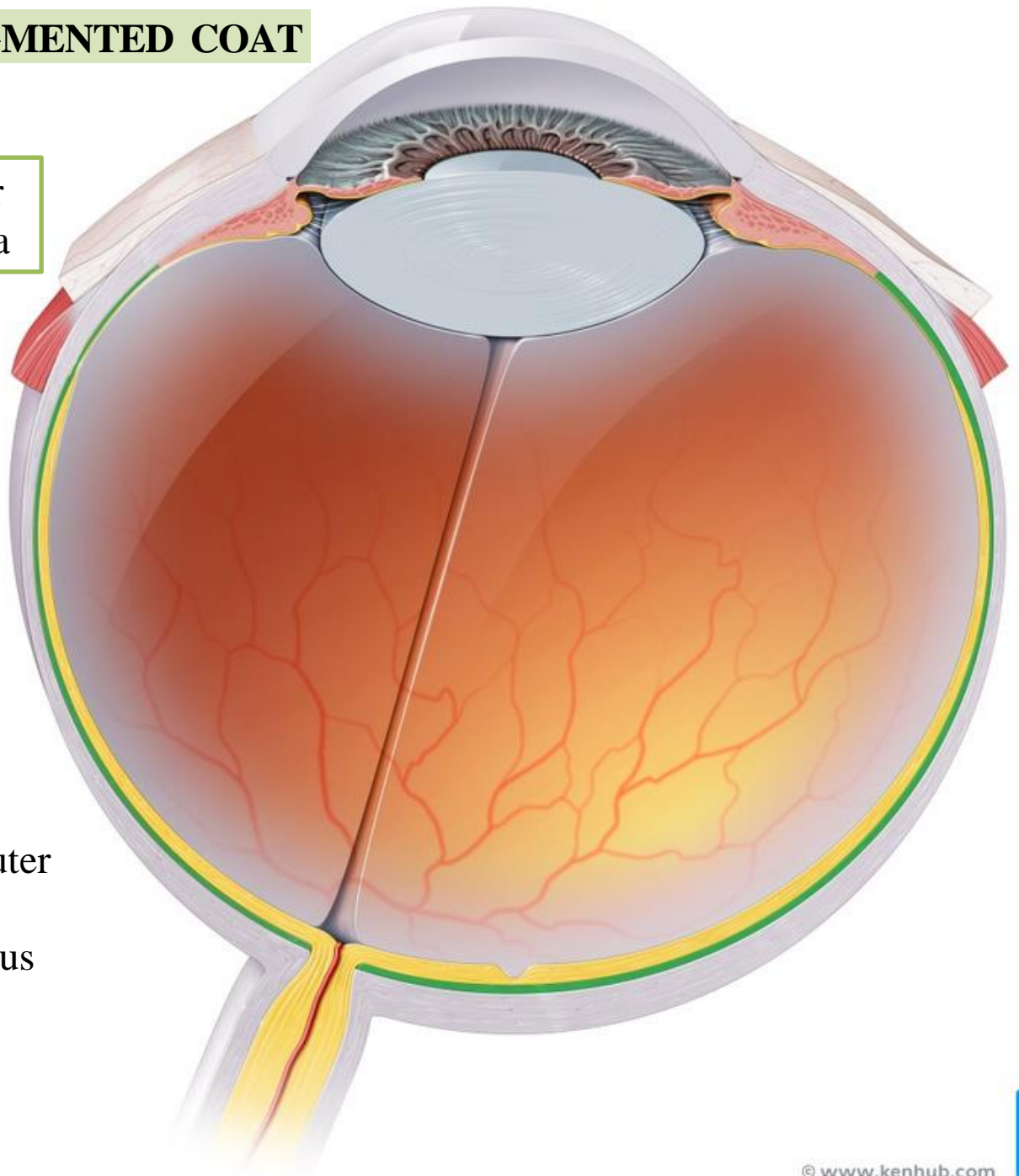
Choroid is a brown vascular membrane deep to the sclera

#### Component:

Areolar connective tissue; highly vascularized, heavily pigmented (contains numerous melanocytes)

#### Function:

- ✓ Supplies nourishment to outer part of retina
- ✓ Pigment absorbs extraneous light

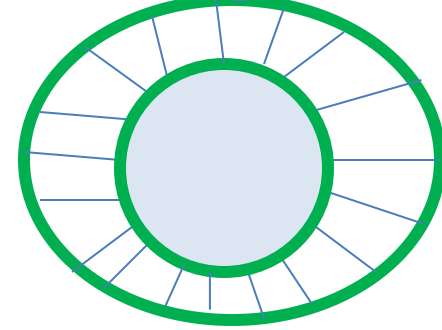




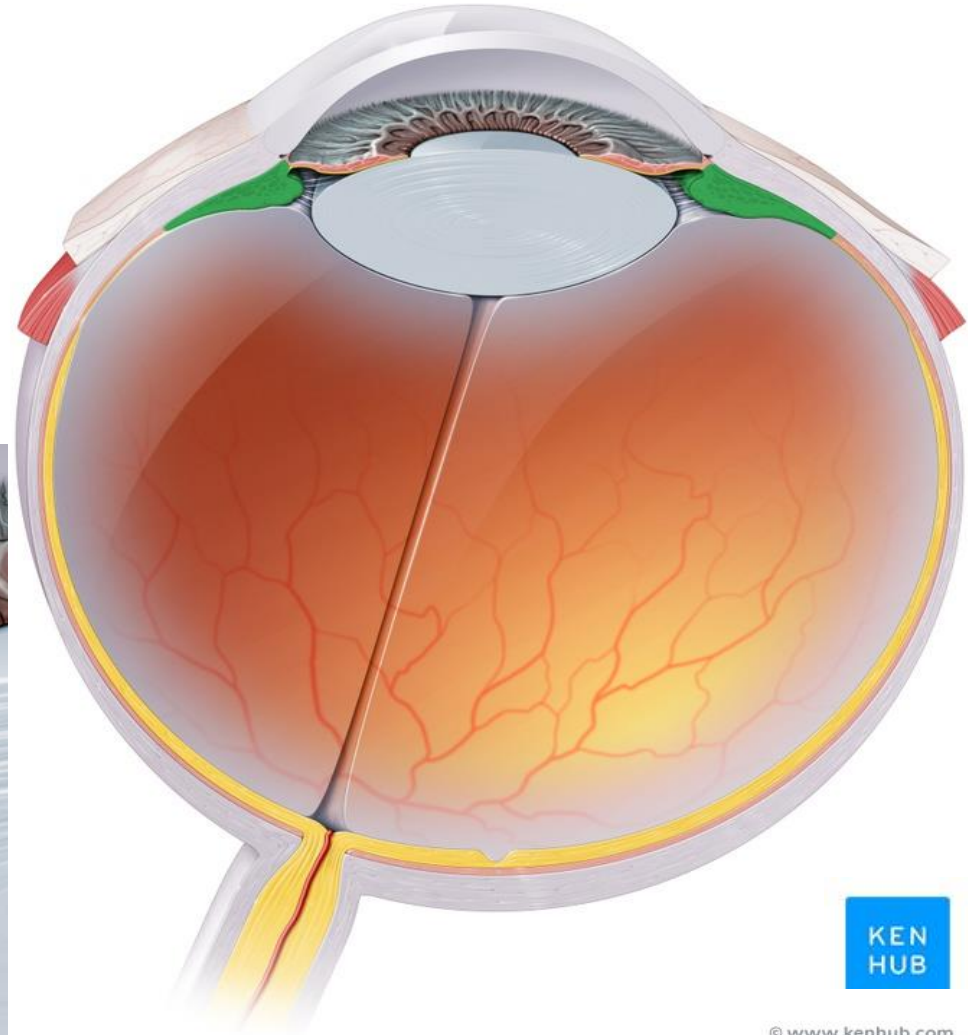
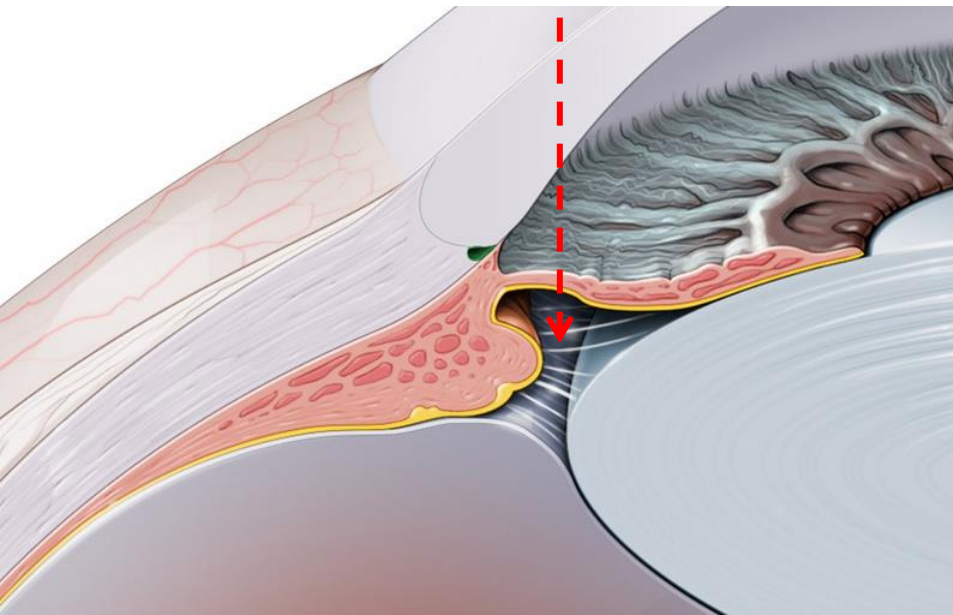
# MIDDLE VASCULAR PIGMENTED COAT

## 2- Ciliary body

- ✓ The ciliary body is ring-shaped and continuous posteriorly with the choroid, and anteriorly it lies behind the peripheral margin of the iris
- ✓ Contains **the ciliary muscle (the main muscle of accommodation)**
- ✓ It is connected to the lens by the suspensory ligaments of the lens (zonular fibers)



Dr. Heba Kalbouneh



# Ciliary body

## Component:

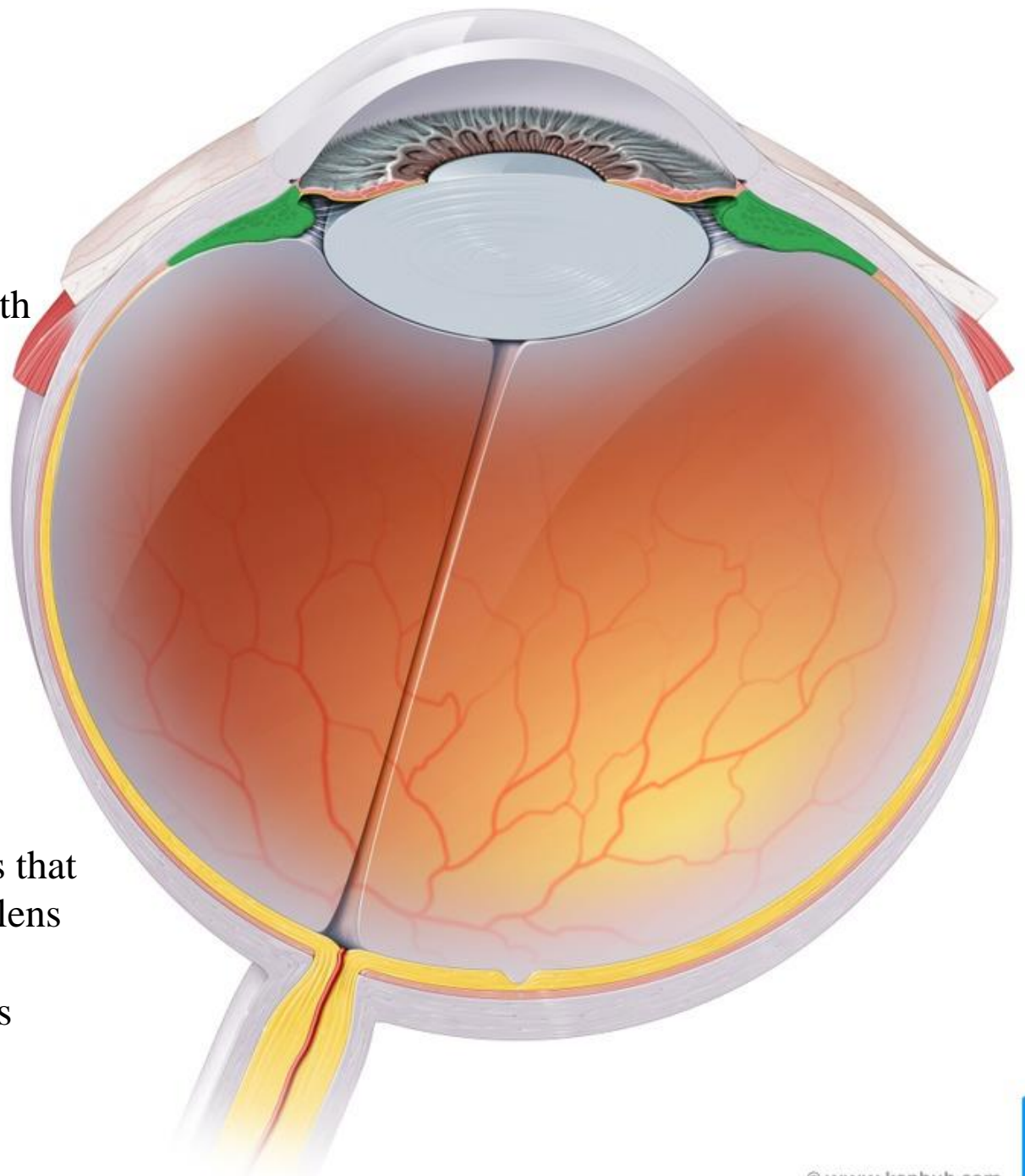
Ciliary muscle

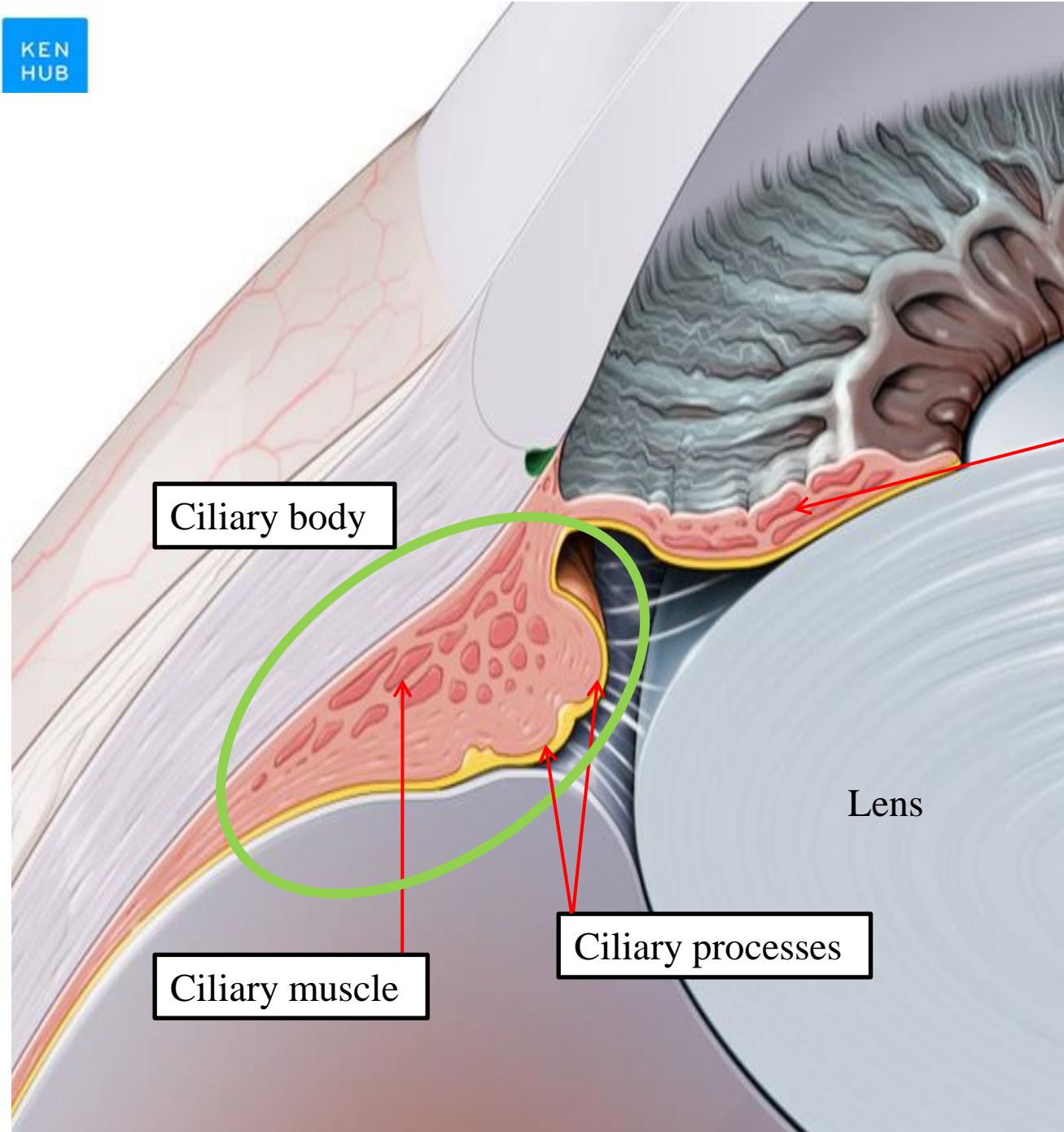
Ciliary processes (covered with a secretory epithelium)

*Dr. Heba Kalbouneh*

## Function:

- ✓ Holds suspensory ligaments that attach to the lens and change lens shape for far and near vision
- ✓ Epithelium secretes aqueous humor





Ciliary body

Iris

✓ **The ciliary processes** secrete aqueous humor into the posterior chamber

Lens

Ciliary muscle

Ciliary processes



# The ciliary muscle

KEN  
HUB

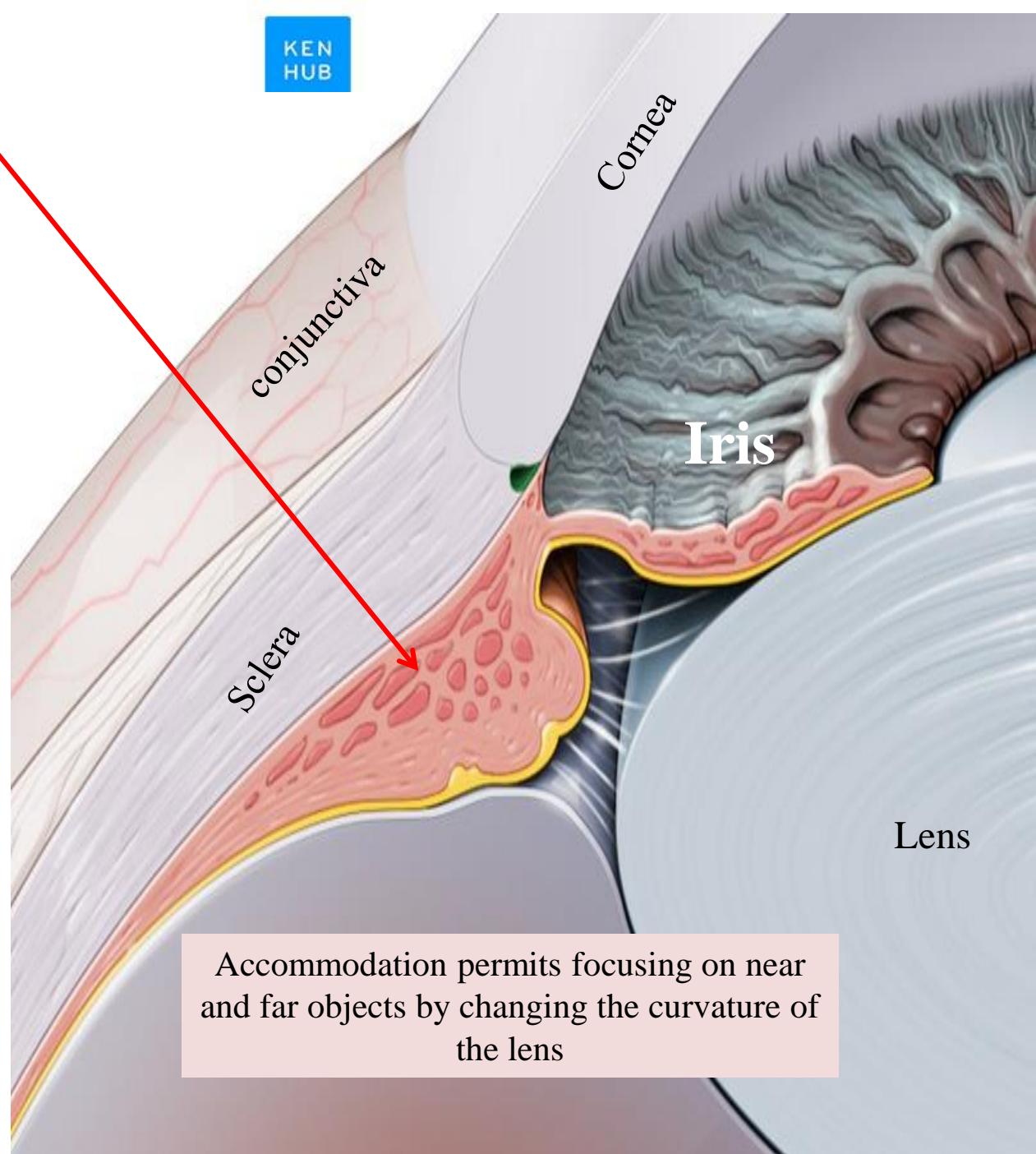
## Nerve supply:

The ciliary muscle is supplied by the **parasympathetic fibers from the oculomotor nerve.**

After synapsing in the ciliary ganglion, the postganglionic fibers pass forward to the eyeball in the short ciliary nerves.

## Action:

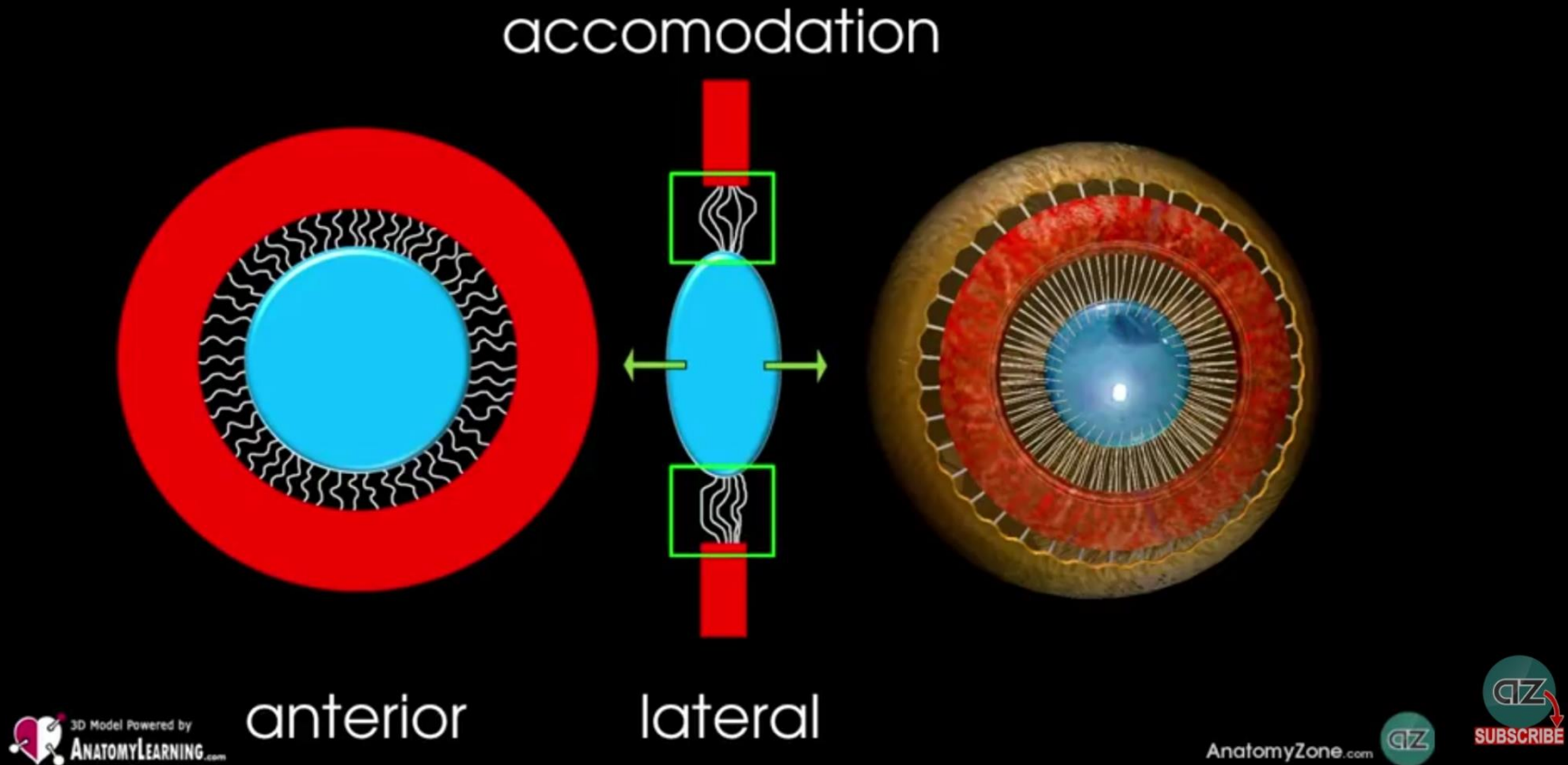
Contraction of the ciliary muscle relieves the tension in the suspensory ligament, and the elastic lens becomes more convex. This increases the refractive power of the lens.



Accommodation permits focusing on near and far objects by changing the curvature of the lens

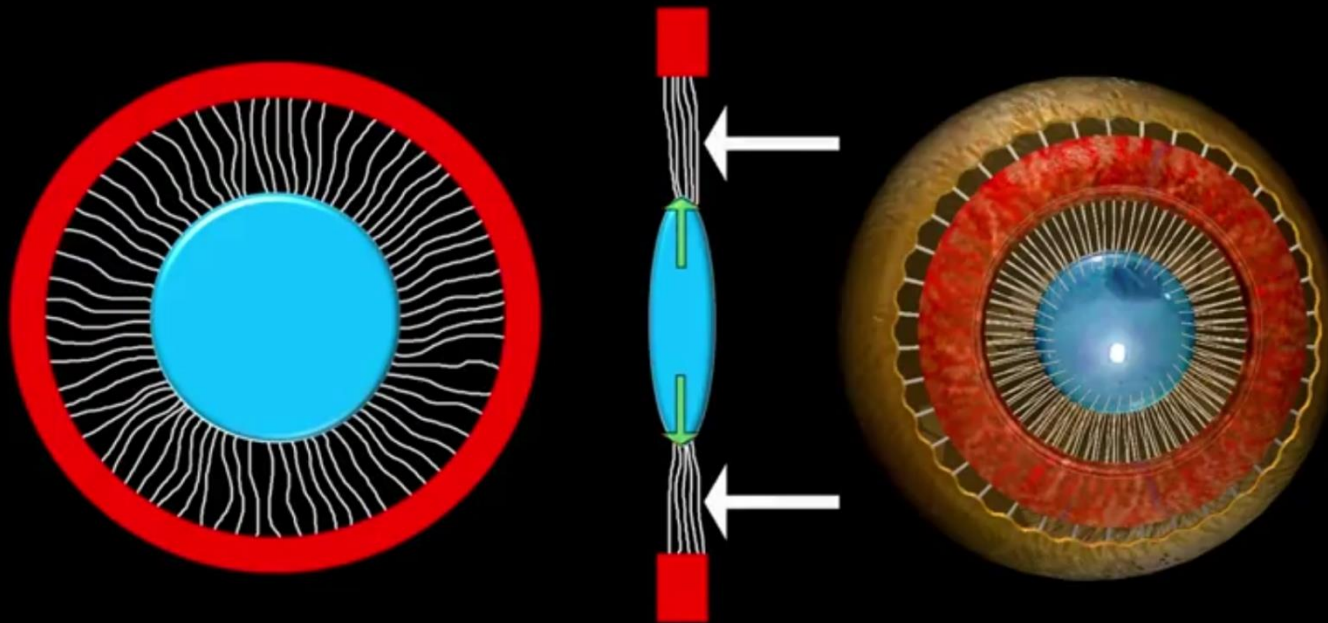


To accommodate the eye for **close objects**, the ciliary muscle contracts so that the radiating fibers of the suspensory ligament are relaxed. This allows the elastic lens to assume a more globular shape



**Near vision**

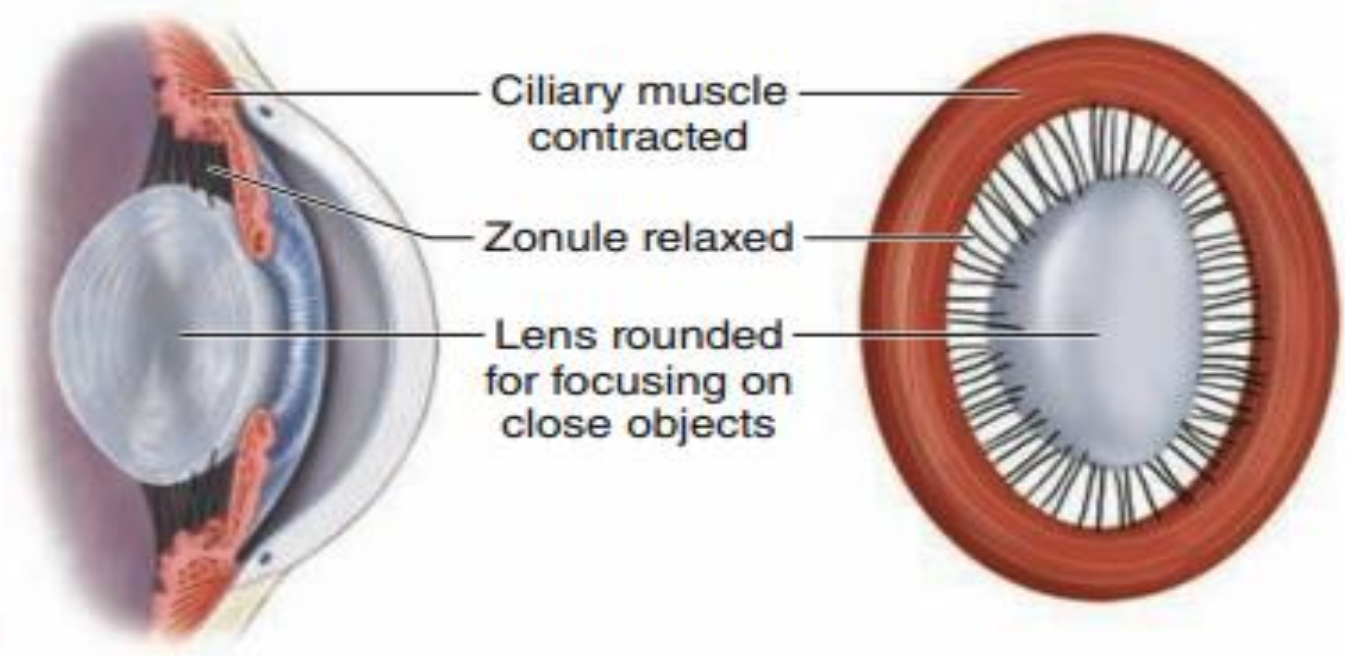
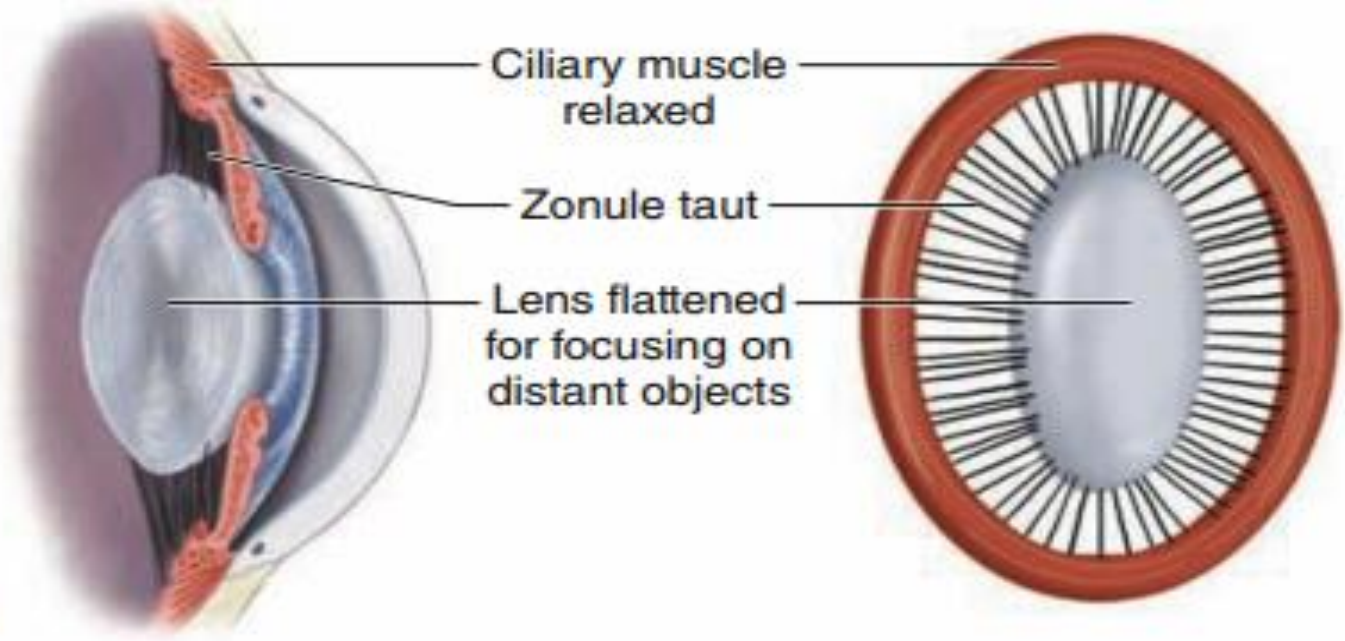
When the ciliary muscle relaxes so that the radiating fibers of the suspensory ligament are tense. This allows the elastic lens to assume a flatter shape



anterior

lateral

**Far vision**





## MIDDLE VASCULAR PIGMENTED COAT

### 3- Iris

Is a thin, contractile and pigmented smooth muscle with a central aperture the **pupil**

➤ It is suspended in the aqueous humor between the cornea and the lens.

➤ The periphery of the iris is attached to the ciliary body.

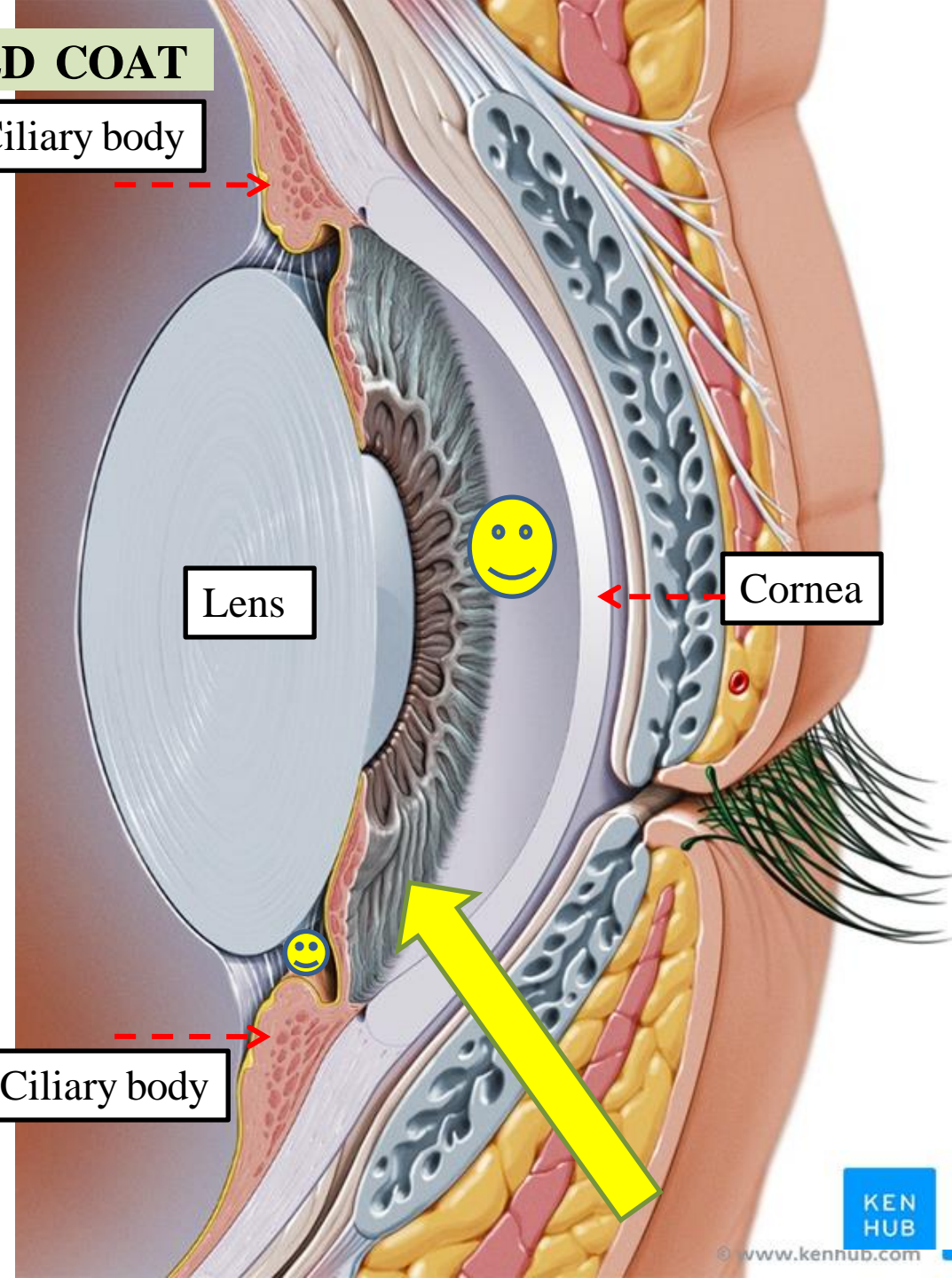
➤ It divides the space between the lens and the cornea into an anterior and a posterior chamber 😊

Ciliary body

Lens

Cornea

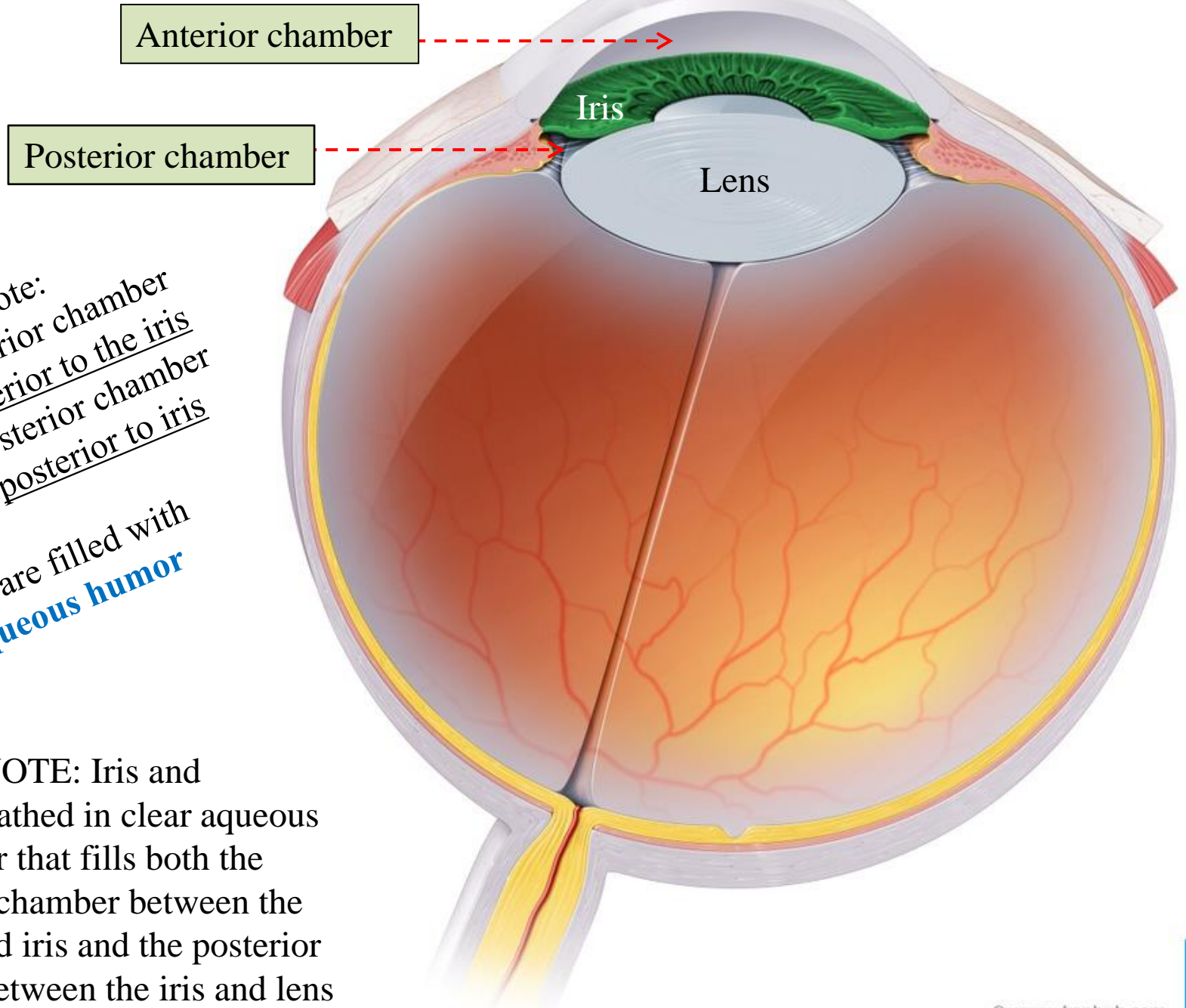
Ciliary body





# Iris

Dr. Heba Kalbouneh



Anterior chamber

Posterior chamber

Iris

Lens

Note:  
The anterior chamber  
lies anterior to the iris  
The posterior chamber  
lies posterior to iris

Both are filled with  
**aqueous humor**

NOTE: Iris and  
lens are bathed in clear aqueous  
humor that fills both the  
anterior chamber between the  
cornea and iris and the posterior  
chamber between the iris and lens

# Iris

## Component:

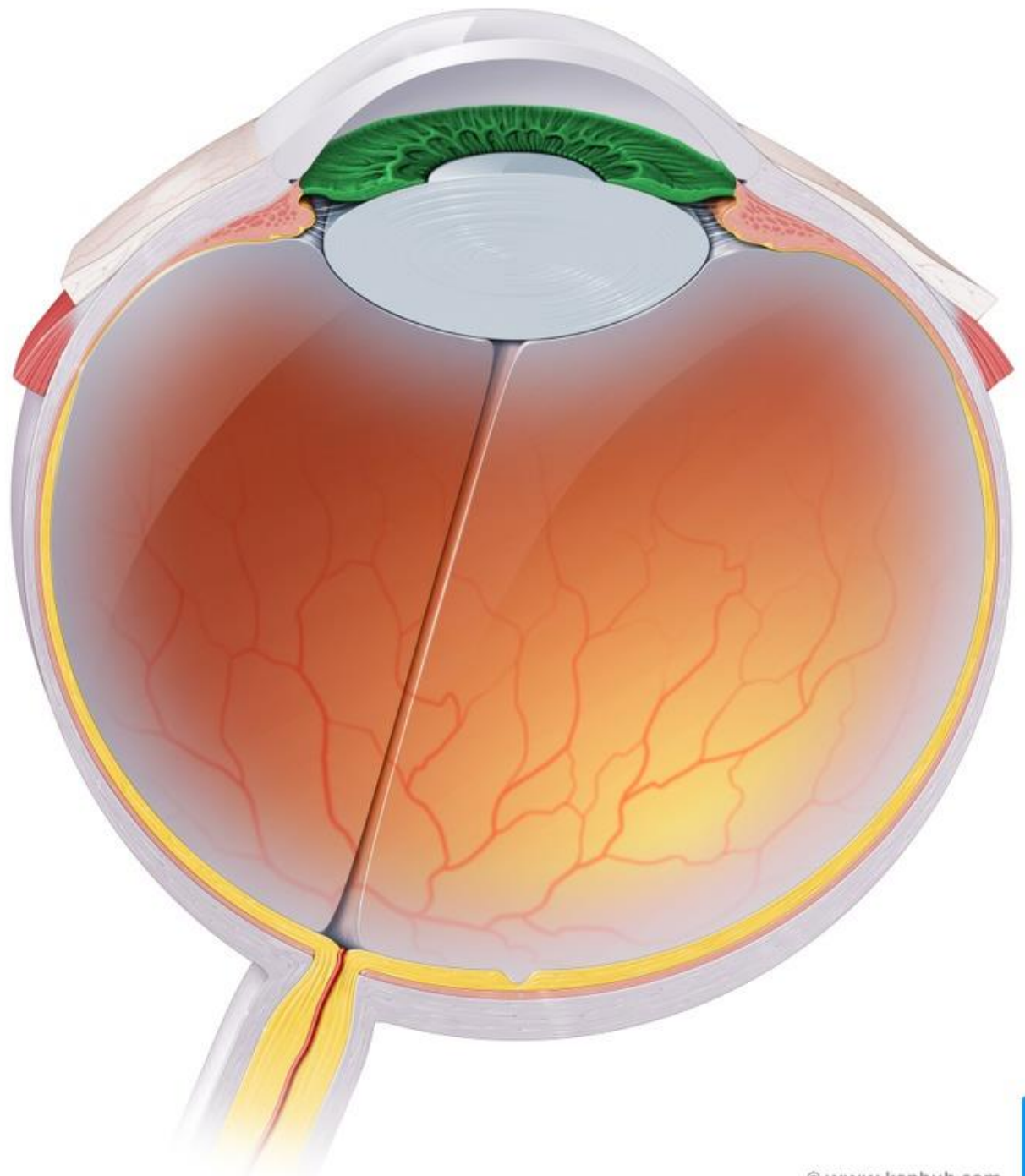
Two smooth muscles (sphincter pupillae and dilator pupillae) and connective tissue stroma (contains melanocytes), with a central pupil

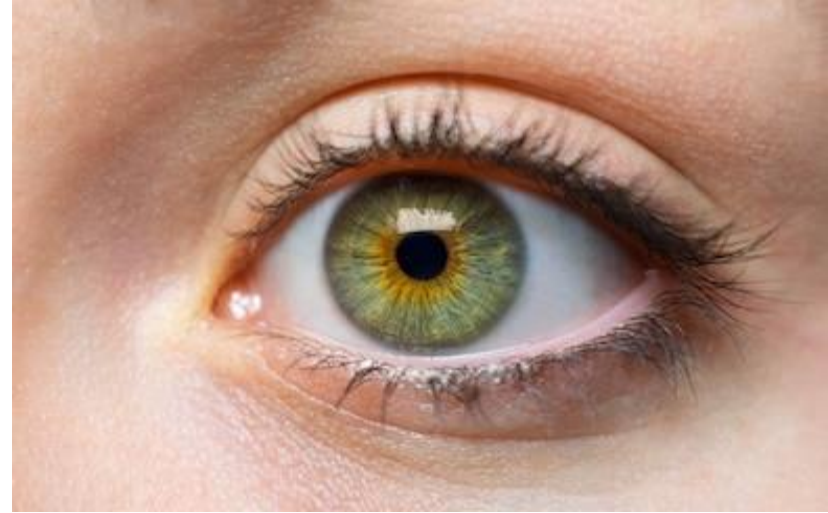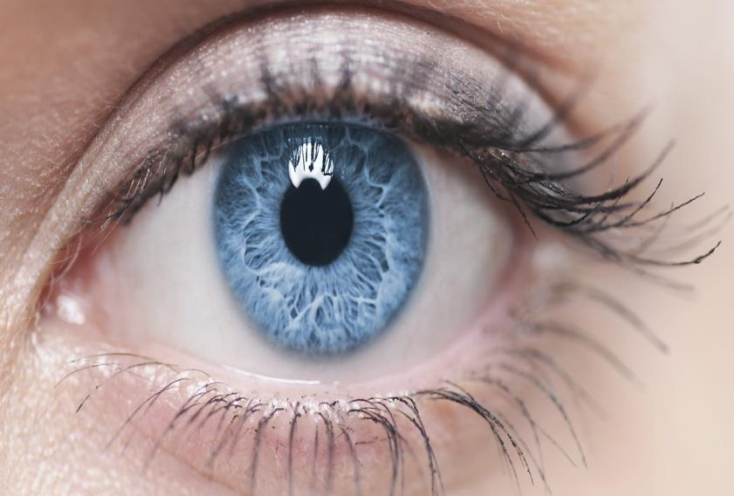*Dr. Heba Kalbouneh*

Melanocytes of the iris stroma provide the color of one's eyes.

## Function:

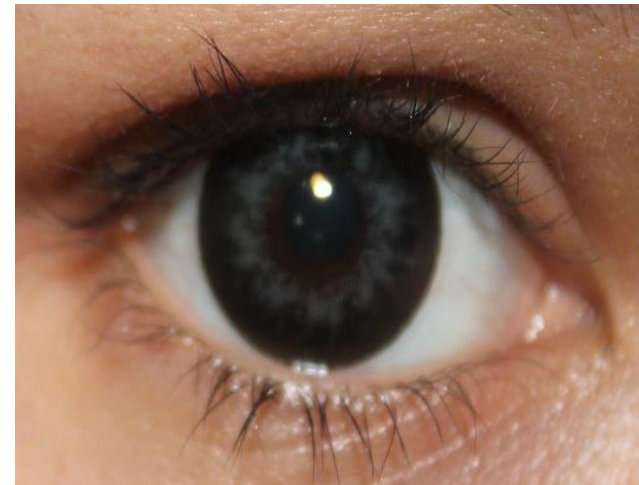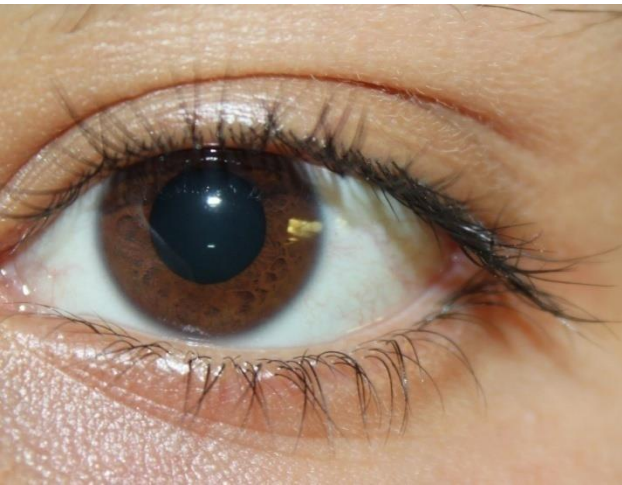
Controls pupil diameter and thus the amount of light entering the eye





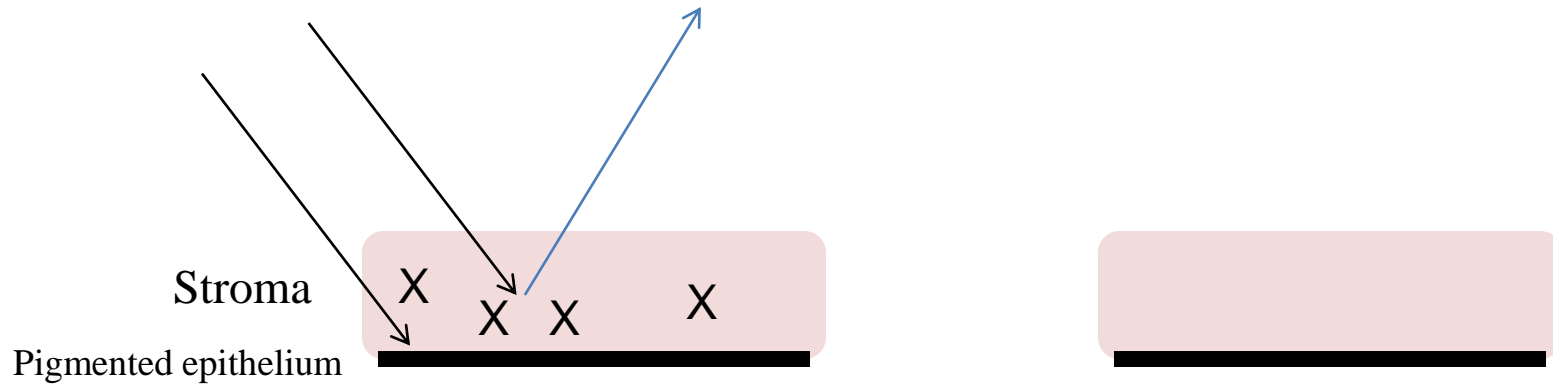
In individuals with very few melanin pigment in the stroma, light with a blue color is reflected back (producing the blue color of iris).

As the density of melanin increases in the stroma, the iris color changes through various shades of green, gray, and brown.



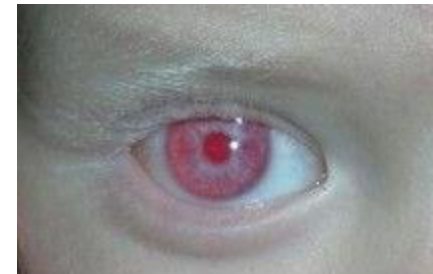

The scattering of light by the turbid medium in the stroma of the iris



Blue eyes have low concentrations of melanin in the stroma of the iris, which lies in front of the dark epithelium. Longer wavelengths of light tend to be absorbed by the dark underlying epithelium, while shorter wavelengths are reflected and undergo Rayleigh scattering in the turbid medium of the stroma

Individuals with albinism have almost no pigment and the pink color of their irises is due to the reflection of incident light from the blood vessels of the stroma.

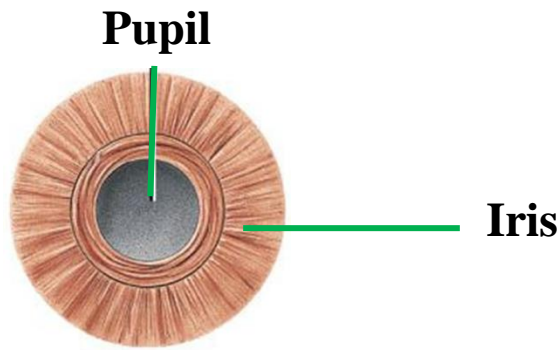




The **Tyndall effect** is scattering of light by particles in a colloid or particles in a fine suspension. It can be seen when the light passes through the colloids or turbid substances causing the light to scatter in multiple directions.




Flour suspended in water  
(appears light blue  
because blue light is  
scattered off the flour  
particles to a greater  
extent than red light)



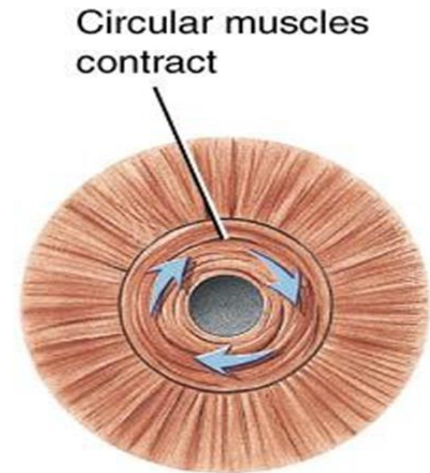
The muscle fibers of the iris are **involuntary** and consist of circular and radiating fibers.

**The circular fibers form the sphincter pupillae**

Nerve supply: is supplied by **parasympathetic** fibers from the oculomotor nerve. After synapsing in the ciliary ganglion, the postganglionic fibers pass forward to the eyeball in the short ciliary nerves.




**Action:**  
The sphincter pupillae constricts the pupil in the presence of bright light and during accommodation



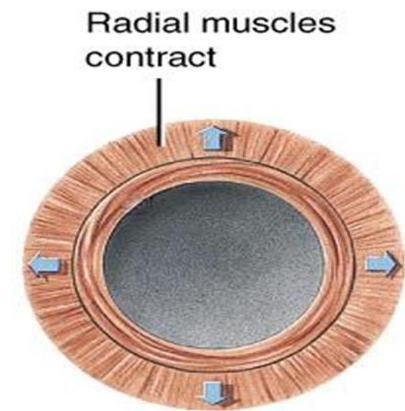
Bright light

**The radial fibers form the dilator pupillae**

Nerve supply: is supplied by **sympathetic** fibers, which pass forward to the eyeball in the long and short ciliary nerves.



**Action:**  
The dilator pupillae dilates the pupil in the presence of light of low intensity or in the presence of excessive sympathetic activity such as occurs in fright



Dim light

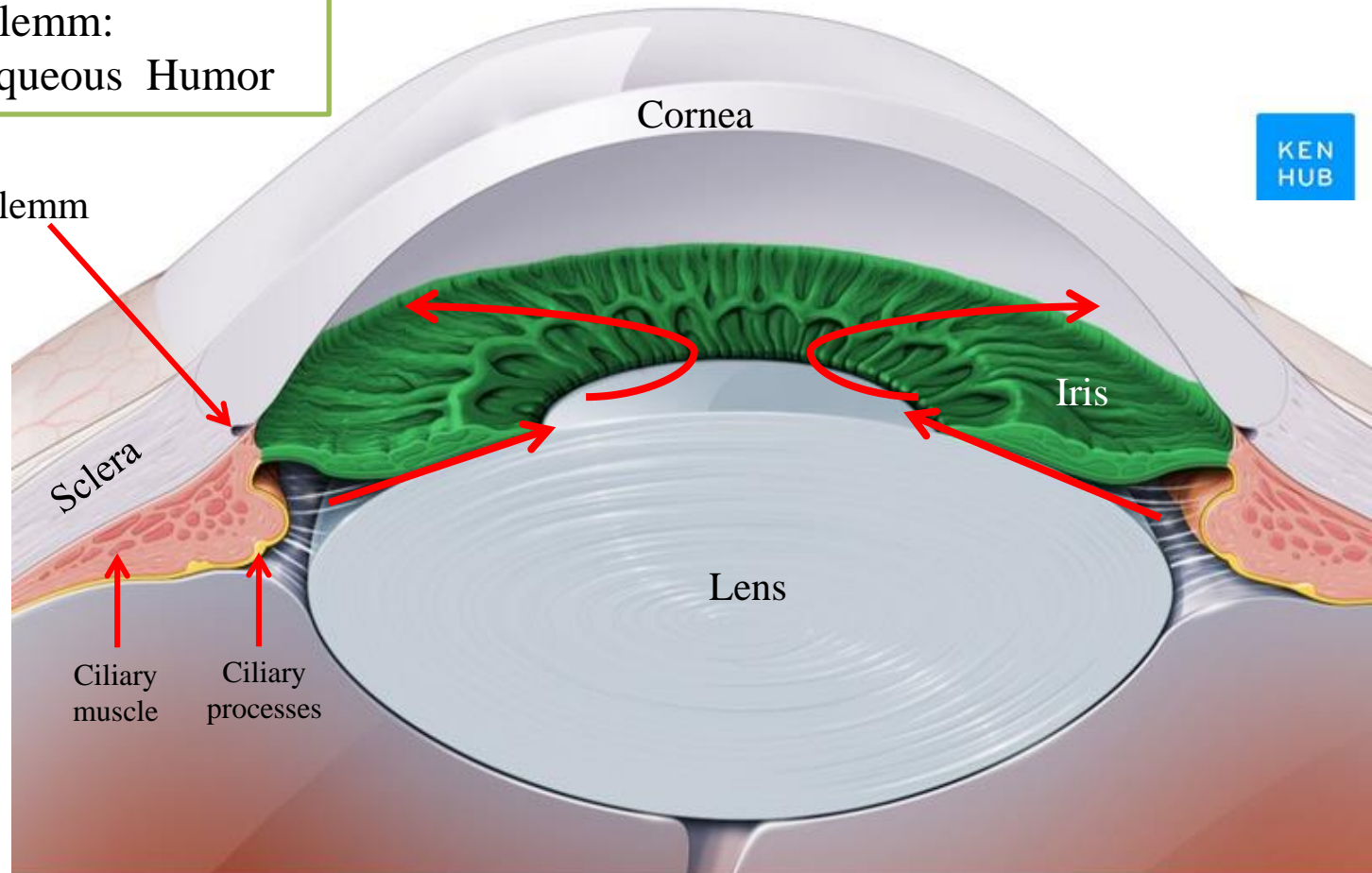
# Production of aqueous humor and intraocular pressure

1. Ciliary Process: Produces Aqueous Humor
2. Posterior Chamber: Aqueous Humor flows from this chamber through the pupil to the Anterior Chamber
3. Canal of Schlemm: Reabsorbs Aqueous Humor

Obstruction to the draining of the aqueous humor results in a rise in intraocular pressure, this may lead to optic neuropathy (glaucoma)

Canal of Schlemm

**Aqueous Humor** is a clear fluid that fills the anterior and posterior chambers of the eyeball



# The Lens

The lens is a transparent, biconvex structure  
It is situated behind the iris and in front of the  
vitreous body  
It focuses light on the retina

## Accommodation of the Eye

To accommodate the eye for close objects,  
the ciliary muscle contracts so that the  
radiating fibers of the suspensory ligament  
are relaxed. This allows the elastic lens to  
assume a more globular shape.

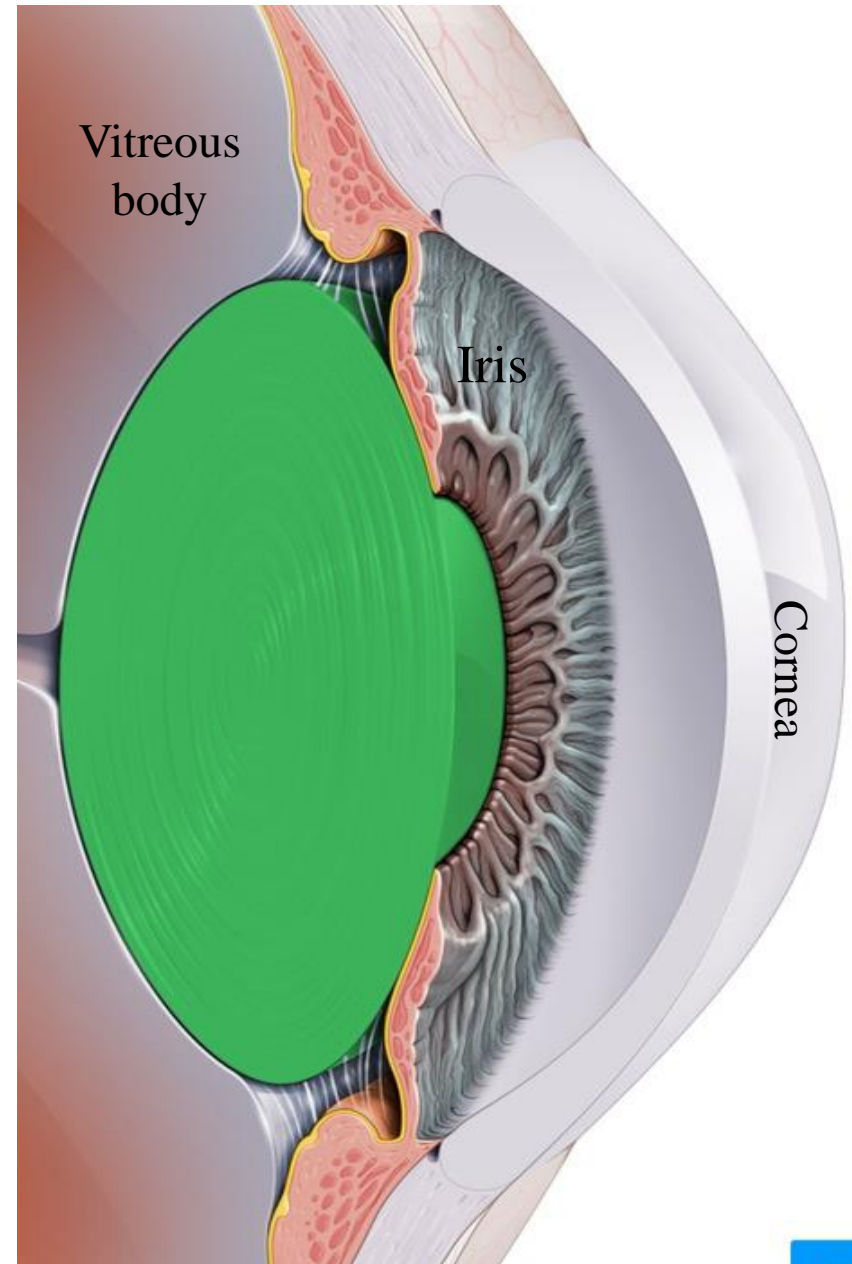


### *Clinical note:*

With advancing age, the lens becomes denser  
and less elastic, and, as a result, the ability to  
accommodate is lessened (**presbyopia**).  
Presbyopia is corrected by wearing glasses  
with convex lenses (reading glasses).

**Presbyopia** (Gr. presbyter, elder + L. opticus, relating to eyes)

The lens is a unique avascular tissue and is  
highly elastic





Lens protein= crystallins

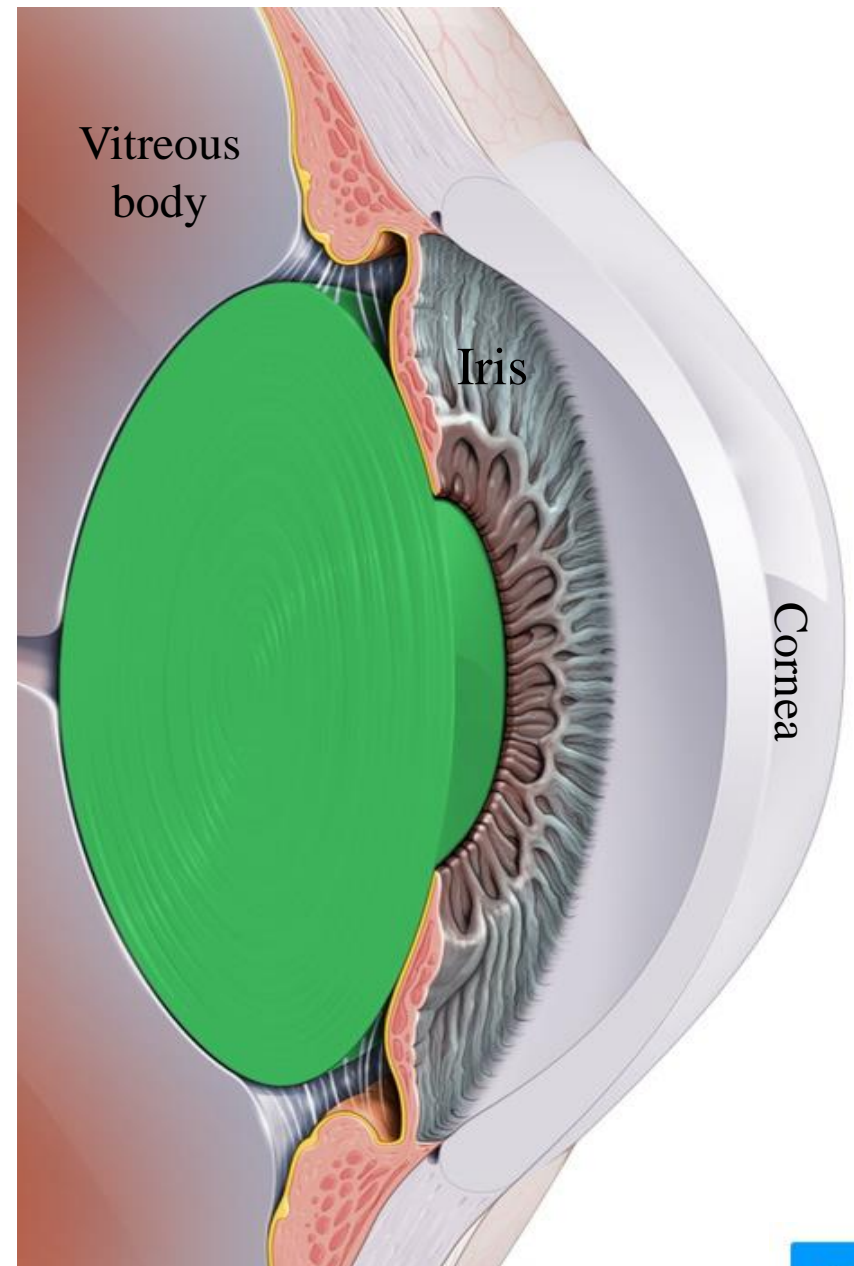


*Clinical notes:*

In older individuals, denaturation of crystallins commonly begins to occur in lens fibers, making them less transparent. When areas of the lens become opaque or cloudy and vision is impaired, the condition is termed a **cataract**.

*A **cataract** is a cloudy area that forms in the lens of the eye*

Causes of cataract include excessive exposure to ultraviolet light or other radiation, trauma, and as secondary effects in diseases such as diabetes mellitus and hypertension.



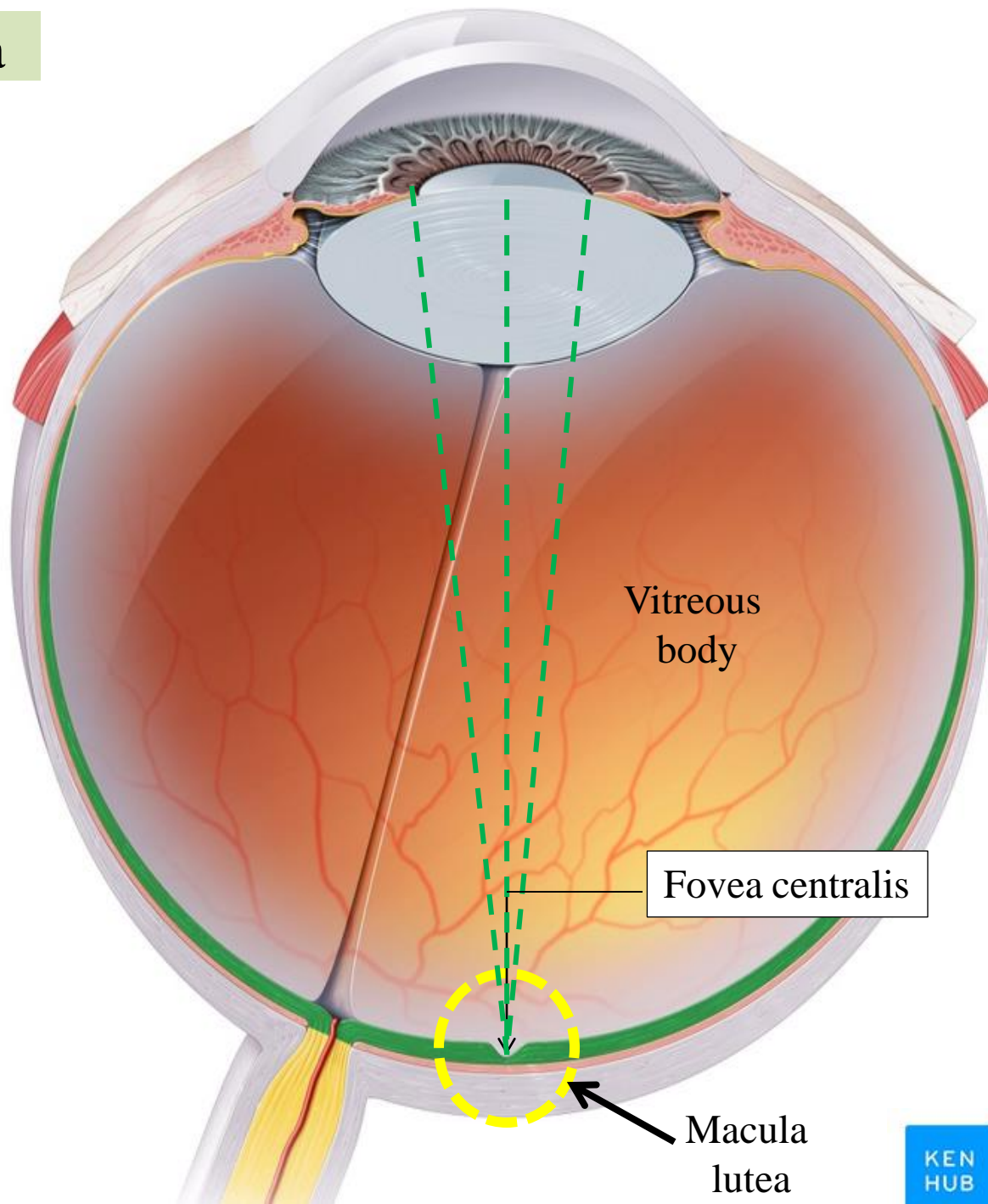
## Nervous Coat: The Retina

The retina consists of an outer pigmented layer and an inner nervous layer

Its outer surface is in contact with the choroid, and its inner surface is in contact with the vitreous body

At the center of the posterior part of the retina is an oval, yellowish area, the **macula lutea**, which is the area of the retina for the most distinct vision.

It has a central depression, the fovea centralis



# Nervous Coat: The Retina

## Component:

Pigmented layer: Pigmented epithelial cells

Neural layer:

Photoreceptors, bipolar neurons, ganglion cells, and supporting Müller cells

## Function:

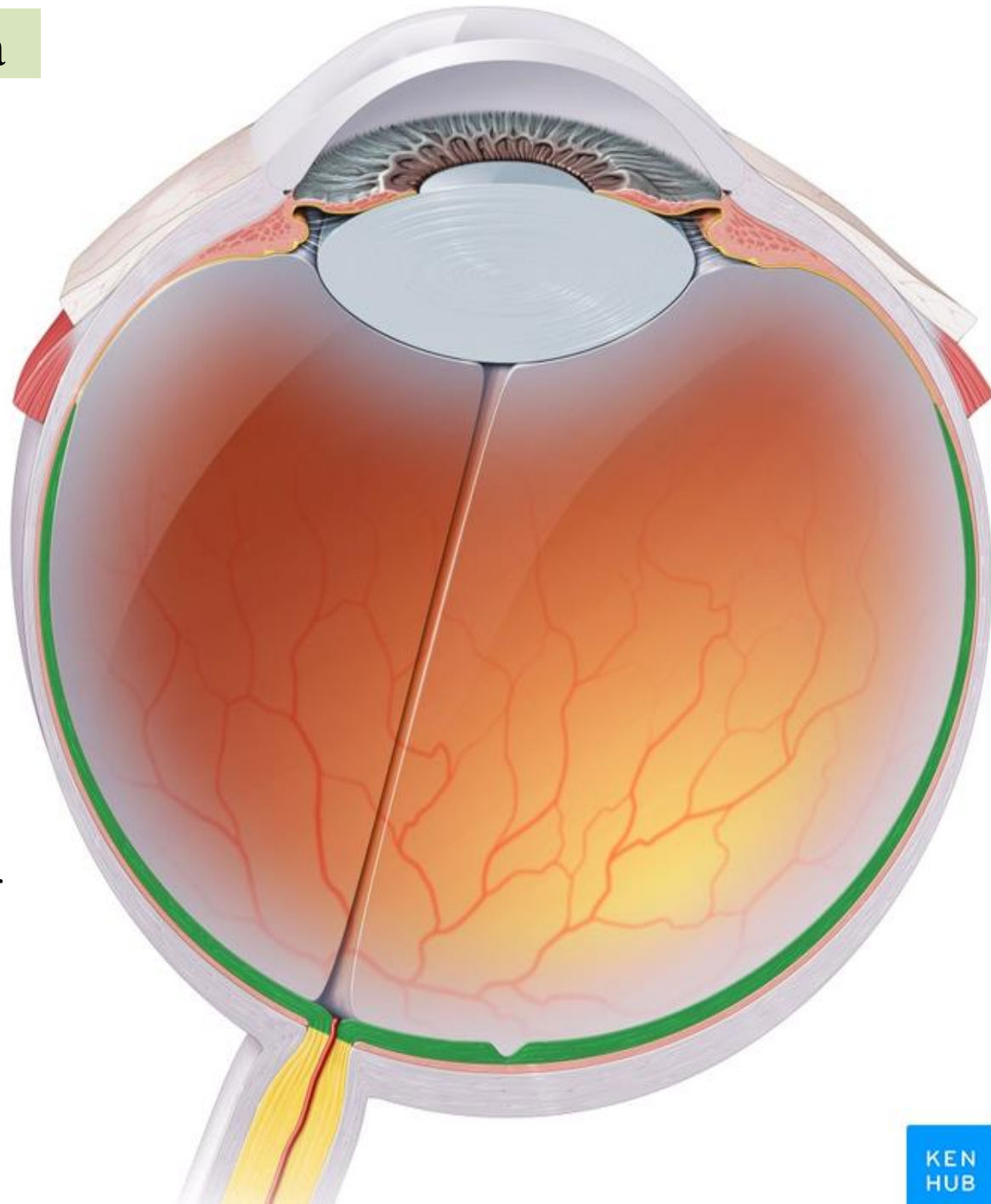
Pigmented layer:

Absorbs extraneous light (supplementing the choroid in this regard)

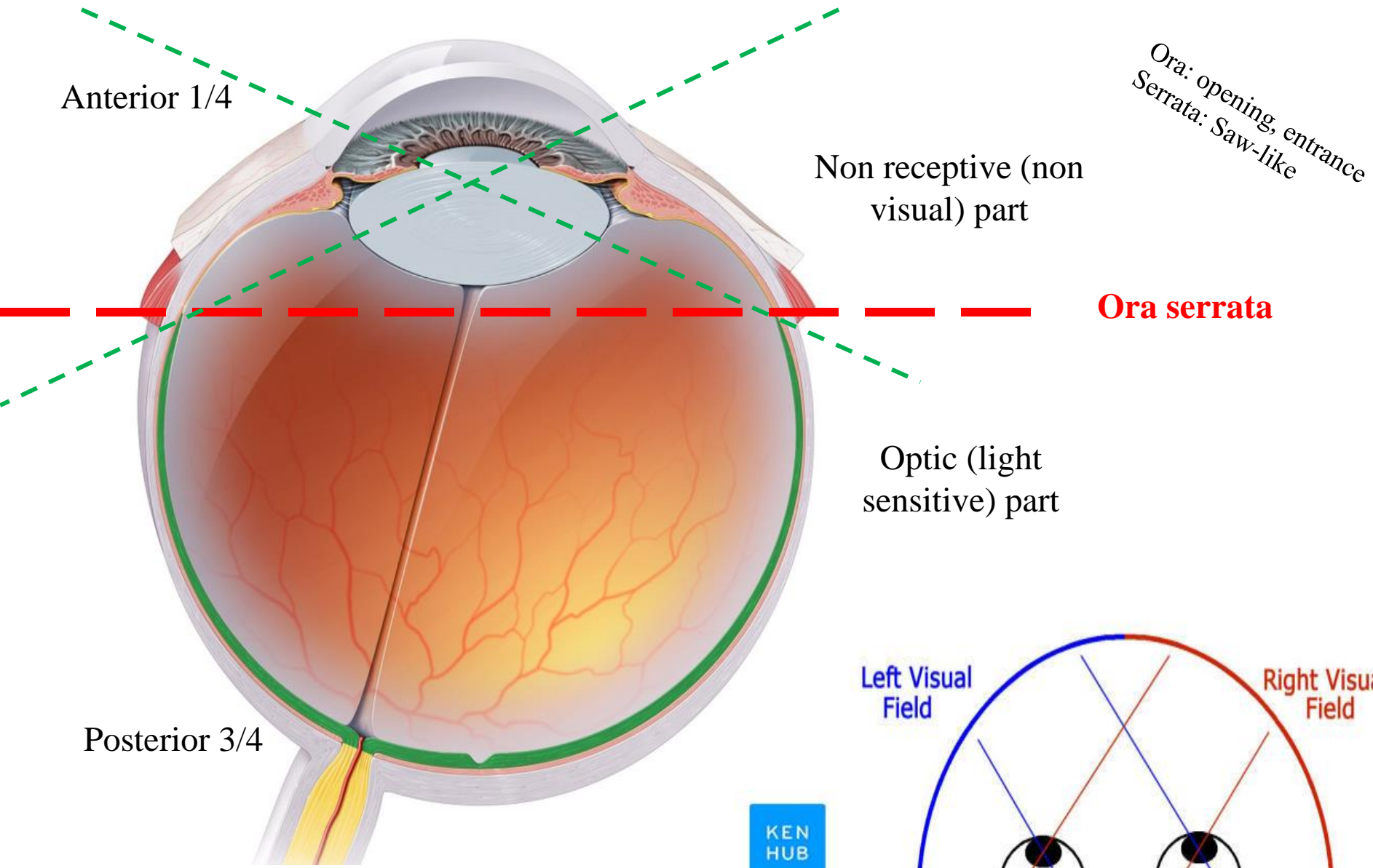
Provides vitamin A for photoreceptor cells

Neural layer:

Detects incoming light rays; light rays are converted to nerve signals and transmitted to the brain



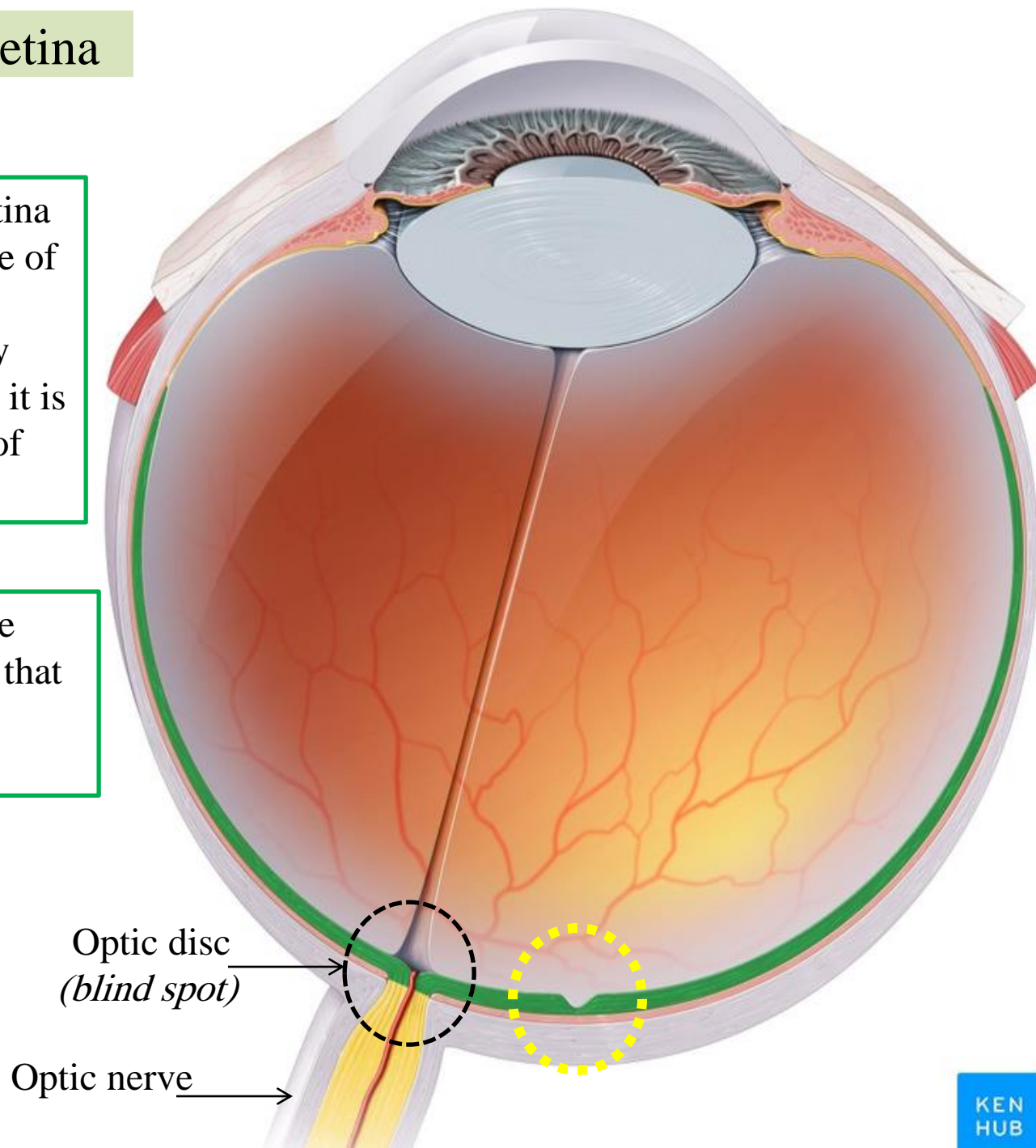


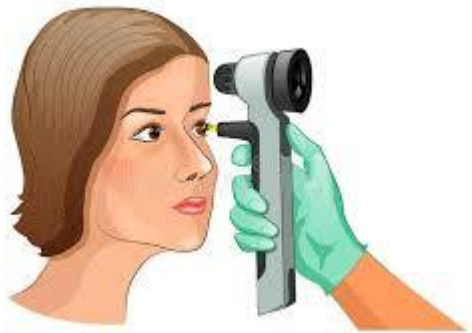

## Nervous Coat: The Retina

The optic nerve leaves the retina about 3 mm to the medial side of the macula lutea by the **optic disc**. The optic disc is slightly depressed at its center, where it is pierced by the central artery of the retina

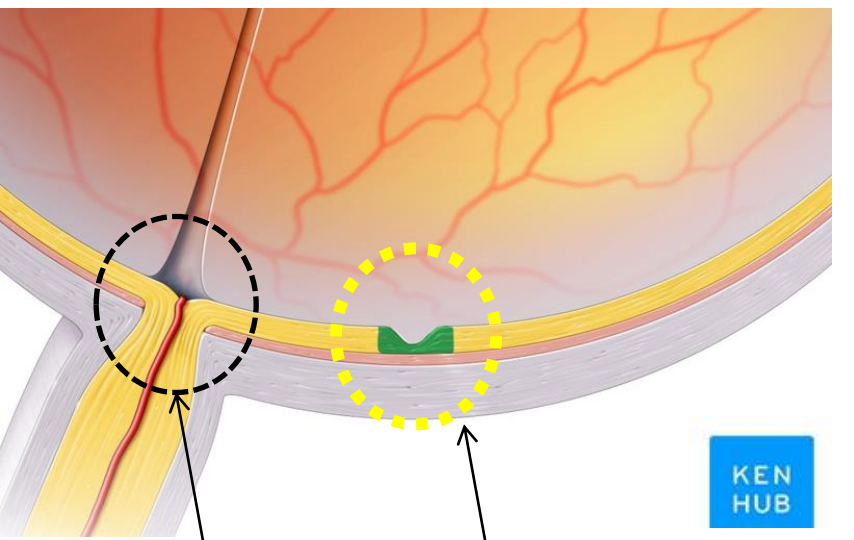
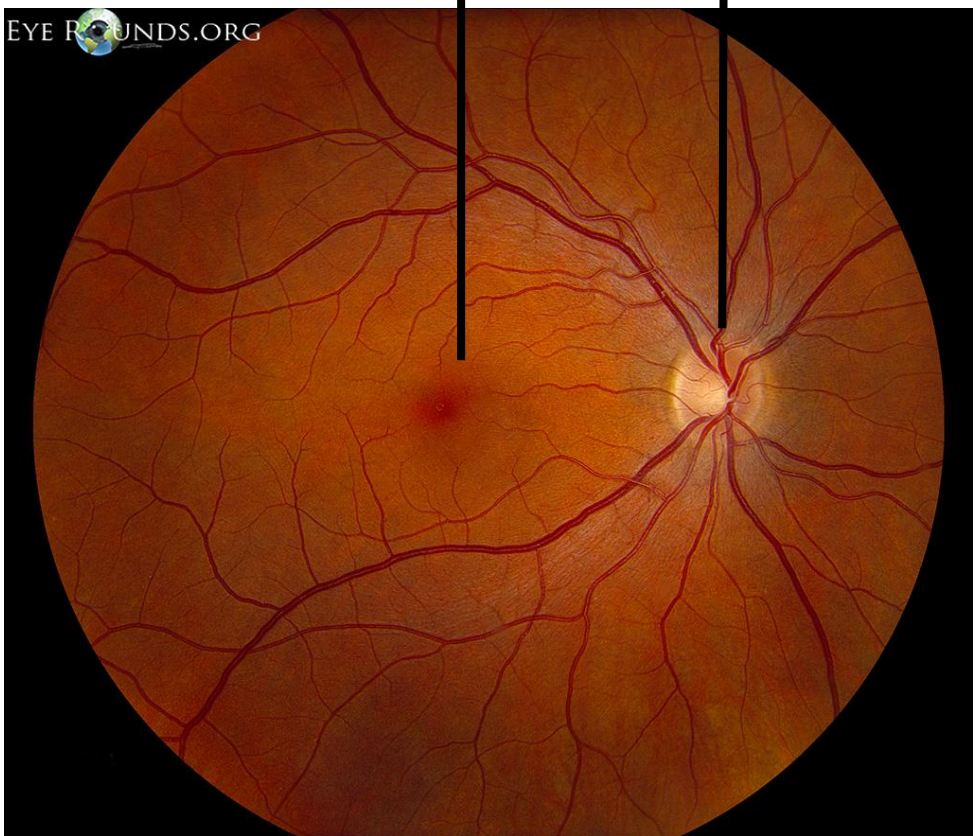
At the optic disc is a complete absence of rods and cones so that it is insensitive to light and is referred to as the **blind spot**





Macula lutea with fovea centralis

Optic disc



Optic disc  
(blind spot)

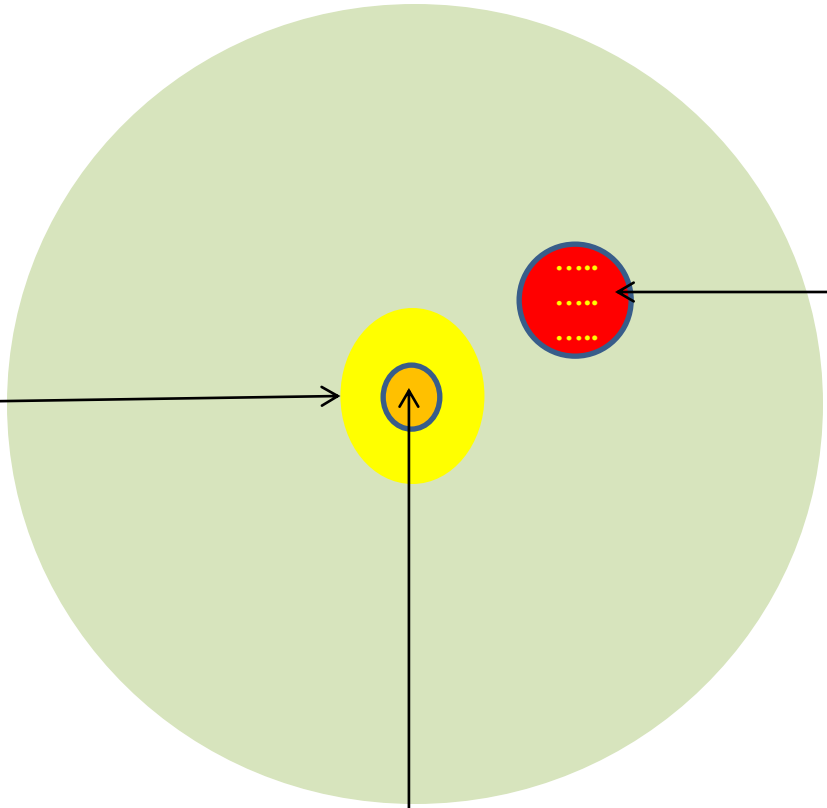
Macula lutea with  
fovea centralis

Ophthalmoscopic (Fundoscopic)  
examination of the right eye



Temporal

Nasal



**Macular lutea**  
(yellow, inferolateral)

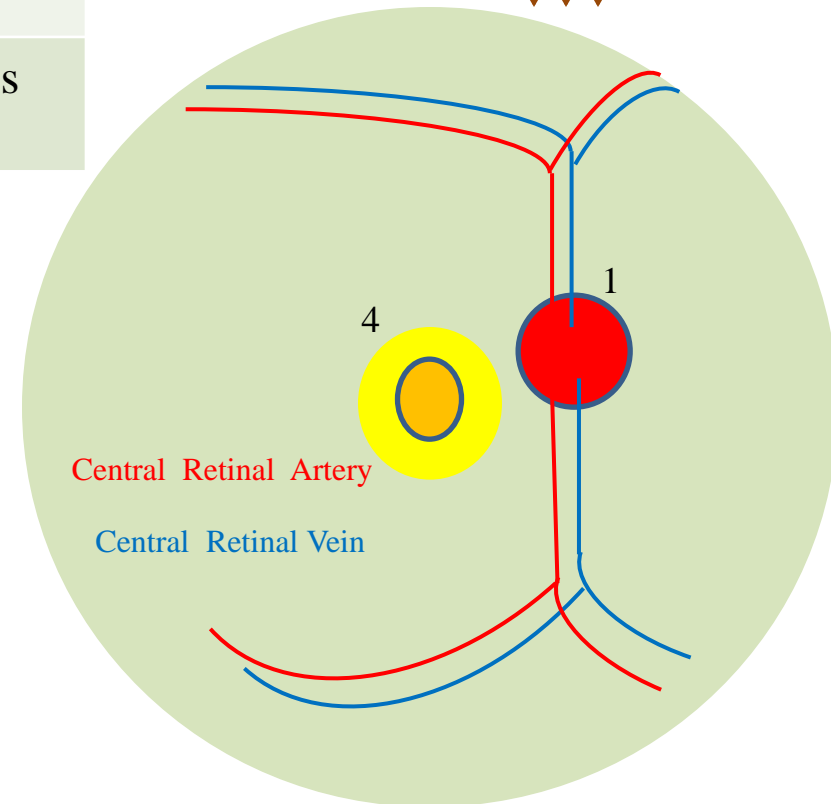
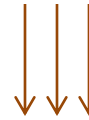
**Optic disc**  
(superiomedial)  
Where optic nerve fibers  
pass through  
Blind spot (no rods and  
cones)

**Fovea centralis**  
The point of sharpest vision  
Highest concentration of cones

Fundoscopic/  
Ophthalmoscopic  
Exam  
RT eyeball

Macula lutea (4)	Optic disc (1)
Central depression: fovea centralis	Central depression: physiological cupping
Fovea centralis is the point of sharpest vision	Blind spot (no rods and cones)
Diffuse margins	Sharp margins
Lateral and slightly Inferior	Medial and slightly Superior
Avascular	Vascular (blood vessels entering/ leaving)

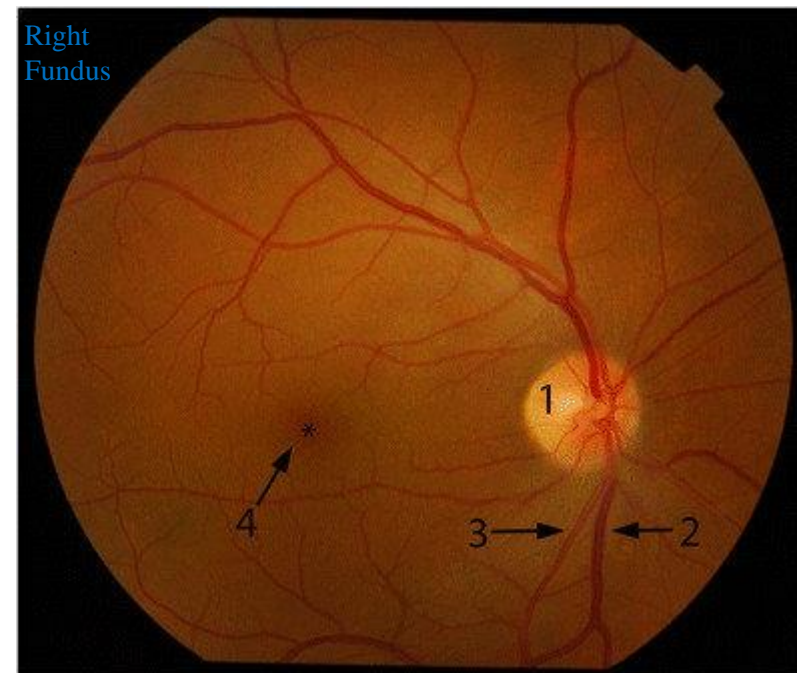
These are end arteries  
They don't communicate/  
anastomose with each other



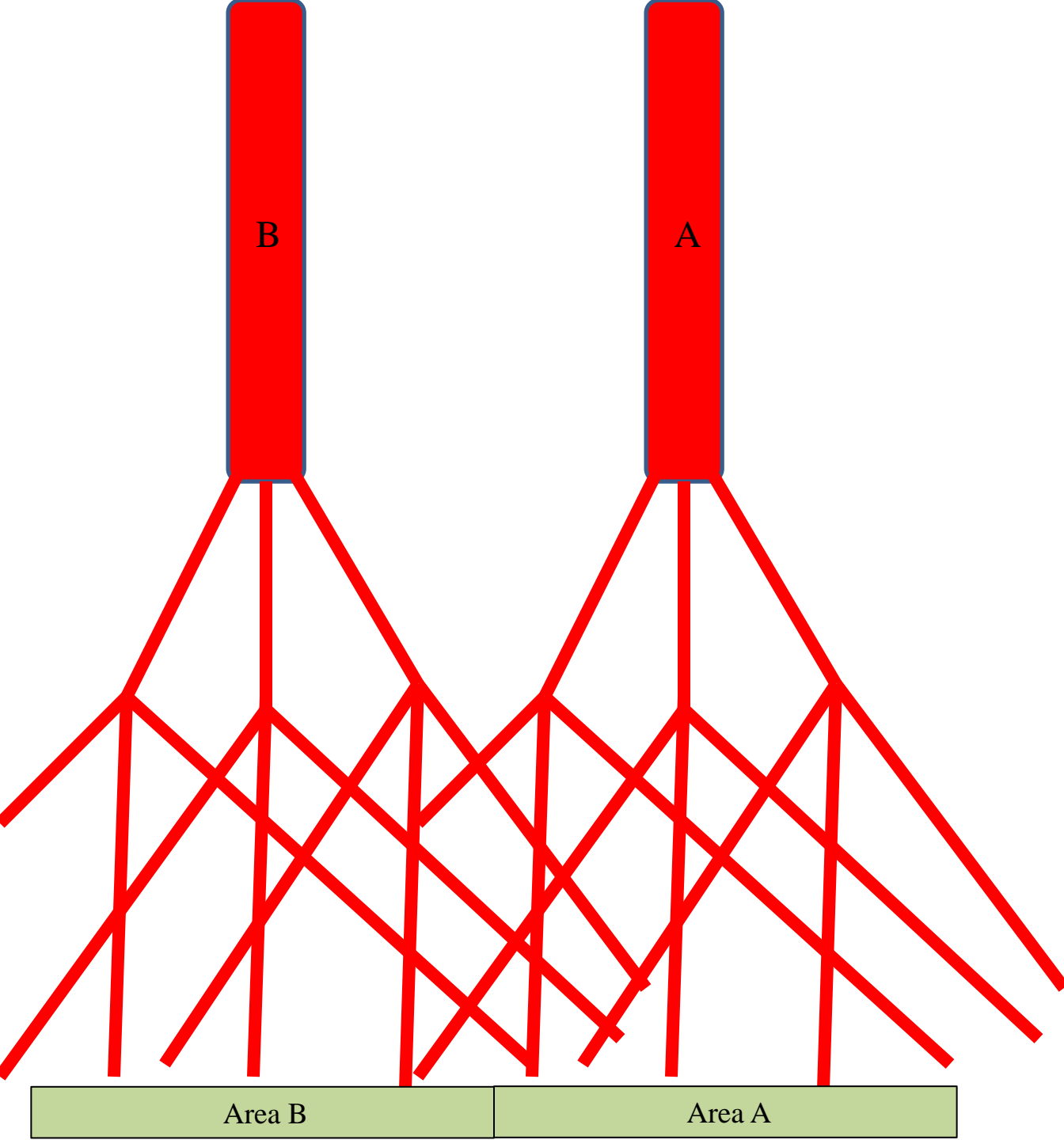
Central Retinal Artery

Central Retinal Vein

Right Fundus

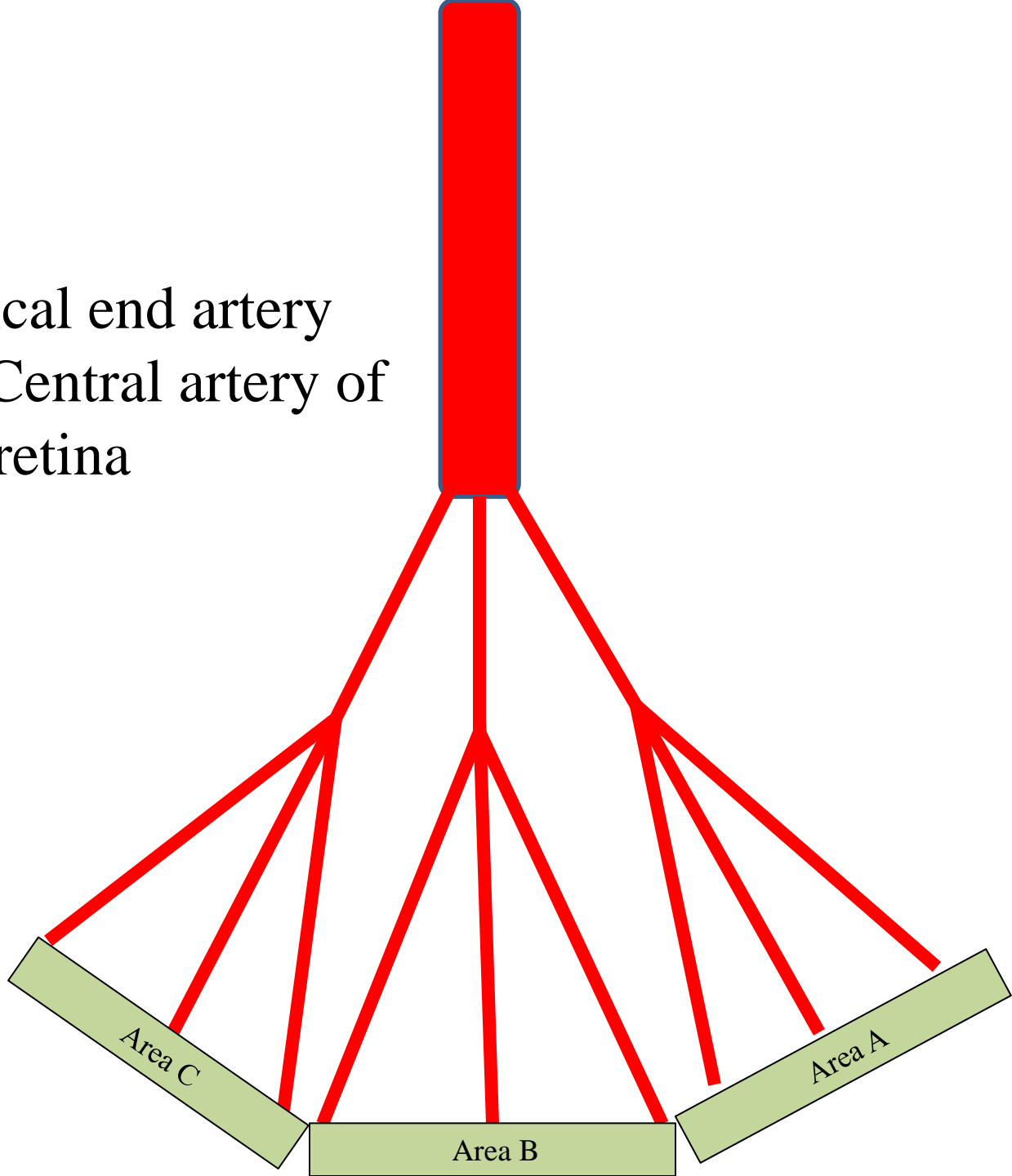


Right Fundus





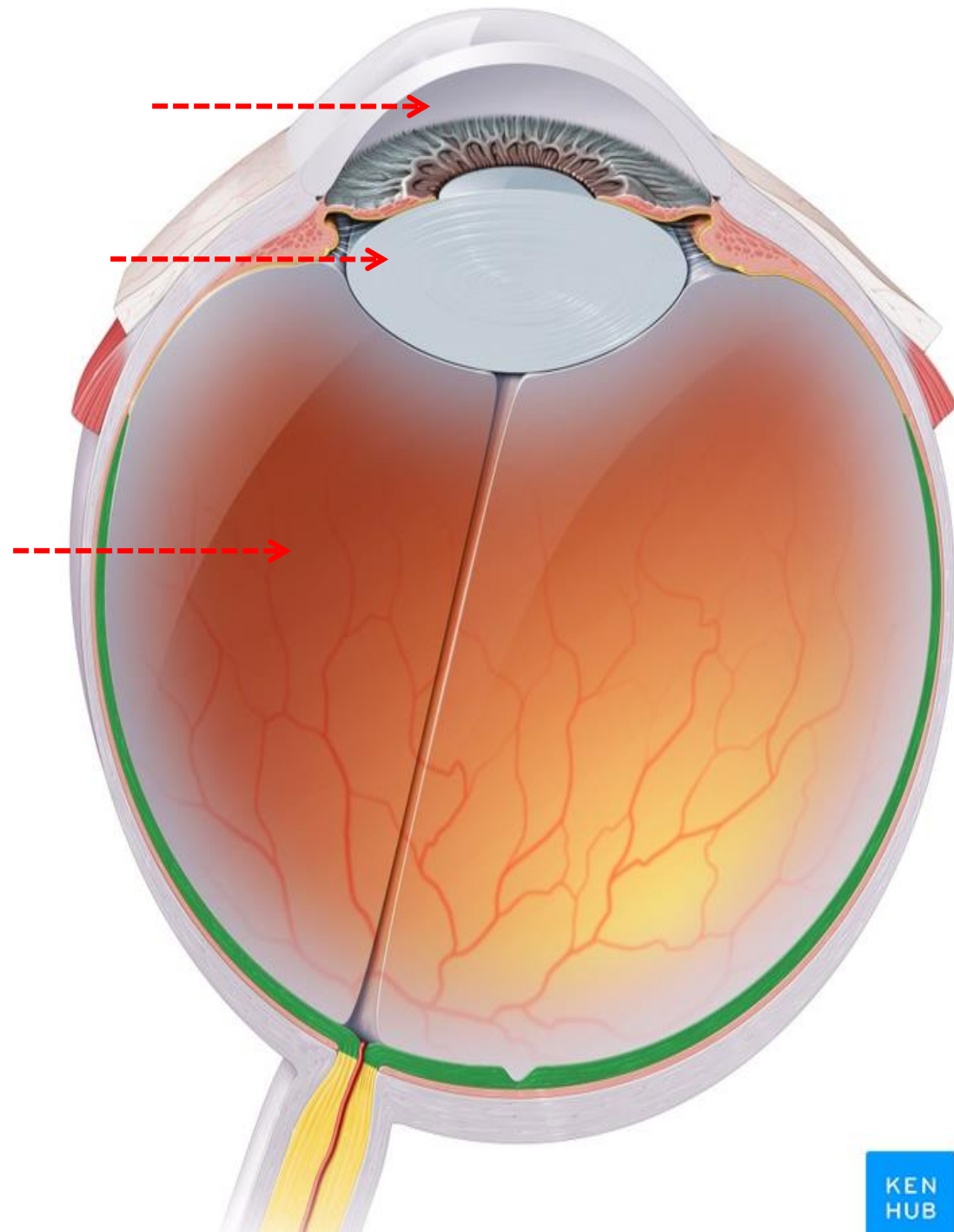
Anatomical end artery  
Example: Central artery of retina



# Contents of the Eyeball

The contents of the eyeball consist of:

- 1-THE AQUEOUS HUMOR
- 2-THE VITREOUS BODY
- 3- THE LENS



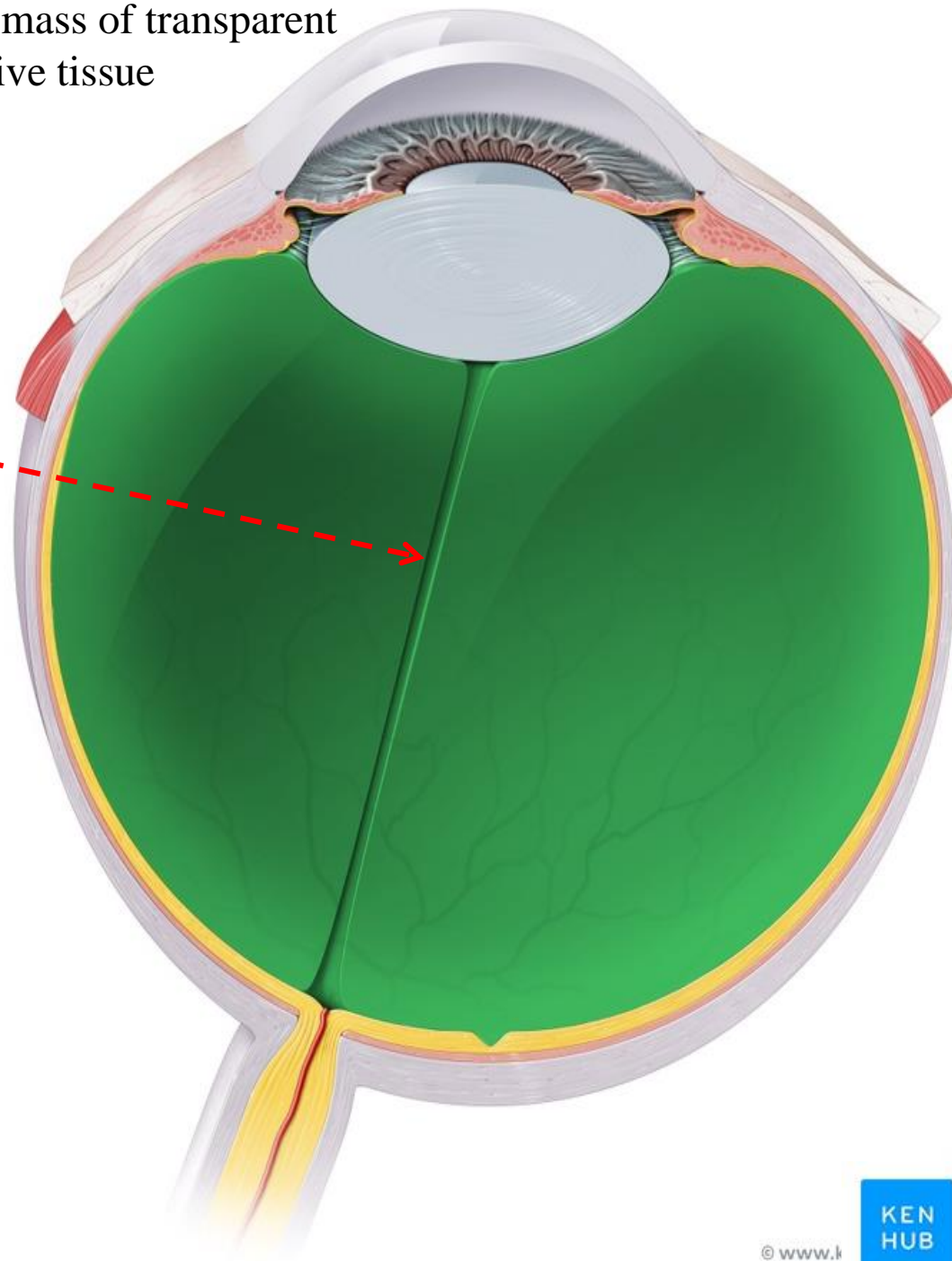
# Vitreous Body

A large gelatinous mass of transparent connective tissue

The vitreous body fills the eyeball behind the lens and is a transparent gel.

The **hyaloid canal** is a narrow channel that runs through the vitreous body from the optic disc to the posterior surface of the lens; in the fetus, it is filled by the hyaloid artery, which disappears before birth.

The function of the vitreous body is to contribute slightly to the magnifying power of the eye. It supports the posterior surface of the lens and assists in holding the neural part of the retina against the pigmented part of retina



Detached retina !!!



**Ocular blood supply**

**Supratrochlear artery**

**External nasal artery**

**Supraorbital artery**

Anterior ethmoidal artery

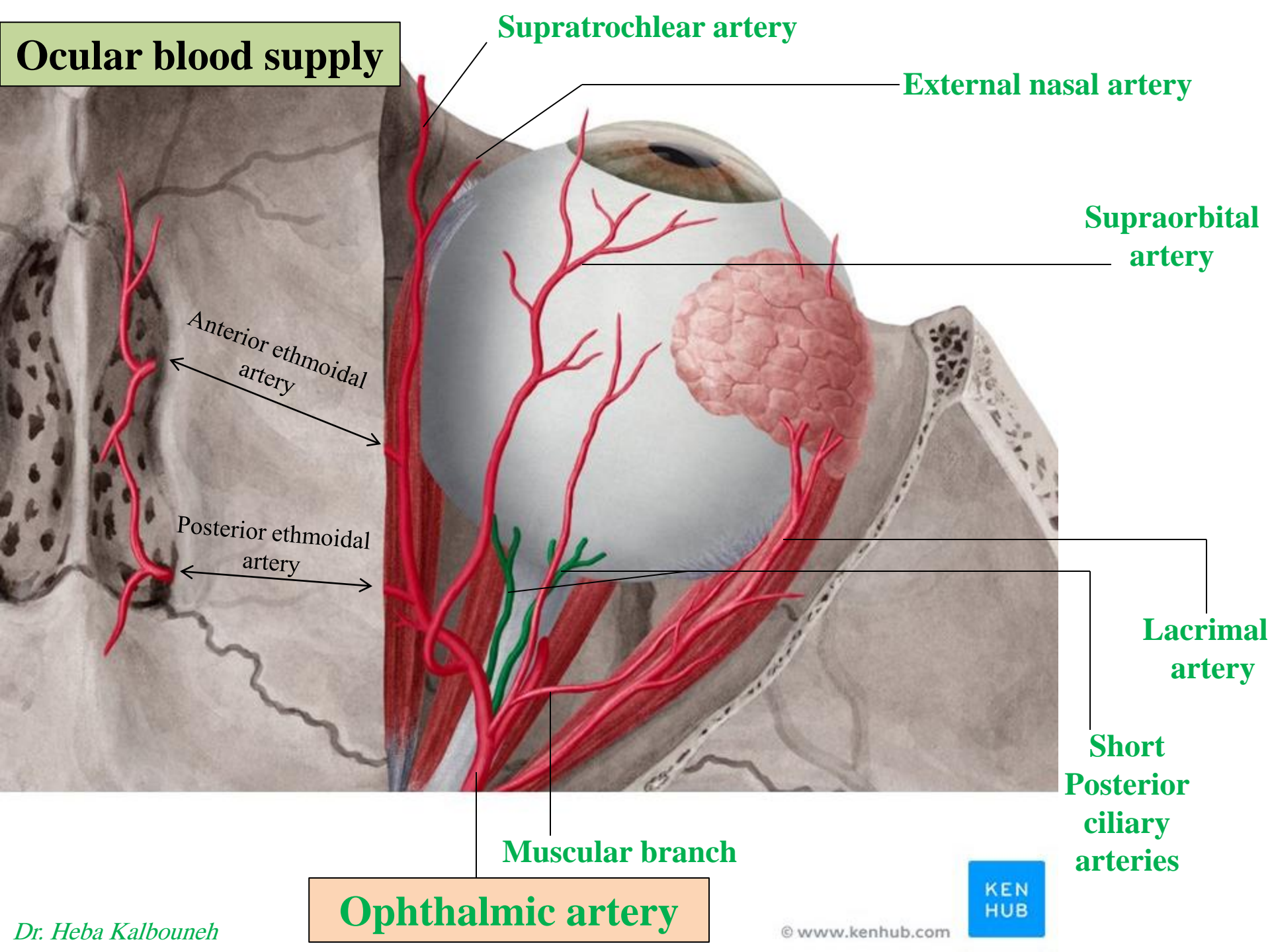
Posterior ethmoidal artery

**Lacrimal artery**

**Short Posterior ciliary arteries**

**Muscular branch**

**Ophthalmic artery**



## Ocular blood supply

✓ The arterial input to the eye is provided by several branches from the ophthalmic artery, which is derived from the internal carotid

✓ These branches include:

Central retinal artery

Short and long posterior ciliary arteries

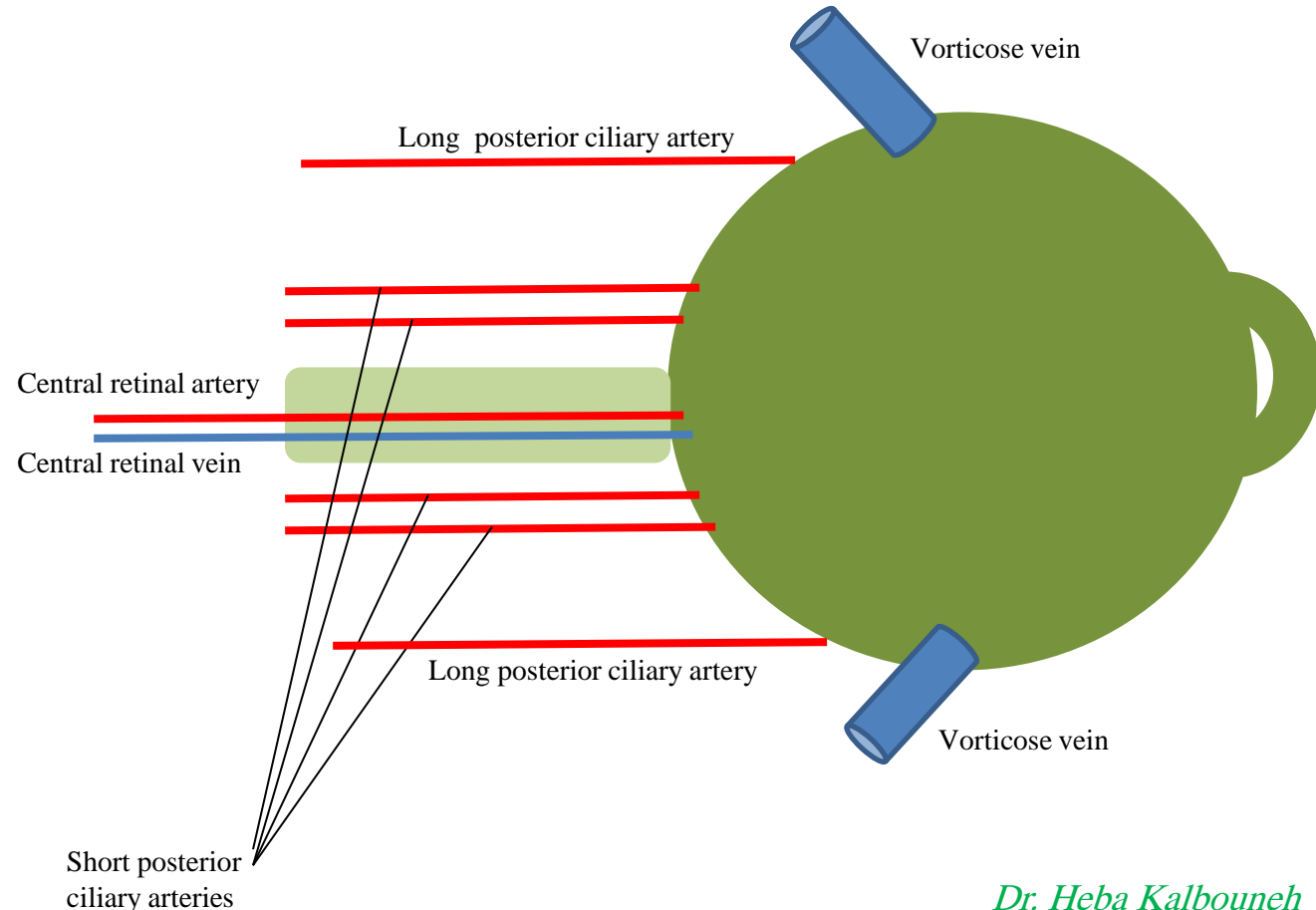
Anterior ciliary arteries

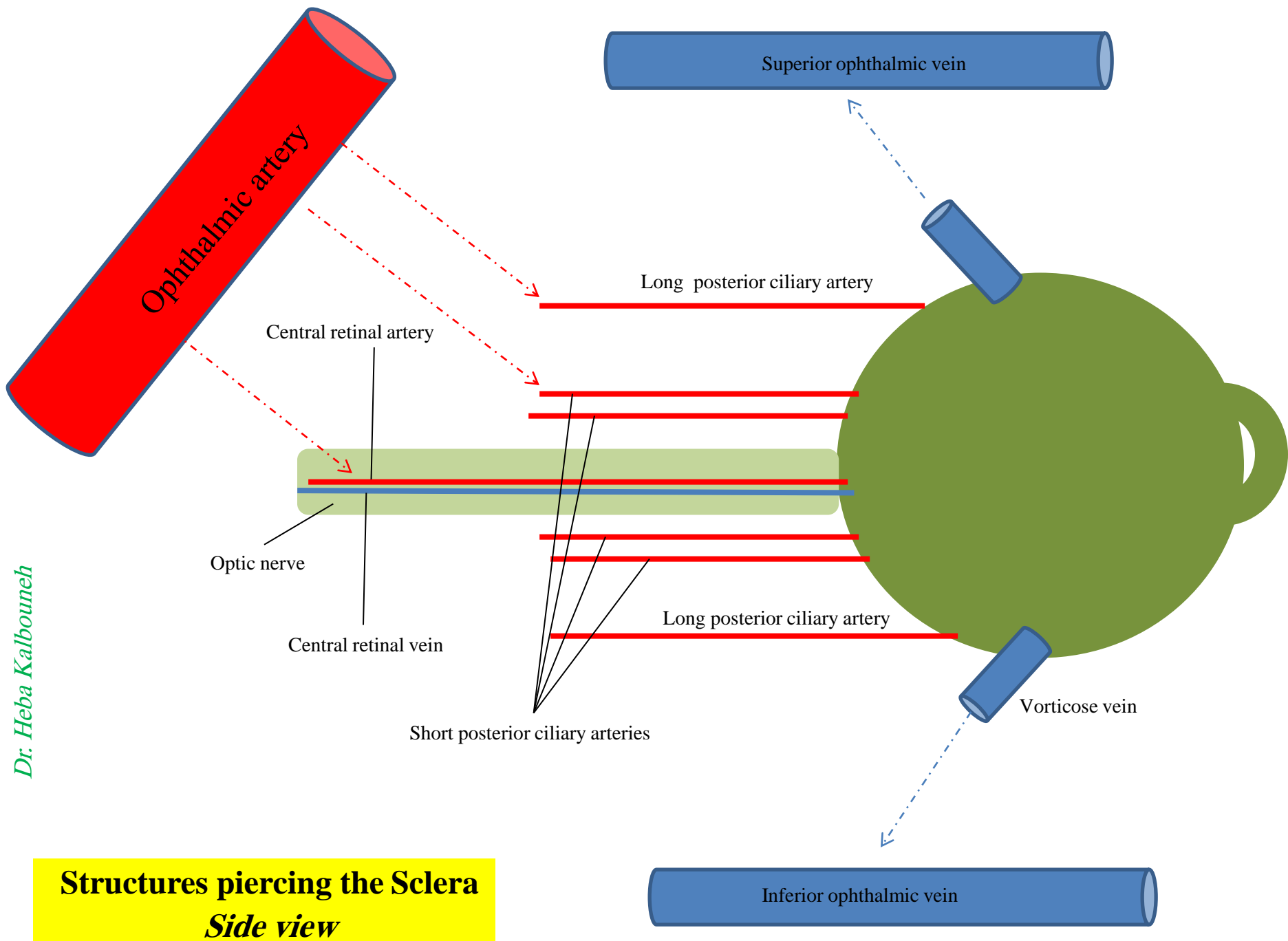
✓ Venous outflow from the eye is primarily via the vortex veins and the central retinal vein, which merge with the superior and inferior ophthalmic veins that drain into the cavernous sinus, the pterygoid venous plexus and the facial vein

The short posterior ciliary arteries: (from 6-12 in number) pierce the posterior part of the sclera just around the optic nerve.

The long posterior ciliary arteries: (2 in number) pierce the posterior part of the sclera at some little distance from the optic nerve.

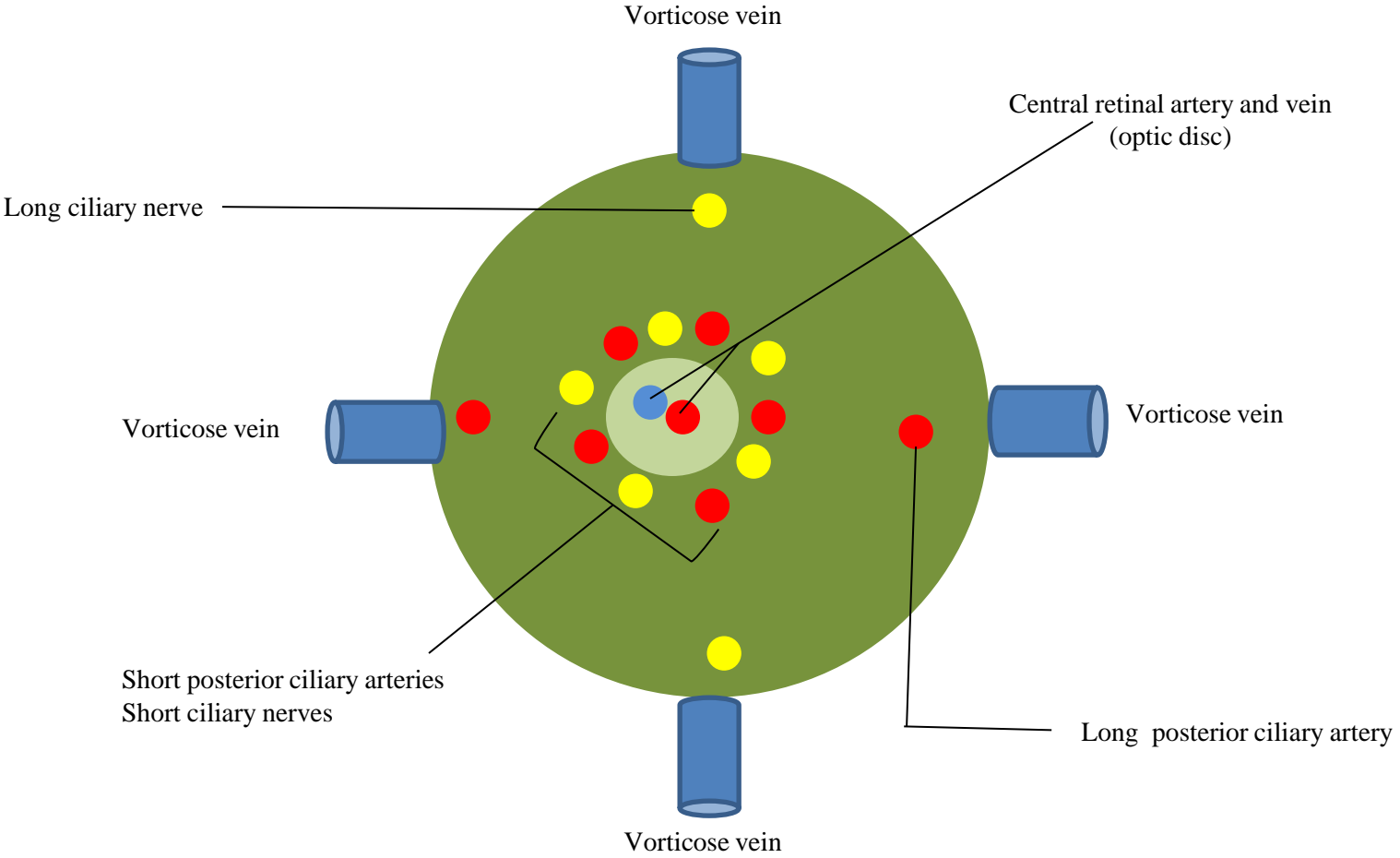
The anterior ciliary arteries are derived from the muscular branches of the ophthalmic artery.





**Structures piercing the Sclera**  
*Side view*

*Dr. Heba Kalbouneh*



**Structures piercing the Sclera**  
*posterior view*



Some vortex veins drain into the superior ophthalmic vein which drains into the cavernous sinus  
Some vortex veins drain into the inferior ophthalmic vein which drains into the pterygoid plexus and cavernous sinus 😊

The **vorticose veins (vortex veins)** (mostly 4 in number) drain the ocular choroid

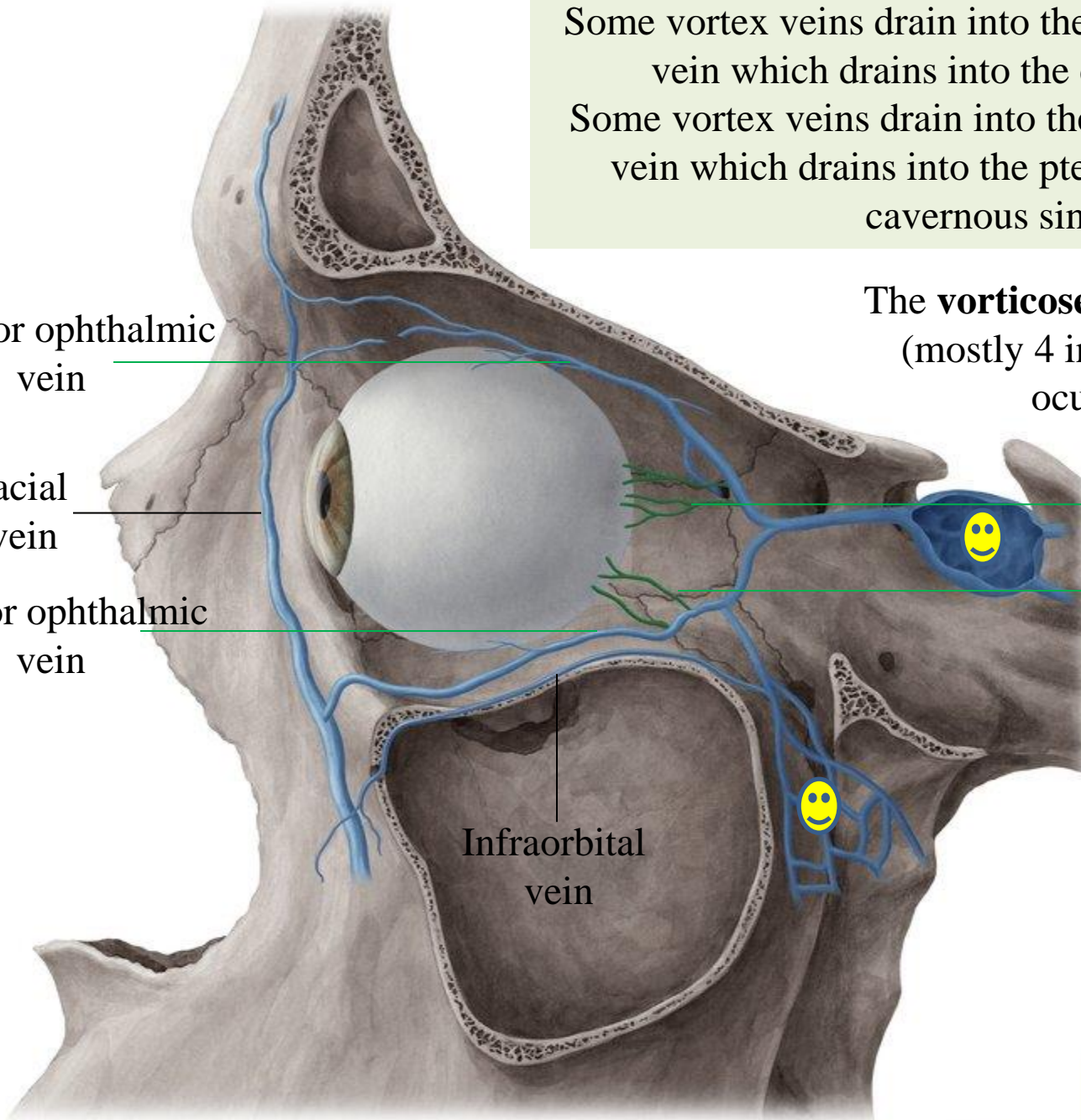
Varicose veins

Superior ophthalmic vein

Facial vein

Inferior ophthalmic vein

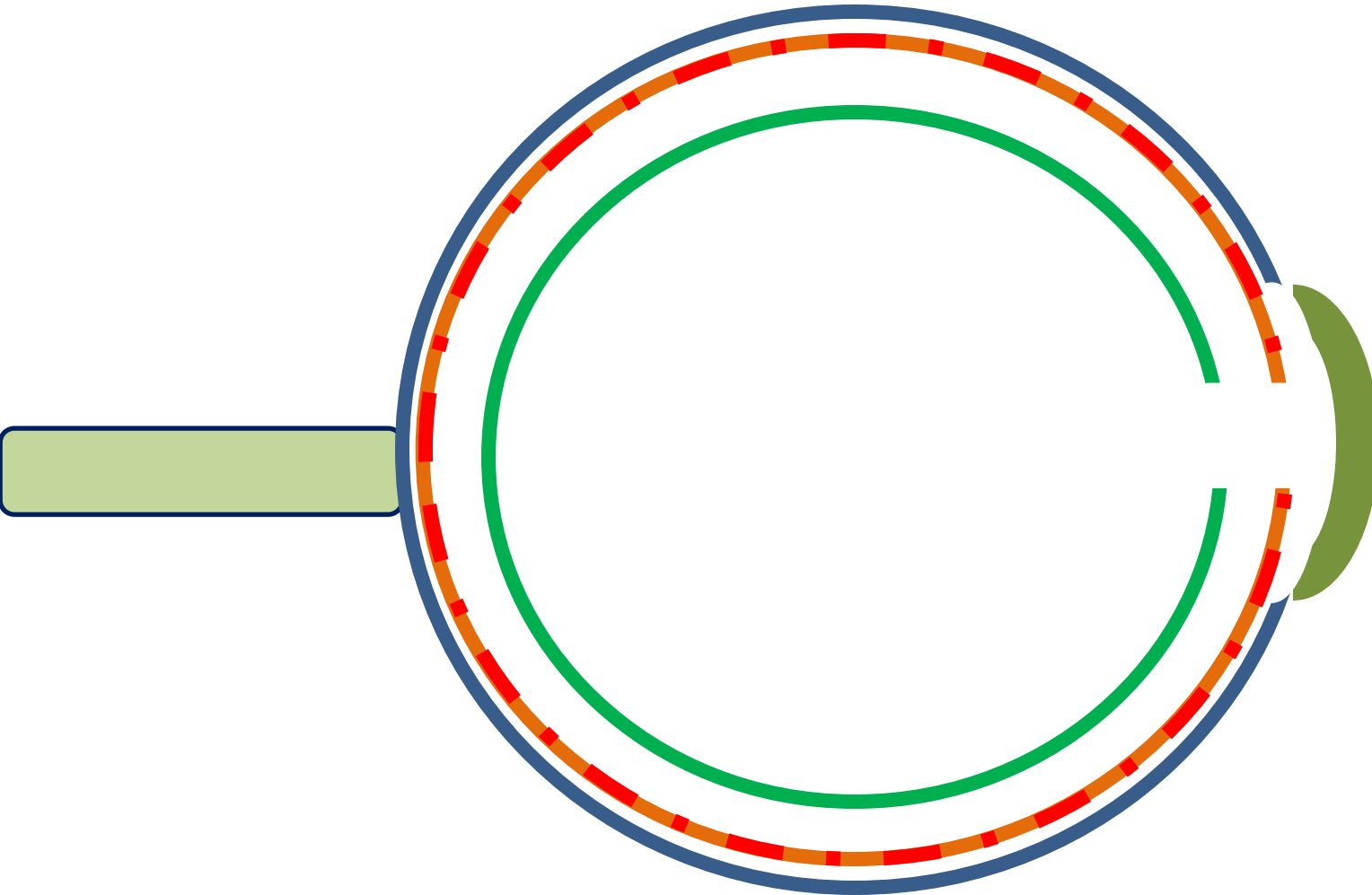
Infraorbital vein




**Sclera**

**Choroid**

**Retina**

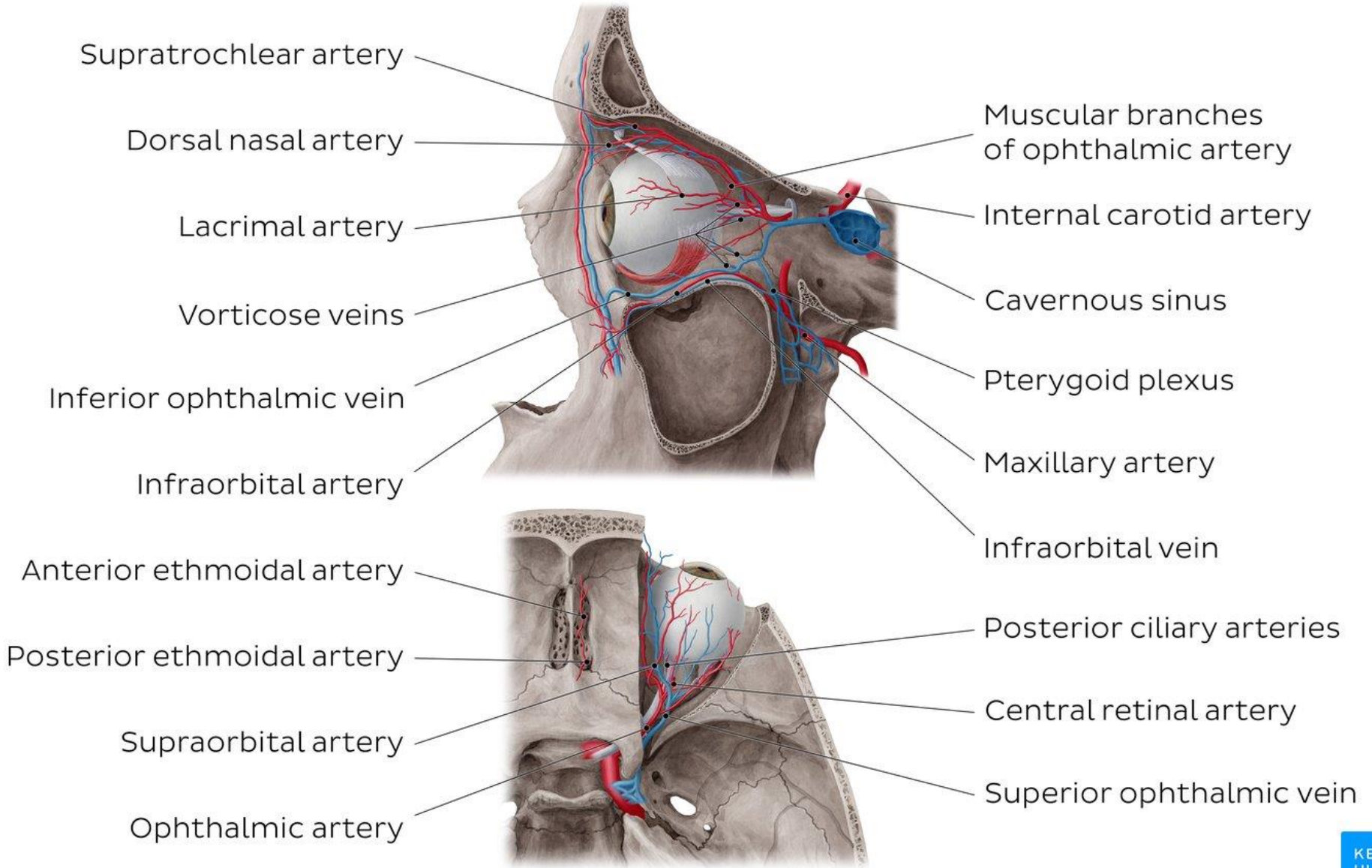


**Sclera**  
**Choroid**  
**Retina**



Note: The choroidal arteries arise from long and short posterior ciliary arteries  
The corresponding veins drain into the vortex veins

The **choriocapillaris** is an extensive, anastomosing capillary system derived from the choroidal vessels





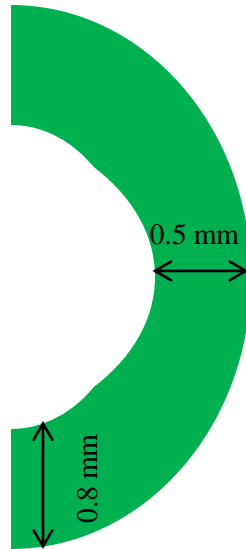
The human cornea is about 0.5 mm thick at the center, increasing somewhat towards the periphery

# Histology of cornea

Cornea is:  
Two layers of epithelium with organized connective tissue in between

## Functions

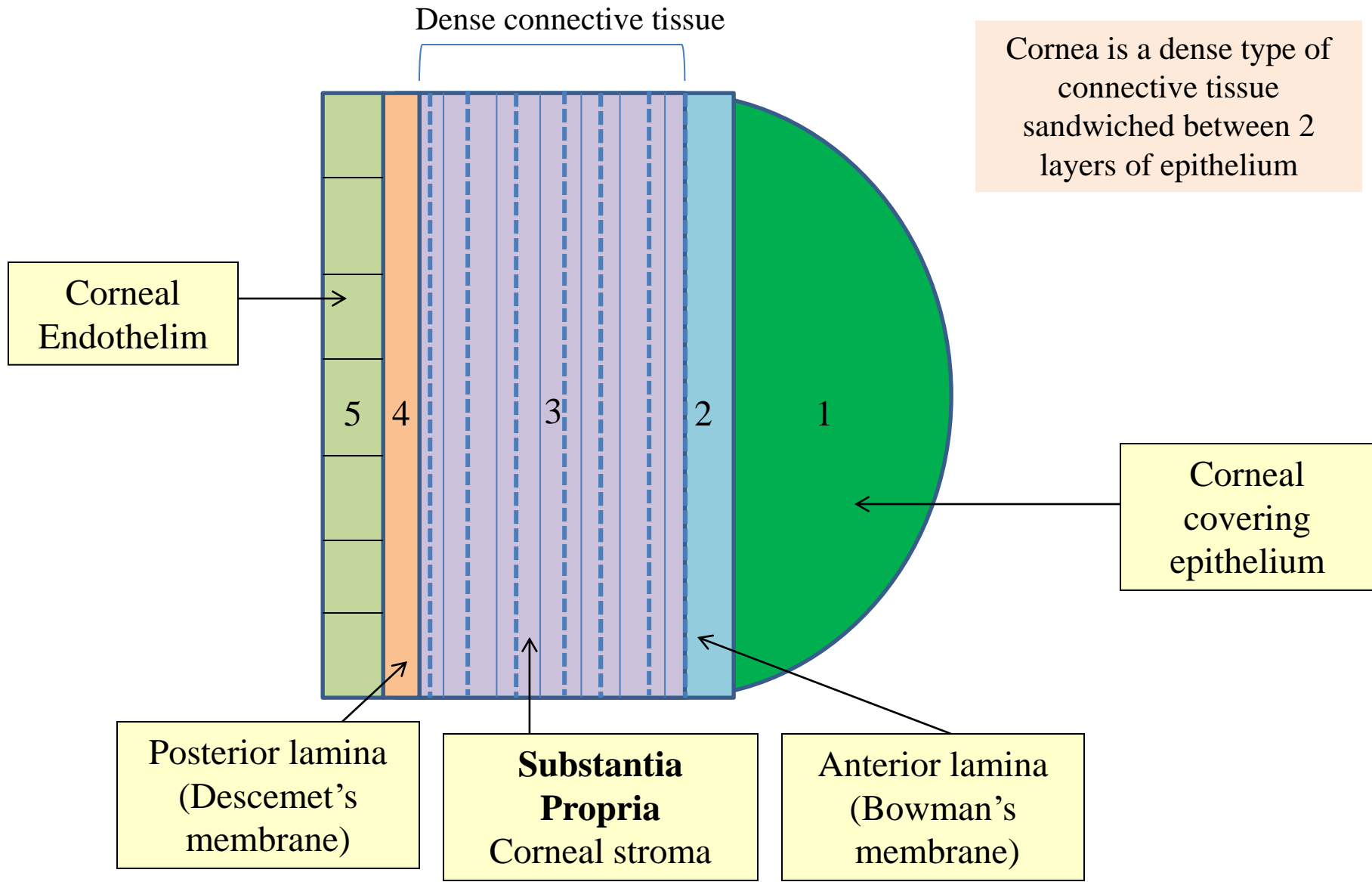
- 1- Transmission of light (as it is transparent)
- 2- Refraction of light for better focus (as it is curved)
- 3- Plays a role in structural integrity of the eyeball (as its tough)
- 4- Protection

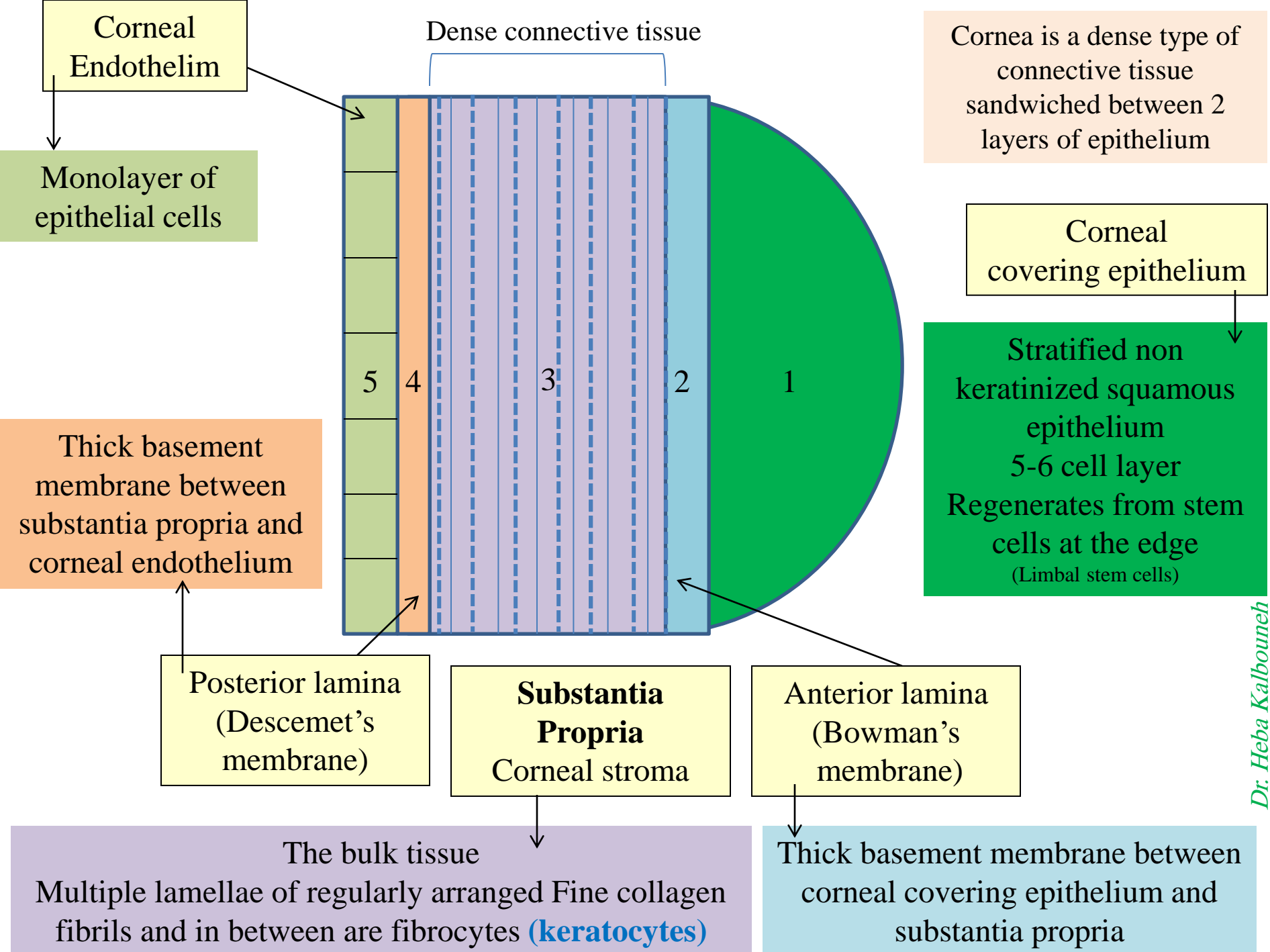


A section of the cornea shows five distinct layers:

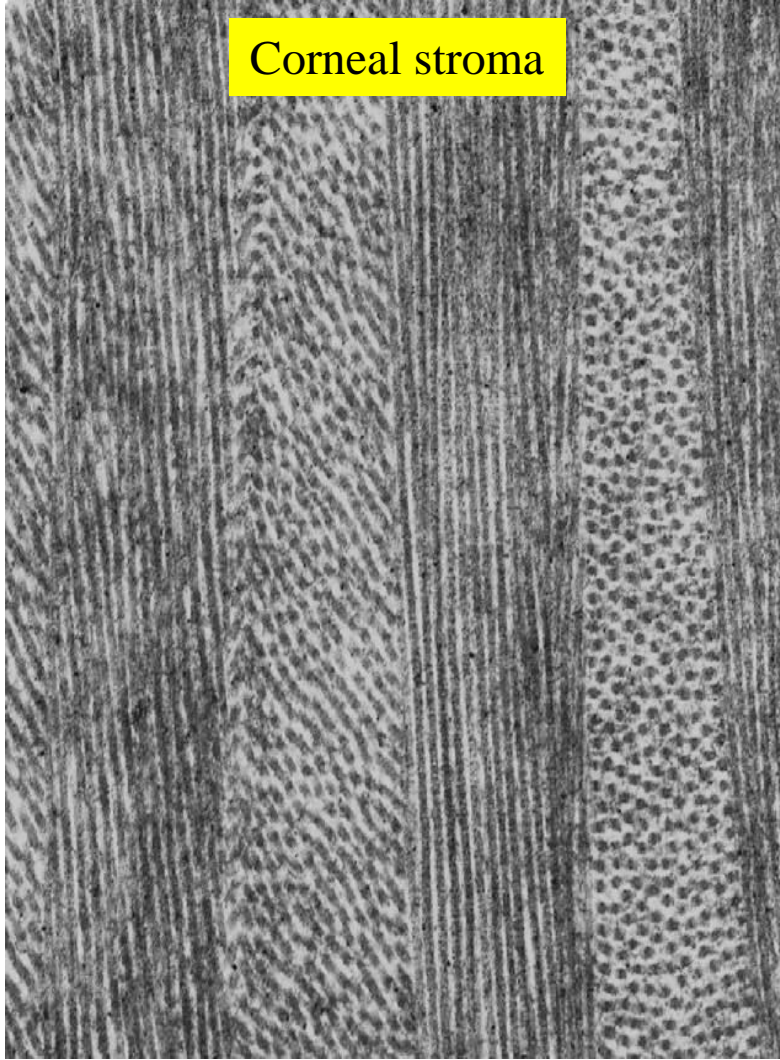
- ✓ An external stratified squamous epithelium non keratinized
- ✓ An anterior limiting membrane (Bowman's membrane), which is the basement membrane of the external stratified epithelium
- ✓ A thick stroma
- ✓ A posterior limiting membrane (Descemet's membrane), which is the basement membrane of the endothelium
- ✓ An inner monolayer of epithelial cells (endothelium).

The cornea can be reshaped by surgical procedures  
(**LASIK**)

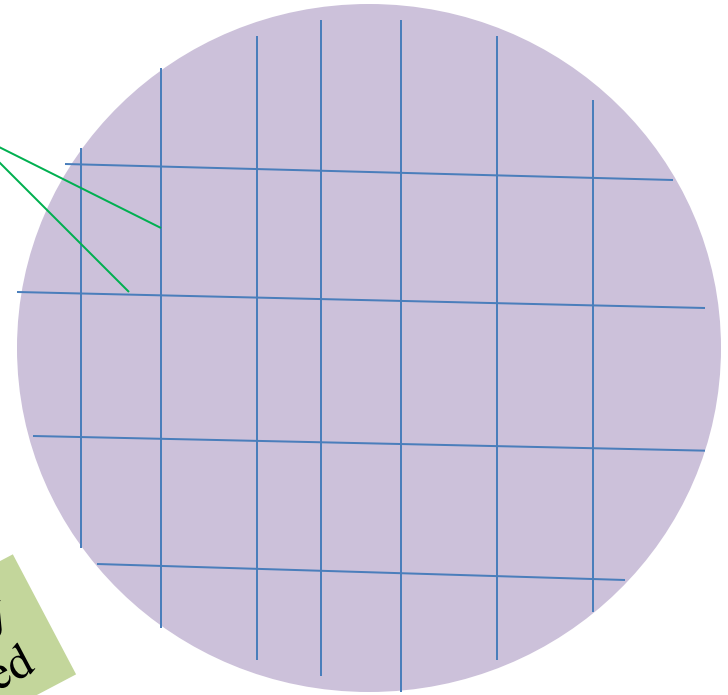




Corneal stroma



Collagen lamella



Is relatively dehydrated

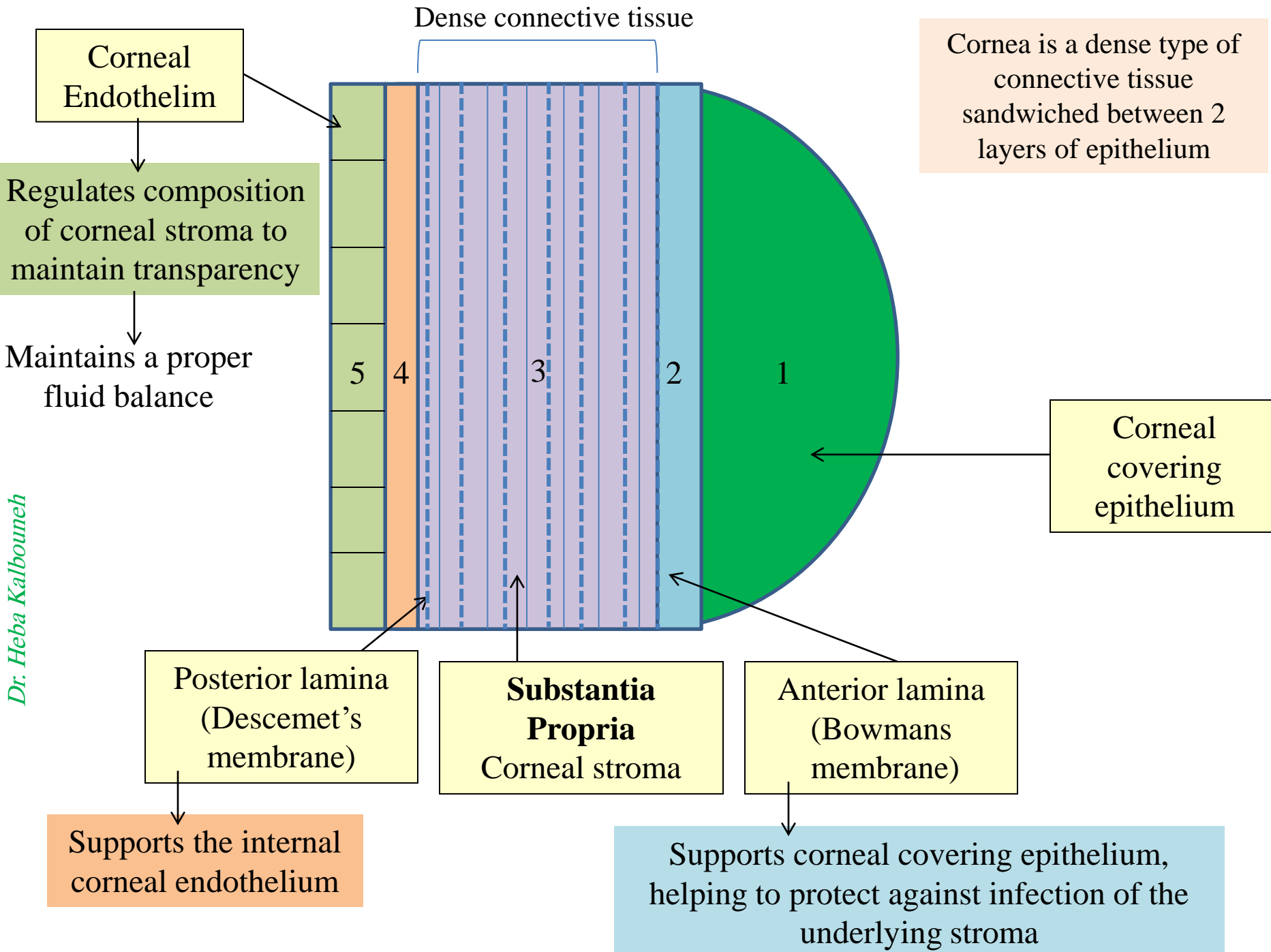
Around 250 Collagen lamellae are arranged vertically and horizontally forming a lattice

*NOTE: Collagen fibrils are parallel and are superimposed like book pages*

The uniform arrangement of collagen fibrils contributes to the transparency of this avascular tissue

The fibrils are spaced apart by a ground substance that is essentially a hydrated gel of proteoglycans





Cornea is a dense type of connective tissue sandwiched between 2 layers of epithelium

Corneal Endothelium

Regulates composition of corneal stroma to maintain transparency

Maintains a proper fluid balance

Corneal covering epithelium

Posterior lamina (Descemet's membrane)

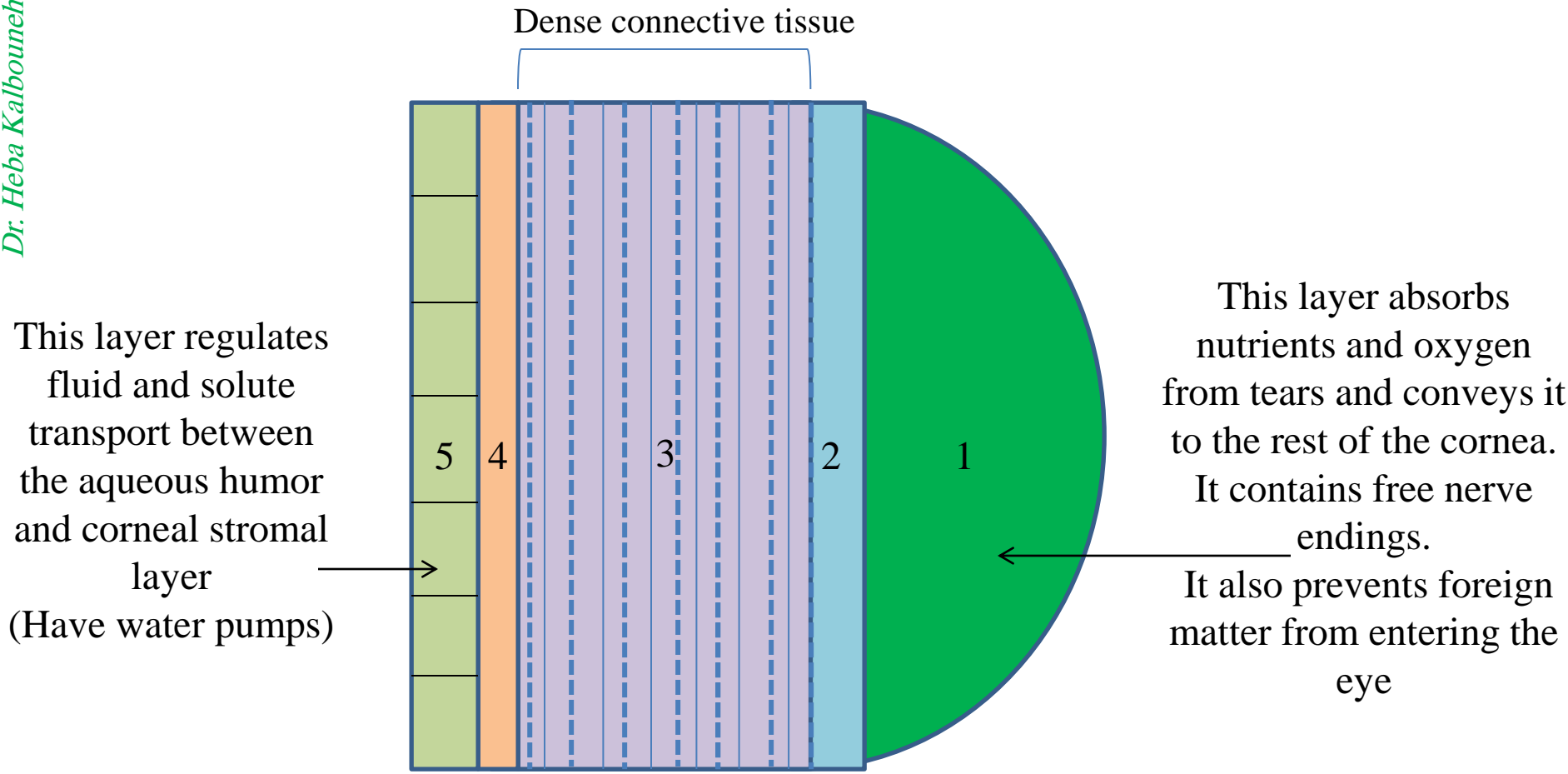
Supports the internal corneal endothelium

**Substantia Propria**  
Corneal stroma

Anterior lamina (Bowmans membrane)

Supports corneal covering epithelium, helping to protect against infection of the underlying stroma

Dr. Heba Kalbouneh



Layers 1 and 5 prevent excess fluid build up in stromal layer, stromal swelling and subsequent loss of transparency

**More fluid**

↓ ↓

Cornea becomes opaque

Aging!!!

The shape or curvature of the cornea can be changed surgically to improve certain visual abnormalities involving the ability to focus.

In the common ophthalmologic procedure, laser-assisted in situ keratomileusis (LASIK) surgery, the corneal epithelium is displaced as a flap and the stroma reshaped by an excimer laser which vaporizes collagen and keratocytes in a highly controlled manner with no damage to adjacent cells or ECM. After reshaping the stroma, the epithelial flap is repositioned and a relatively rapid regenerative response reestablishes normal corneal physiology.

Clinical notes

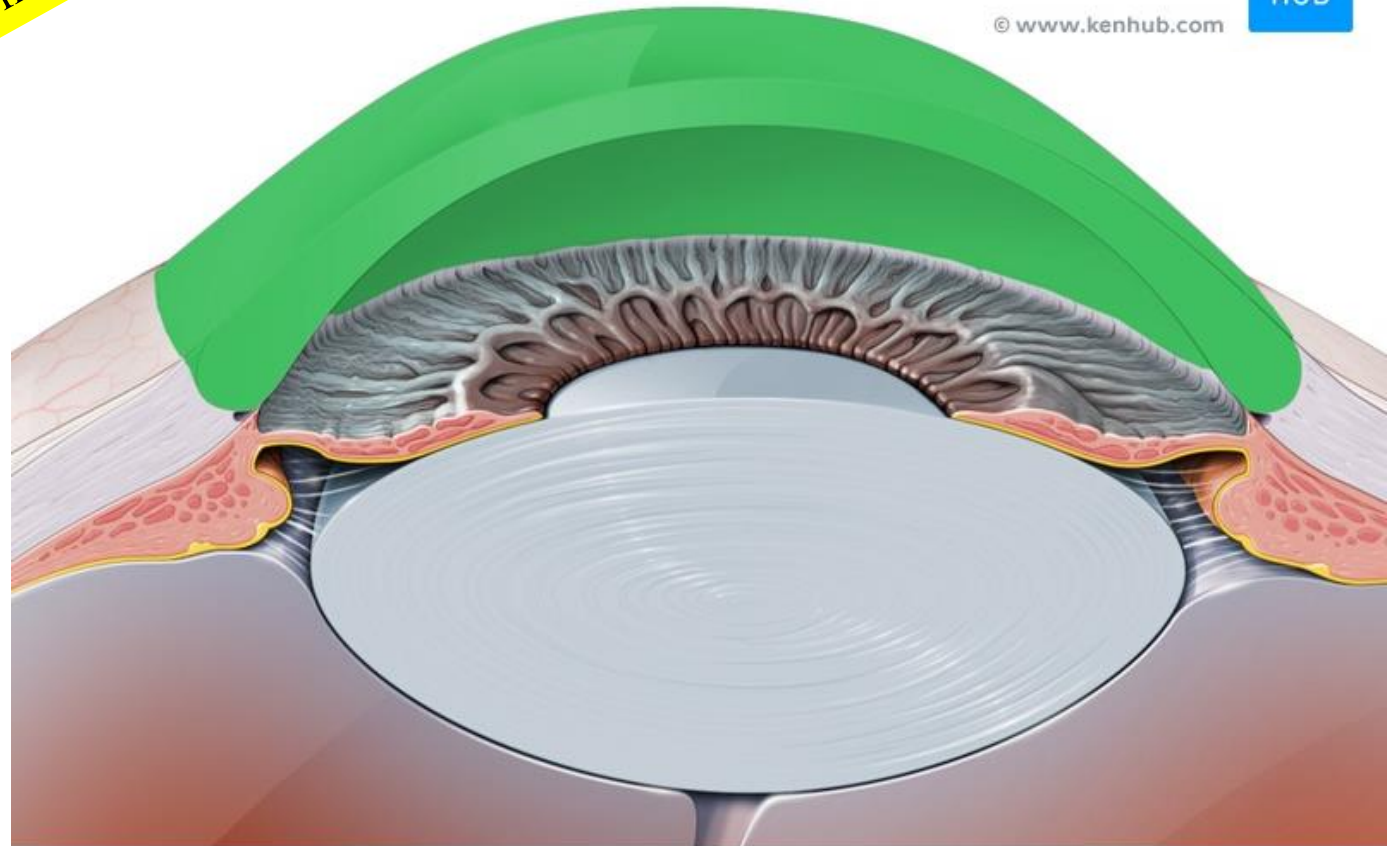
Read only 😊

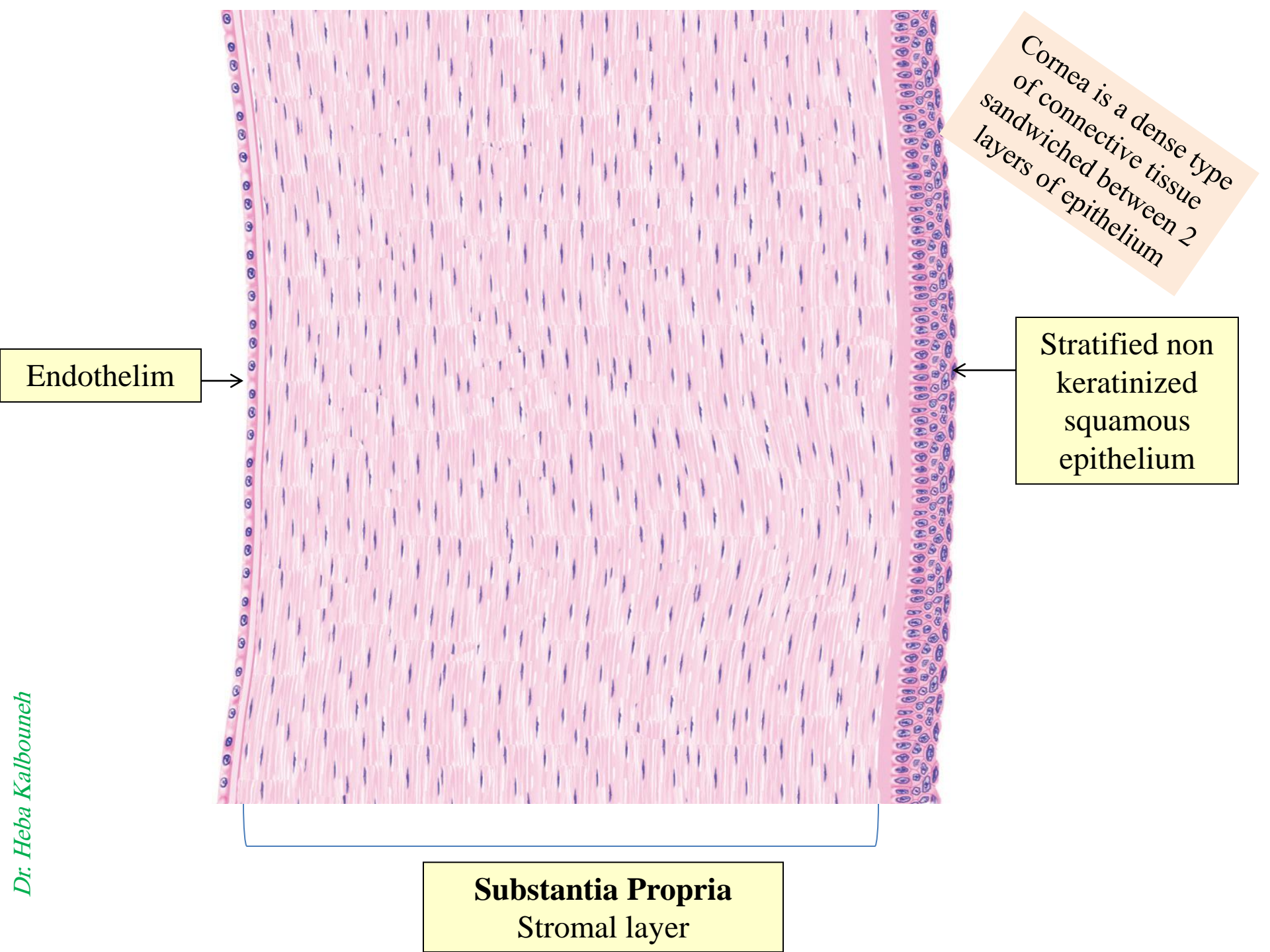
© www.kenhub.com

KEN  
HUB

### Corneal grafts

(transplants) between unrelated individuals can usually be accomplished successfully without immune rejection due in part to this tissue's lack of both a vascular supply and lymphatic drainage





Endothelium

Cornea is a dense type of connective tissue sandwiched between 2 layers of epithelium

Stratified non keratinized squamous epithelium

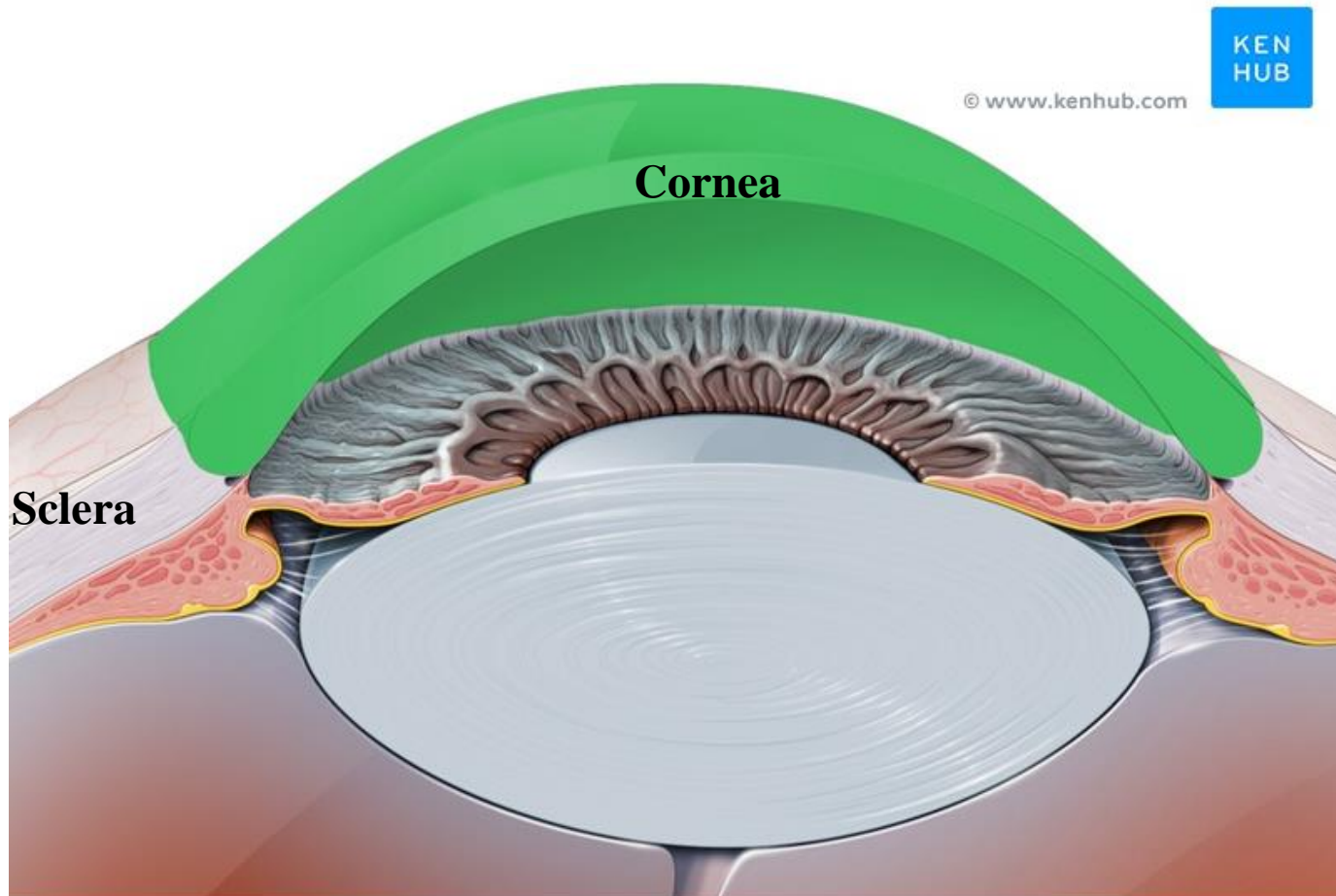
Substantia Propria  
Stromal layer



Both sclera and cornea are composed of fibrous connective tissue

Why the sclera is white while the cornea is transparent??????

The **sclera** is opaque due to the irregularity of the Type I **collagen** fibers with different thicknesses, as opposed to the near-uniform thickness and parallel arrangement of the **corneal collagen fibrils**



# Histology of retina

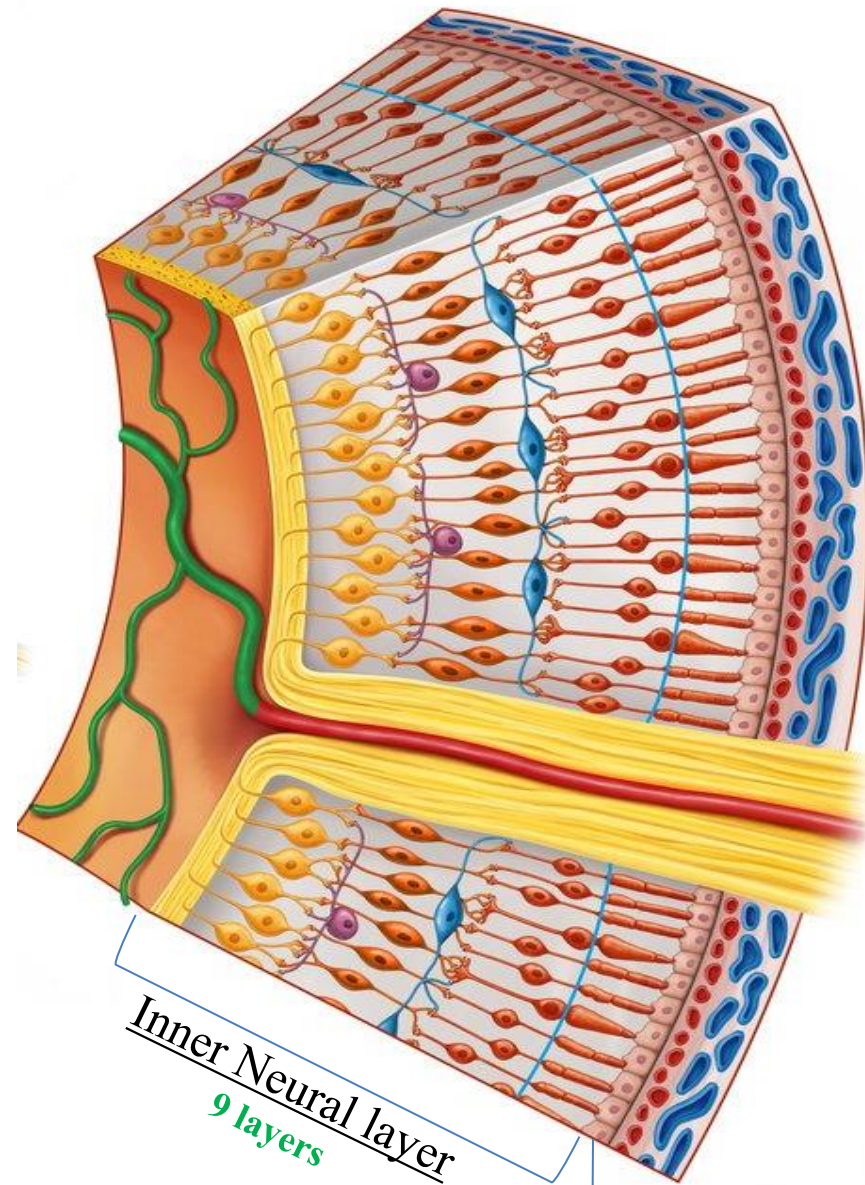

## Component:

Pigmented layer: Pigmented epithelial cells

## Neural layer:

Photoreceptors, bipolar neurons, ganglion cells, and supporting Müller cells

**10 layers!!!**



Inner Neural layer  
9 layers

Outer Pigmented layer  
1 layer

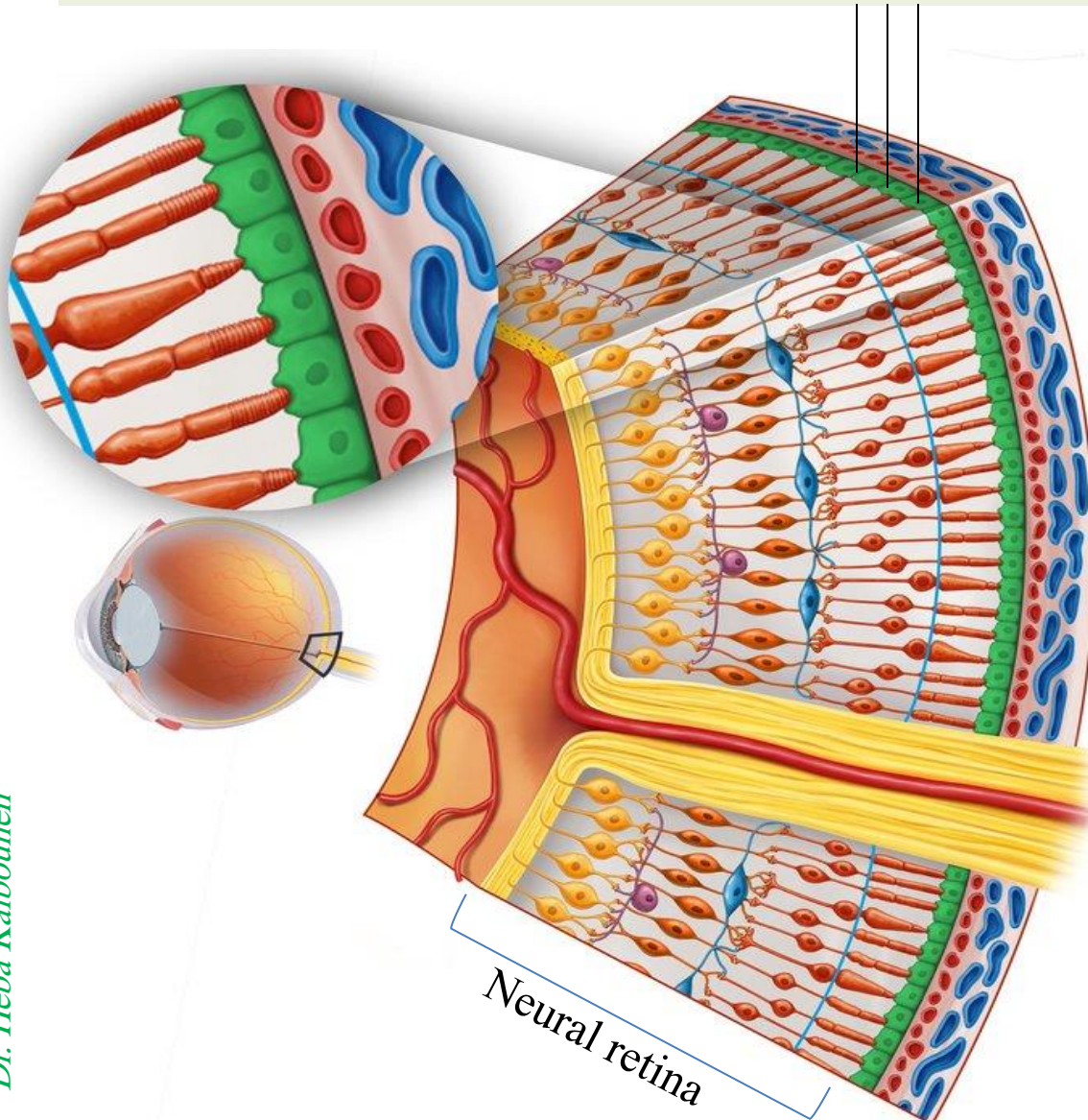
© www.kenhub.com





## Retinal Pigment Epithelium

The pigmented epithelial layer consists of cuboidal or low columnar cells and surrounds the neural layer of the retina



Retinal pigment epithelium protects and nourishes the retina, removes waste products, prevents new blood vessel growth into the retinal layer and absorbs light not absorbed by the photoreceptor cells; these actions prevent the scattering of the light and enhance clarity of vision.

## Neural Retina : 9 distinct layers

- 1- **The rod and cone layer**: contains the outer segments of the rod and cone cells
- 2- **The outer limiting layer**
- 3- **The outer nuclear layer**: contains cell bodies of the rod and cone cells.
- 4- **The outer plexiform layer**: includes axons of the rod and cone cells and dendrites of the bipolar cells
- 5- **The inner nuclear layer**: contains the nuclei of the bipolar cells, amacrine cells, and horizontal cells, Muller cells

## 6- **The inner plexiform layer**

**layer**: includes axons of the bipolar cells and dendrites of the ganglion cells

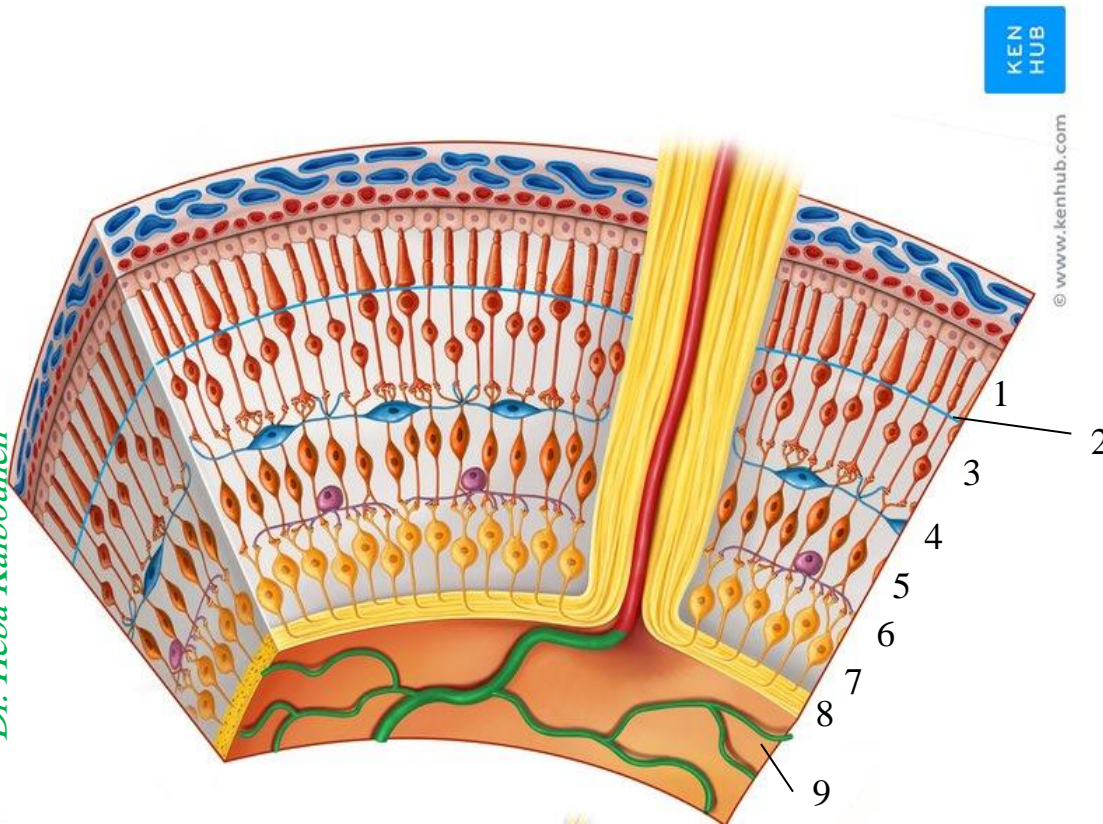
## 7- **The ganglionic layer**

contains cell bodies of ganglion cells

## 8- **The nerve fiber layer**


containing the ganglionic cell axons that converge at the optic disc and form the optic nerve.

## 9- **The inner limiting layer**

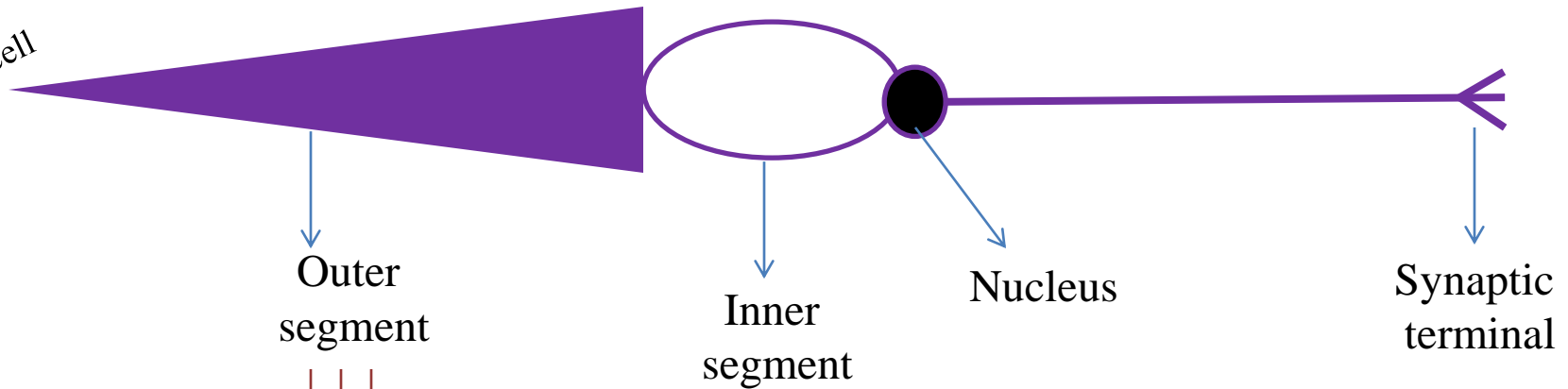




Rod cell



Cone cell



Outer  
segment

Inner  
segment

Nucleus

Synaptic  
terminal

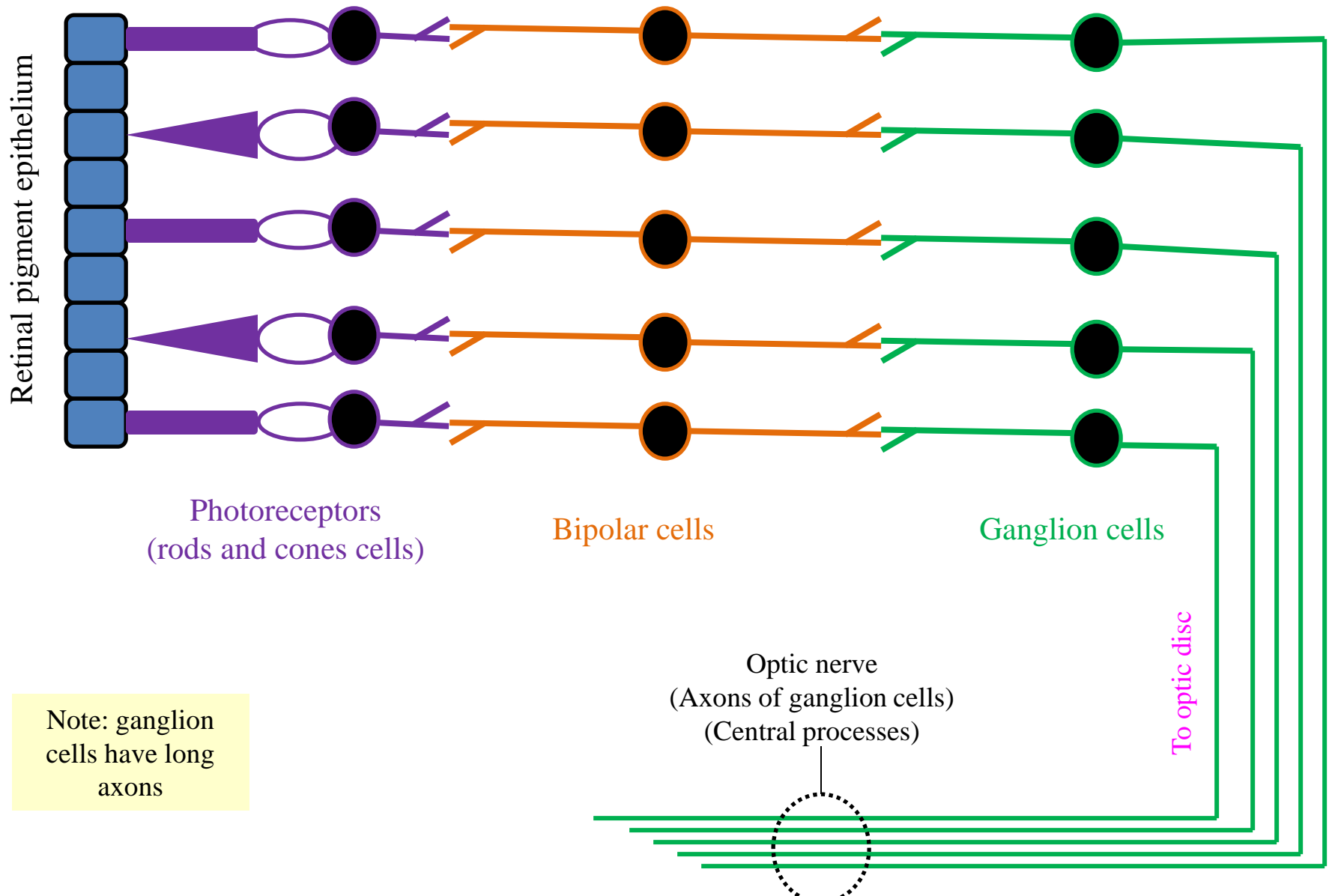


**Photosensitive region**  
Generation of the receptor  
potential

The rod and cone cells (photoreceptors), named for the shape of their outer segments, are polarized neurons with their photosensitive portions aligned in the retina's rod and cone layer (RCL)

# Neural Retina : Main cells

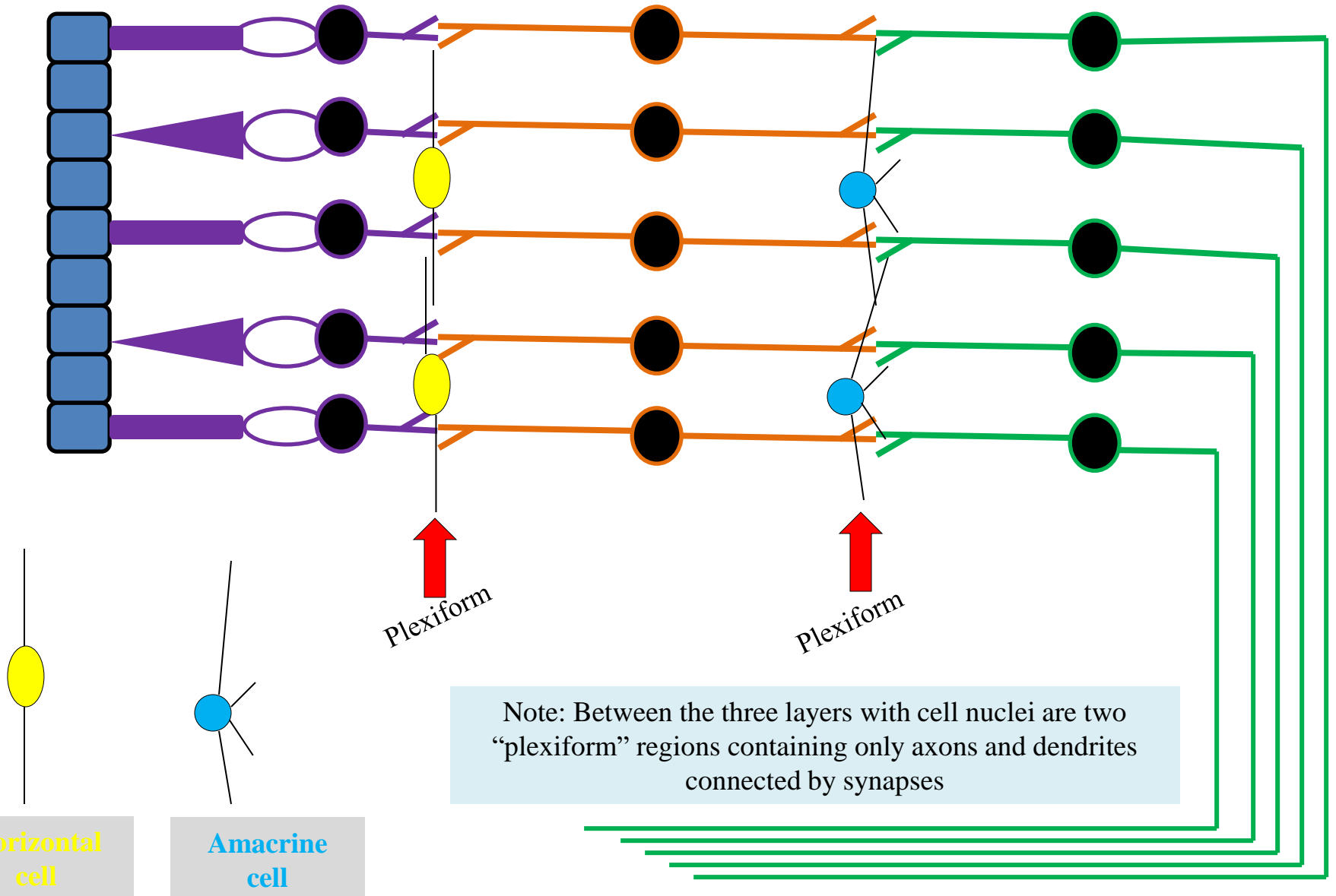
RBG



# Neural Retina : Cross-talking cells

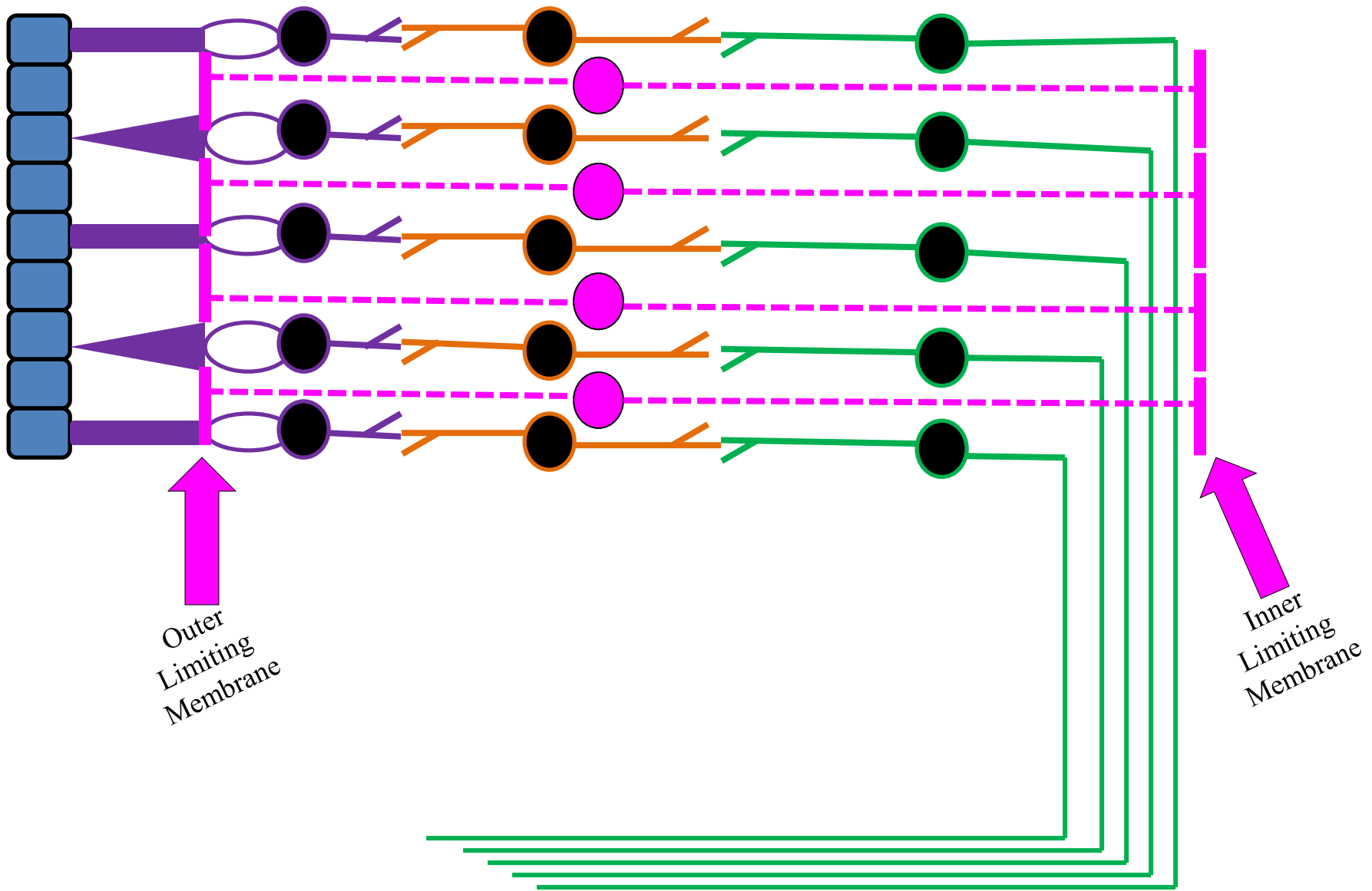
HA

*Make specific connections with other neurons*

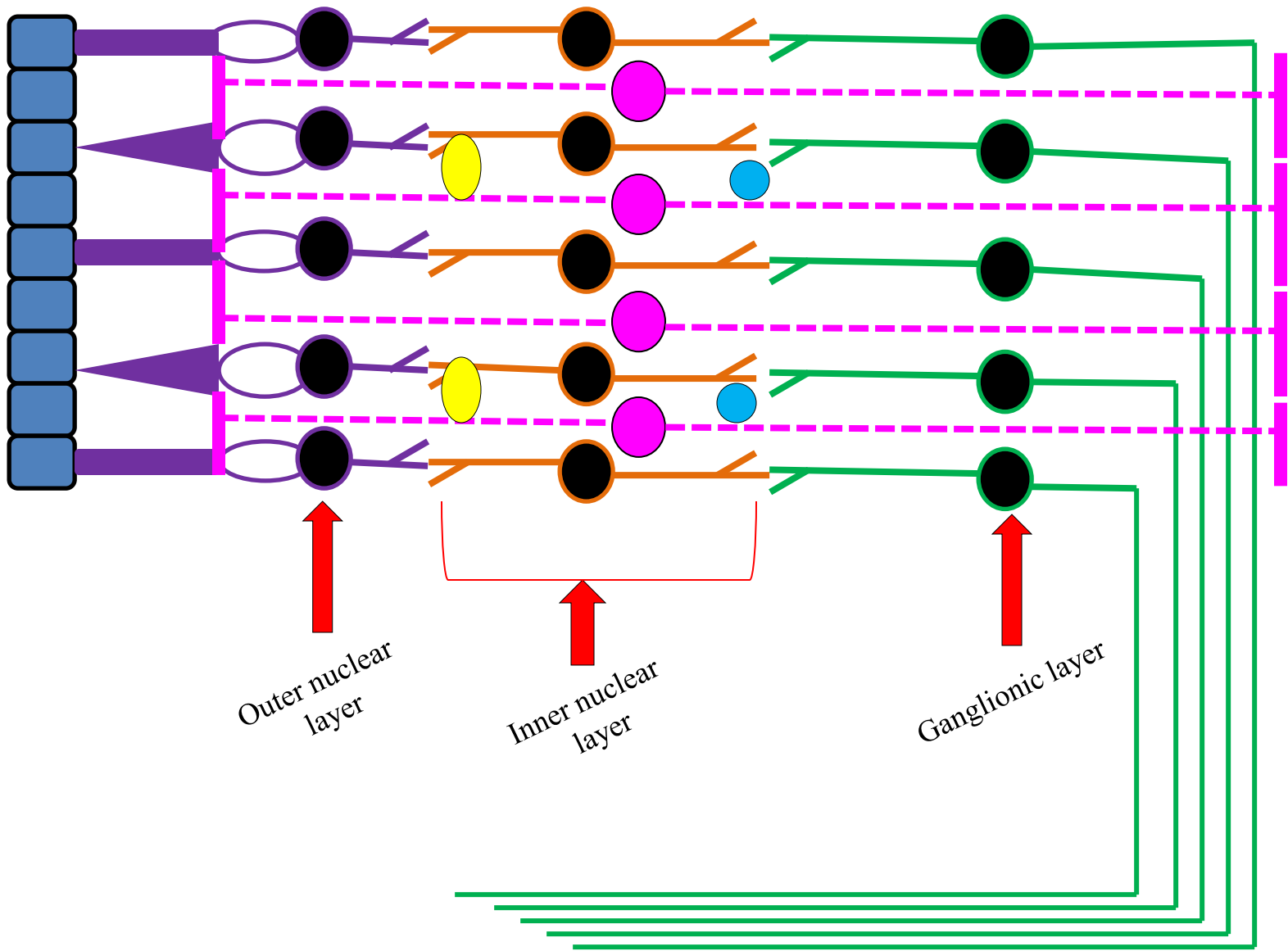


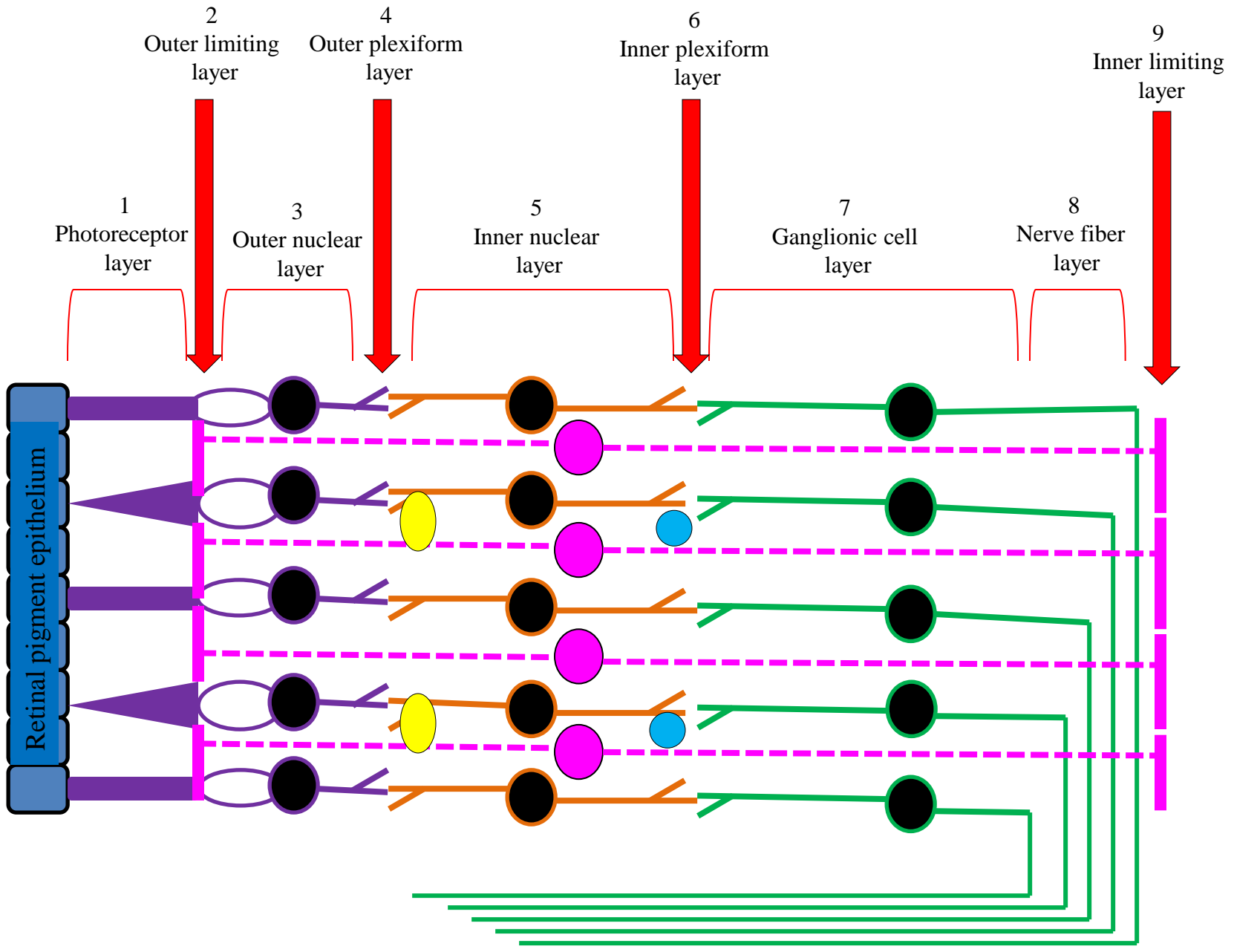
# Neural Retina : Glial cells

Muller cell









# Müller cells

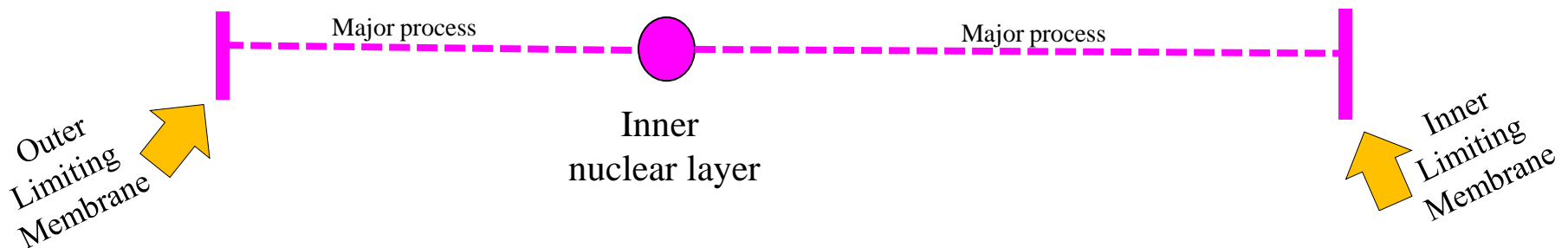
- ✓ Müller cells are retinal neuroglial cells
- ✓ Their cell bodies are located in the inner nuclear layer of the retina
- ✓ Müller cells extend processes that span across the entire neural retina
- ✓ From these major Müller cell processes smaller lateral extensions ramify to form:

**The outer limiting membrane**

**The inner limiting membrane** (forms the inner surface of the retina)

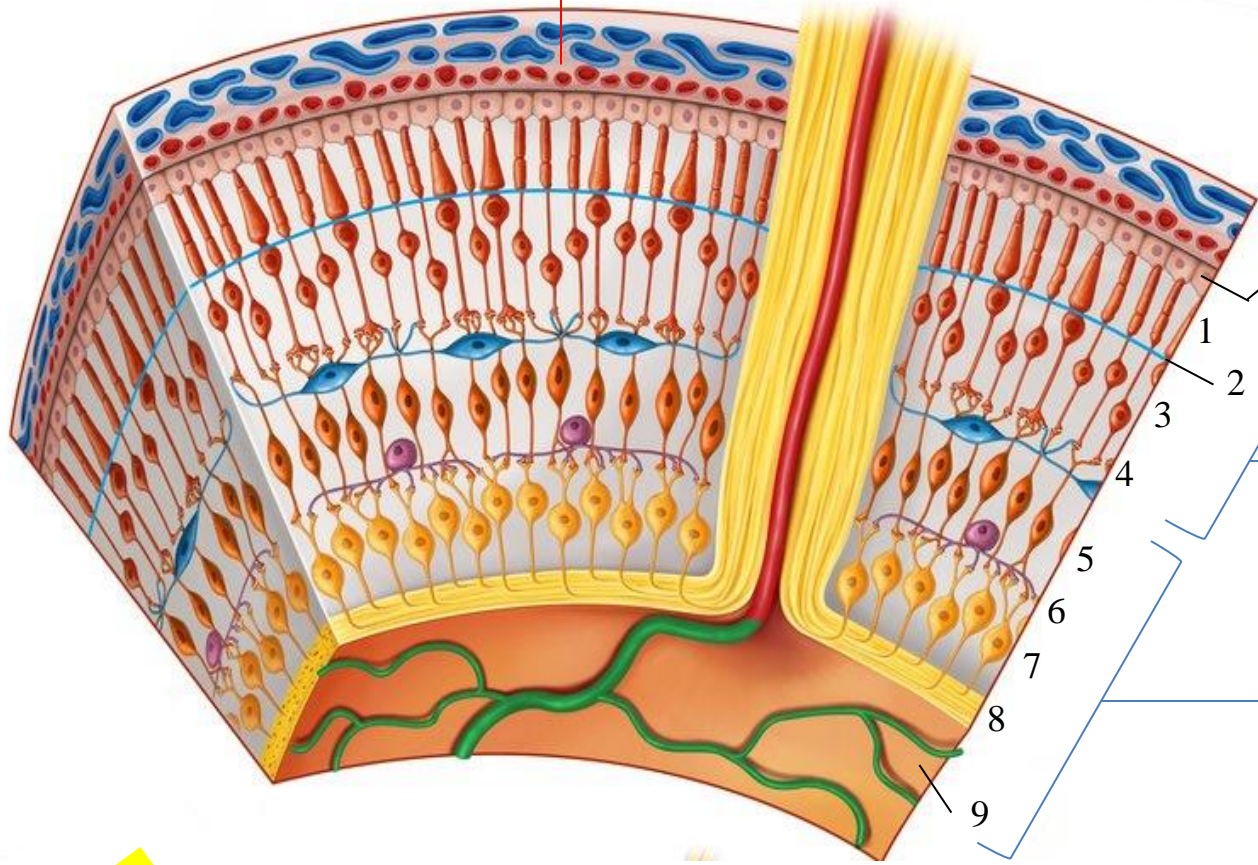
✓ The major role of the Müller cells is to maintain the structural and functional stability of retinal cells. This includes regulation of the extracellular environment via uptake of neurotransmitters, removal of debris, regulation of  $K^+$  levels, storage of glycogen, electrical insulation of receptors and other neurons, mechanical support of the neural retina, and maintaining a blood-inner retina barrier.

Read only 😊



# Choroidocapillary lamina of the choroid

These layers receive O<sub>2</sub> and nutrients by diffusion from the choroidocapillaries of the choroid.



Retinal pigmented epithelium

These layers are supplied by branches of Central Artery of Retina

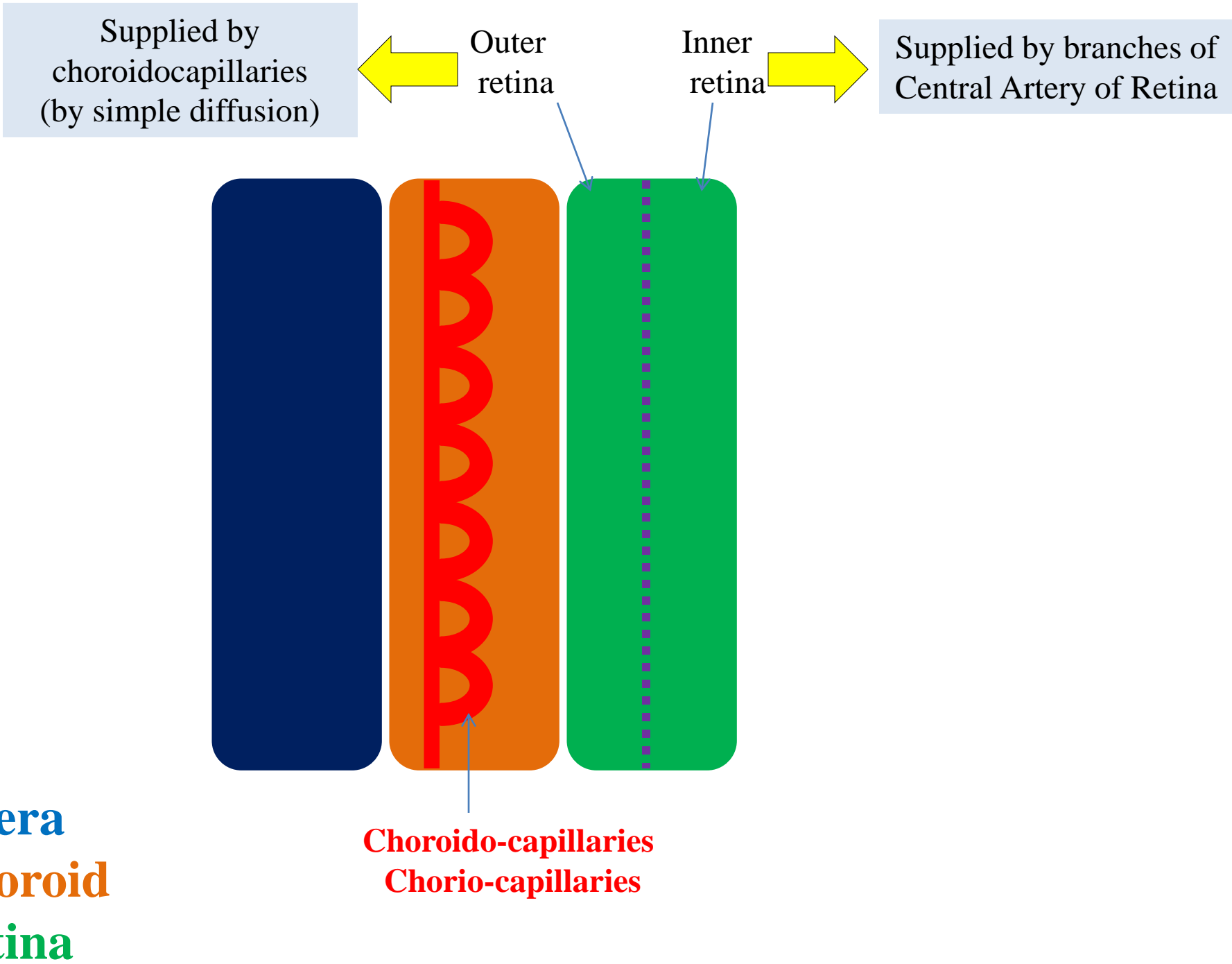
Dr. Heba Kalbouneh

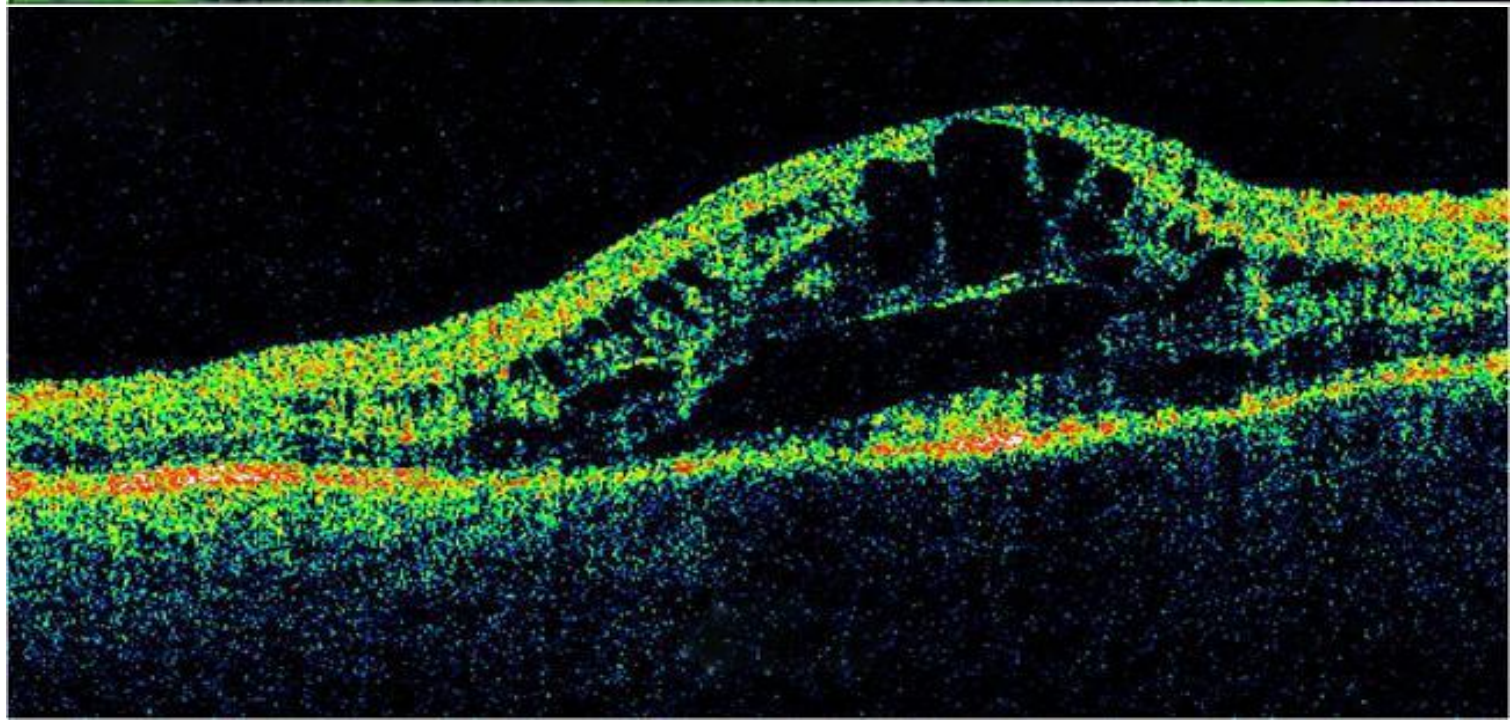
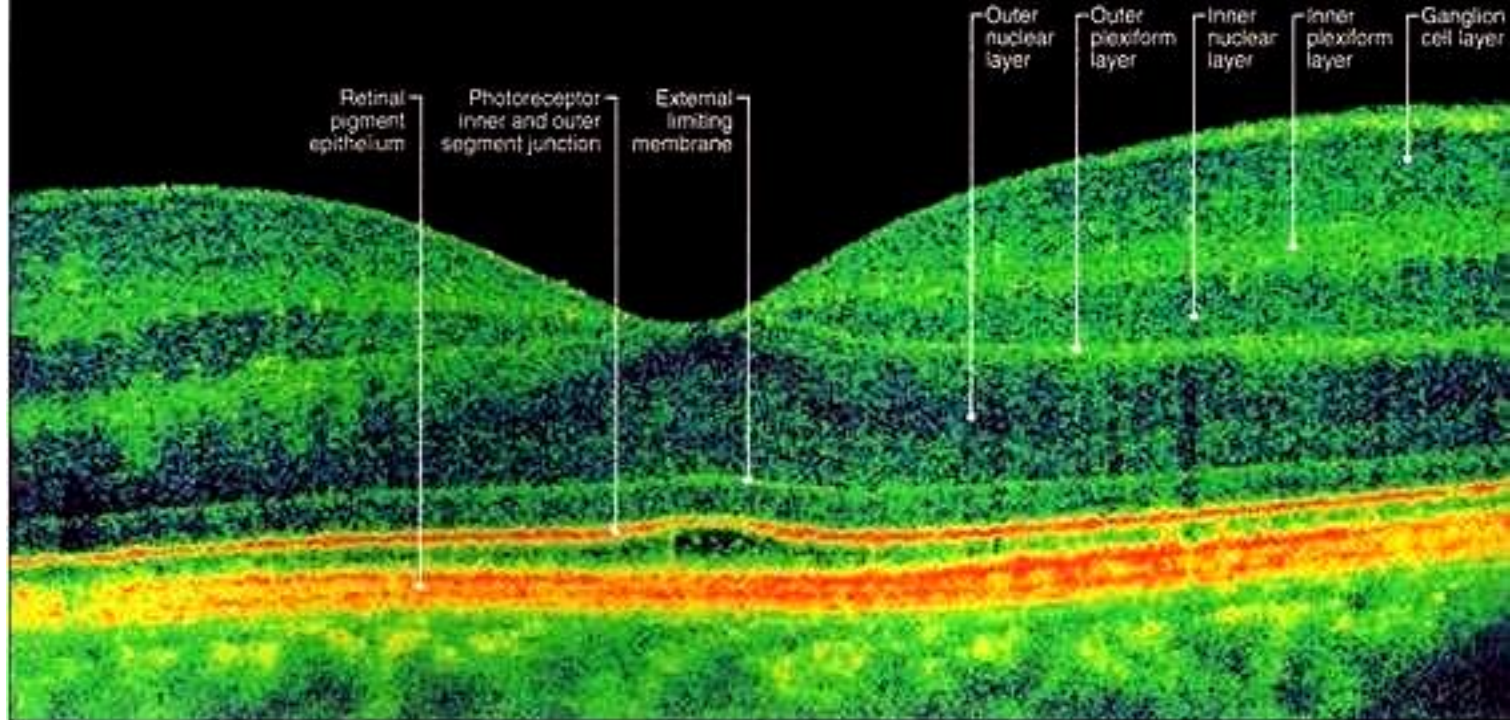
Read only 😊

The retinal pigmented epithelium and the photoreceptor layer of the retina, derived from the two layers of the optic cup, are not firmly joined to each other. Head trauma or other conditions can cause the two layers to separate with an intervening space. In such regions of detached retina, the photoreceptor cells no longer have access to metabolic support from the pigmented layer and choroid and will eventually die. Prompt repositioning of the retina and reattaching it with laser surgery is an effective treatment.



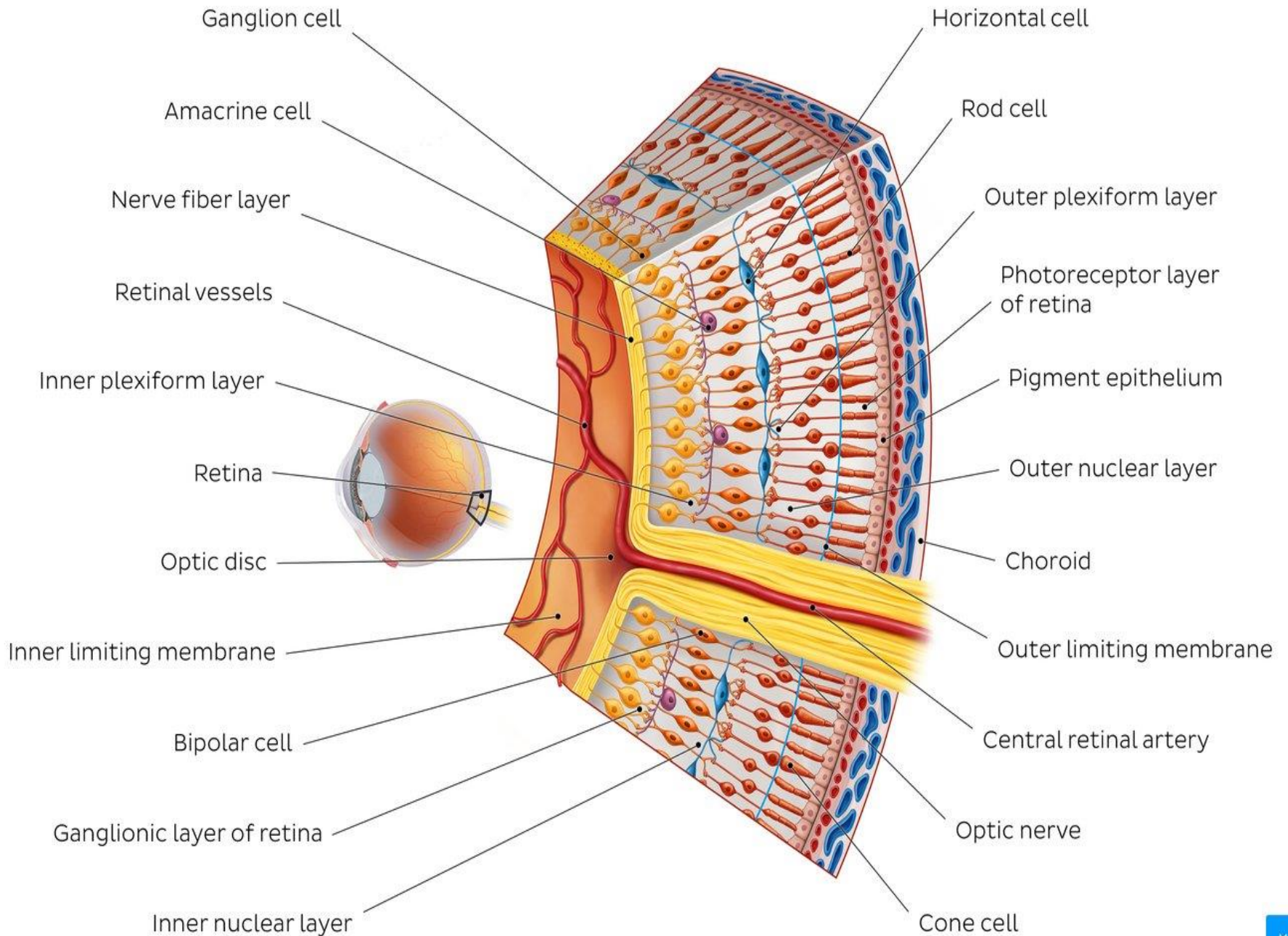
*Dr. Heba Kalbouneh*





Detached  
retina





Rod cell

Rhodopsin  
(protein + vit. A (Retinol))



Cone cells

Iodopsin



Iodopsin



Iodopsin



Dr. Heba Kalbouneh

- ✓ **Rods** are responsible for black/white vision and function best in dim light (responsible for night vision)
- ✓ Deficiency of vitamin A (**night blindness!!!**)

- ✓ **Cones** are responsible for color vision and function best in relatively bright light
- ✓ Cone cells are densely packed in the fovea centralis
- ✓ Three types

Color blindness!





Rods	Cones
More concentrated in the peripheral part of retina	More concentrated in the central part of retina (macula lutea)
Sensitive to dim light <b>(Night vision)</b>	Sensitive to bright light <b>(Day vision)</b>
More abundant	Less abundant

