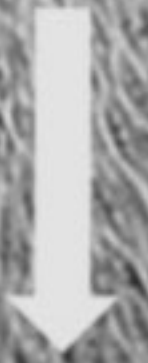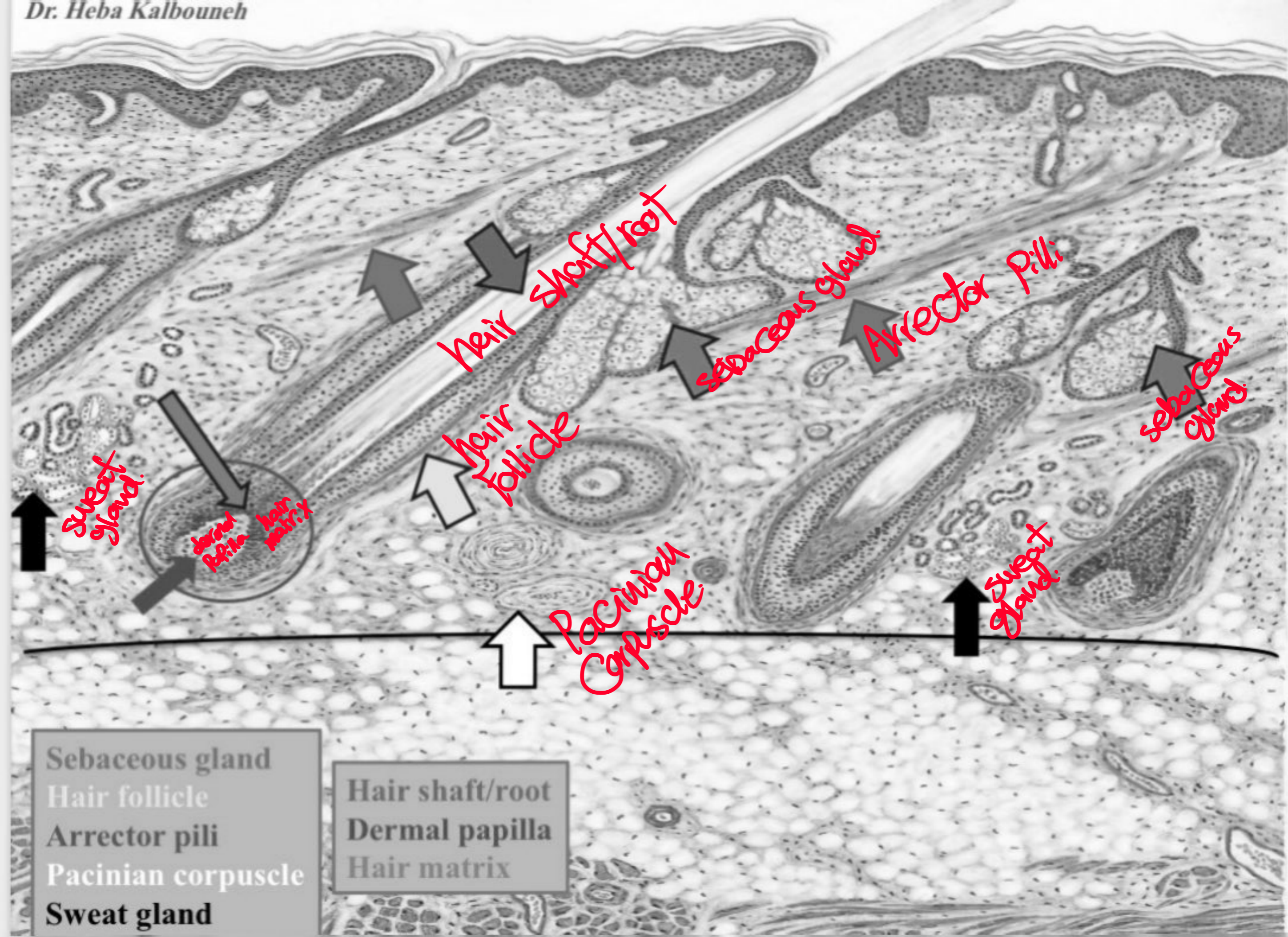
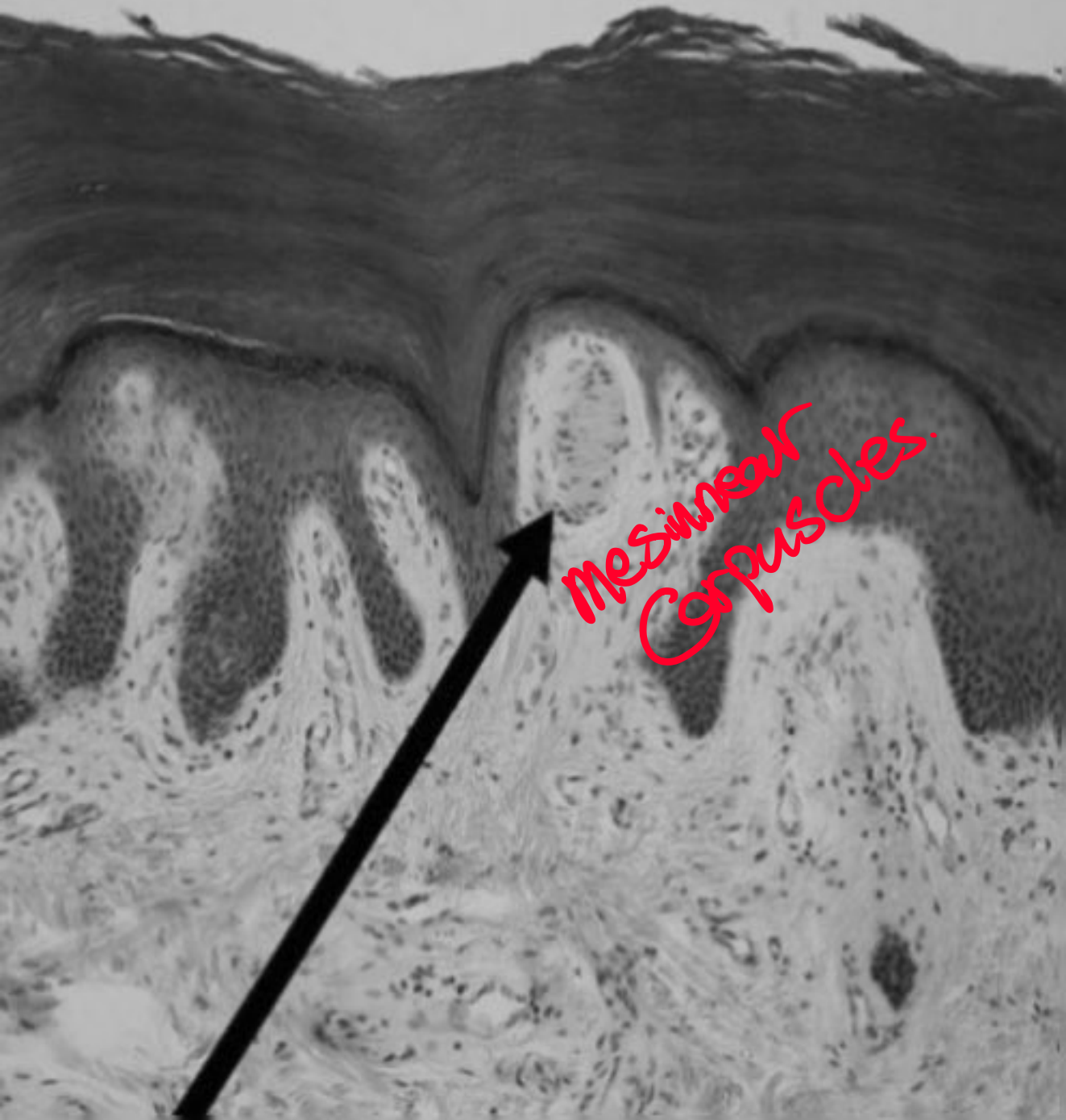


Epidermal ridge
Dermal papilla

← E. ridges.
← d. Papilla.

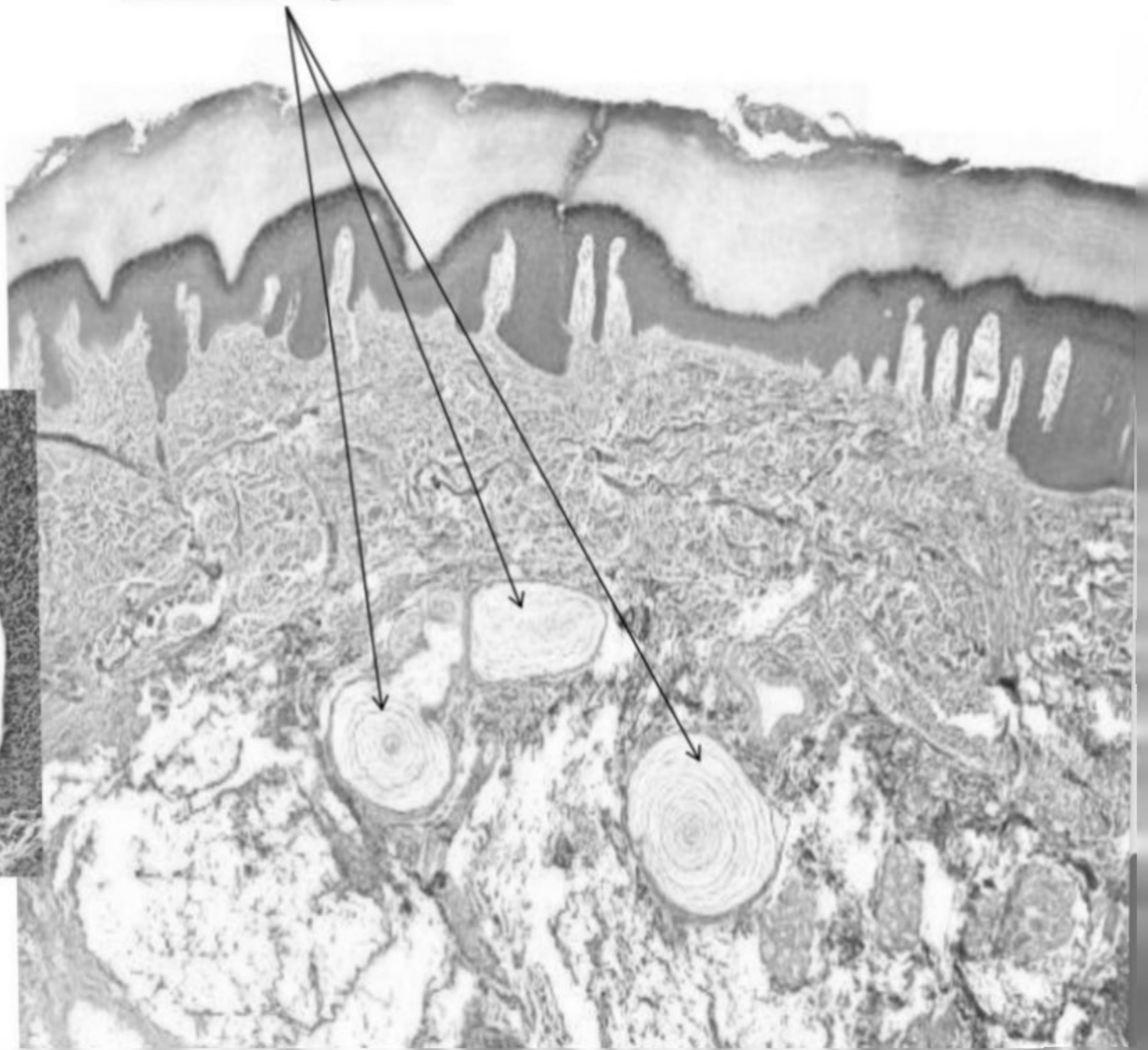
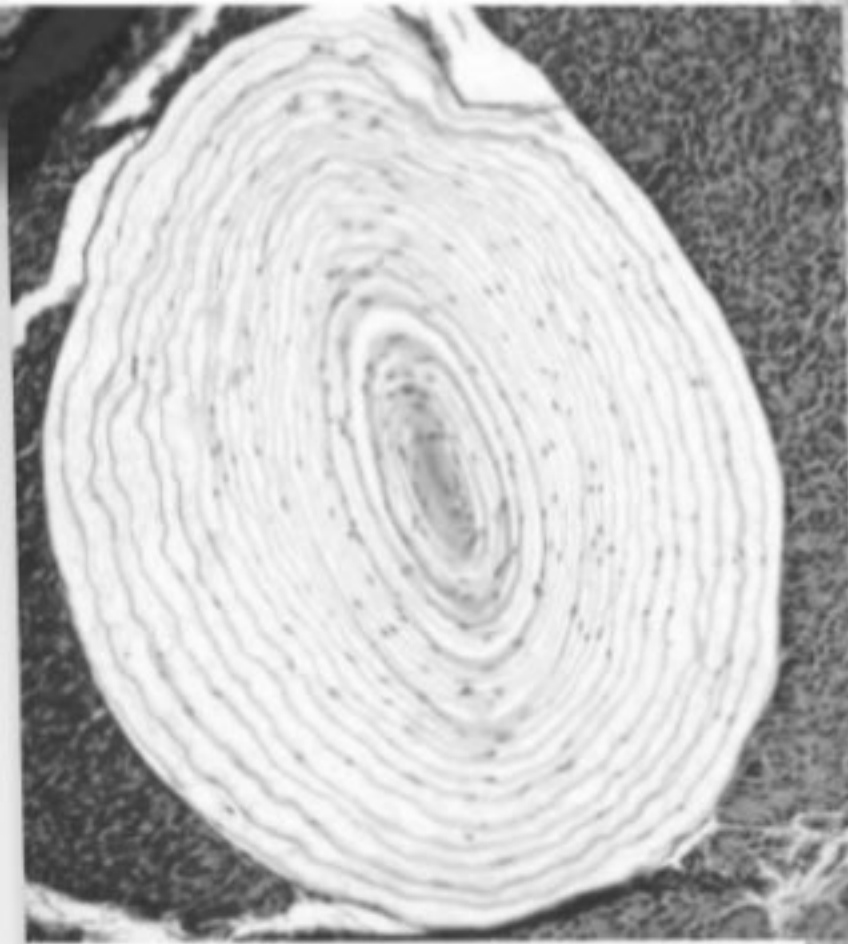






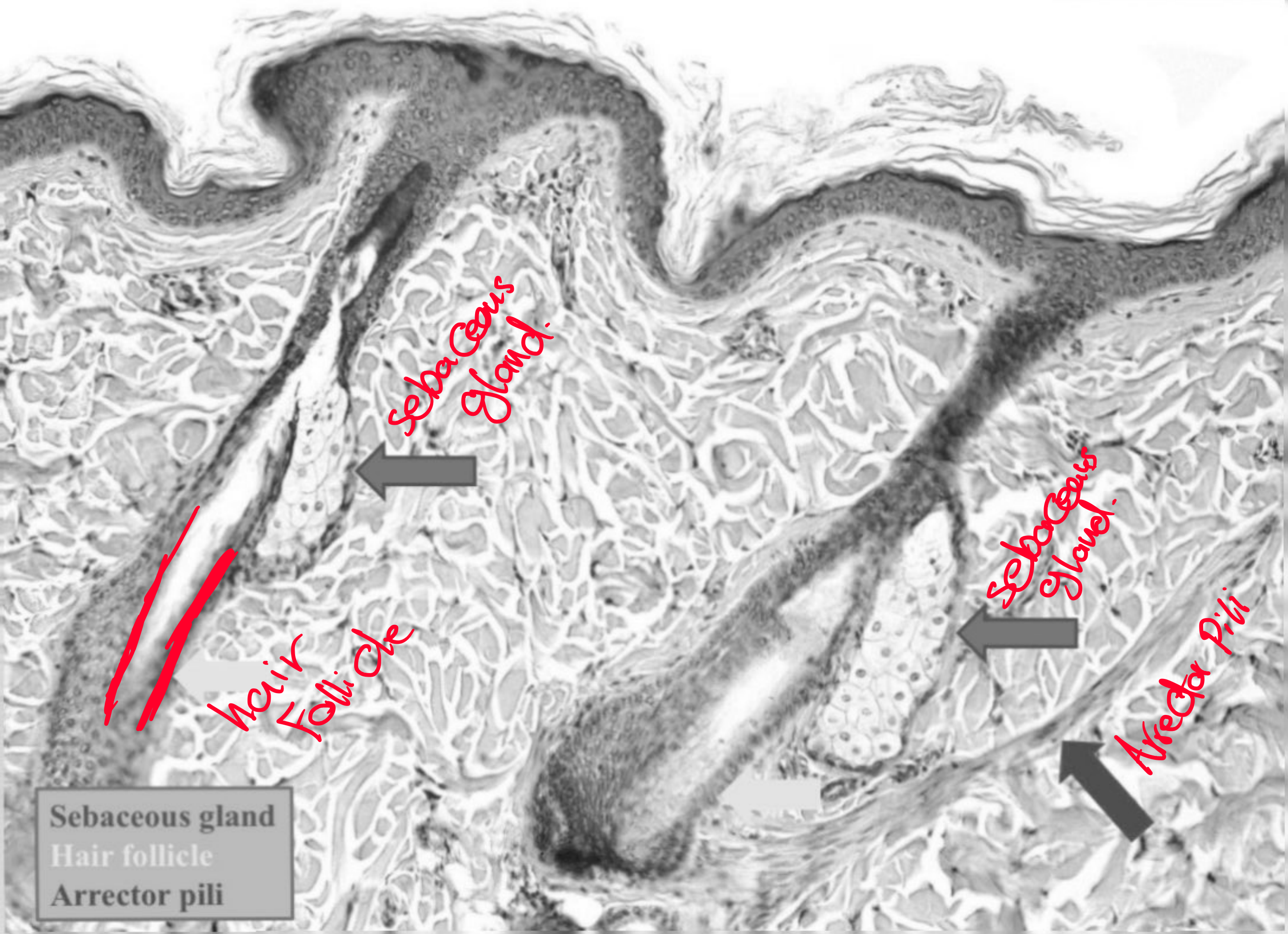
mesenteric
Corpuscles

Pacinian corpuscles



Dr. Heba Kalbounch

Scanned with CamScanner



Sebaceous Gland.

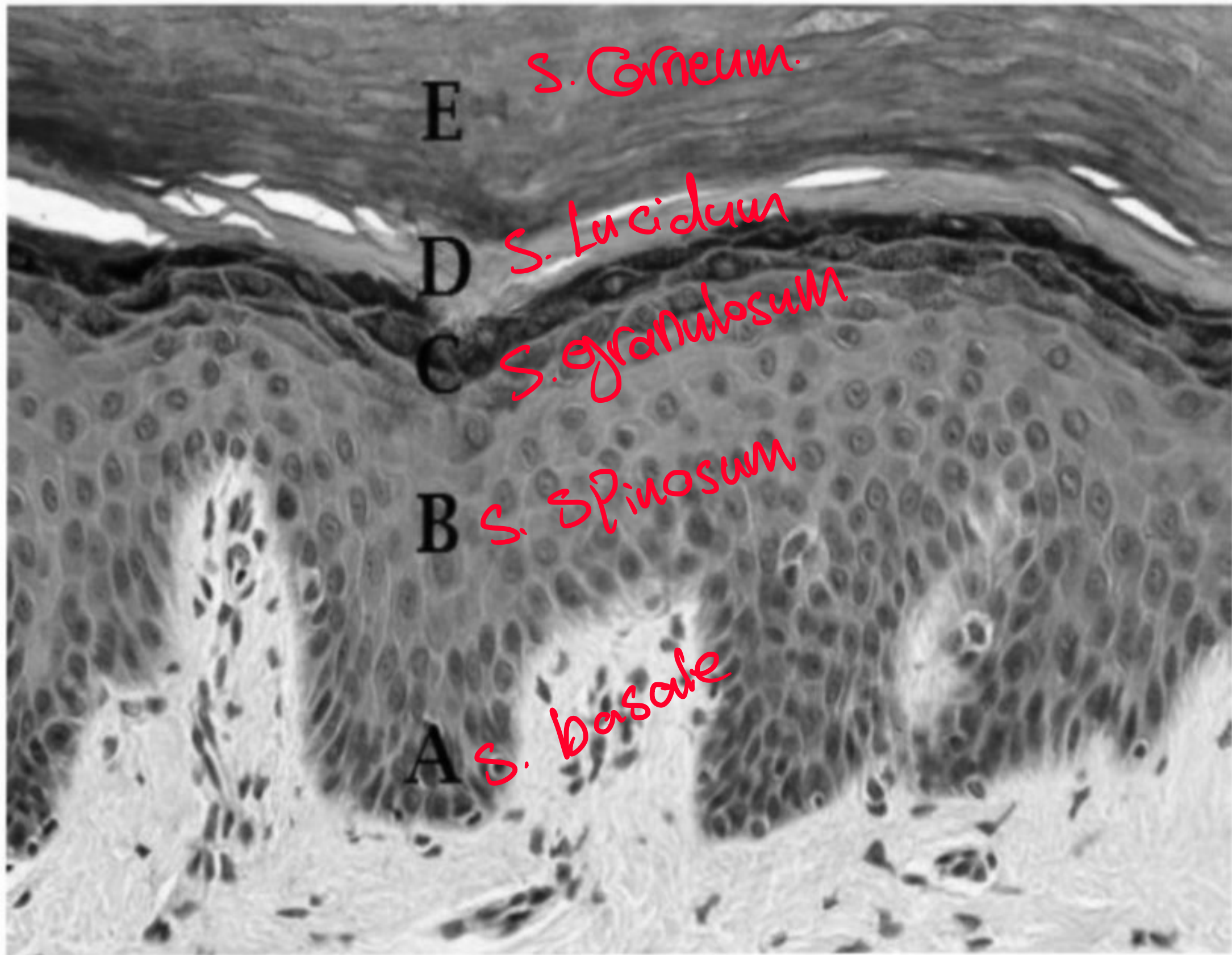
Sebaceous Gland.

Hair Follicle

Arrector Pili

Sebaceous gland
Hair follicle
Arrector pili

Thick skin \Rightarrow 5 layers




Dr. Heba Kalbouneh

Scanned with CamScanner

THICK OR THIN SKIN ????

5 layers



V2

-In the last slide, it's a thick skin, because of the presence of *S. lucidum*.