



MSS

MICROBIOLOGY

5



WRITER:
Ammar Ismail

CORRECTOR:
Adawi

DOCTOR:
Nader Al-Araideh

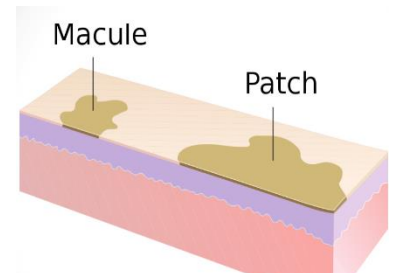
THIS PAGE IS NOT REQUIRED, IT'S FROM US. YOU CAN SKIP IT

Let's start with some terminology to make the lecture easier.

Here are general terms used to describe skin lesions.

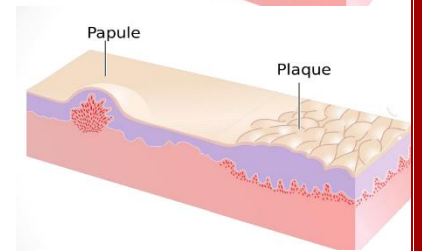
Macule and patch.

These two mean a flat lesion that is not raised, they are simply a discoloration of the skin. Macule: small, patch: large.



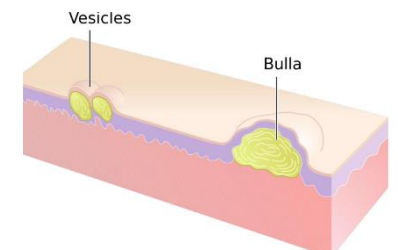
Papule and plaque.

These are raised solid skin lesion. Papule: small, plaque: large.



Vesicle and bullae.

These two are fluid containing blisters. Vesicle: small, bullae: large.



Pustule is a vesicle containing **pus**.

Scale: is flaking of the stratum corneum. (قشور)

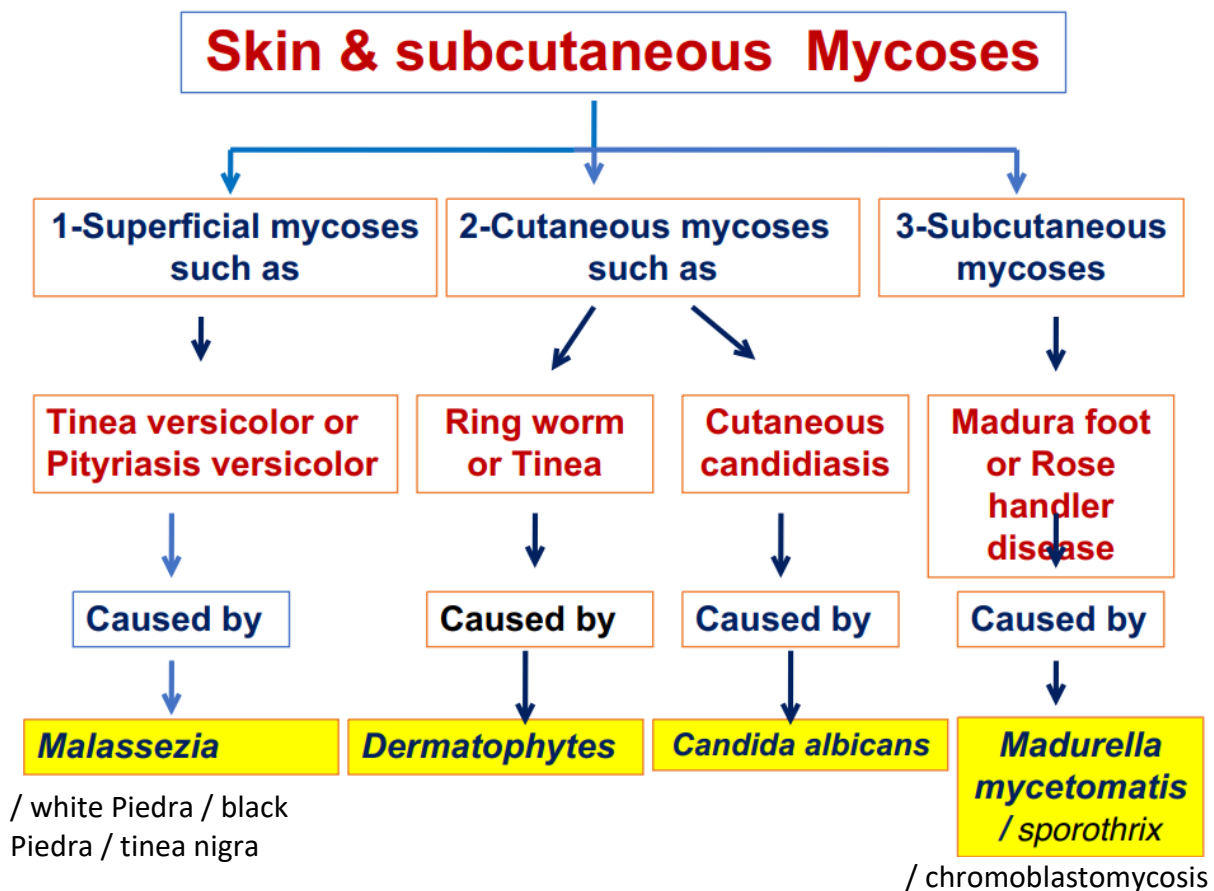
Crust: is dried exudate.

Now some notes for this lecture.

All tinea are caused by dermatophytes except versicolor it is caused by Malassezia.

FUNGAL INFECTIONS

➤ Note: **bold red** text → what doctor emphasized from slides.



SUPERFICIAL MALESSEZIA INFECTIONS: PITYRIASIS (TINEA) VERSICOLOR

- **Lipophilic yeast** (favors sebaceous glands) **round in shape**.
 - They're yeasts, but they can be hyphae.
 - **Malassezia** can exist in either hyphae or yeast while being pathogenic (inside human body) or non-pathogenic (outside the human body).
 - They can be found on trunk, neck, and beard.
- **Normal commensals (flora) of skin**
 - They can't be transmitted to others because they're normal flora.
 - They're also normal flora of animals.
- **Can cause skin infections and catheter associated infections.**
 - They become pathogenic and infect skin due to gaining a virulence factor or being introduced to another abnormal site (in catheters).
- **Skin (stratum corneum) infection.**

➤ It only affects the outermost layer of the skin, there are no other symptoms than the cosmetic ones. This is the difference between it and the cutaneous infections.

● **Trunk and proximal limbs** or any part of the body.

● *M. furfur*, *M. globose* and *M. sympodialis*.

● Common in tropics and **precipitated by sun exposure**.

➤ When there are excessive humidity and sun exposure, the infection becomes severe.

➤ Versicolor means changing color. Therefore, when the patient is white, the infection causes **hyperpigmentation** (darkening of the skin), and when he's black, it is **hypopigmentation** (lightening of the skin).

● **Carboxylic acid produced by the yeast causes the depigmentation.**

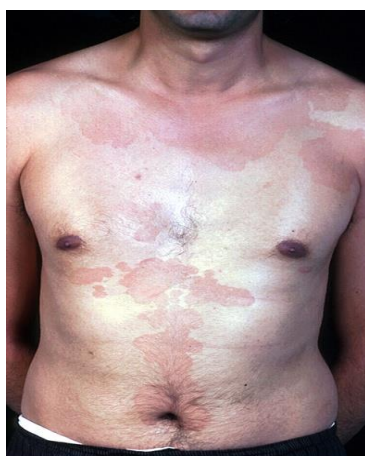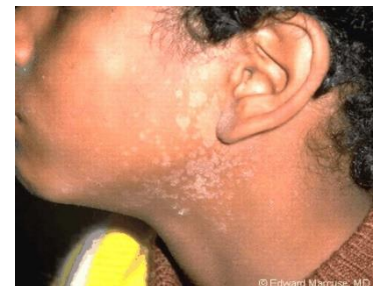Note from the writers: we said that they are lipophilic, they consume the lipids and produce acids that inhibit melanin production.

● Clinically:

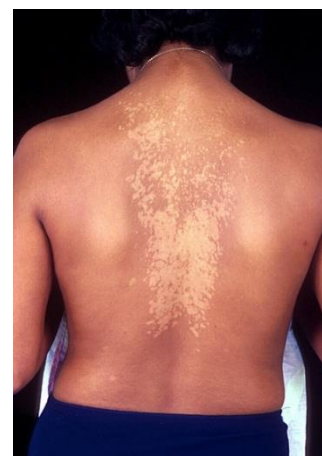○ **Asymptomatic, non-itchy macules hypo or hyper pigmented.**

○ **Can coalesce to form scaly plaques.**

➤ Look at the following picture, the patient has well-demarcated big pink to brown lesions, and they tend to merge together, and has some scales sometimes.



Light-skinned man with **hyperpigmentation**



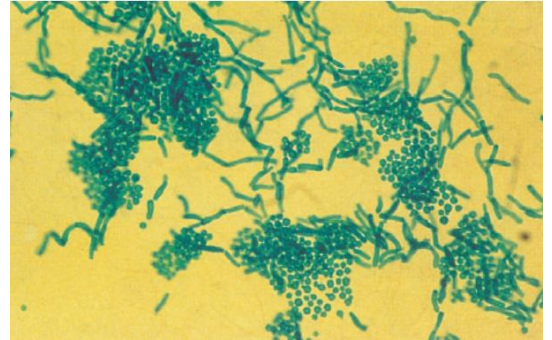
Dark-skinned man with **hypopigmentation**

Diagnosis:

- UV light: **pale greenish** (orange-coppery) **colour under Wood's ultra-violet light**.
- **Skin scraping then ink and KOH staining** (simply, using microscope).
- Look at the picture, they look under microscope as **thick septate hyphae and clusters of budding yeast cells (spaghetti and meatballs)**.

- **Treatment if needed is for cosmetic reasons:**

- **Some resolve spontaneously.**
- **Topical azoles cream/shampoo** (or selenium sulfide) for 2 weeks or in severe cases use oral azoles.
- **Recurrence is common.**



- **Seborrheic dermatitis:**

- Skin hyperproliferation with hair **dandruff being the mildest manifestation.**
- **Lesions are red and covered with greasy scales and itching is common in the scalp.**
- ***M. furfur*** has a hand in seborrheic dermatitis.
- Treatment: **Azoles.**
 - The relationship between *M. furfur* and seborrheic dermatitis is association not causation. This is because azoles alleviate this disease symptoms.
 - Extra explanation from us: seborrheic dermatitis is a skin disorder; which often appears as red lesion with yellow scales on areas rich with sebaceous glands, such as the scalp and the face, so they may cause itching in the scalp, okay? What does it have to do with fungi? Well, they noticed that it is treated with antifungals, so they assumed that there is an association between it and tinea versicolor.
 - Other superficial infections are black and white piedra, they affect the hair.
 - Tinea nigra is caused by dematiaceous fungi, it appears as black papules on the palms and soles.

CUTANEOUS MYCOSES

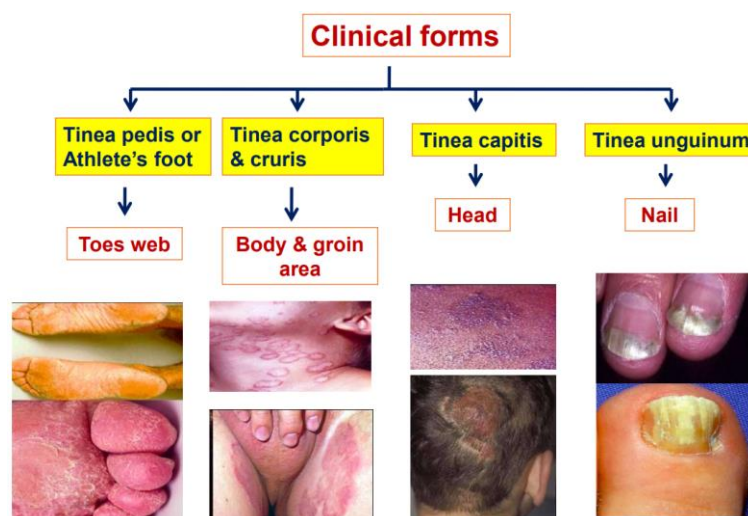
RING WORM OR TINEA

- Caused by **dermatophytes** (filamentous fungi/molds) which include **3 genera: *Microsporum*, *Trichophyton* & *Epidermophyton***.
- These fungi **affect the keratinized tissues as skin, hair & nails** (as well as the outer most layer).
 - Immunological response and symptoms (pruritus “itchy”) are present.
- Infection not spread to deeper tissues.



SOURCE OF INFECTION

1. **Man to man** by direct contact (**Anthrophilic**).
 - Usually chronic, high recurrence.
 2. **From animals** e.g., dogs and cats (**Zoophilic**).
 3. **From the soil** (**Geophilic**). (Inanimate objects)
 - Zoophilic and geophilic are usually acute, lower recurrence.
- The intact skin is an important barrier against infection.
 - **Heat and humidity enhance the infection.**



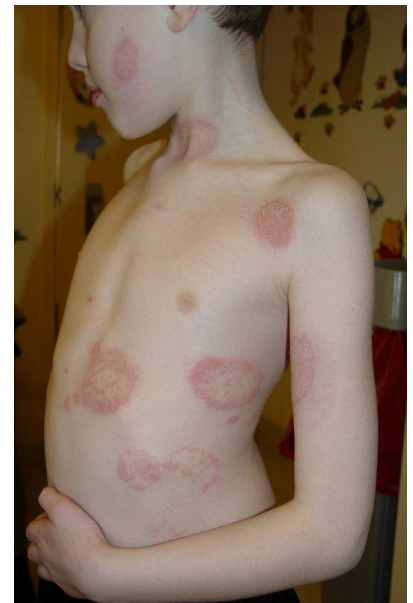- Dermatophytes are named tinea + suffix (according to the infected site).
 1. In the feet, **tinea pedis** or **athlete's foot**.
 2. Glabrous (hairless) skin, **tinea corporis**.
 - If it infects hairy skin, it's called **tinea barbae**.

- 3. Proximal medial thighs (groin), **tinea cruris**.
- 4. Scalps, **tinea capitis** (the most common form).

Scaling and hair loss leaving black dots

- Hair loss (alopecia) with black dots.
- The most severe type (most contagious) is **tinea favosa**.

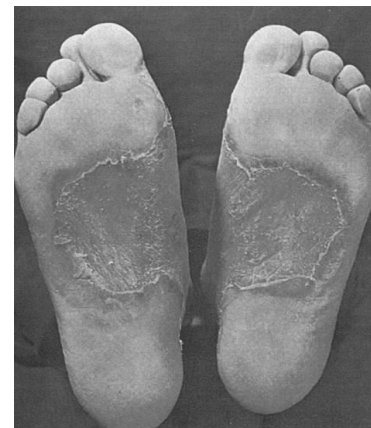
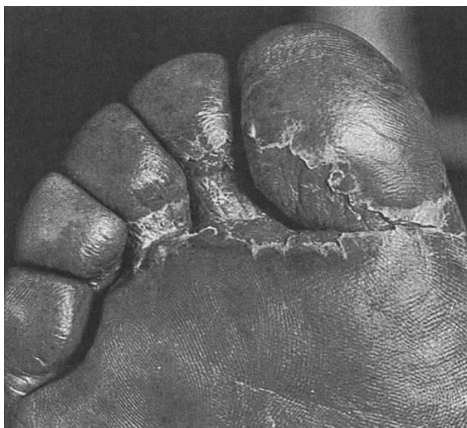- 5. Nails, **tinea unguinum** (also called **onychomycosis**).
- It doesn't affect the nail bed and fold; it causes yellow and brittle nails. No inflammation (redness). It's painless.



White and opaque / yellow, thickened & broken nails.

Clinical pictures:

- **Red, itchy scaly rash, ring like with raised more inflamed border on the body or groin.**
 - They're named ringworm because they appear like red rings with diminution toward the center (normal skin color in the center).
- **DDX: Eczema, psoriasis, impetigo, alopecia, drug reactions.**



- **Tinea pedis showing interdigital scalping**
 - Mild form.
- **Dermatophytes of the soles**
 - Severe form, complete loss of tissue.
- Both of them is caused by ***T. mentagrophytes***

Pitriyasis (tinea) versicolor	Ring worm (tinea)
Not contiguous	Contiguous
Sun exposure precipitates the infection	Heat and humidity enhance the infection
No immunological response	Immunological response
Usually not itchy	Itchy

Yeast and hyphae (spaghetti and meatballs)

Hyphae (molds)

Diagnosis

Microscopic examination

❖ Skin scales, nail & hair are examined microscopically after digestion using 10% KOH.

➤ Branching hyphae are detected among epithelial cells of skin & nails.

➤ Hyphae or spores are detected in the hair. Spores either detected inside the hair (**endothrix**) or outside the hair (**ectothrix**).

Culture

❖ Culture on **Sabouraud's dextrose agar (SDA)**:

❖ The agar incubated at room temperature for 4 ws.

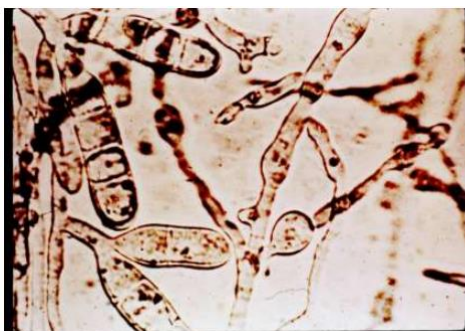The arising colonies examined microscopically after staining with **lactophenol cotton blue stain**.

Treatment

Local antifungal cream as miconazole or oral terbinafine weeks to months

- Diagnosis:
 - **KOH** method (KOH destroys all tissues except the fungal).
Note: KOH is the universal protocol for all fungal infections' diagnosis.
 - **Culture** method by SDA then using lactophenol cotton blue stain.
- It affects hair and nails, so we can take them as specimens.

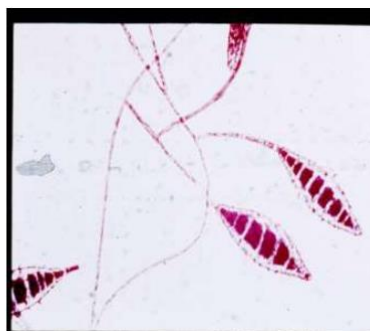COMMON DERMATOPHYTES



Epidermophyton

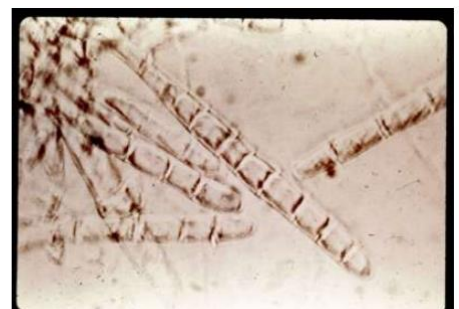
floccosum:

Bifurcated hyphae with multiple, smooth, club shaped **macroconidia** (2-4 cells)



Microsporum:

Thick wall spindle shape multicellular



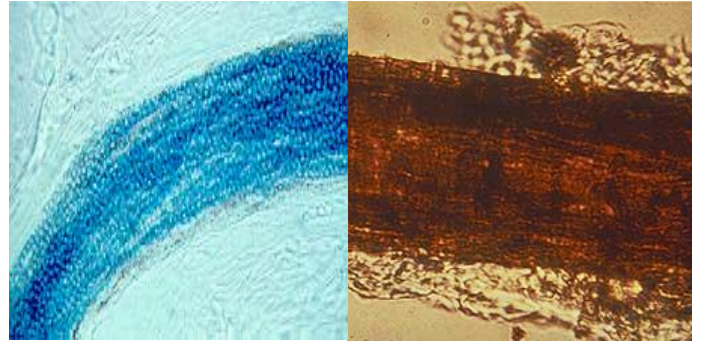
Trichophyton:

Large, smooth, thin wall, septate, pencil-shaped

- Patients after starting treatment may get **dermatophyte id reaction**, that they get sterile vesicles (no bacteria nor fungi). It's a hypersensitivity response.

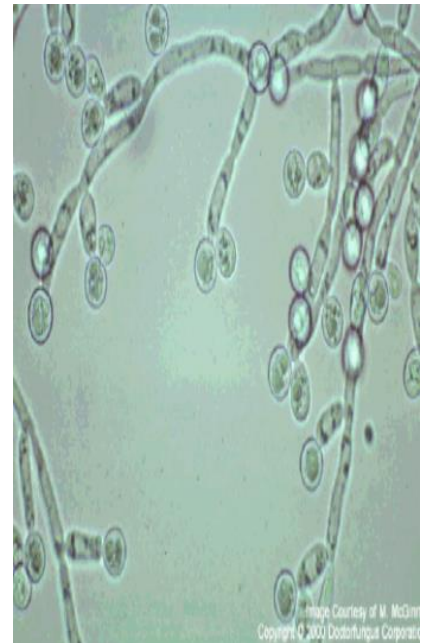
HAIR EXAMINATION

- The picture on the left is **endothrix**, it is a hair sample with fungal spores within the hair shaft.
- The picture on the right is **ectothrix**, the spores are outside the hair shaft.



CANDIDIASIS

- *Candida albicans* is the most important of the species of candida (**other species...**).
- *Candida albicans* is oval gram-positive budding yeast which produce **pseudohyphae**.
- They're normally yeasts, when they become pathogenic, they turn into pseudohyphae from, they even form true hyphae when they get deeper into tissues.
- It's a member of the normal flora that may go through overgrowth or be introduced to sterile sites. It **colonizes the mucous membranes of the upper respiratory, GIT & female genital tracts**.
- It causes superficial infections but can predominate with lowering in immunity causing infection, so it is one of the opportunistic fungi.

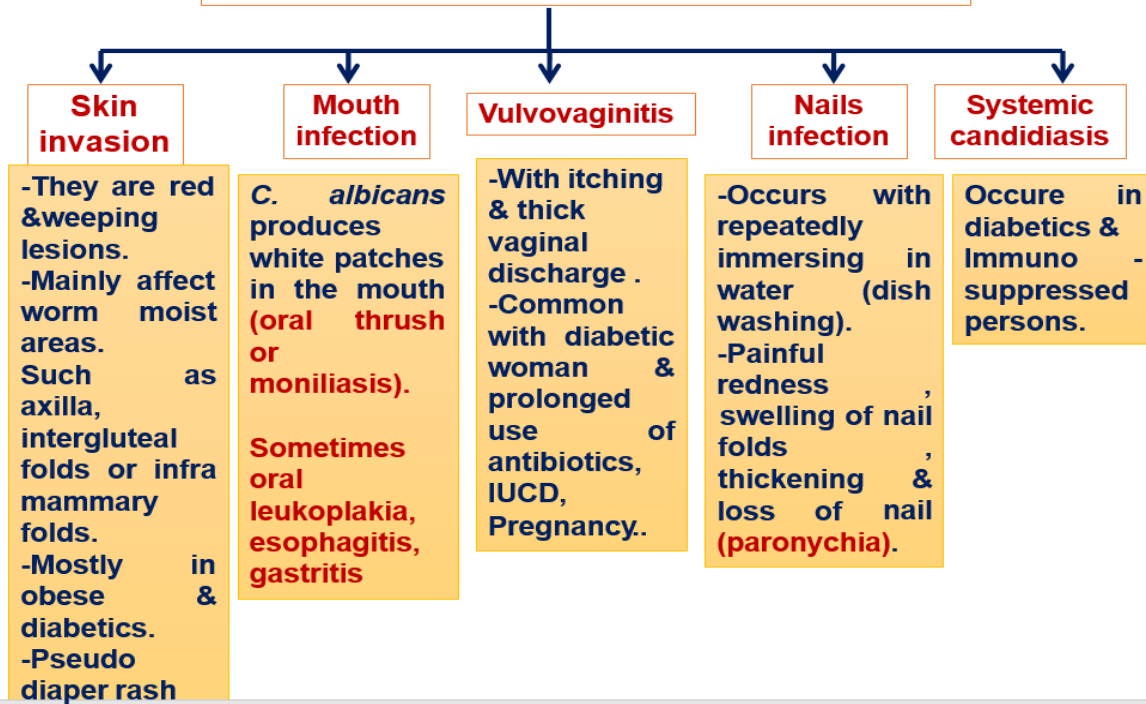


PREDISPOSING FACTORS TO CANDIDA INFECTIONS

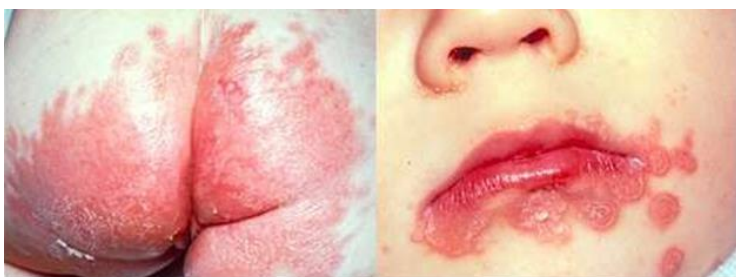People at high risk of getting infected:

- 1- Diseases as **AIDS & diabetes mellitus**.
- 2- Drugs: prolonged treatment with **broad spectrum antibiotics & corticosteroids**.
- 3 - **General debility** (e.g.: patients in the ICU).
- 4 - Indwelling **urinary** or vascular **catheters**.

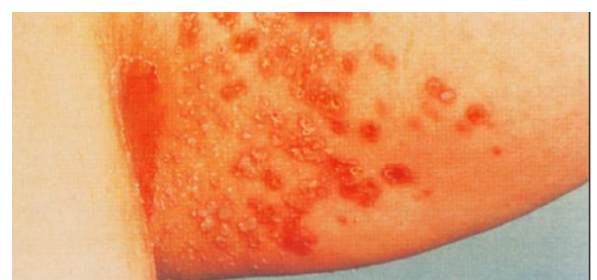Pathogenesis & Symptomatology



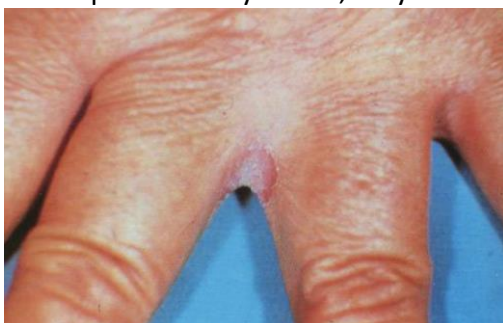- Candidiasis typically takes place where two opposing surfaces of skin meet (axilla, inframammary, etc.).
- Oral thrush (moniliasis): white membrane covering all the mouth.
- Vulvovaginitis is characterized by redness, itchiness, and vaginal cottage-cheese discharge (odorless).
there are factors that predispose the infection in women, for example diabetes or usage of prolonged usage of antibiotics which disrupts the normal flora and causes these organisms to grow
- Nail infections here include the nail bed **and fold**, it's **painful**.



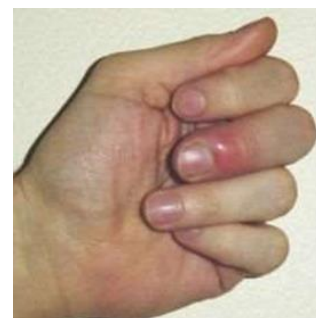Diaper rash: erythema, may contain scales



Red-weeping lesions in the axilla



Candida finger web erosion: related to fatness, occupation etc. common with cockers who keep their hand in water for prolonged time.

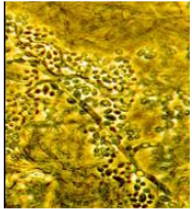


Paronychia: red, painful, tender, and no yellowish

Laboratory diagnosis

Direct microscopic examination

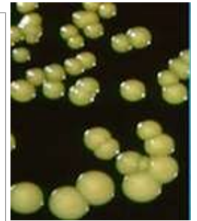- Specimens from skin, vaginal discharge or exudates from mucous surfaces are examined.
- *C. albicans* is oval gram positive budding yeast cell with pseudohyphae.



Culture

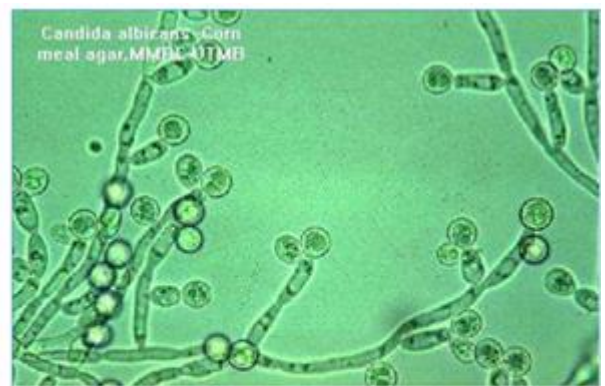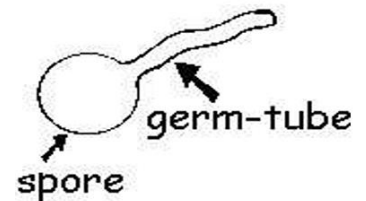
On nutrient agar, corn meal agar & SDA. Colonies are creamy in color & identified by:

- 1 **Morphology:** oval budding gram +ve yeast cells.
- 2 **Differentiation tests:**
 - a. **Germ tube test :** germ tube is formed when colonies incubated with human serum at 37 C for 30 min.
 - b. **Chlamydospore** formation on corn meal agar.
 - c. **Biochemical reactions:** *C. albicans* ferments glucose & maltose with acid & gas production.

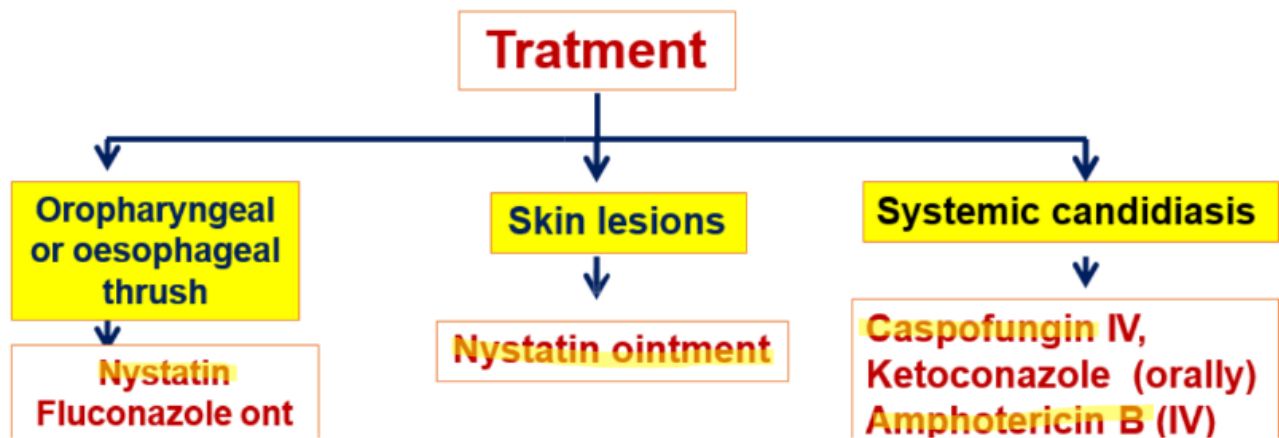


30

- All *Candida* species, if cultured on SDA, shows white creamy waxy colonies.
- The differentiation tests in the culture are used for differentiation between the species of *Candida*.
- If this germ tube is formed, we can make sure that this is *C. albicans*.
- for *C. albicans*, you can see under the microscope pseudohyphae with terminal chlamydospores.
- As you can see in cutaneous and the oropharyngeal topical and oral treatments are given, but systemic infections need systemic antifungals (aggressive).

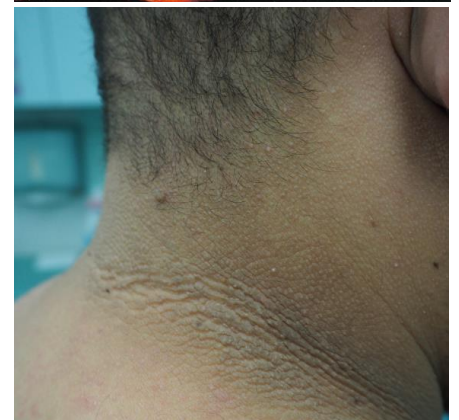
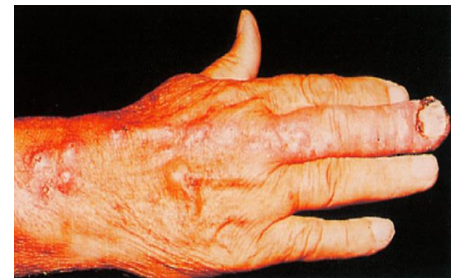
Terminal Chlamydospore & pseudohyphae



SUBCUTANEOUS MYCOSES (SPOROTRICHOSIS)

- Nodular condition caused by *Sporothrix schenckii*.
- This is a dimorphic fungus, exist as molds outside the body, and yeast inside it.
- The fungi introduced into subcutaneous tissues through trauma.
- Pathogenesis: traumatic implantation of *Sporothrix schenckii*, that normally resides on roses, into skin. Then, they start forming small nodules (chronic granulomatous reaction).
- These nodules grow larger and larger while they drain through lymphatics.
- Rose gardener's disease
- A small papule or subcutaneous nodule develops at the site of trauma 1 week to 6 months after inoculation, and infection spreads, producing a series of secondary nodules along the lymphatics that drain the site.
- This is **Acanthosis nigricans**, it may be confused with tinea versicolor. It is in the axilla and the back of the neck. It's a sign of insulin resistance and related to T2DM.



CREATE A LEGACY, SO THAT WHETHER THEY LIKE YOU OR NOT, THEY RESPECT YOU.

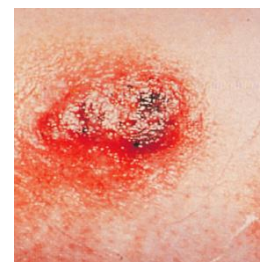➤ The next topics aren't exam material.

ENDEMIC MYCOSIS

- Endemic mycosis is caused by a thermally dimorphic fungus, and the infections are initiated in the lungs following inhalation of the respective conidia.
- Each of the four primary systemic mycoses—coccidioidomycosis, histoplasmosis, blastomycosis, and paracoccidioidomycosis—is geographically restricted to specific areas of endemicity.
- Most infections are asymptomatic or mild and resolve without treatment. However, a small but significant number of patients develop pulmonary disease.

COCCIDIOIDOMYCOSIS & BLASTOMYCOSIS

- *Coccidioides immitis* & *Blastomyces dermatitidis* are soil inhabiting Dimorphic Fungus, endemic in south-western U.S.A., northern Mexico and various parts of South America.
- Respiratory infection, resulting from the inhalation of microconidia, often resolves rapidly leaving the patient with a strong specific immunity to re-infection.
- Some individuals the disease may progress to a chronic pulmonary condition or a systemic disease involving the meninges, bones, joints, subcutaneous, cutaneous tissues.
 - Antigen Skin test positive.
 - Not significant in diagnosis.



LABORATORY DIAGNOSIS

- Direct microscopy and culture should be performed on all specimens (sputum, bronchial washings, CSF, pleural fluid tissue biopsies from various visceral organs).
- Wet mounts in 10% KOH with India ink, Ovoid-budding yeast cells (b) Gram-stain smear.
- Cultures on Sabouraud dextrose agar should be maintained for one month at 25°C, fungal growths & Wet Mount. Identification ..produces hyphae-like conidio-phores & Spores, color of fungal growth.
- Serological tests are of limited value, not significant.
- Detection of Histoplasm antigen in blood & urine is significant.

V2

- Page 7:
 5. Nails, **tinea unguinum** (also called **onychomycosis**).
It doesn't affect the nail bed and fold; it causes yellow and brittle nails.
No inflammation (redness). It's painless.
- Page 12:

This is a dimorphic fungus, exist as molds outside the body, and yeast inside it.