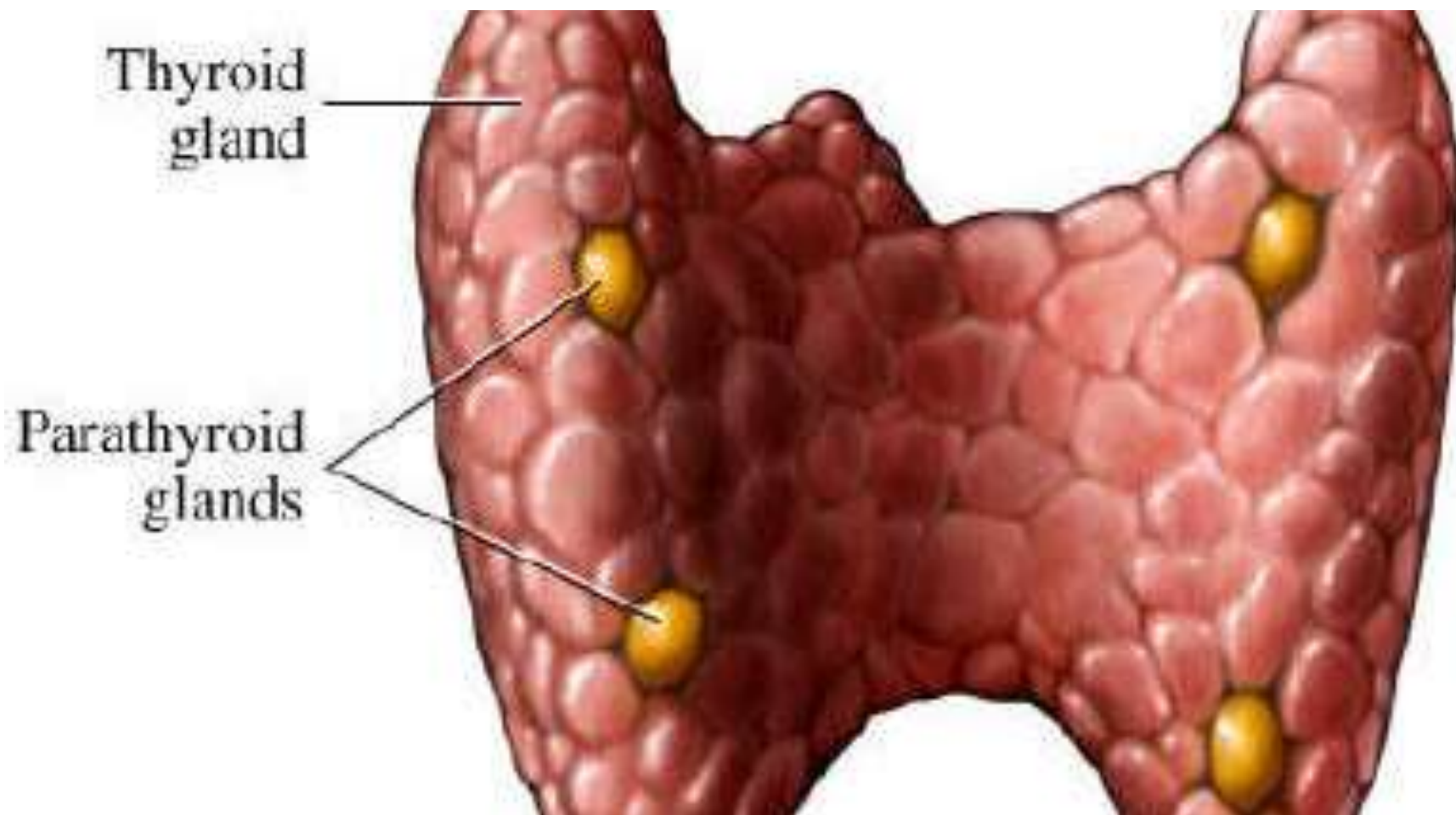


Diseases of the Parathyroid Glands

Dr Heyam Awad

FRCPath

Parathyroid gland = جار درقية



Parathyroid glands

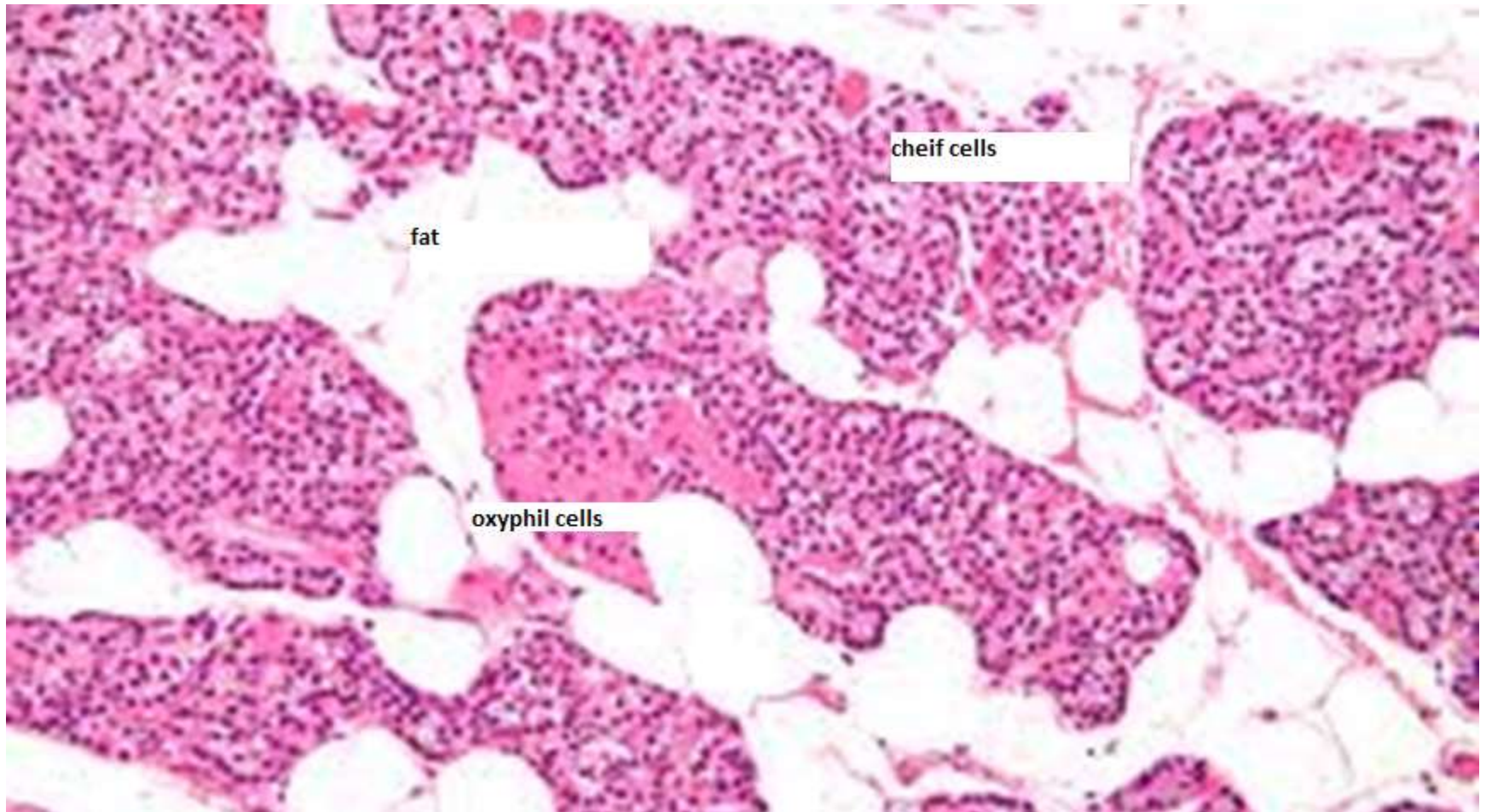
- There are **four** parathyroid glands
- They are derived from the **pharyngeal pouches**
- Located in close proximity to the upper and lower poles of each thyroid lobe.
- Each gland is yellow-brown in color and resemble lentil seed



Histology

- Parathyroid glands are composed of **chief cells** that secrete parathyroid hormone (PTH)
- **Oxyphil cells** are eosinophilic and contain mitochondria.. Their function is unknown. Some research suggests that they can secrete PTH in some cases of hyperparathyroidism
- **Normal parathyroid glands contain fat** as well.
- SEE NEXT IMAGES FOR DETAILS

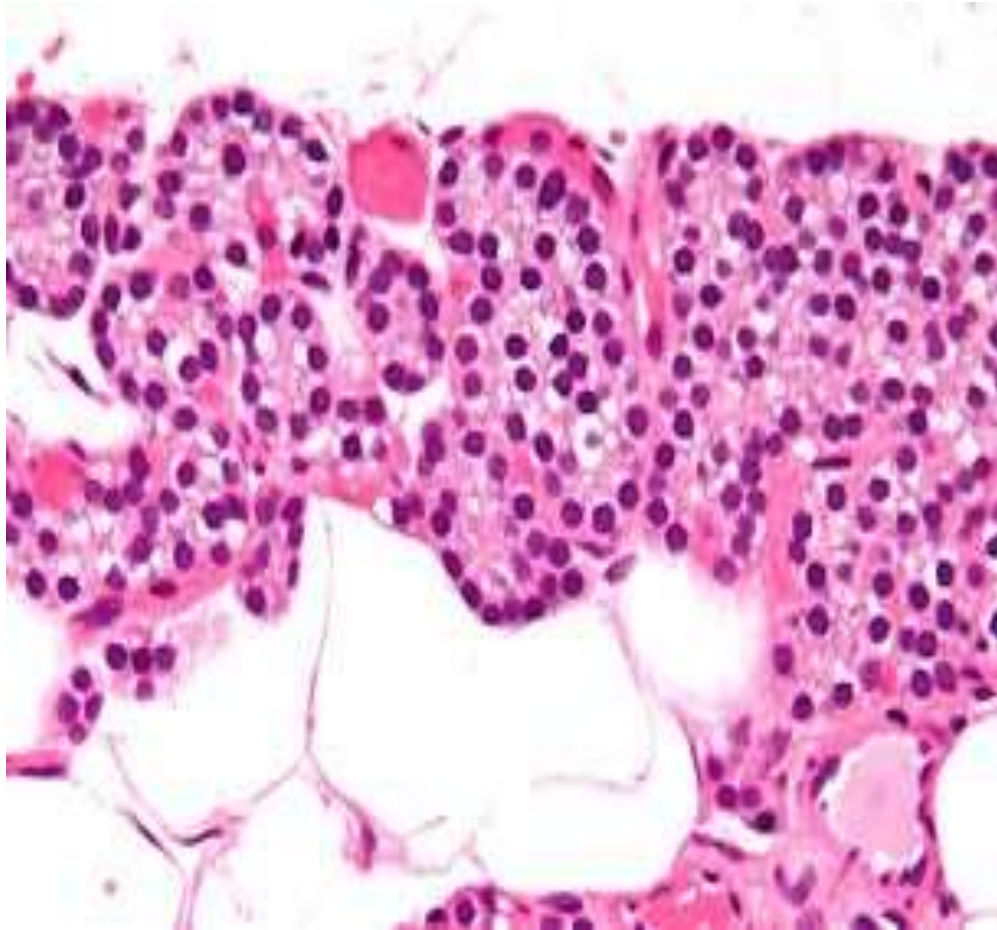
Parathyroid gland



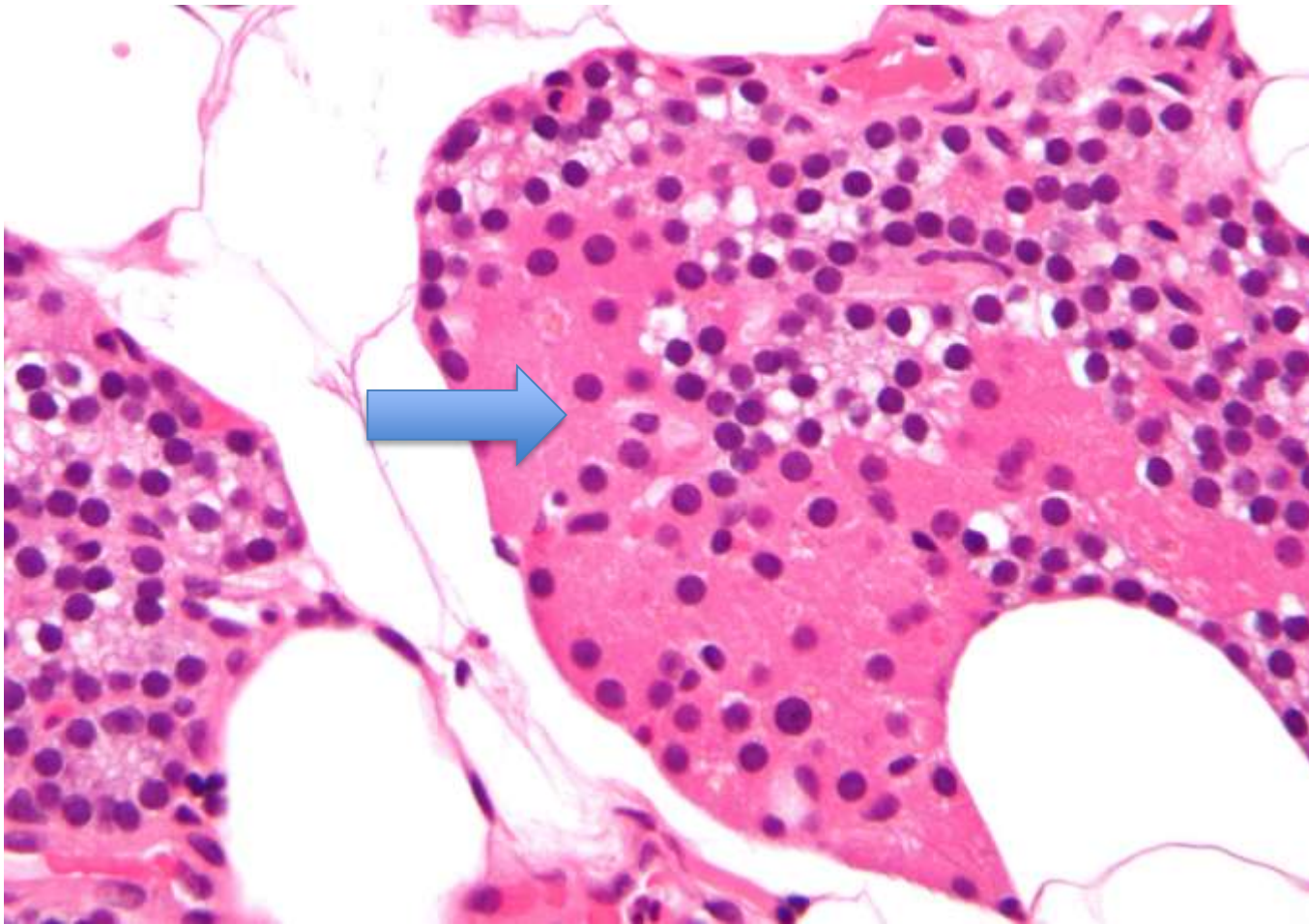
Note:

- As we said normal parathyroid contains fat.
- This is important to know because parathyroid hyperplasia and adenoma usually do not contain fat and this is an important feature to distinguish between them histologically.

Parathyroid chief cells



Oxyphil cells



Regulation of PTH

- PTH regulates calcium level in blood.
- If blood calcium decreases.. Parathyroid gland secretes PTH...
- NOTE: the regulation of PTH secretion is NOT under control of the pituitary BUT is regulated by calcium levels in the blood.

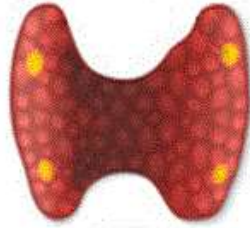Functions of PTH

- PTH increases blood calcium by its effects on the kidneys, GIT and bone.

PTH/ functions

- Increases **renal** tubular reabsorption of calcium
- Increases conversion of **vitamin D** to its active form.. Which increases **gastrointestinal** absorption of calcium
- Increases **osteoclastic activity** (increases bone resorption) so releasing calcium from bone to blood.
- Increases **phosphate excretion in urine**.. So phosphate level is decreased.. So less calcium binds to phosphate.. So more free calcium in blood.

Parathyroid Glands

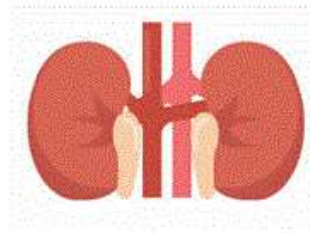


Parathyroid hormone (PTH)



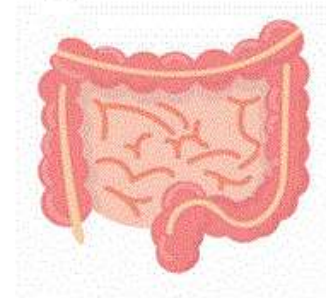
Bones

Release calcium



Kidneys

Reduce Calcium
clearance
Vitamin D activation



Intestines

Activated vitamin
D helps absorb
calcium in gut

Diseases of the parathyroid

- Hyperparathyroidism
- Hypoparathyroidism
- Mass lesions: adenomas and carcinomas.

HYPERPARATHYROIDISM :

- A. **Primary:** **autonomous** increase in parathyroid hormone not caused by decreased calcium (the problem is in the parathyroid gland or there is ectopic secretion of parathyroid hormone as a paraneoplastic syndrome)
- B. **Secondary:** parathyroid hormone increases **due to decreased calcium level**. The most common cause is renal failure.
- C. **Tertiary** hyperparathyroidism: in some patients with secondary hyperparathyroidism, the increased parathyroid hormone production becomes autonomous and not regulated by calcium levels.

Primary Hyperparathyroidism

- Primary: means **autonomous** secretion of PTH.. That is not caused by decreased calcium level
- Primary hyperparathyroidism is a common disorder and important cause of hypercalcemia

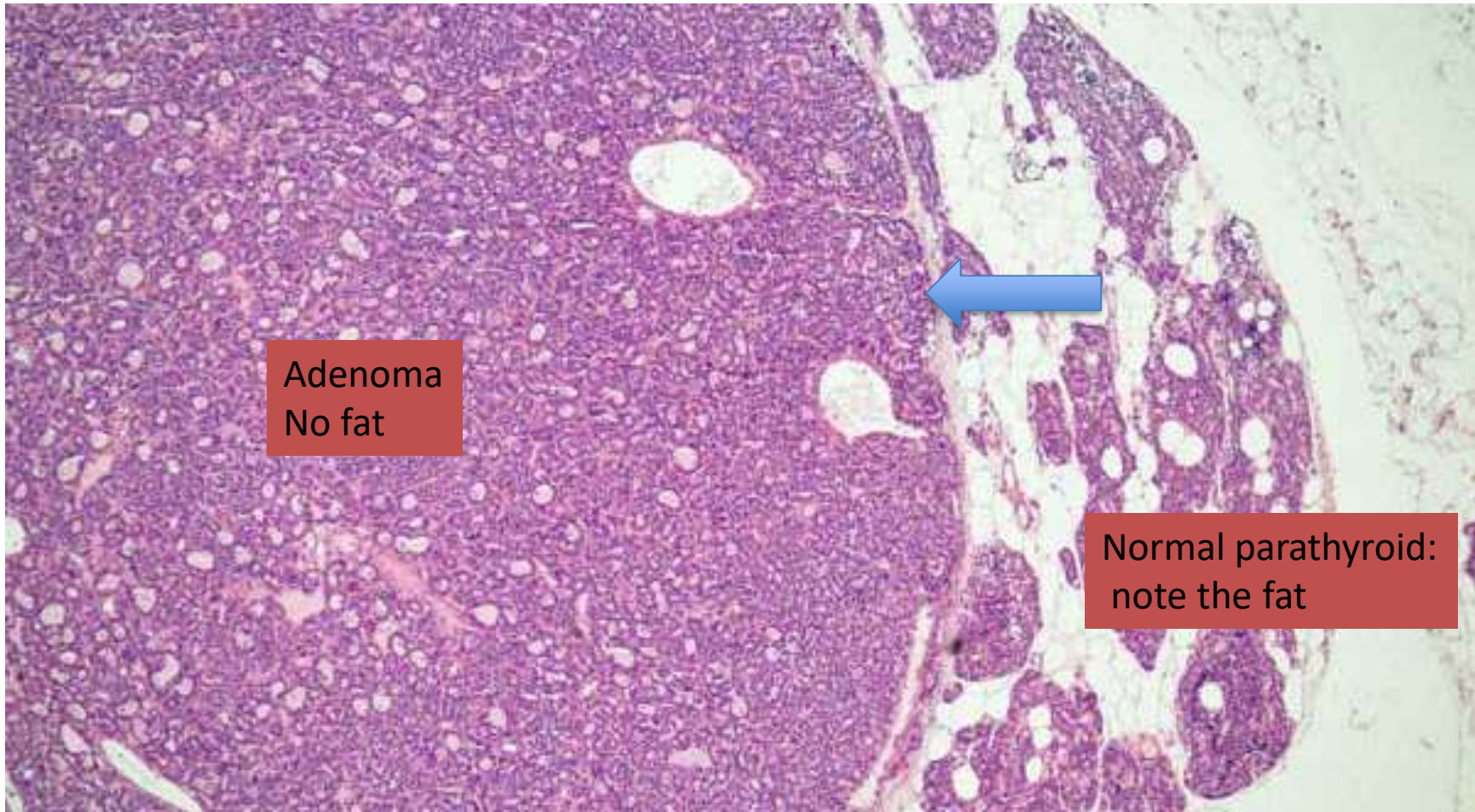
Causes of primary hyperparathyroidism:

1. **Parathyroid adenoma** (85% to 95%)
2. Primary parathyroid hyperplasia-5% to 10%.
3. Parathyroid carcinoma-(1%)

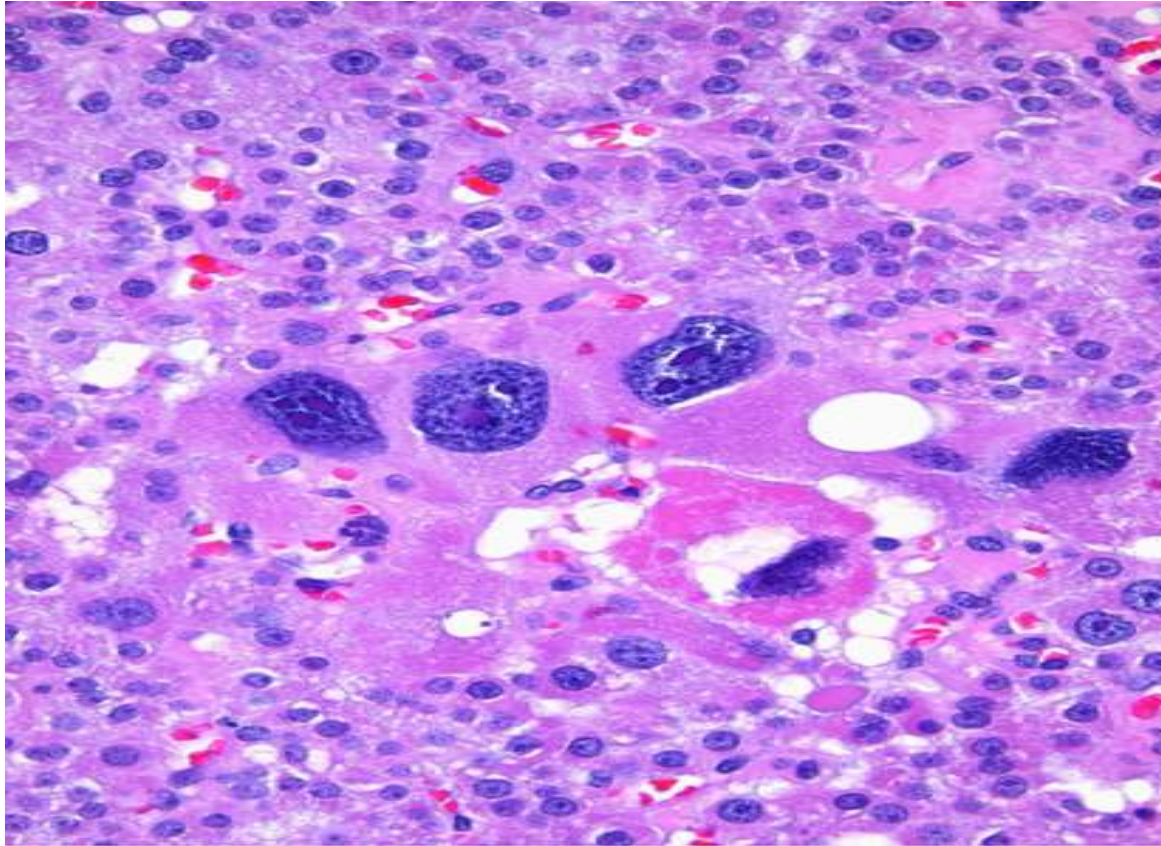
Parathyroid adenoma:

- Most parathyroid adenomas weigh between 0.5 and 5 g.
- They are encapsulated, soft and **solitary**.
- **One gland only is usually affected and the other three are normal or atrophic**
- A rim of compressed, normal, non-neoplastic, parathyroid tissue, separated by a fibrous capsule, is visible at the edge of the adenoma.
- Cells with pleomorphic nuclei may be seen (**endocrine atypia**) and must **not be taken as a sign of malignancy**.
- Mitotic figures are rare .
- inconspicuous adipose (fatty) tissue .

Parathyroid adenoma. Note the thin capsule (arrow) separating the adenoma from normal



Endocrine atypia.. This is not necessarily a malignant feature.



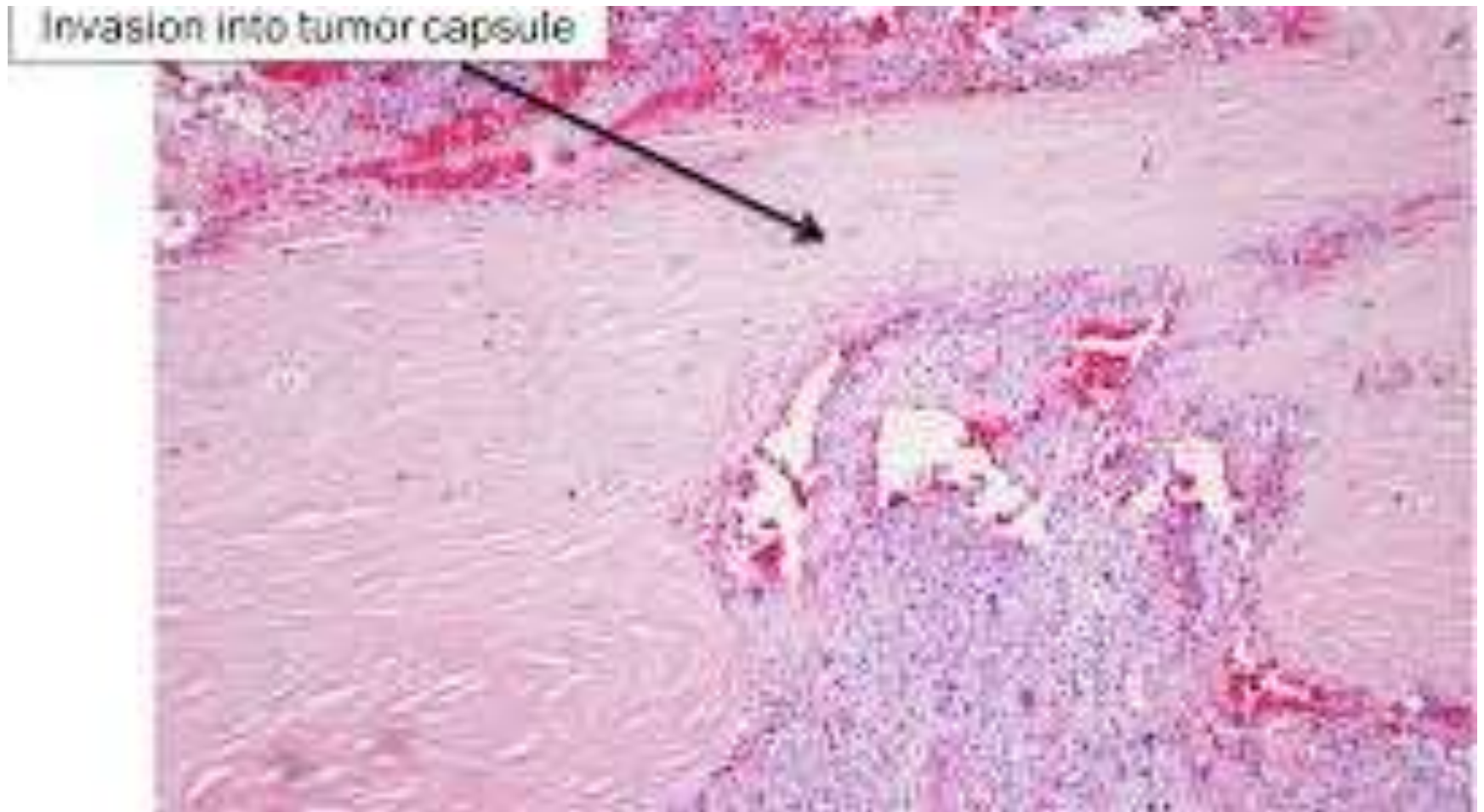Parathyroid hyperplasia

- **Multi-glandular** process (more than one gland enlarged)
- The combined weight of all glands rarely exceeds 1.0 g .
- Stromal fat is inconspicuous within foci of hyperplasia.

Parathyroid carcinomas :

- one gland affected.
- Consist of irregular masses that sometimes **exceed 10 g** in weight .
- The diagnosis of carcinoma based on cytologic detail is unreliable, and **invasion of tissues and metastasis** are the only definitive criteria
- **Local recurrence occurs in one third of cases,**
- **Distant dissemination (metastasis) occurs in another third**

Parathyroid carcinoma



note

- In hyperplasia, adenoma and carcinoma..
Amount of fat in the gland decreases.

Morphologic changes in other organs in hyperparathyroidism

- Hyperparathyroidism affects many organs and can result in
 - 1. skeletal changes
 - 2. kidney changes
 - 3. metastatic calcifications

1. Skeletal changes

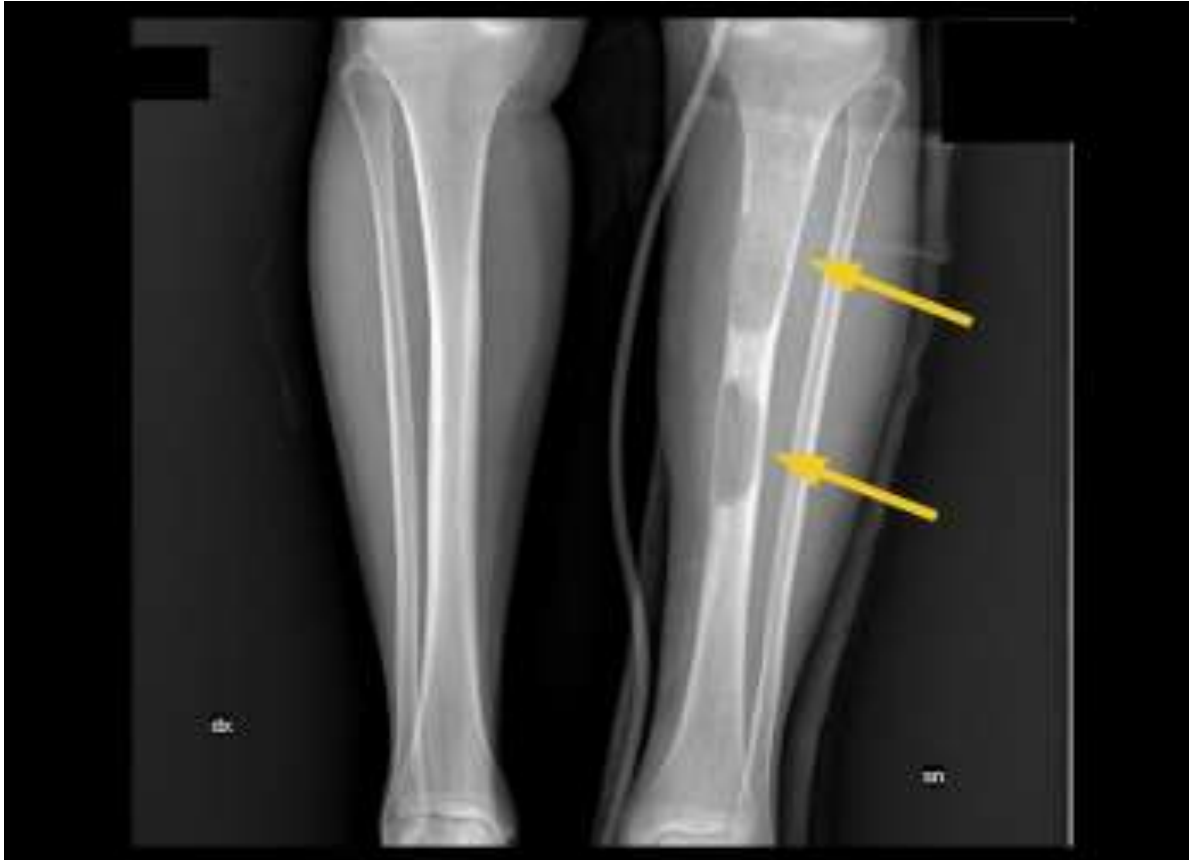A. Increased osteoclastic activity, resulting in erosion of bone and mobilization of calcium salts.

- In severe cases the cortex is grossly thinned and the marrow contains increased amounts of fibrous tissue accompanied by foci of hemorrhage and cysts (**Osteitis fibrosa cystica**)

B. Brown tumors of hyperparathyroidism)

- Aggregates of osteoclasts,, and hemorrhage occasionally form masses that may be mistaken for neoplasms

Osteitis fibrosa cystica



Osteitis fibrosa cystica

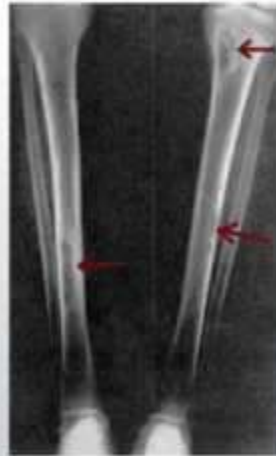
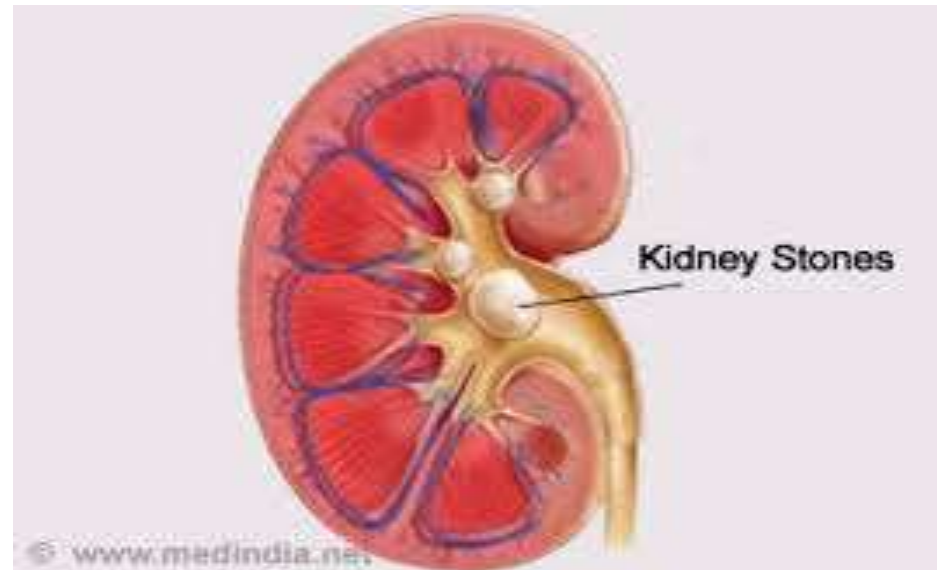
Image from Wikipedia.org licensed under available at wikipedia.org/wiki/Osteitis_fibrosa_cystica#/media/File:Xray.jpg

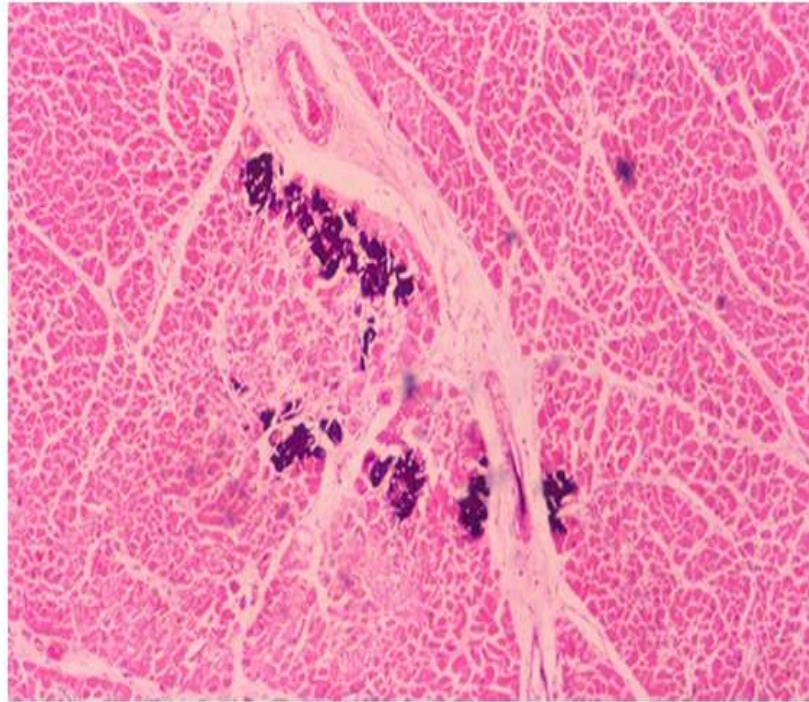
2. **Kidney changes**

- a. Increased calcium favours formation of urinary tract **stones** (nephrolithiasis)
- b. **Calcification** of the renal interstitium (nephrocalcinosis)



3. Metastatic calcification

- may be seen in the stomach, lungs, myocardium, and blood vessels



Clinical features of primary hyperparathyroidism

- Primary hyperparathyroidism is a disease of **adults** and is much more common in **women** than in men.
- *The most common manifestation is an increase in serum calcium*
- *Primary hyperparathyroidism is the most common cause of clinically silent hypercalcemia.*
- **Note: The most common cause of clinically apparent hypercalcemia in adults is malignancy: paraneoplastic syndromes or bone metastasis.**

Clinical Manifestations :

painful bones,
renal stones,
abdominal groans,
psychic moans.

Why the abdominal groans (abdominal pain)..reasons include:

peptic ulcers,
pancreatitis,
Gallstones
Renal stones

- Painful bones: due to fractured bones(bones become weak due to osteoporosis and osteitis fibrosa cystica and this causes fractures)

Secondary Hyperparathyroidism –

caused by chronic decreases in the serum calcium level

- *Renal failure is the most common cause*

Chronic renal insufficiency results in:

1. decreased phosphate excretion, which in turn results in hyperphosphatemia. Which depresses serum calcium levels and so stimulates parathyroid gland activity
2. Reduced availability of α_1 -hydroxylase enzyme necessary for the synthesis of the active form of vitamin D, which in turn reduces intestinal absorption of calcium

- Clinical Features

- Are dominated by those related to chronic renal failure
- Bone abnormalities (*renal osteodystrophy*) are less severe than those seen in primary type
- **Serum calcium remains near normal because compensatory increase in PTH levels sustains serum calcium.**

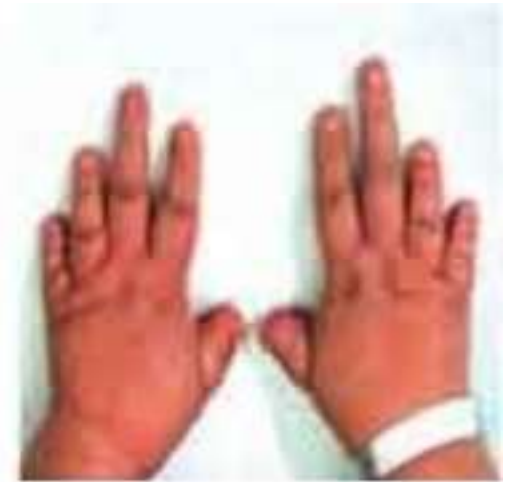Note- *In a minority of patients, parathyroid activity may become autonomous and excessive, with resultant hypercalcemia-a process sometimes termed tertiary hyperparathyroidism.*

HYPOPARATHYROIDISM:

Is less common than hyperparathyroidism and the major causes are:.

- a. *Surgically induced hypoparathyroidism*: inadvertent removal of parathyroids during thyroidectomy.
- b. *Congenital absence*: This occurs in conjunction with thymic aplasia (Di George syndrome) and cardiac defects,
- c. *Autoimmune hypoparathyroidism* :This is a hereditary polyglandular deficiency syndrome

Hypoparathyroidism



Causes:

- absent parathyroid from birth
- accidental removal upon thyroid removal

Symptoms:

- decreased Ca levels in blood (hypocalcemia)
- sensitive nerves
- uncontrollable spasms of the limbs

Treatment

- daily calcium and vitamin D supplements

*Thank
you*

