



Temporal and Infratemporal fossae

Dr. Heba Kalbouneh

DDS, MSc, DMD/PhD

Professor of Anatomy, Histology and Embryology

Muscles of Mastication

Temporalis muscle

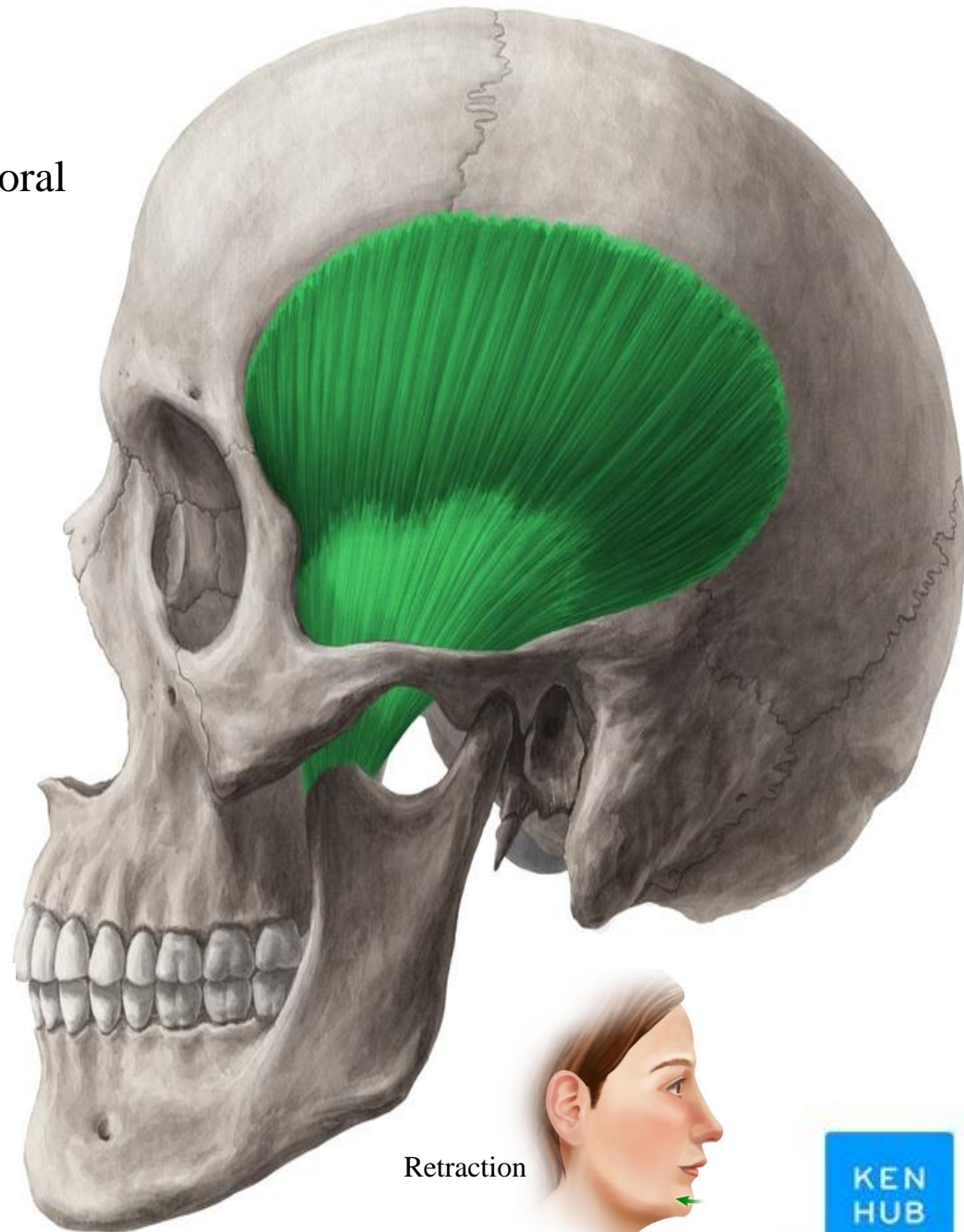Origin: from the bony surfaces of the temporal fossa

Insertion: coronoid process
And anterior border of the ramus of the mandible

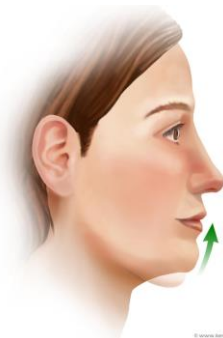Action: Temporalis is a powerful elevator of the mandible, **closing jaws**
Retraction of the mandible

Temporalis is innervated by deep temporal nerves from the **mandibular nerve [V3]**

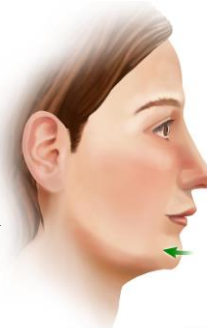Note: The temporalis muscle is a large fan-shaped muscle that fills much of the temporal fossa



Elevation



Retraction



Muscles of Mastication

Masseter muscle

Origin: the zygomatic arch, maxillary process of zygomatic bone.

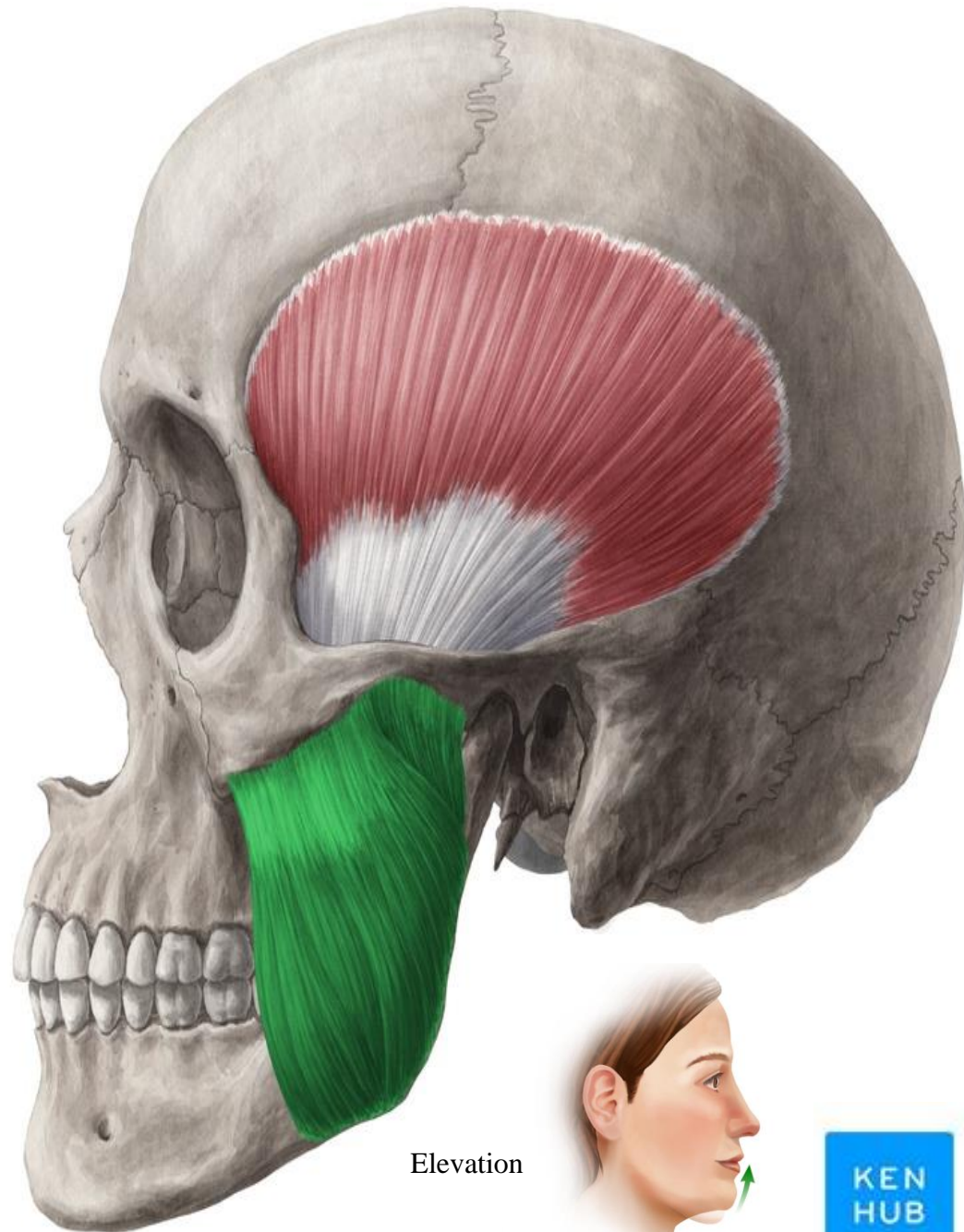
Insertion: into the lateral surface of the ramus of the mandible

Action: elevation of the mandible, **closing jaws**

The masseter is innervated by the masseteric nerve from the **mandibular nerve [V3]**

The masseter muscle is quadrangular in shape

Note: The masseter overlies the lateral surface of the ramus of the mandible



Elevation

Muscles of Mastication

Medial pterygoid

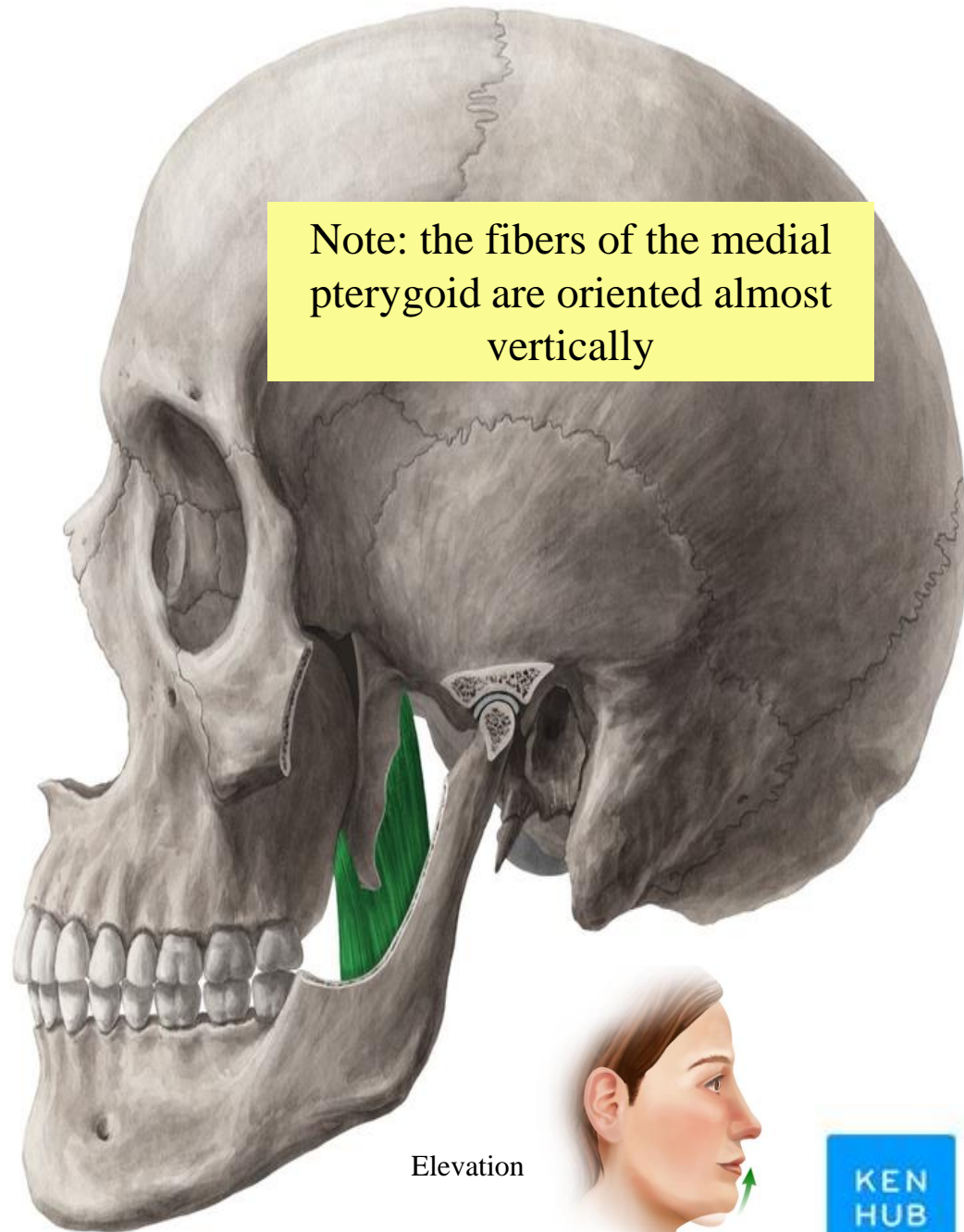
Origin: medial surface of the lateral pterygoid plate

Insertion: medial surface of the ramus of mandible near the angle

Action: The medial pterygoid mainly elevates the mandible, **closing jaws**

The medial pterygoid is innervated by the nerve to medial pterygoid from **the mandibular nerve [V3]**.

The medial pterygoid muscle is quadrangular in shape and has deep and superficial heads



Elevation

Muscles of Mastication

Lateral pterygoid

The upper head originates from the roof of the infratemporal fossa (inferior surface of the greater wing of the sphenoid and the infratemporal crest)

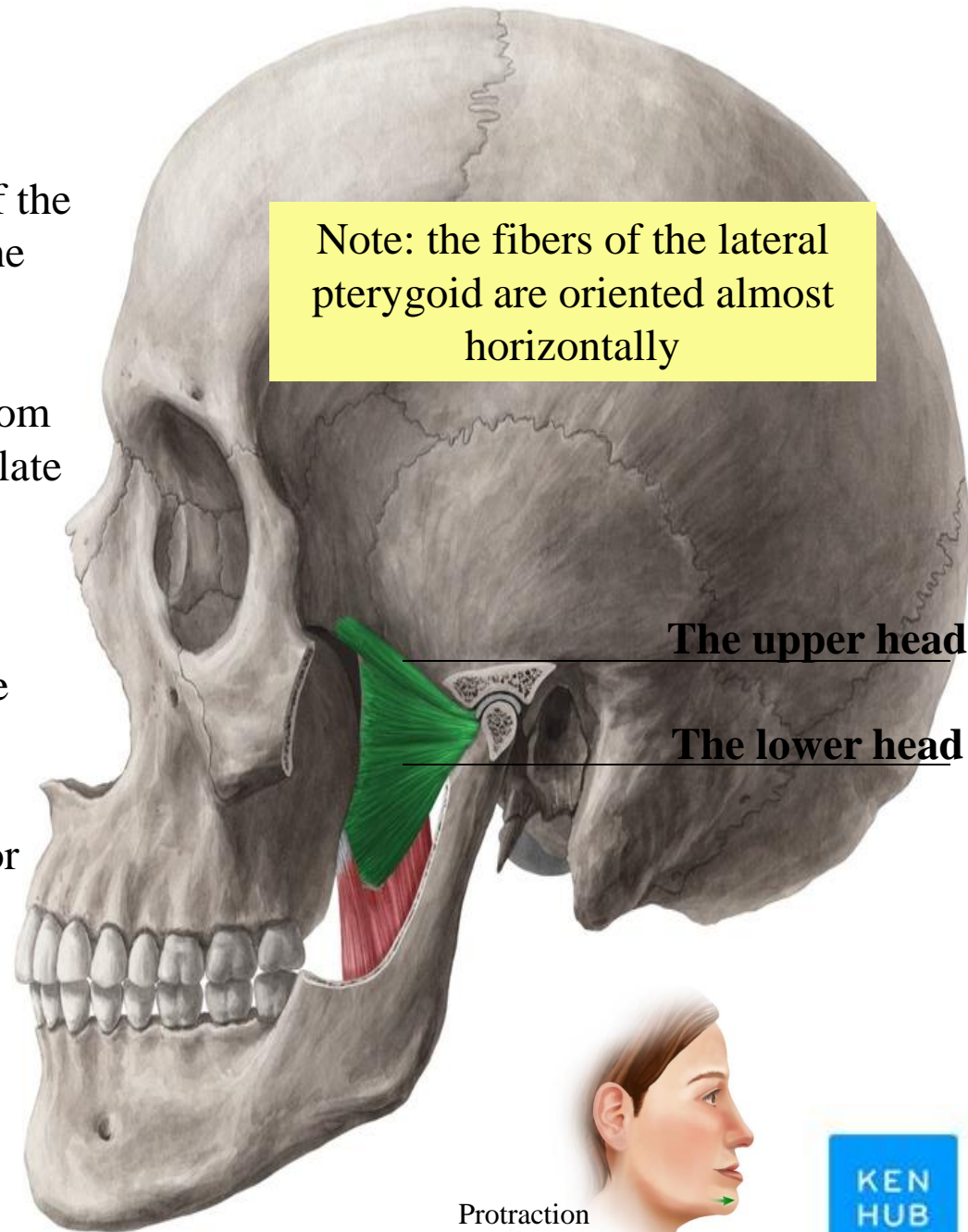
The lower head is larger and originates from the lateral surface of the lateral pterygoid plate

Insertion: into the neck of mandible (pterygoid fovea), into the capsule of the Temporomandibular joint (TMJ)

Action: The lateral pterygoid is the major protruder of the lower jaw

The lateral pterygoid is innervated by the nerve to lateral pterygoid from the **mandibular nerve [V3]**.

The lateral pterygoid is a thick triangular muscle and has two heads



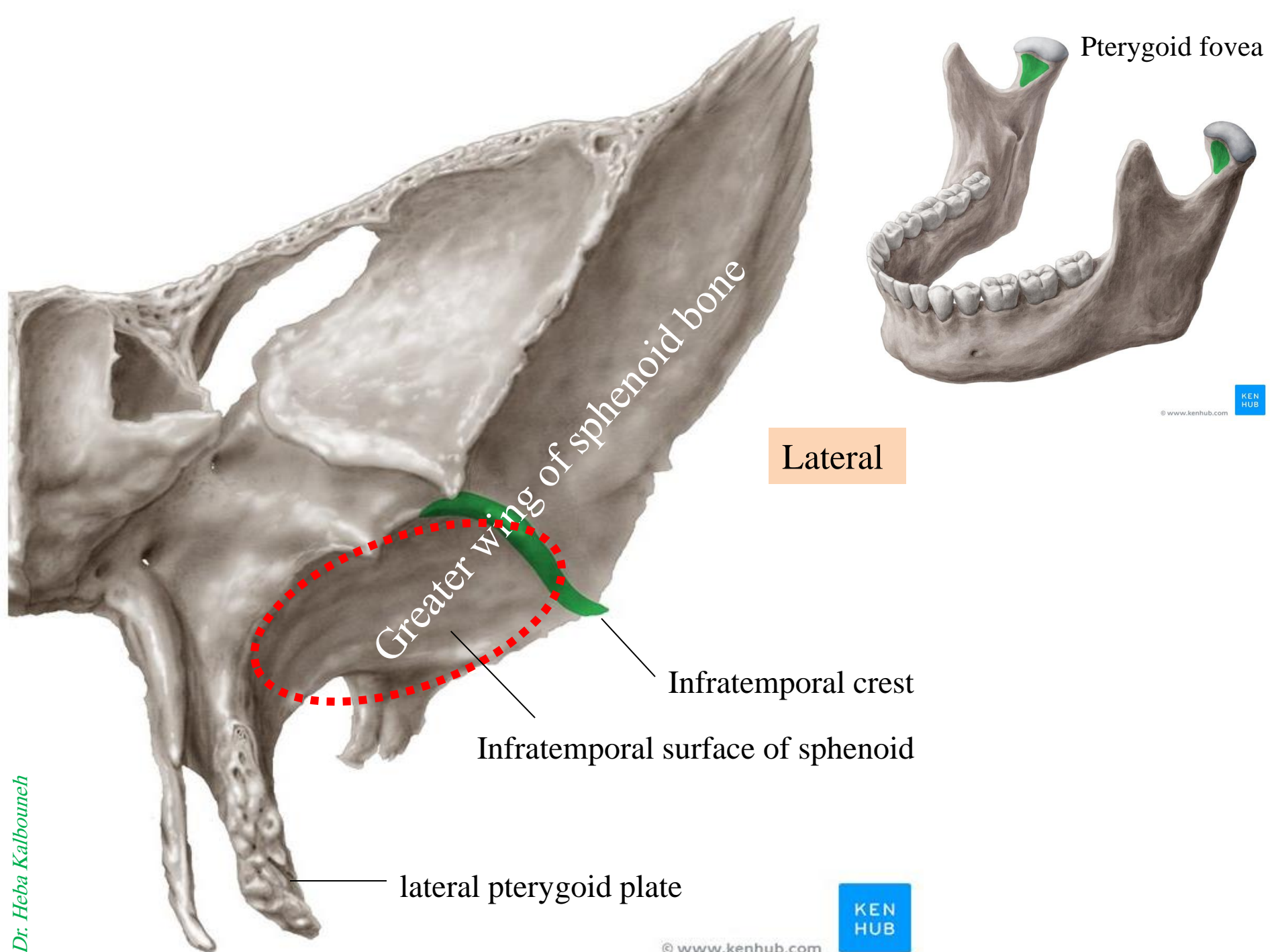
Note: the fibers of the lateral pterygoid are oriented almost horizontally

The upper head

The lower head

Protraction

KEN
HUB



Greater wing of sphenoid bone

Lateral

Pterygoid fovea

Infratemporal crest

Infratemporal surface of sphenoid

lateral pterygoid plate

© www.kenhub.com

KEN HUB

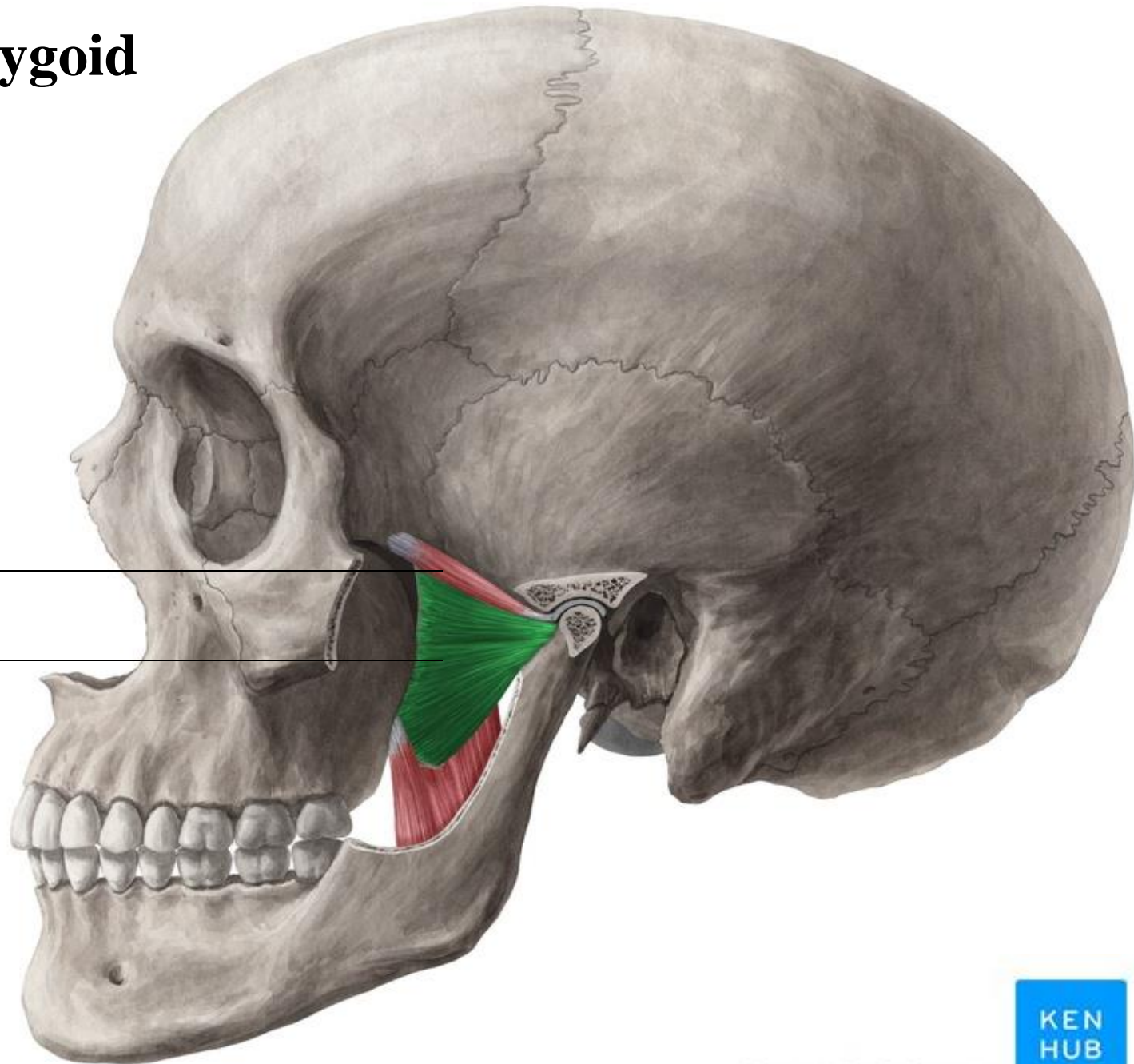
© www.kenhub.com

Dr. Heba Kalbouneh

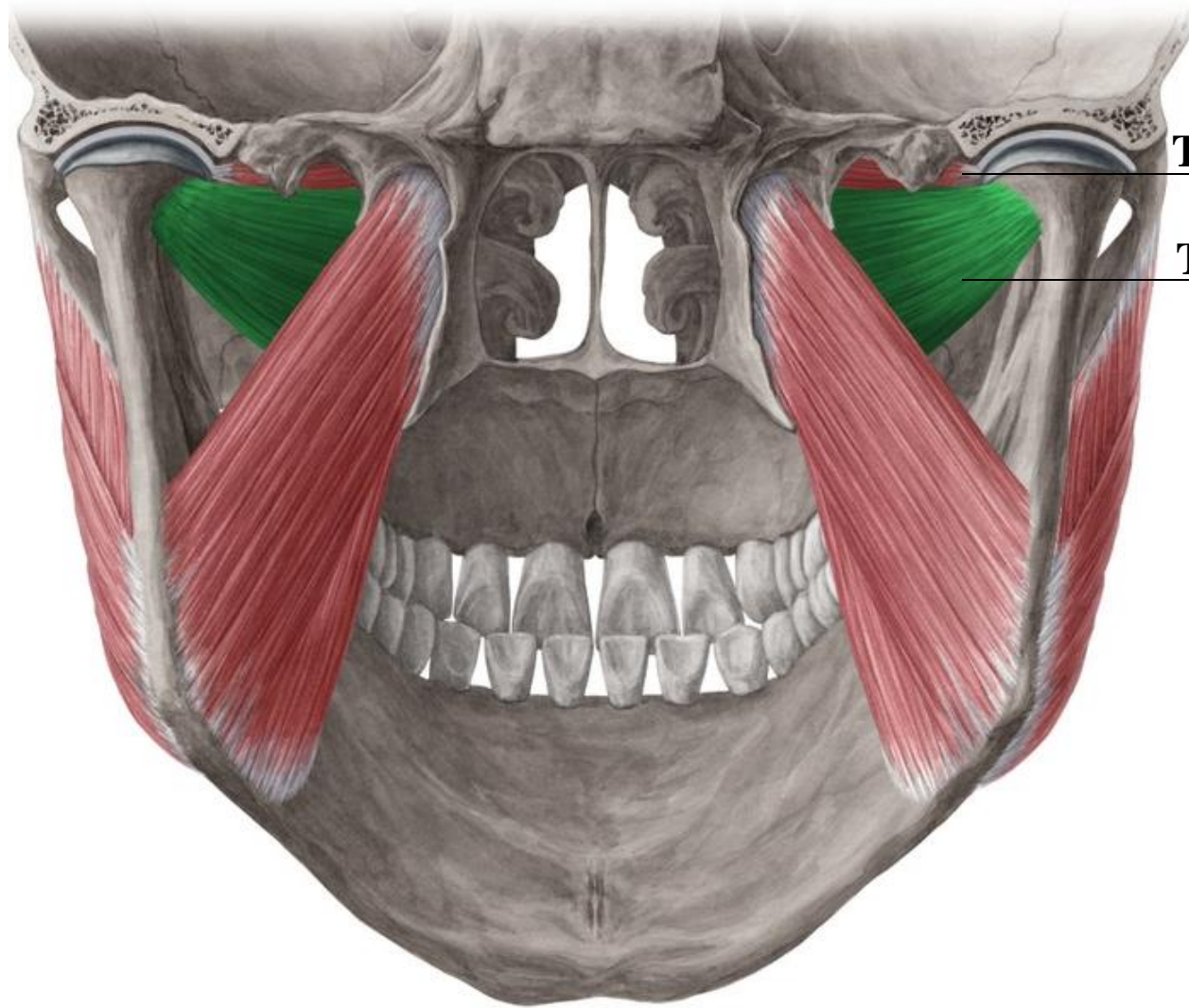
Lateral pterygoid

The upper head

The lower head



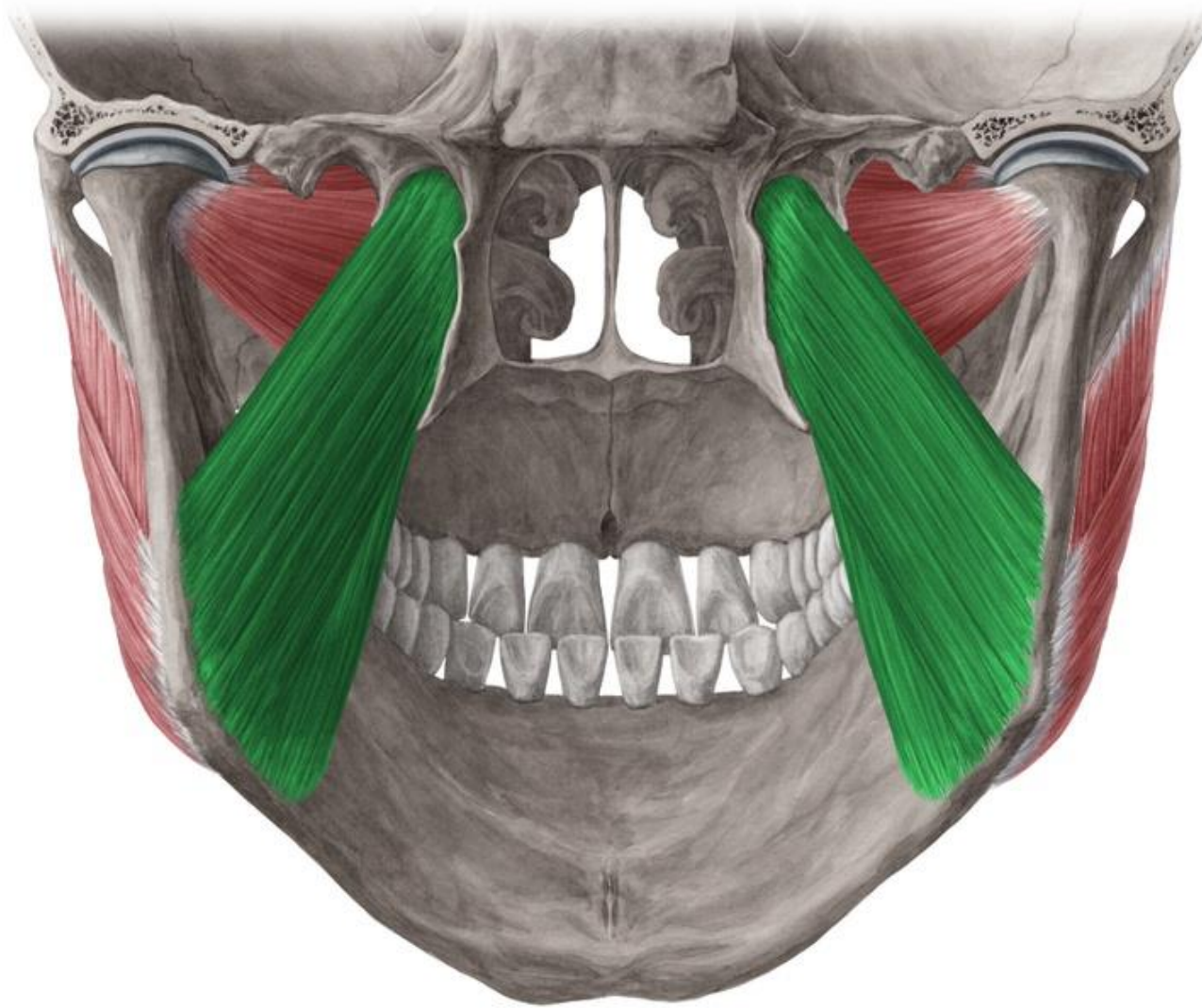
Lateral pterygoid



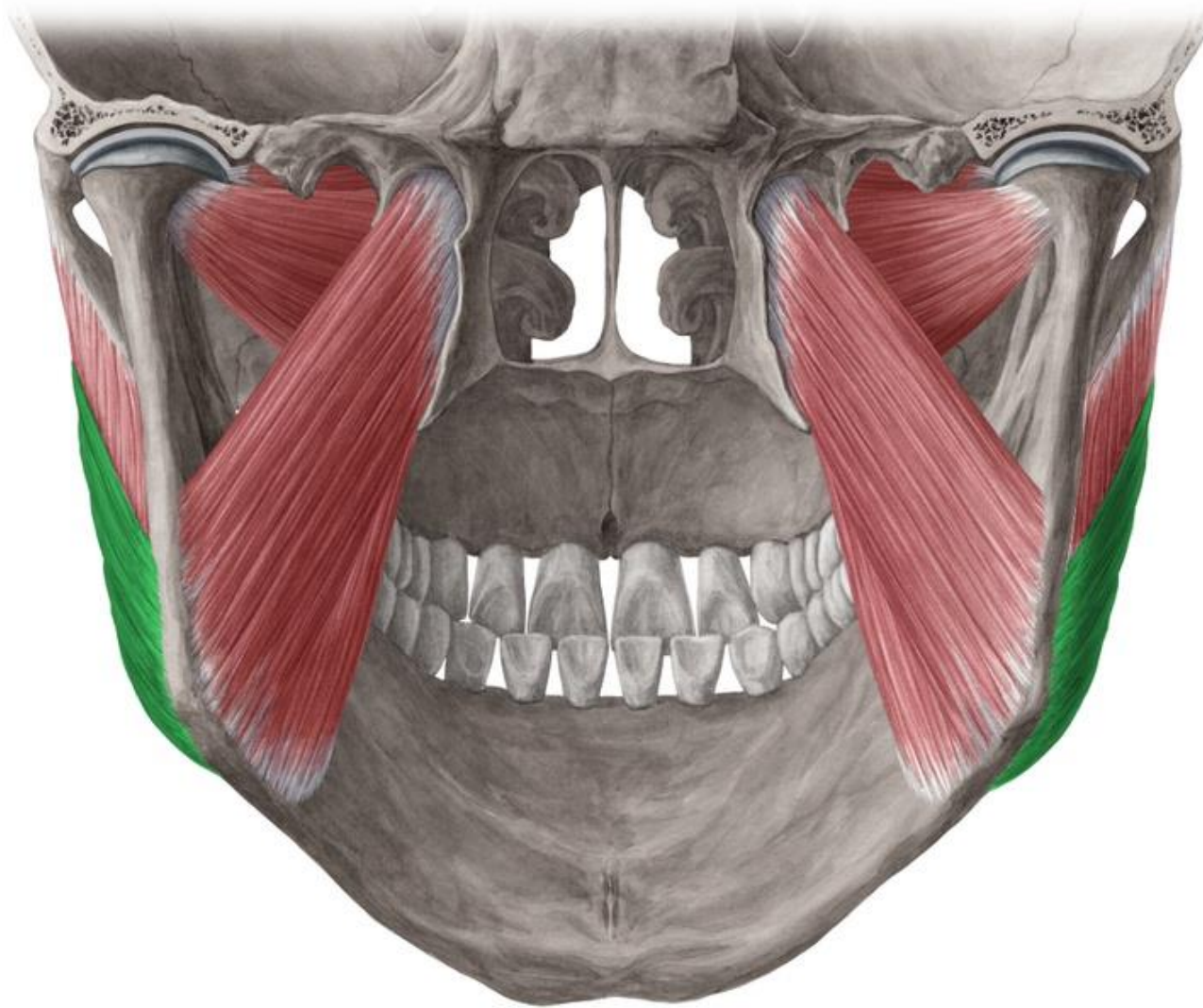
The upper head

The lower head

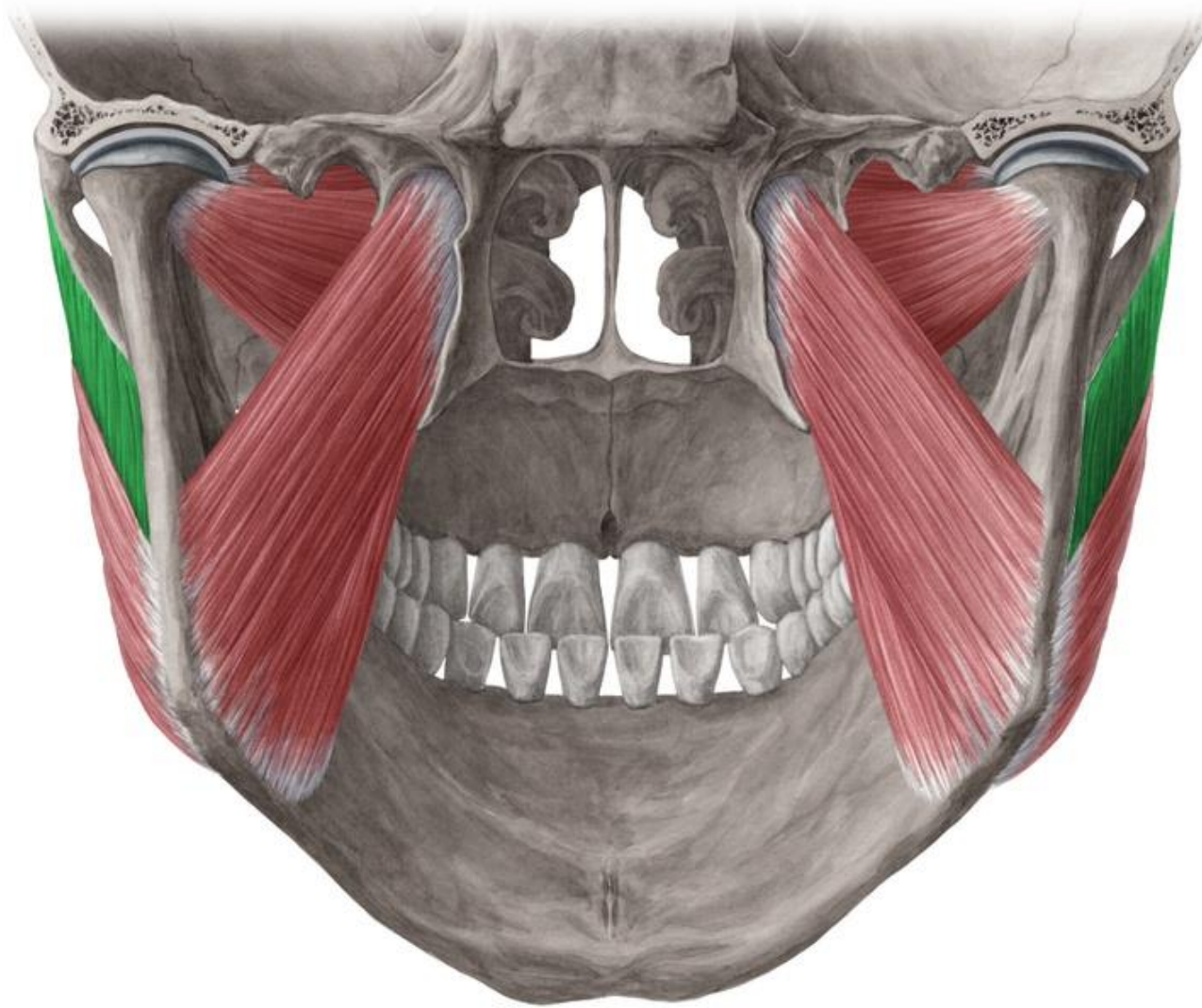
Medial pterygoid

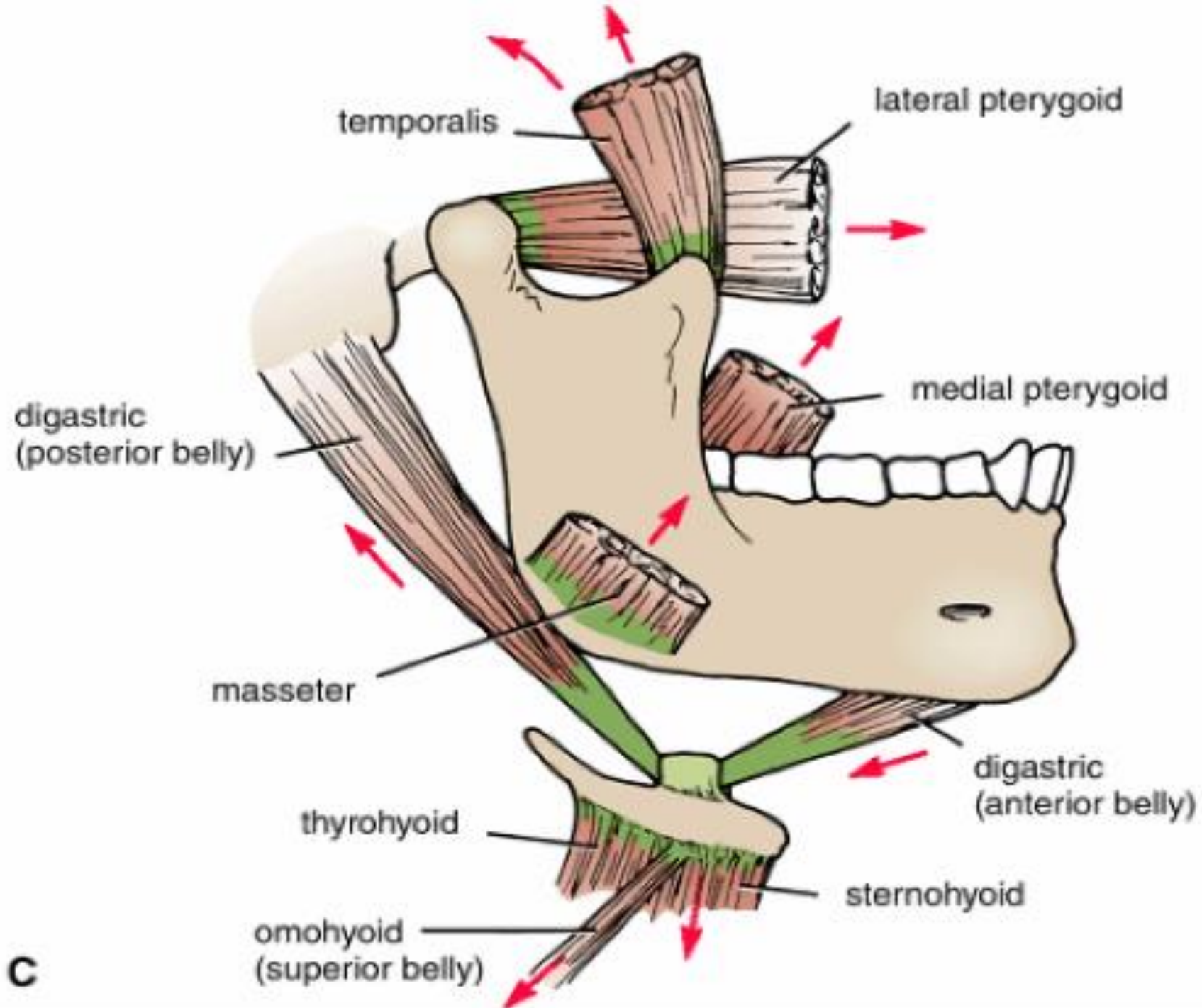


Masseter/ Superficial part



Masseter/ deep part



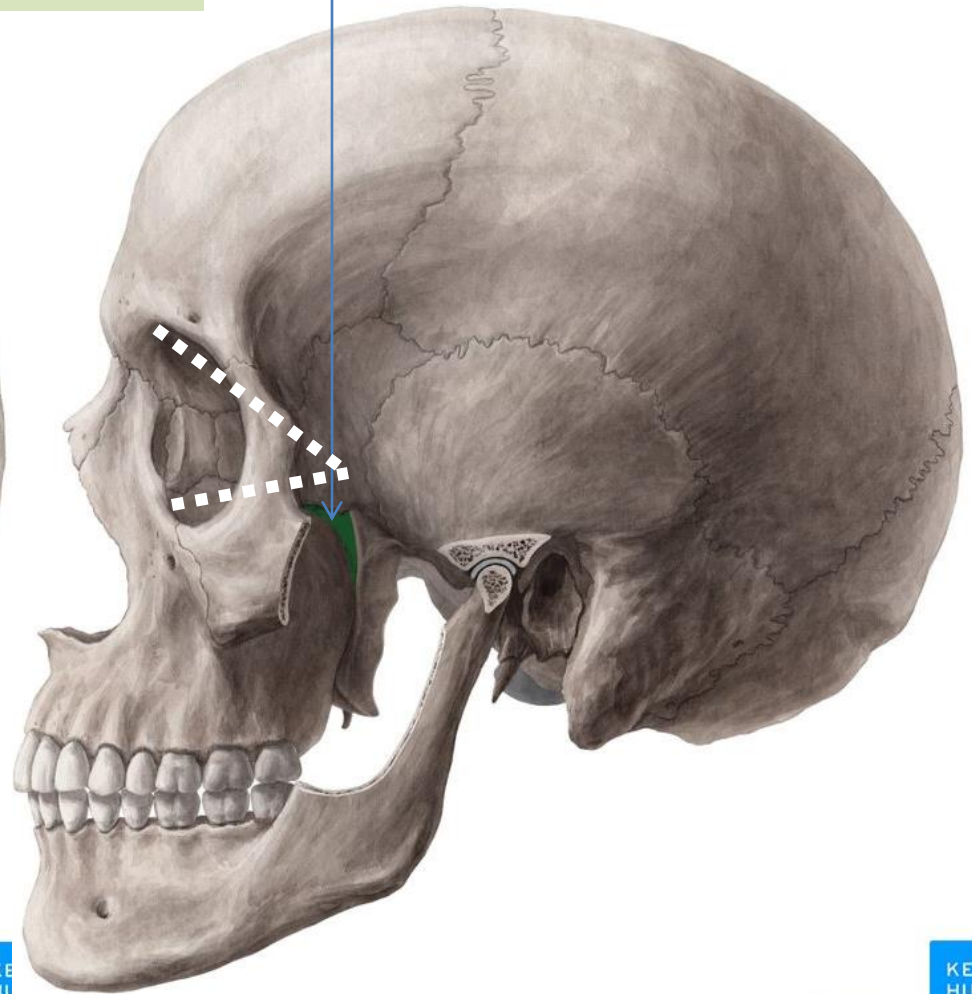
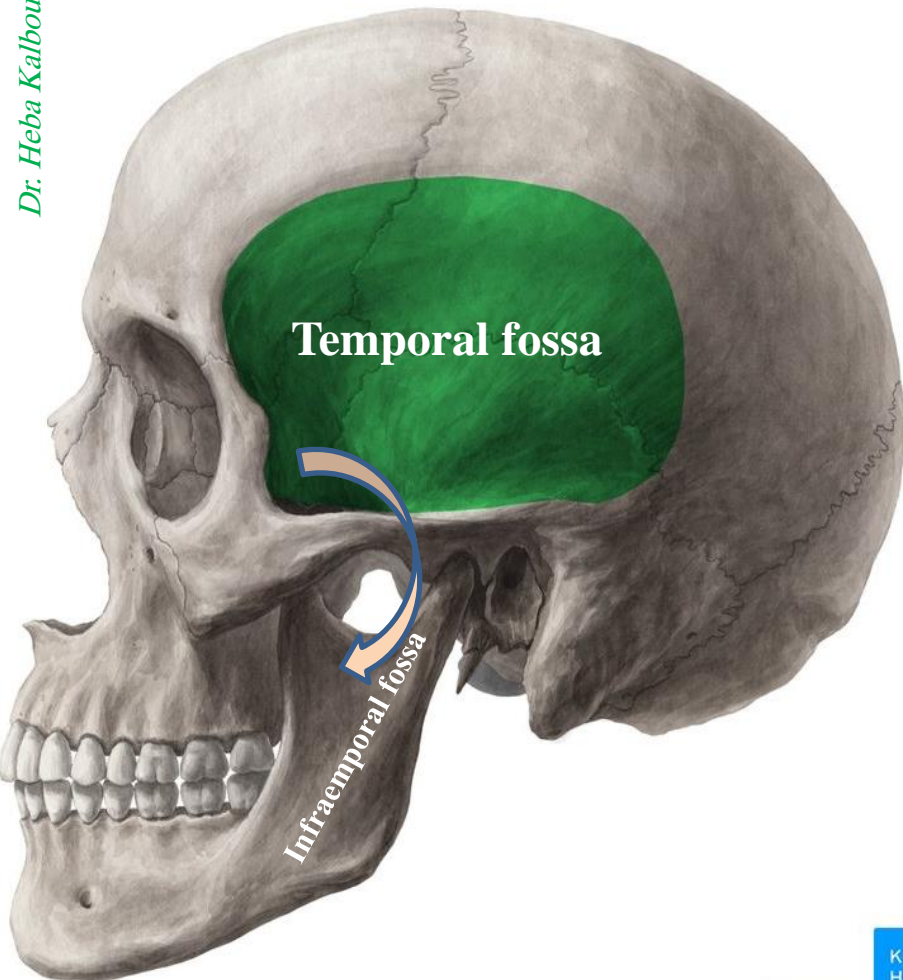


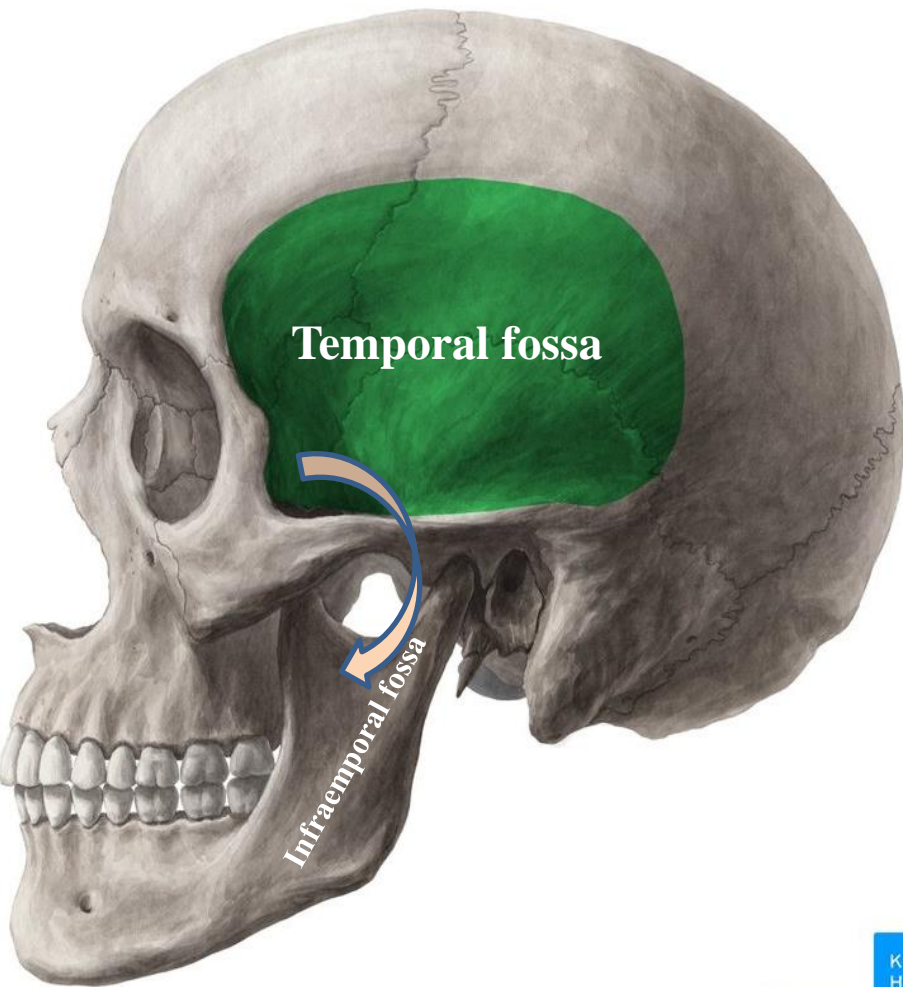
Temporal and infratemporal fossae are interconnected spaces on the lateral side of the head

Temporal fossa is superior to the infratemporal fossa above the zygomatic arch


Pterygo-palatine fossa
Lies below the apex of the orbit

Dr. Heba Kalbouneh

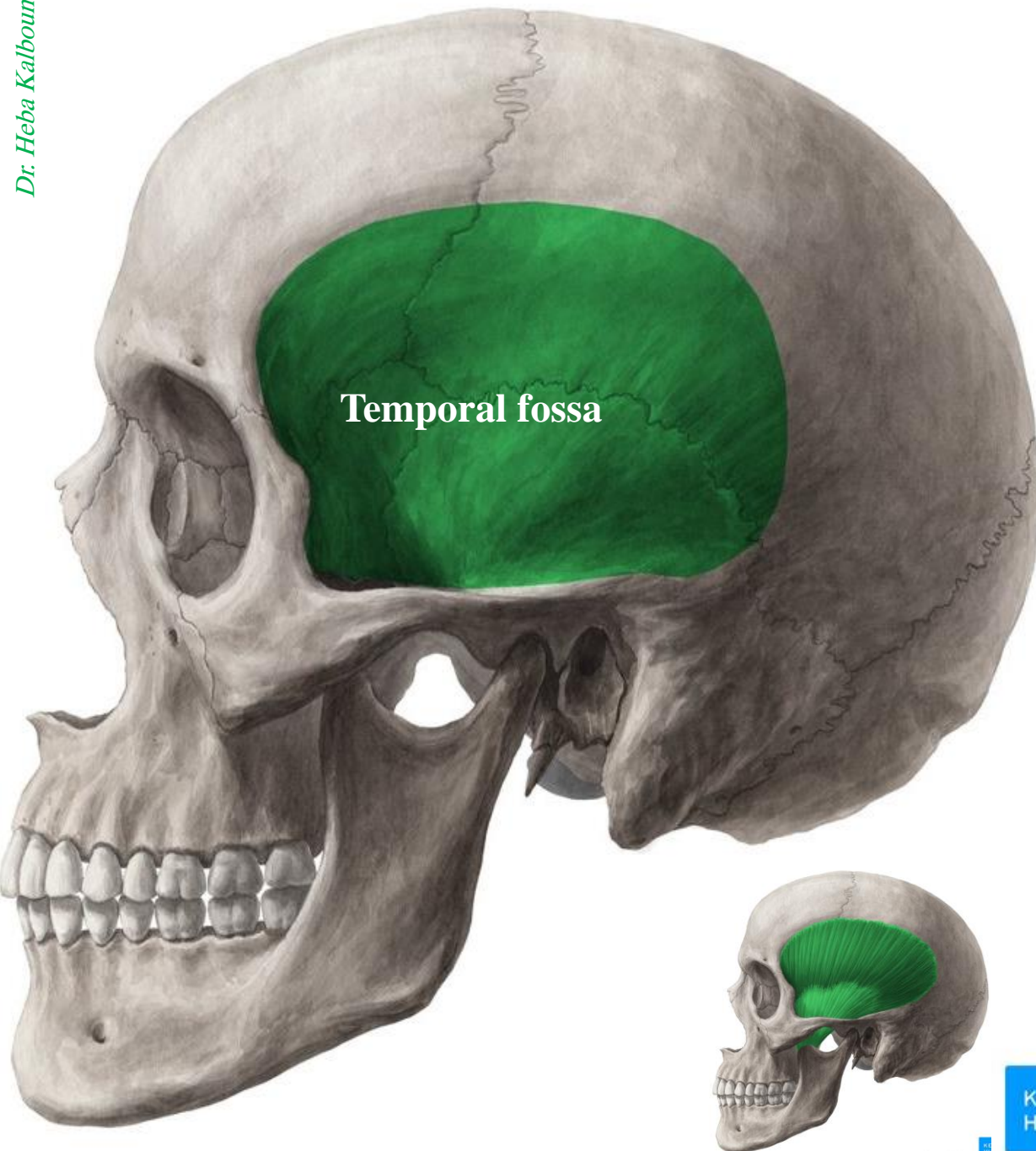




Of the four muscles of mastication (masseter, temporalis, medial pterygoid, and lateral pterygoid) that move the lower jaw at the TMJ



One (masseter) is lateral to the infratemporal fossa
Two (medial and lateral pterygoid) are in the infratemporal fossa
One fills the temporal fossa (temporalis)



Temporal fossa is a narrow fan shaped space that covers the lateral surface of the skull

Floor is formed by 4 bones:
frontal, parietal, temporal,
and sphenoid

Contents

Temporalis muscle

Temporal fascia

Deep temporal arteries

Deep temporal nerves

Zygomaticotemporal nerve

Superficial temporal vessels

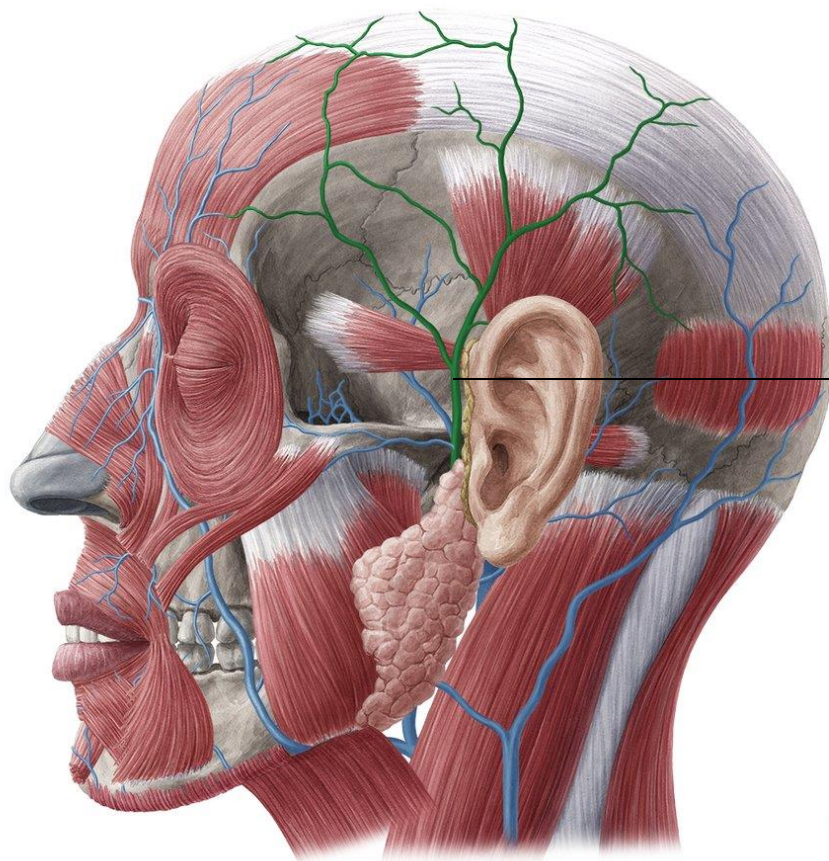
Auriculotemporal nerve

Temporal branch of facial nerve

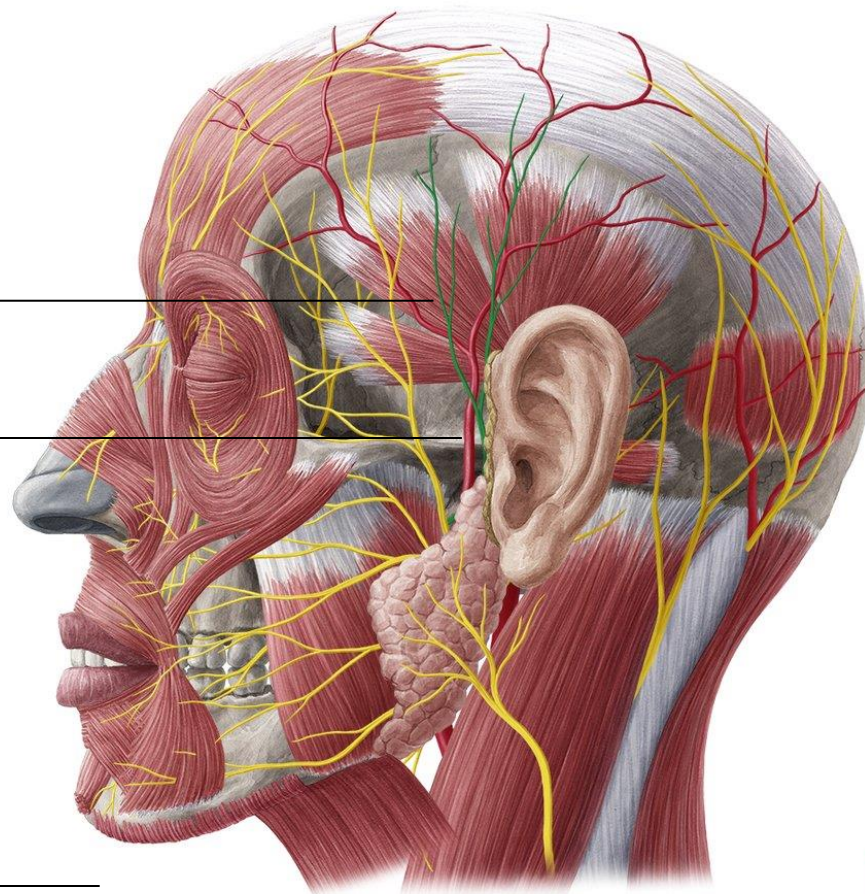
Middle temporal artery

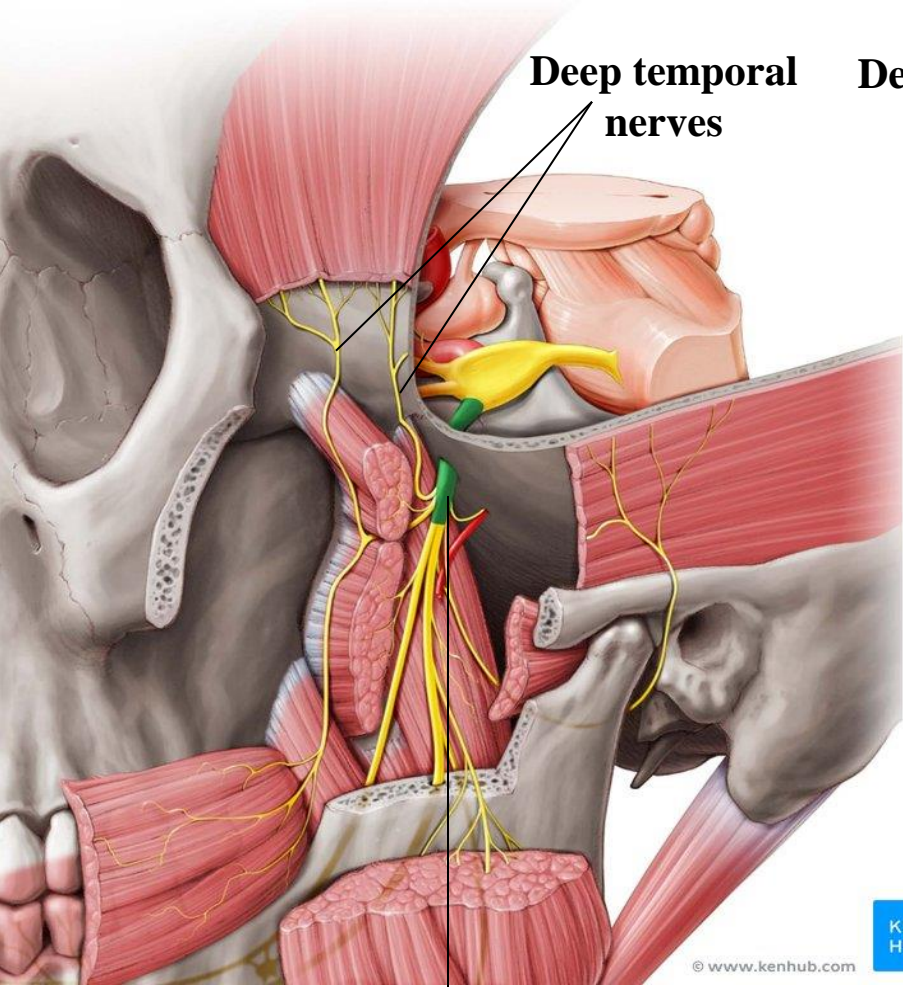
Auriculotemporal nerve

Superficial temporal artery

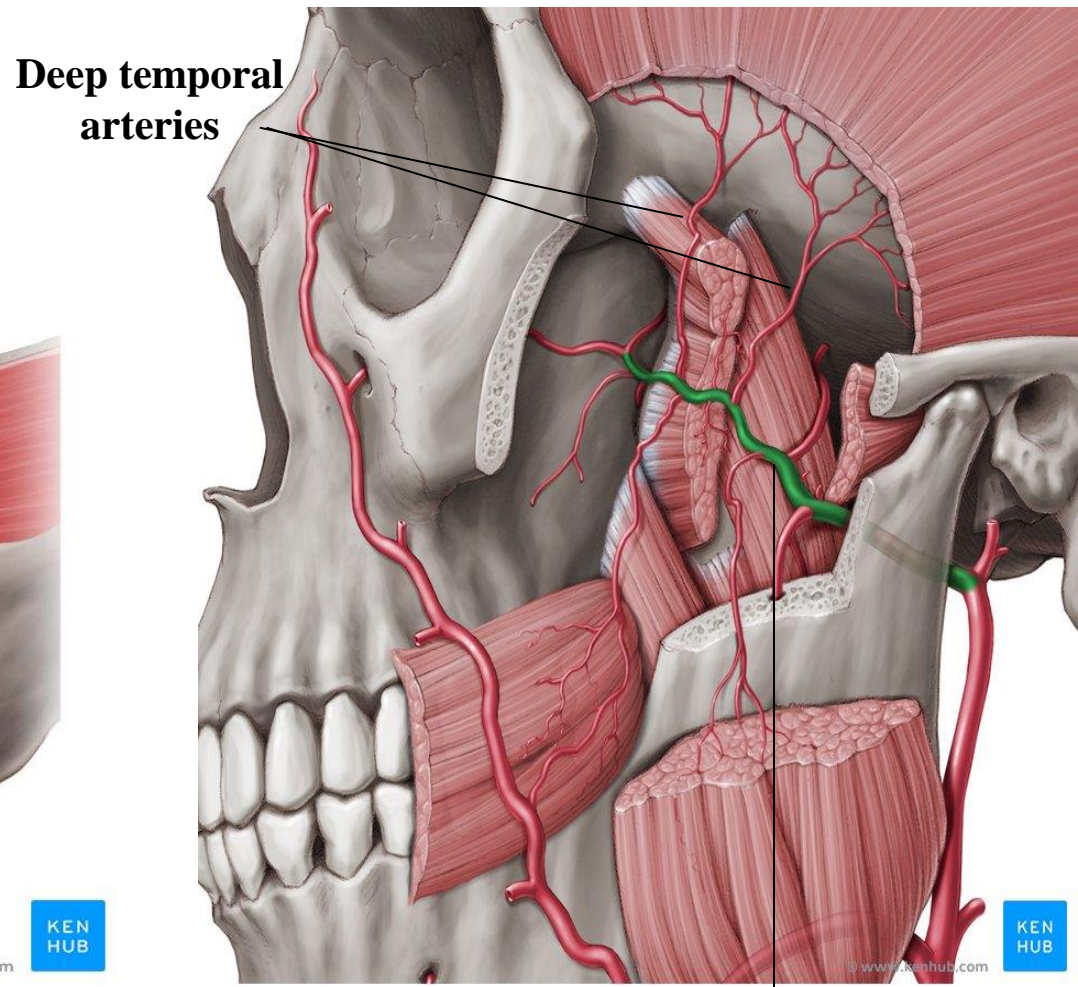


Superficial temporal vein

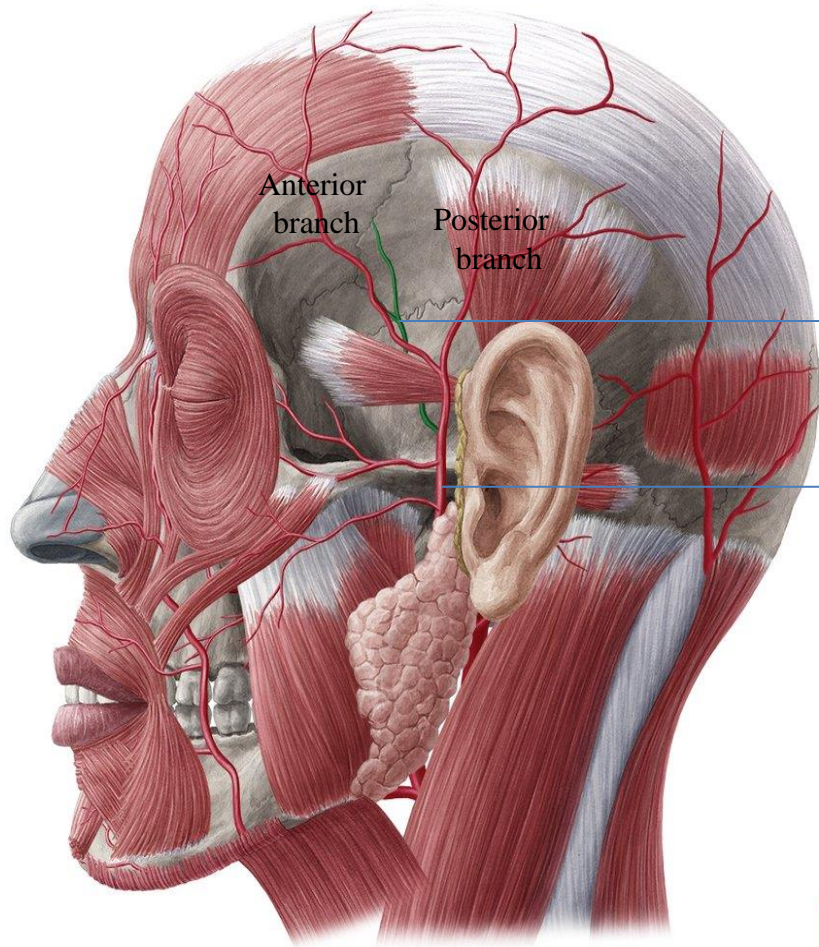




Mandibular nerve



Maxillary artery



Anterior
branch

Posterior
branch

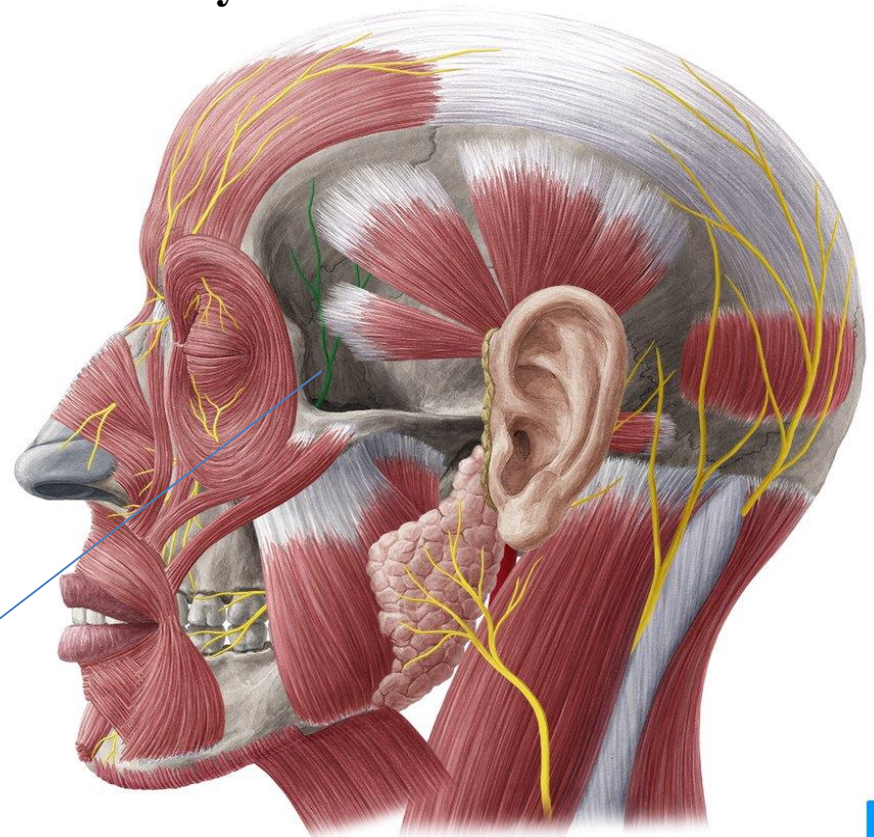
Middle temporal artery

**Superficial temporal
artery**

© www.kenhub.com

KEN
HUB

Zygomaticotemporal nerve



© www.kenhub.com

KEN
HUB

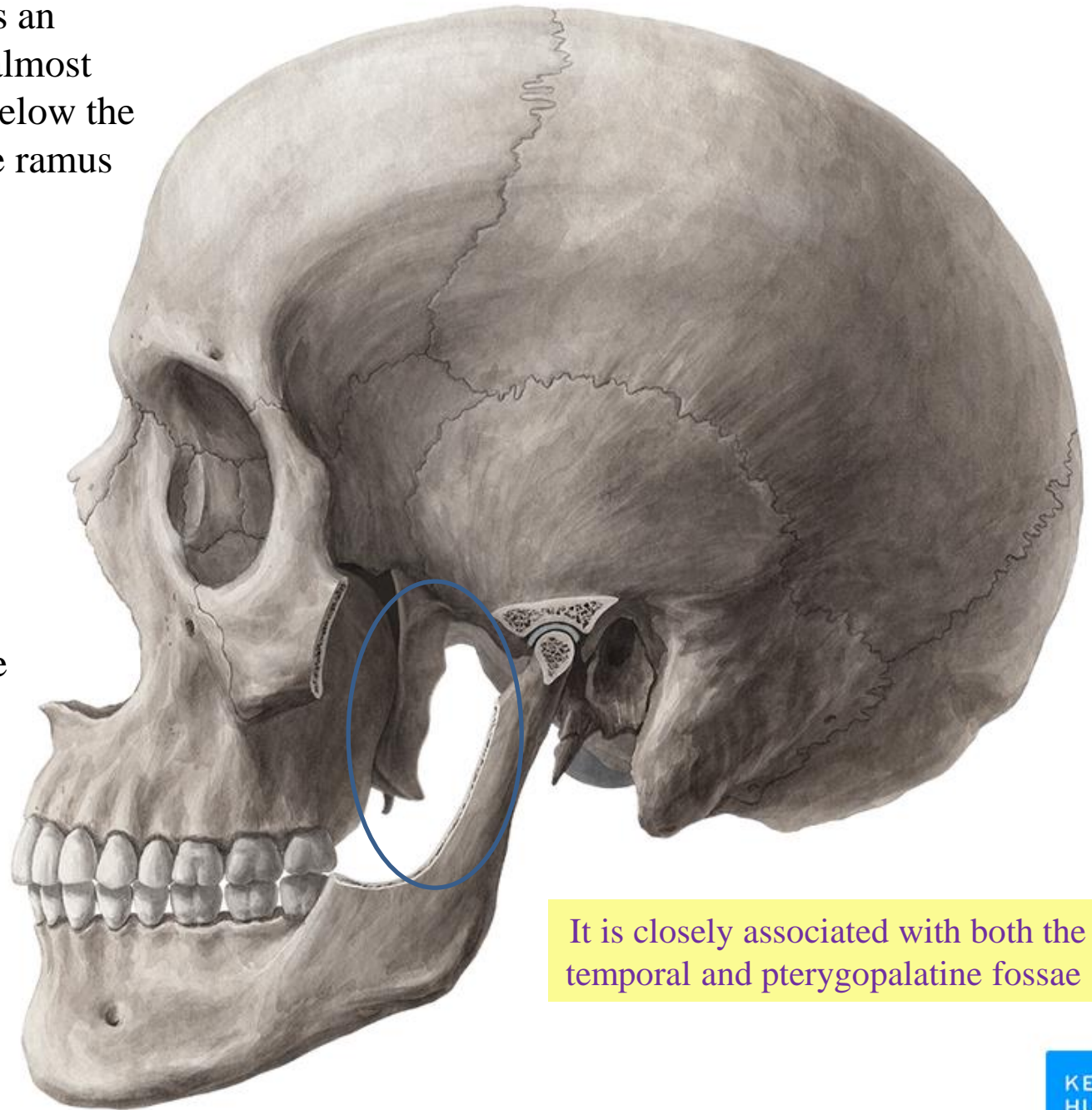
The **infratemporal fossa** is an irregularly shaped cavity (almost wedge in shape), situated below the zygomatic arch, deep to the ramus of the mandible

The infratemporal fossa acts as a pathway for neurovascular structures passing to and from the cranial cavity, pterygopalatine fossa and temporal fossa.

It also contains some of the muscles of mastication



The **medial** and **lateral pterygoids** are located within the fossa itself, whilst the masseter and temporalis muscles insert and originate into the borders of the fossa.



It is closely associated with both the temporal and pterygopalatine fossae

Infra temporal fossa

Anterior wall: back of the maxilla

Medial wall: lateral pterygoid plate

Roof: greater wing of sphenoid bone

Lateral wall: ramus of mandible

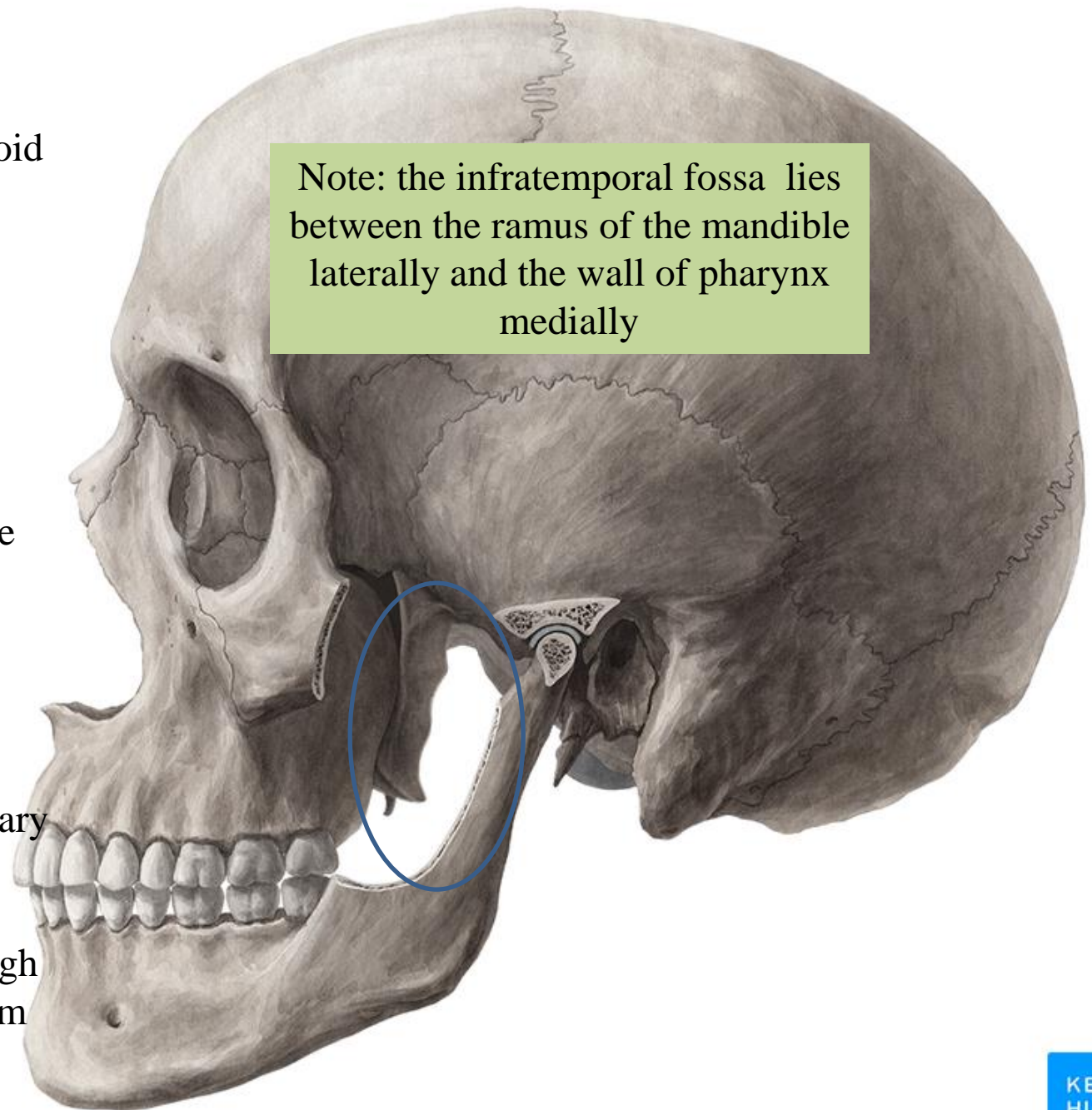
Communications

Temporal fossa: through the gap deep to the zygomatic arch

Orbit: through the inferior orbital fissure

Pterygo-palatine fossa: through the pterygo-maxillary fissure

Middle cranial fossa: through foramen ovale and spinosum

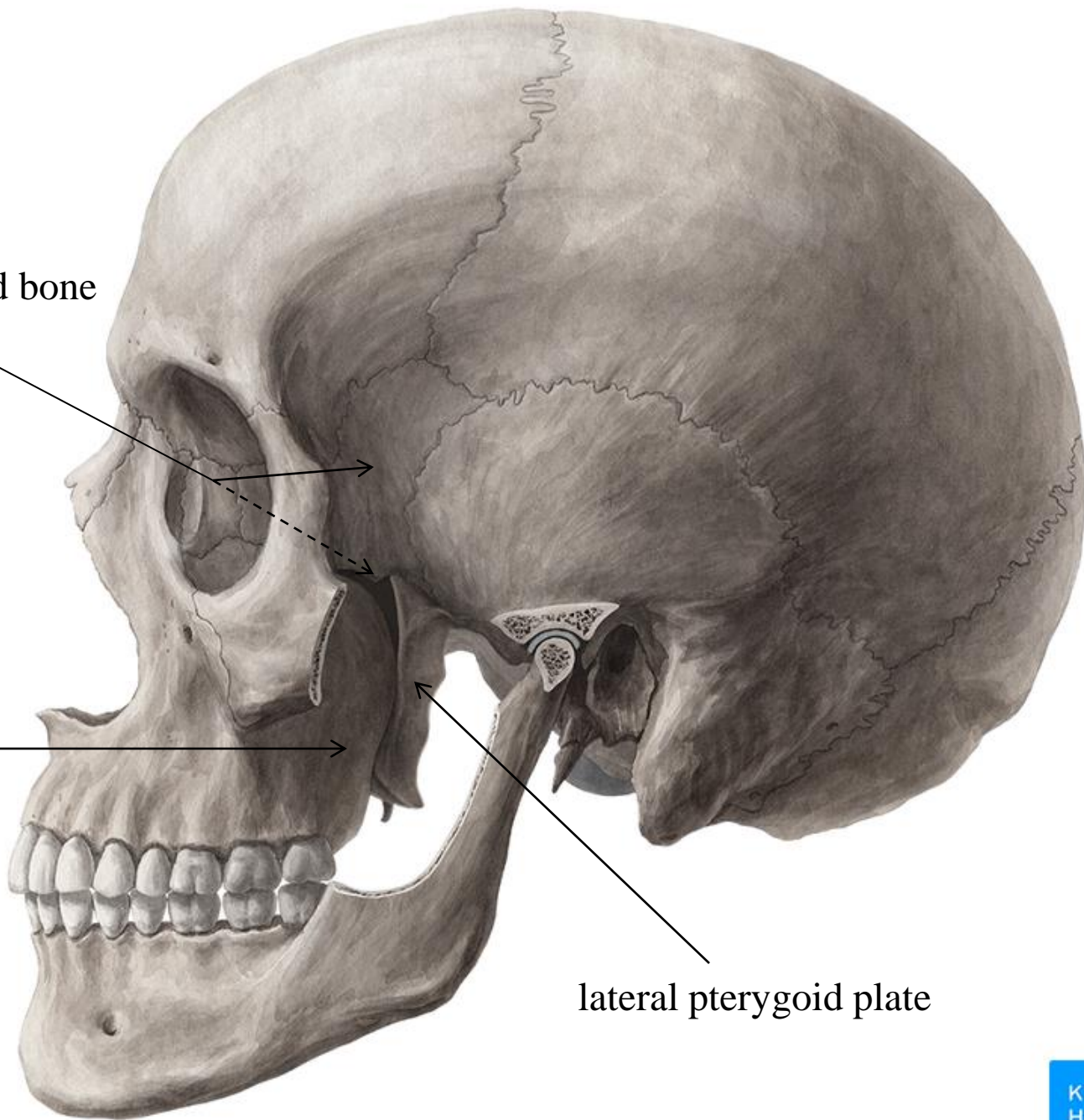


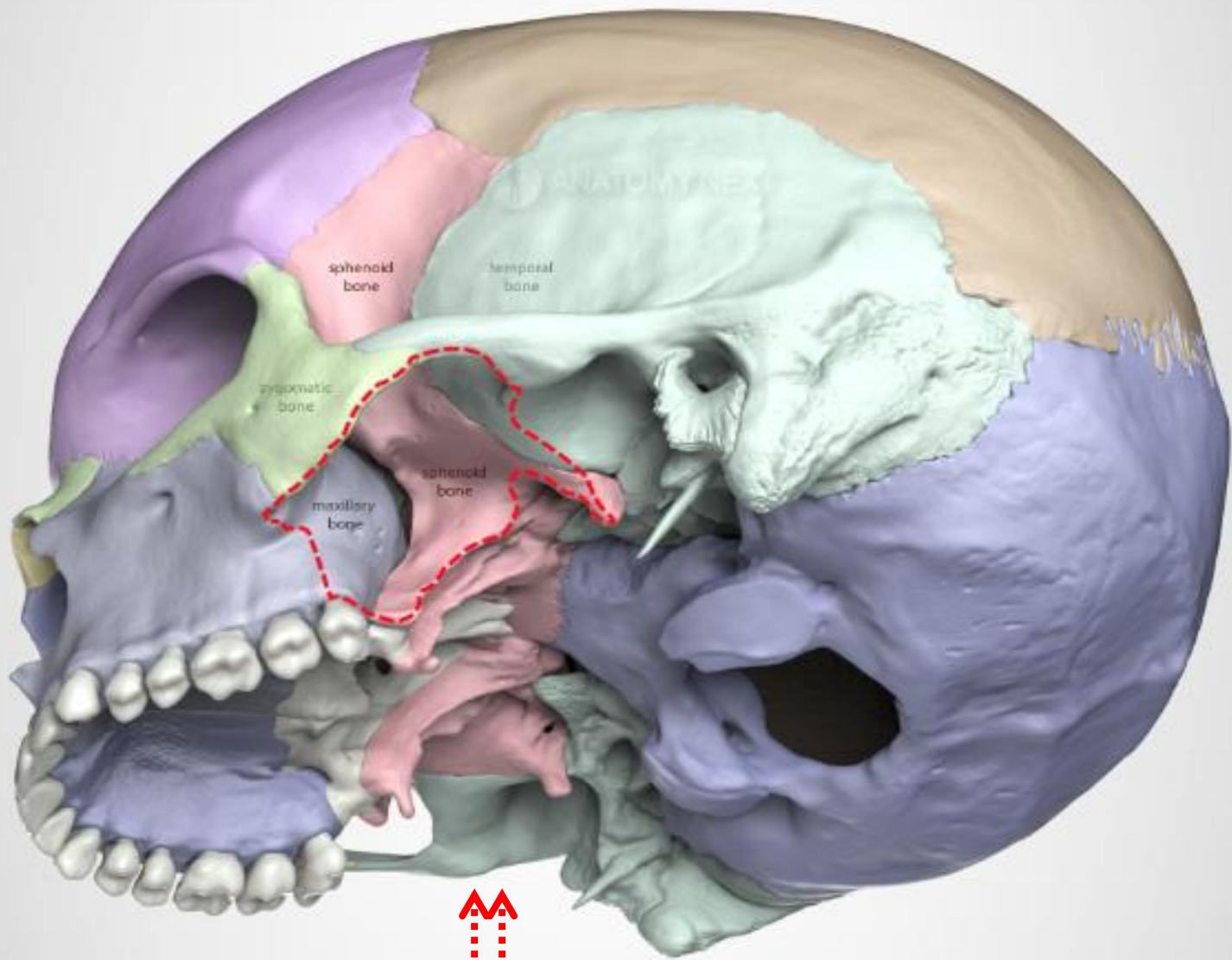
Note: the infratemporal fossa lies between the ramus of the mandible laterally and the wall of pharynx medially

Greater wing of sphenoid bone

Back of the maxilla

lateral pterygoid plate





Infratemporal fossa

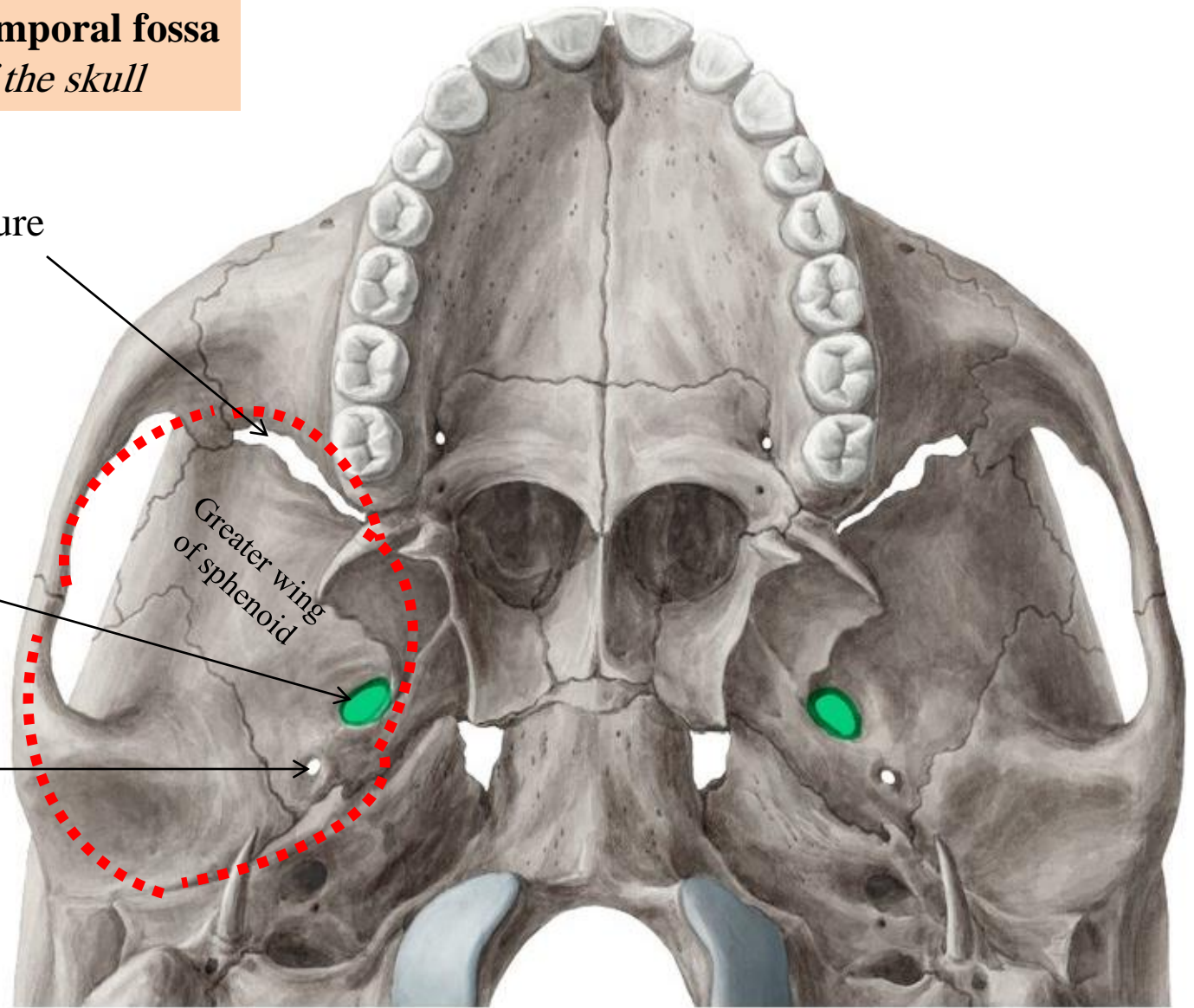
The roof of Infratemporal fossa

Inferior view of the skull

Inferior orbital fissure

Foramen ovale
(Mandibular nerve)

Foramen spinosum
(Middle meningeal artery)



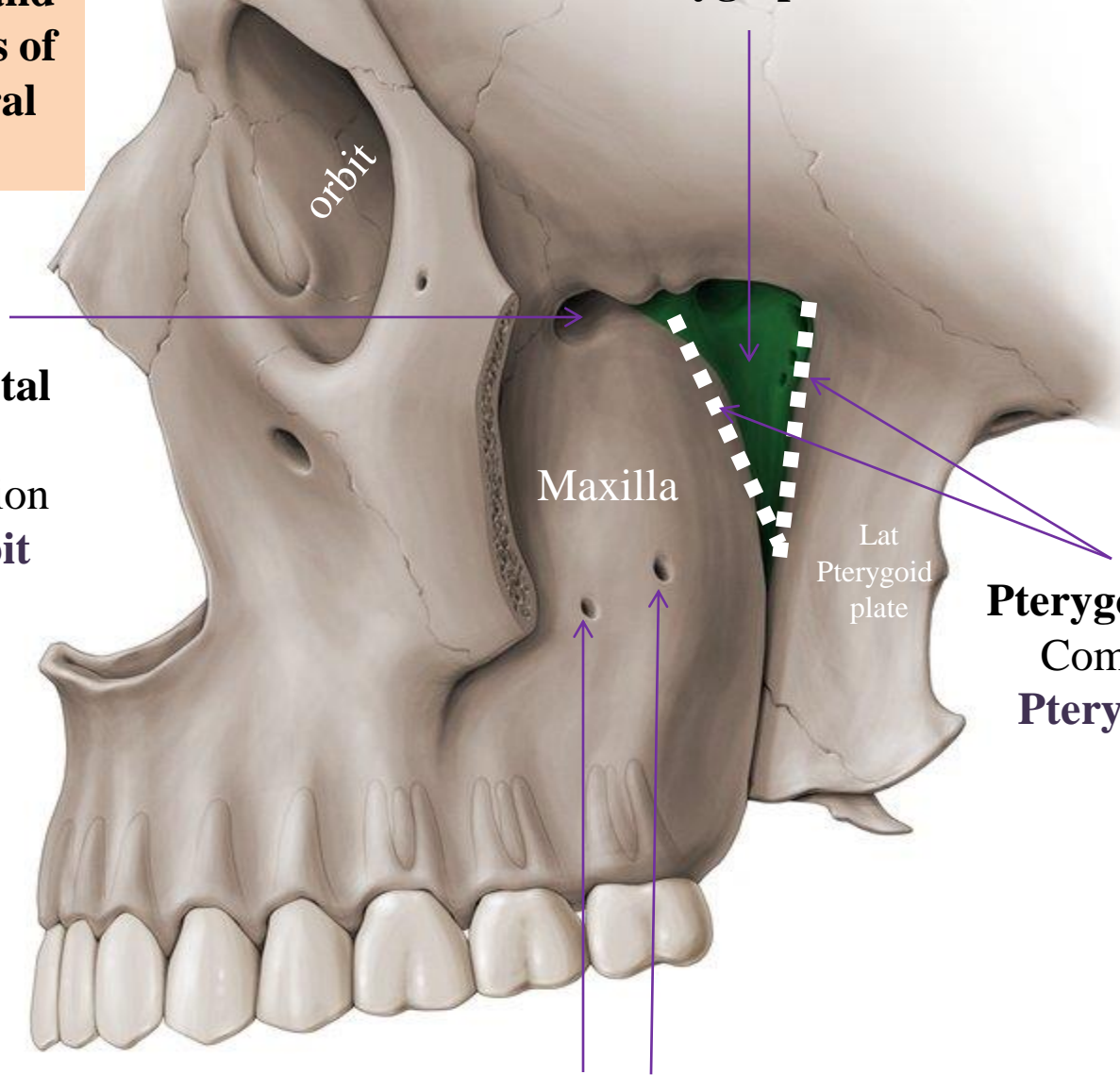
Note:

The foramen ovale and foramen spinosum open on its roof

The medial and anterior walls of Infratemporal fossa

Inferior orbital fissure
Communication with the **orbit**

Pterygo-palatine fossa



Maxilla

Lat Pterygoid plate

Pterygo-maxillary fissure
Communication with **Pterygo-palatine fossa**

Alveolar foramina (leading to alveolar canals)



Lateral wall is formed by the medial surface of the ramus of mandible
Which contains the **mandibular foramen**

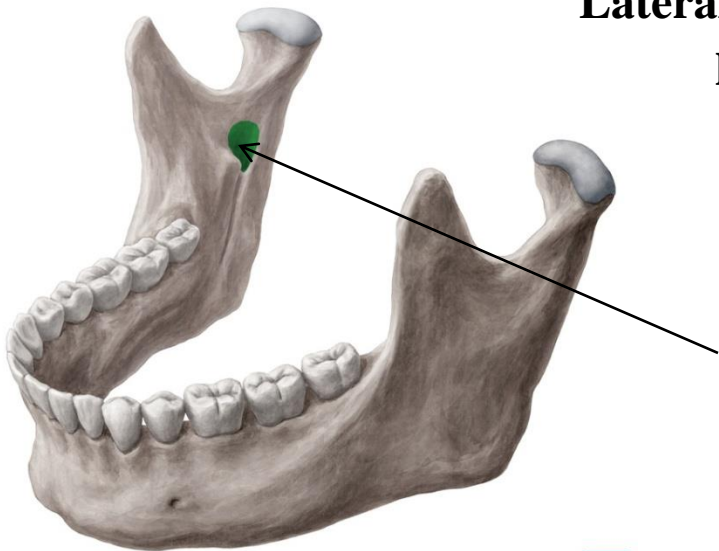
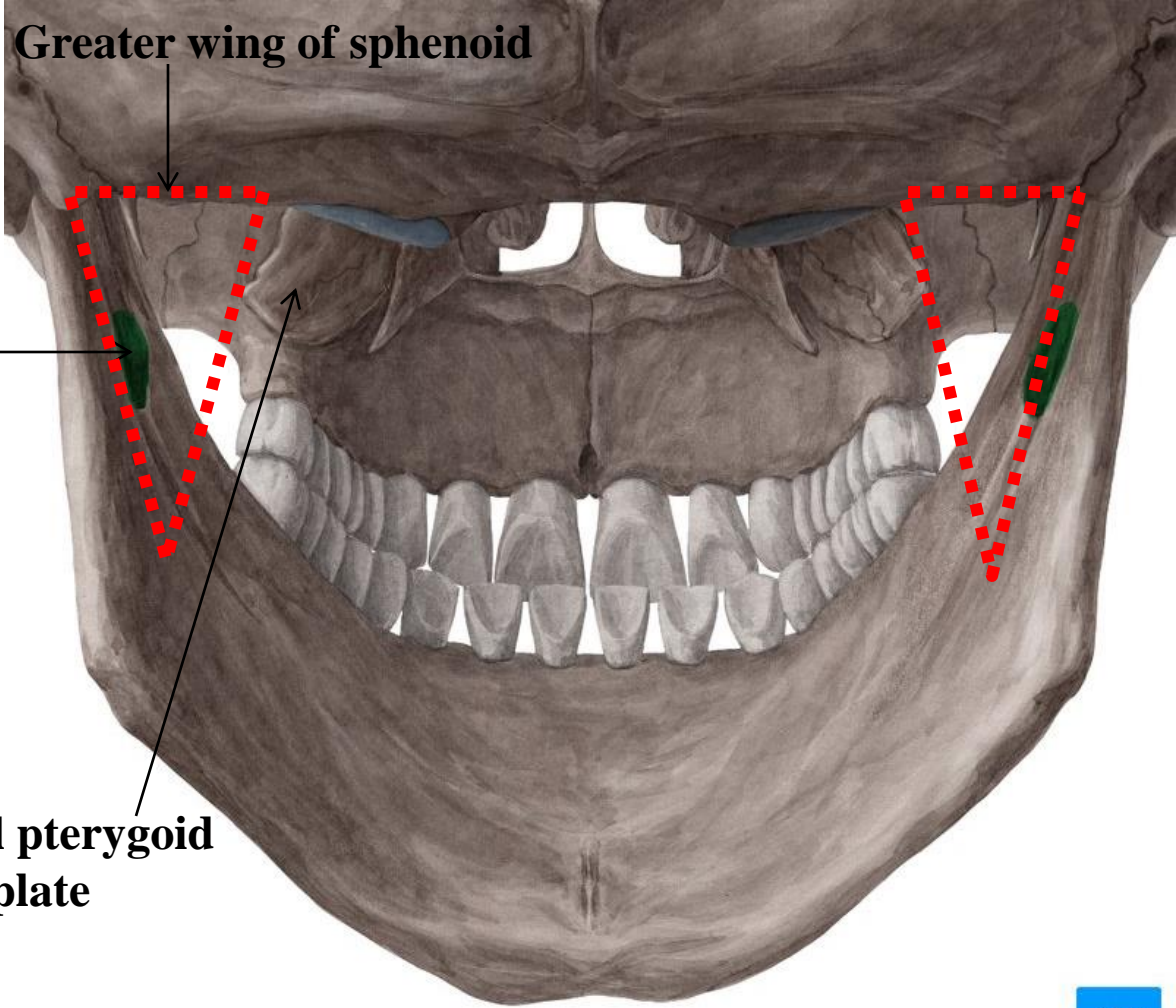
The lateral wall of Infratemporal fossa

The infratemporal fossa can be said to have a wedge shape

Lateral pterygoid plate

Mandibular foramen: an opening to the mandibular canal

Transmits inferior alveolar nerve (a branch from mandibular nerve) and blood vessels



Contents of infratemporal fossa

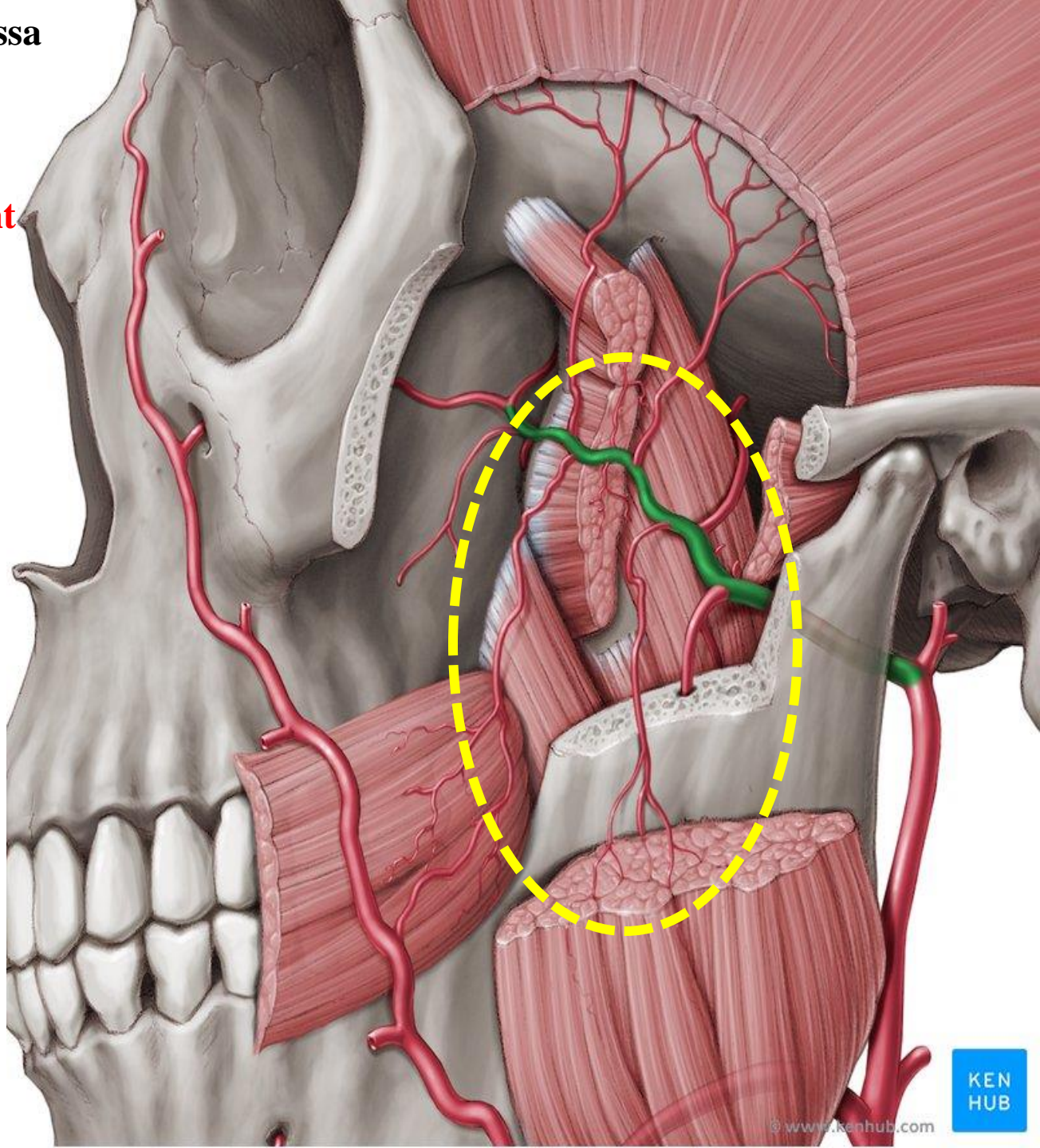
Lateral pterygoid muscle
Medial pterygoid muscle
Sphenomandibular ligament
Maxillary artery (and its branches):

☺ *Middle meningeal artery*
Deep temporal arteries
Buccal artery
Inferior alveolar artery
Pterygoid branches

Mandibular nerve (and its branches):

Auriculotemporal nerve
Buccal nerve
Lingual nerve
Inferior alveolar nerve

Chorda tympani
Pterygoid venous plexus
Maxillary vein
Middle meningeal vein
Otic ganglion



Temporalis

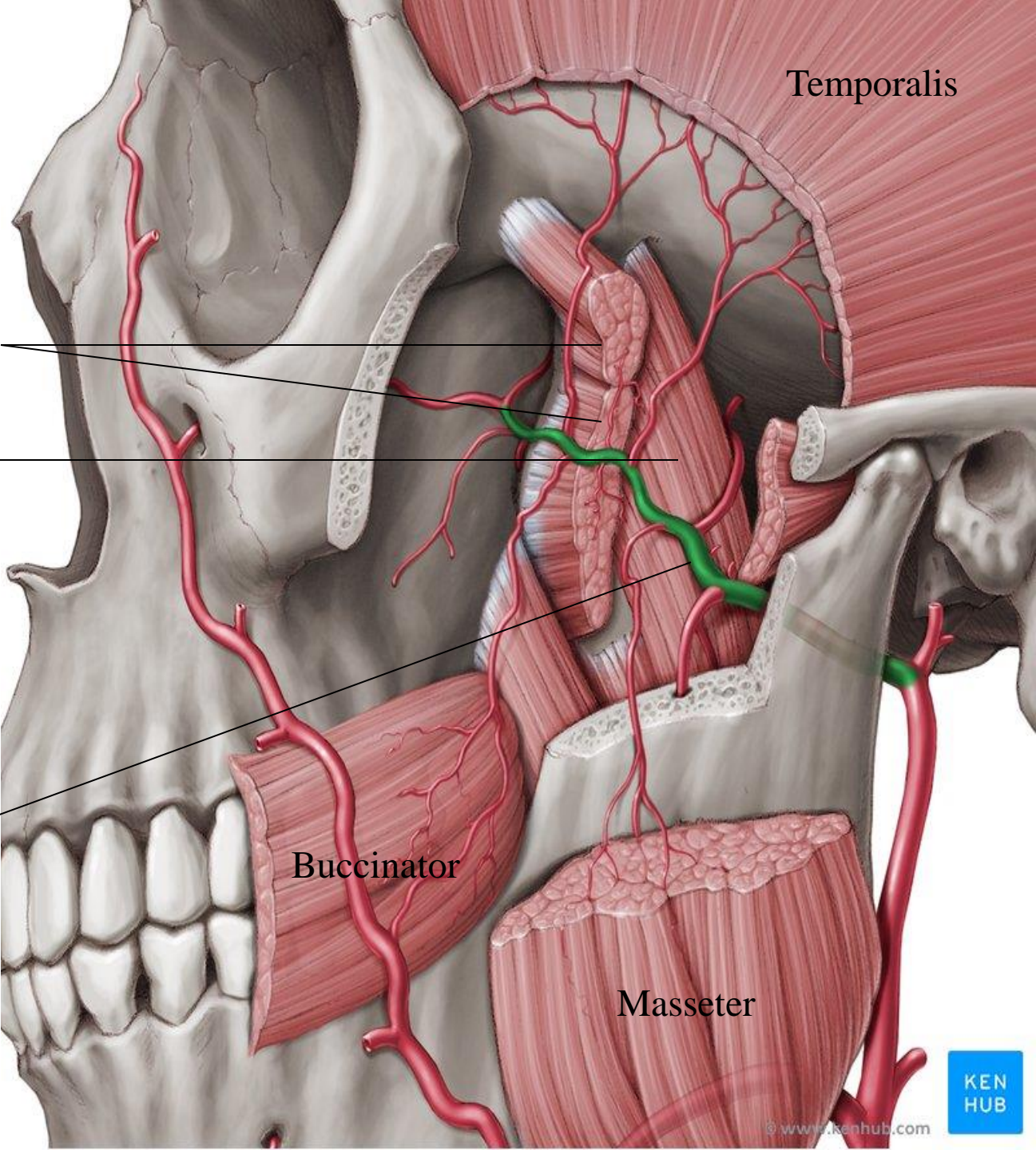
Lateral pterygoid muscle

Medial pterygoid muscle

Maxillary artery

Buccinator

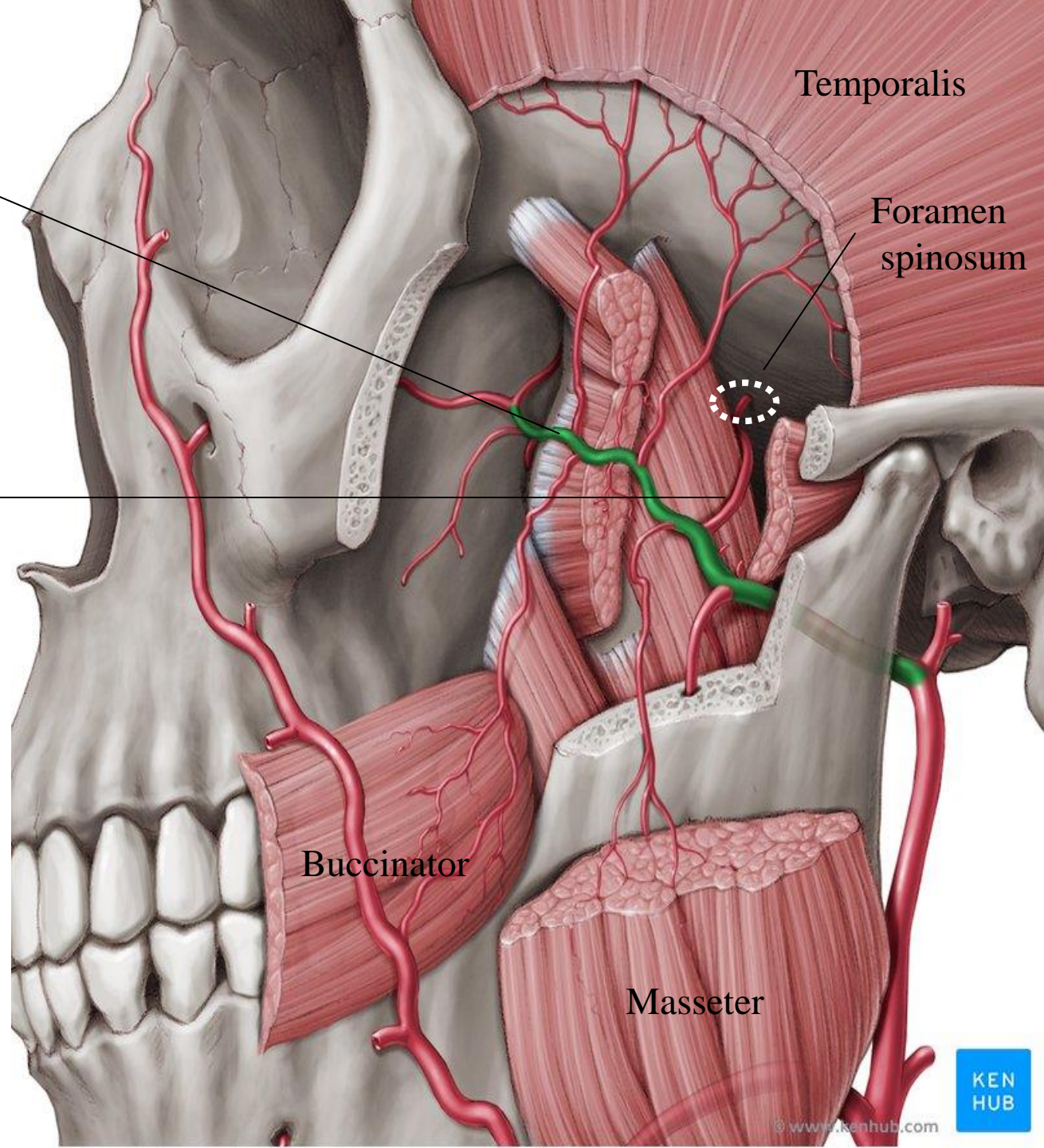
Masseter



Maxillary artery

the terminal branch of the external carotid artery. It travels through the infratemporal fossa.

Within the fossa, it gives rise to the **middle meningeal artery**, which passes through the foramen spinosum.

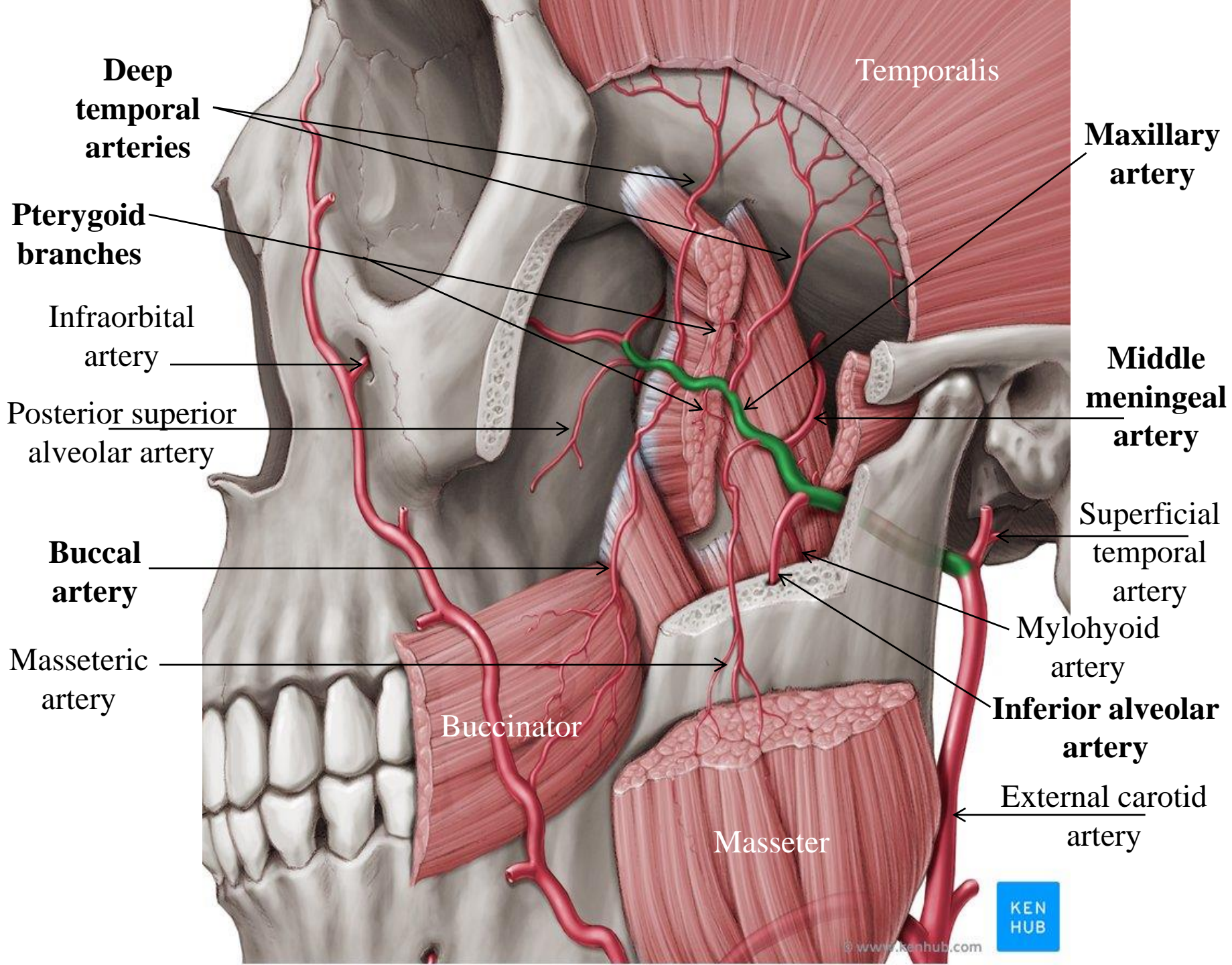


Temporalis

Foramen spinosum

Buccinator

Masseter



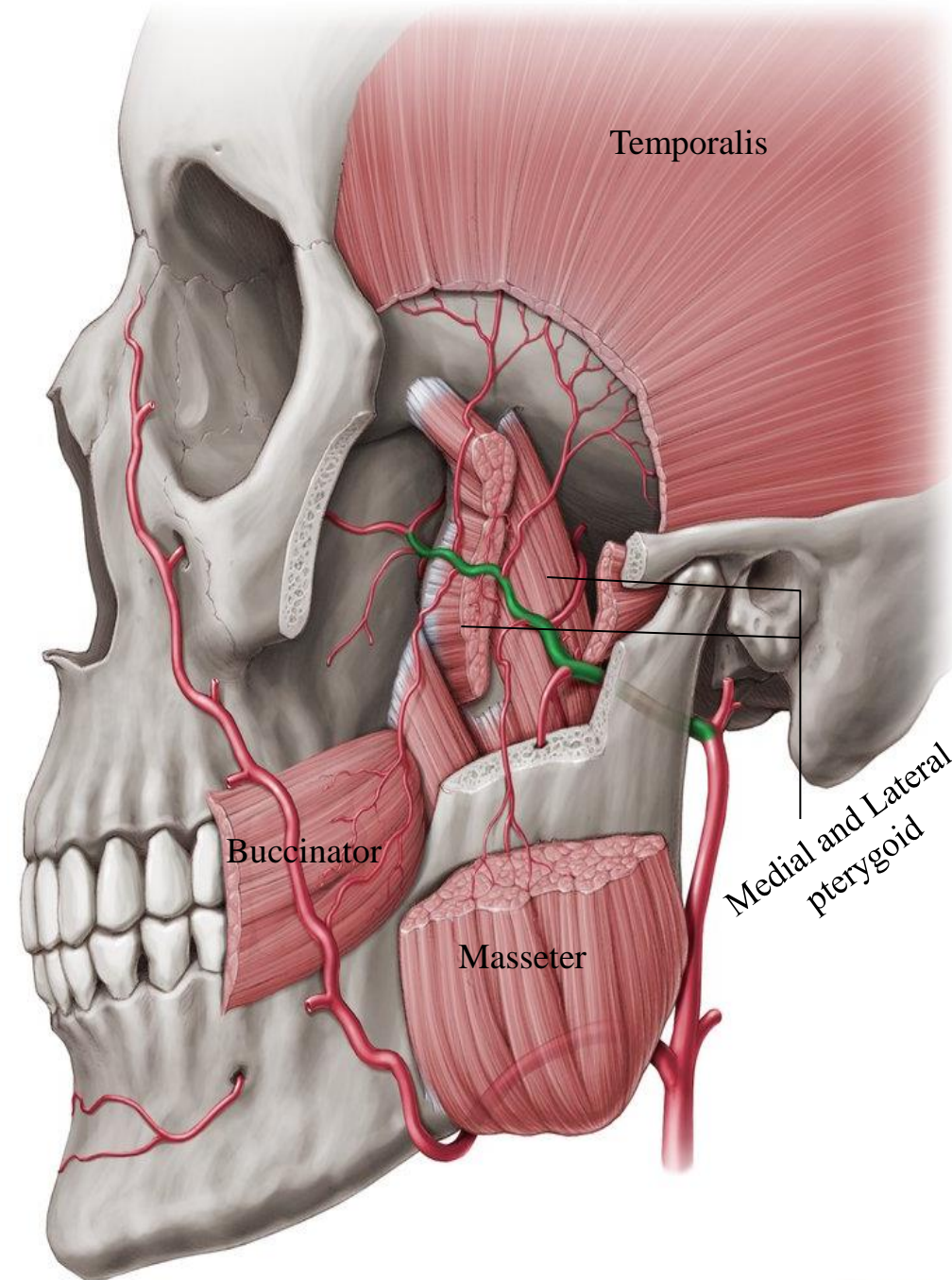
Dr. Heba Kalbouneh

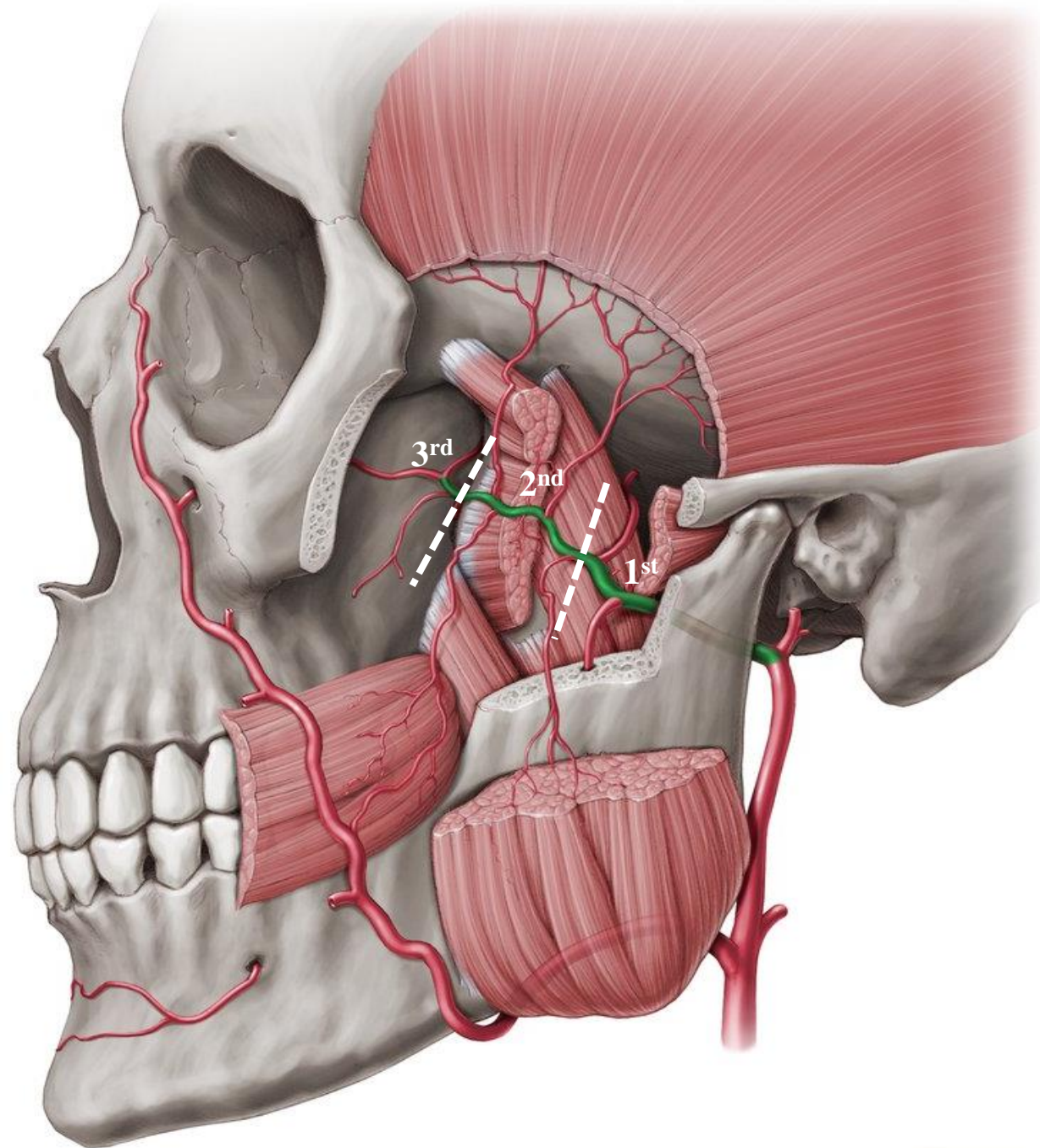


© www.kenhub.com

The maxillary artery

- ✓ The larger of the two terminal branches of the external carotid artery
- ✓ Originates in the substance of the parotid gland
- ✓ Passes forward between the neck of the mandible and the sphenomandibular ligament into the infratemporal fossa
- ✓ Ascends obliquely in the infratemporal fossa to enter the pterygopalatine fossa by passing through the pterygomaxillary fissure
- ✓ Runs either superficial or deep to the lower head of lateral pterygoid muscle
- ✓ It supplies the deep structures of the face, maxilla, mandible, all teeth, nasal cavity and cerebral dura mater



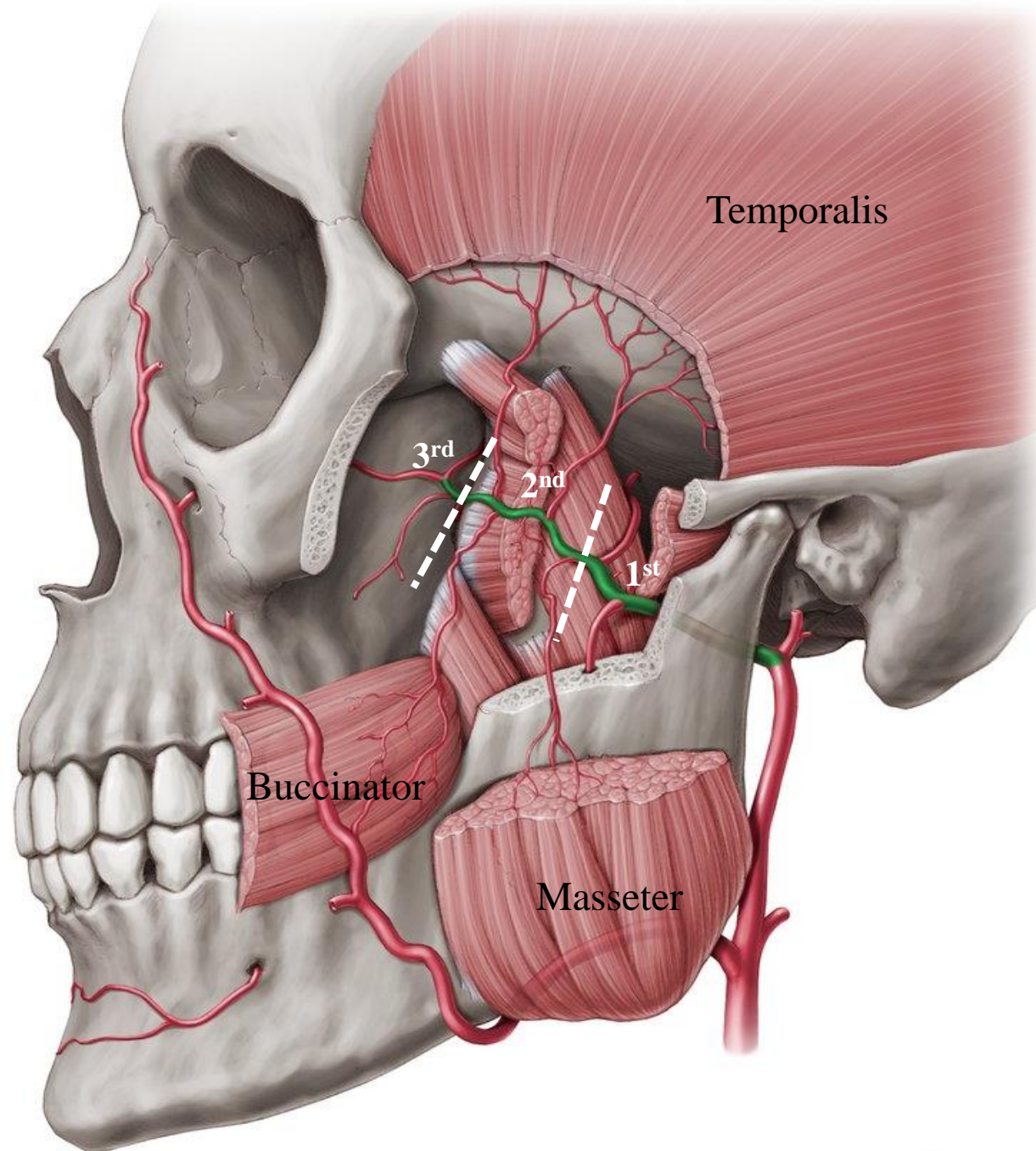


The main trunk of the maxillary artery is divided into three parts, which are named according to related structures along the artery's course

Mandibular part (1st part)

Pterygoid part (2nd part)

Pterygopalatine part (3rd part)



Mandibular part (1st part)

Middle meningeal artery

Inferior alveolar artery

Deep auricular artery

Anterior tympanic artery

Accessory meningeal artery

Pterygoid part (2nd part)

(its branches course with branches of mandibular nerve)

Deep temporal arteries

Masseteric artery

Buccal artery

Pterygoid branches

Pterygopalatine part (3rd part)

(its branches course with branches of maxillary nerve and pterygopalatine ganglion)

Sphenopalatine artery

Descending palatine artery

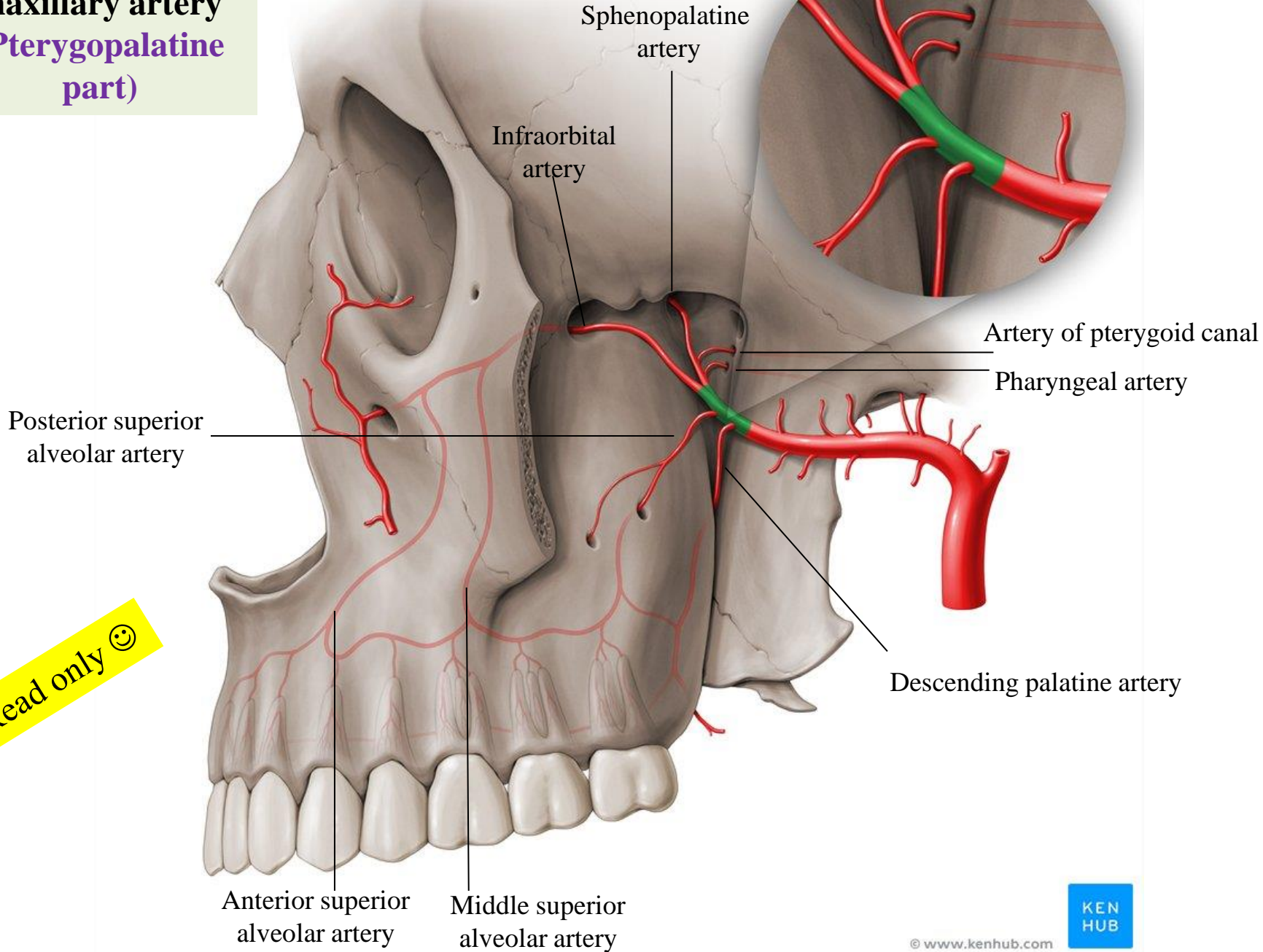
Infraorbital artery (gives off Middle and Anterior superior alveolar arteries)

Posterior superior alveolar artery

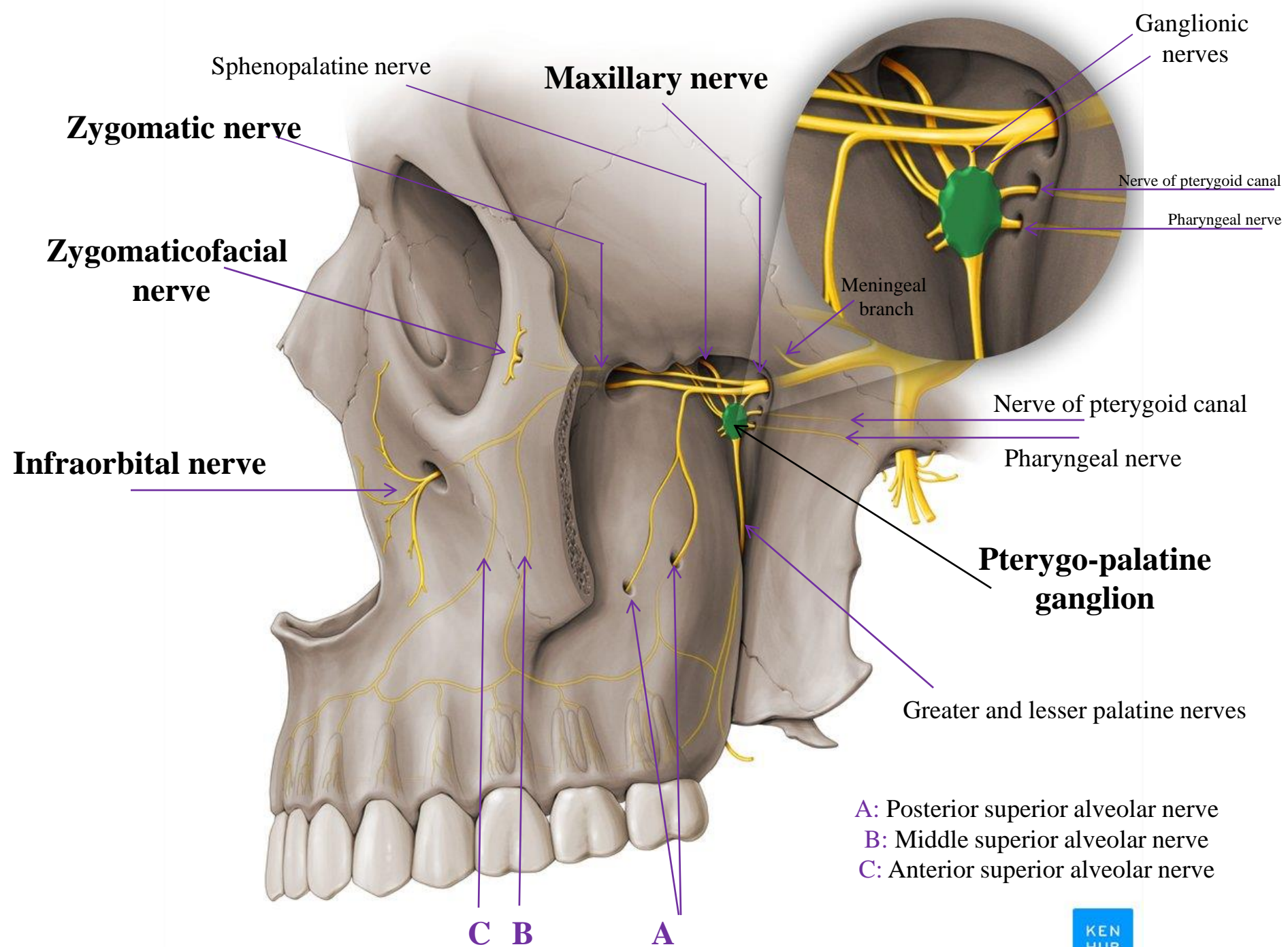
Pharyngeal artery

Artery of the pterygoid canal

Third part of maxillary artery (Pterygopalatine part)



Read only 😊



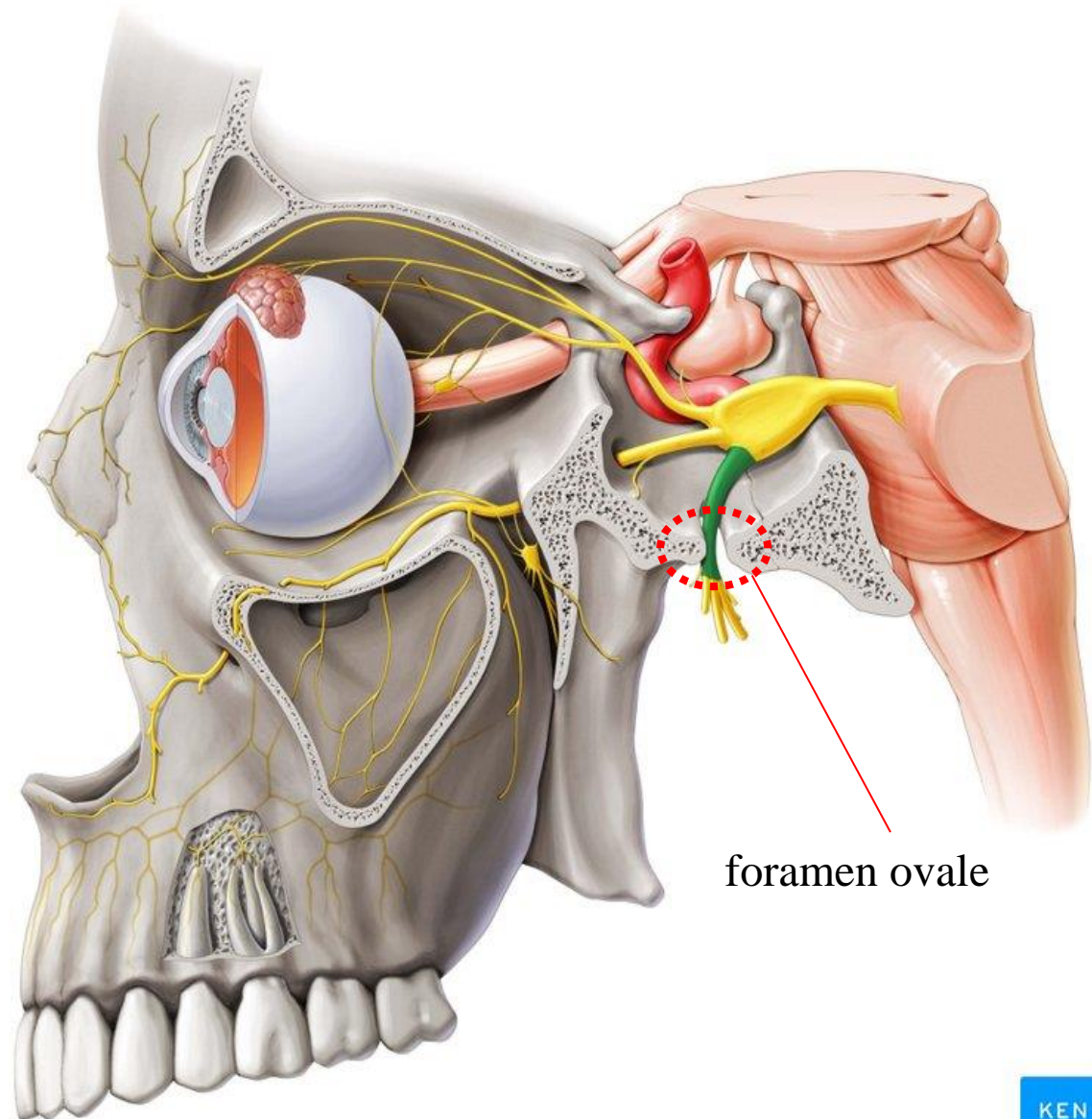
Mandibular Nerve (V3)

The mandibular nerve is both motor and sensory

The sensory root leaves the trigeminal ganglion and passes out of the skull through the foramen ovale to enter the infratemporal fossa.

The motor root of the trigeminal nerve also leaves the skull through the foramen ovale and joins the sensory root to form the trunk of the mandibular nerve

Then divides into a small anterior and a large posterior division



foramen ovale

Branches From the Main Trunk of the Mandibular Nerve:

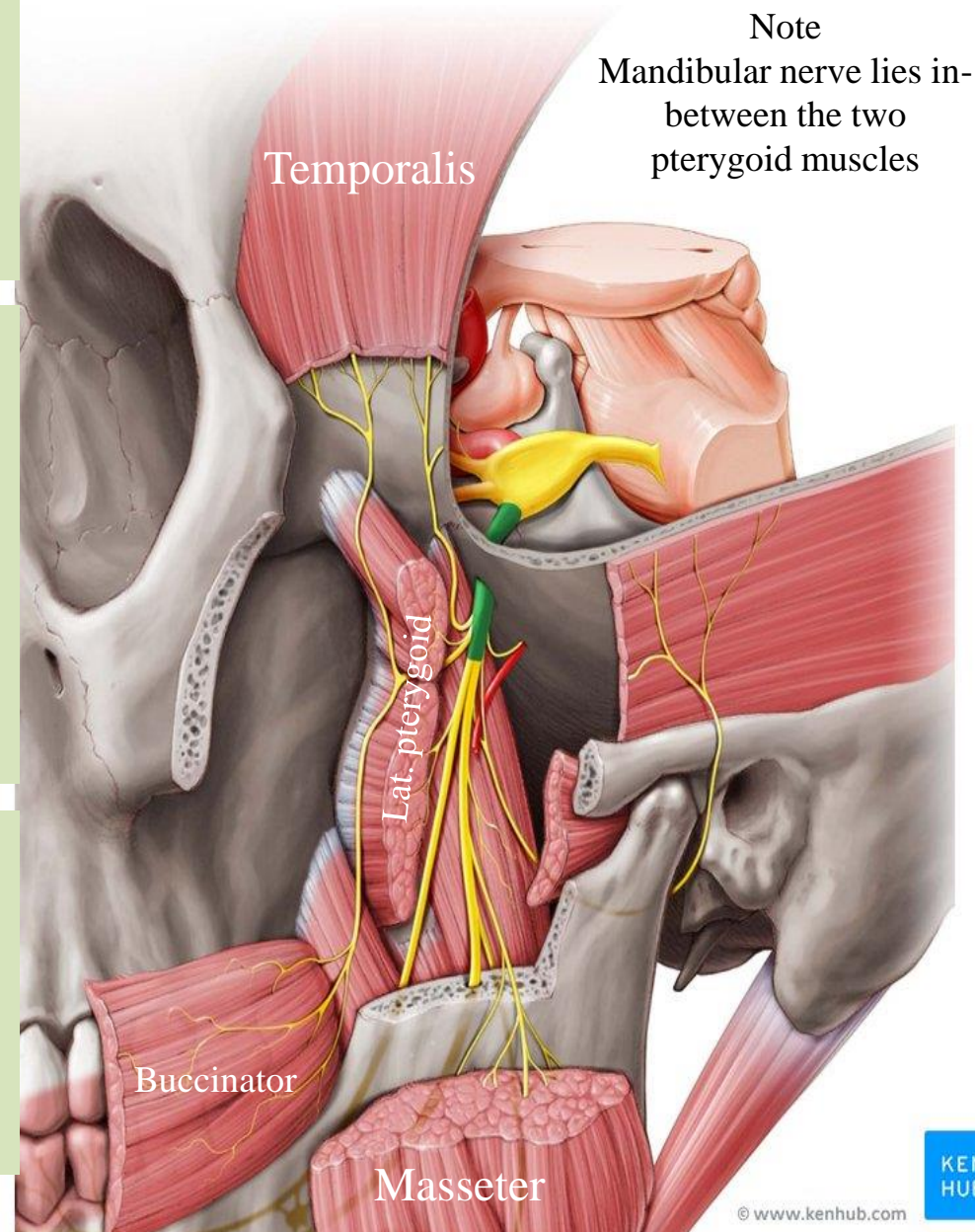
- 1- Meningeal branch
- 2- Nerve to the medial pterygoid muscle

Branches From the Anterior Division of the Mandibular Nerve

- 1- Masseteric nerve (to masseter muscle)
- 2- Deep temporal nerves (to temporalis muscle)
- 3- Nerve to the lateral pterygoid muscle
- 4- Buccal nerve

Branches From the Posterior Division of the Mandibular Nerve

- 1- Auriculotemporal nerve
- 2- Lingual nerve
- 3- Inferior alveolar nerve



Foramen spinosum

Foramen ovale

Meningeal branch

Nerve to the medial pterygoid

Tensor tympani
Tensor veli palatini

Posterior Division

Anterior Division

Auriculotemporal nerve

Lingual nerve

Inferior alveolar nerve

Masseteric nerve

Deep temporal nerves

Nerve to the lateral pterygoid

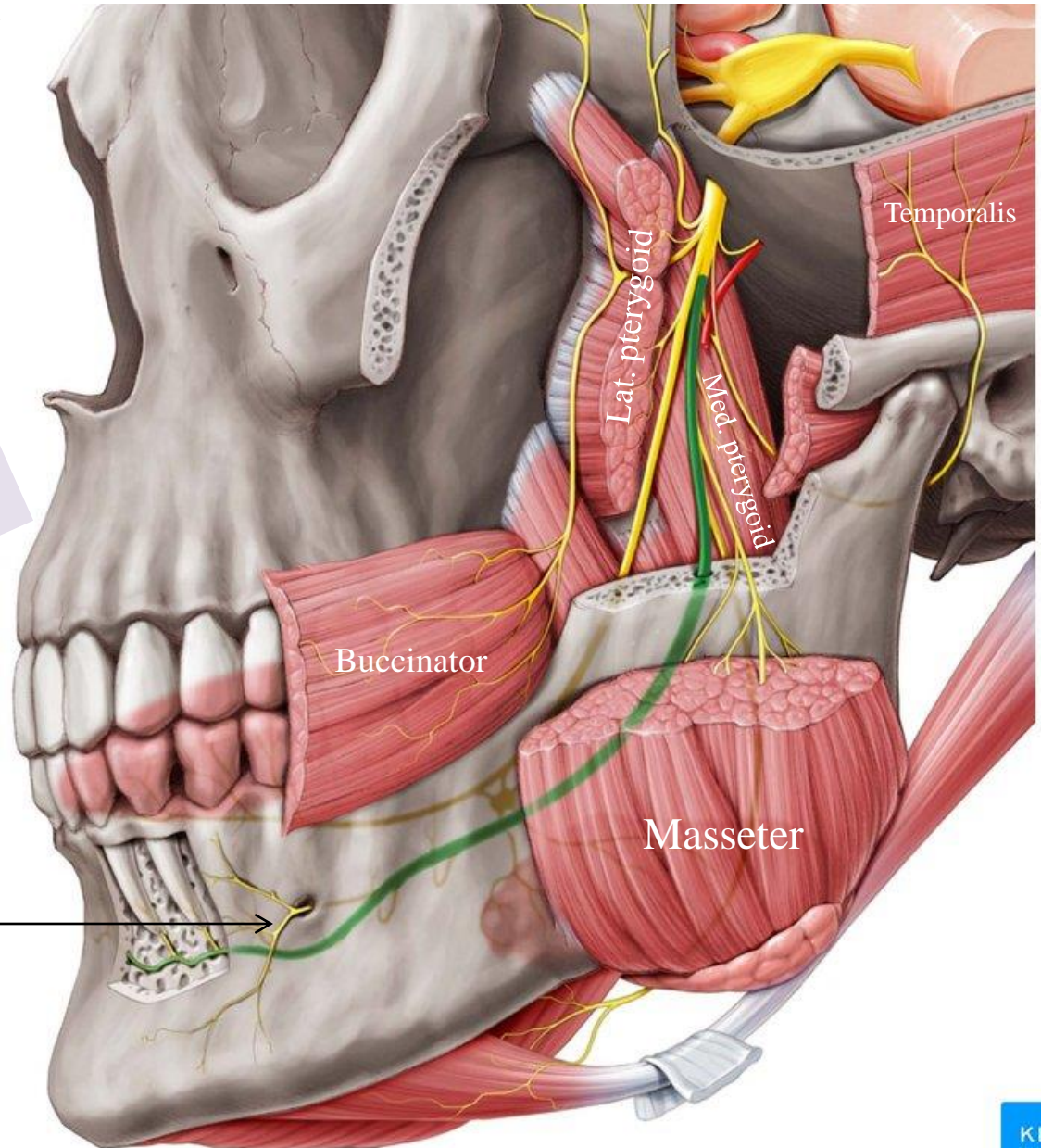
Buccal nerve

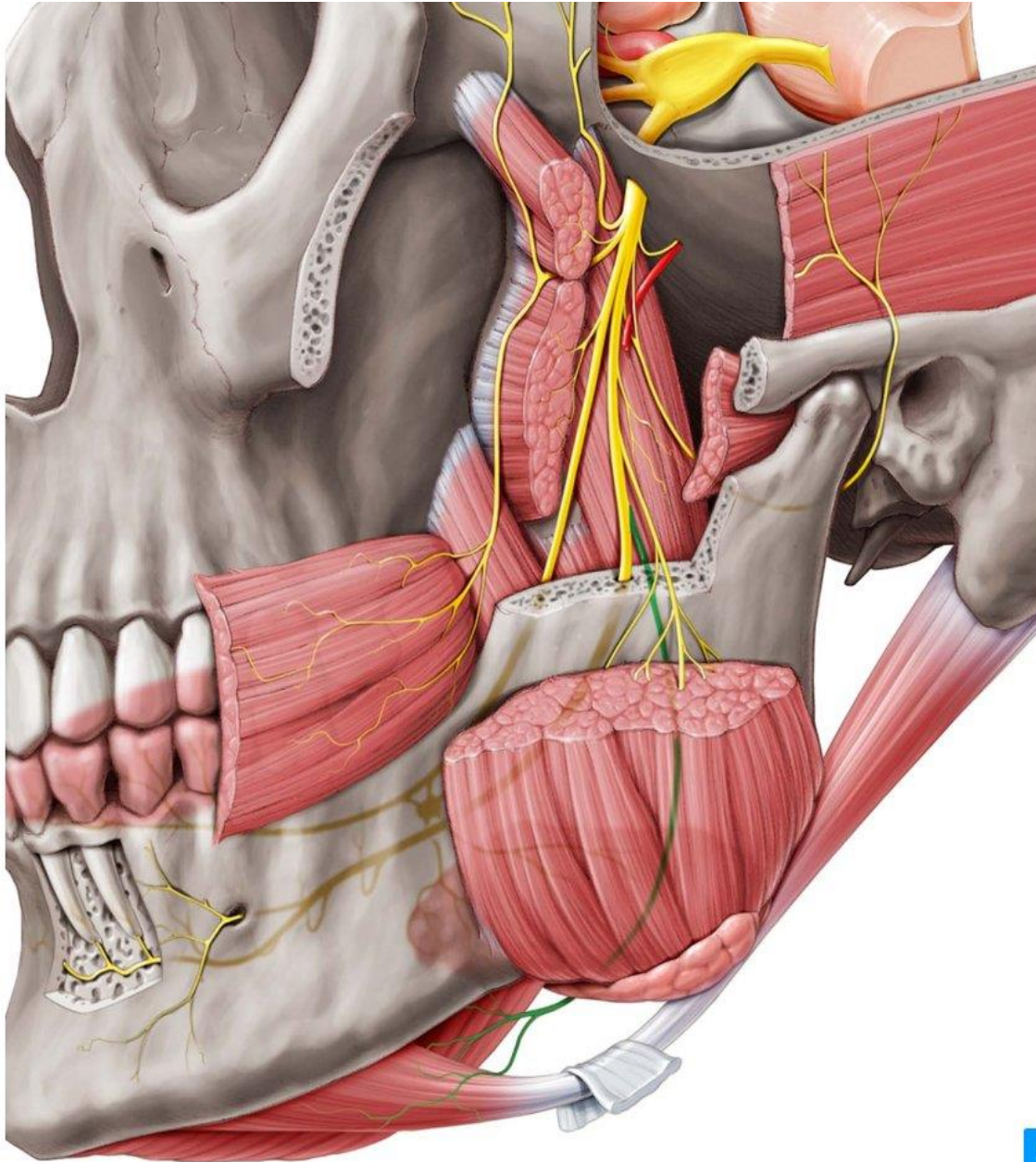
The **inferior alveolar nerve** (**inferior dental nerve**) is a branch of the mandibular nerve of the mandibular nerve

It supplies sensation to the lower teeth, lower lip and chin

Before entering the canal, it gives off **nerve to mylohyoid**, which supplies the mylohyoid muscle and the anterior belly of the digastric muscle

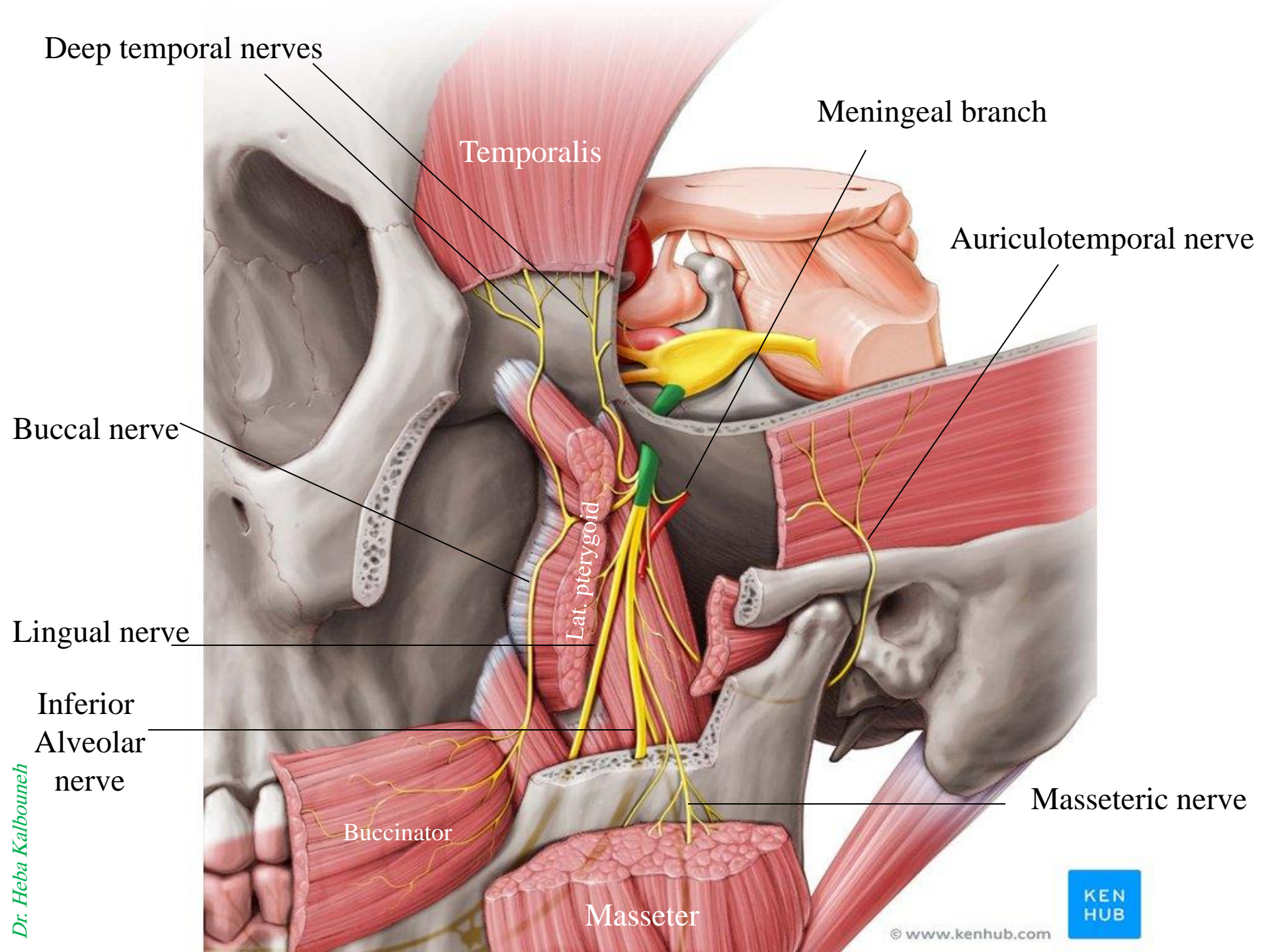
Mental nerve is a branch of inferior alveolar nerve to supply the skin and mucous membrane of the lower lip and chin
(*Passes through mental foramen*)





Note

As the inferior alveolar nerve enters the mandibular foramen, it gives off nerve to *mylohyoid* which runs in the mylohyoid groove (along with mylohyoid blood vessels), and supplies the mylohyoid muscle and the anterior belly of the digastric muscle



Deep temporal nerves

Temporalis

Meningeal branch

Auriculotemporal nerve

Buccal nerve

Lat. pterygoid

Lingual nerve

Inferior Alveolar nerve

Masseteric nerve

Buccinator

Masseter



Nerve to medial pterygoid supplies:

- 1- The medial pterygoid muscle
- 2- The tensor veli palatini muscle
- 3- The tensor tympani muscle

Lingual nerve

- ✓ It supplies the mucous membrane of the anterior two thirds of the tongue and the floor of the mouth (**general sensations**)
 - ✓ It is joined by the chorda tympani nerve
- ✓ It gives off preganglionic parasympathetic secretomotor fibers to the submandibular ganglion, (*the chorda tympani !!*)
- ✓ It carries taste sensations from the anterior two thirds of the tongue (*the chorda tympani !!*)

Buccal nerve is the only sensory branch of the anterior division of mandibular nerve.

Buccal nerve of mandibular is SENSORY and does not supply the buccinator muscle (which is supplied by buccal nerve of facial MOTOR)

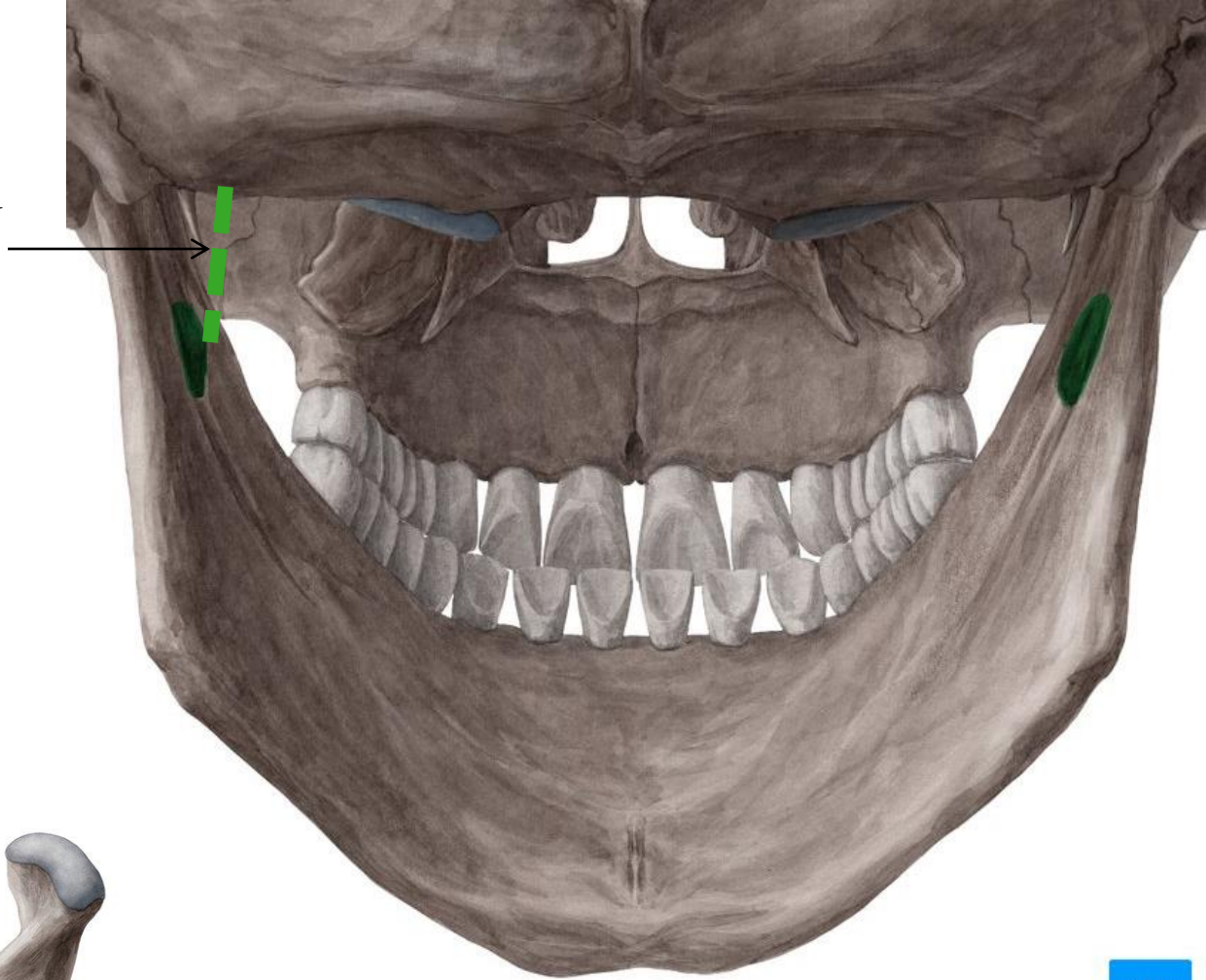
Buccal nerve supplies the skin and the mucous membrane of the cheek

Auriculotemporal nerve conveys postganglionic parasympathetic secretomotor fibers from the otic ganglion to the parotid salivary gland.

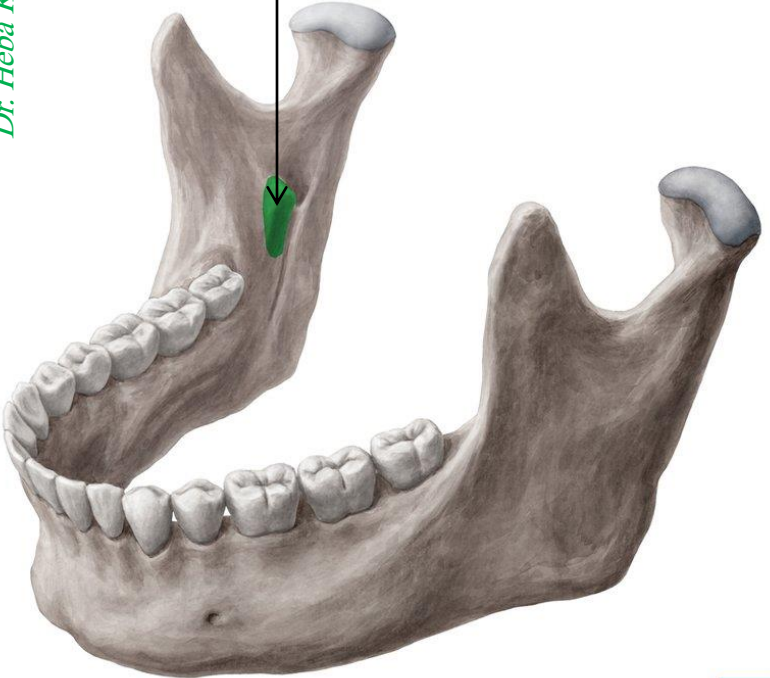
Remember: Auriculotemporal nerve brings sensations from the skin of the auricle, the external auditory meatus, outer surface of tympanic membrane, the temporomandibular joint, parotid gland and the scalp

Sphenomandibular ligament is an extra-capsular ligament of TMJ

It runs between the spine of sphenoid and the lingula of the mandible

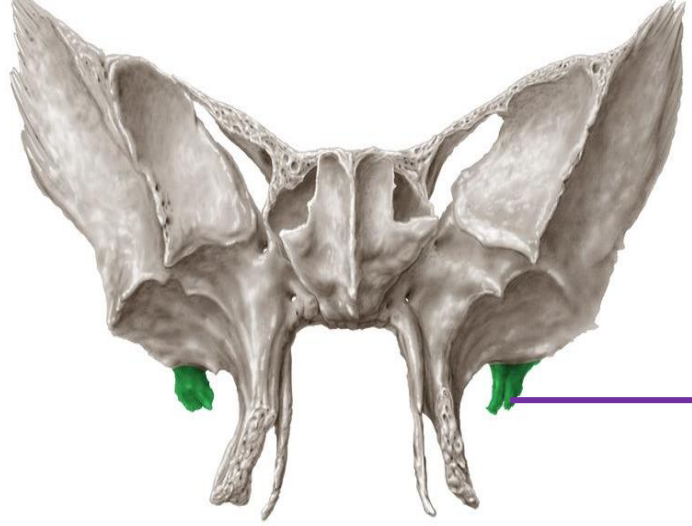


Lingula

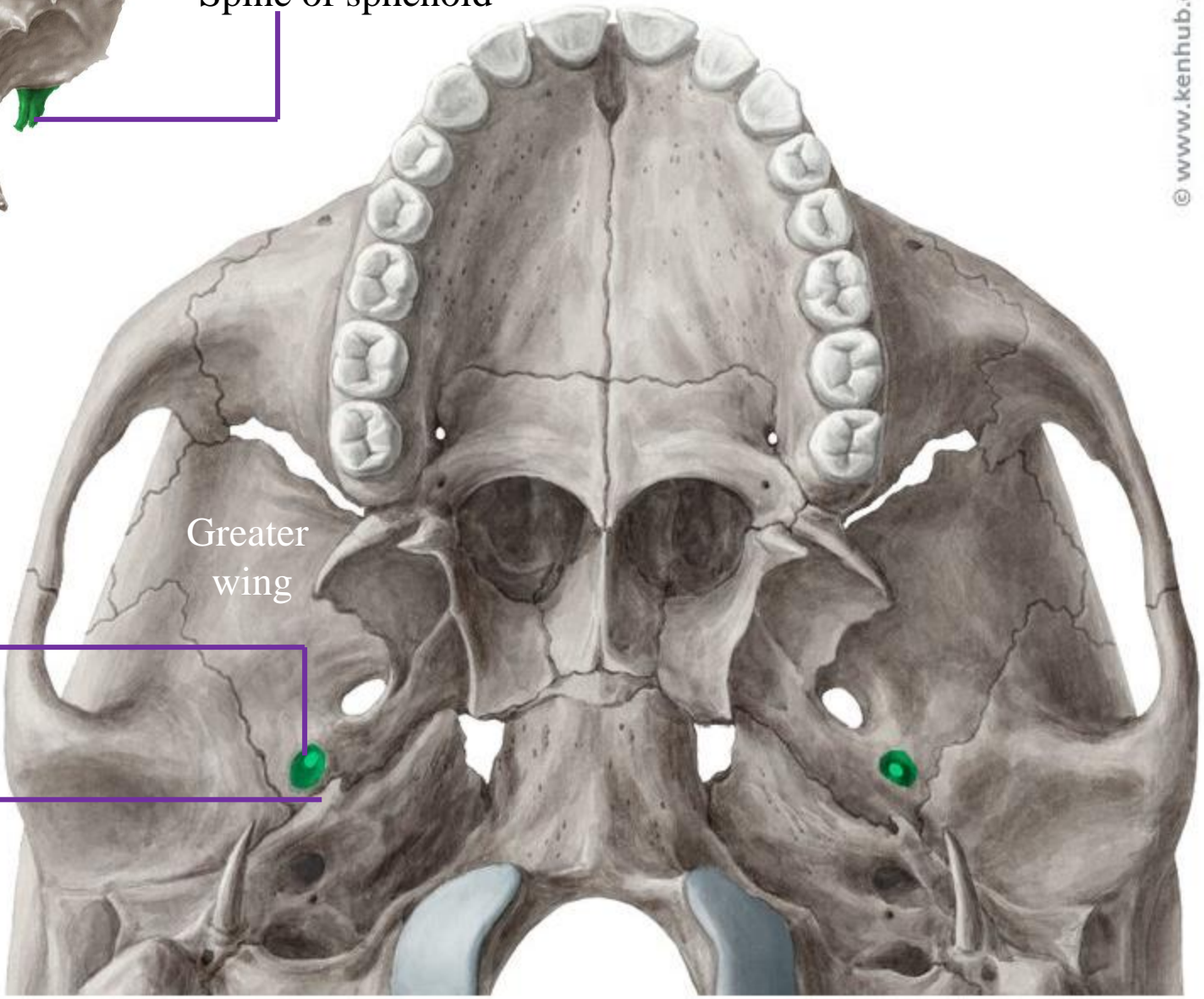


Dr. Heba Kalbouneh

Dr. Heba Kalbouneh



Spine of sphenoid



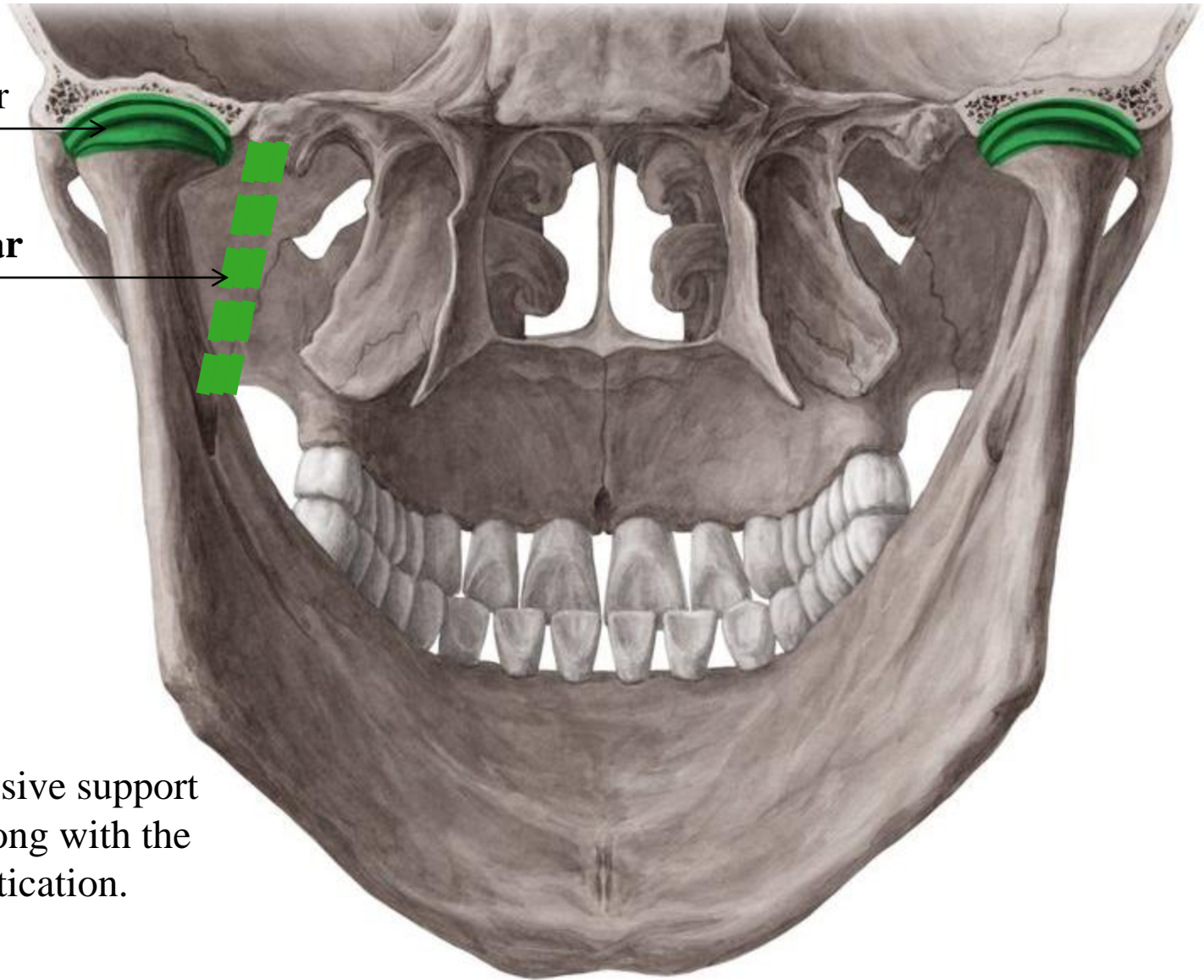
Greater wing

Foramen spinosum

Spine of sphenoid

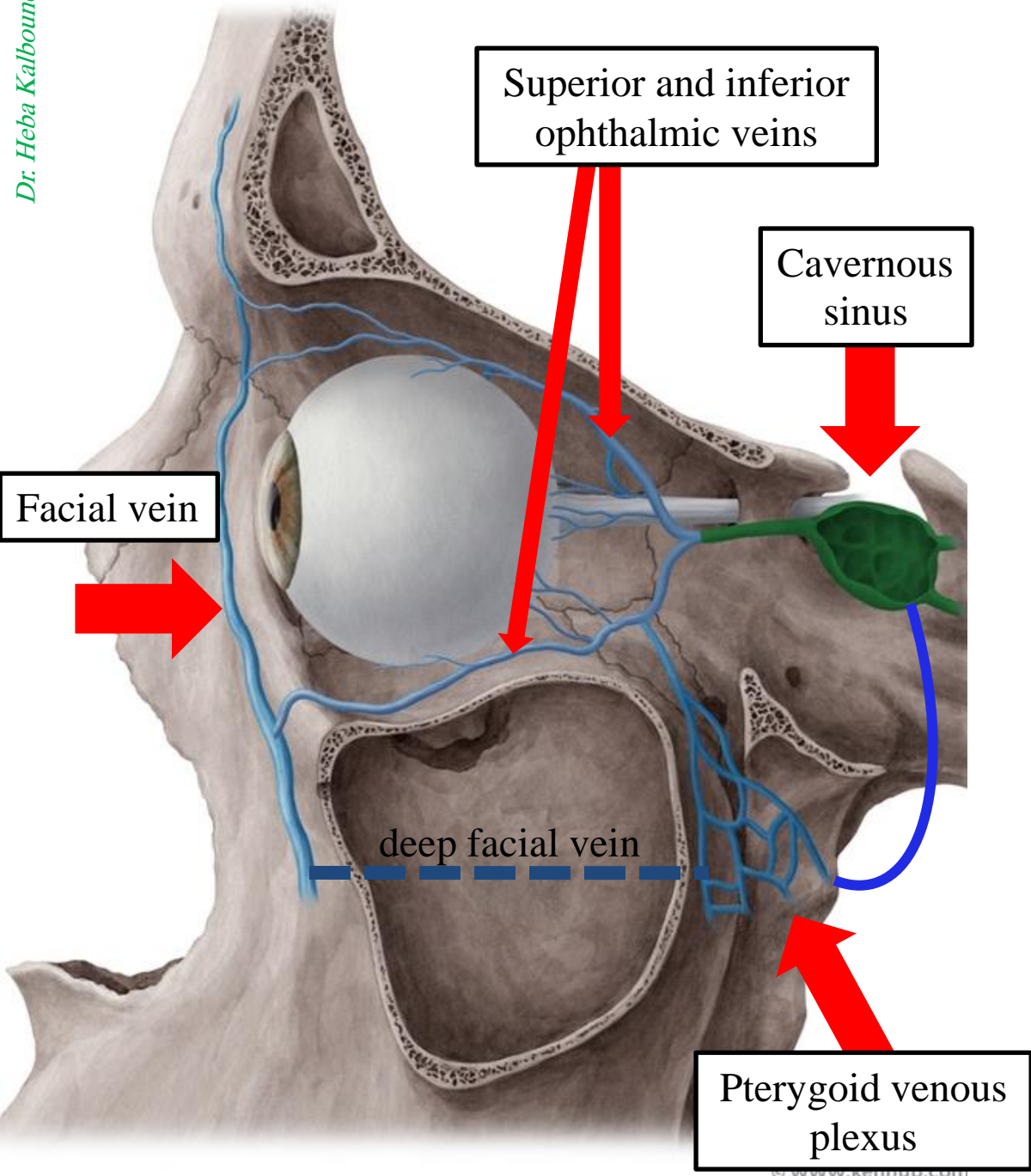
Temporomandibular
joint

Sphenomandibular
ligament



Dr. Heba Kalbouneh

It is the primary passive support
of the mandible, along with the
muscles of mastication.



Pterygoid venous plexus

It is a valveless venous plexus of considerable size, and is situated on the lateral aspect of medial pterygoid within the infratemporal fossa

It drains the eye and is directly connected to the cavernous sinus. It provides a potential route by which infections of the face can spread intracranially.

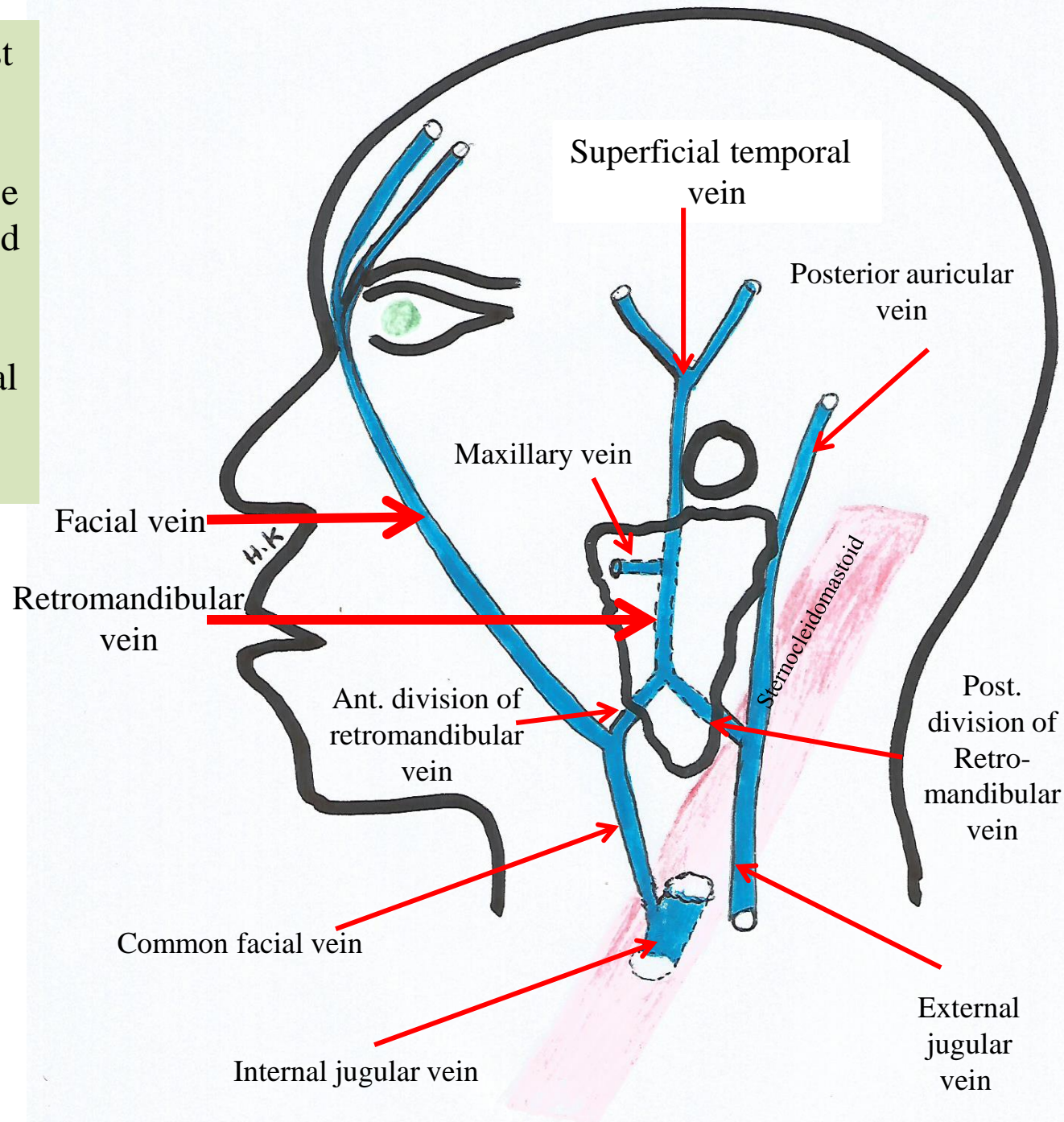
It receives tributaries corresponding with the branches of the maxillary artery

It forms the maxillary vein

The **maxillary vein** consist of a short trunk

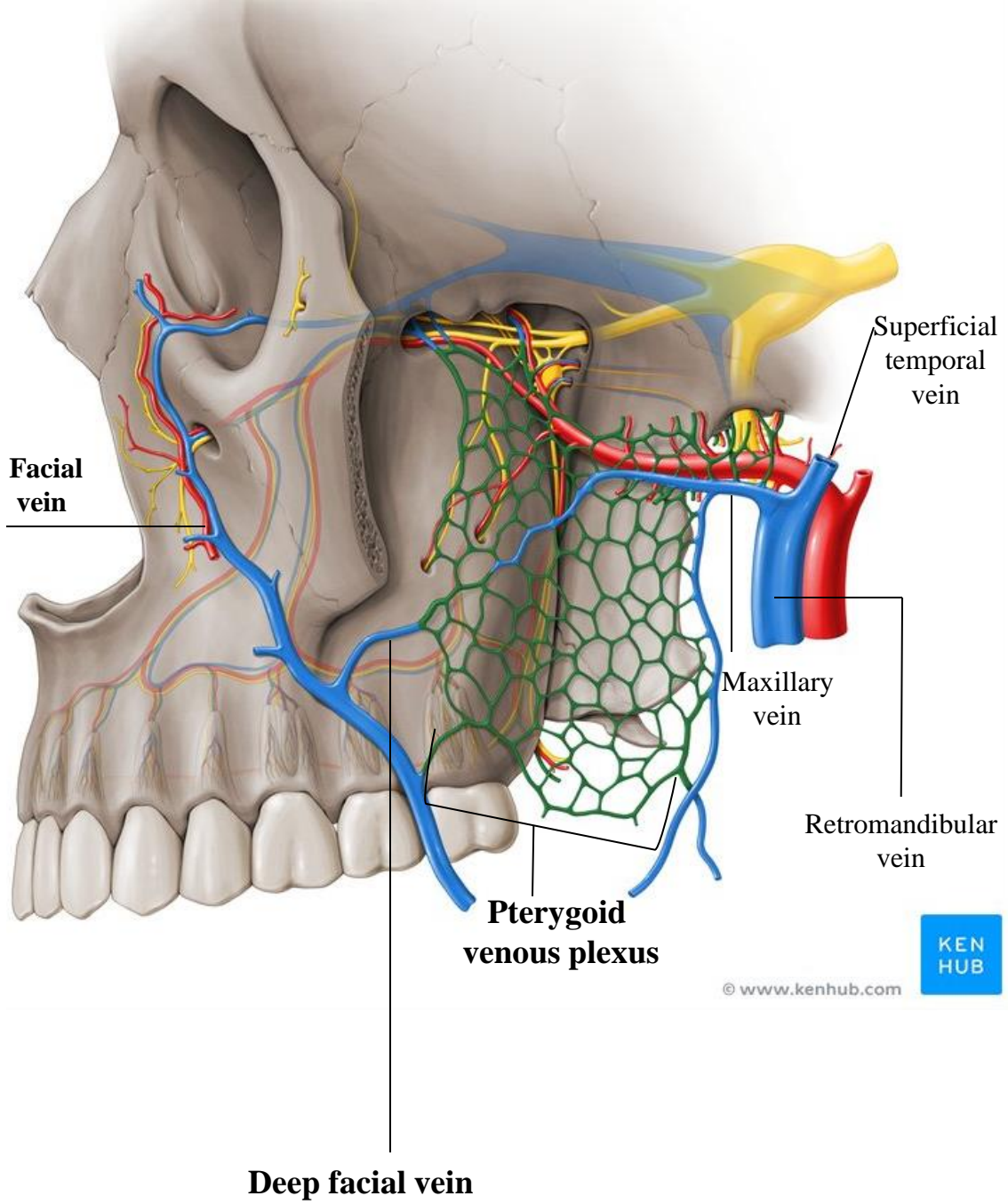
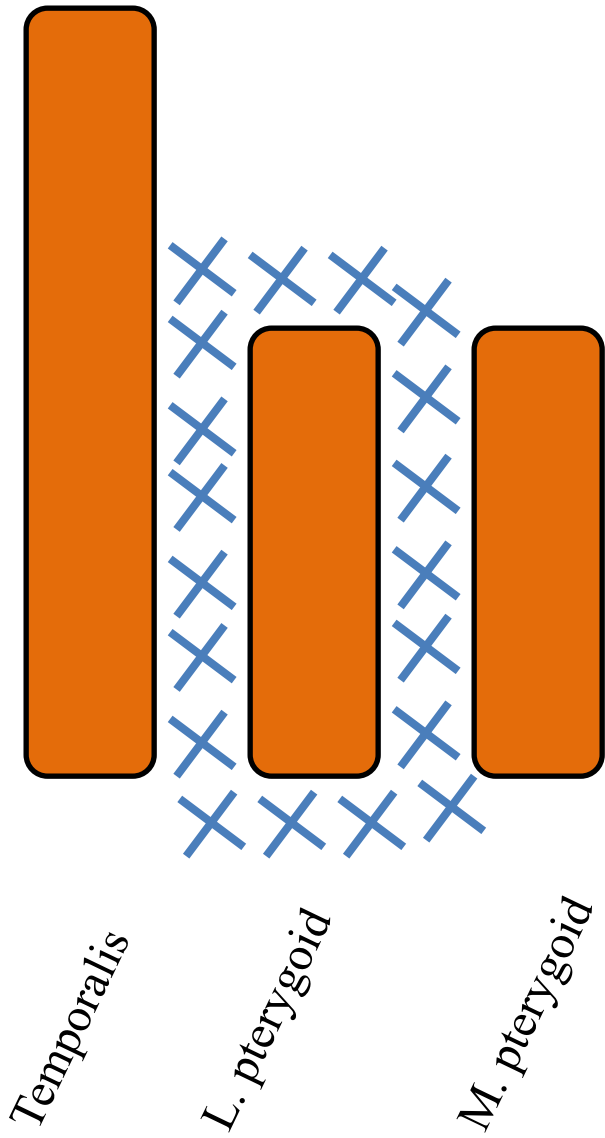
It is formed by a confluence of the veins of the pterygoid plexus

It unites with the superficial temporal vein to form the retromandibular vein




Note:

Pterygoid venous plexus lies around lateral pterygoid muscle



The **otic ganglion** is a small parasympathetic ganglion located immediately below the foramen ovale in the infratemporal fossa and on the medial surface of the mandibular nerve.

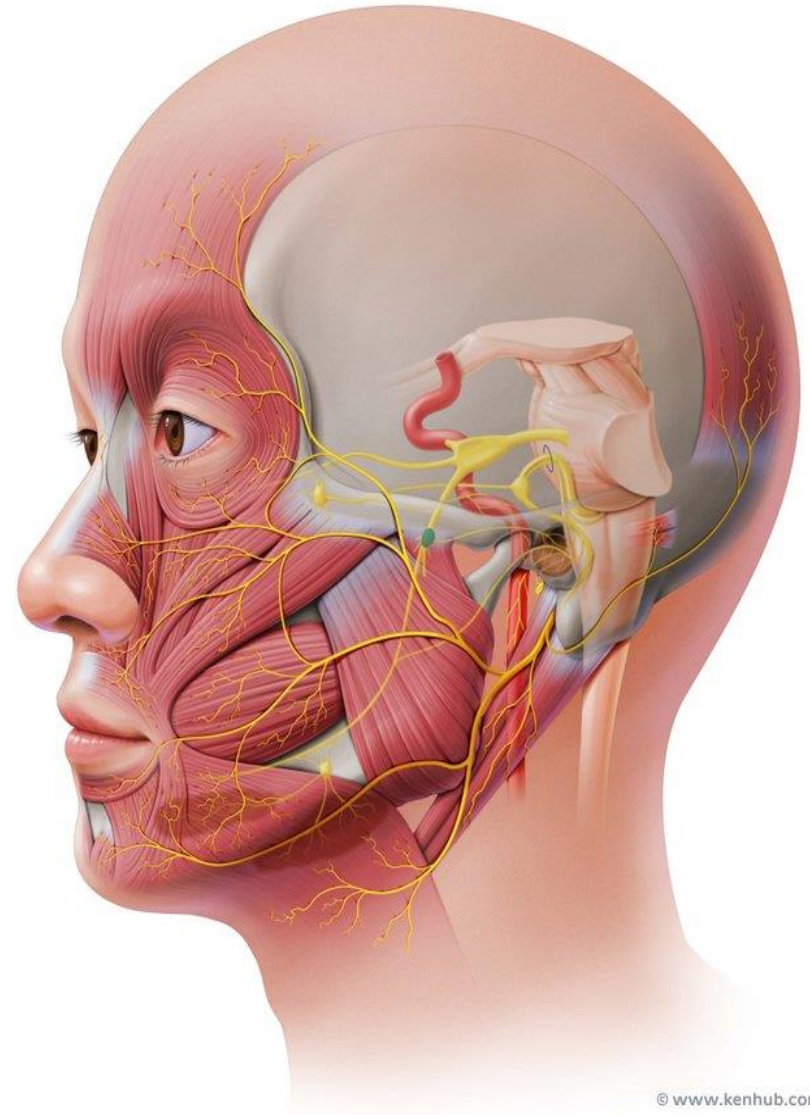
It is functionally associated with the glossopharyngeal nerve and innervates the parotid gland for salivation.



The preganglionic parasympathetic fibers originate in the glossopharyngeal nerve, and they reach the ganglion via the **lesser petrosal nerve**

The postganglionic parasympathetic (secretomotor) fibers reach the parotid salivary gland via the **auriculotemporal nerve**.

Nerve fibers leaving this ganglion ‘hitchhike’ along the auriculotemporal nerve to reach the parotid gland.



Tympanic Nerve

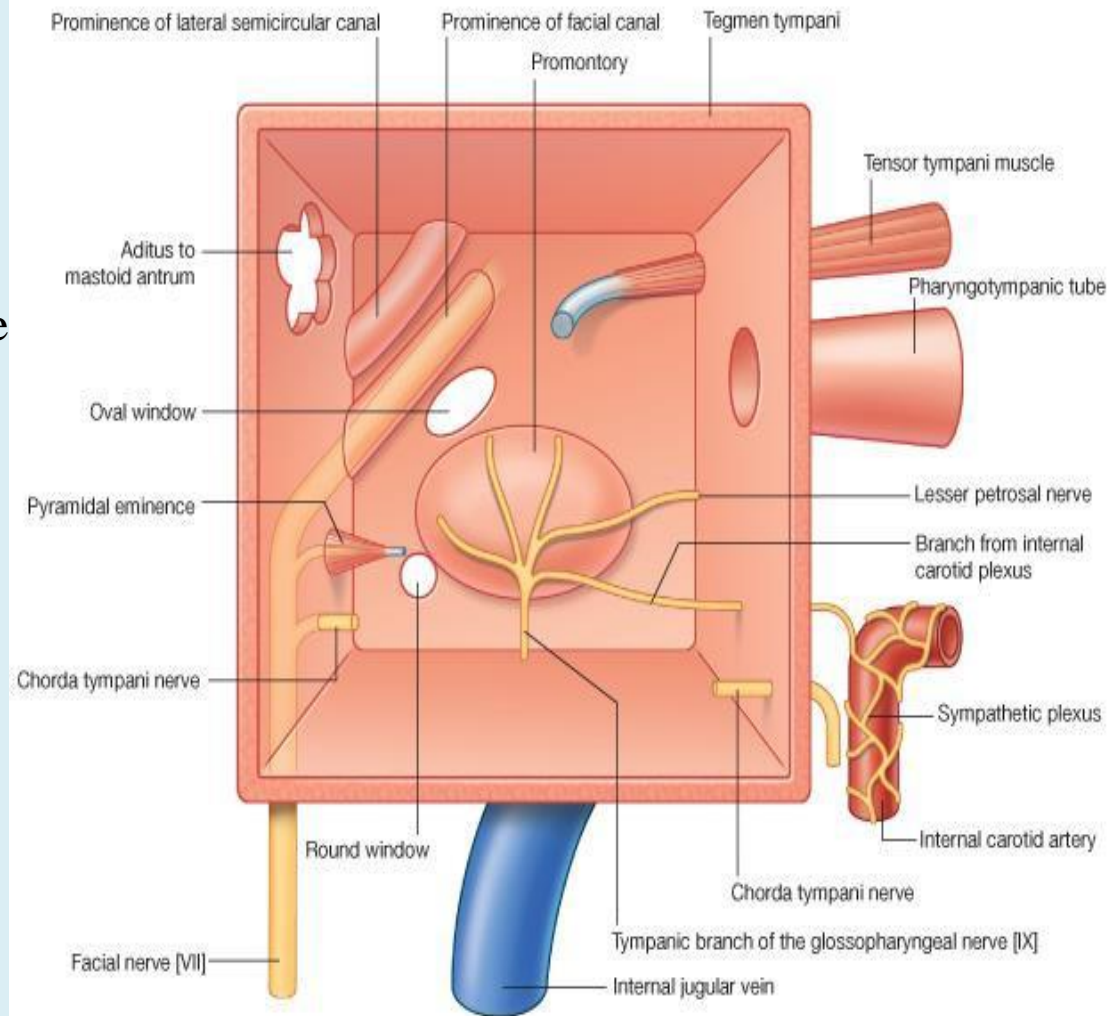
- The tympanic nerve arises from the glossopharyngeal nerve, just below the jugular foramen
- It passes through the floor of the middle ear and onto the promontory
- Here it splits into branches, which form the **tympanic plexus**.
- The tympanic plexus supplies the lining of the middle ear and gives off:

Lesser petrosal nerve

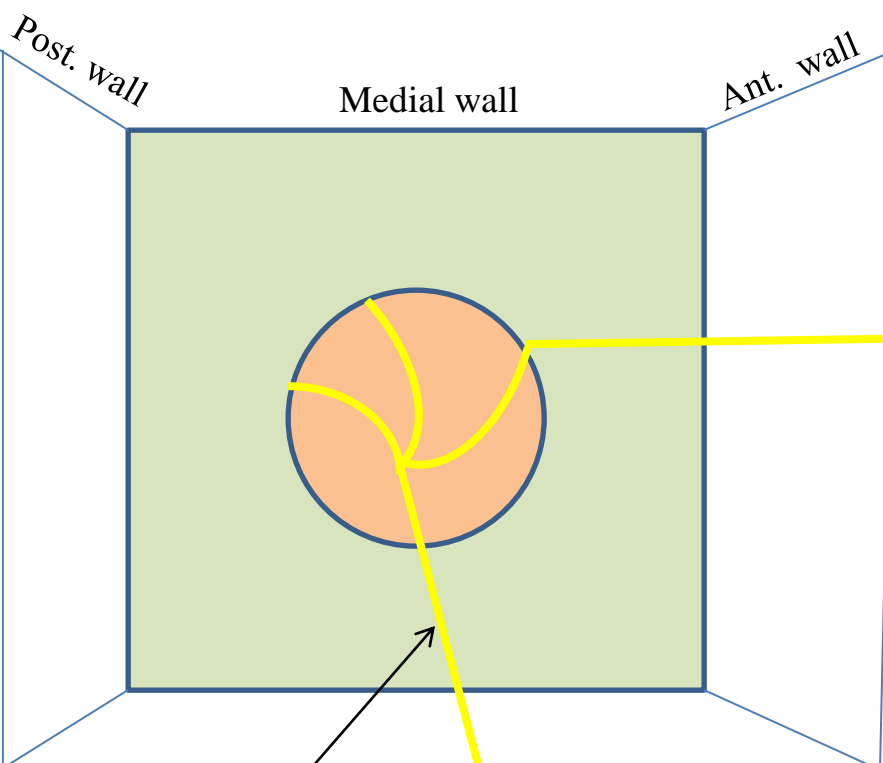
It leaves the skull through the foramen ovale



Carries preganglionic parasympathetic fibers to the parotid gland via the **otic ganglion**

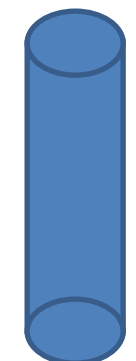


The **lesser petrosal nerve** is a branch from glossopharyngeal nerve (CN IX), carrying parasympathetic preganglionic fibers from the tympanic plexus to the parotid gland. It synapses in the otic ganglion, from where the postganglionic fibers emerge

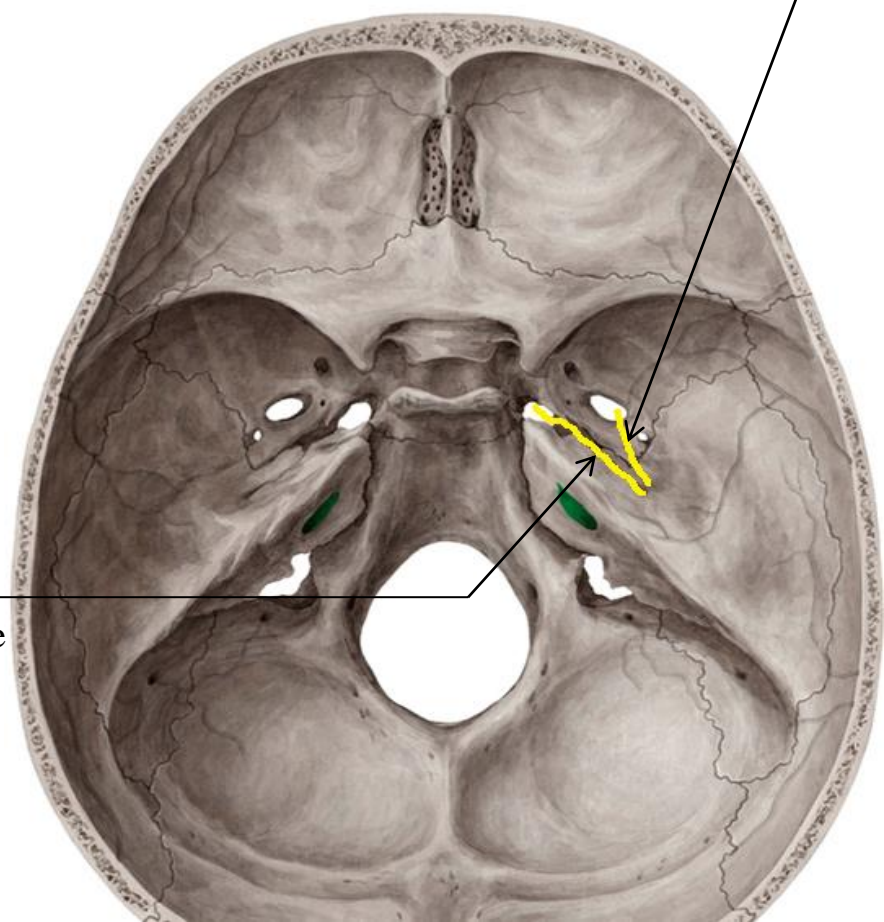


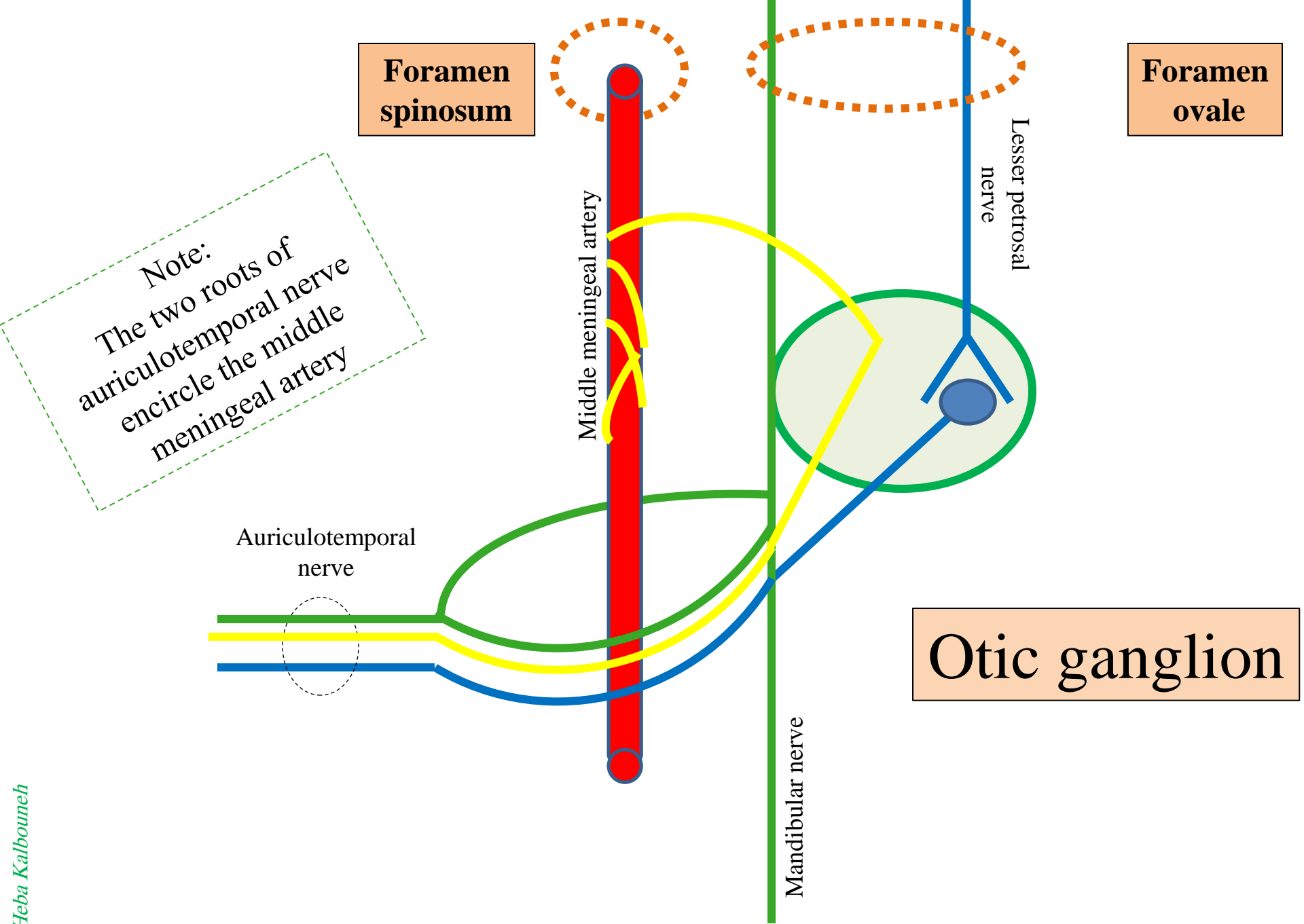
Lesser petrosal nerve

Tympanic nerve



Glossopharyngeal nerve





Foramen spinosum

Foramen ovale

Note:
The two roots of
auriculotemporal nerve
encircle the middle
meningeal artery

Middle meningeal artery

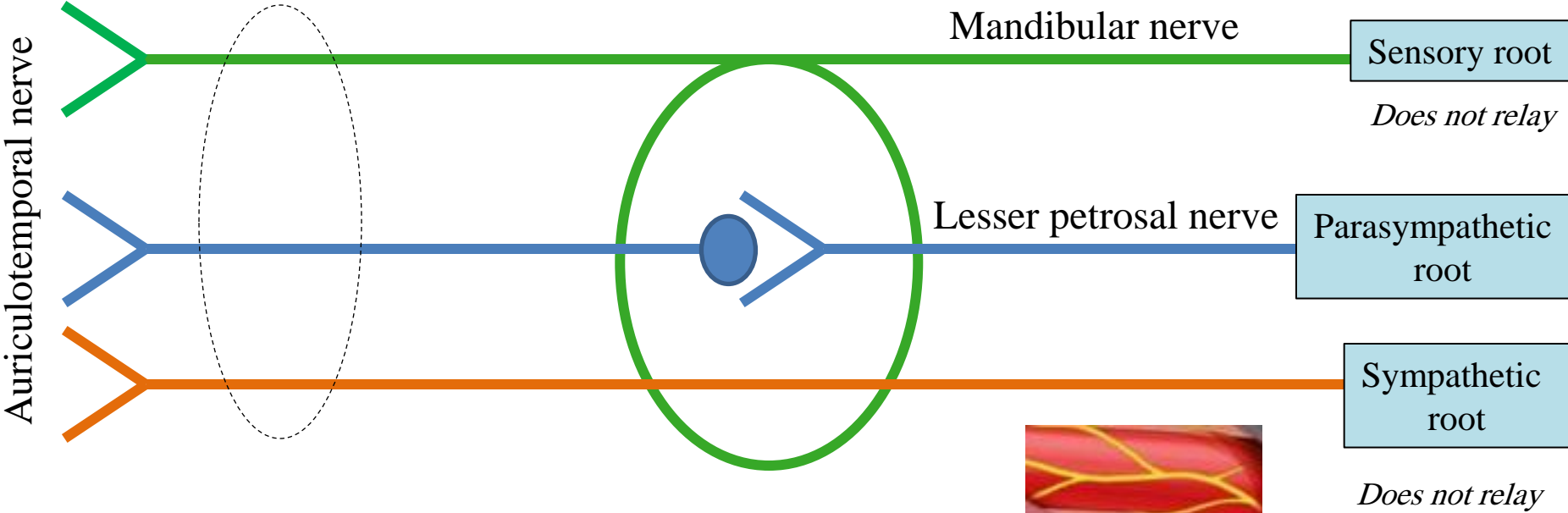
Lesser petrosal
nerve

Auriculotemporal
nerve

Otic ganglion

Mandibular nerve

Anatomically, its connected to mandibular nerve
Functionally, its associated with the glossopharyngeal nerve



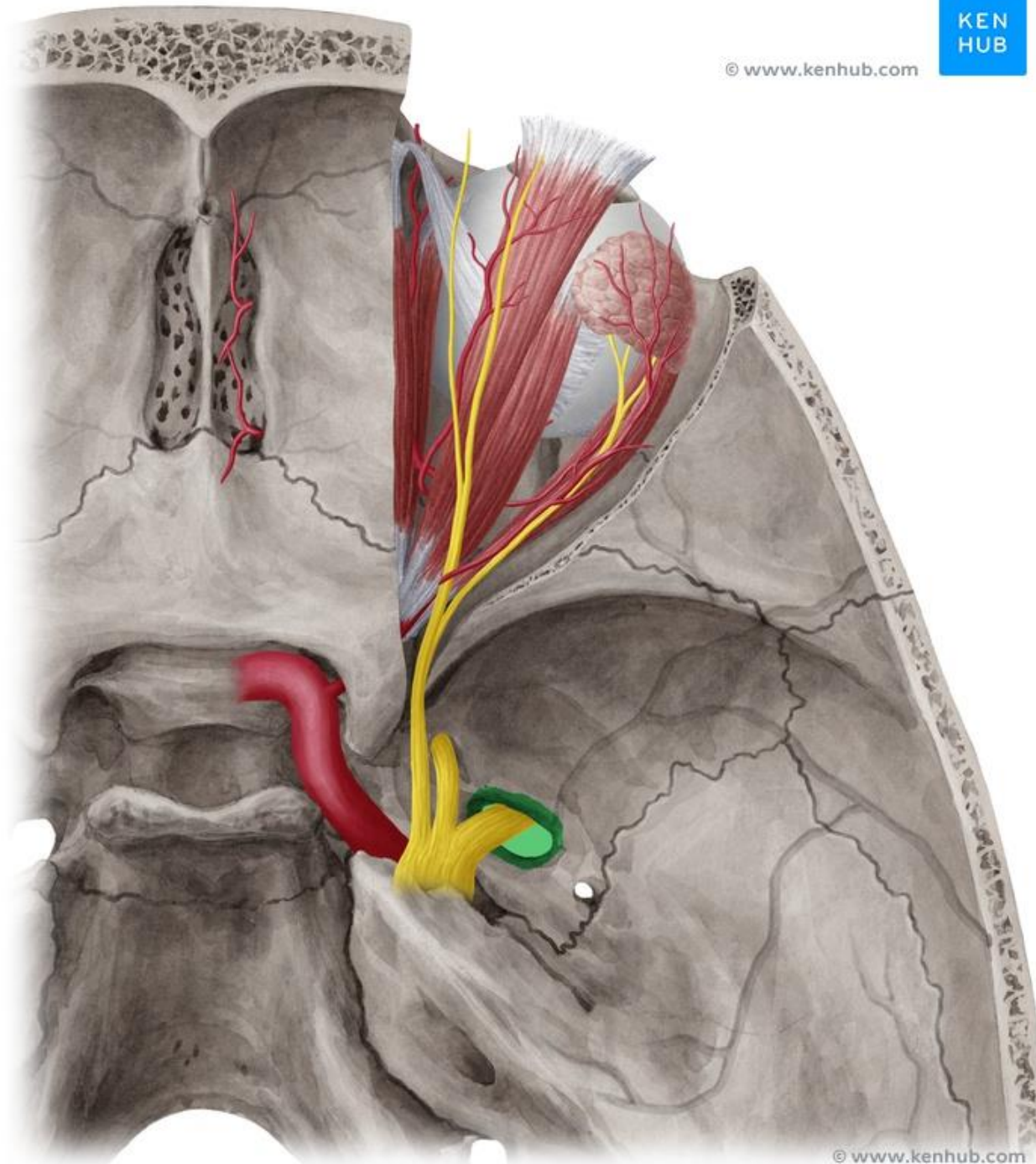
Otic ganglion

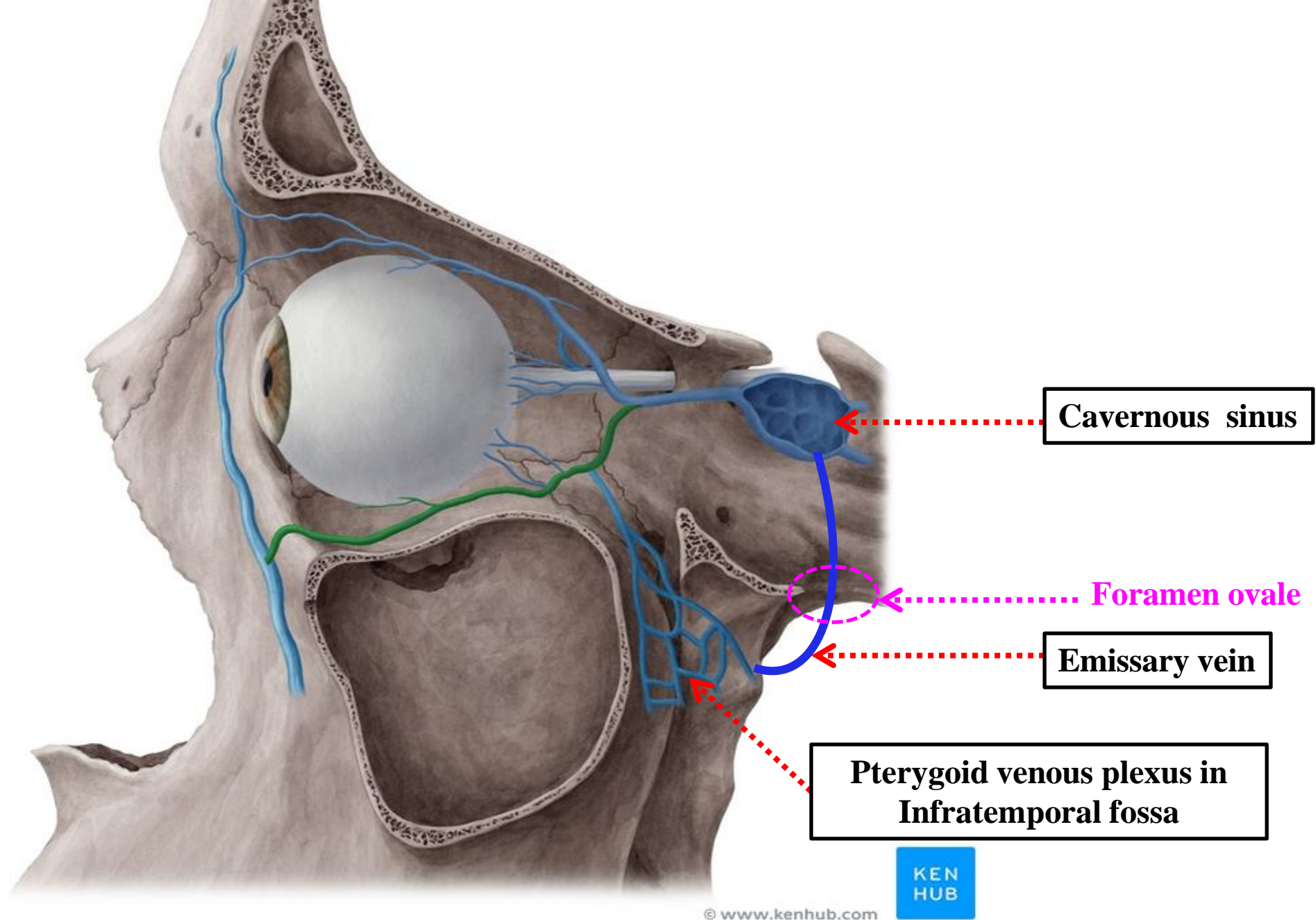
Foramen ovale transmits:

Mandibular nerve
Accessory meningeal artery
Lesser petrosal nerve
Emissary vein



MALE





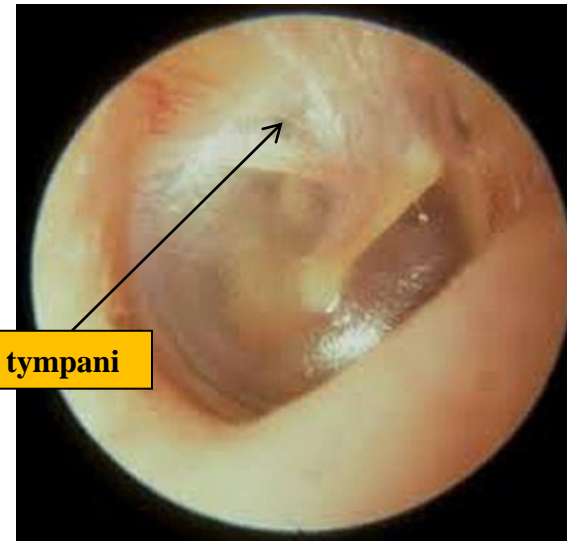
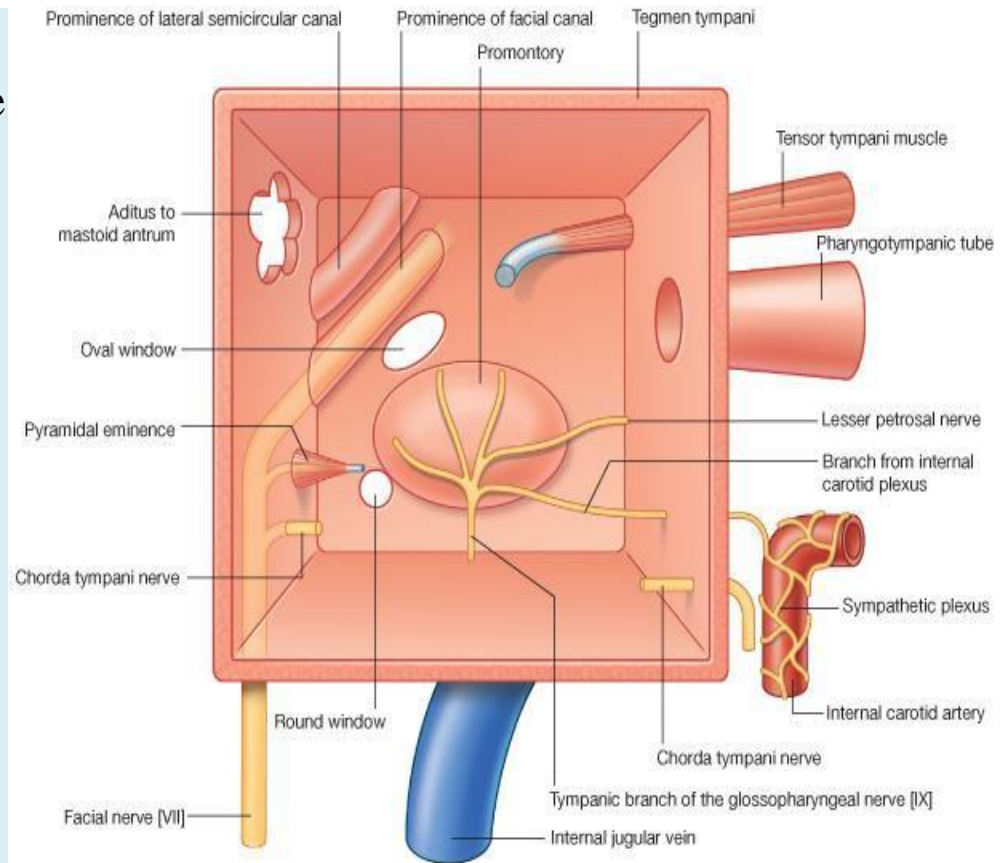
The chorda tympani

- ✓ It arises from the facial nerve just above the stylomastoid foramen
- ✓ It enters the middle ear close to the posterior border of the tympanic membrane.
- ✓ It then runs forward over the tympanic membrane and crosses the root of the handle of the malleus
- ✓ It leaves the middle ear through the petrotympanic fissure and enters the infratemporal fossa, where it joins the lingual nerve



The chorda tympani contains:

1. Taste fibers from the mucous membrane covering the anterior two thirds of the tongue and the floor of the mouth.
2. Carries preganglionic parasympathetic fibers to the submandibular and sublingual glands via the **submandibular ganglion**



The **petrotympanic fissure** is a fissure in the temporal bone

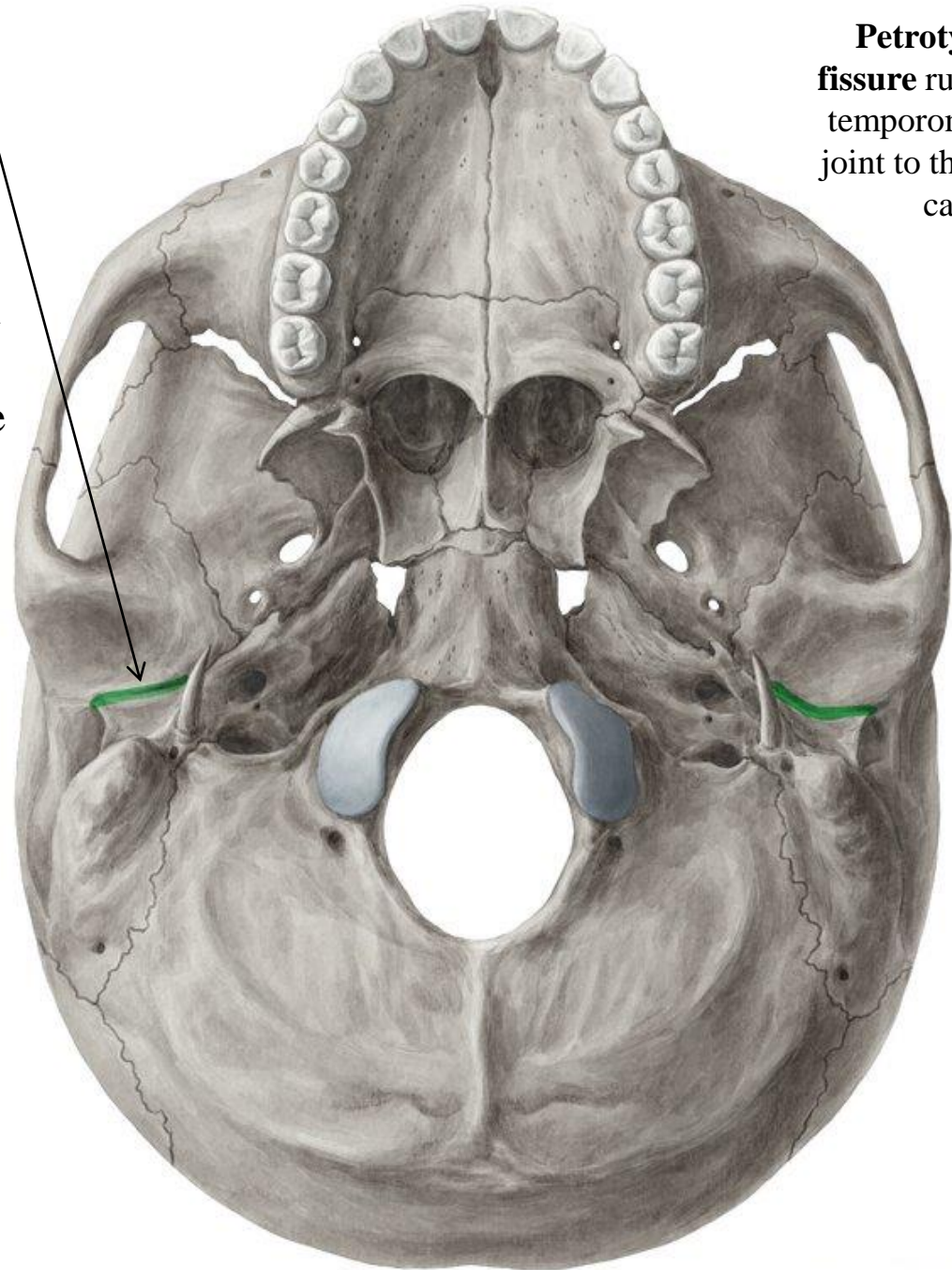


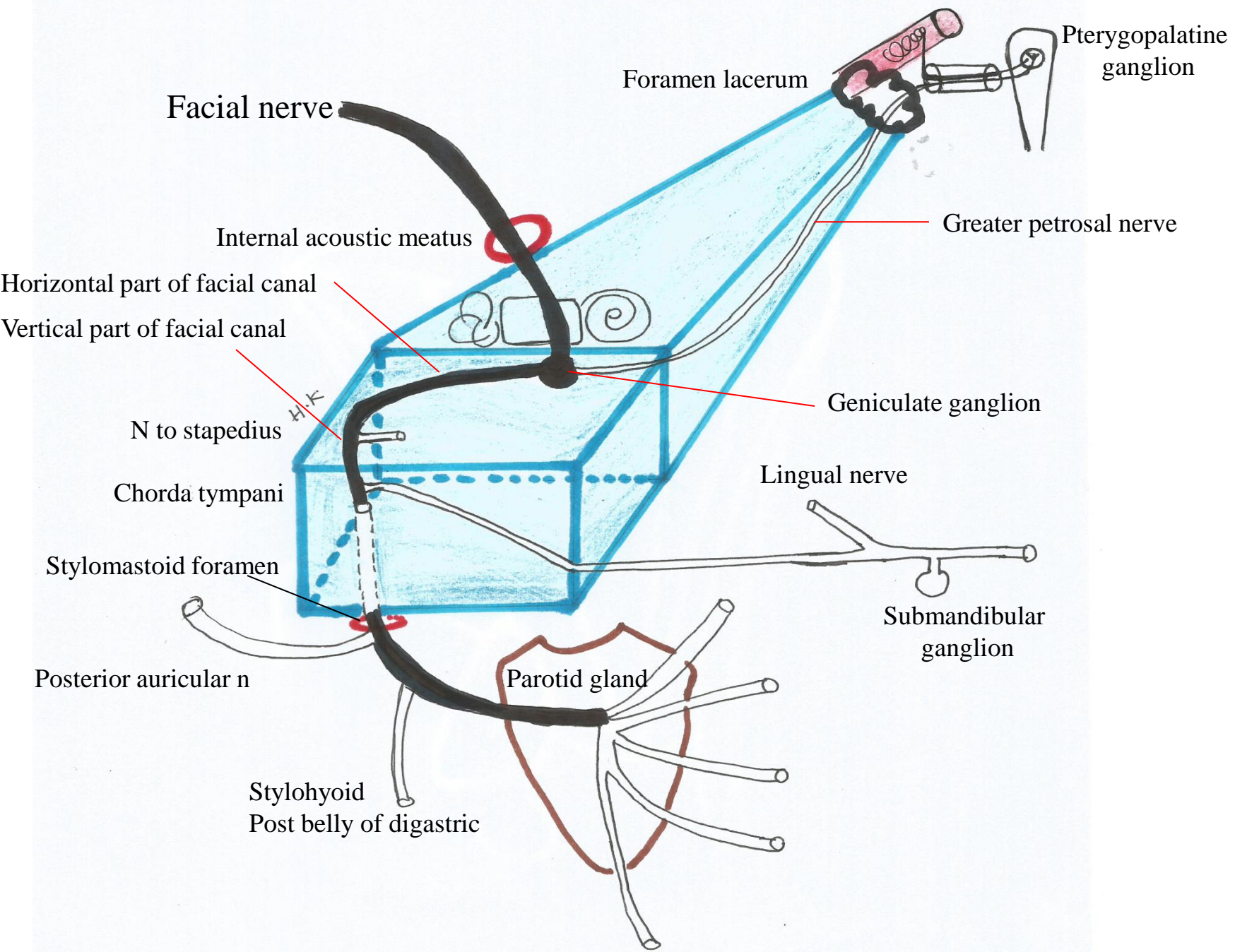
The chorda tympani runs through the fissure to join with the lingual nerve in the infratemporal fossa. It provides taste innervation to the anterior 2/3 of the tongue.

The **chorda tympani** is a branch of the facial nerve

The **chorda tympani** passes medial to the tympanic membrane and the handle of the malleus, and again enters the temporal bone. It exits the skull through the petrotympanic fissure and descends in the infratemporal fossa.

Petrotympanic fissure runs from the temporomandibular joint to the tympanic cavity





Anatomically, its connected to lingual nerve
Functionally, its associated with the facial nerve (chorda tympani)

