



Clinical cases

Head and Neck Anatomy

Edited by: **Batool B.**

Dr. Heba Kalbouneh

Associate Professor of Anatomy and Histology

Study the following case histories and select the best answer to the questions following them.

Case 1: A 51-year-old man comes to the office because of a 6-month history of a lump on his tongue that is interfering with his speech and eating; he also has had a 6 kg weight loss during this period. He has smoked 1 pack of cigarettes daily and has consumed six 12-oz bottles of beer on weekend nights during the past 30 years. His vital signs are within normal limits. Physical examination shows a 1.5-cm mass on the apex of the tongue. Further evaluation of the mass confirms squamous cell carcinoma.

It is most appropriate to evaluate which of the following lymph nodes first for evidence of metastasis in this patient?

USMLE

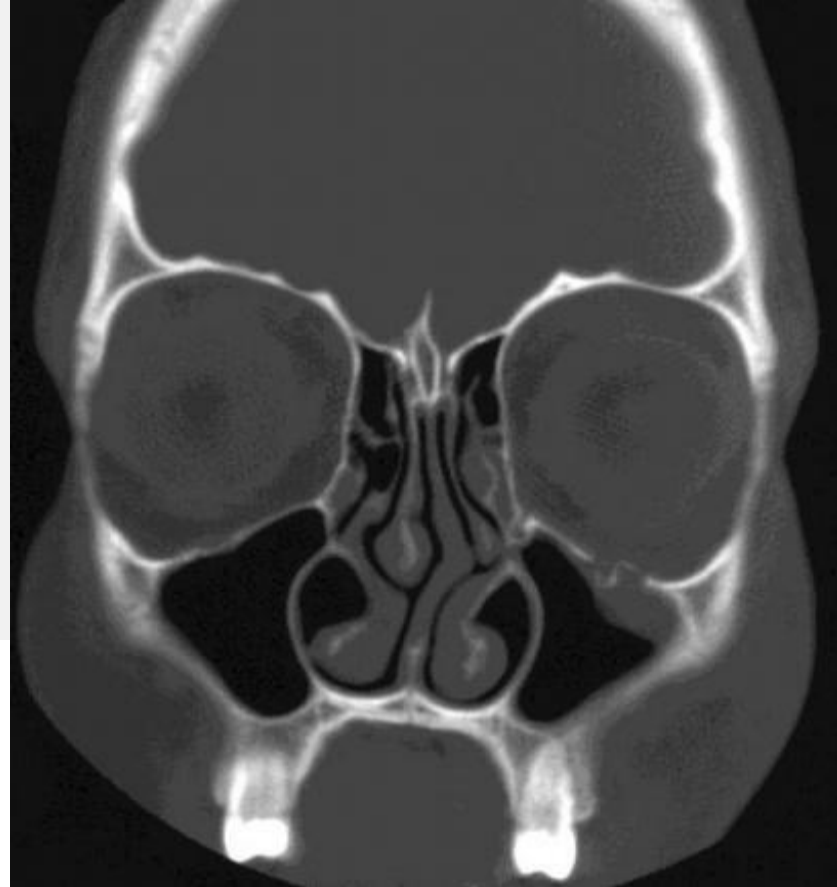
- (A) Inferior deep cervical
- (B) Parotid
- (C) Retropharyngeal
- (D) Submental
- (E) Superior deep cervical

Answer: D)submental
Submental drains parts of the tongue, and it's the first draining node of its course.

Case 2: A 42-year-old woman is brought to the emergency department because of double vision that began 20 minutes after she fell from her horse and landed on the left side of her face. Examination of the face shows ecchymoses over the left zygomatic arch. ACT scan of the head is shown.

Which of the following arteries is at greatest risk for injury in this patient?

- (A) Facial
- (B) Frontal
- (C) Infraorbital
- (D) Lacrimal
- (E) Ophthalmic



USMLE

Answer: C) infraorbital
Passes through the site of injury

Case 3: A 33 year old woman undergoes a lymph node biopsy for her deep cervical nodes on the left side of her neck. Immediately following surgery, she complains of weakness in her left shoulder, on exam, the left shoulder droops, and she is unable to raise the point of her shoulder. She denies numbness in her shoulder, back and neck

What nerve appears to have been accidentally cut during the biopsy?

- A. Greater occipital nerve
- B. Spinal nerve C3
- C. Dorsal scapular nerve
- D. Accessory nerve
- E. Dorsal primary ramus of C2

Answer: D) accessory

Because there's no numbness so cutaneous nerves are excluded, and the injury is most probably in trapezius because there's loss of shoulder support but not its entire function.

Case 4: A 62-year-old woman has a parotidectomy. After the procedure, she has trouble chewing her food. Tests reveal that her trigeminal nerve has not been damaged. However, innervation to which of the following muscles was damaged during the procedure?

- A. Temporalis
- B. Medial pterygoid
- C. Masseter
- D. Lateral pterygoid
- E. Buccinator

Answer: E) Buccinator

Because it's supplied by the facial nerve
All the others by mandibular

Case 5: A 16 year old female volleyball player is admitted to the hospital after being hit in the eye with a ball spiked at the net. Radiographic examination reveals a blow-out fracture of the inferior wall of the orbit. Physical examination also reveals that the pupil of her eye cannot be turned upward

This question is flawed, as the superior rectus would still be able to lift the eyeball even if IO is disabled. Just imagine that only the function of IO was lost,

Which of the following muscle(s) is (are) most likely injured?

- A. Inferior rectus and inferior oblique
- B. Medial and inferior recti
- C. Inferior oblique
- D. Medial rectus, inferior rectus and inferior oblique
- E. Inferior rectus

Answer: C) inferior oblique

Because it suits the function and is located in the site of injury

Case 6: 24-year-old man is brought to the emergency department 40 minutes after he was involved in a motor vehicle collision. He was the unrestrained driver. He is conscious. Physical examination shows numerous lacerations and ecchymoses over the face. His vision is normal. Ocular, facial, and lingual movements are intact. The gag reflex is present. Sensation to pinprick is absent over the right side of the face anterior to the right ear, extending down along the full extent of the mandible to the chin. Sensation also is absent over the right side of the tongue. X-rays of the skull show fractures of the orbit, zygomatic arch, and infratemporal fossa.

The most likely cause of these findings is a fracture affecting which of the following locations?

USMLE

- (A) Foramen lacerum
- (B) Foramen ovale**
- (C) Foramen rotundum
- (D) Foramen spinosum
- (E) Jugular foramen

As you read, vision is normal: optic is normal
Ocular, lingual and facial are normal: 3, 4, 6 are normal
12 is normal and 7 is normal
Gag reflex is mediated by the 9th (sensory) and 10th
(motor reflex) C.Ns so they're normal

Case 7: A 20-year-old man is brought to the emergency department 1 hour after he was involved in a motorcycle collision. He was not wearing a helmet. Physical examination shows clear **fluid dripping from the nose**. X-rays show a fracture of the cribriform plate of the ethmoid bone.

This patient is at greatest risk for impairment of which of the following senses? **CSF**

- A. Balance
- B. Hearing
- C. Olfaction**
- D. Taste from the anterior two thirds of the tongue
- E. Taste from the posterior one third of the tongue
- F. Vision

Case 8: A 43-year-old woman was seen in the emergency department with a large abscess in the middle of the right posterior triangle of the neck. The abscess was red, hot, and fluctuant. The abscess showed evidence that it was pointing and about to rupture. The physician decided to incise the abscess and insert a drain. The patient returned to the department for the dressings to be changed 5 days later. She stated that she felt much better and that her neck was no longer painful. However, there was one thing that she could not understand. She could no longer raise her right hand above her head to brush her hair.

The following statements explain the signs and symptoms in this case, suggesting that the spinal part of the accessory nerve had been incised, except which?

A. To raise the hand above the head, it is necessary for the trapezius muscle, assisted by the serratus anterior, to contract and rotate the scapula so that the glenoid cavity faces upward.

B. The trapezius muscle is innervated by the spinal part of the accessory nerve.

C. As the spinal part of the accessory nerve crosses the posterior triangle of the neck, it is deeply placed, being covered by the skin, the superficial fascia, the investing layer of deep cervical fascia, and the levator scapulae muscle.

D. The knife opening the abscess had cut the accessory nerve.

Case 9: A 17-year-old girl visited her dermatologist because of severe acne of the face. On examination, it was found that a small abscess was present on the side of the nose. The patient was given antibiotics and was warned **not to press the abscess**.

The following facts concerning this patient emphasize why it is important to adequately treat this condition except which?

A. The skin area between the eye, the upper lip, and the side of the nose is a hazardous area to have an infection of the skin.

B. The danger area is drained by the facial vein.

C. Interference with a boil by squeezing or pricking it can lead to spread of the infection and thrombosis of the facial vein.

D. The facial vein communicates with the cavernous sinus via the superior and inferior ophthalmic veins.

E. Cavernous sinus thrombosis can occur by the spread of infection by the venous blood.

F. The blood in the facial vein is unable to spread upward because of valves.

So the infection wouldn't spread to dangerous areas

Case 10: A 7-year-old boy with right-sided otitis media was treated with antibiotics. The organisms did not respond to the treatment, and the infection spread to the mastoid antrum and the mastoid air cells. The surgeon decided to perform a radical mastoid operation. After the operation, it was noticed that the boy's face was distorted.

The following signs and symptoms suggest that the right facial nerve had been damaged during the operation except which?

- A. The mouth was drawn upward to the left.
- B. Saliva tended to accumulate in his left cheek.
- C. He was unable to close his right eye.
- D. The saliva tended to dribble from the right corner of his mouth.
- E. All the muscles of the right side of his face were paralyzed.

Answer: B

It would accumulate in the right not the left, because the buccinator is impaired.

Case 11: A 43-year-old woman visited her physician complaining of severe intermittent pain on the right side of her face. The pain was precipitated by exposing the right side of her face to a draft of cold air. The pain was stabbing in nature and lasted about 12 hours before finally disappearing. When asked to point out on her face the area where the pain was experienced, the patient mapped out the skin area over the right side of the lower jaw extending backward and upward over the side of the head to the vertex.

The following signs and symptoms in this patient strongly suggest a diagnosis of trigeminal neuralgia except which?

- A. The skin area where the patient experienced the pain was innervated by the mandibular division of the trigeminal nerve.
- B. The stabbing nature of the pain is characteristic of the disease.
- C. The trigger mechanism, stimulation of an area that received its sensory innervation from the trigeminal nerve, is characteristic of trigeminal neuralgia.
- D. Examination of the actions of the masseter and the temporalis muscles showed evidence of weakness on the right side.
- E. The patient experienced hyperesthesia (excessive feeling) in the distribution of the right auriculotemporal nerve.

Answer: D → Because trigeminal neuralgia only affects the sensory part

Case 12: A 26-year-old baseball player was struck on the right side of the head with a ball. The player fell to the ground but did not lose consciousness. After resting for 1 hour and then getting up, he was seen to be confused and irritable. Later, he staggered and fell to the floor. On questioning, he was seen to be drowsy, and twitching of the lower left half of his face and left arm was noted.

A diagnosis of extradural hemorrhage was made based on the following statements except which?

- (a) A minor blow on the side of the head can easily fracture the thin anteroinferior part of the parietal bone.
- (b) The posterior branch of the middle meningeal artery may be sectioned at the site of the fracture.
- (c) Arterial hemorrhage outside the meningeal layer of the dura mater may occur.
- (d) A large blood clot outside the dura can exert pressure on the motor area of the brain
- (e) The blood clot exerts pressure on the motor area that supplies the facial muscles and the muscles of the upper limb → explains the observed symptoms

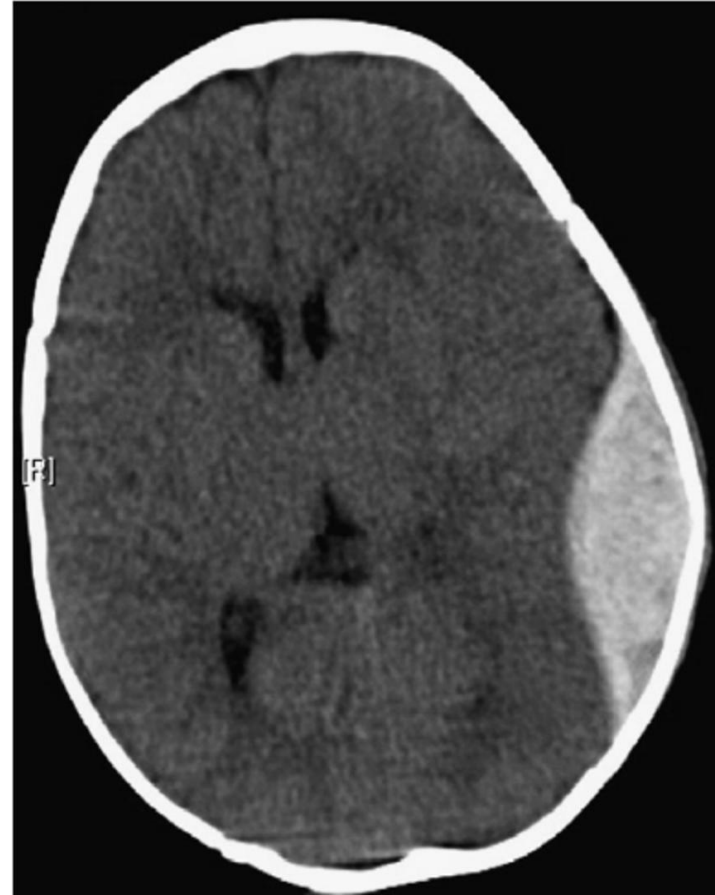
Case 13: A 35 year old man was involved in a fight and sustained a punch to the right orbit. He came to the emergency department with double vision. Examination of the orbits revealed that when the patient was asked to look upward the right eye was unable to rotate superiorly when adducted.

Which of the following muscle(s) is (are) most likely injured?

- A. Inferior rectus and inferior oblique
- B. Medial and inferior recti
- C. Inferior oblique
- D. Medial rectus, inferior rectus and inferior oblique
- E. Inferior rectus
- F. Inferior oblique and superior rectus

Answer: C) Inferior Oblique

Case 14: A 33 year old man was playing cricket for his local Sunday team. As the new bowler pitched the ball short, it bounced higher than he anticipated and hit him on the side of his head. He immediately fell to the ground unconscious, but after about 30 seconds he was helped to his feet and felt otherwise well. It was noted he had some bruising around his temple. He decided not to continue playing and went to watch the match from the side. Over the next hour he became extremely sleepy and was eventually unrousable. He was rushed to hospital. ACT scan was performed.



Diagnosis: Epidural hematoma
Tip: Suspect then inspect
(think of ED.HT then confirm with CT)

Case 15: In preparation of neck dissection (surgical procedure to remove cervical lymph nodes due to metastasis), the surgeon gave the junior doctor a task of describing the lymphatic drainage of the head and neck, he asked him the following questions:

The lymph from posterior part of the SCALP drains into the ____group of lymph nodes:

- a. Buccal.
- b. Occipital.
- c. Laryngeal.
- d. Paratracheal.
- e. Anterior cervical.

Answer: B

The submental group of lymph nodes drain the lymph from:

- a. Upper lip
- b. Parotid gland
- c. Upper incisors
- d. Tip of the tongue
- e. External auditory meatus

Answer: D

The superficial cervical lymph nodes are located alongside the ____ vein:

- a. Subclavian.
- b. Internal jugular.
- c. External jugular.
- d. Brachiocephalic.

Answer: C

The carotid triangle hosts the _____ group of lymph nodes:

- a. Parotid.
- b. Mastoid.
- c. Laryngeal.
- d. Deep cervical.
- e. Submandibular.

Answer: D

You're made for the top, where eagles fly.
Keep doing your best, keep striving. The
sky is your stepping stone.

I wish you the best in your exam

