

Past Papers for Anatomy GIS

1-What is wrong about the anal canal:

- a. In internal hemorrhoid a branch of inferior rectal vein is involved.
- b. It extends from the anorectal junction to the anus.

Answer: a

2-In PR examination, we can palp all of the following except:

- a. sigmoid colon
- b. ureter
- c. prostate
- d. seminal vesicles
- e. urinary bladder

Answer: b

3-All of the following regarding the rectus sheath is true except:

- a. 2 muscles
- b. 2 epigastric arteries
- c. Lower intercostals nerves
- d. Ilioinguinal and iliohypogastric nerves
- e. Tendinous intersections

Answer: d

4- An injury to the ilio-inguinal nerve , might be associated with one of these types of hernia :

- a. direct hernia
- b. indirect hernia
- c. lumbar hernia
- d. internal hernia
- e. incisional hernia

Answer: a

5-All the following statements about the abdominal sympathetic chain are true except :

- a. has 4-5 segmental ganglia

- b. the left chain lies on the left edge of the aorta
- c. the sympathetic fibers that innervates the sigmoid comes from the sup & inf mesenteric plexuses
- d. it passes behind the medial arcuate ligament
- e. it passes behind the common iliac vessels

Answer: c

6- The ventral mesentery forms all the following ligaments and omenta EXCEPT:

- a. Falciform ligaments
- b. Ligamentum teres
- c. Coronary ligaments
- d. Triangular ligaments
- e. Lesser omentum

Answer: b

7- The dorsal pancreatic bud forms all the following parts of the pancreas EXCEPT:

- a. Uncinate process of the pancreas
- b. Superior part of the head
- c. Neck
- d. Body
- e. Tail

Answer: a

8- In the posterior abdominal wall all of the following lies at the left side of psoas major muscle Except:

- a. Femoral nerve
- b. Lateral cutaneous nerve of the thigh
- c. Genitofemoral nerve
- d. Iliohypogastric nerve
- e. Ilioinguinal nerve

Answer: c

9- The lower third of the anal canal all the following statements are correct EXCEPT:

- a. Surrounded by external anal sphincter
- b. It is ectodermal in origin
- c. The lining epithelium is stratified squamous
- d. It is sensitive to pain and touch
- e. It contains anal columns

Answer: e

10- The palatine tonsil all the following statement are correct EXCEPT:

- a. It lies in the tonsillar sinus between two folds of mucosa
- b. Has sensory innervation from the lesser palatine nerve
- c. Has lymphatic drainage to the jugulodigastric lymph nodes
- d. The source of bleeding after tonsillectomy is usually the arterial blood supply
- e. Receives blood supply from the facial artery

Answer: d

11- Meckel's diverticulum all the following statement are correct EXCEPT:

- a. Occurs in the antimesenteric branch of the ileum
- b. May contain gastric mucosa
- c. It is situated 2 feet from the ileocecal junction
- d. It represents a persistent of vitelline duct
- e. May communicate with bladder

Answer: e

12- Patient who lost taste from the anterior part of his tongue

- a. loss in facial nerve
- b. loss in hypoglossal nerve
- c. loss in oculomotor nerve

Answer: a

13- Wrong about palatine tonsils

- a. The tonsil is covered on its lateral surface by a fibrous capsule
- b. sensory from vagus nerve

Answer: b

14- A patient who may have lost facial nerve in injury, the wrong test is

- a. ask him to show his teeth
- b. ask him to close his eyes
- c. ask him to clench his teeth

Answer: c

15- Wrong about pharynx

- a. all muscles are innervated by pharyngeal plexus except stylopharyngeus that receives it from the vagus nerve
- b. The pharyngeal recess is a depression in the pharyngeal wall behind the tubal elevation

Answer: a

16- About swallowing, all true except,

- a. composed of voluntary and involuntary phases.
- b. primary peristalsis is initiated at the pharynx
- c. secondary peristalsis is initiated in the esophagus by remnant of food in the esophagus.
- d. preceded by relaxation wave to open the lower esophageal sphincter.
- e. closure of epiglottis is voluntary

Answer: e

17- A needle in the right 9th intercostal space will not pierce

- a. Intercostal vein
- b. Serratus anterior
- c. Intercostal artery

Answer: b

18- Wrong about indirect hernia

- a. sac from superficial inguinal ring will be below and lateral to pubic tubercle
- b. It is 20 times more common in young males than females

Answer: a

19- Wrong about spermatic cord

- a. inner spermatic fascia is form internal oblique
- b. External Spermatic fascia is derived from the external oblique aponeurosis

Answer: a

20- Stab to right inguinal region injuring what nerve that will cause loss of sensation in the inguinal region

- a. T10
- b. first lumbar nerve
- c. 3rd lumbar nerve

Answer: b

21- Which one of the following blood vessels usually causes post-operative bleeding after tonsillectomy:

- a. External palatine vein.
- b. Tonsillar branch of facial artery.
- c. Tonsillar branch of lingual artery.
- d. Tonsillar vein.
- e. Pharyngeal plexus of vein.

Answer: a

22- Not in the parotid bed

- a. medial pterygoid
- b. sternocleidomastoid
- c. ramus of mandible

Answer: a

23- Wrong about mesentery

- a. jejunum has wide diameter compered to ileum
- b. in the jejunum there are simple arcades and short vasarectea

Answer: b

24- Wrong about pancreas

- a. anterior surface is covered by peritoneum of greater sac
- b. posterior surface has no peritoneum

Answer: a

25- Wrong about direct hernia:

- a. bulges from superficial inguinal ring
- b. medial to inferior epigastric artery

Answer: a

26-A peptic ulcer in the posterior wall of the first part of the duodenum caused bleeding, what artery

- a. left gastric artery
- b. gastroduodenal

Answer: b

27-One of the following muscles is forming the palatine aponeurosis:

- a. Levator veli palatini muscle.
- b. Tensor veli palatini muscle.
- c. Musculus uvula.
- d. Palato-pharyngeus.
- e. Glosso-pharyngeus.

Answer: b

28- Mark the wrong match about the Large intestine, Appendix, Rectum and Anal Canal

- a. Mc Burney's point -identified tip of appendix
- b. transverse colon supplied by superior and inferior mesenteric arteries
- c. transverse rectal folds two at the left side and one at the right side
- d. lymph from lower half of anal canal -drain into superficial inguinal nodes
- e. rectal peritoneum-related to rectum in three different fashions

Answer: a

29- Which one of the following nerves is sensory and secretomotor to the parotid gland:

- a. Lesser petrosal nerve.

- b. Glossopharyngeal nerve.
- c. Facial nerve.
- d. Greater petrosal nerve.
- e. Auriculotemporal nerve.

Answer: e

30- Not a portal vein that participates in porto-systemic anastomoses

- a. superior mesenteric vein
- b. superior pancreaticoduodenal veins
- c. azygos vein

Answer: c

31- Wrong about sympathetic chain (question removed)

- a. great splanchnic nerves enter abdomen by piercing the median arcuate ligament

Answer: a

32- What nerve transmits presynaptic fibers to this ganglion (submandibular)

- a. oculomotor
- b. hypoglossal
- c. facial
- d. vagus

Answer: c

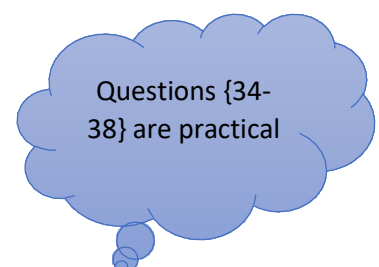
33- What is the type of hernia that exits form this triangle (inguinal triangle)

- a. indirect inguinal hernia
- b. direct inguinal hernia
- c. hiatal hernia

Answer: b

34- splenic artery doesn't supply

- a. pancreas
- b. stomach



c. duodenum

Answer: c

35- VC doesn't drain

- a. duodenum
- b. right suprarenal gland

Answer: a

36- Not posterior to this structure (caecum)

- a. femoral nerve
- b. psoas muscle
- c. quadratus lumborum

Answer: c

37- The pyloric sphincter which one of the following statements is incorrect?

- a. The nerve of laterjet of vagus nerve is responsible of drainage of stomach.
- b. Sphincter is a thickening of the most inner oblique smooth muscle.
- c. It lies on the transpyloric line at the level of first lumber vertebra.
- d. It lies one inch to the right of midline.
- e. Closure of the sphincter by the action of sympathetic fibers.

Answer: b

38- The lesser omentum contains all the following structures EXCEPT:

- a. The left gastric artery.
- b. The hepatic artery.
- c. Common bile duct.
- d. Branches of the vagus nerves.
- e. The right gastroepiploic artery.

Answer: e

39- true about defecation

- a. parasympathetic to intrinsic anal sphincter
- b. parasympathetic to extrinsic anal sphincter
- c. sympathetic to intrinsic anal sphincter
- d. sympathetic to extrinsic anal sphincter

Answer: a

40- wrong about palatine tonsils

- a. blood supply from tonsillar artery from lingual artery
- b. drain to the jugulodigastric node

Answer: a

41- Not medial to sublingual gland

- a. lingual nerve
- b. stylohyoid muscle
- c. submandibular duct

Answer: b

42- Wrong about liver

- a. quadrate lobe drains into right hepatic duct
- b. right lobe is the largest one

Answer: a

43- Wrong about epiploic foramen:

- a. between the greater sac and the lesser sac.
- b. quadrate lobe is superior to it

Answer: b

44- Wrong about tendinous intersection

- a. attach to posterior border of rectus sheath

Answer: a

45- The portal vein receives tributaries from the following organs EXCEPT:

- a. Pancreas.
- b. Liver.
- c. Duodenum.

- d. Stomach.
- e. Spleen.

Answer: b

46- All origins to external muscles of tongue except

- a. pterygoid process
- b. styloid process

Answer: a

47- wrong about blood supply of vermiform appendix:

- a. superior mesenteric artery
- b. inferior mesenteric artery

Answer: b

48- Wrong about posterior relation of duodenum

- a. 3rd part → The right ureter
- b. 4th part → origin of mesentery & superior mesenteric artery

Answer: b

49- Wrong statement about mesentery of small intestine

- a. Contains jejunal and ileal branches of superior mesenteric artery and vein
- b. suspends the small intestine from the posterior abdominal wall
- c. Root of mesentery directed from L1 to right sacroiliac joint
- d. Broad and a fan-shaped

Answer: c

50- Wrong

- a. ligament of Treitz attach to left crus
- b. DJ junction is held in position by the ligament of Treitz

Answer: a

51- What is medial to the hyoglossus muscle

- a. lingual artery
- b. lingual nerve
- c. submandibular duct

d. submandibular ganglion

Answer: a

52- Which one of the following structures is found between the superior and middle constrictor muscles of the pharynx?

- a. stylopharyngeus muscle
- b. internal laryngeal muscle

Answer: a

53- which structure isn't related to the anterior surface of inferior vena cava:

- a. common hepatic duct
- b. right renal artery
- c. gastroduodenal artery

Answer: b

54- Which part of the following is related to 1st part of duodenum

- a. epiploic foramen
- b. right kidney
- c. gallbladder

Answer: a

55- The anal canal, all are true except:

- a. mucous membrane of upper part is sensitive to pain
- b. lower part is sensitive to pain

Answer: a

56- Patient with chronic gastric ulcer, that hadn't responded to medical treatment, at operation the surgeon was found that the posterior wall of the stomach was stuck down in the peritoneum of abd. Wall, the surgeon has to proceed with great care to avoid damaging all the following except:

- a. IVC
- b. Left suprarenal gland
- c. Spleen
- d. Pancreas

Answer: c

57- As a complication of appendicitis abscess may found in the following sites except:

- a. left subphrenic space
- b. right subphrenic space

Answer: a

58- All lie posterior to the first part of duodenum except:

- a. right gastroepiploic artery
- b. IVC
- c. Lesser sac

Answer: a

59- Select the wrong statement concerning the small intestine

- a. superior mesenteric vessels course anterior to third part of duodenum
- b. root of mesentery extends from left side of 2nd lumbar to right sacroiliac joint
- c. Jejunum has complex arterial arcades while ileum has simple arcades
- d. Bile duct and common pancreatic duct has close relation lo 2nd part of duodenum
- e. jejunum and ileum form an elongated mobile intraperitoneal tube

Answer: c

60- All of the following concerning the direct inguinal hernia are true except:

- a. the hernia sac lies lateral to inferior epigastric artery
- b. usually bilateral

Answer: a

61- Liver, all correct except:

- a. tributaries of the hepatic vein are found on the center of the hepatic lobes
- b. caudate lobe drains into the right hepatic branch

- c. liver can reach up to the left intercostal space
- d. ligature of the structures in the free edge of the lesser omentum prevents liver bleeding
- e. hepatocyte do not come into contact with blood sinusoid

Answer: b

62- Appendix, all correct except:

- a. it's a derivative of the midgut
- b. opens into posteromedial aspect of the cecum
- c. lamina propria is rich in lymphatic nodule and crypts of lieberkuhn
- d. its base corresponds to McBurney's point
- e. blood supply from anterior cecal artery through the appendicular artery

Answer: e

63- Duodenum, all correct except:

- a. is retro peritoneal except the first and last inches
- b. first part forms inferior boundary of epiploic foramina
- c. third part is crossed anteriorly by inferior mesenteric vessels
- d. submucosa contains brunner's glands

Answer: c

64- Direct inguinal hernia, all correct except:

- a. hernial sac lies medial to the inferior epigastric artery
- b. common in the old
- c. usually bilateral
- d. the hernial sac never reaches the scrotum
- e. in superficial inguinal ring test, you feel impulse on the tip of your index

Answer: e

65- Concerning the abdomen, all are true except:

- a. the lower 6th intercostal nerves lie between the int. oblique and ext. oblique

Answer: a

66- Peritoneal spaces, all correct except:

- a. right lateral paracolic gutter reaches up to the right subphrenic space
- b. phrenicocolic ligament intervenes between left lateral paracolic gutter and left subphrenic space
- c. right medial paracolic gutter does not reach down to the pelvis
- d. ligament of treitz connects the duodeno jejunal junction with left crus of diaphragm

Answer: d

67- Somone with incontinence that can't control his defecation because problem in anorectal junction, which of the following is damaged

- a. internal anal sphincter
- b. superficial external anal sphincter
- c. deep external anal sphincter
- d. d-subcutaneous external anal sphincter

Answer: c

68- All of the following innervate the pharynx except

- a. external laryngeal
- b. internal laryngeal
- c. glossopharyngeal nerve

Answer: a

69- Not involved in pudenda canal:-

- a. superior rectal vessels
- b. internal pudendal artery
- c. pudendal nerve

Answer: a

70- All of the following are posterior to rectum except

- a. median sacral
- b. internal iliac vein
- c. sympathetic trunk
- d. sacral plexus

Answer: b

71-Stomach, all correct except:

- a. parietal cells show intracellular canaliculi during their activity
- b. cut of the nerves of Latarjet does not impair emptying of the stomach
- c. blood supply is through the branches of celiac trunk only
- d. lesser sac lies between the stomach and pancreas
- e. parietal cells are few in pyloric region

Answer: b

72- WRONG ABOUT IVC

- a. right renal artery is anterior to IVC
- b. left renal vein crosses anterior of aorta
- c. IVC is formed by two common iliac veins in front of common iliac arteries

Answer: a

73- Wrong about anterior abdominal wall:

- a. the intercostal nerve lies between internal oblique and transversus abdominis muscle
- b. below the arcuate line, the posterior wall of rectus sheath is formed **by transversus abdominis fascia**
- c. innervation to the skin just above the symphysis pubis is from iliohypogastric nerve
- d. the rectus sheath contains two epigastric arteries and two muscles
- e. tendinous intersection of rectus abdominis are firmly attached to the anterior wall of rectus sheath

Answer: If choice b was “transversalis fascia” then the answer is c, if not(like above), choose b

74-During surgery for the inguinal hernia in a 24 years Old male patient, choose the wrong statement

- a. division of the ilioinguinal nerve will cause direct inguinal hernia
- b. division of the genital branch of the genitofemoral nerve will cause loss of cremasteric reflex

- c. the artery to vas deferens is part of the spermatic cord
- d. in indirect hernia, the deep inguinal ring is reinforced by conjoint tendon
- e. to get access to the canal, the external oblique aponeurosis should be divided

Answer: d

75- Application of clamp at the free edge of lesser omentum, all of the following are correct EXCEPT

- a. it helps to reduce the bleeding during liver injury
- b. the hepatic artery and portal vein are occluded
- c. the common bile duct but not the common hepatic duct is occluded
- d. it interrupts the blood flow to the stomach
- e. the inferior vena cava is not occluded

Answer: c

76- Which of the following muscles is diagnostic of right hypoglossal nerve injury

- a. intrinsic muscles of the tongue
- b. genioglossus
- c. palatoglossus
- d. Styloglossus
- e. hyoglossus

Answer: b

77- Wrong about abdomen

- a. the ligamentum teres represents obliterated left umbilical vein
- b. the fundus of the gall bladder lies opposite the tip of the right ninth costal cartilage
- c. the left lateral paracolic gutter communicates freely with left subdiaphragmatic space
- d. the ligamentum venosum results from obliteration of the ductus venosus
- e. the ligament of Treitz connect the DJ junction with the right crus of the diaphragm

Answer: c

78- About innervation of the pharynx, choose the wrong statement

- a. Sensory innervations to the oropharynx is by vagus nerve
- b. Sensory innervations to the laryngopharynx is by nerve passes between middle and inferior constrictor muscle
- c. All the muscles innervated by pharyngeal plexus except one
- d. The stylopharyngeus innervated by the glossopharyngeal nerve
- e. Sensory innervation to the nasopharynx is by maxillary nerve

Answer: a

79- In pyloroplasty, what nerve is important for drainage of stomach, and thus preserved during the procedure

- a. anterior and posterior nerves of laterjet
- b. anterior vagal trunk
- c. celiac branch of vagus
- d. sympathetic branch of celiac plexus of nerves
- e. hepatic branch of vagus

Answer: a

80- wrong about greater omentum

- a. between the layers, it contains the greater sac
- b. it has two layers of visceral peritoneum extending from the greater curvature of the stomach and beginning of the duodenum
- c. the two visceral layers also extend to envelop the transverse colon
- d. it contains two gastroepiploic vessels
- e. it is called the policeman of the abdomen

Answer: a

81- All are intraperitoneal structures except

- a. Jejunum
- b. Ileum
- c. Transverse Colon
- d. Second Part of the Duodenum

e. Stomach

Answer: d

82- All the following are supplied by the celiac trunk except:

- a. stomach
- b. the third part of the duodenum
- c. pancreas

Answer: b

83- Innervation of the pylorus

- a. Anterior & posterior latorjet nerves

Answer: a

84- Wrong about defecation process:

- a. intrinsic reflexes are controlled by sympathetic fibres

85- The most common site for the collection of appendicitis abscess:

- a. Morrison's pouch

Answer: a

86- Pancreatic vessels are in which structure:

- a. Splenorenal ligament
- b. Gastrosplenic ligament

Answer: a

87- Wrong about secretomotor innervation of parotid gland?

- a. Pain Sensation through fascial nerve
- b. Nerve supply via otic ganglia

Answer: a

89- A man has portal hypertension what is wrong

- a. Can have hemorrhoids
- b. hematemesis in these patients is caused by esophageal varices
- c. para umbilical make anastomosis with epigastric

- d. anastomoses of right gastric with tributaries of azygous veins occurs at the lower part of esophagus

Answer: d

90-When holding the free edge omentum by a clamp, which is not affected

- a. IVC
- b. bile duct
- c. portal vein
- d. blood flow to stomach

Answer: a

91-If we have a rupture in the penile urethra, the urine will reach all except

- a. thigh to the attachment of fascia late
- b. penis
- c. scrotum (colles facia)
- d. goes upward above umbilicus

Answer: d

92-About bile, which is wrong:

- a. bile has detergent effect.
- b. Bile salts in the bile act as emulsifiers for fat.
- c. form micelles.
- d. All bile secreted is lost in the feces, and replaced by de novo synthesis in liver.

Answer: d

93-All of the following are related to palatine tonsil except:

- a. Fibrous capsule
- b. Internal jugular vein
- c. Superior constrictor muscle of the pharynx
- d. Tonsillar artery
- e. External palatine vein

Answer: b

94-All of the following are found posterior to the first part of the duodenum except

- a. Hepatic artery
- b. Neck of the pancreas
- c. Portal vein
- d. Common bile duct

Answer: b

95-All are true about foramen of Winslow except

- a. Superior: caudate process of caudate lobe of liver
- b. Inferior : 1st part of duodenum
- c. Posterior : portal vein
- d. Anterior: free margin of lesser omentum
- e. For communication between lesser and greater sac

Answer: c

96-Which of the following is not true about pancreas

- a. Superior surface covered by peritoneum from lesser sac
- b. Inferior surface covered by peritoneum from greater sac
- c. Anterior border attached to transverse mesocolon
- d. Posterior surface related to splenic vein
- e. Uncinate process is found between superior mesenteric vessels and aorta

Answer: b

97-About appendix , which is wrong :

- a. Common site is retrocecal
- b. Rare to be associated with gangrene
- c. Supplied by a branch from superior mesenteric artery
- d. Intraperitoneal
- e. Base found at McBurney's point

Answer: b

98-About indirect inguinal hernia , which is wrong :

- a. Commonly unilateral
- b. Common in young

- c. Harnial sac is found lateral to inferior epigastric artery
- d. Caused by injury to ilioinguinal nerve

Answer: d

99-Which of the following is not true about pancreas:

- a. uncinata process is found between aorta and superior mesenteric vessels
- b. splenic artery passes on its superior border
- c. splenic vein pass on its posterior surface
- d. transverse mesocolon attach to its inferior border
- e. the anterior and inferior surfaces are covered by peritoneum

Answer: d

100-An injury to the ilio-inguinal nerve, might be associated with one of these types of hernia:

- a. direct hernia
- b. indirect hernia
- c. lumber hernia
- d. internal hernia
- e. incisional hernia

Answer: a

101-All pertaining to the parotid duct is true except:

- a. one finger breadth above the zygomatic arch
- b. Opens in the oral cavity at the level of the upper second molar teeth
- c. crosses over the masseter and pierces the buccinator muscle

Answer: a

102-Between the hyoglossus and mylohyoid, all correct except

- a. submandibular ganglia
- b. submandibular duct
- c. hypoglossal nerve
- d. deep part of submandibular gland
- e. lingual artery

Answer: e

103-wrong about Meckel's diverticulum:

- a. represents the remains of the vitelline duct
- b. occurs in 2% of subjects
- c. it lies 2 inches from the ileocecal junction
- d. the lining mucosa may contain acid secreting cells
- e. its pain may be confused with pain from appendicitis

Answer: c

104-The wrong statement regarding the Liver and the Gall Bladder

- a. liver is an intraperitoneal organ except three sites
- b. caudate and quadrate lobes are physiologically part of the right lobe
- c. right kidney and its suprarenal gland are related to the visceral surface of the right lobe of the liver
- d. right hepatic artery gives a branch to the gall bladder
- e. fundus of gall bladder located below tip of the right 9th rib

Answer: b

105-Mark the wrong statement regarding the Mouth and Salivary Glands

- a. general sensation from anterior 2/3 of the tongue carried via lingual nerve
- b. posterior third of the tongue drain its lymph in part to jugulodigastric lymph nodes
- c. Palatoglossal arch contains a muscle supplied by the hypoglossal nerve
- d. parotid gland divided into two parts by the facial nerve
- e. submandibular duct courses between mylohyoid and hyoglossus muscles

Answer: c

106-Select the wrong statement concerning the Pharynx and Esophagus

- a. pharynx extends from base of skull to lower border of cricoid cartilage

- b. pharynx supplied mainly by the ascending pharyngeal artery
- c. abdominal esophagus drains its venous blood into inferior vena cava
- d. thoracic esophagus pass through superior and posterior mediastinum
- e. piriform fossa in oropharynx is the common site of foreign body impaction

Answer: e

107-Which match is wrong regarding the anterior abdominal wall?

- a. Tendinous intersections -attached to anterior wall of rectus sheath
- b. conjoint tendon -union of lower arching fibers of internal oblique and transversus abdominis muscles
- c. internal spermatic fascia from fascia transversalis
- d. lower 6 intercostal nerves within rectus sheath
- e. indirect inguinal hernia located medial to inferior epigastric vessels

Answer: e

108-All of the following structures are part of the stomach bed except

- a. pancreas
- b. spleen.
- c. left kidney
- d. celiac trunk
- e. transverse mesocolon

Answer: d

GOOD LUCK EVERYONE :)

Hiba Abu-Hayyah & Samia Simrin & Dania Ayyad

اللَّهُمَّ بَلِّغْ قُلُوبَنَا مِنْهَا وَأَكْرِمْهَا؛ اللَّهُ يَعْذِي هَالْفَتْرَةَ عَلَى خَيْرٍ.