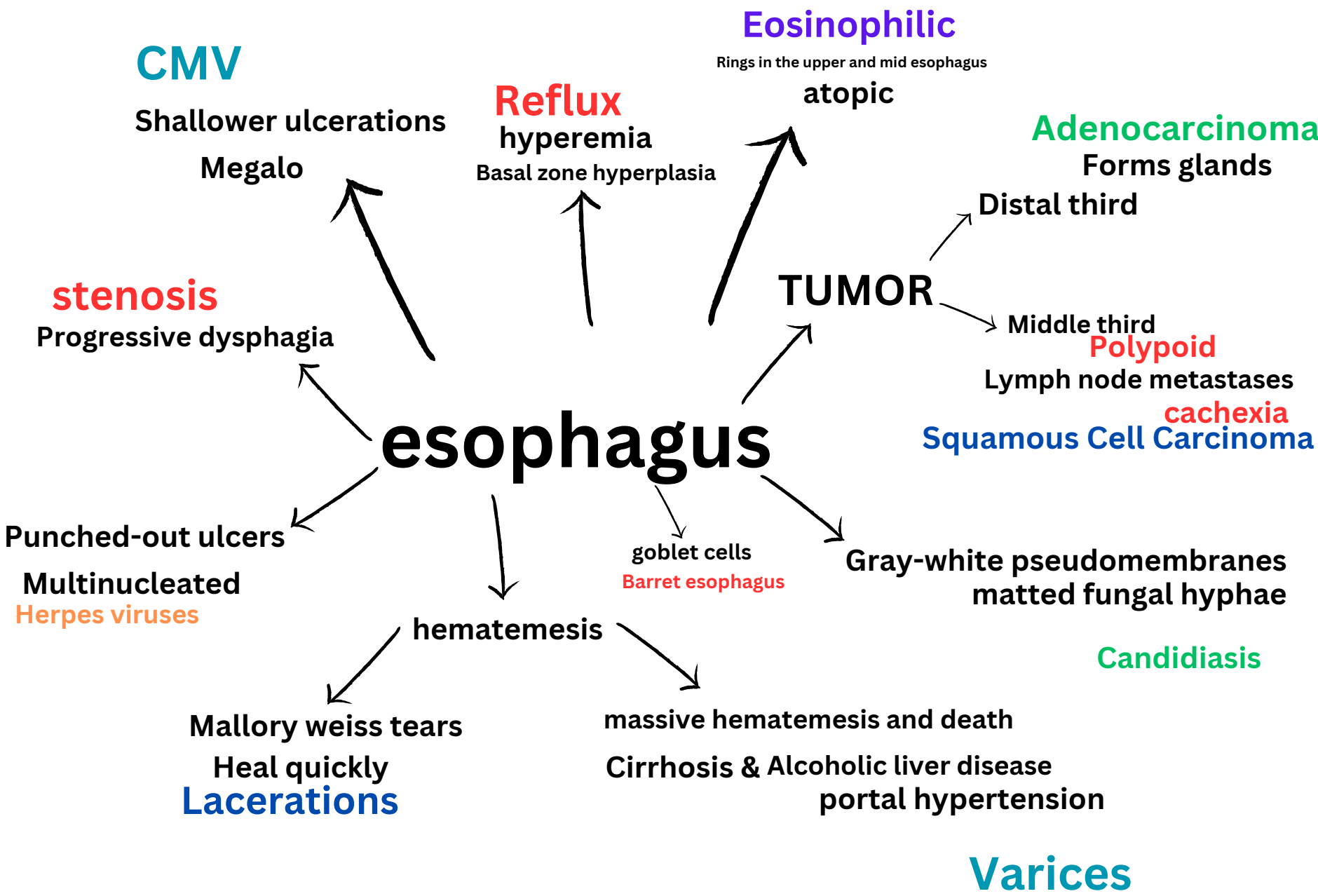

Autoimmune Gastritis

Pernicious anemia

B12 deficiency
pepsinogen I
hypergastrinemia
female predominance

Body macrophages

Younger
signet ring
CDH1
diffuse

H .pylori
Bulky precursor
APC spor- B catenin
intestinal

Adenocarcinoma

stomach

CHRONIC GASTRITIS

H .pylori
triple therapy
Antrum

Acute gastritis

Mucosal injury, neutrophils present
Hyperemia

proximal duodenum

less than 1 cm

Coffee -ground hematemesis

Melena

Curling ulcers

acid hypersecretion

Cushing ulcers

tumor

smooth and clean
release of gastrin

Multiple Granulation

Worse at night

Zollinger-Ellison syndrome

Slower growing

salt and pepper

Cutaneous flushing

right-sided cardiac valvular fibrosis

Carcinoid
appendix

Rectum

rectosigmoid
Aganglionic region
RET

severe in females

Neonatal failure to pass meconium

Hirschsprung Disease

Venous stasis of pregnancy
Constipation

Bleeding

rubber band ligation

Sclerotherapy

Hemorrhoids

Ulcerative Colitis
continuous
Pseudopolyps
Toxic megacolon

Celiac Disease

anti TTG
dermatitis herpetiformis
HLA-DQ2 or HLA-DQ8
steatorrhea
Gluten sensitive

Anemia

Triad

Lactase Deficiency

Osmotic diarrhea

milk

Abetalipoproteinemia

Infants w/ failure to thrive
fat clear cytoplasm

Diarrhea

pancreatic insufficiency

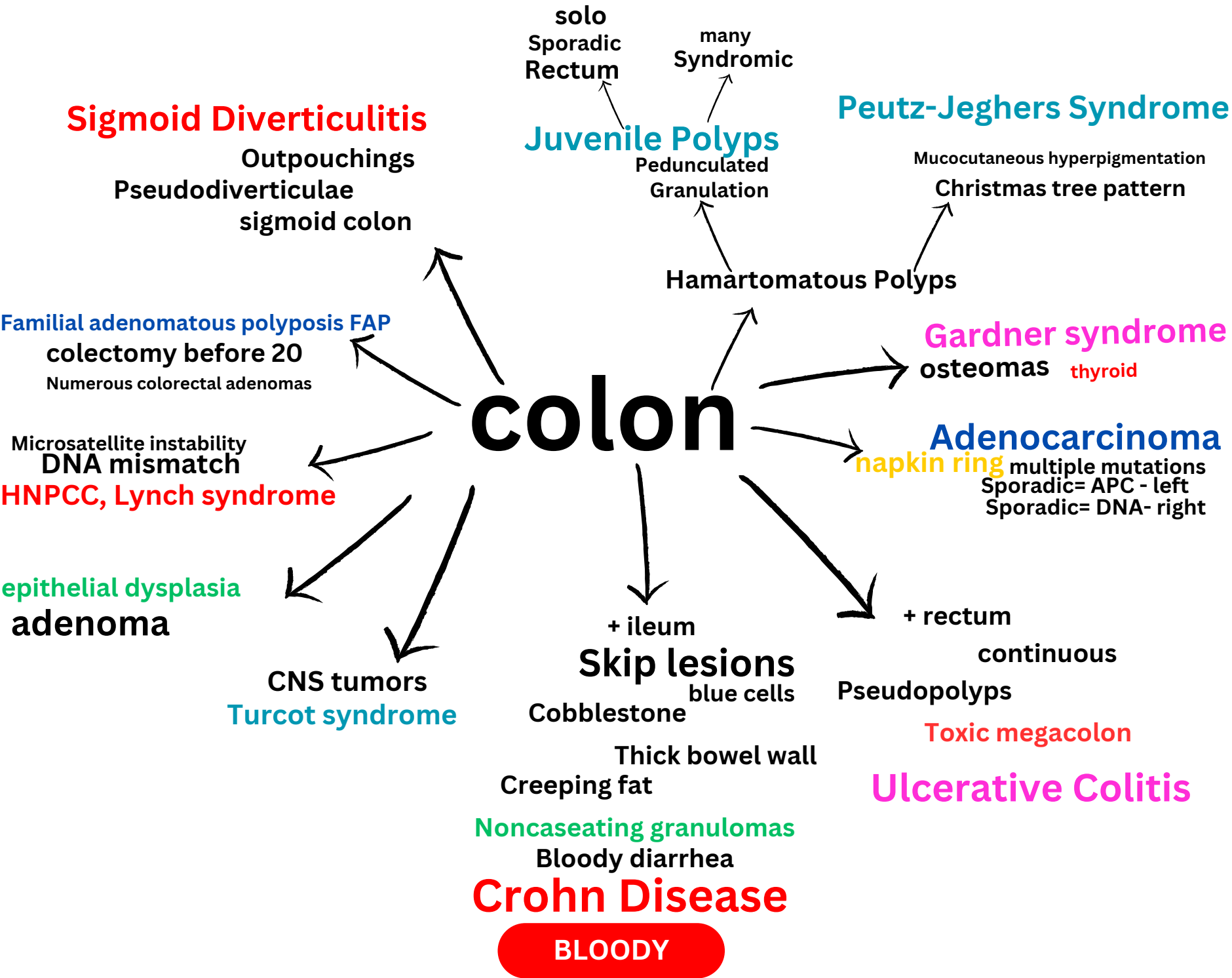
Meconium ileus in neonates

Cystic Fibrosis

steatorrhea
distention Borborygmi

vitamin K & a & b12 & d deficiency

Malabsorptive



appendicitis



necrosis and ulceration
gangrenous




focal abscess
suppurative

TUMOR carcinoid

Distal tip of the appendix

failure to thrive
several days
weight below normal
Abetalipoproteinemia



enlarged abdomen
Meconium ileus in neonates
Cystic Fibrosis



Neonatal failure to pass meconium
first 24 h

Hirschsprung Disease