



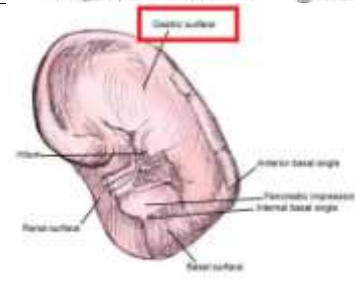
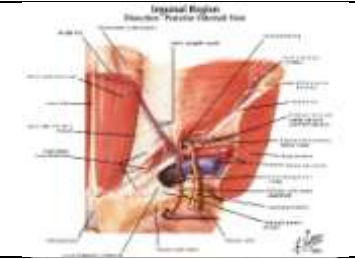
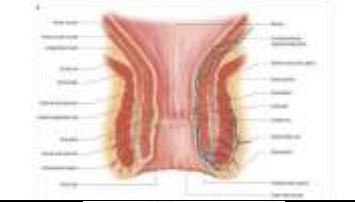

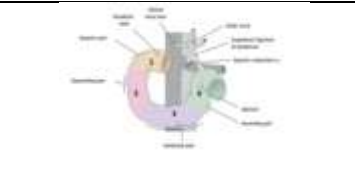


---

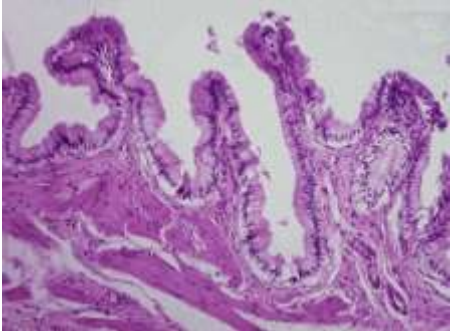
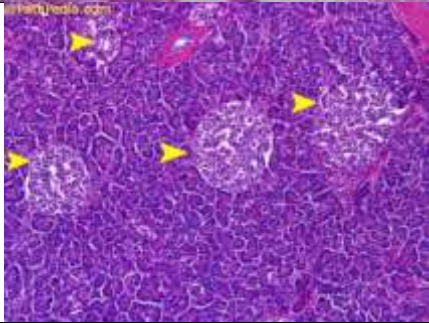
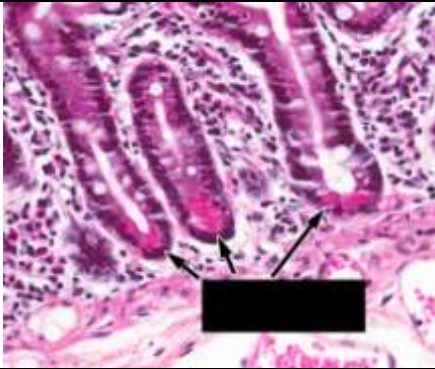

**Done by : Abdullah Nimer**

GI Lab final (second year 2017)

**Anatomy:**

<p>1-Medial to the sublingual gland:</p> <p>Lingual Nerve</p>	
<p>2- Not a paired branch of the Abdominal Aorta:</p> <p>Superior mesenteric artery</p>	
<p>3- Name the pointed impression on spleen:</p> <p>Gastric impression</p>	
<p>4- This structure is lateral to the inguinal ring:</p> <p>Inferior epigastric vessels</p>	
<p>5- The lymphatic drainage from the lower anal ring:</p> <p>Preaortic lymph nodes</p>	
<p>6- one of the following isn't located left to the esophagus:</p> <p>Left main bronchus</p>	
<p>7- related to the 3<sup>rd</sup> part of the duodenum posteriorly:</p> <p>Right ureter</p>	


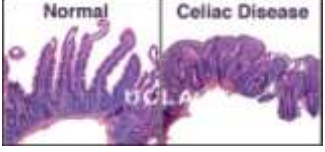
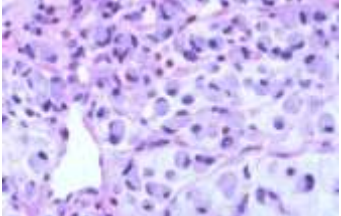
## Histology:

<p>1-This section belongs to:</p> <p>The gall bladder</p>	
<p>2-This section belongs to:</p> <p>The pancreas</p>	
<p>3- The pointed cells are:</p> <p>Paneth cells</p>	
<p>4-This section belongs to:</p> <p>The colon</p>	


**Physiology:**

1- What of the following cause low metabolism rate:	Answer: Malnutrition
---	----------------------

**Pathology:**

1-Wrong about the picture:  This is good prognosis	
2-The disease is:  Celiac disease (because of the antiendomysial bodies)	
3-The disease is:  Diffuse type of gastric carcinoma (signet ring)	

**Microbiology:**

1-The following culture is:  Salmonella (due to the black spots)	
2-The following eggs belong to:  Trichrius trichura	