

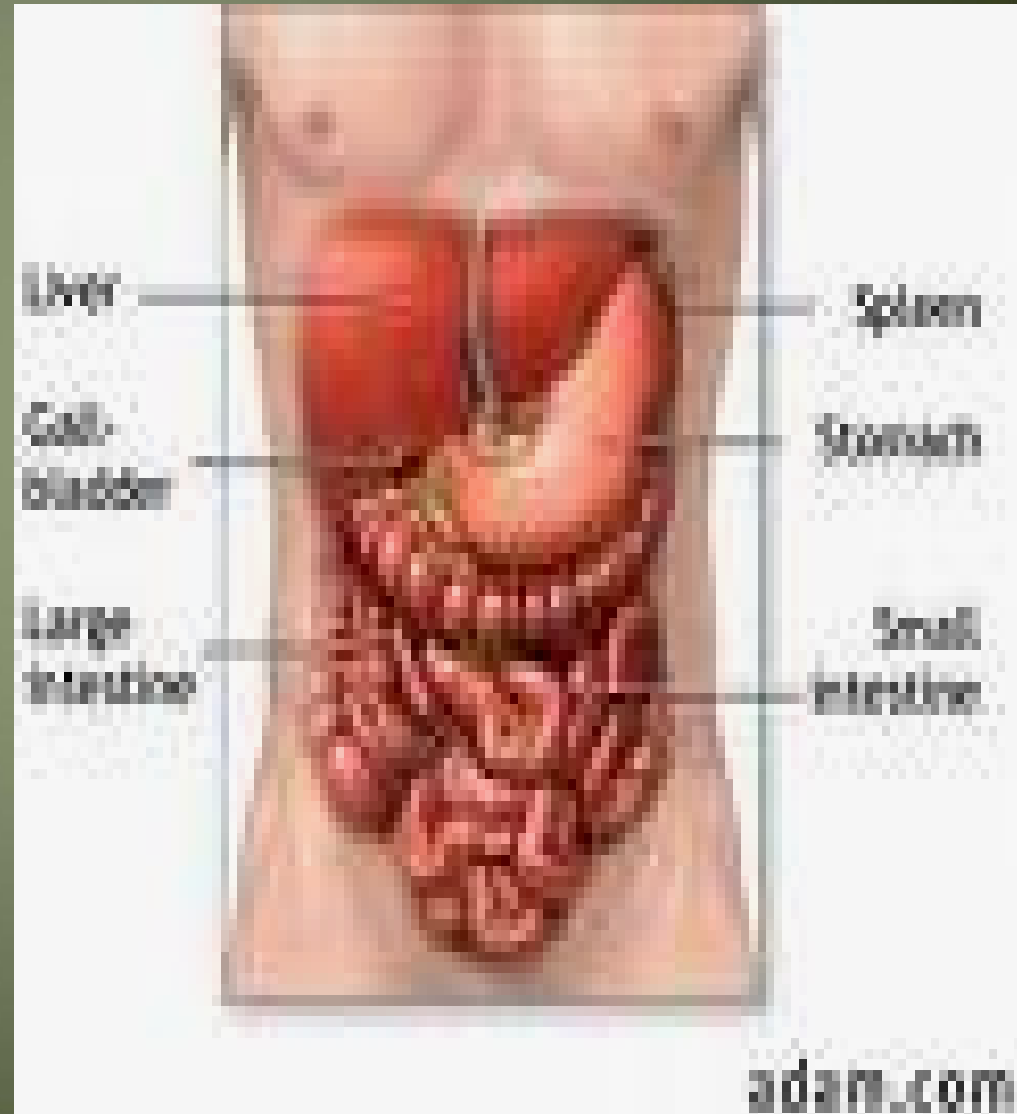
Liver & Gallbladder

Liver

- The liver is the largest gland in the body and has a wide variety of functions
- Weight: $\frac{1}{50}$ of body weight in adult & $\frac{1}{20}$ of body weight in infant
- It is exocrine(bile) & endocrine organ(Albumen , prothrombin & fibrinogen)
- Function of the liver
 - Secretion of bile & bile salt
 - Metabolism of carbohydrate, fat and protein
 - Formation of heparin & anticoagulant substances
 - Detoxication
 - Storage of glycogen and vitamins
 - Activation of vita .D

Location ...

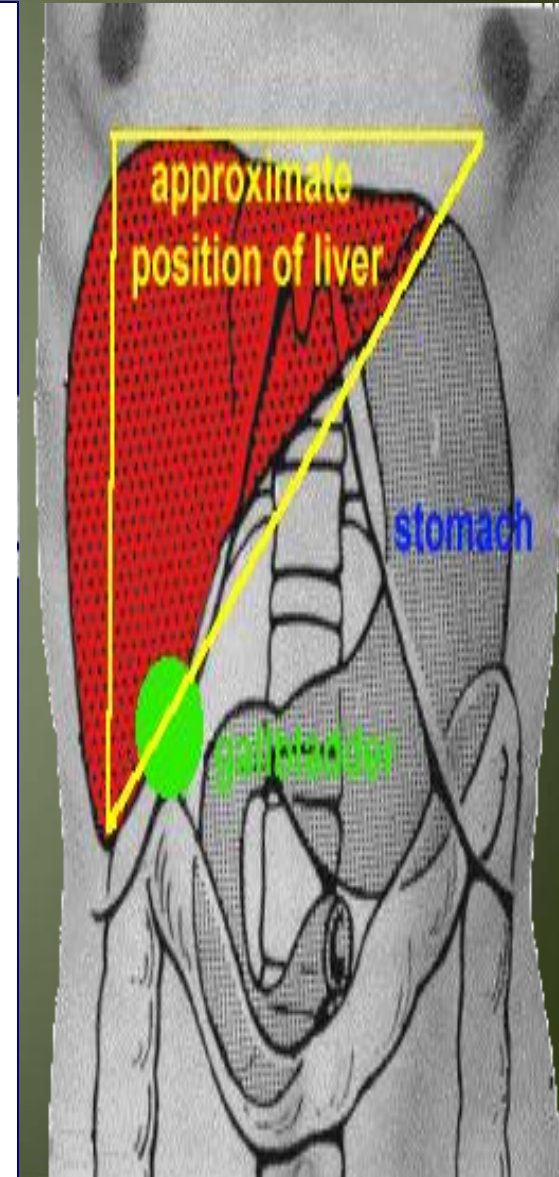
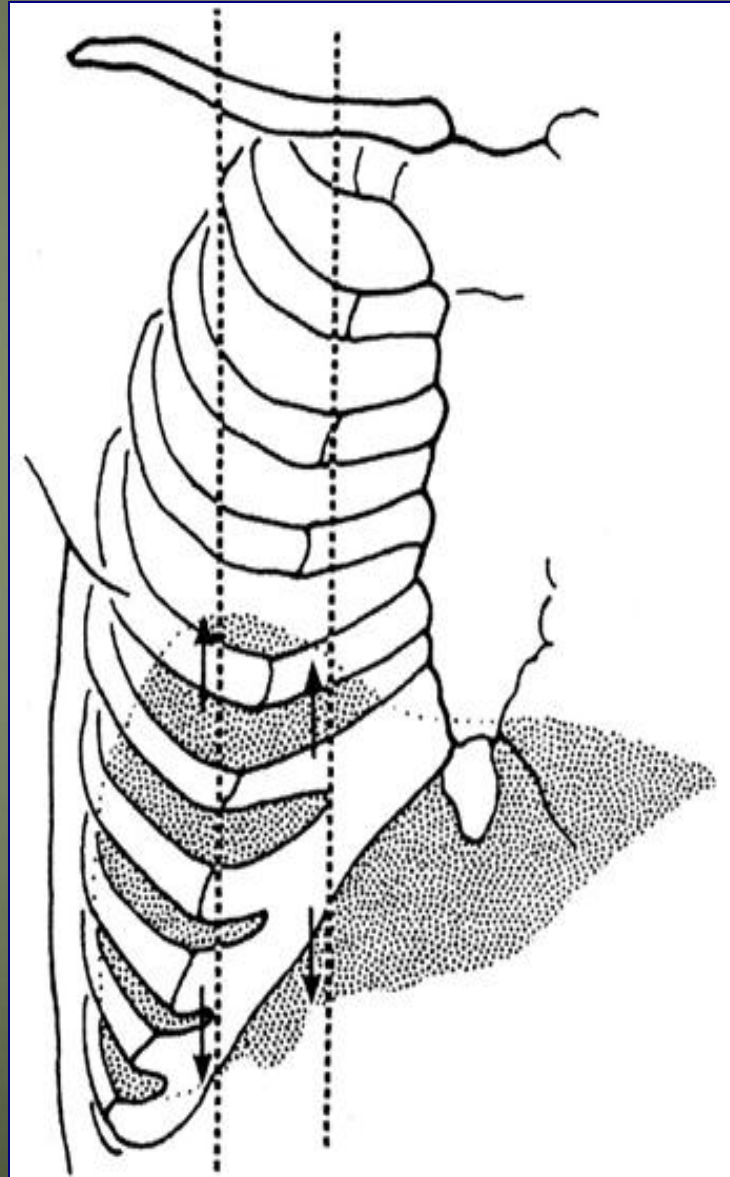
- Occupies right hypochondrium + epigastrium & extends to left hypochondrium



Surface anatomy of the liver

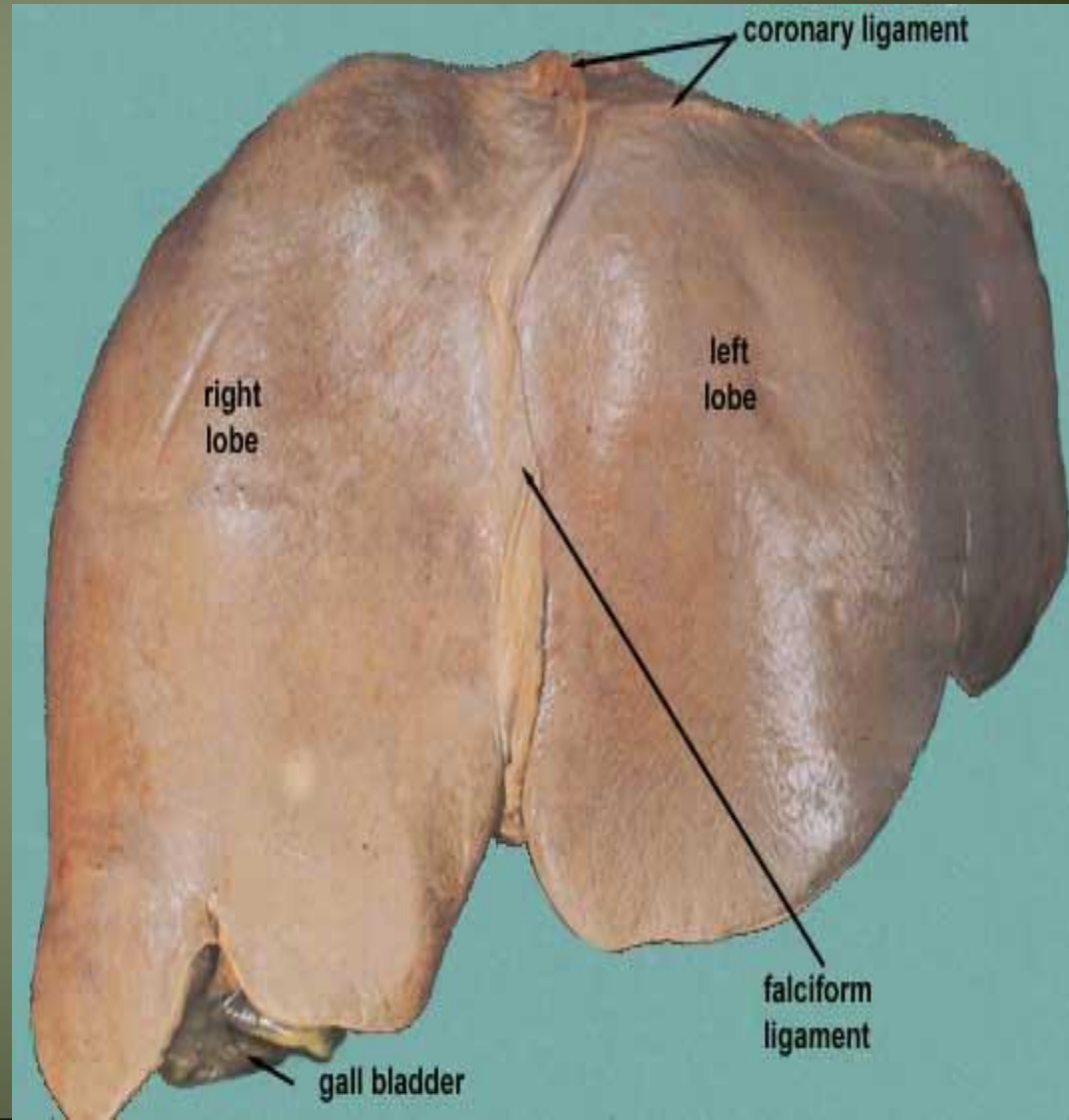
-The greater part of the liver is situated under cover of the right costal margin

- Diaphragm separates it from the pleura, lungs, pericardium, and heart.



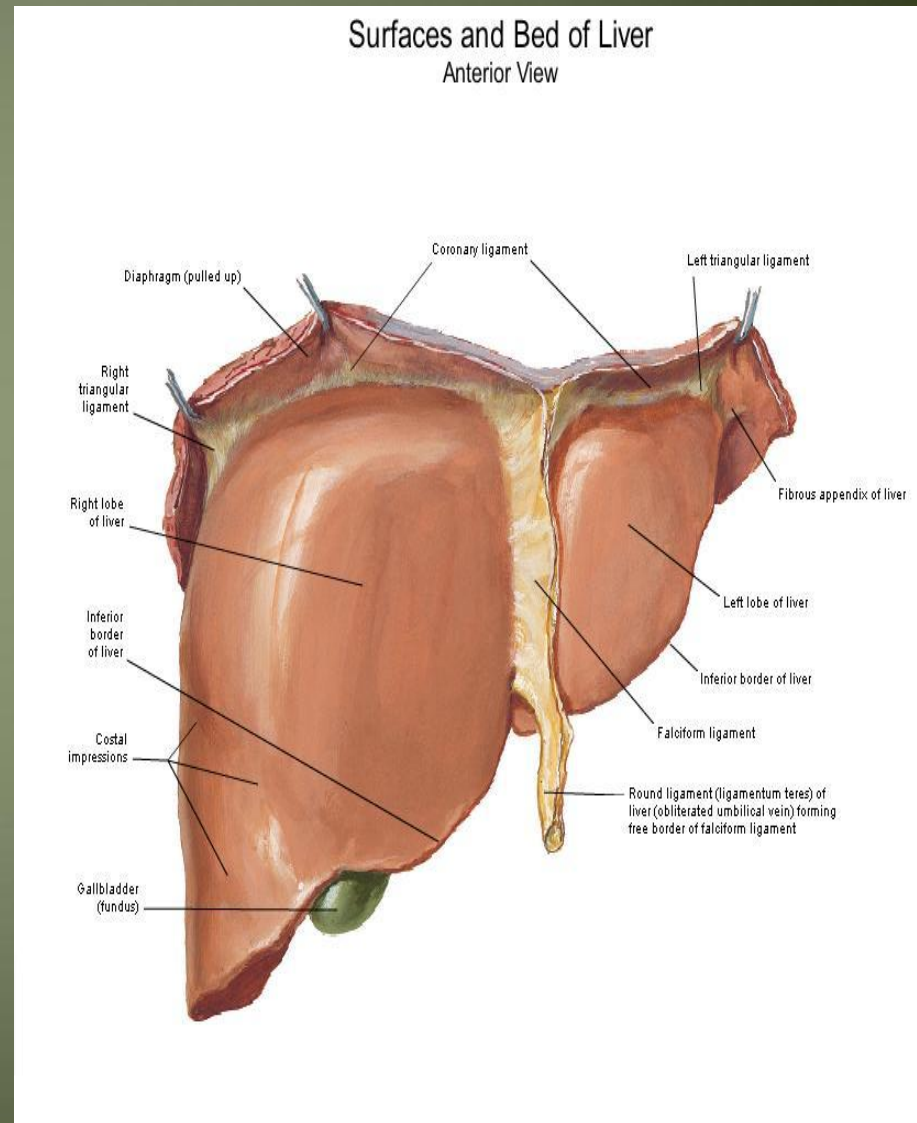
Ant. View of the liver

- Right lobe
- Cut edge of the Falciform ligament
left lobe
- Diverging cut edges of the superior part of the coronary ligament
- Fundus of the gall bladder



Surfaces of the liver, their relations & impressions

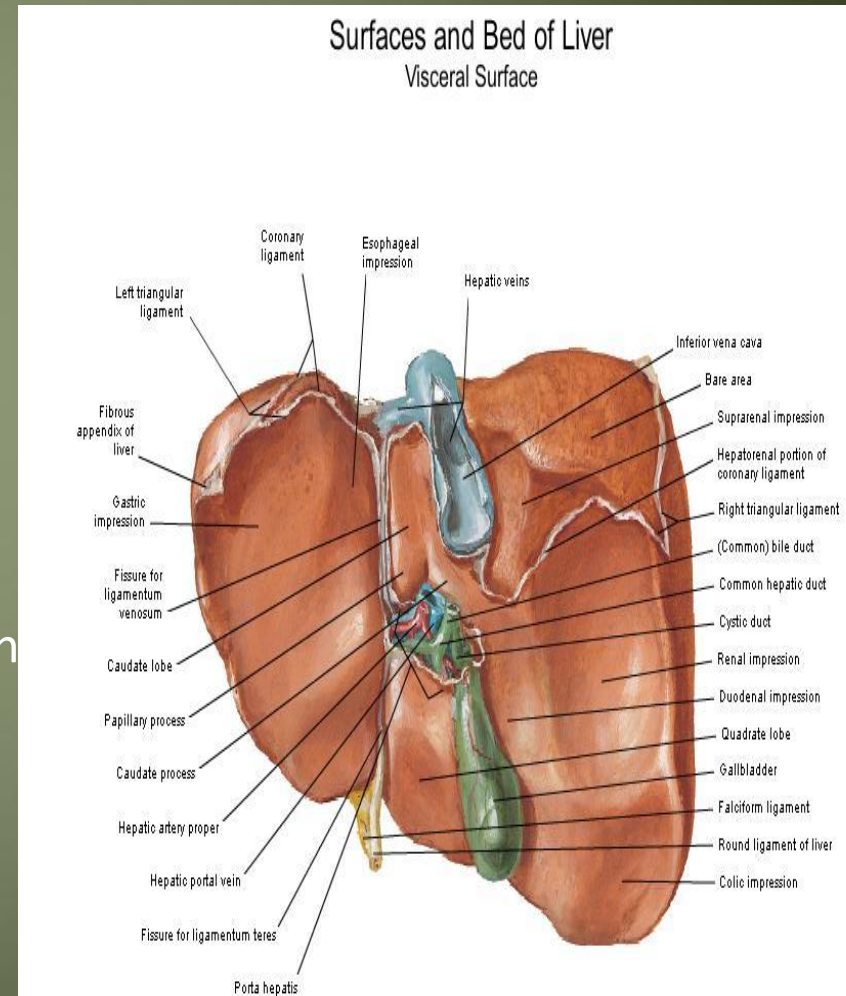
- Postero - inferior surface= visceral surface
- Superior surface = Diaphragmatic surface
- Anterior surface
- Posterior surface
- Right surface



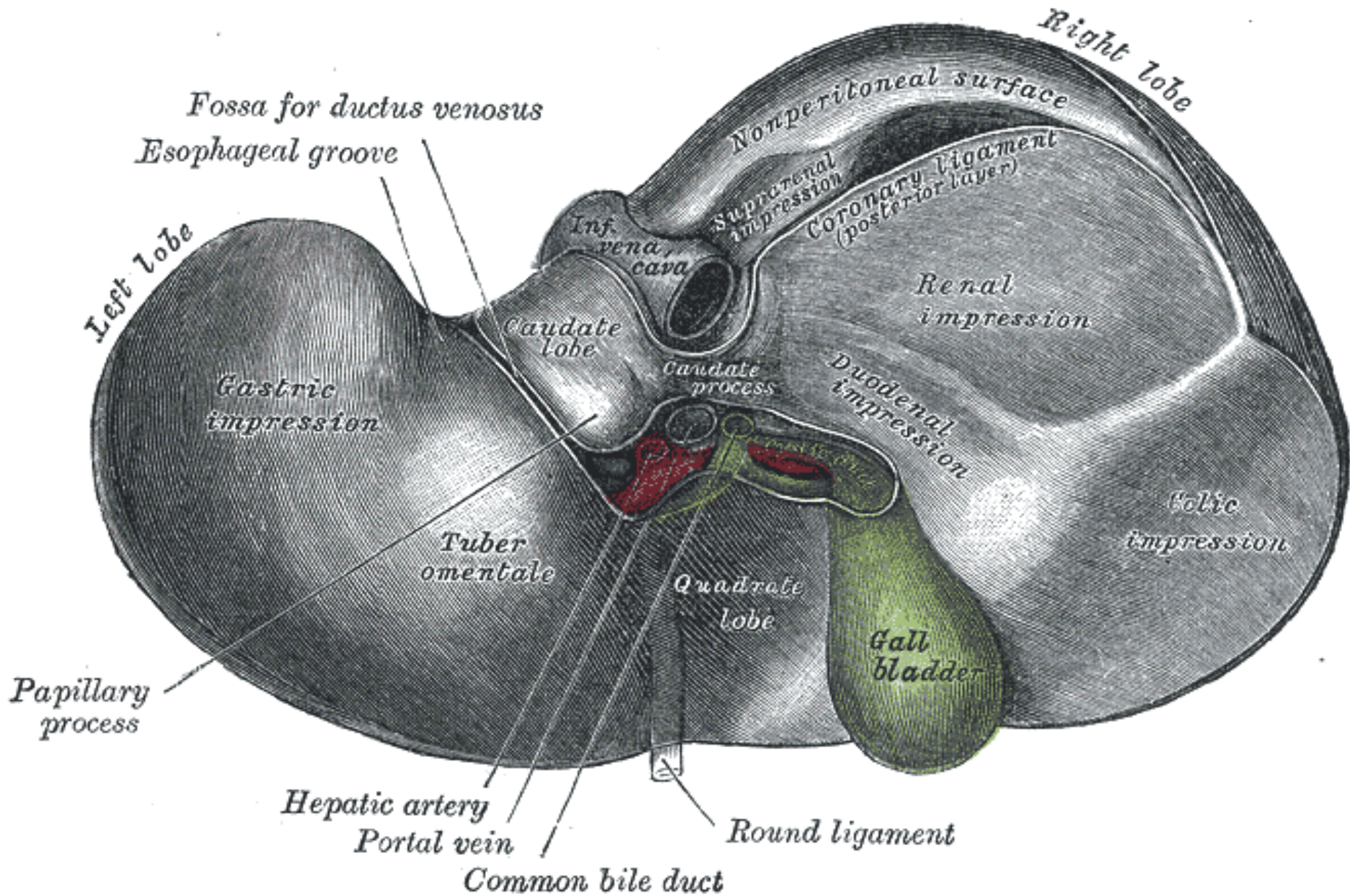
Postero- infero surface= visceral surface

Relations

- I.V.C
- the esophagus
- the stomach
- the duodenum
- the right colic flexure
- the right kidney
- Rt. Suprarenal gland
- the gallbladder.
- Porta hepatic(bile duct,H.a.H.V)
- Fissure for lig. Venoosum & lesser omen
- Tubular omentum
- Lig.teres

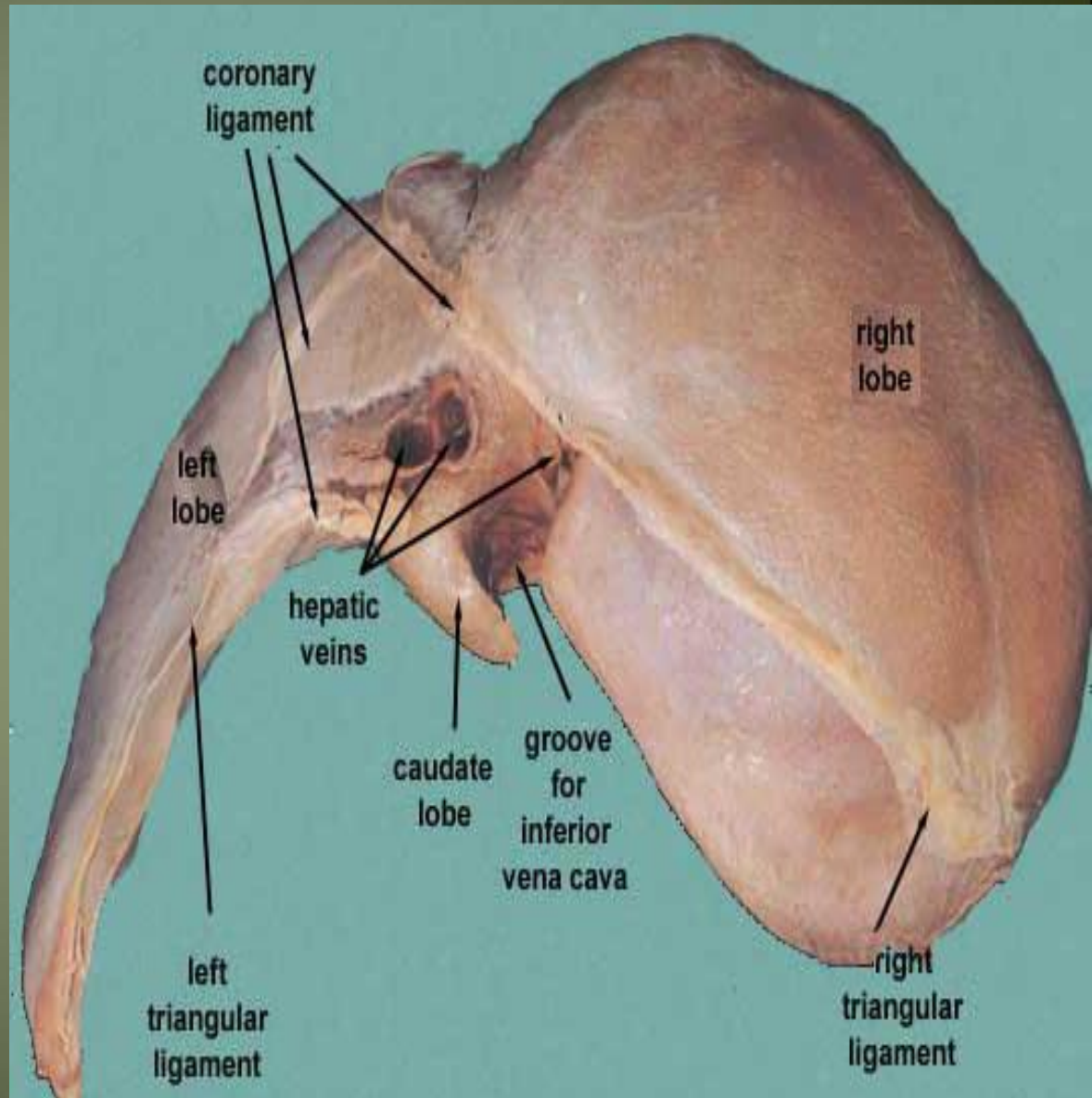


Postero-inferior surface of the liver



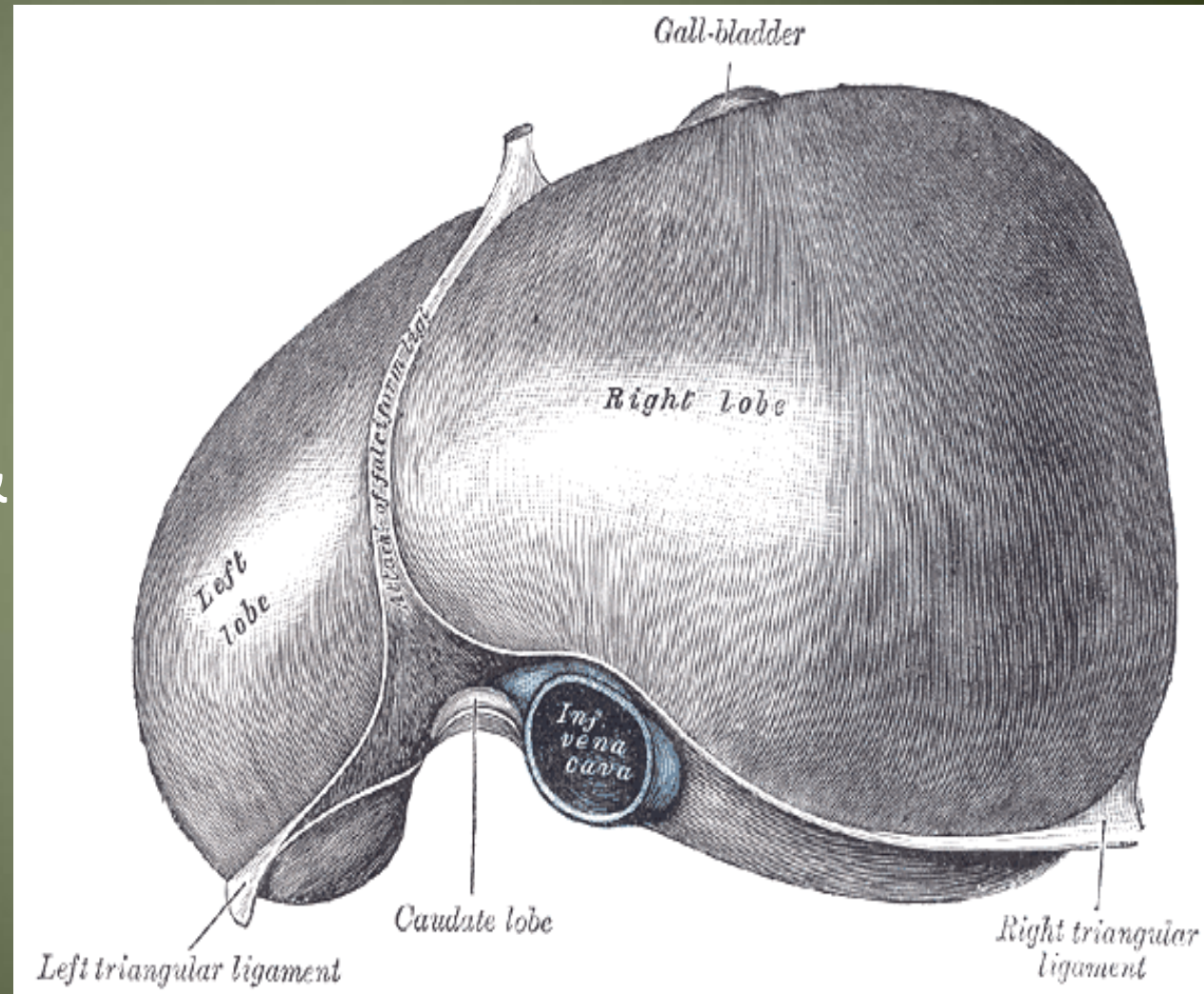
Sup. Surface of the liver

- Right & left lobes
- Cut edge of the Falciform ligament
- The cut edges of the superior and inferior parts of the coronary ligament
- The left triangular ligament
- The right triangular ligament
- Bare area of the liver (where there is no peritoneum covering the liver)
- Groove for the inferior vena cava and the hepatic veins
- Caudate lobe of the liver more or less wrapping around the groove of the inferior vena cava
- Fundus of gall bladder
- Lig.teres



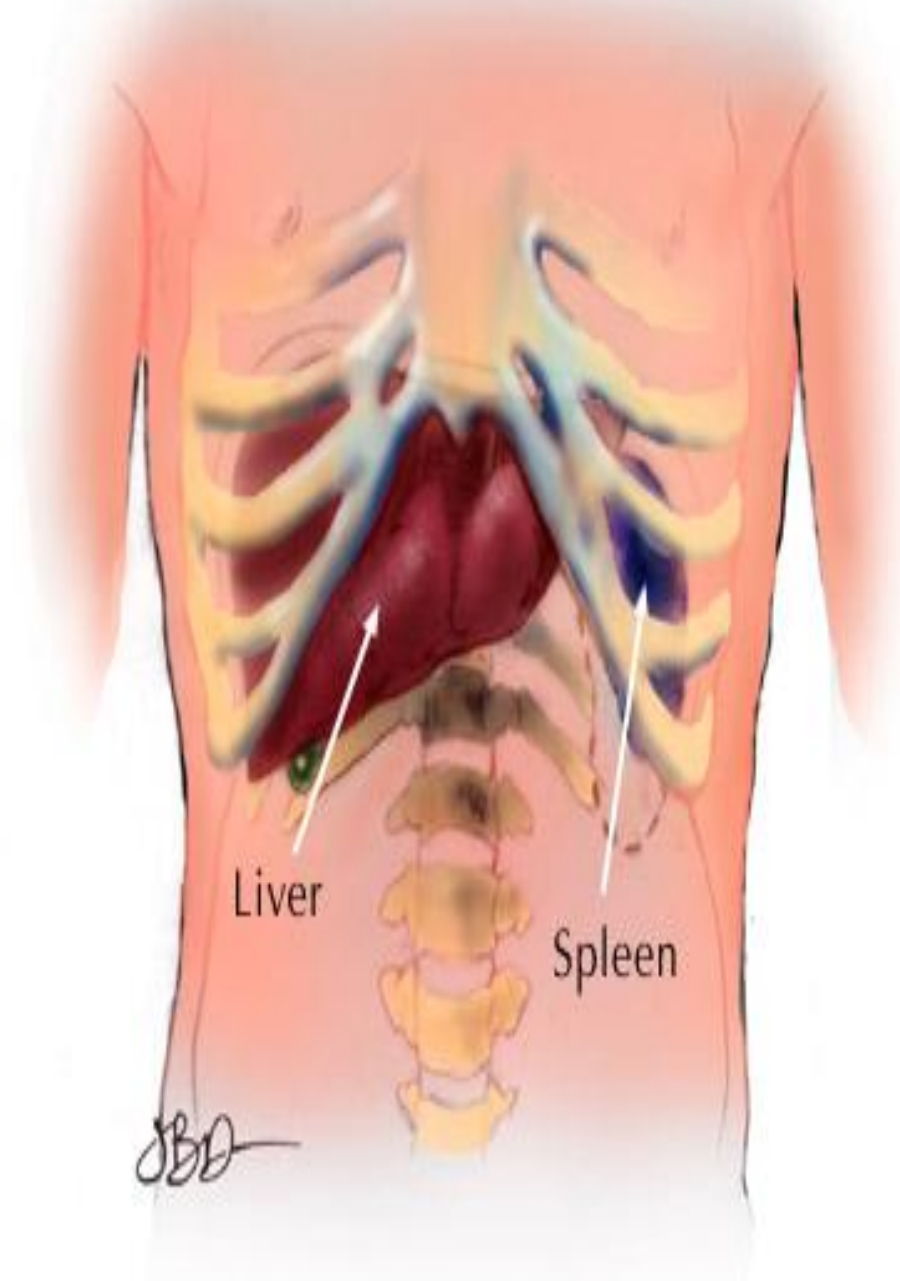
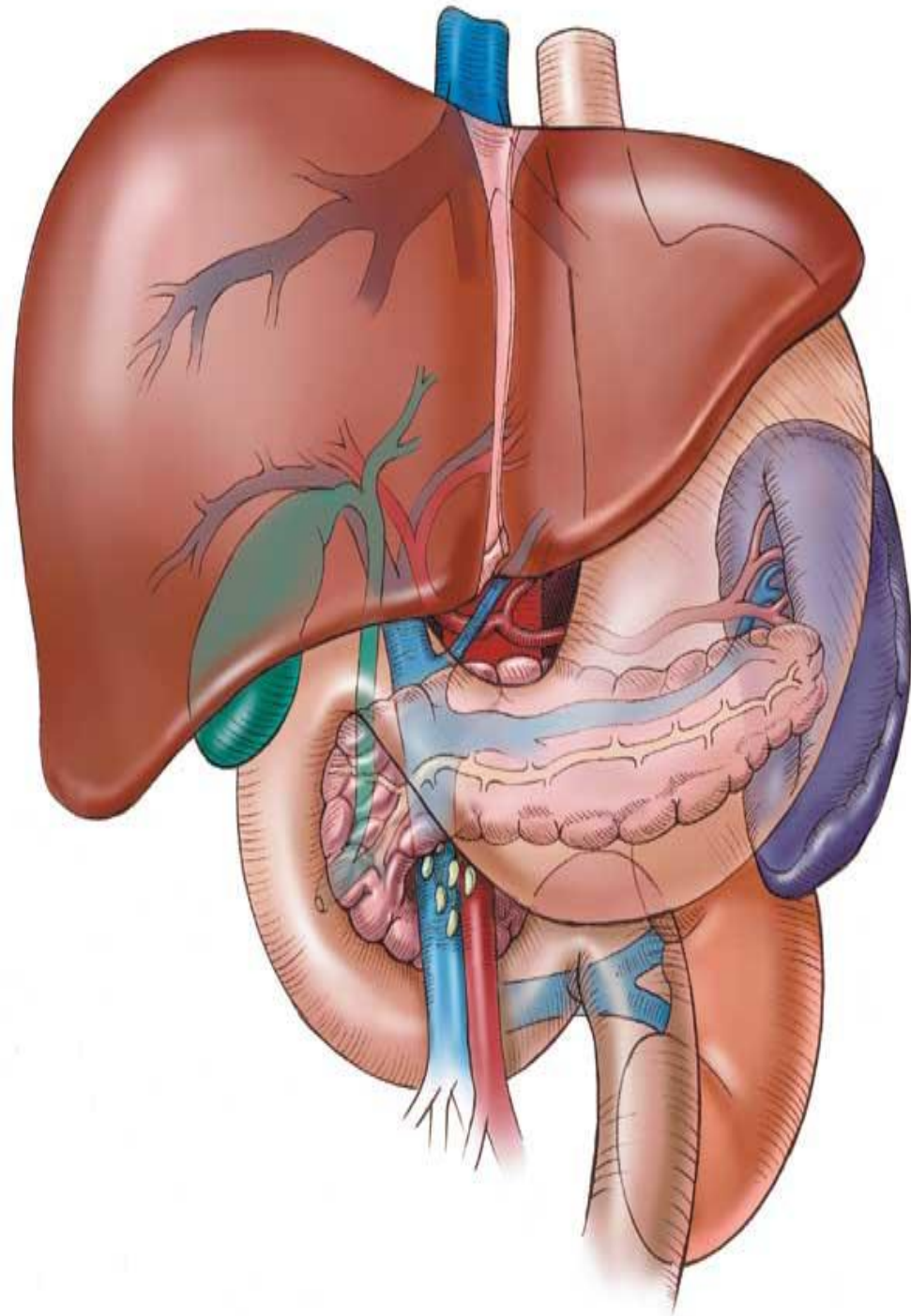
Relations of Sup . surface of liver

- Diaphragm
- Pleura & lung
- Pericardium & heart



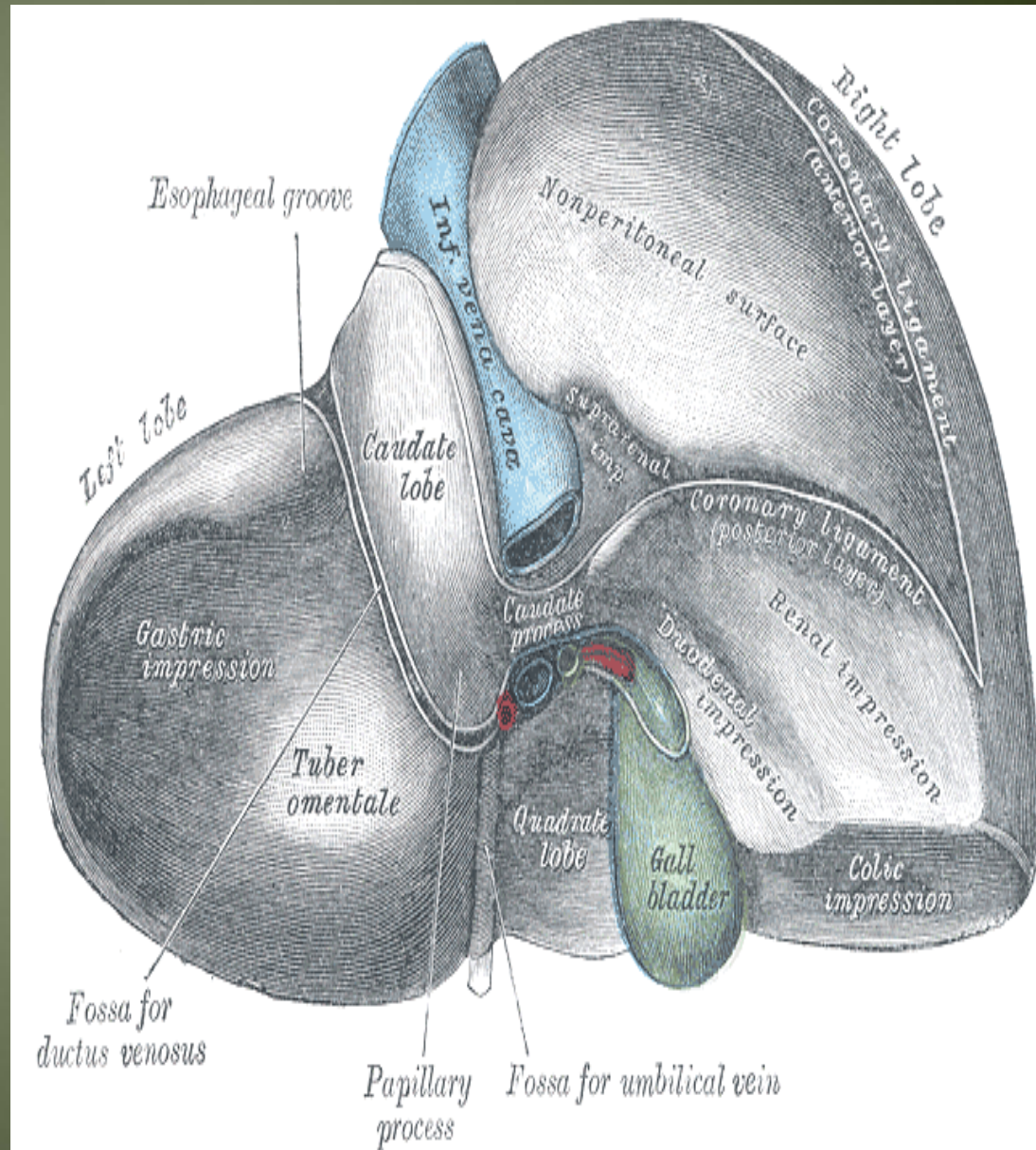
Relations of the liver Anteriorly

- Diaphragm
- Rt & Lt pleura and lung
- Costal cartilage
- Xiphoid process
- Ant. abdominal wall



Posterior relation of the liver

- Diaphragm
- Rt. Kidney
- Supra renal gland
- T.colon(hepatic flexure)
- Duodenum
- Gall bladder
- I.V.C
- Esophagus
- Fundus of stomach

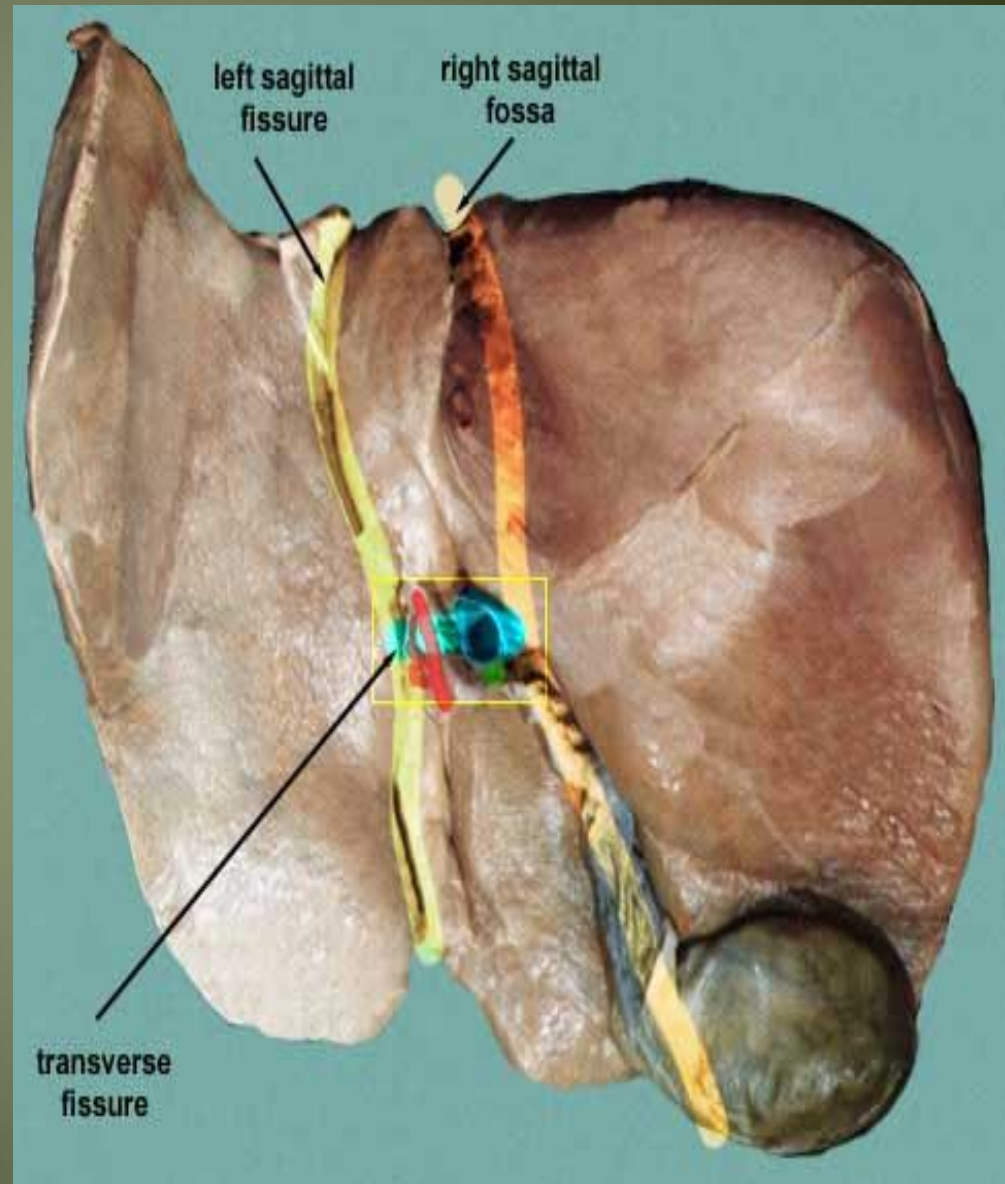


Lobes of the liver

- Rt. Lobe
- Lt .lobe
- Quadrate lobe
- Caudate lobe

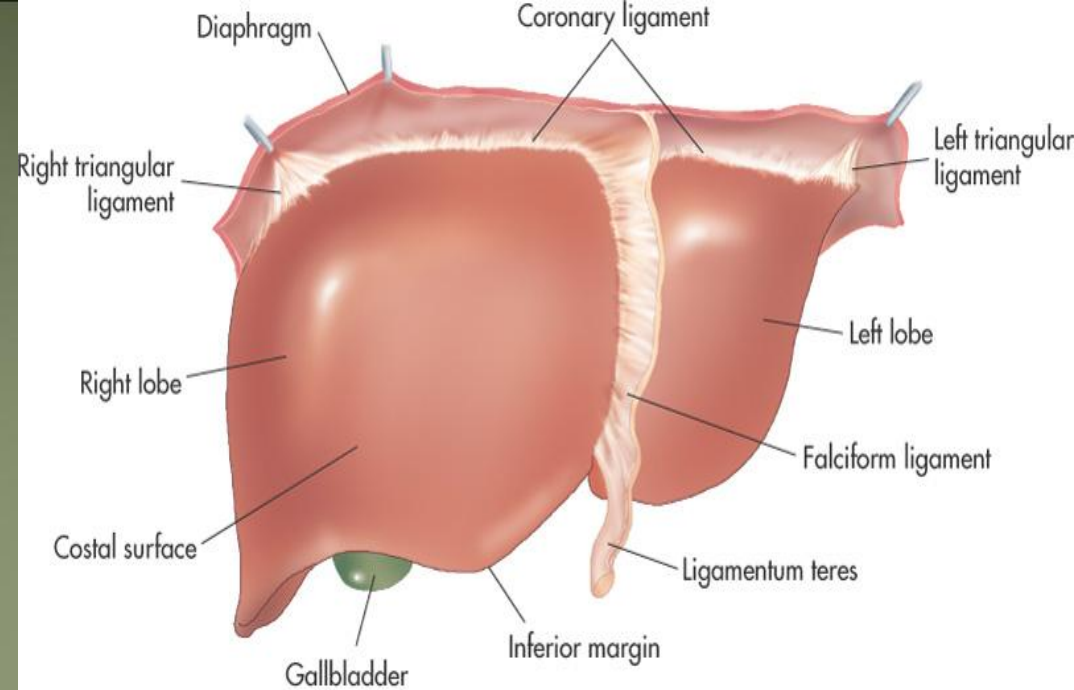
Separation of the four lobes of the liver:

- Right sagittal fossa - groove for inferior vena cava and gall bladder
- left sagittal fissure - contains the Ligamentum Venosum and round ligament of liver
- Transverse fissure (also porta hepatis) - bile ducts, portal vein, hepatic arteries

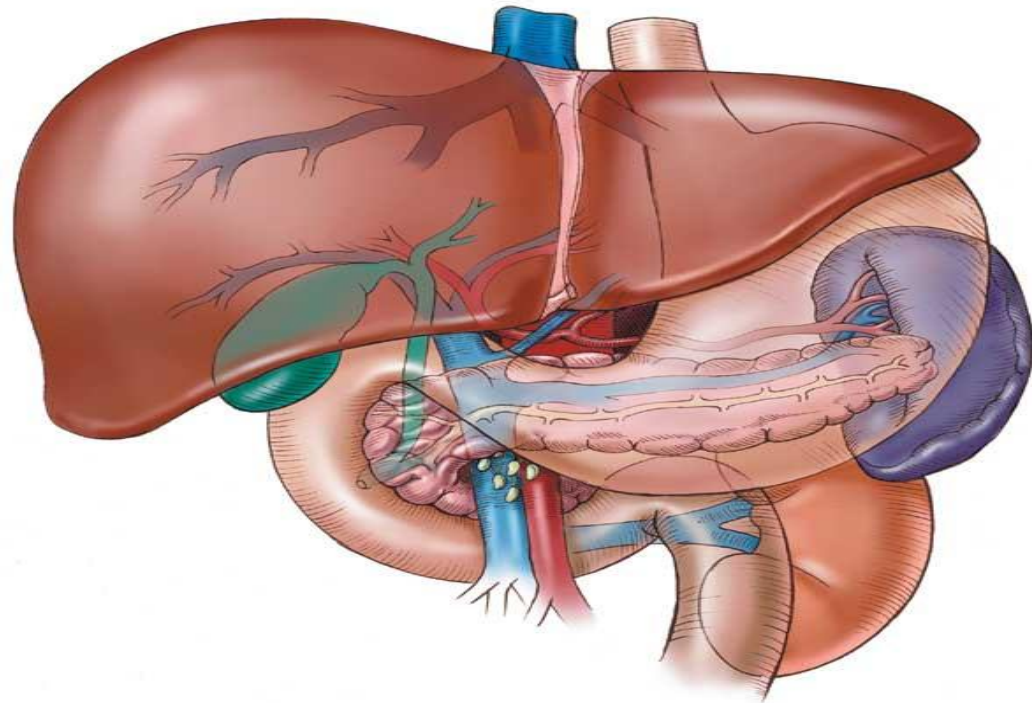


Rt. Lobe

- Largest lobe
- Occupies the right hypochondrium
- Divided into anterior and posterior sections by the right hepatic vein
- Reidel's Lobe extend as far caudally as the iliac crest

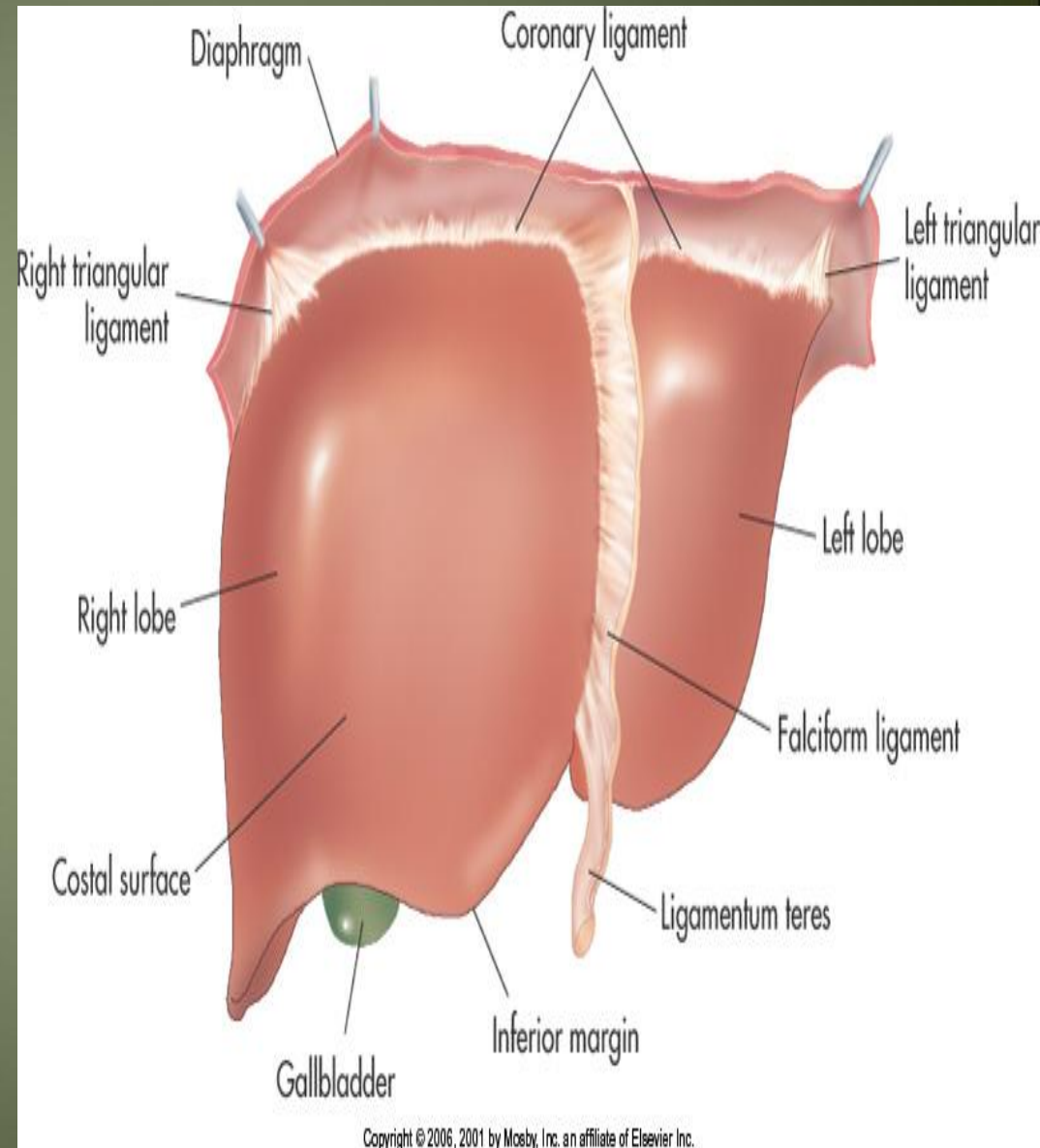


Copyright © 2006, 2001 by Mosby, Inc. an affiliate of Elsevier Inc.



Left Lobe

- Varied in size
- Lies in the epigastric and left hypochondriac regions
- Divided into lateral and medial segments by the left hepatic vein



Lobes of the liver....cont

Rt. & Lt lobe separated by

- Falciform ligament
- Ligamentum Venosum
- Ligamentum teres

Caudate Lobe

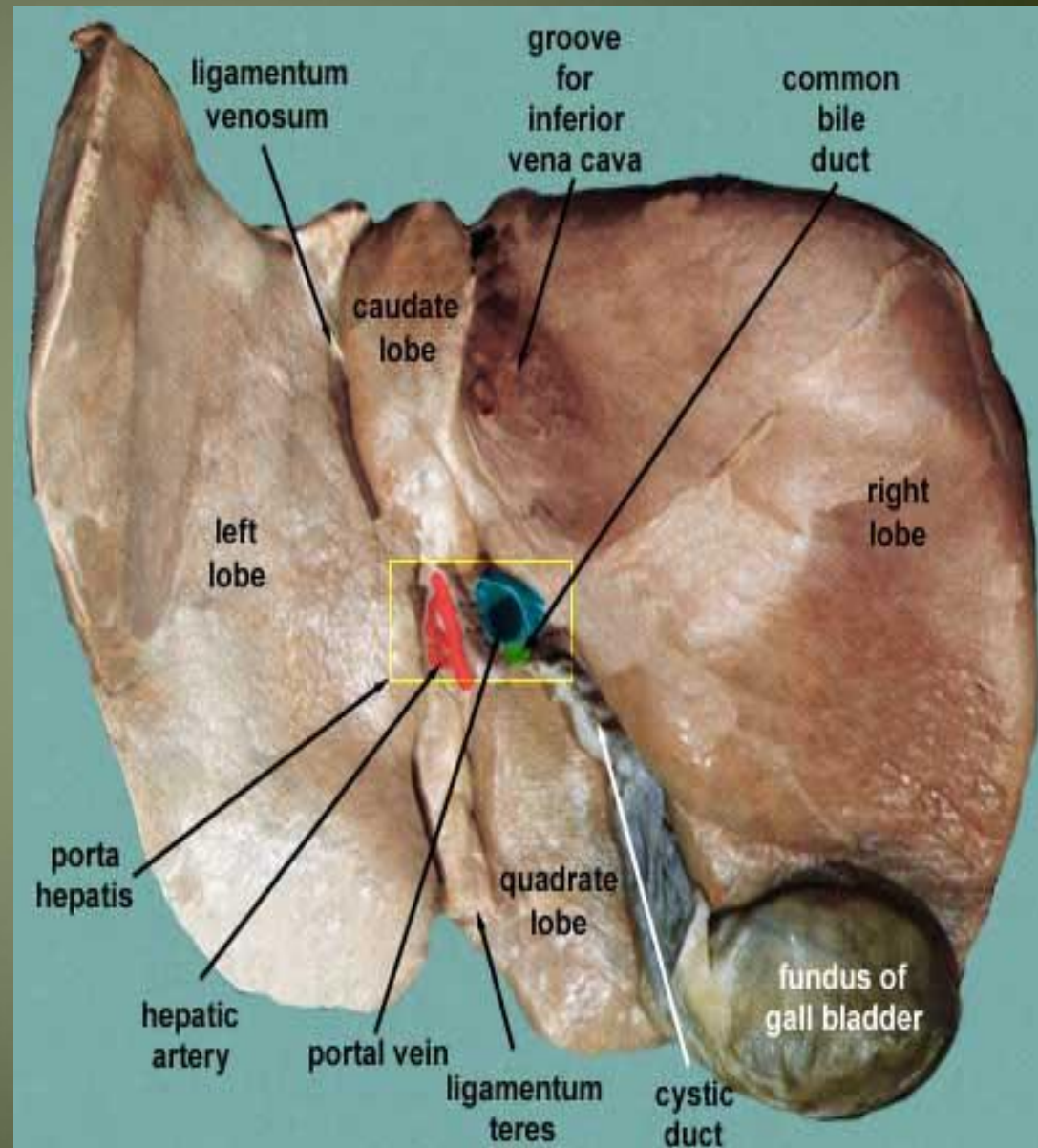
-present in the posterior surface from the Rt. Lobe

Two processes

- 1- c- process
- 2- papillary process

Relations of caudate lobe

- Inf. → the porta hepatis
- The right → the fossa for the inferior vena cava
- The left → the fossa for the lig.venosum.

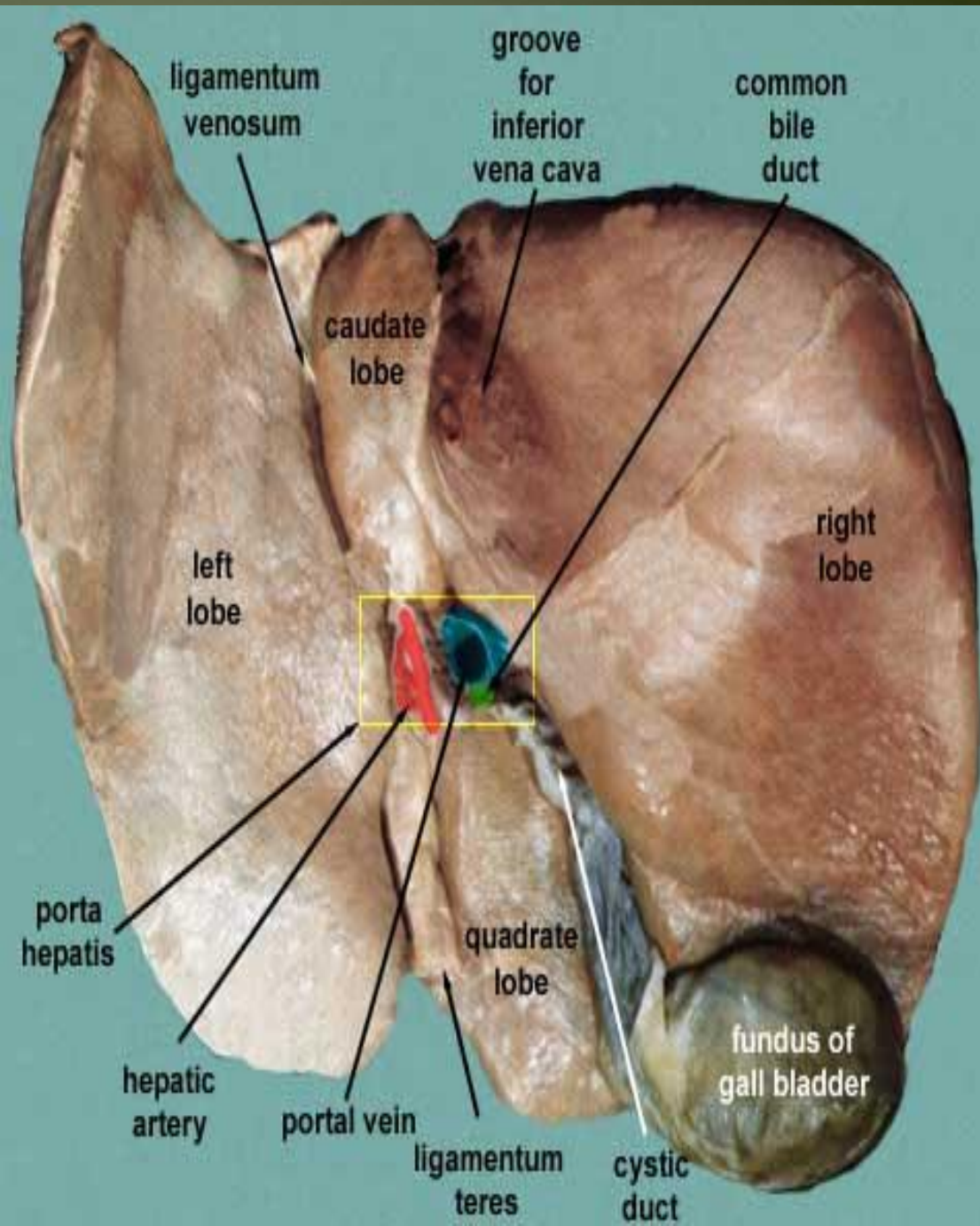


Quadrato lobe

Present on the inferior surface from the Rt. Lobe

Relation

- Ant. → anterior margin of the liver
- Sup. → porta hepatis
- Rt. → fossa for the gallbladder
- Lt → by the fossa for lig.teres

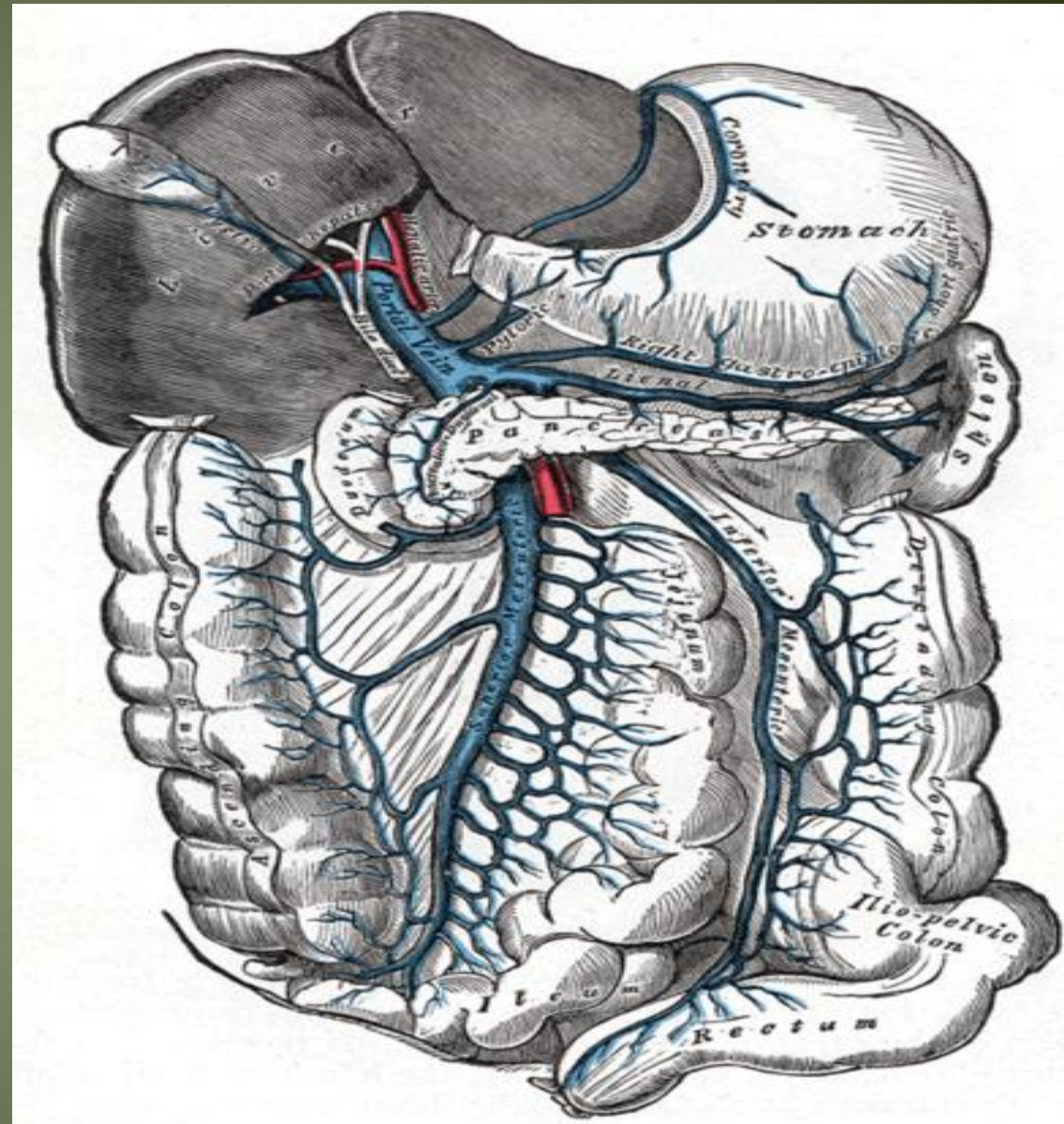


Porta hepatis

- It is the hilum of the liver
- It is found on the posteroinferior surface
- lies between the caudate and quadrate lobes
- Lesser omentum attach to its margin

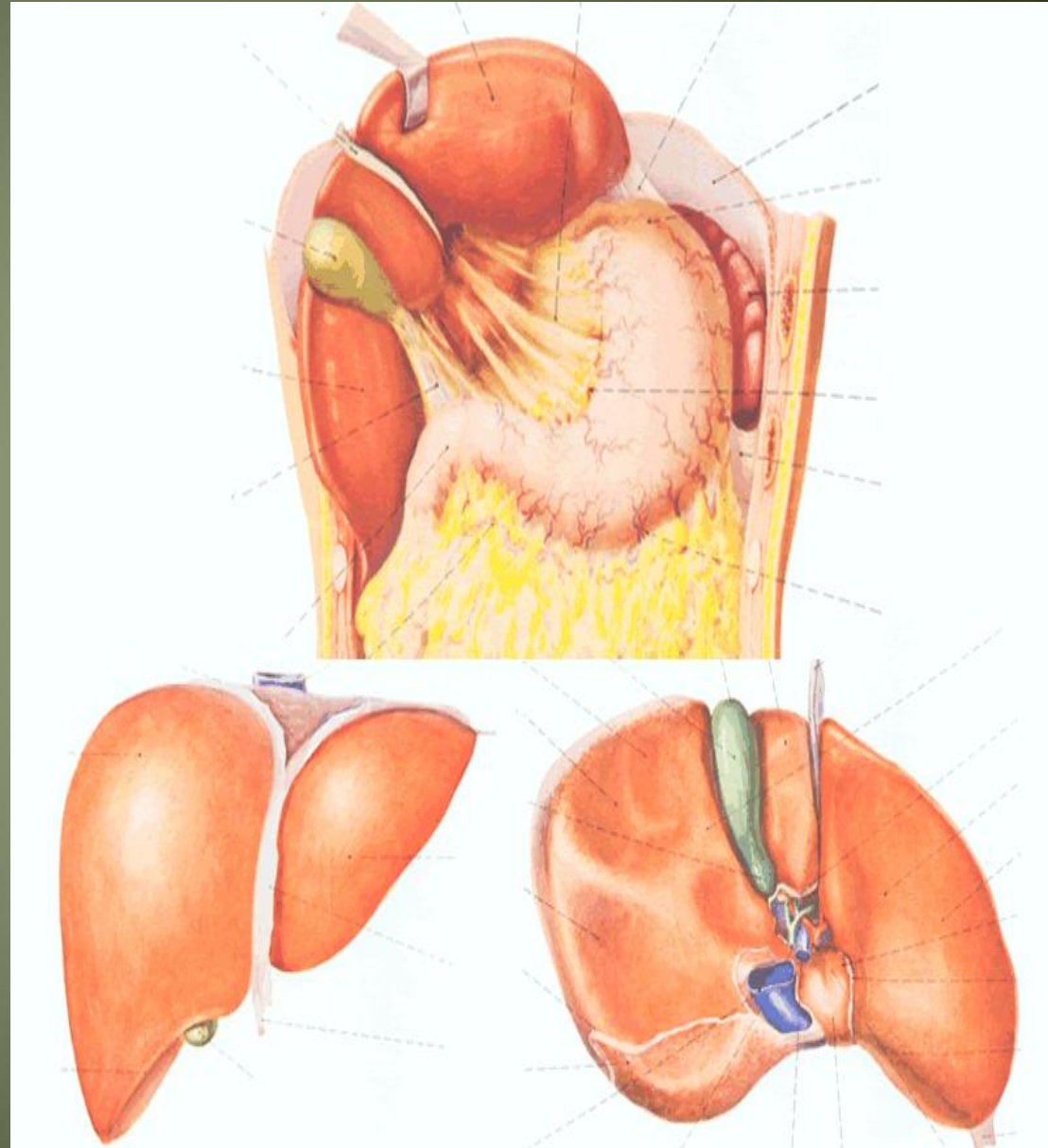
Contents

- Gallbladder → ant.
- Hepatic. Art + nerve+ lymphatic node → middle.
- Portal vein → post.



Peritoneum of the liver

- The liver is covered by peritoneum (intraperitoneal organ) except at bare area (it is origin from septum transversum)
- Inferior surface covered with peritoneum of greater sac except porta hepatis, G.B & Lig.teres fissure
- Rt. Lateral surface covered by peritoneum, related to diaphragm which separate it from Rt. Pleura , lung and the Rt Ribs (6-11)

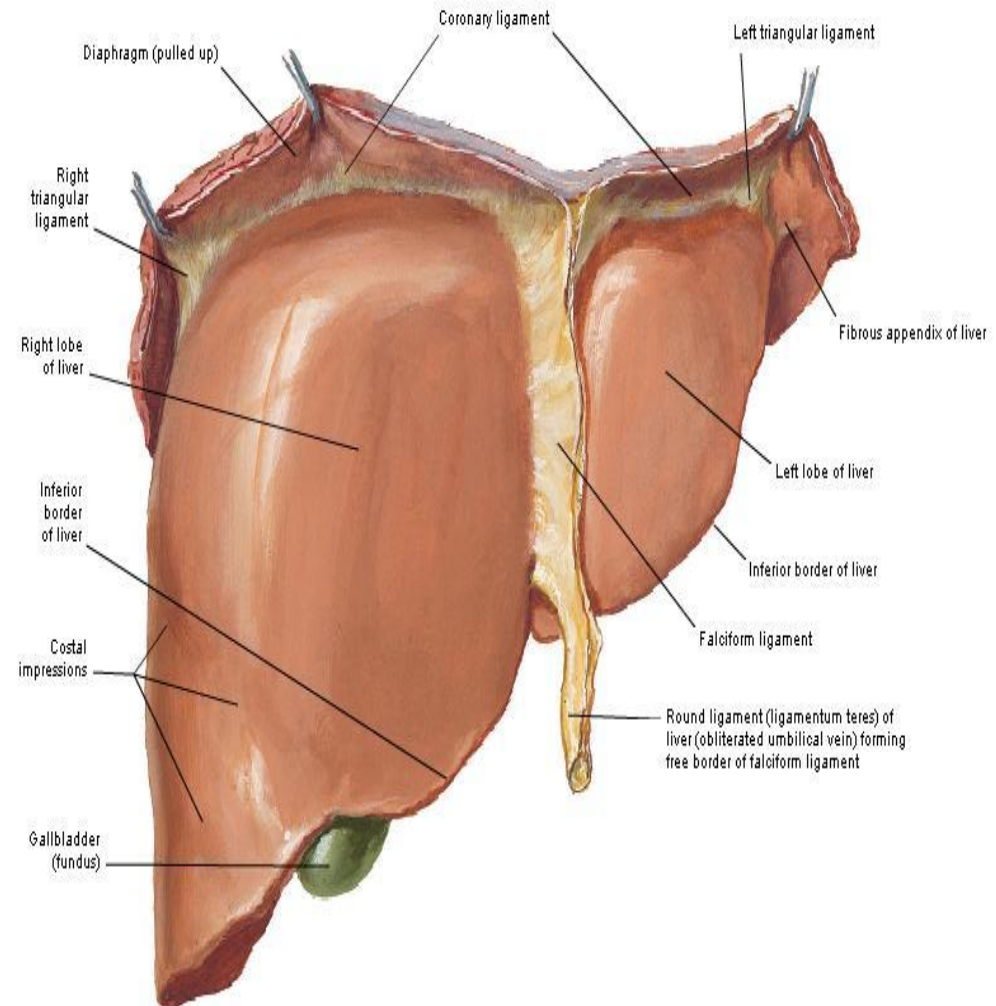


1. The ligaments of the liver

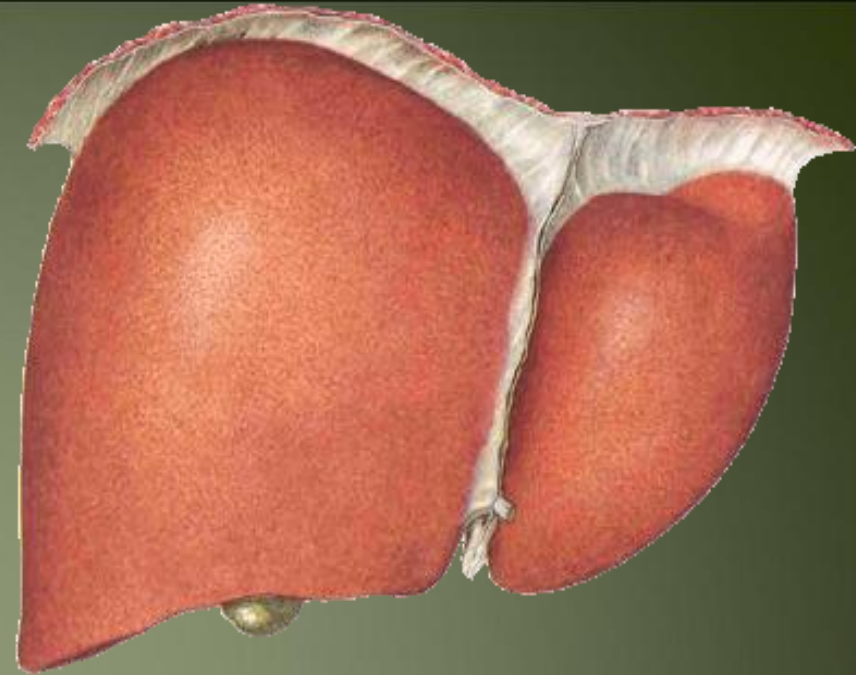
- 1- The **Falciform ligament of liver**
- 2- The **Ligamentum teres hepatis**
- 3- The **coronary ligament**
- 4- The **right triangular ligament**
- 5- The **left triangular ligament**
- 6- The **Hepatogastric ligament**
- 7- The **hepatoduodenal ligament**
- 8- The **Ligamentum Venosum**

- **Falciform ligament of liver**
 - Consists of double peritoneal layer
 - Sickle shape
 - Extends from anterior abdominal wall (umbilicus) to liver
 - Free border of the ligament contains Ligamentum teres (obliterated umbilical vein)

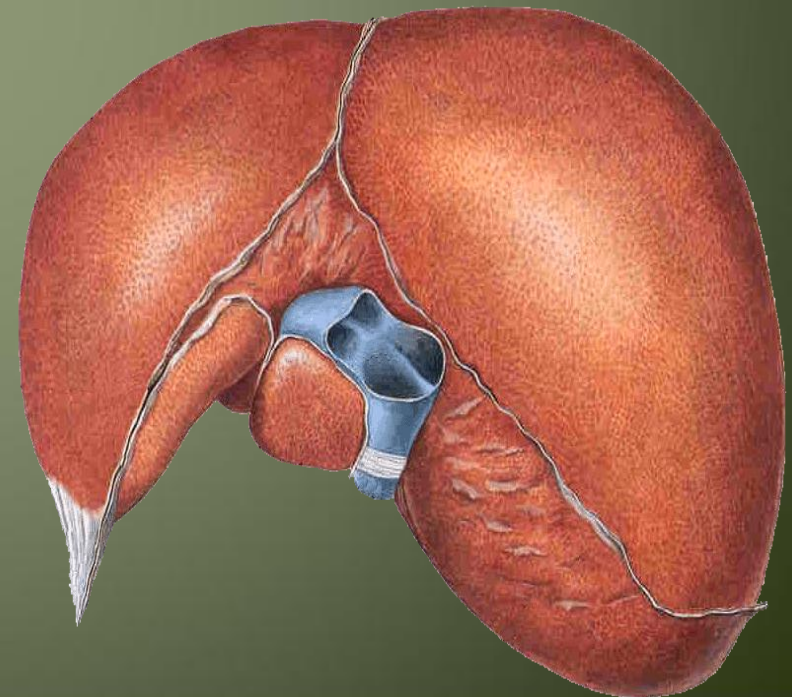
Surfaces and Bed of Liver
Anterior View



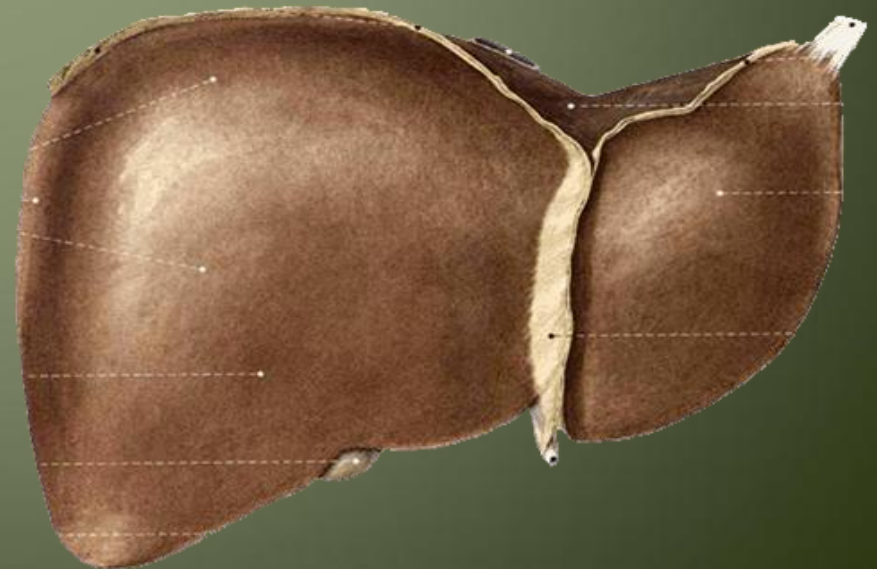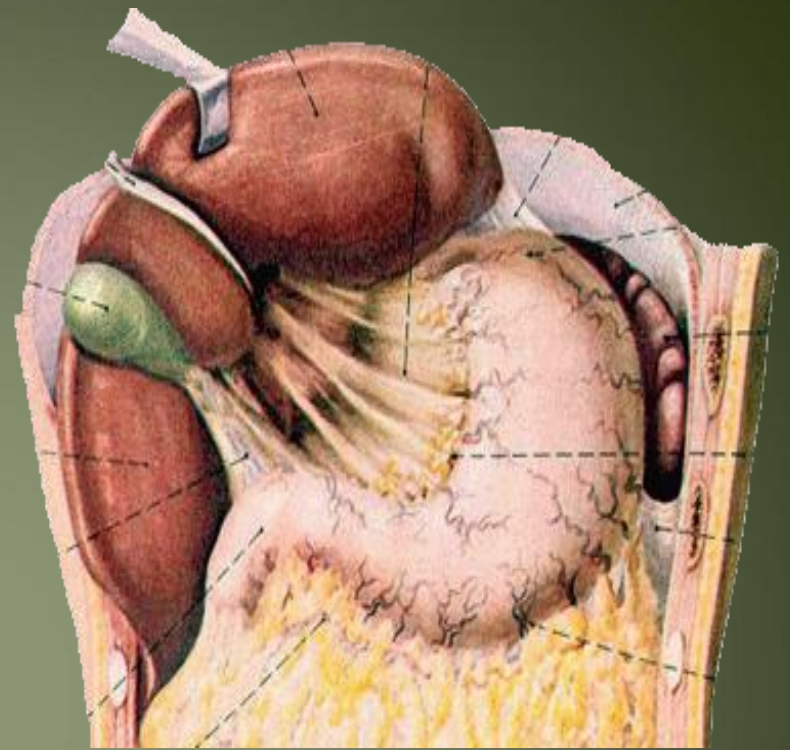- **Coronary ligament**
the area between upper and lower layer of the coronary ligament is the bare area of liver which contract with the diaphragm;



- **Left and right triangular ligaments** formed by left and right extremity of coronary ligament

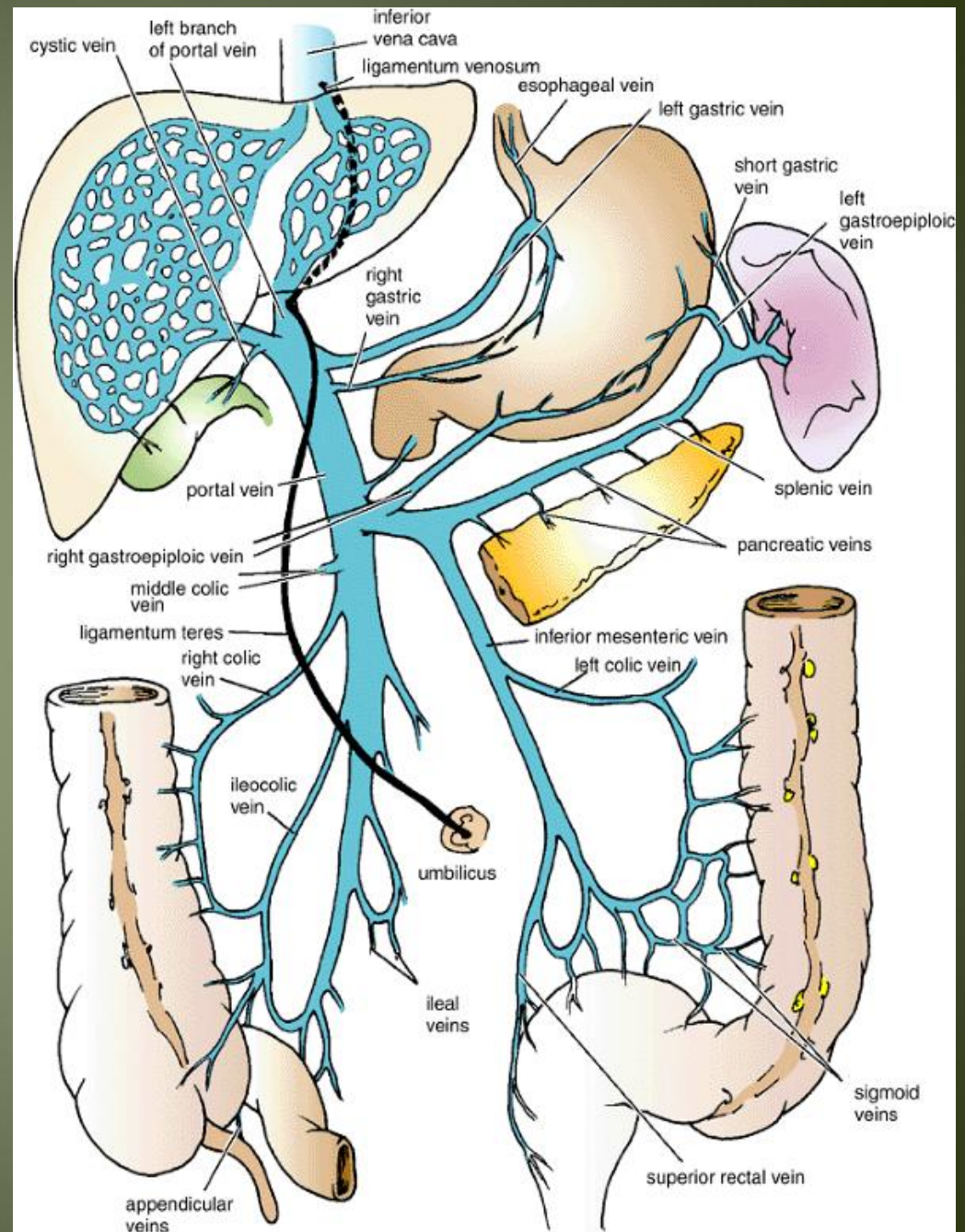


- **Hepatogastric ligament**
- **Hepatoduodenal ligament**



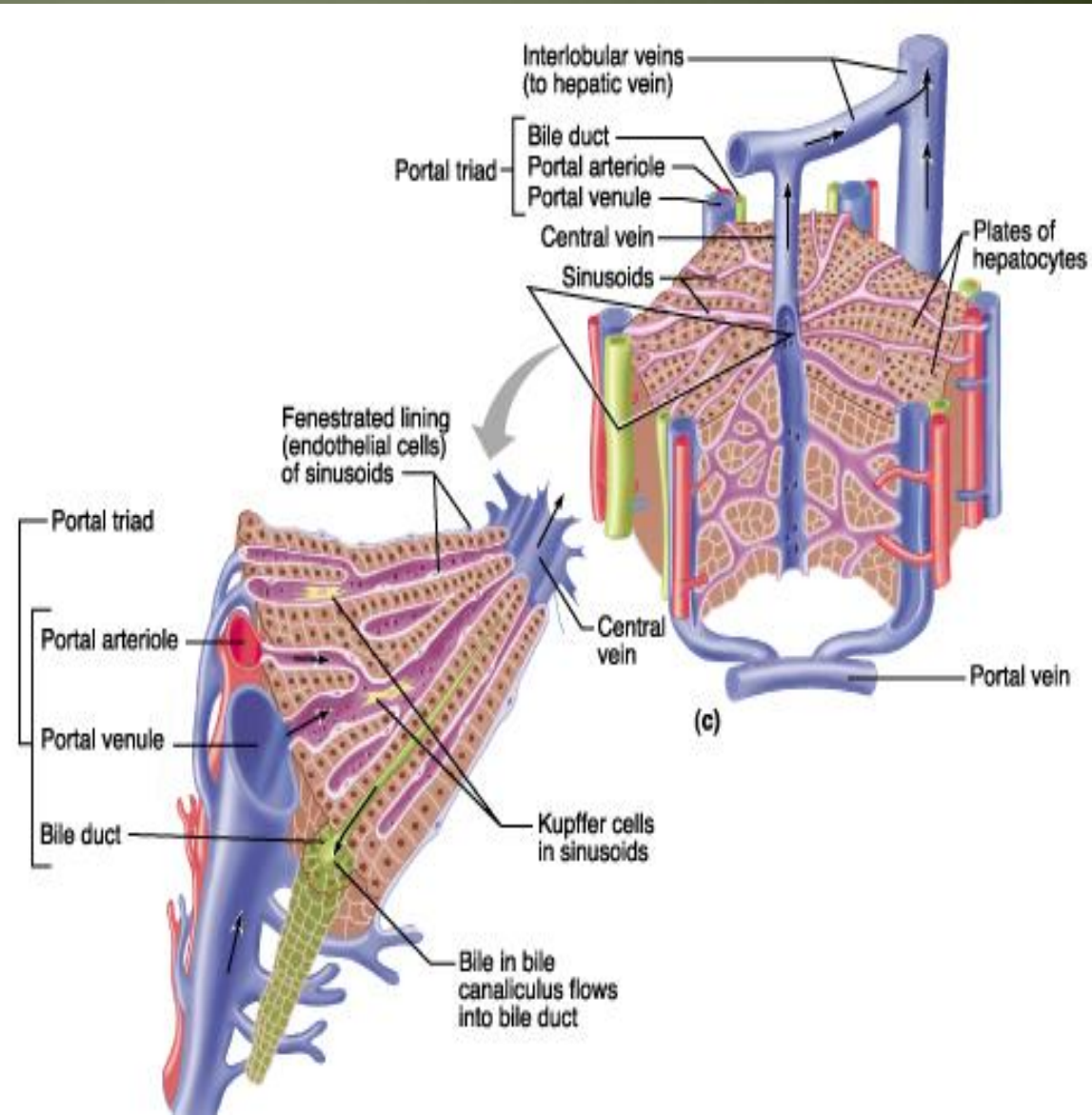
The Ligamentum Venosum

- Fibrous band that is the remains of the ductus venosus
- Is attached to the left branch of the portal vein and ascends in a fissure on the visceral surface of the liver to be attached above to the inferior vena cava

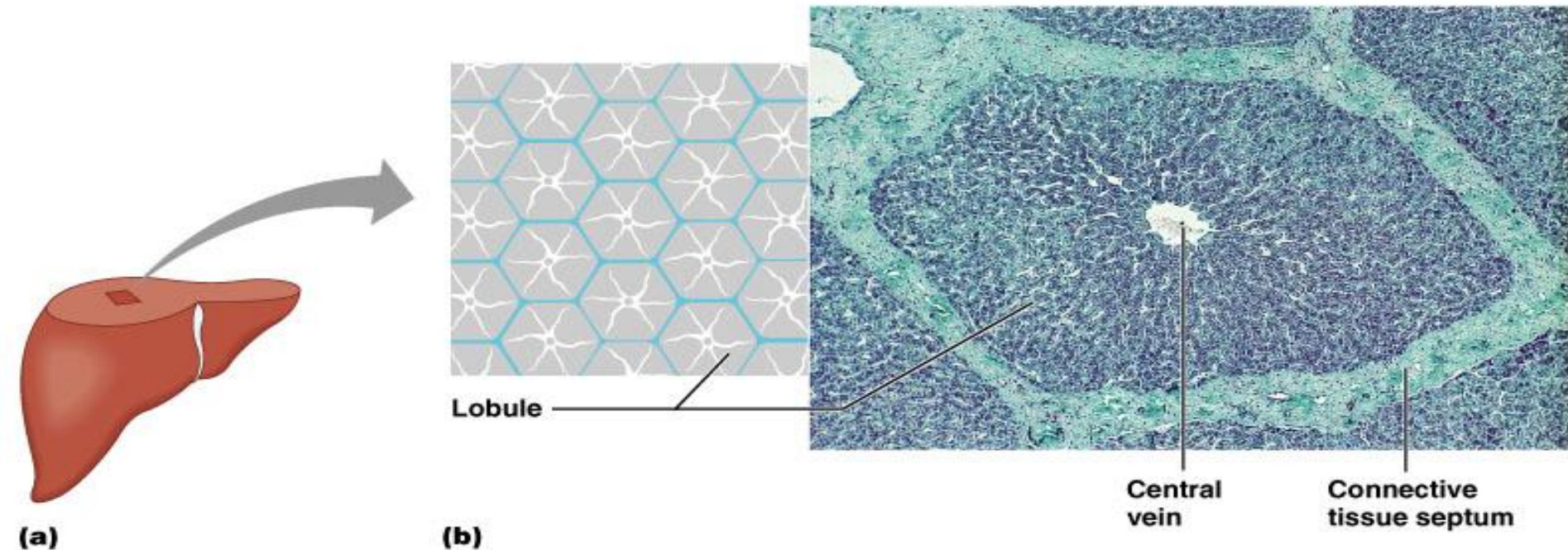


LIVER Histology

- lobules >> roughly **hexagonal** structures **consisting of** hepatocytes. Radiate outward from a central vein.
- At each of the six corners of a lobule is a portal triad (p.arteriole, p.venule & bile duct)
- Between the hepatocytes are the liver sinusoids.

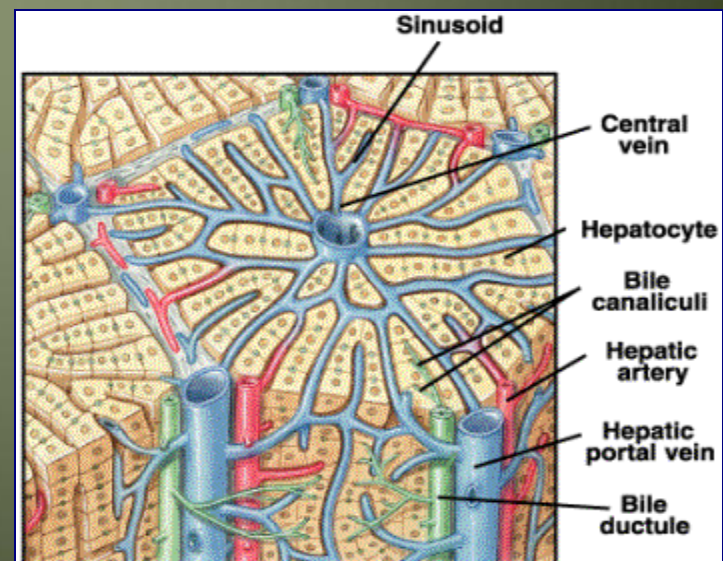


Where do the two blood supplies mix?



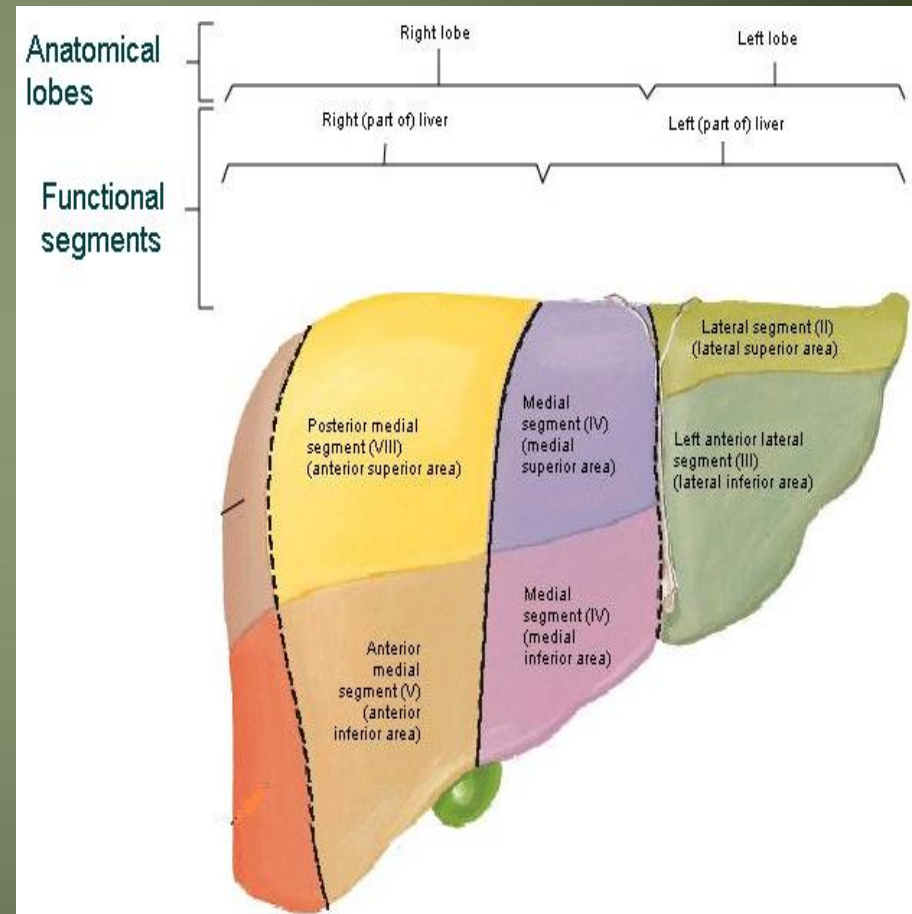
Copyright © 2004 Pearson Education, Inc., publishing as Benjamin Cummings.

- Liver surrounded by a thin capsule at portahepatic(it is thick)→Glisson's capsule invests the liver and send septa into liver subset subdivide the parenchyma into lobules



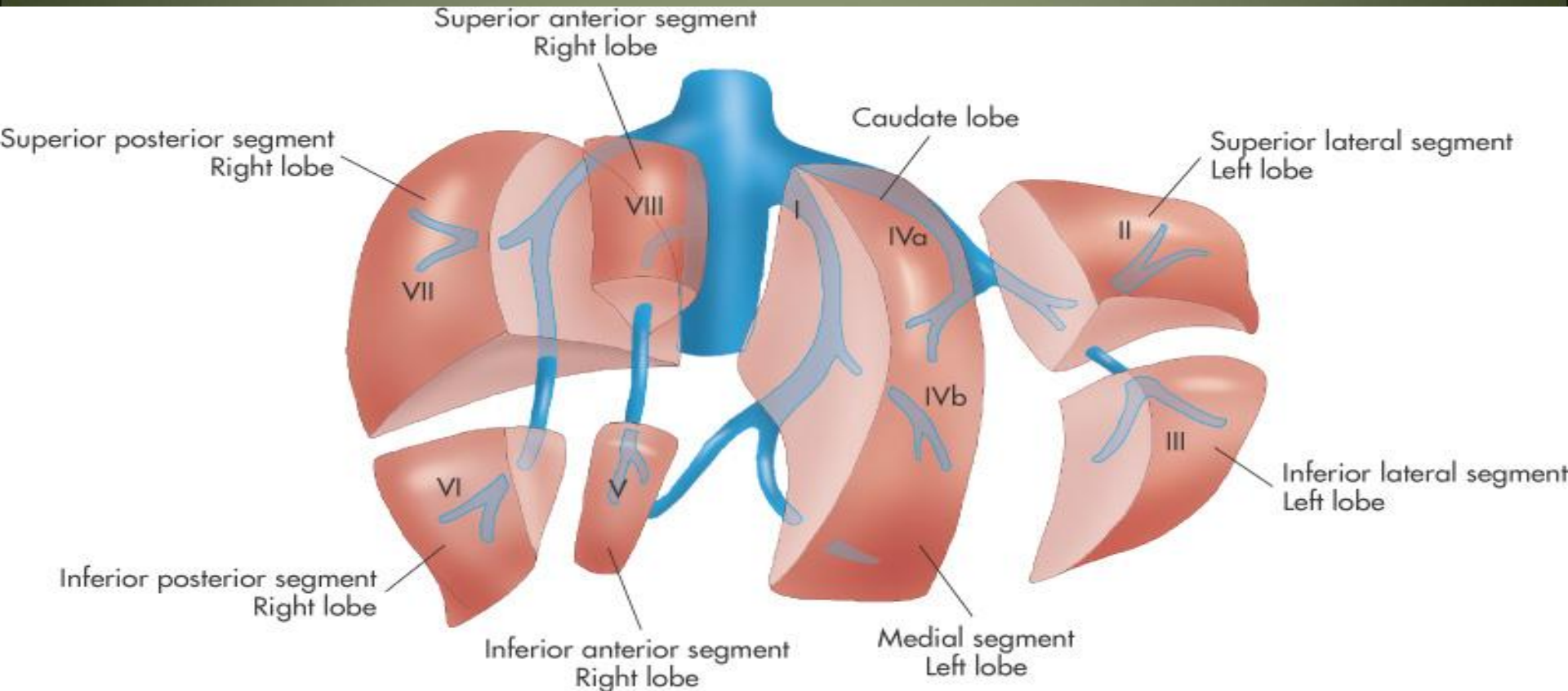
Segmental anatomy of the liver

- Rt .& Lt. lobes anatomically no morphological significance. Separation by ligaments (Falciform, lig. Venosum & Lig.teres)
- True morphological and physiological division by a line extend from fossa of GD to fossa of I.V.C each has its own arterial blood supply, venous drainage and biliary drainage
- No anastomosis between divisions
- 3 major hepatic veins → Rt, Lt & central
- 8 segments based on hepatic and portal venous segments

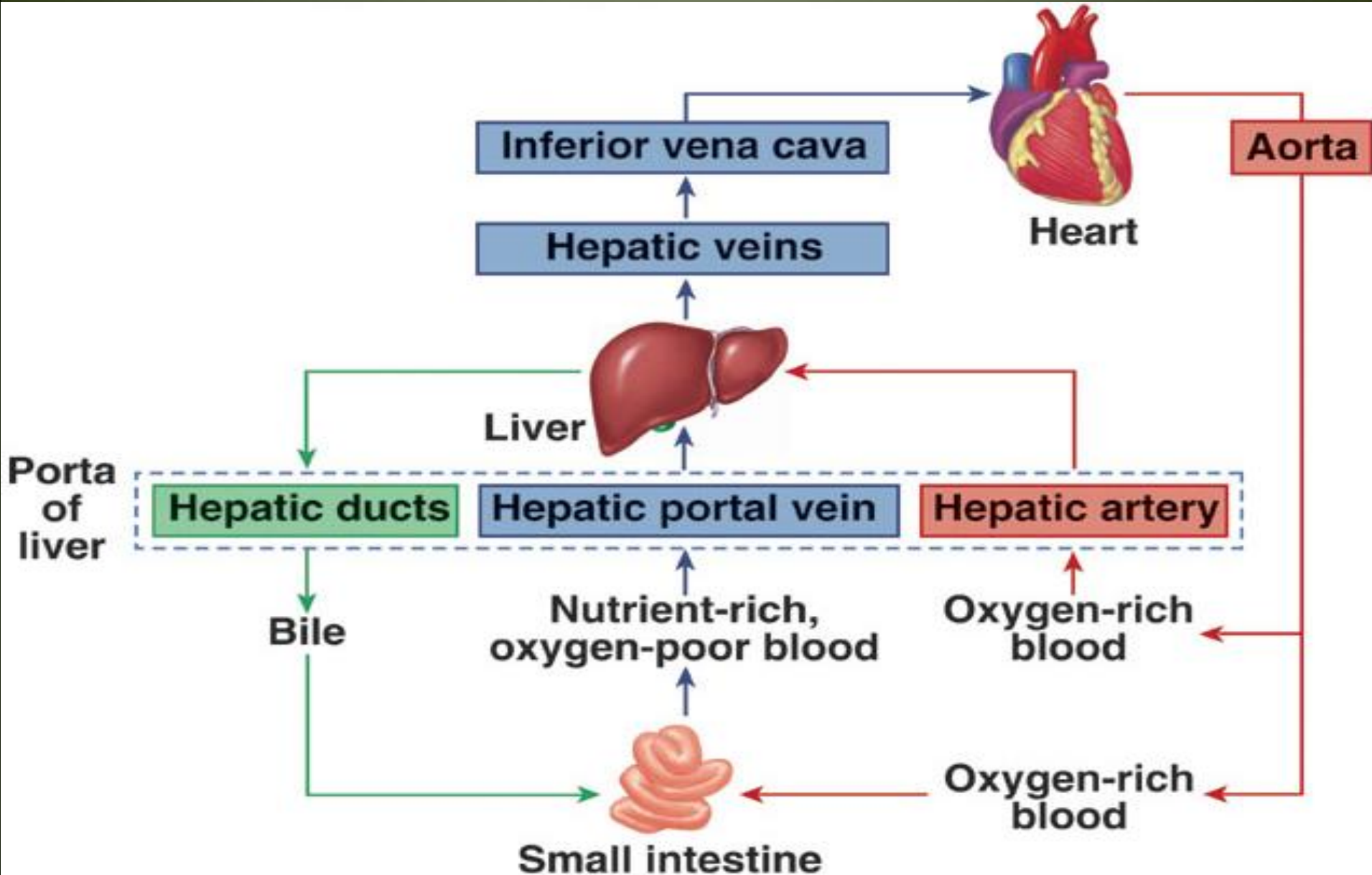


Segmental anatomy of the liver

- Liver segments are based on the portal and hepatic venous segments

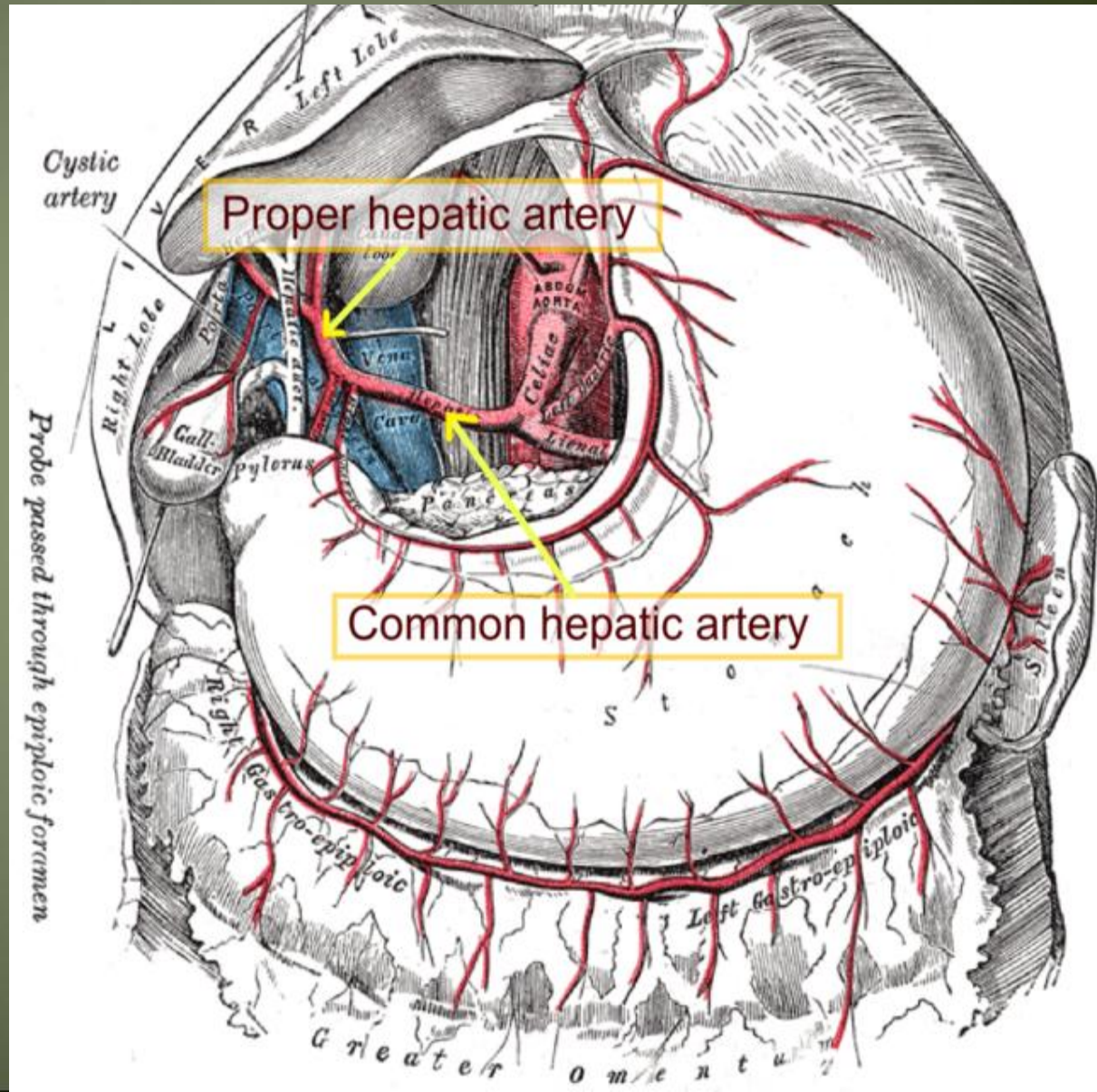


Blood supply of the liver



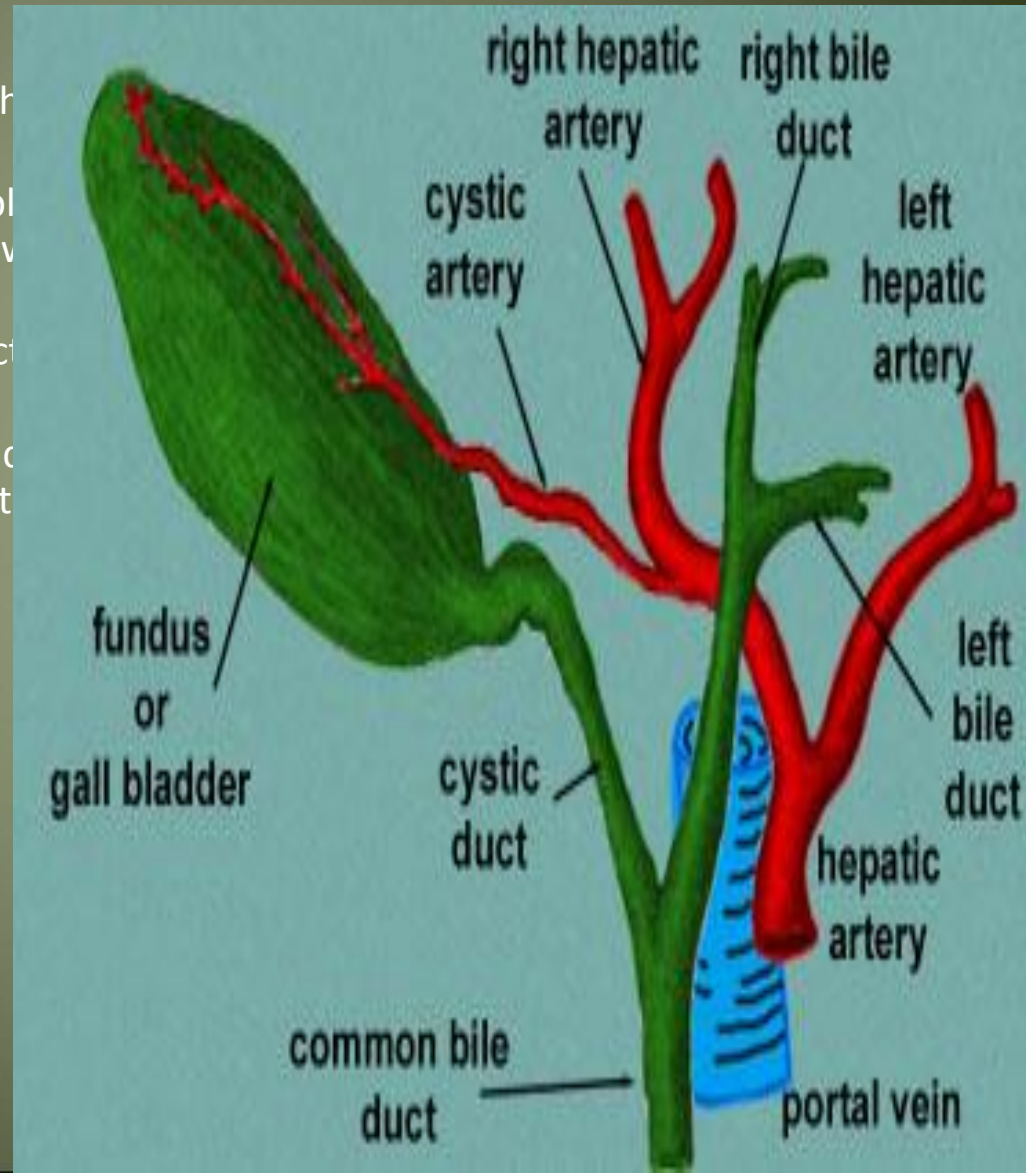
Blood supply of the liver

- Proper hepatic artery → The right and left hepatic arteries enter the porta hepatis.
- The right hepatic artery usually gives off the cystic artery, which runs to the neck of the gallbladder.



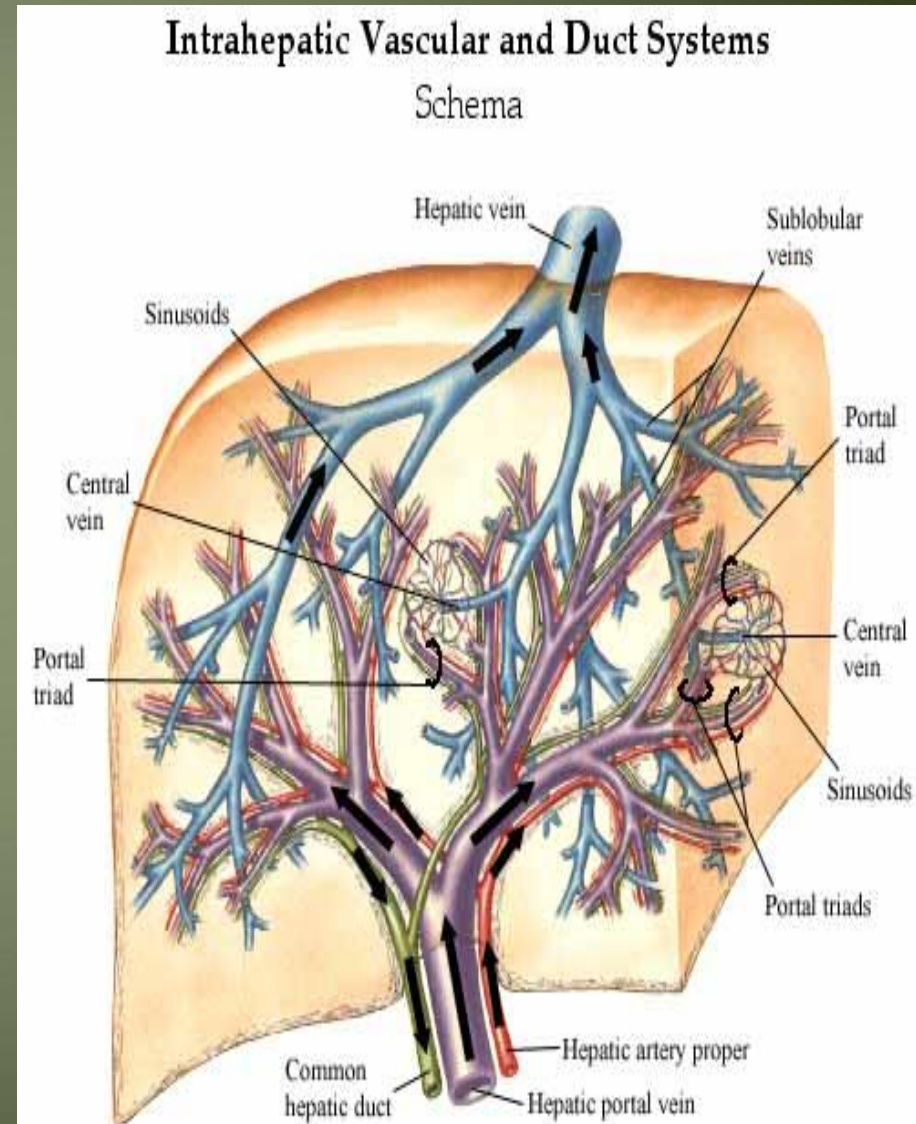
Blood Circulation through the Liver

- The blood vessels conveying blood to the liver (70%).
- The hepatic artery brings oxygenated blood to the liver, which is rich in the products of digestion, from the gastrointestinal tract.
- The arterial and venous blood is conducted to the liver sinusoids.
- The central veins drain into the right and left hepatic veins, which open directly into the inferior vena cava.



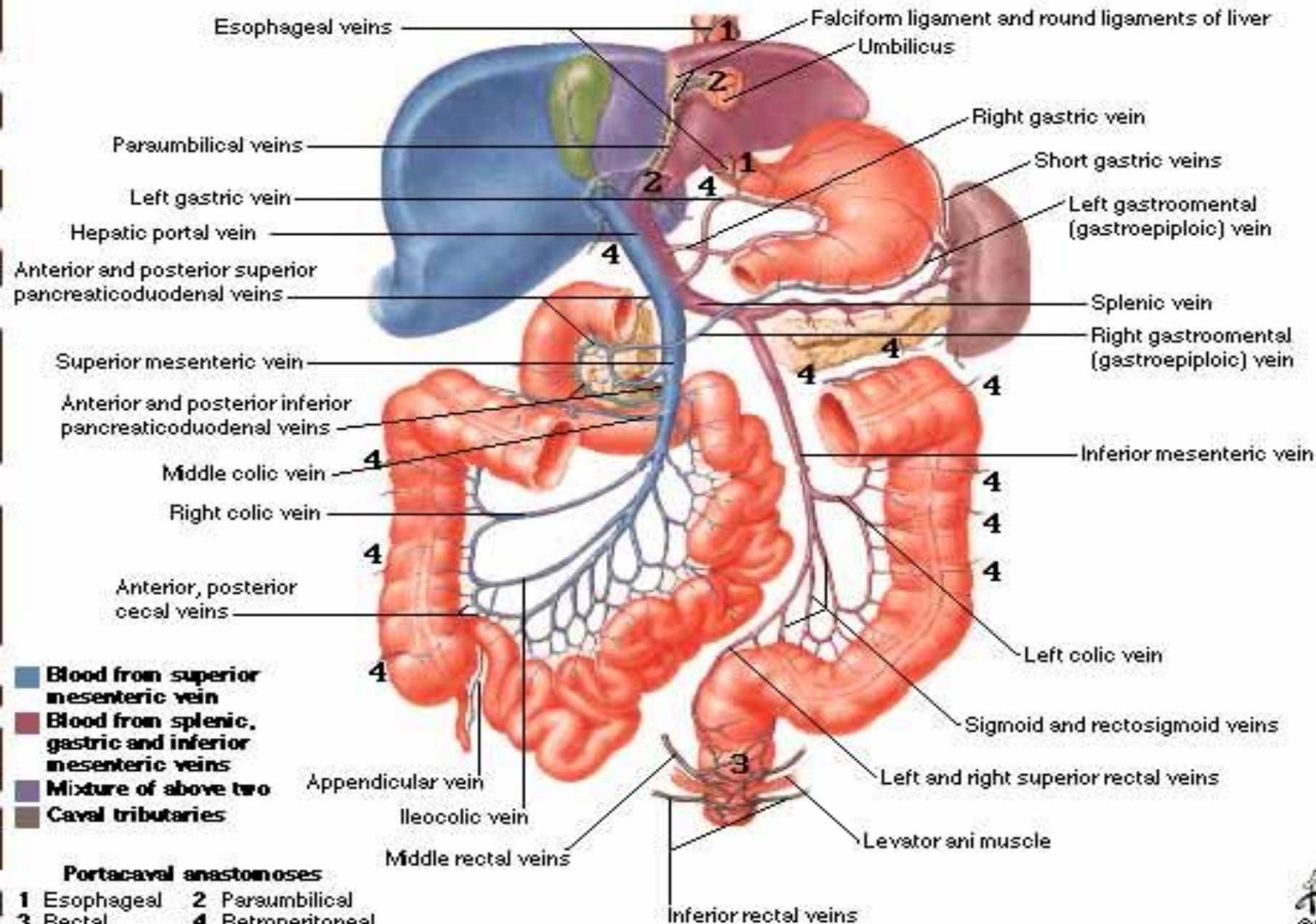
Vein drainage of the liver

- The portal vein divides into right and left terminal branches that enter the porta hepatis behind the arteries.
- The hepatic veins (three or more) emerge from the posterior surface of the liver and drain into the inferior vena cava.



Hepatic Portal Vein Tributaries

Portocaval Anastomoses



Lymphatic drainage of the liver

- Liver produce large amount of lymph~ one third – one half of total body lymph
- Lymph leave the liver and enters several lymph nod in porta hepatis → efferent vessels pass to celiac nodes
- A few vessels pass from the bare area of the liver through the diaphragm to the posterior Mediastinal lymph nodes.

- Nerve supply
- Sympathetic → hepatic plexus>>> celiac plexuses → thoracic ganglion chain T1-T12
- Parasympathetic → vagous nerve(anterior part)

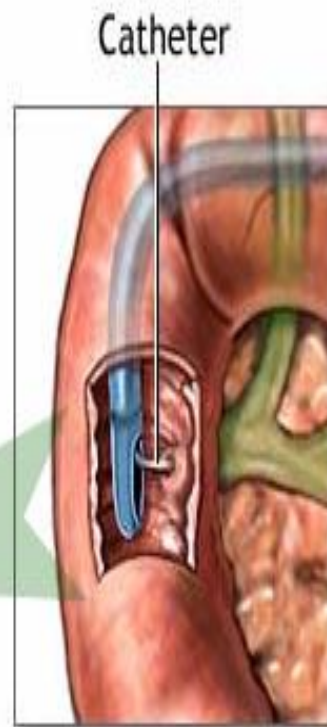
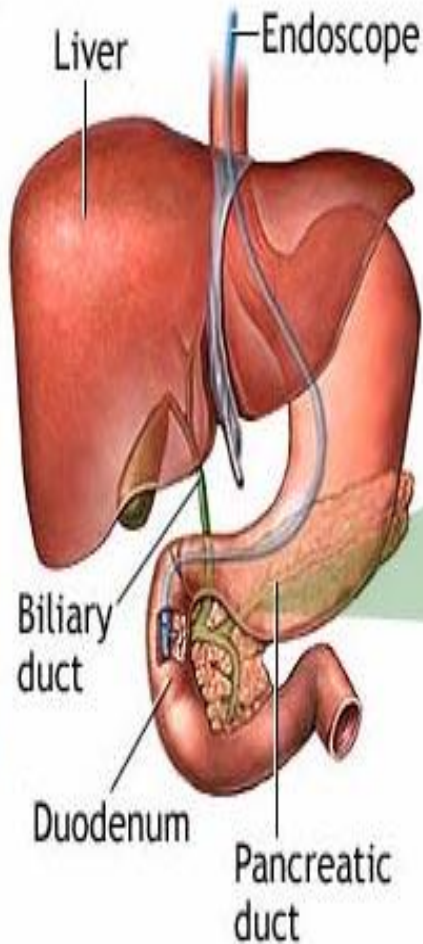
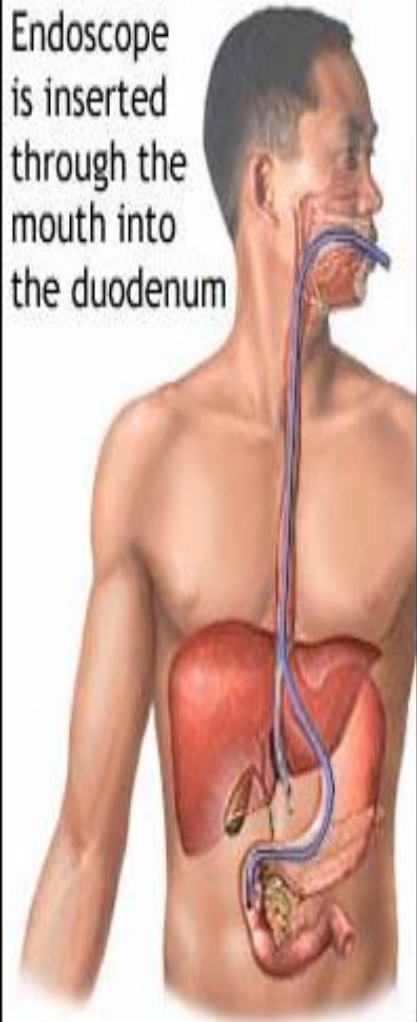
- Sympathetic and parasympathetic nerves form the celiac plexus.
- The anterior vagal trunk gives rise to a large hepatic branch, which passes directly to the liver

Endoscopic retrograde cholangiopancreatography (ERCP)

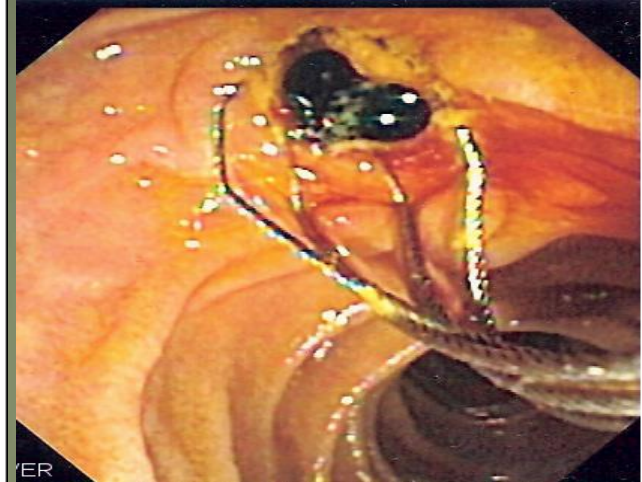- It is a technique that combines the use of endoscopy and fluoroscopy to diagnose and treat certain problems of the biliary or pancreatic ductal systems. Through the endoscope, the physician can see the inside of the stomach and duodenum, and inject dyes into the ducts in the biliary tree and pancreas so they can be seen on X-rays.
- ERCP is used primarily to diagnose and treat conditions of the bile ducts, including gallstones, inflammatory strictures (scars), leaks (from trauma and surgery), and cancer.

ERCP

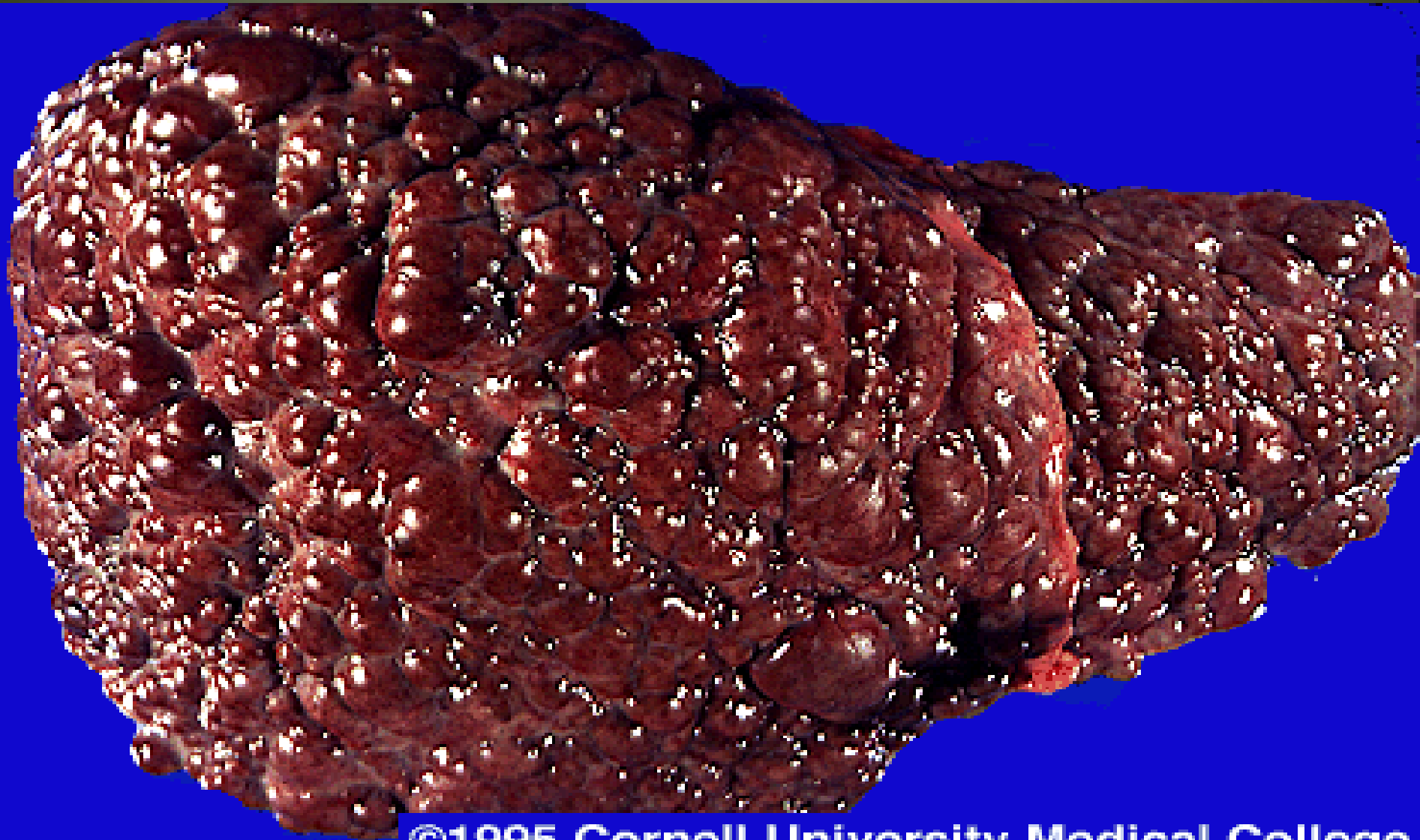
Endoscope is inserted through the mouth into the duodenum



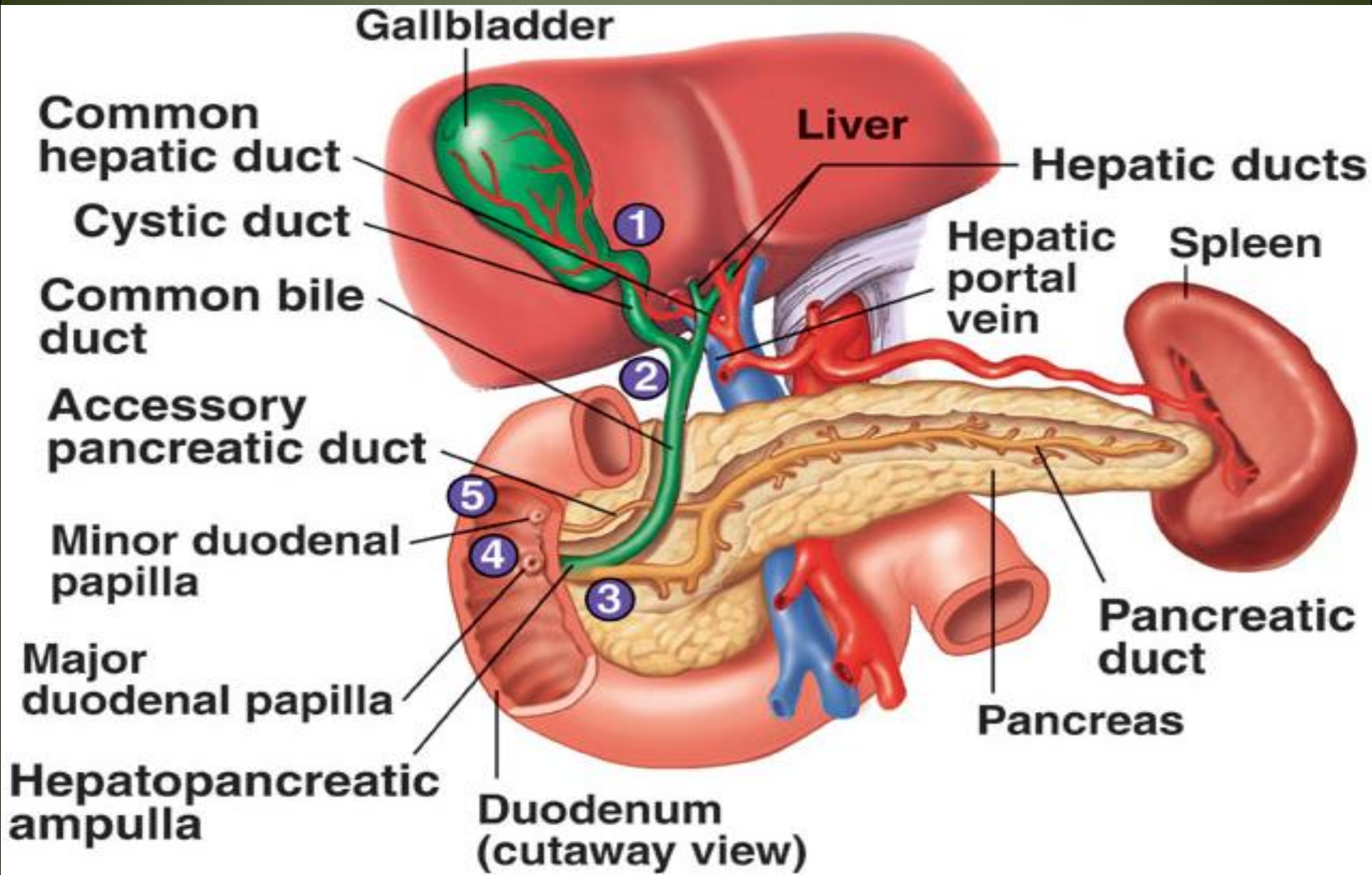
Dye is injected through a catheter into the pancreatic or biliary ducts



Liver cirrhosis



GALLBLADDER

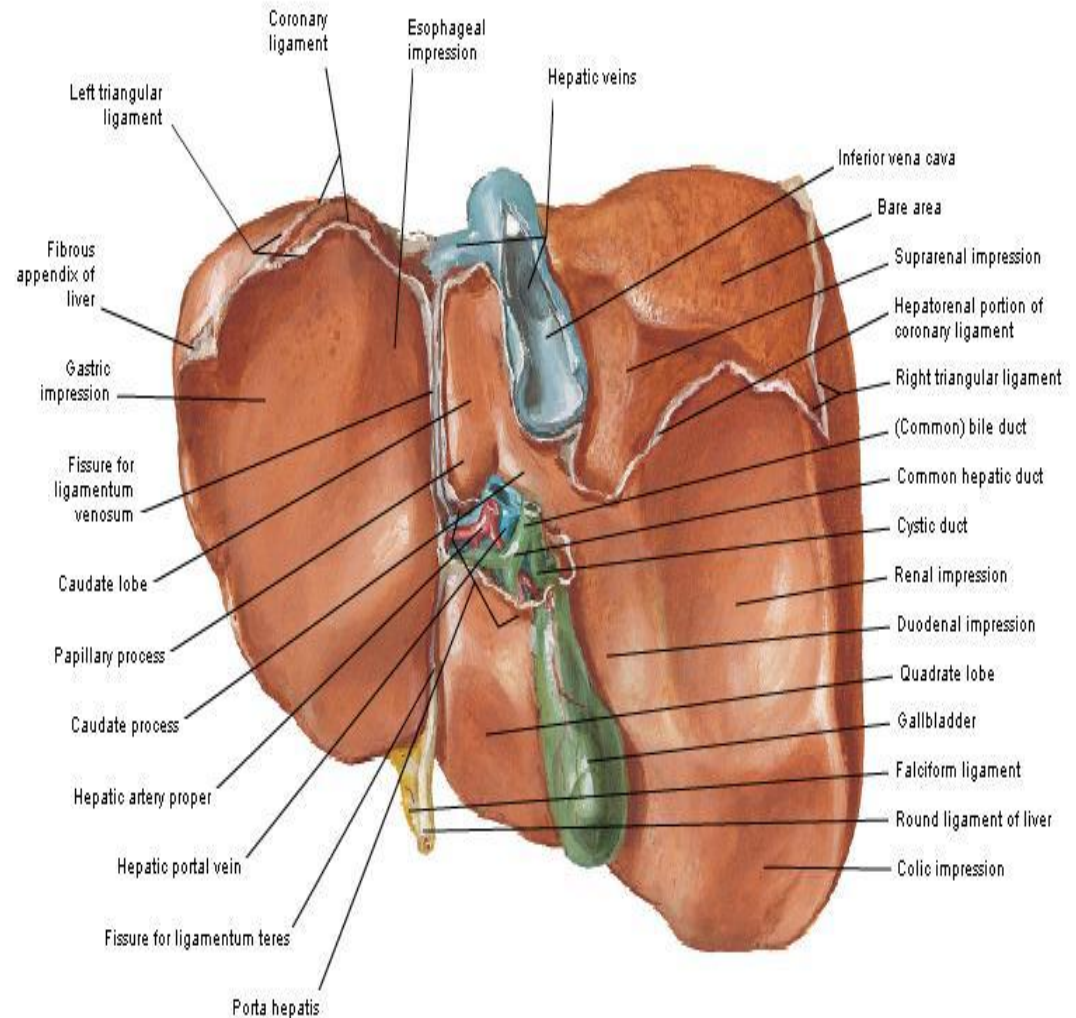


Anatomical position of GB

- Epigastric - Right hypochondrium region
- At the tip of the 9th RT . C.C
- Green muscular organ
- Pear-shaped, hollow structure
- On inferior surface of liver
- Between quadrate and right lobes
- Has a short mesentery
- Capacity 40- 60 cc
- Body and neck
- Directed toward porta hepatis

Surfaces and Bed of Liver

Visceral Surface



Structure of GB

Fundus

- Ant: ant.abdominal wall
- Post.inf: transverscolon

Body

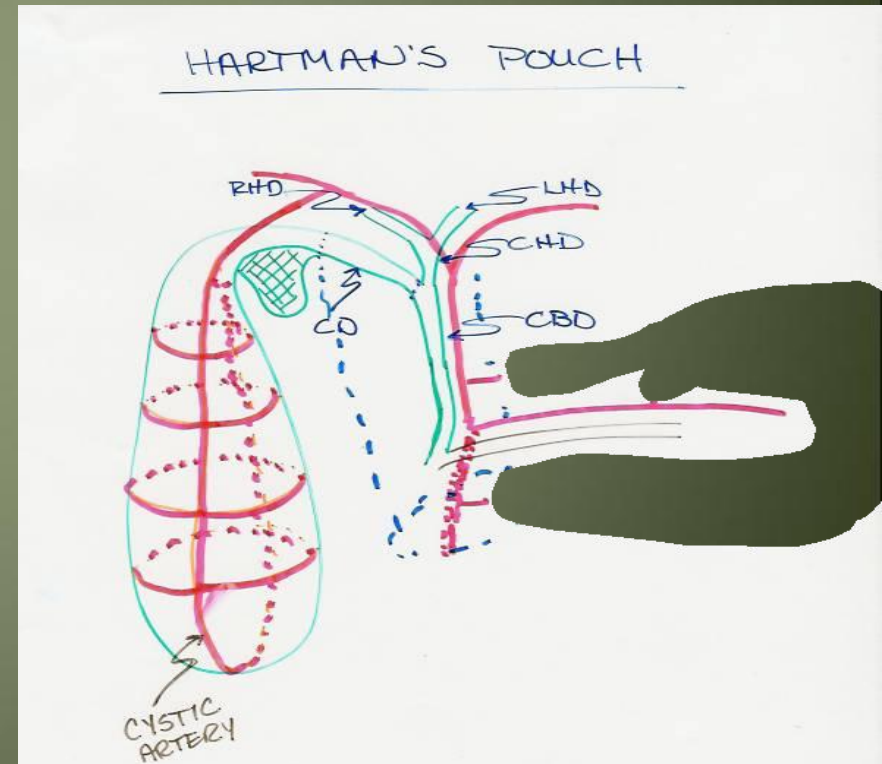
- sup: liver
- post.inf: Tr.colon. End of 1st part of doudenum ,
begins of 2nd part of doudenum

Neck

- Form the cystic duct, 4cm

Hartmann's Pouch

1. Lies between body and neck of gallbladder
2. A normal variation
3. May obscure cystic duct
4. If very large, may see cystic duct arising from pouch



Gall Bladder

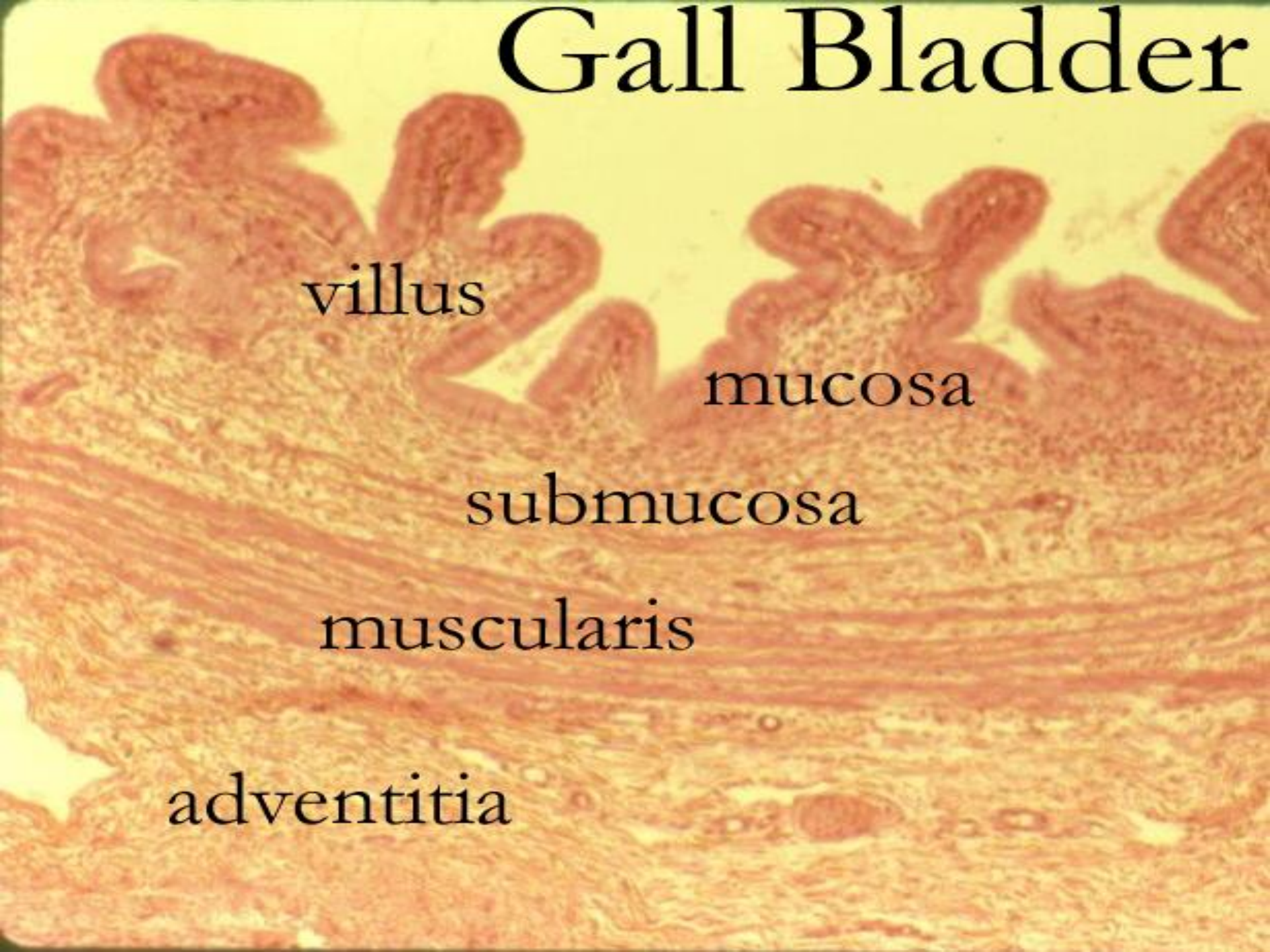villus

mucosa

submucosa

muscularis

adventitia



Gall Bladder H&E

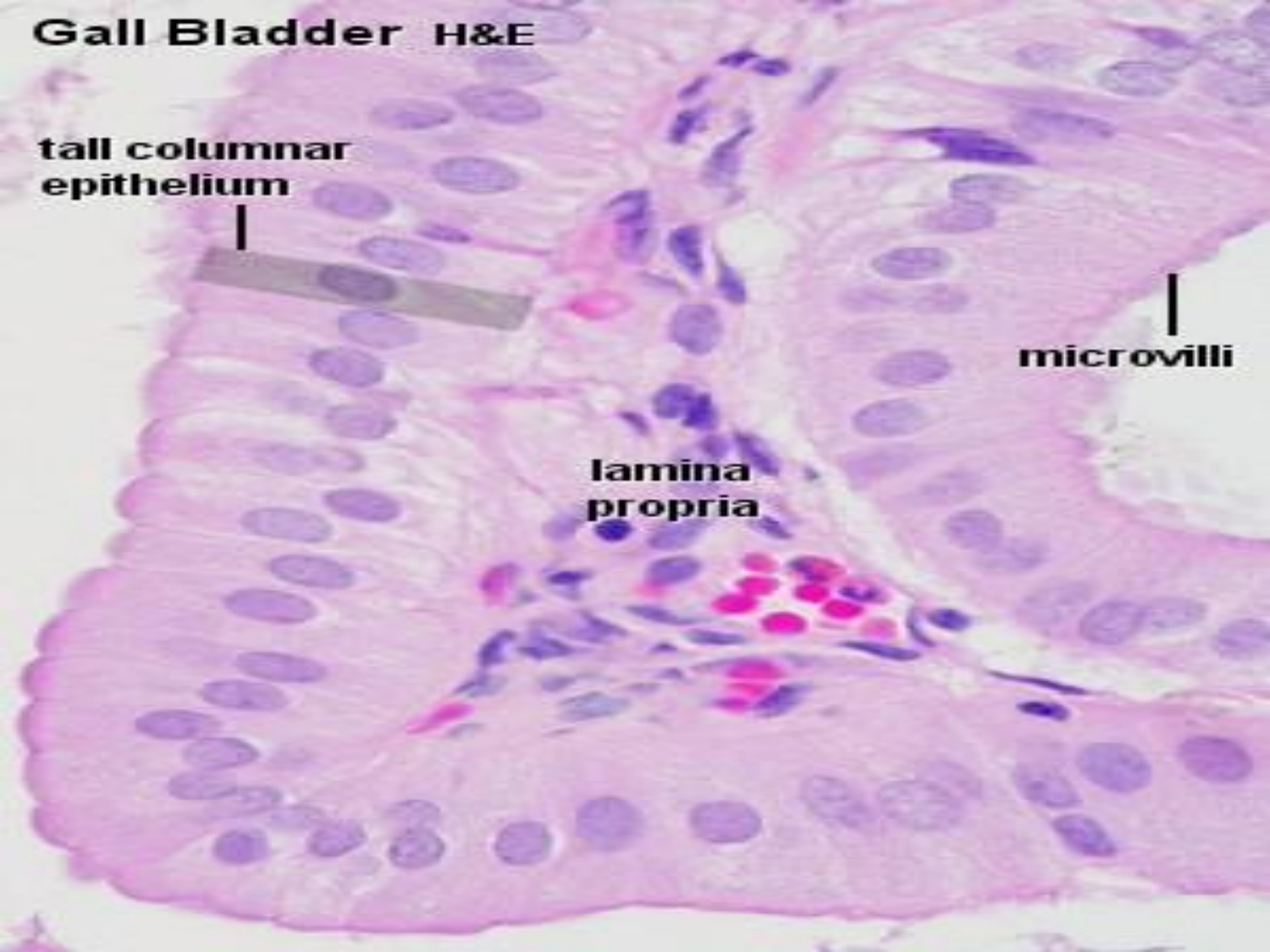
tall columnar
epithelium



microvilli

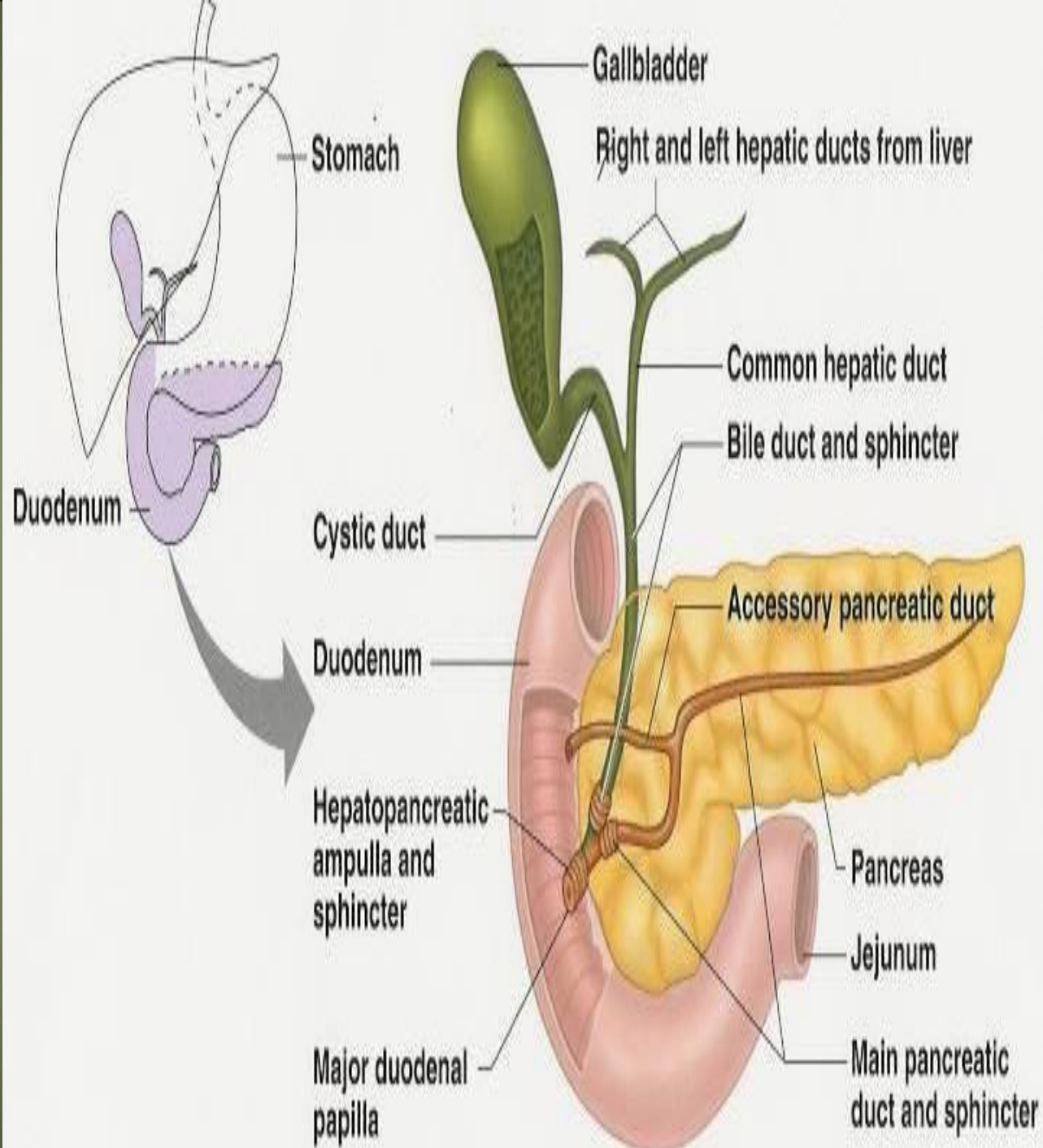


lamina
propria



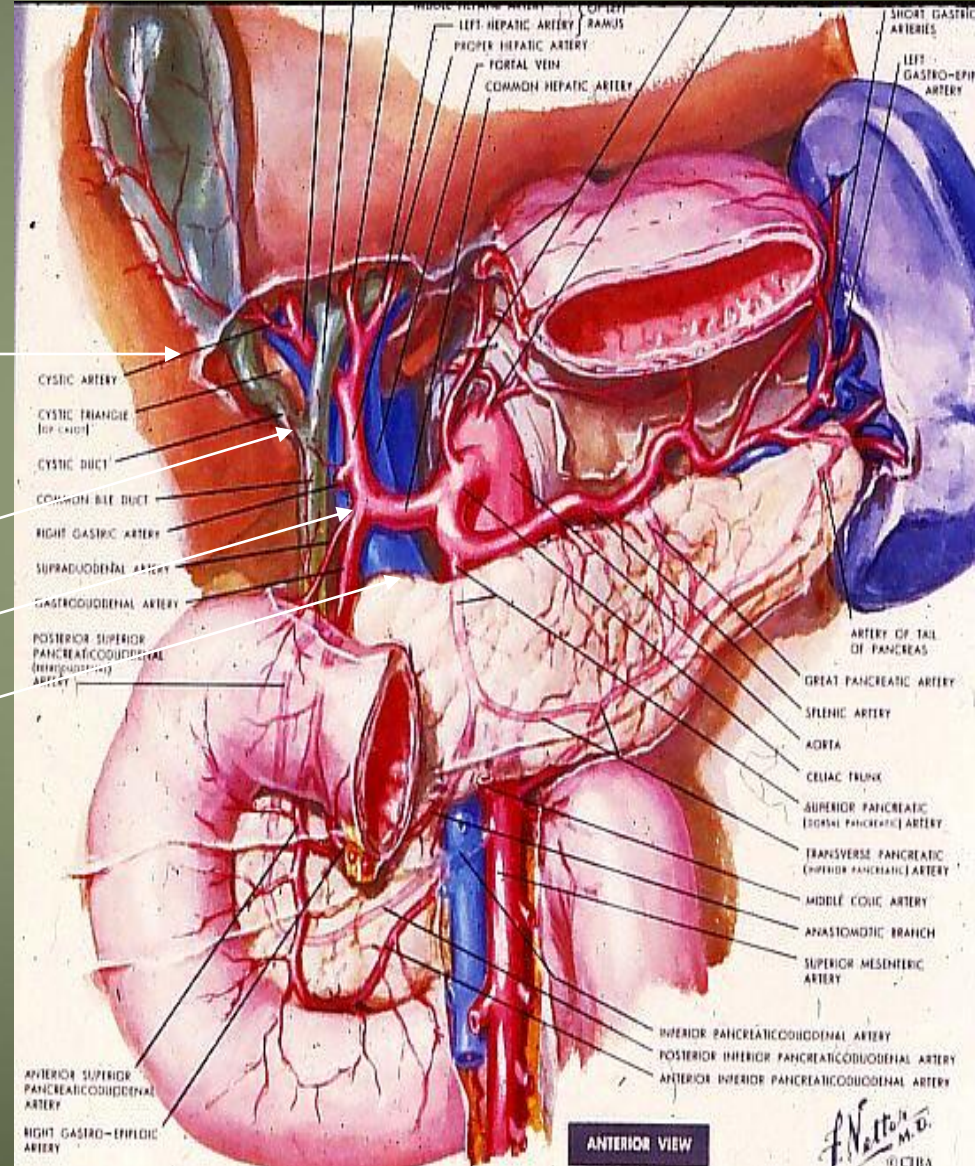
Cystic duct

- It joins common hepatic duct



Arterial Supply to the Gallbladder

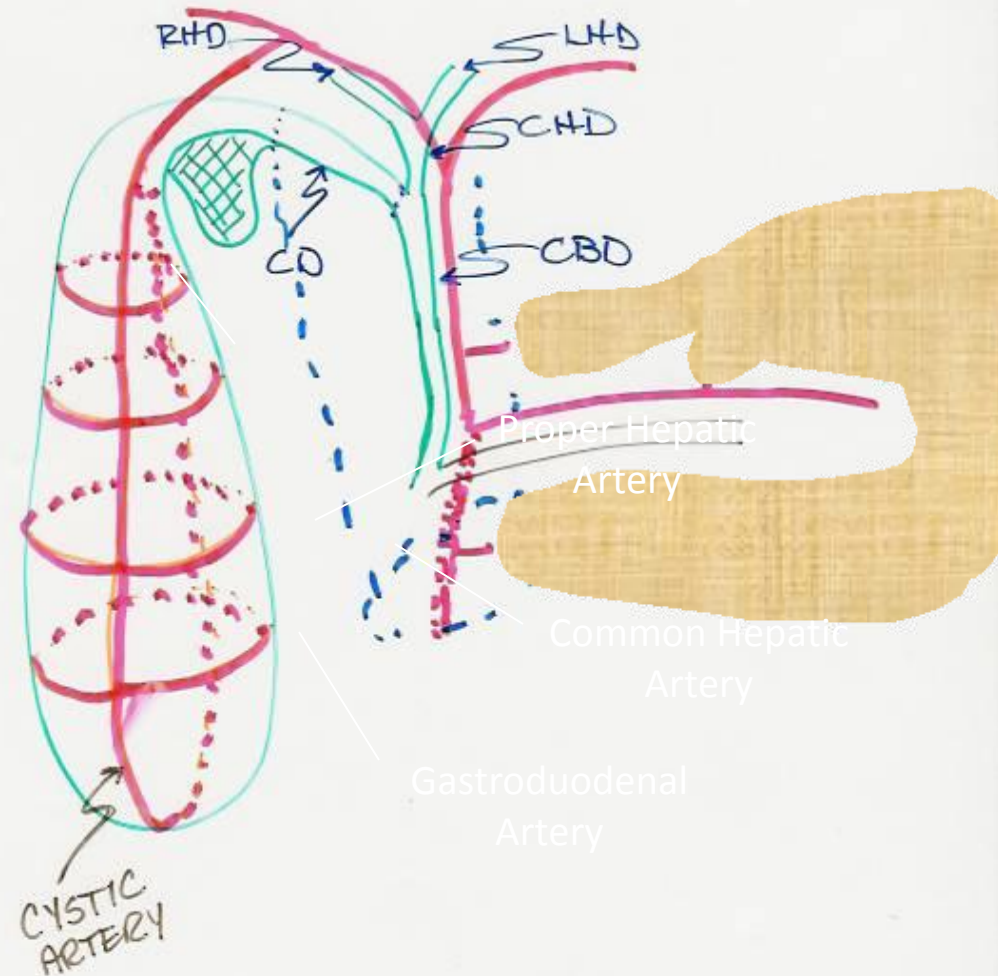
- Cystic artery
- Right hepatic artery
- Proper hepatic artery
- Common hepatic artery



HARTMAN'S POUCH

Blood supply of GB:

- Cystic artery → branch of Rt. Hepatic artery
- Cystic vein → end in portal vein
- Small branches (arteries and veins) run between liver and gall bladder



Lymphatic drainage of GB

1. Terminate @ celiac nodes
2. Cystic node at neck of GB
 - a. Actually a hepatic node
 - b. Lies at junction of cystic & common hepatic ducts
3. Other lymph vessels also drain into hepatic nodes

Nerve supply

- Sympathetic and parasympathetic from celiac plexus
- Parasympathetic ---- vagous nerve
- Hormone → cholecystokini → duodenum

Common bile duct

Extra hepatic biliary system

Rt. hepatic duct

+

Lt hepatic duct

↓

Common hepatic duct

+

Cystic duct

↓

Common bile duct

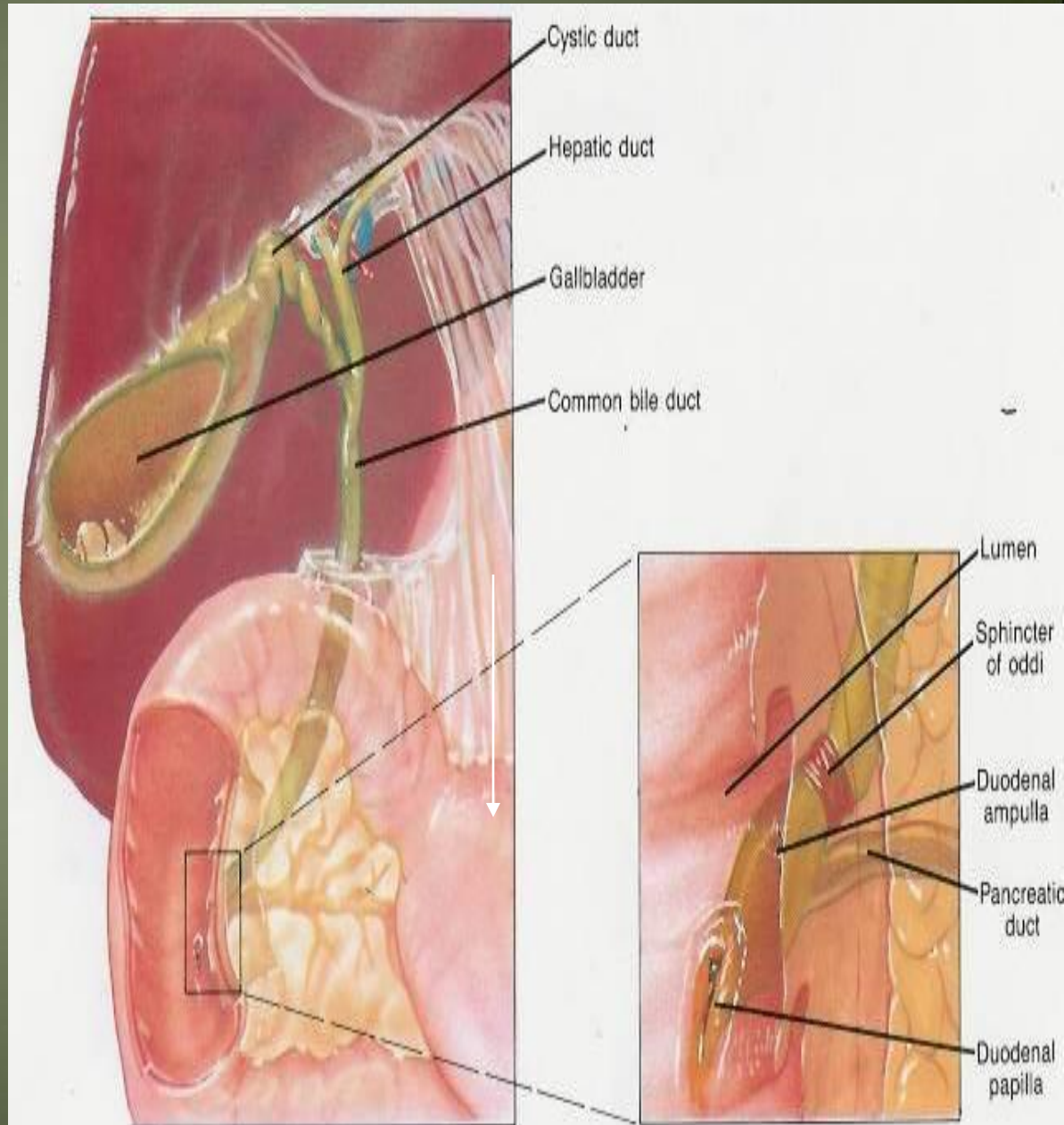
- 4cm

- Descend in free edge of lesser omentum

- Supra duodenal part

Retro duodenal part

Retro pancreatic part



Bile duct..... parts and relations

-3 inc long

-1st part

- Located in right free margin of lesser omentum
- in front of the opening into the lesser sac (Epiploic opening)
- Rt to hepatic artery and portal vein

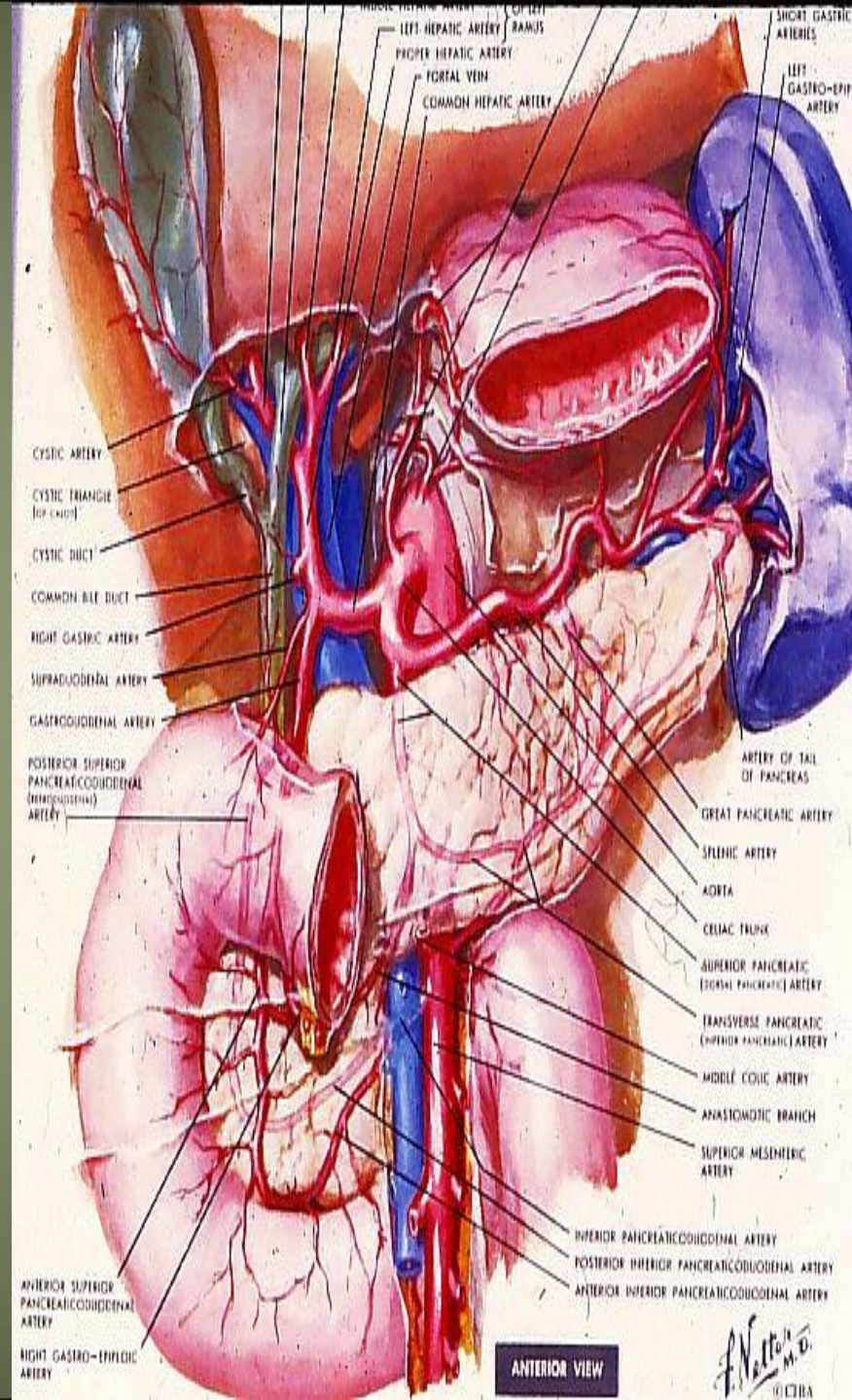
- 2nd part

- Behind the 1st part of the duodenum
- Rt to the gastroduodenal artery

-3 rd part

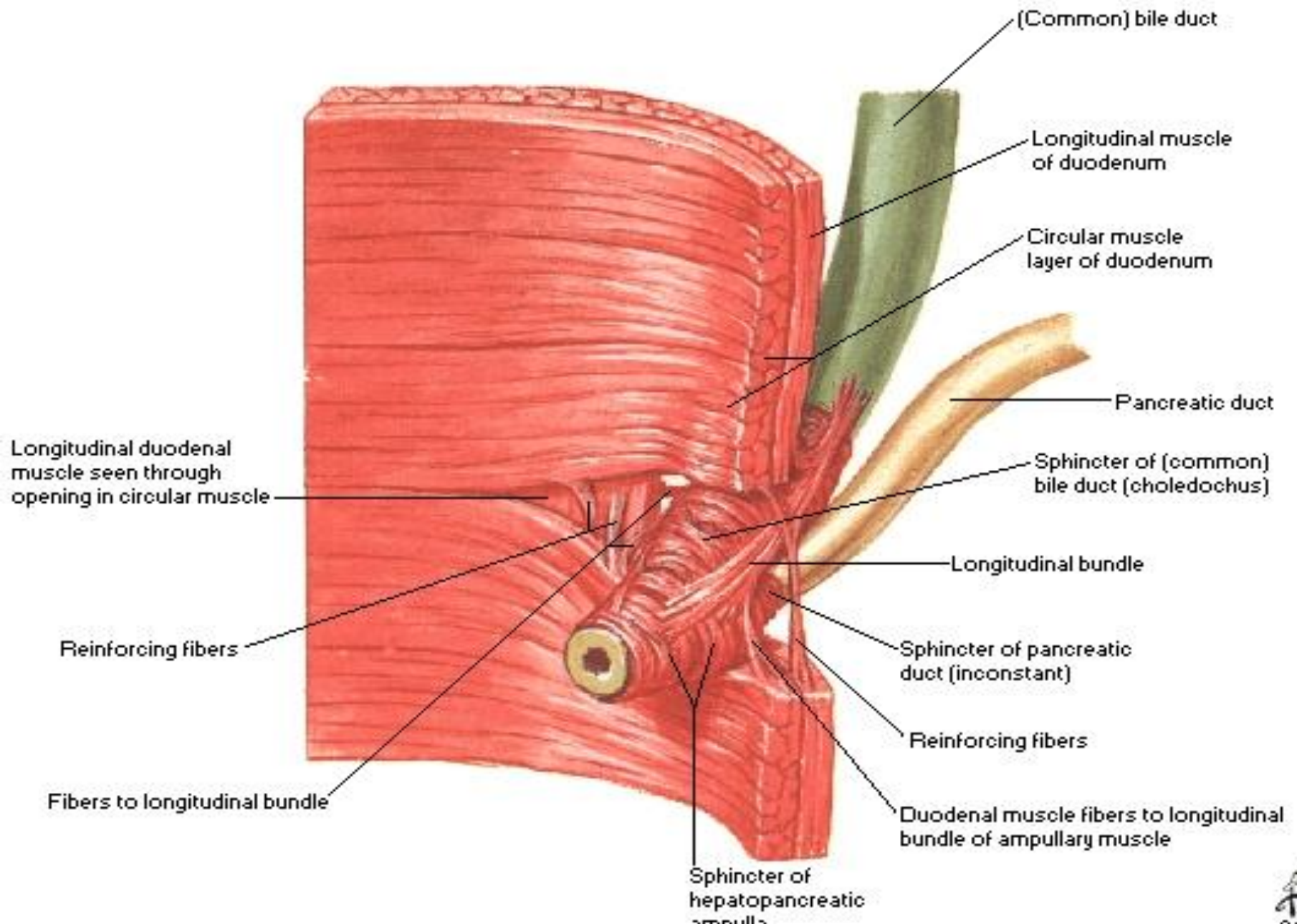
- Posterior surface of the head of the pancreas
- Contact with main pancreatic duct
- Related with IVC, gastroduodenal artery, portal vein

-End in the half second part of duodenum at ampulla of Vater

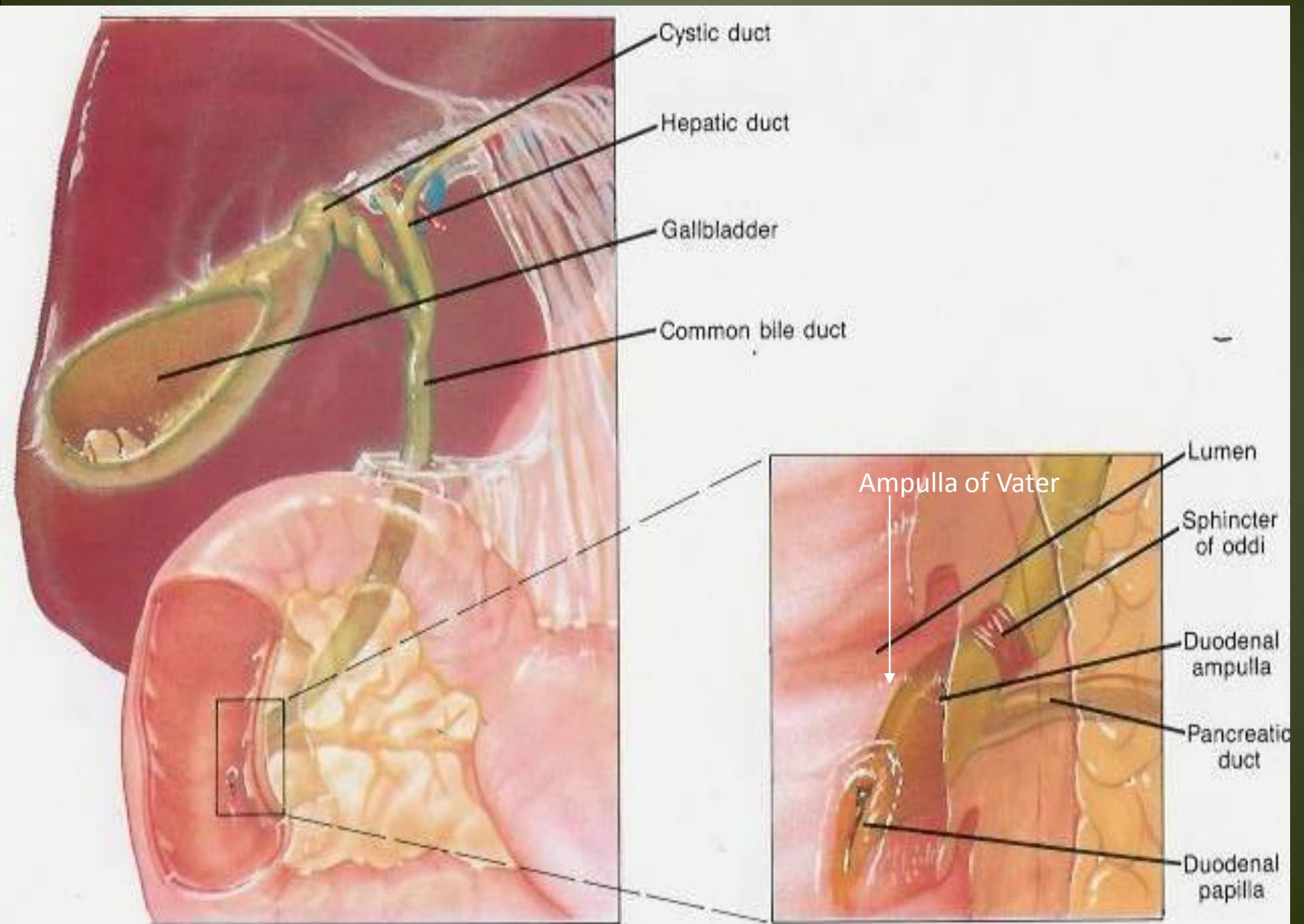


Junction of Bile Duct and Duodenum

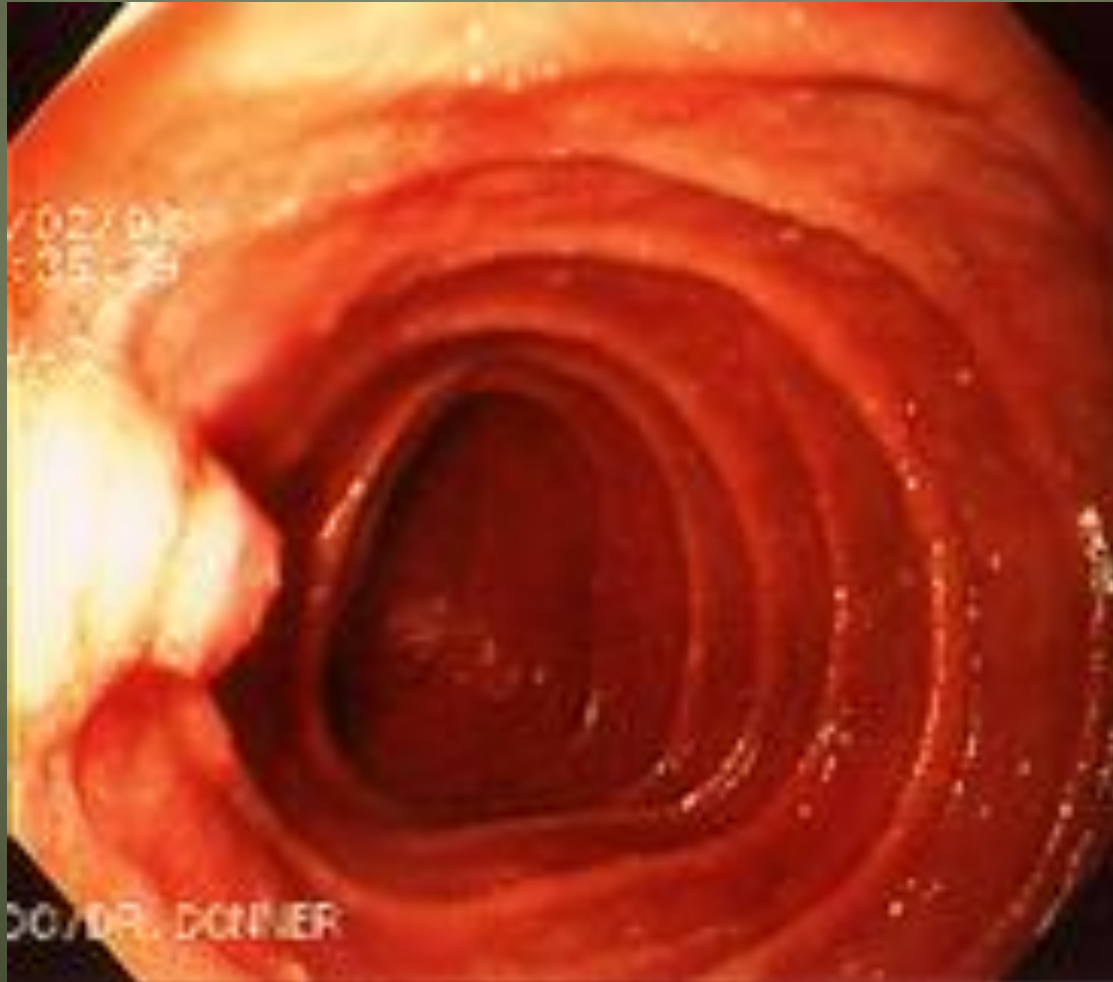Dissection



Ampulla of Vater with CBD and Pancreatic Duct



Hepaticopancreatic ampulla (Ampulla of Vater)



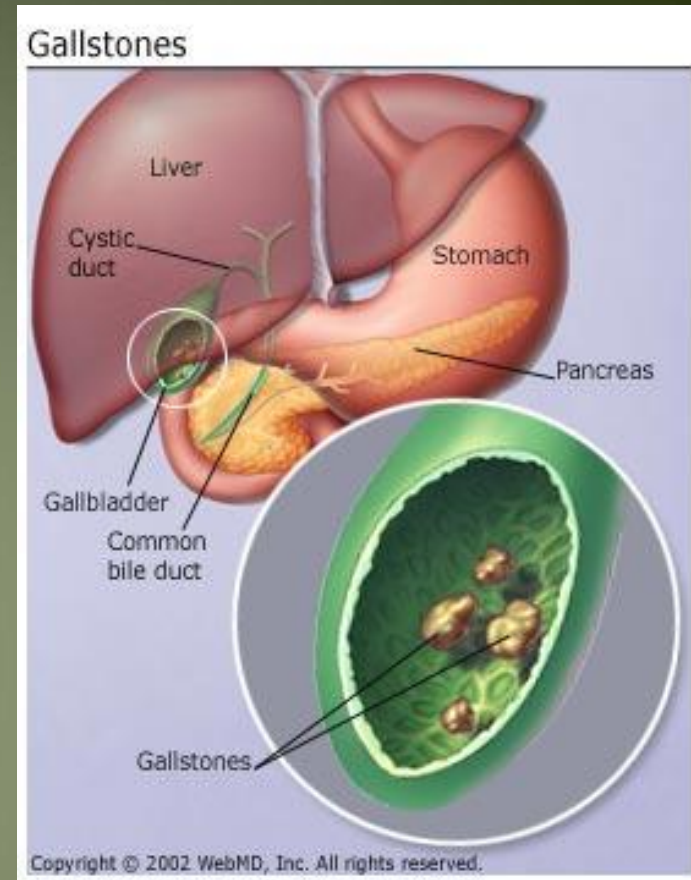
Blood supply of CBD

Small arteries supplying CBD

- a. Arise from cystic artery
- b. Posterior branch of superior pancreaticoduodenal artery

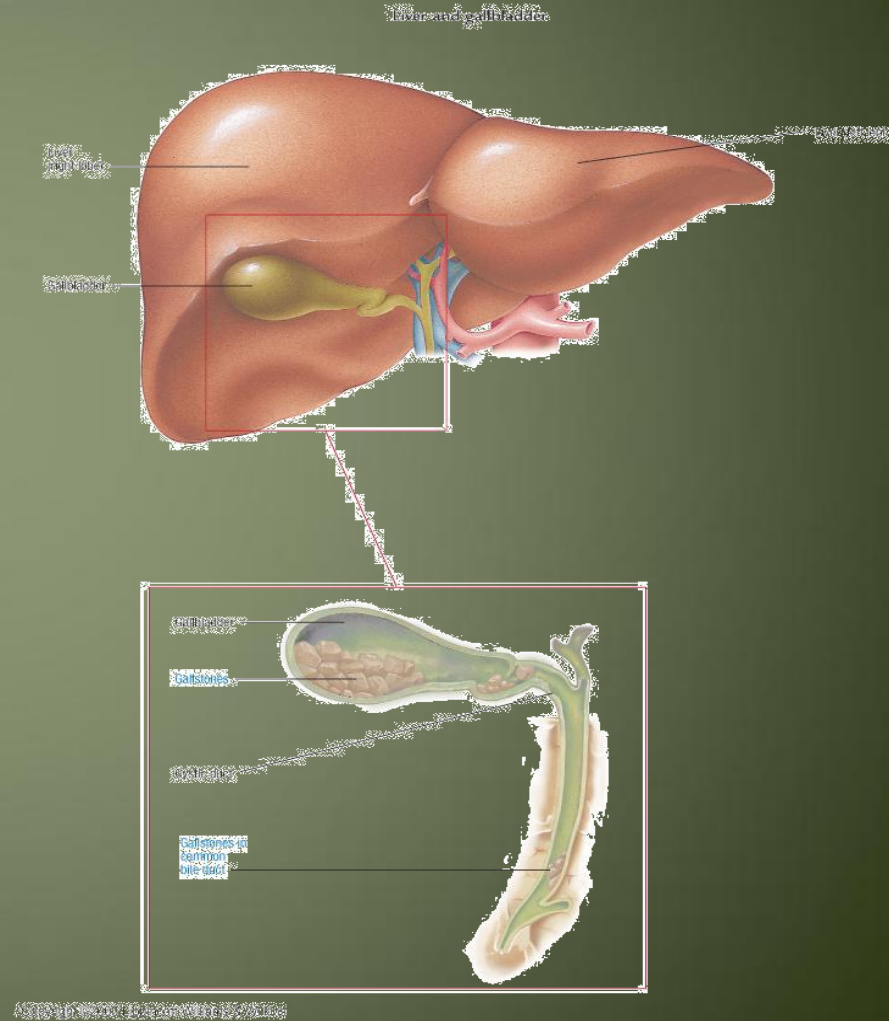
What is bile?

- Bile composed of water, ions, bile acids, organic molecules (including cholesterol, phospholipids, bilirubin)
- Gallstones are mostly cholesterol
- Acids and salts emulsify fats for absorption across wall of small intestines into lacteal lymph capillaries (review)
- Contains waste products from RBC breakdown and other metabolic processing (color of feces from bilirubin in bile)(review)
- Ions buffer chyme from stomach (review)



Cholelithiasis

- GB shows likely sites of stone formation/deposition
- Gangrene of gallbladder is rare
- Stone in C.B.D obstruct jaundice & pancreatitis



Gallbladder Diseases

1- Cholelithiasis & Cholecystitis

Cholecystitis = inflammation of GB

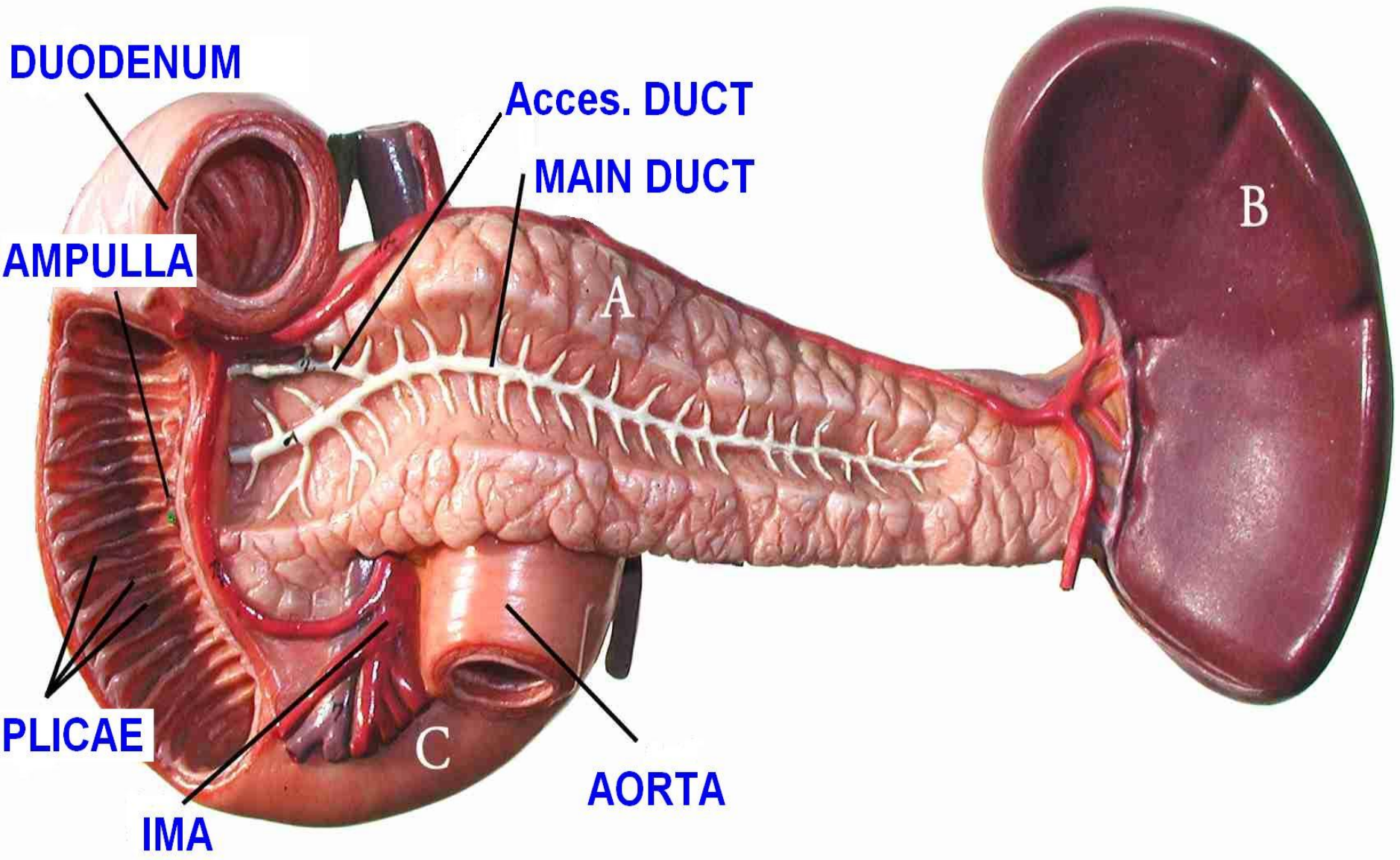
Cholelithiasis = Stone(s) in GB

2- Obstructive jaundice: liver patterns

3- Gangrene of gall bladder rare

4- Congenital defects

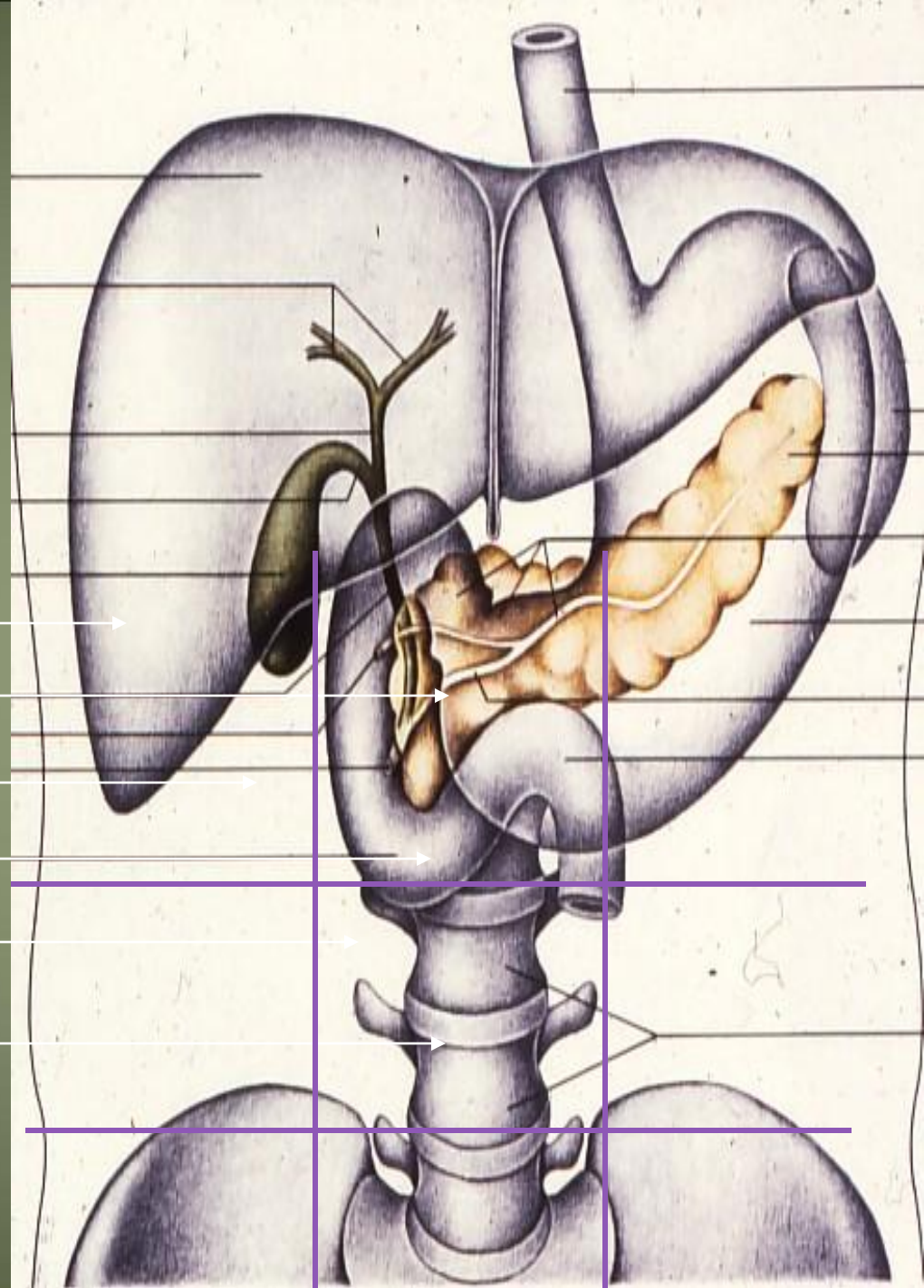
PANCREAS



Anatomical position

- Epigastric
- left upper hypochondrium region

- Right lobe of liver
- Falciform ligament
- Gallbladder
- Pancreas
- Duodenum
- L-3



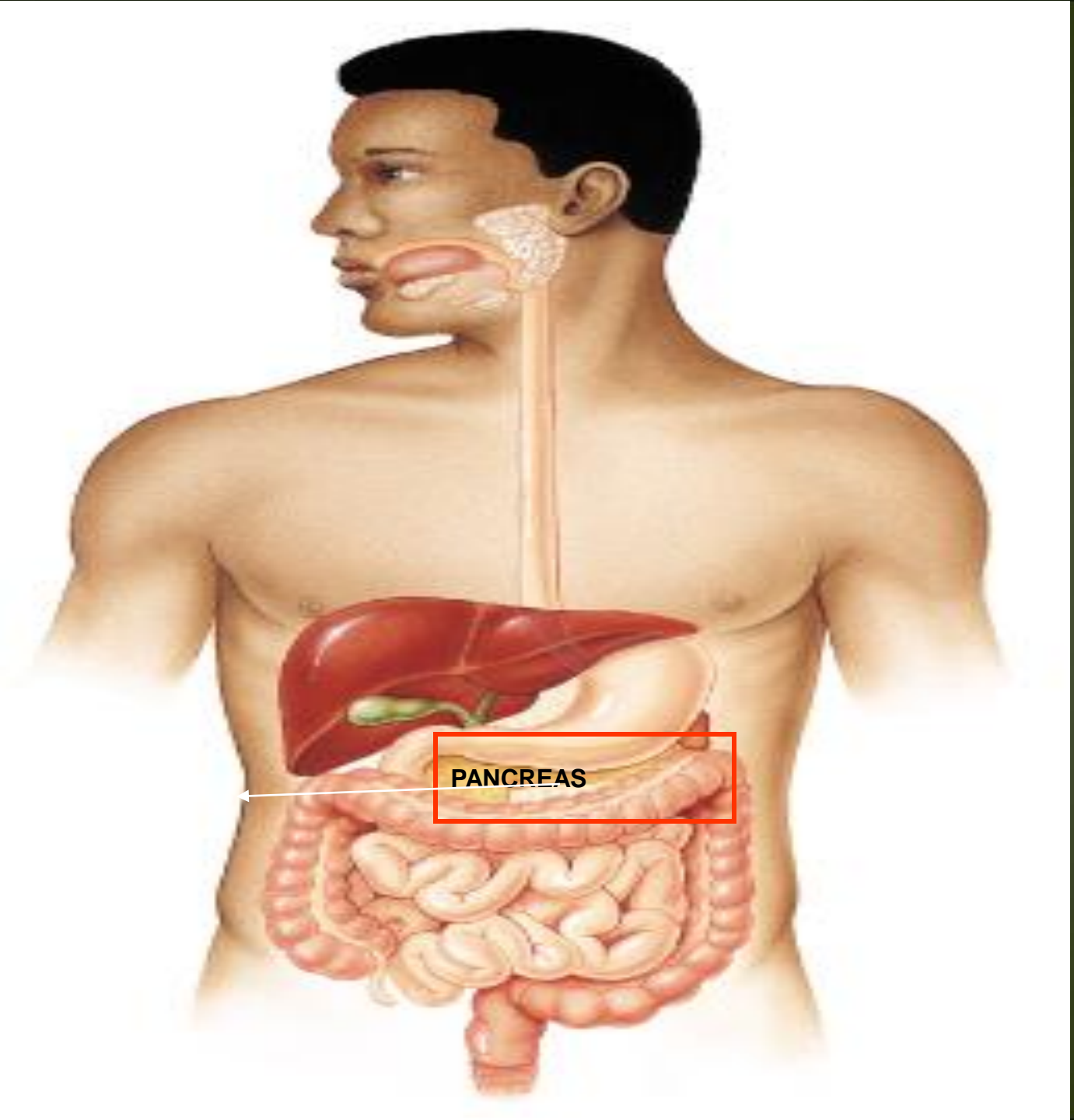
Common relation

Anterior

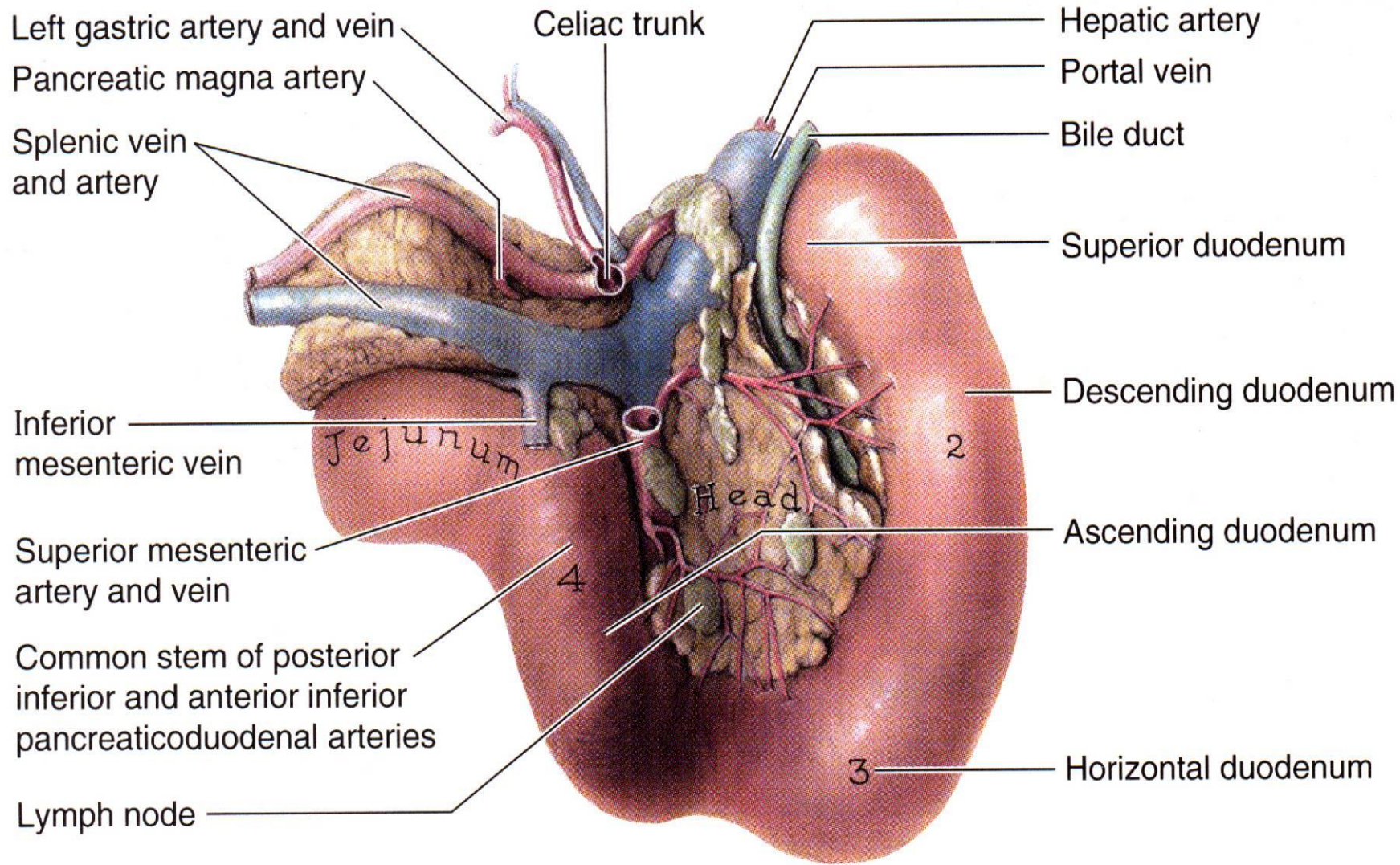
- Transverse colon
- Transvers mesocolon
- Lesser sac
- Stomach

-Posterior

- Bile duct
- Portal vein
- Splenic vein
- IVC
- Aorta
- origin of Sup.mesentric.a
- Lt.Psoas muscle
- Lt.Suoprenal gland
- Left kidney
- Hilum of the spleen



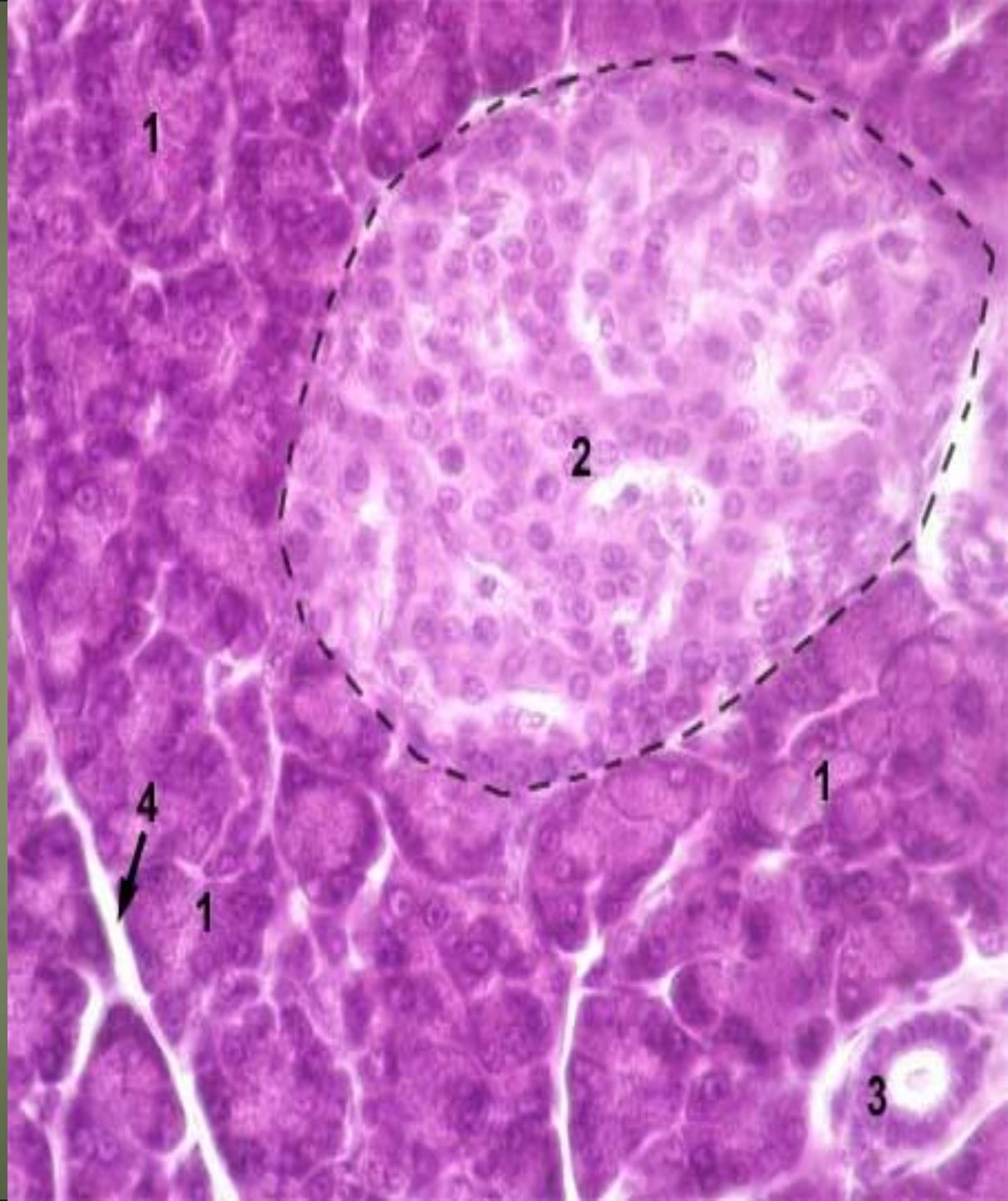
Posterior view of duodenum/pancreas



Histology of pancreas

Exocrine part → Pancreatic juice

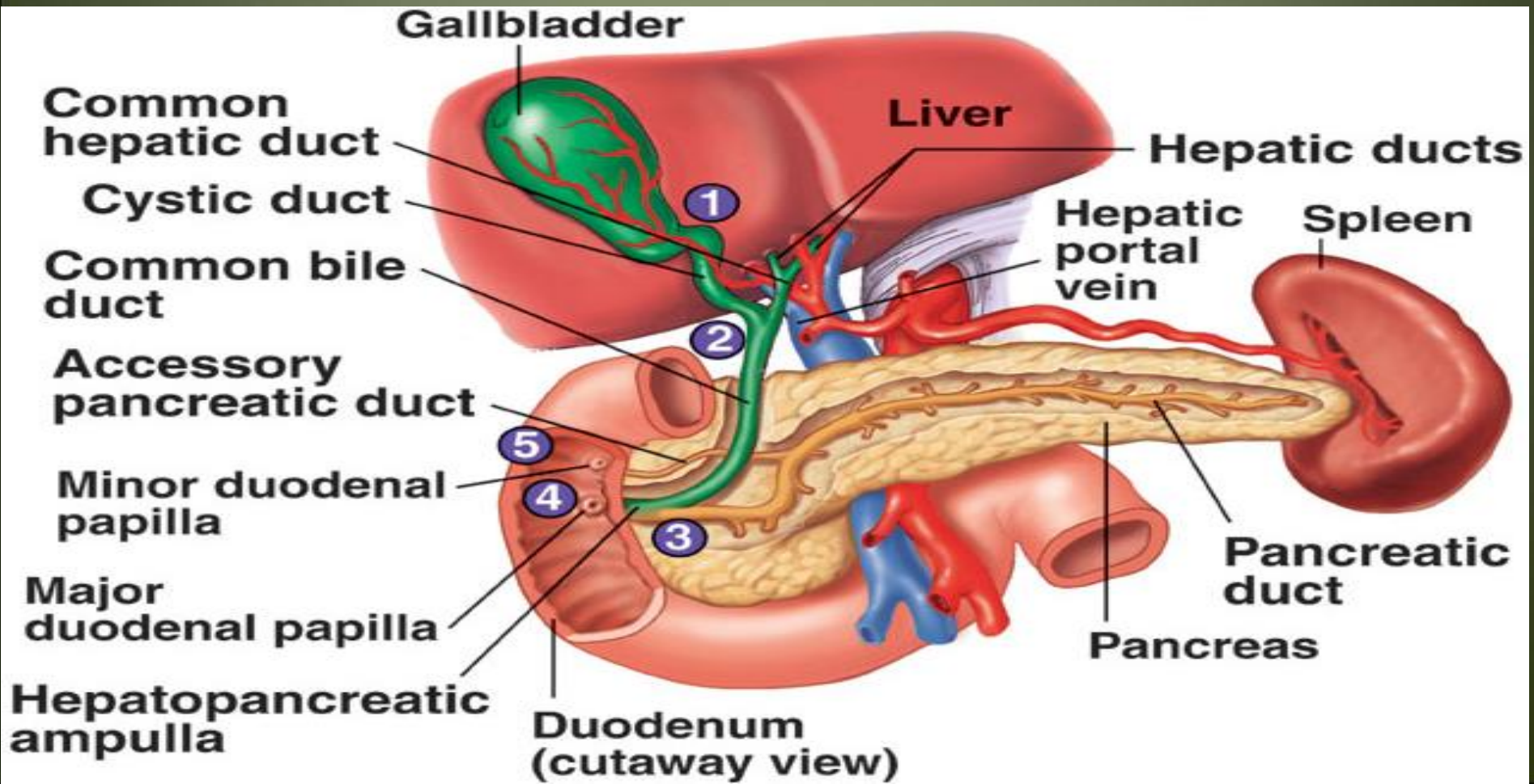
Endocrine part → Insulin, glucagon and somatostatin



Parts of the pancreas

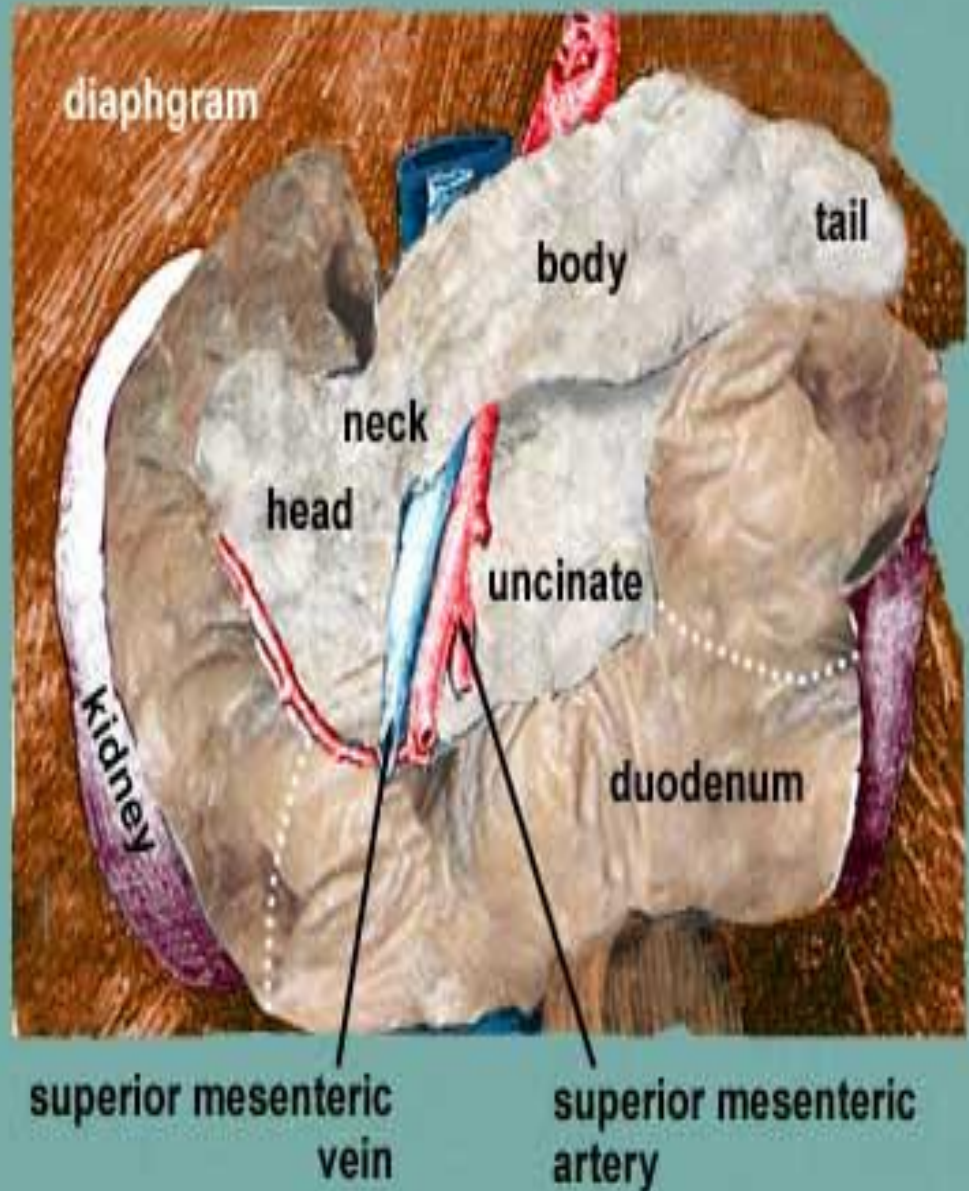
Parts

- Head
- Neck
- body
- Tail



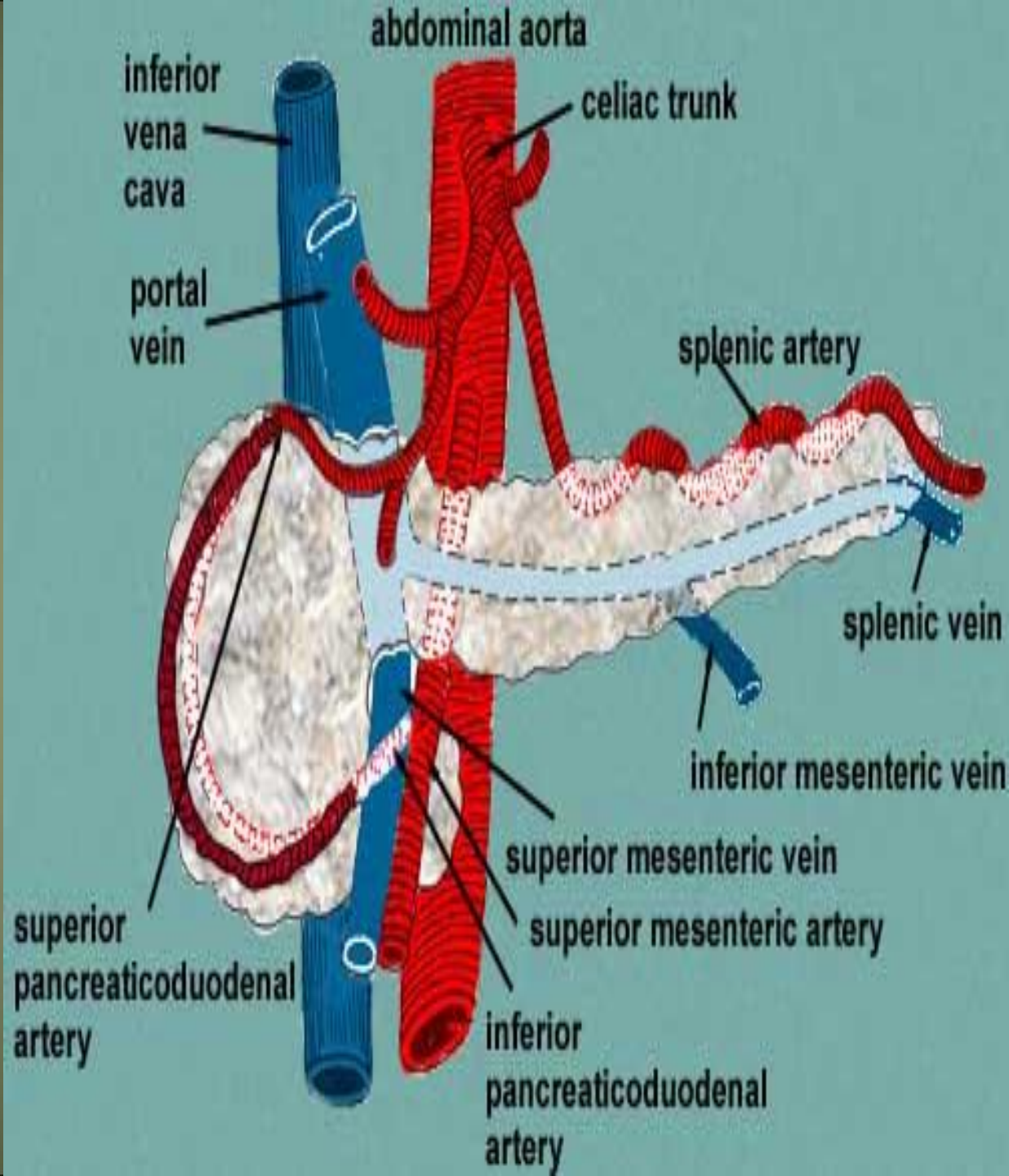
The head

- It is disc shaped
- lies within the concavity of the duodenum
- A part of the head extends to the left behind the superior mesenteric vessels and is called the **Uncinate process**.



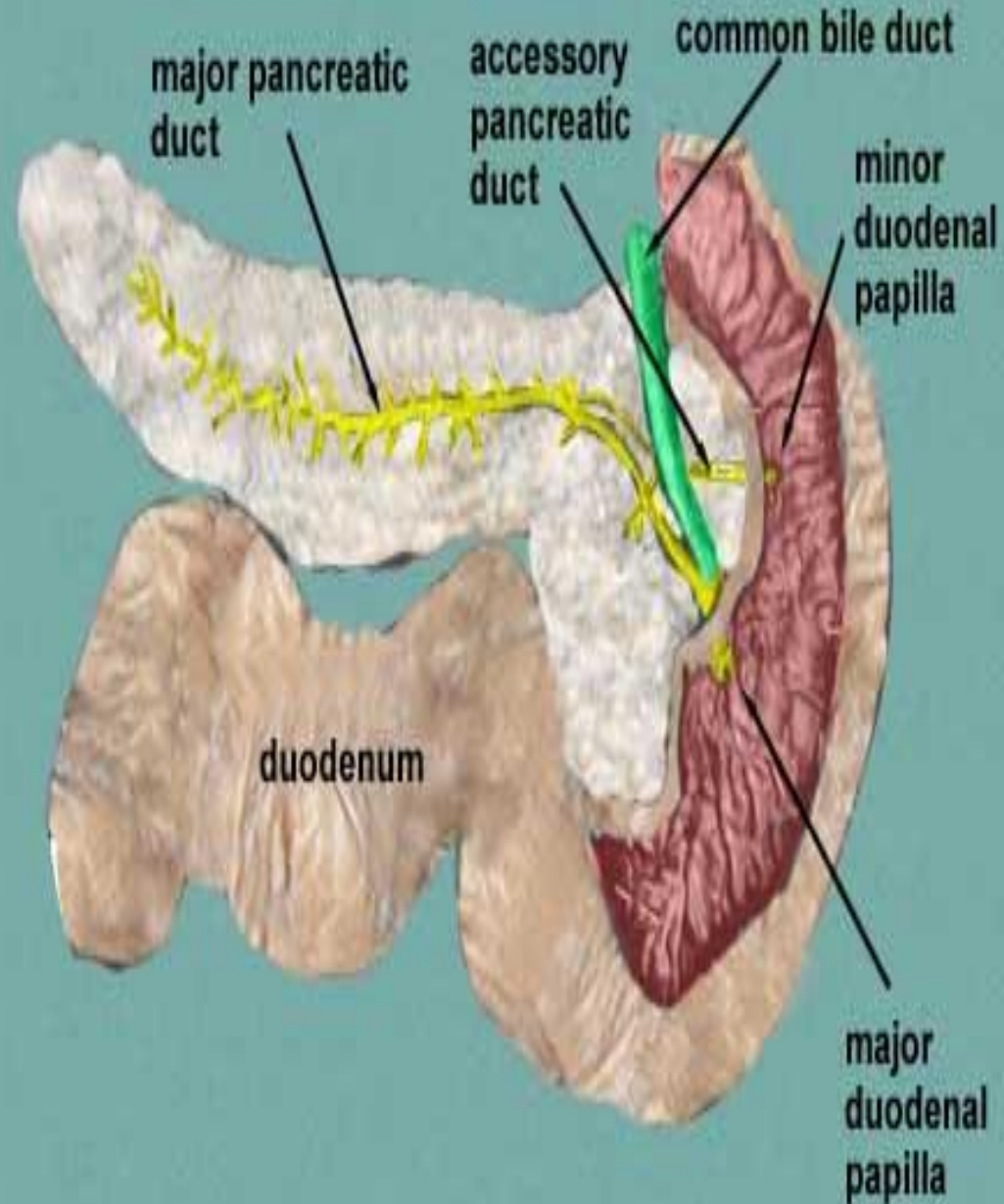
The neck

- It is the constricted portion of the pancreas
- connects the head to the body.
- It lies in front of the beginning of **the portal vein** the origin of the



The body

- Runs upward and to the left across the midline
- It is somewhat triangular in cross section.



Body of pancreas...cont

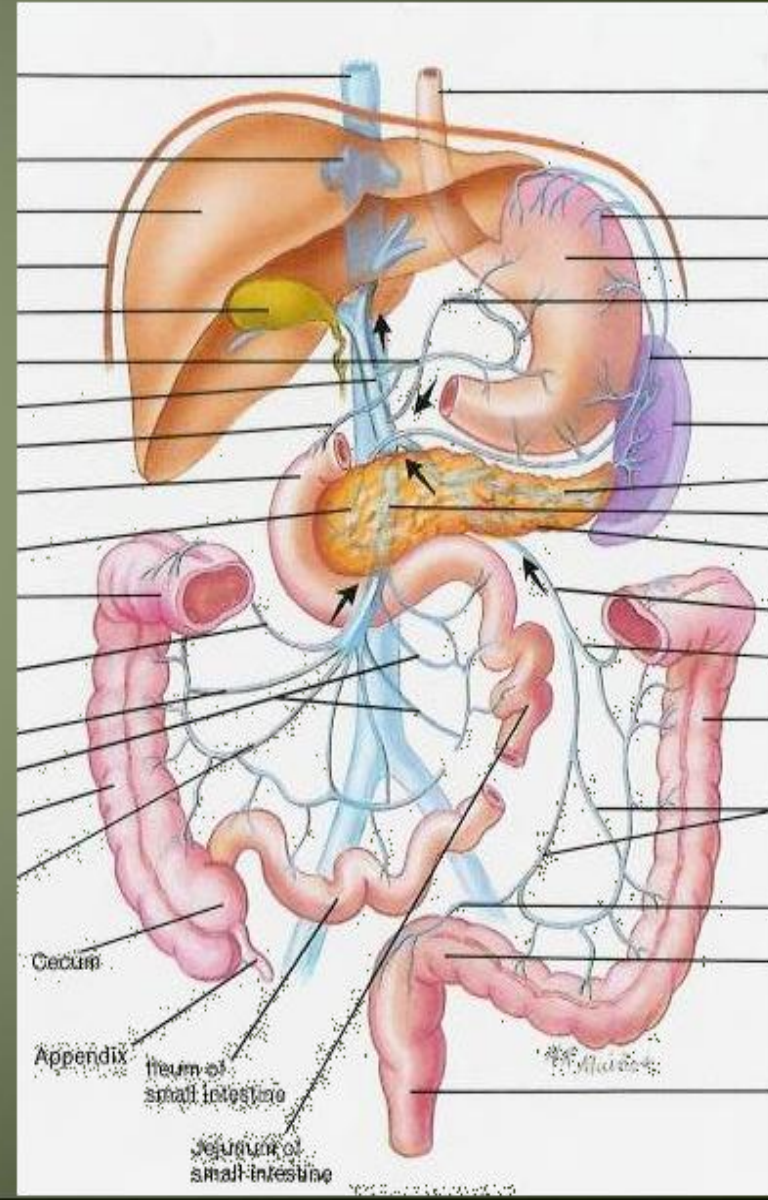
- Three surfaces: **anterior, posterior, and inferior.**
- Three borders: **ant ,post & inf**

The anterior surface

1- Covered by peritoneum of post. Wall of lesser sac

2- **Tuber omental :**

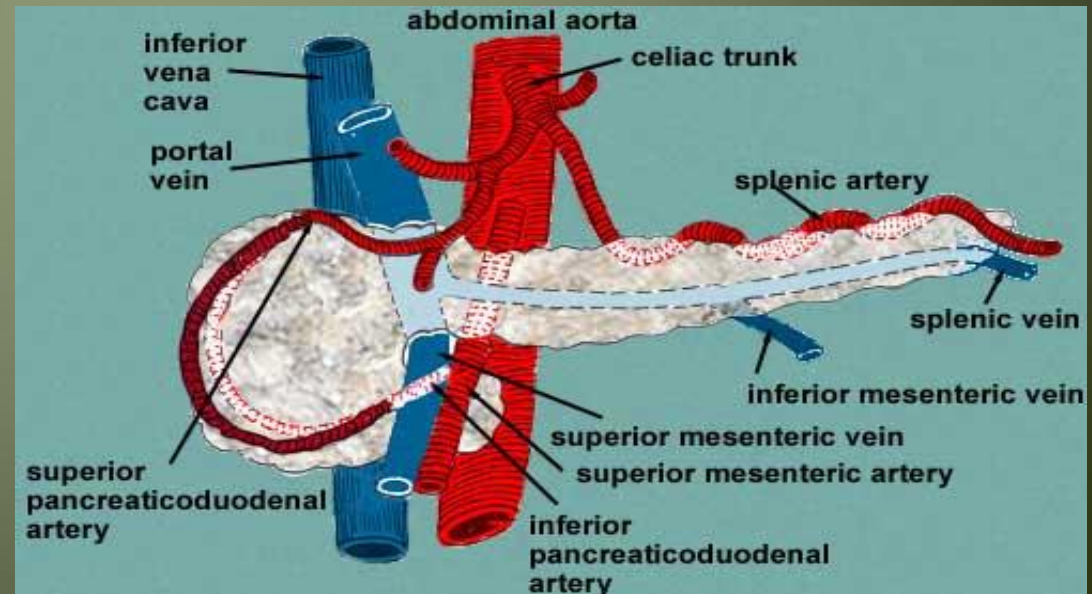
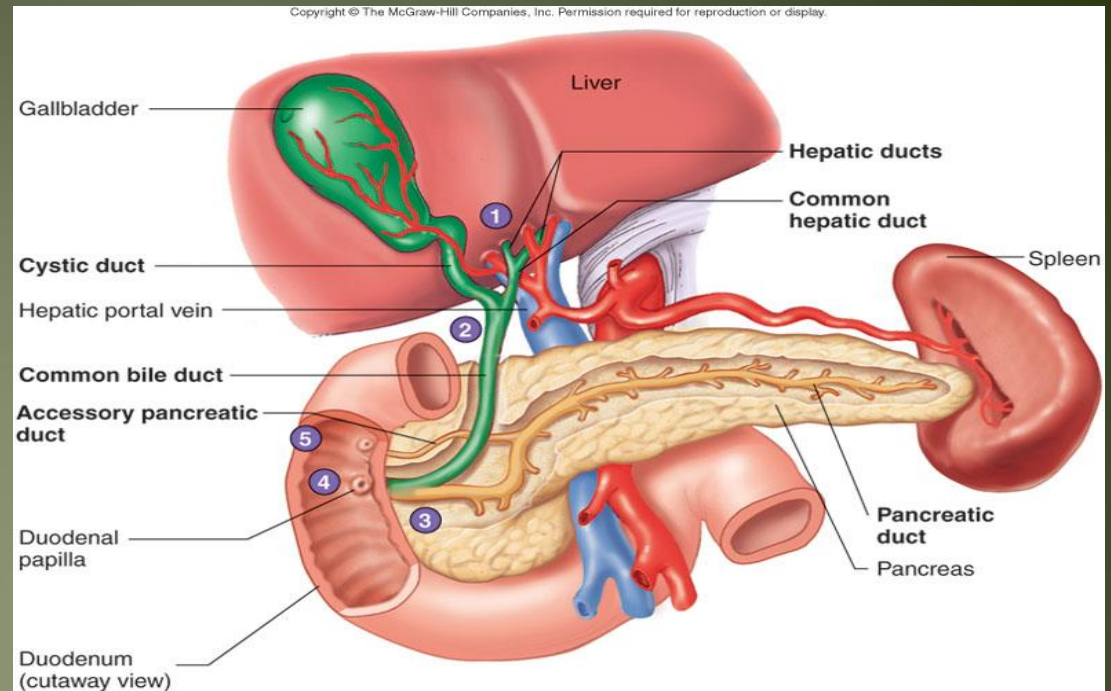
where the ant. surface of pancreas join the neck



Body of pancreas...cont

The posterior surface

- devoid of peritoneum
- in contact with
 - 1- the aorta
 - 2- the splenic vein
 - 3- the left kidney and its vessels
 - 4- the left suprarenal gland
 - 5- the origin of the superior mesenteric artery
 - 6- and the crura of the diaphragm.



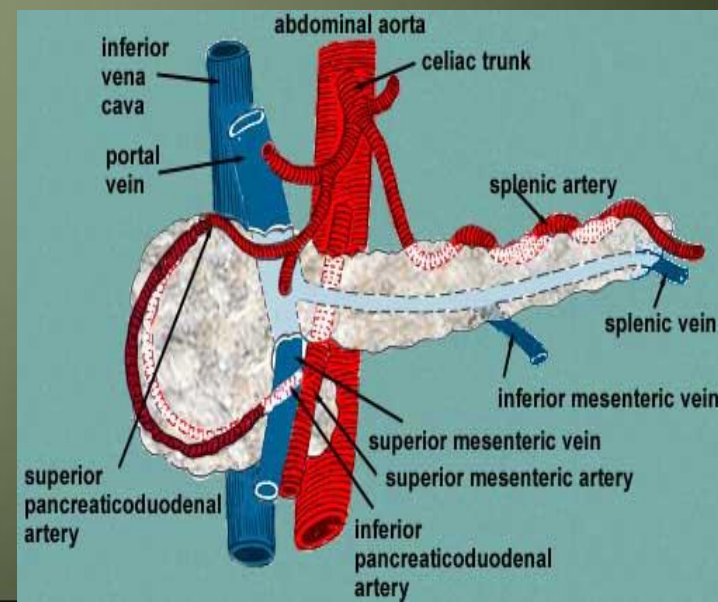
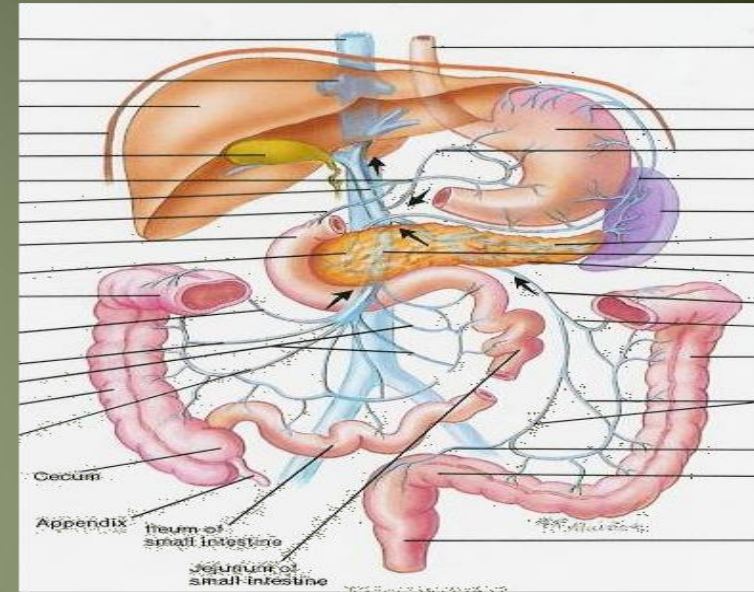
Body of pancreas...cont

- **The inferior surface**

- Narrow on the right but broader on the left
- Covered by peritoneum of greater omentum
- lies upon the duodenojejunal flexure
- Some coils of the jejunum
- its left extremity rests on the left colic flexure

- **The superior border**

- Blunt and flat to the right;
- Narrow and sharp to the left near the tail
- It commences on the right in the omental tuberosity
- In relation with
 - 1- The celiac artery
 - 2- Hepatic artery
 - 3- The splenic artery runs toward the left in a groove along this border.



Body of pancreas...cont

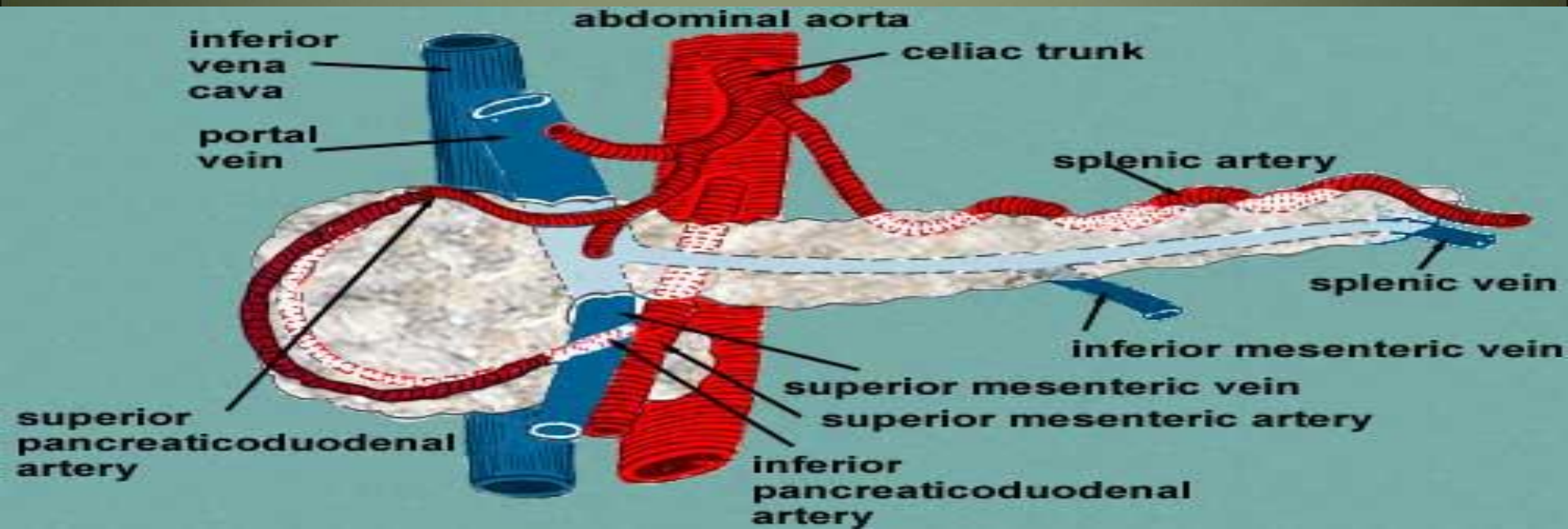
The anterior border

- separates the anterior surface from the inferior surface
- along this border the two layers of the transverse mesocolon diverge from one another; one passing upward over the anterior surface, the other backward over the inferior surface.

Body of pancreas

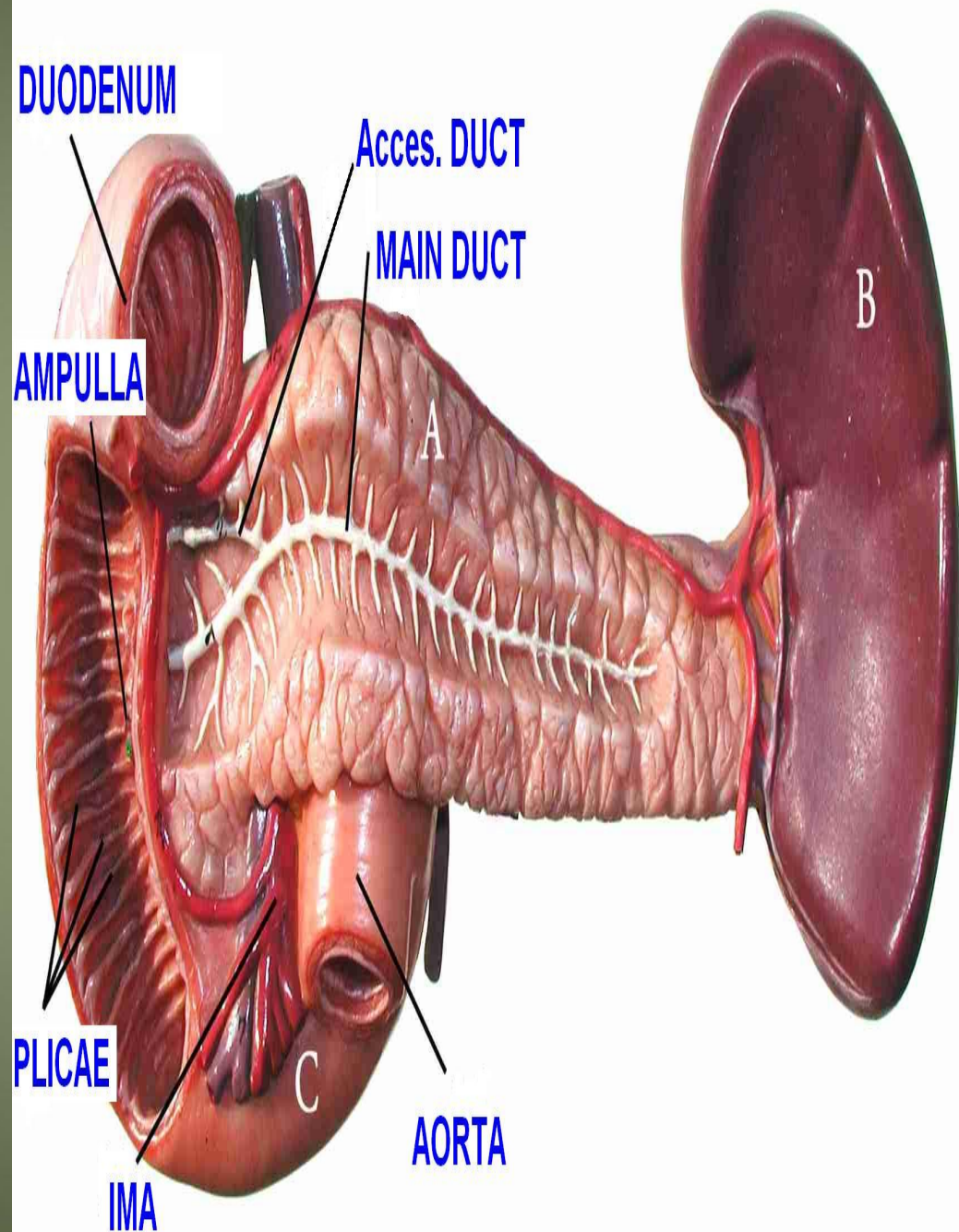
The inferior border

- separates the posterior from the inferior surface
- the superior mesenteric vessels emerge under its right extremity.



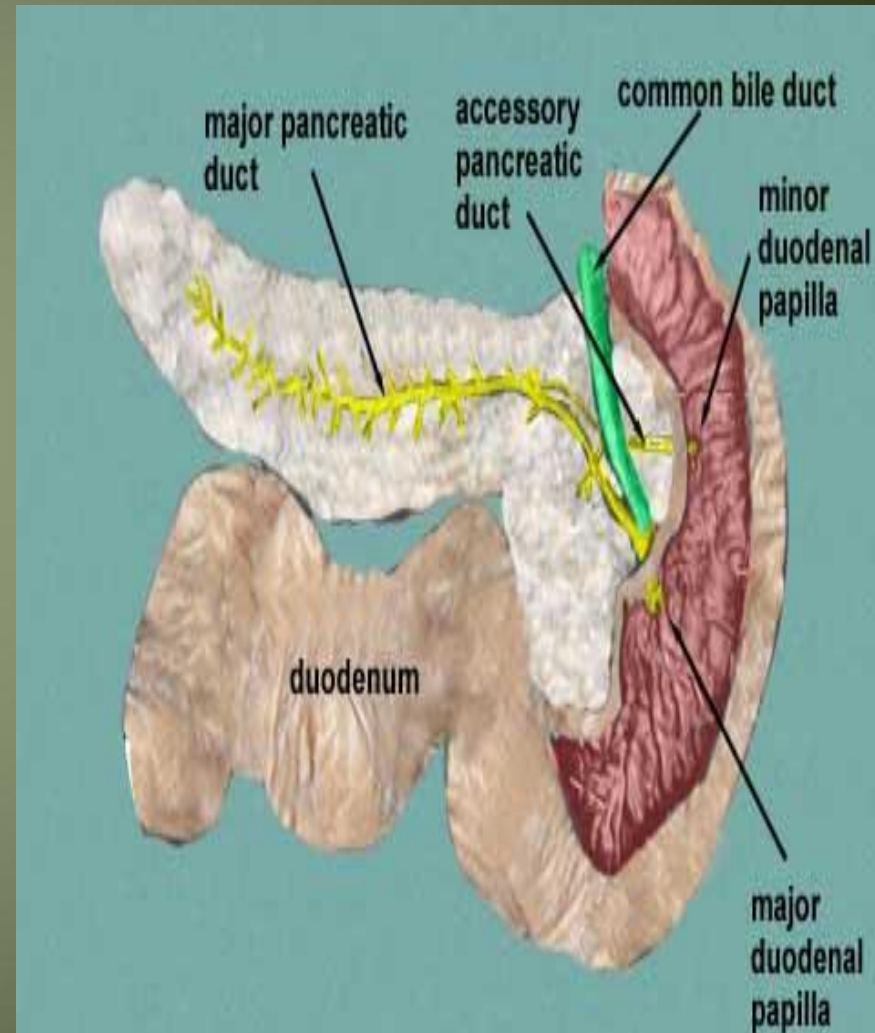
The Tail

- Passes forward in the **splenicorenal** ligament and comes in contact with the hilum of the spleen



Pancreatic ducts

- **The main duct**
 - Begins in the tail and runs the length of the gland
 - Receiving numerous tributaries on the way .
 - It opens into the second part of the duodenum at about its middle with the bile duct on the **major duodenal papilla**
- **Accessory duct**
 - When present, drains the upper part of the head
 - Then opens into the duodenum a short distance above the main duct on the minor duodenal papilla .
 - The accessory duct frequently communicates with the main duct



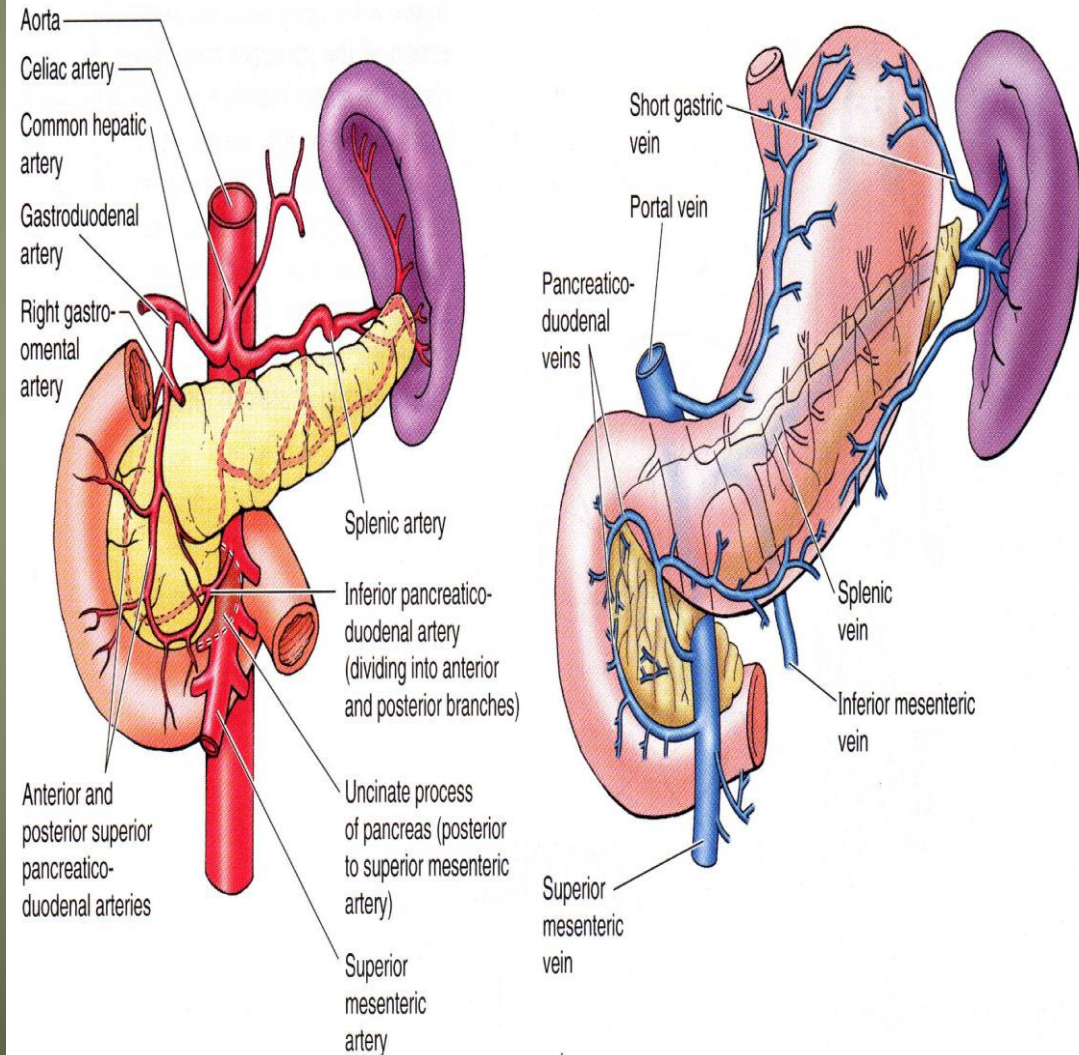
Blood Supply of pancreas

Arteries

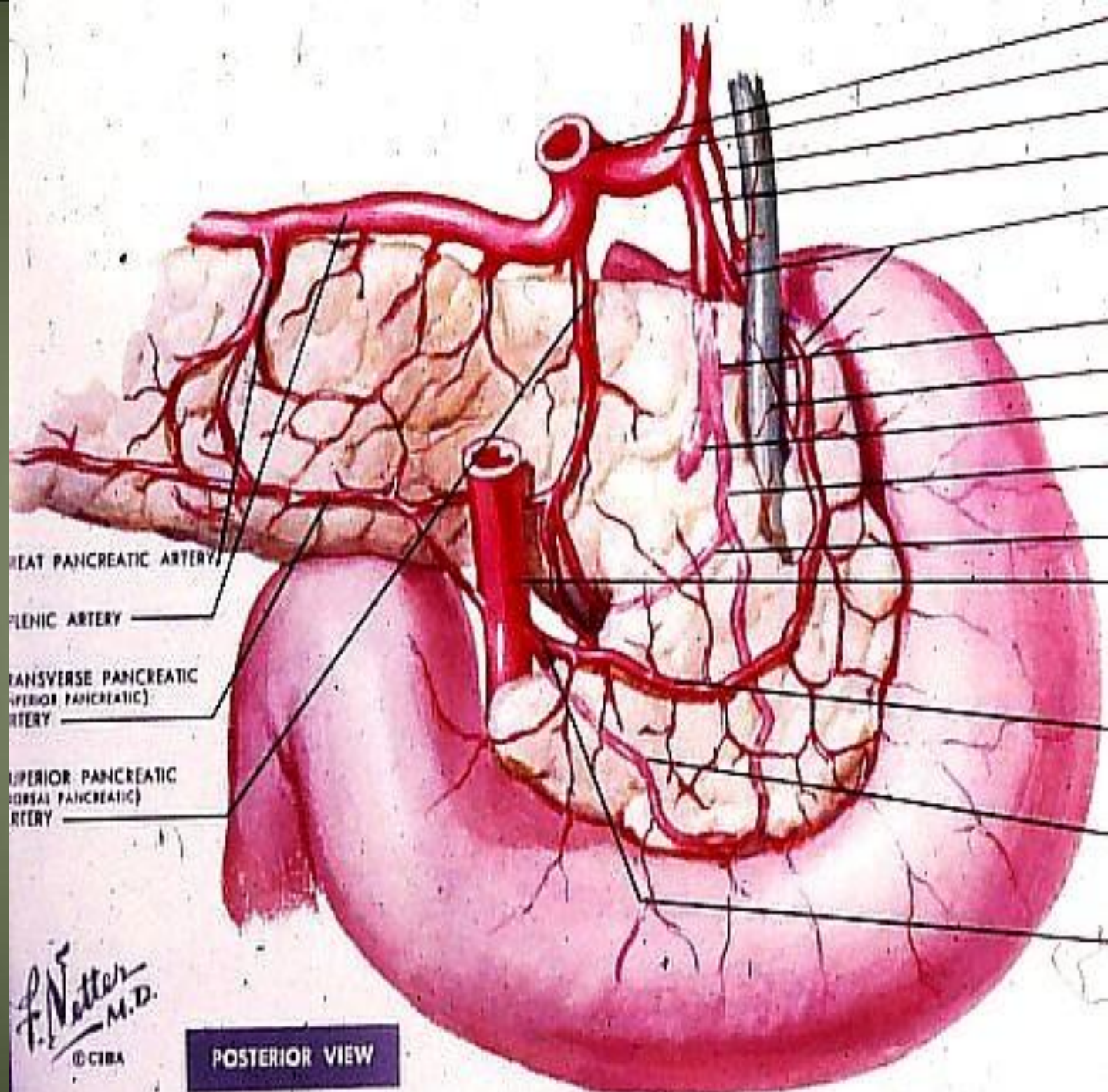
- The splenic.a
- The superior pancreaticoduodenal .a
- Inferior pancreaticoduodenal arteries.a

Veins

- The corresponding veins drain into the portal system.

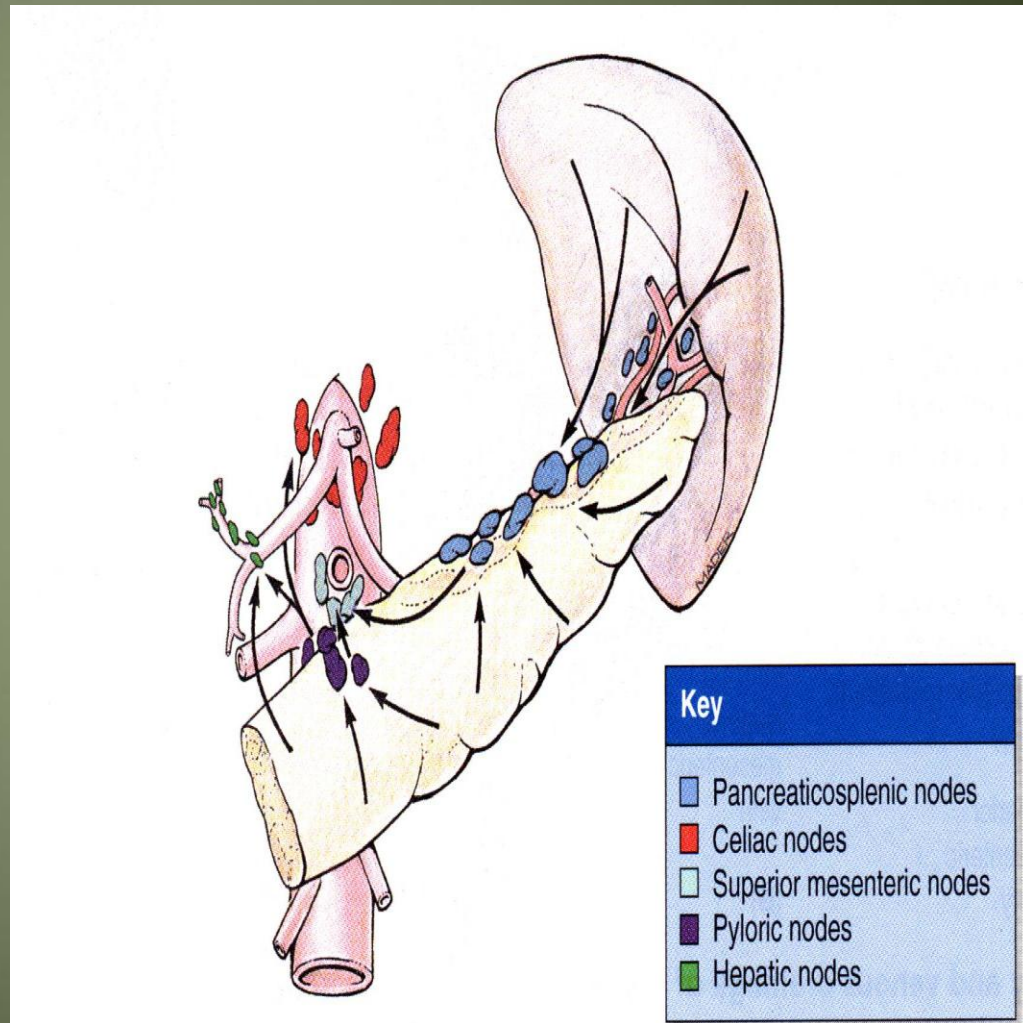


pancreaticoduodenal artery and its branches



Lymphatic drainage of pancreas

- Lymph nodes are situated along the arteries that supply the gland.
- The efferent vessels ultimately drain into the **celiac** and **superior mesenteric lymph nodes**.



Nerve supply

- Sympathetic and parasympathetic chain
- Parasympathetic = vagus nerve

Congenital defects of pancreas

- **Annular Pancreas** (pancreas encircles duodenum) (rare)
- **Ectopic Pancreas** (very common)= Outside the gastrointestinal tract

Clinical notes

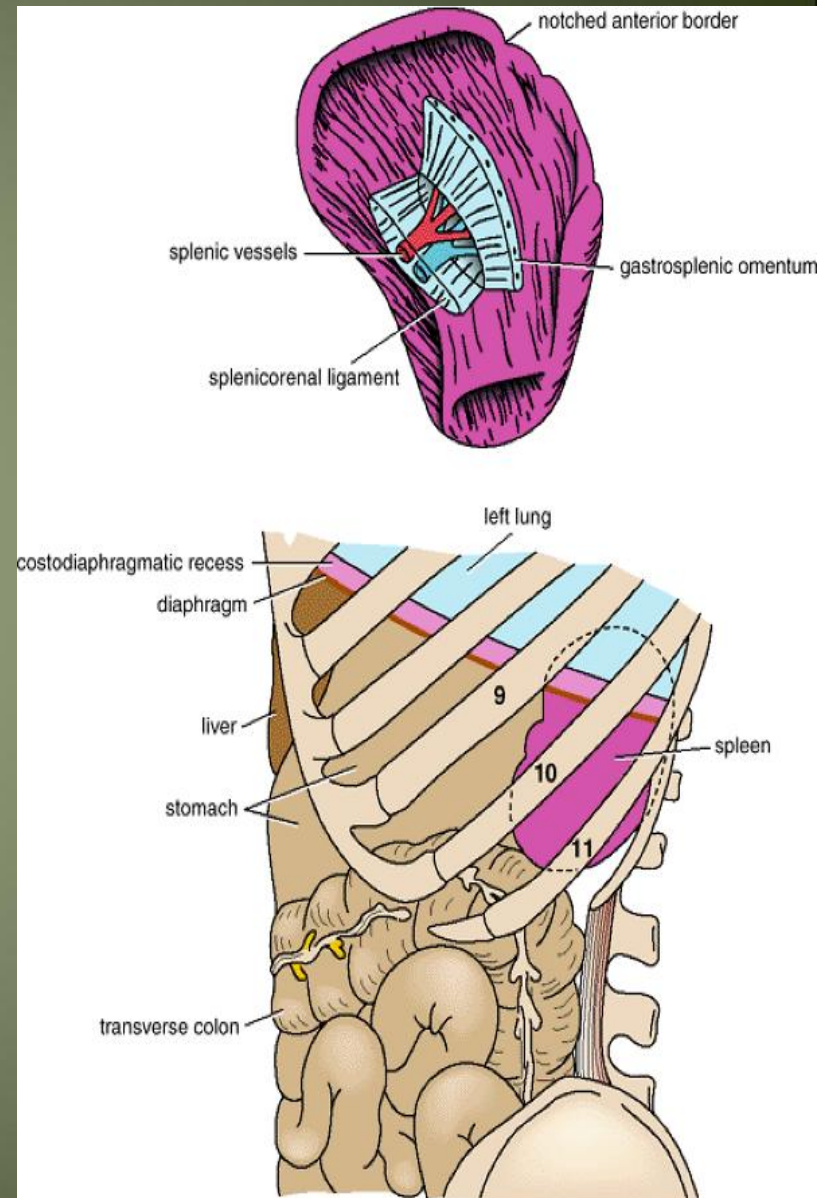
- Cancer head of pancreas → Obstruction jaundices
- Cancer body of pancreas → pressure → I.V.C & portal vein
- Acute pancreatitis= inflammation of pancreas

Spleen

Spleen

Location and Description

- it is reddish & oval shaped
- the largest single mass of lymphoid tissue in the body.
- and
- has a notched anterior border.
- **location:**
 - Lt hypochondrium
 - It lies just beneath the left half of the diaphragm
 - under the 9th, 10th, and 11th ribs.
 - Its long axis parallel to the 10th rib
 - Medial end is 4 cm away from mid line post
 - Lat.end is in left mid axillary line



Spleen

- **Peritoneum**

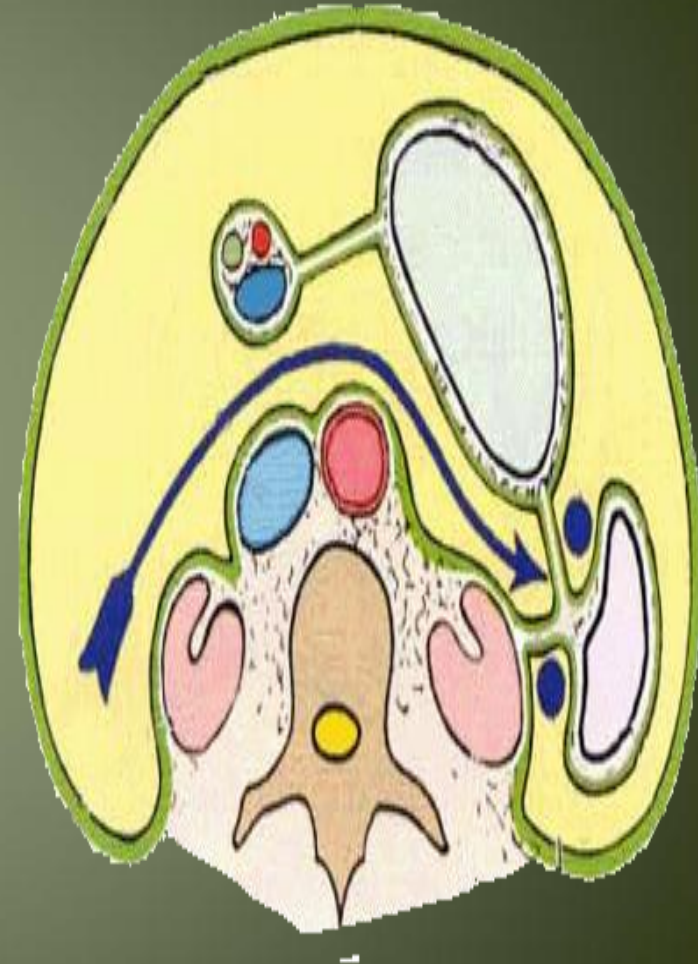
- The spleen is completely covered with peritoneum → **intraperitoneal** organ

- **Two ligaments**

- 1- **the gastrosplenic omentum**

(ligament) → between the spleen & the greater curvature of the stomach (carrying the short gastric and left gastroepiploic vessels)

- 2- **splenicorenal ligament** → between spleen & kidney (carrying the splenic vessels and the tail of the pancreas).



Spleen.....cont

Size

- 1 inch thick
- 3 inch broad
- 5 inch long

Weight

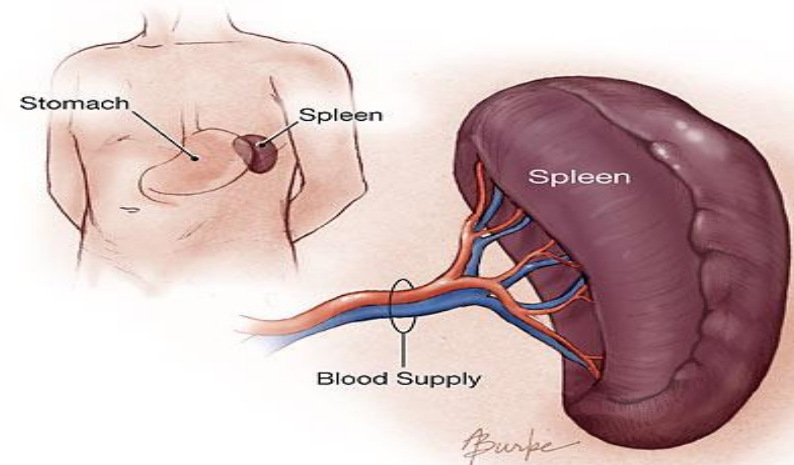
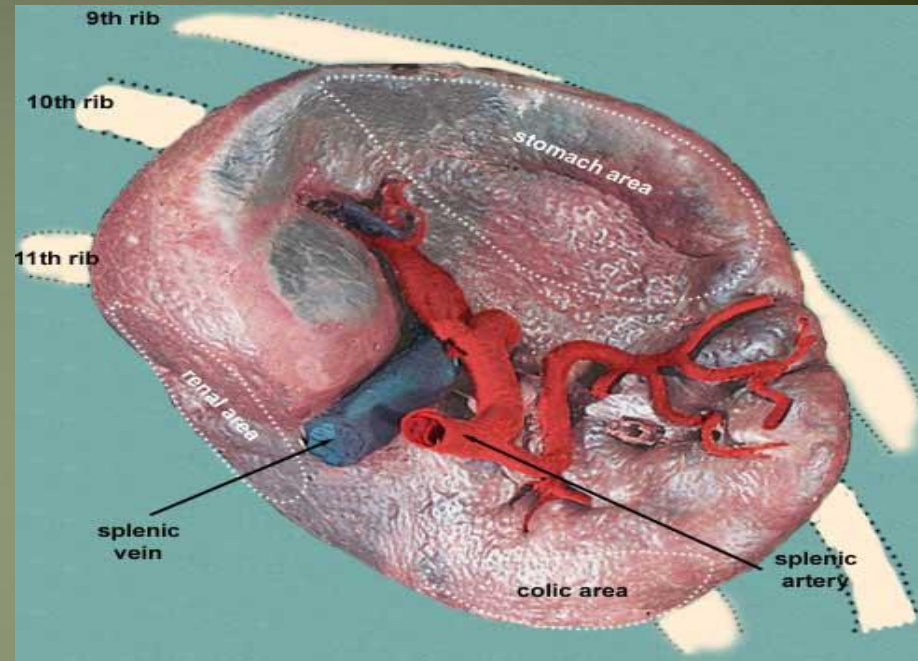
- 7 ounce

Shape → variable

- 2 ends
- 2 borders
- 2 surfaces

Notched

- Due to lobulation in embryo



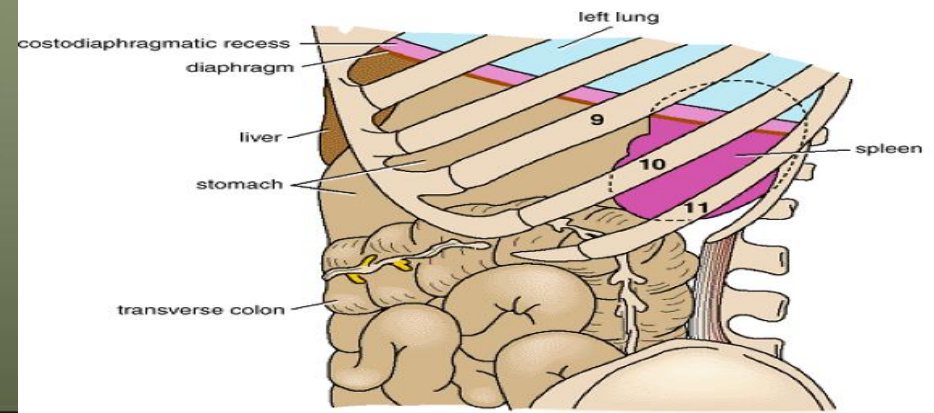
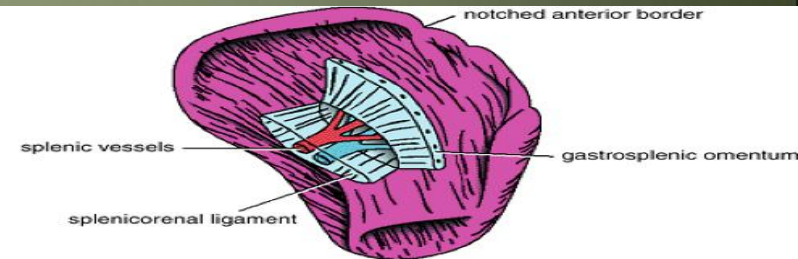
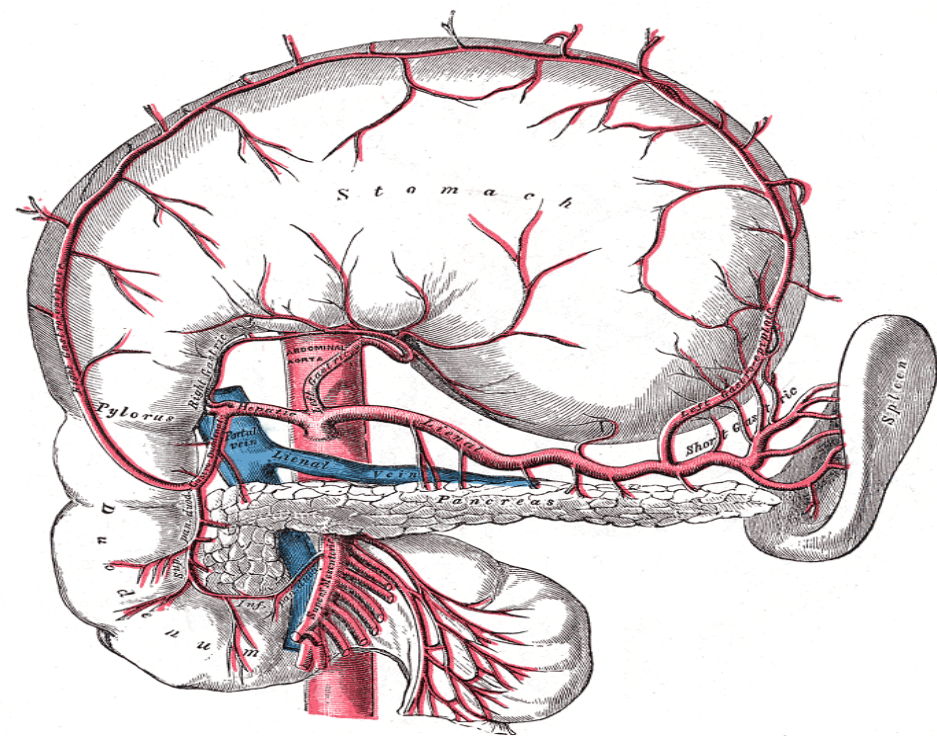
Surfaces of spleen

2 surfaces

- Diaphragmatic surface
- Visceral surface

1- Diaphragmatic surface

- Has Post- lat. relation
- Convex
- Smooth
- Diaphragm separates it from
 - Pleura & lung
 - Ribs 9,10 ,11



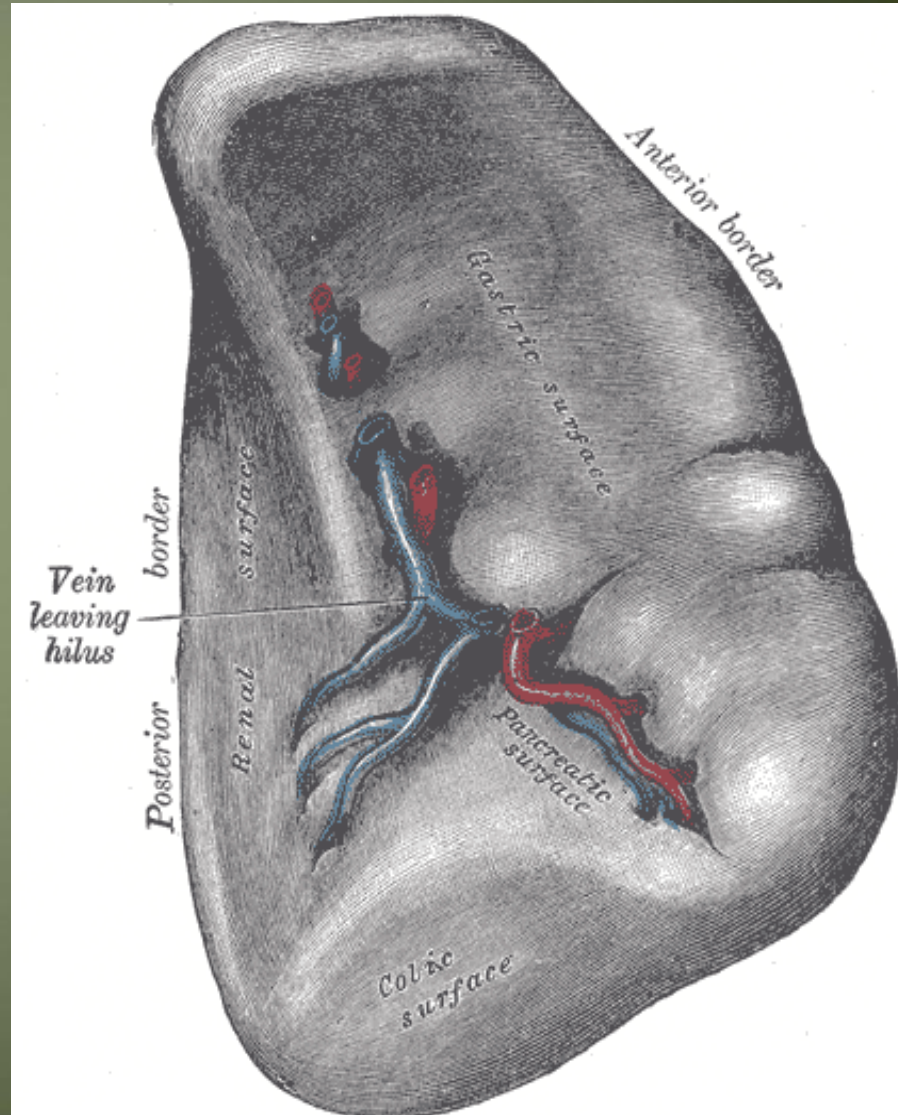
Spleen.....cont

2- Visceral surface

- Has Ant- med. Relations
- It is divided by a ridge into
 - 1- An anterior or gastric
 - 2- A posterior or renal portion.

Lower extremity has

- Colic surface
- Pancreatic surface



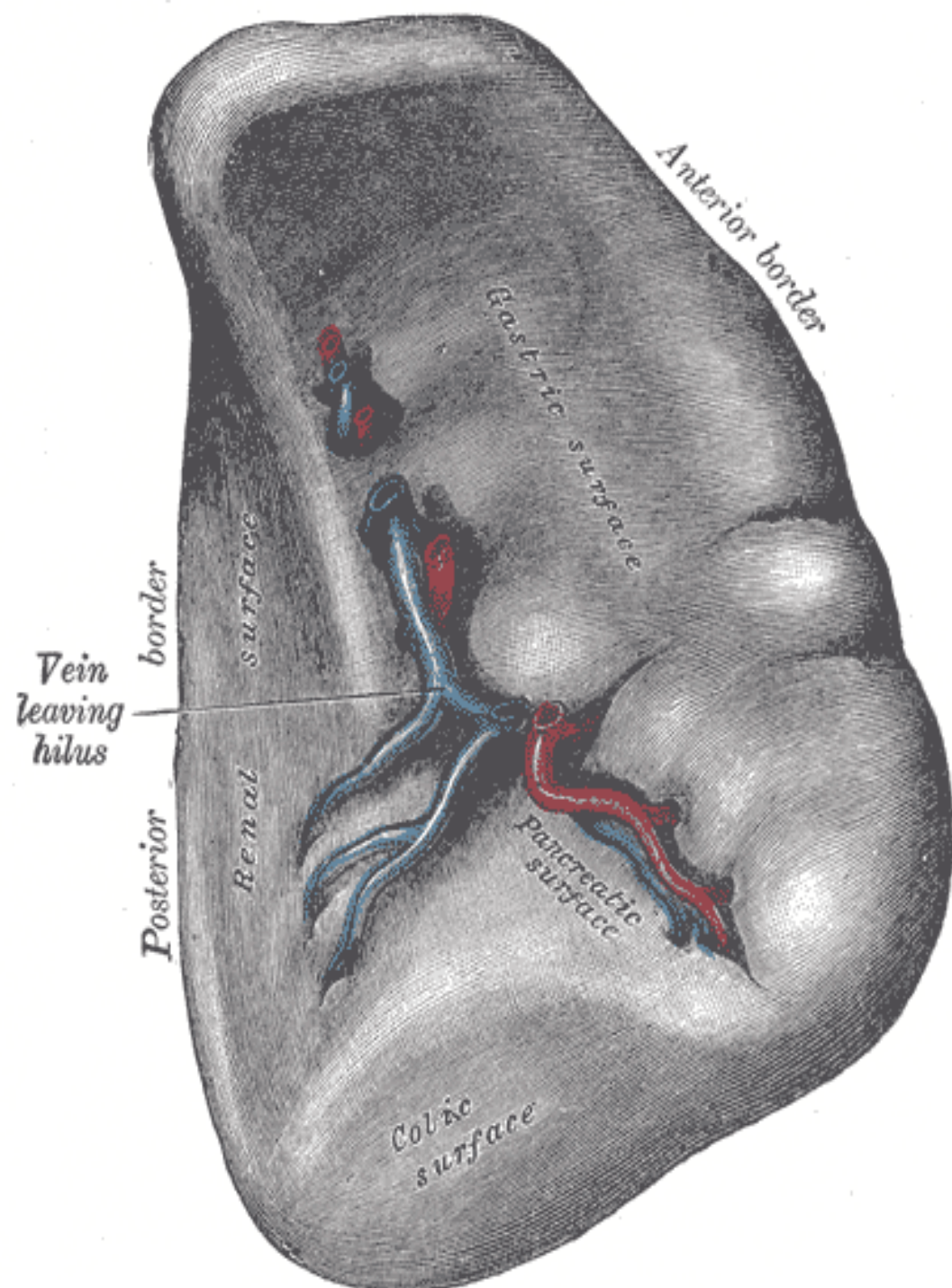
Spleen.....cont

Gastric surface

- Extends forward, upward, and medialward
- Broad and concave
- Related to stomach

Renal surface

- Directed medialward and downward.
- It is somewhat flattened
- Related to Lt.kidney



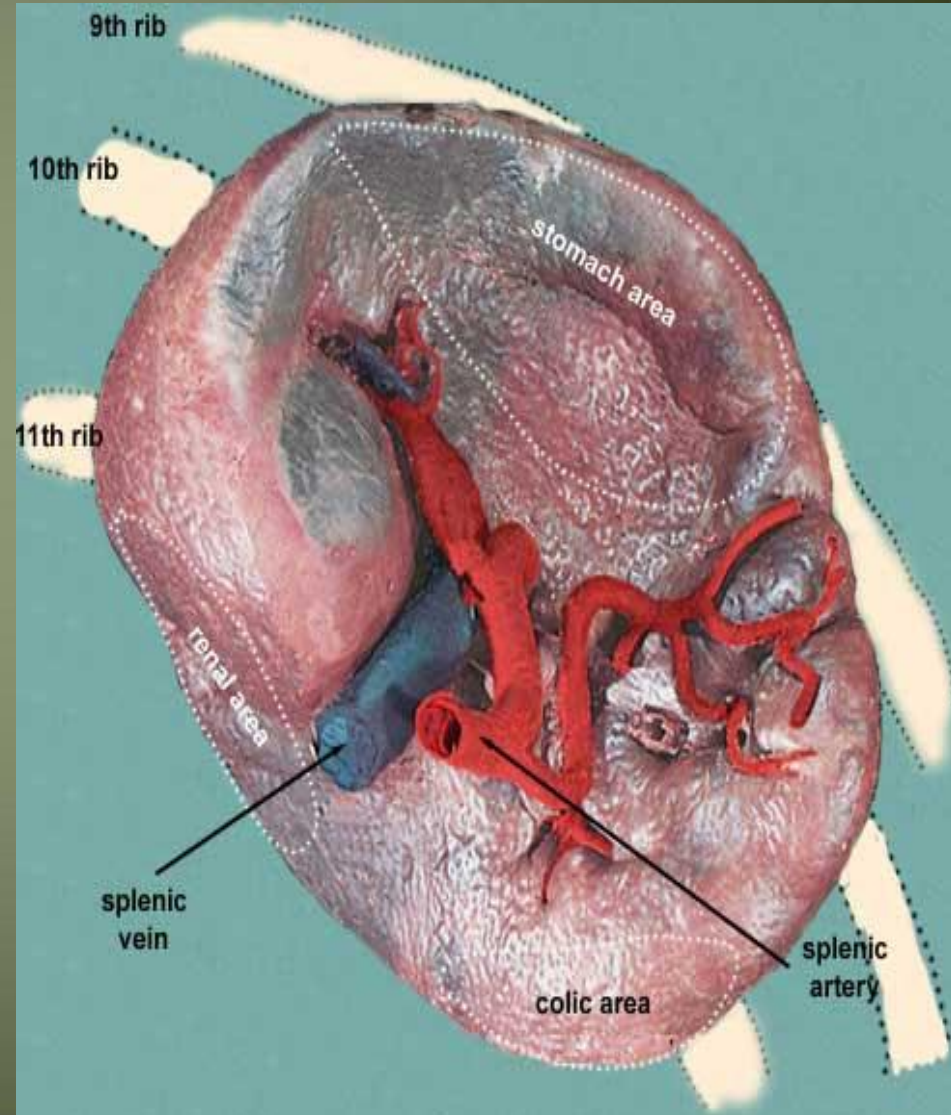
Spleen.....cont

The lower extremity or **colic surface**

- It is flat
- Triangular in shape
- Rests upon the left flexure of the colon and the phrenicocolic ligament, and is generally in contact with the tail of the pancreas(**pancreatic surface**)

Spleen...cont

- Hilum of spleen
 - Splenic . A → ant
 - Splenic . v → post
 - Tail of pancreas

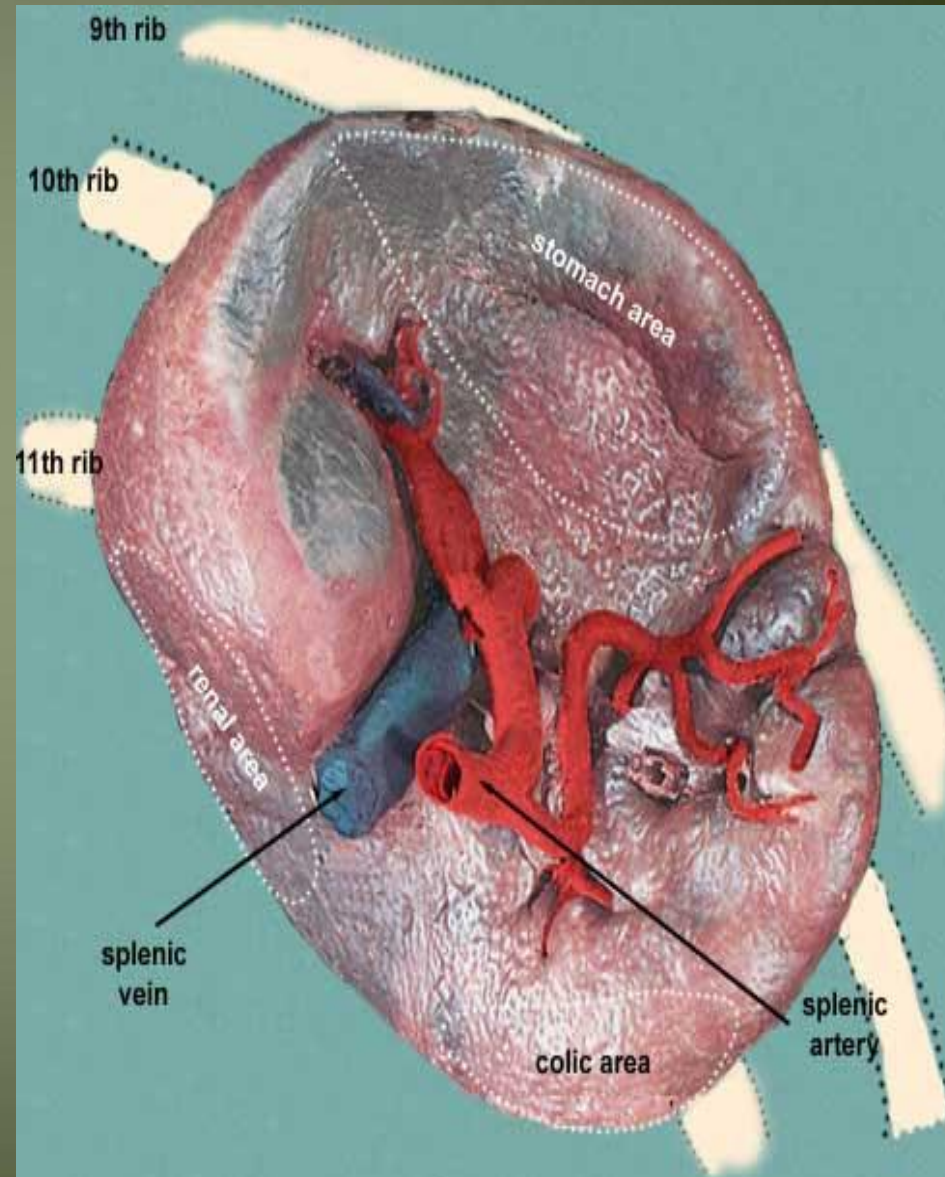


Spleen..cont

- Borders of spleen

- 1- sup. Border

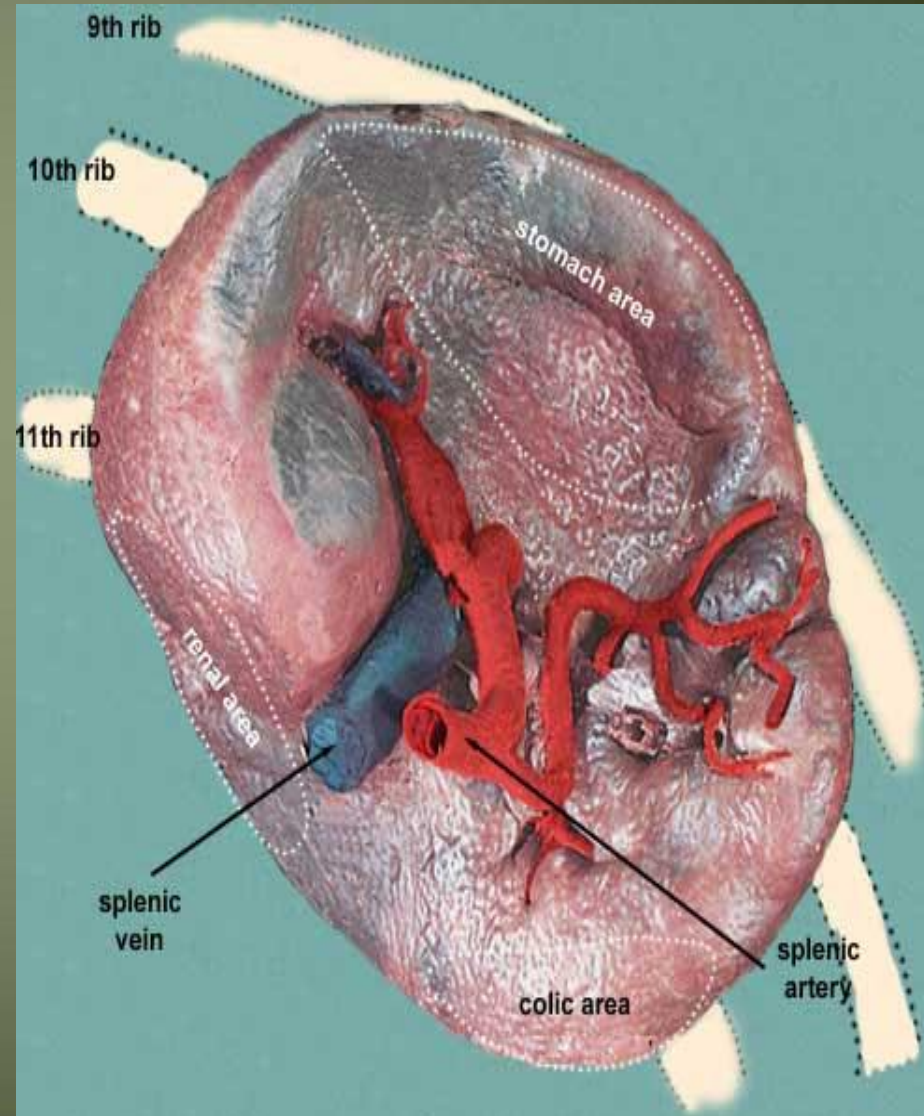
- It is free
- Sharp
- Thin
- Often notched (sup. notch), especially below
- It separates the diaphragmatic surface from the gastric surface



Spleen.....cont

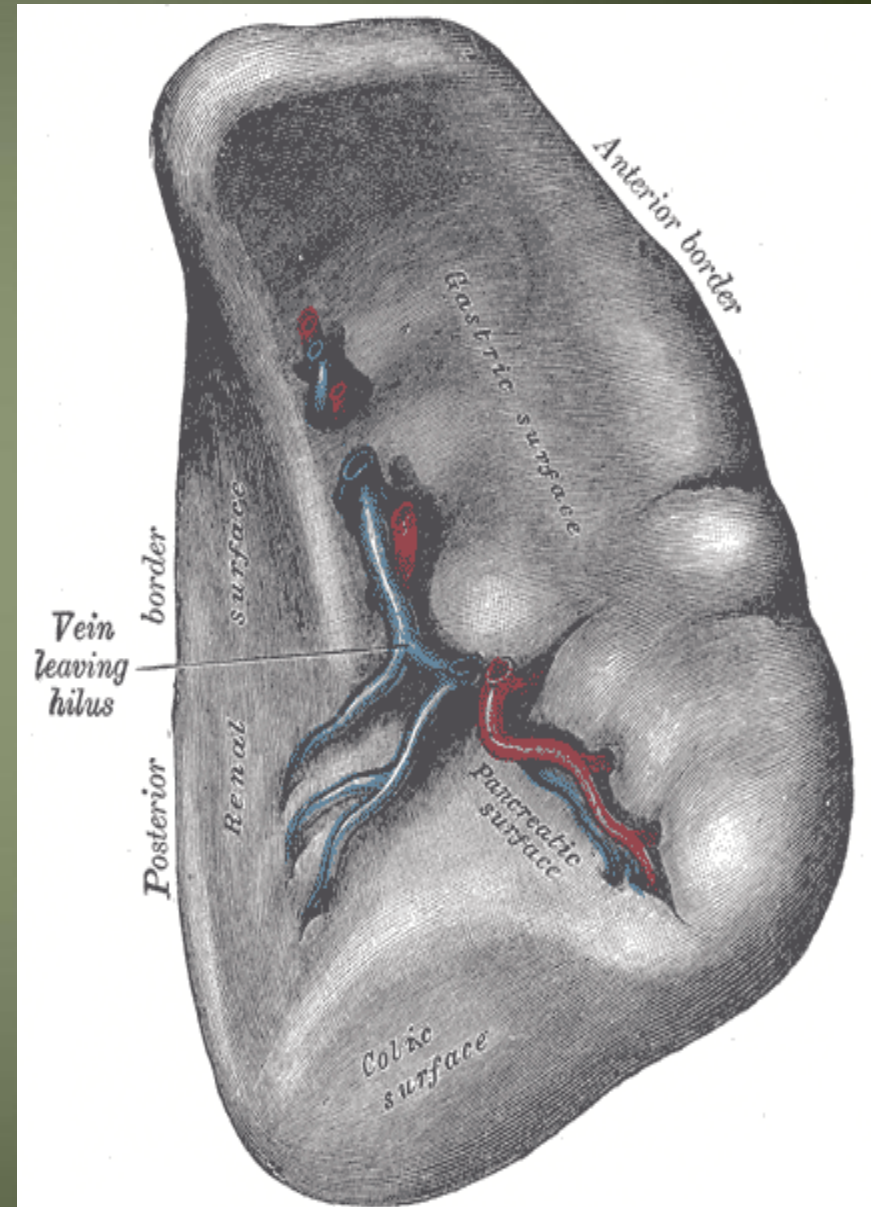
2- inferior border

- More rounded and blunter
- Separates the renal from the diaphragmatic surface;
- It corresponds to the lower border of the eleventh rib
- lies between the diaphragm and left kidney. The



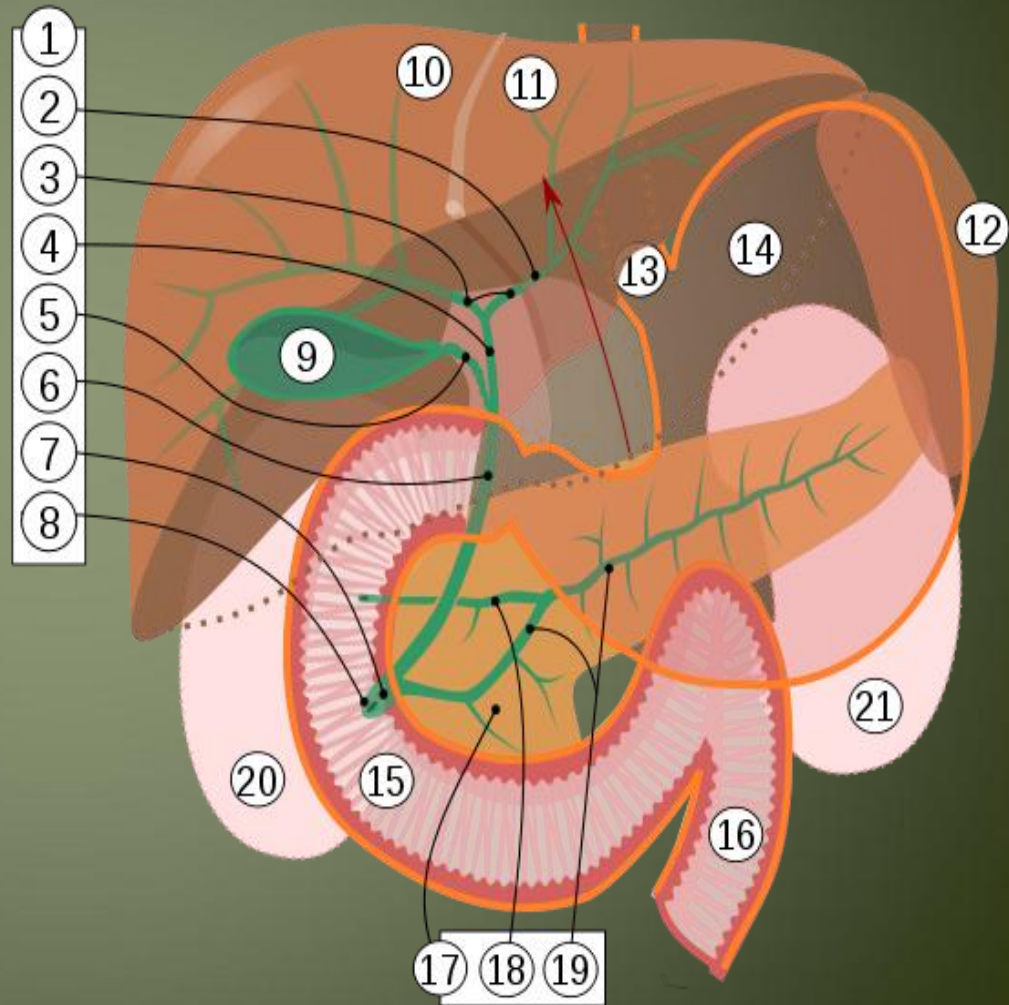
Spleen...cont

- Intermediate margin is the ridge which separates the renal and gastric surfaces.
- Internal border separates the diaphragmatic from the colic surface.



Spleen...cont

- 2 Ends
- **Med.end** → sup & back
- 4cm away from mid line post
- **Lat.end** → in left mid axillary line



Blood supply

- The large splenic artery is the largest branch of the celiac artery.
- It has a tortuous course
- It runs along the upper border of the pancreas
- The splenic artery then divides into about six branches, which enter the spleen at the hilum

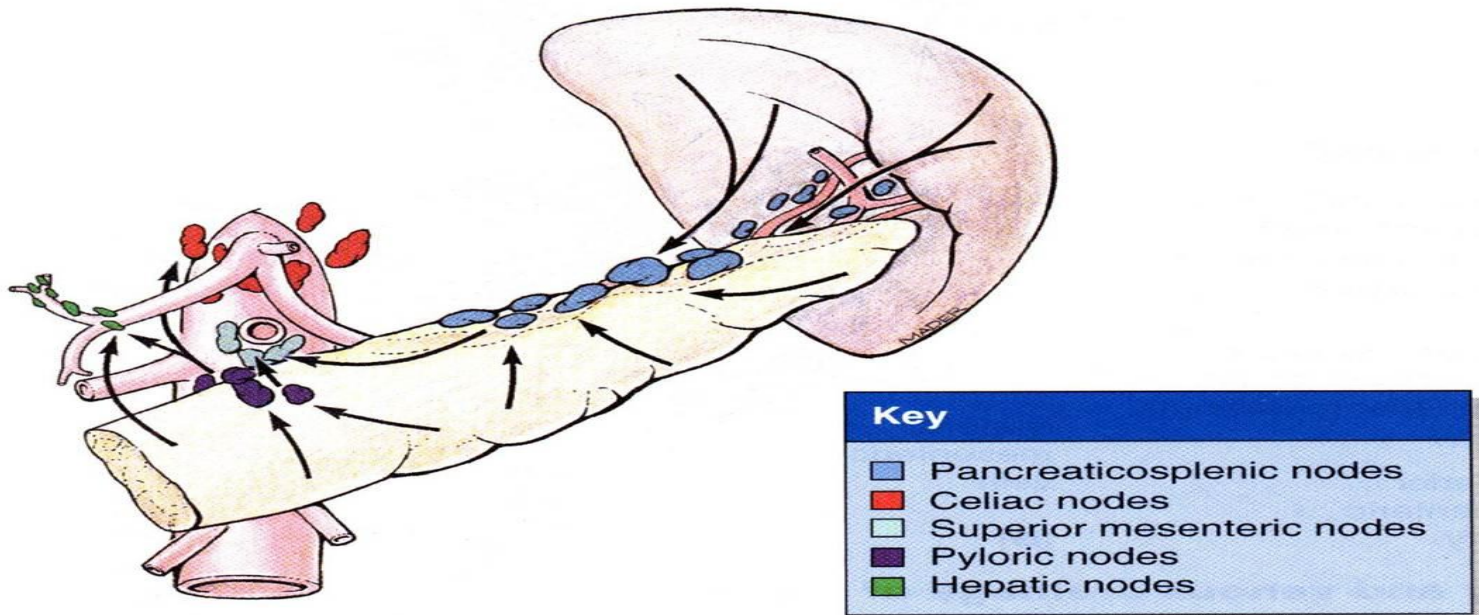
Blood supply of spleen

- Veins

- The splenic vein leaves the hilum and runs behind the tail and the body of the pancreas.
- Behind the neck of the pancreas, the splenic vein joins the superior mesenteric vein to form **the portal vein.**

Lymphatic Drainage of spleen

- The lymph vessels emerge from the hilum and pass through a few lymph nodes along the course of the splenic artery and then drain into the celiac nodes.



Nerve Supply of spleen

- The nerves accompany the splenic artery and are derived from the celiac plexus.

Thank you