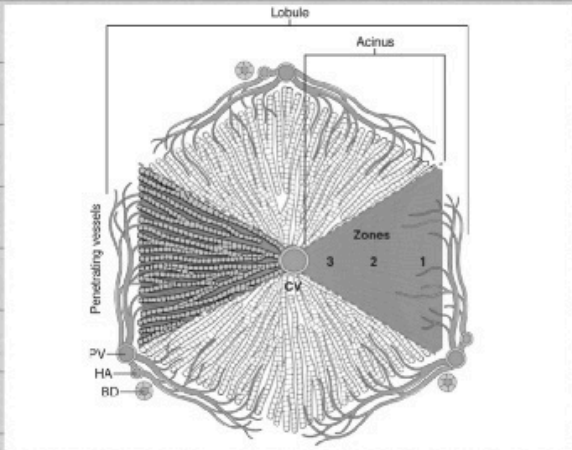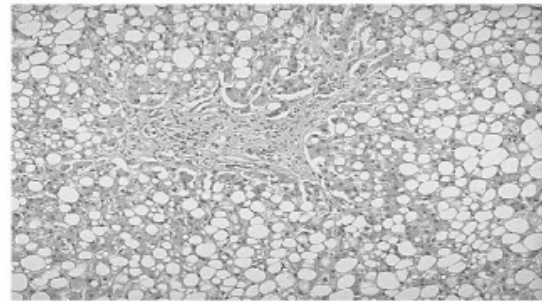


fatty change

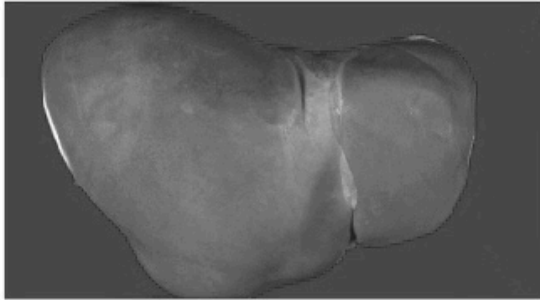


11

fatty change

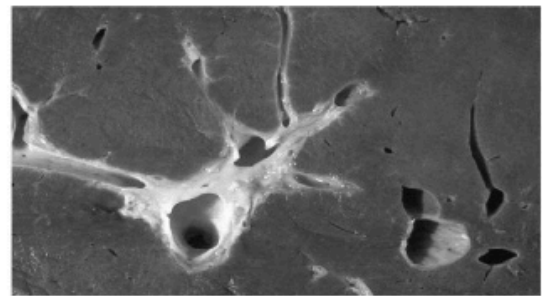


Normal liver



5

Cross section of normal liver

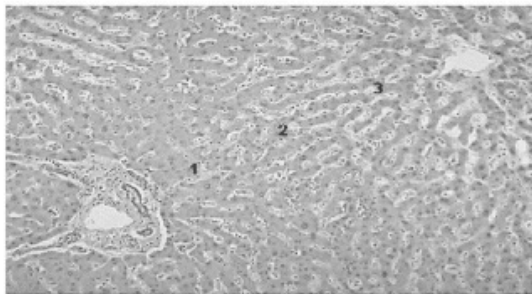


Normal liver

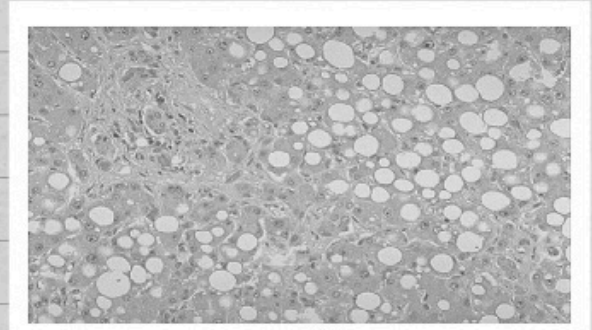
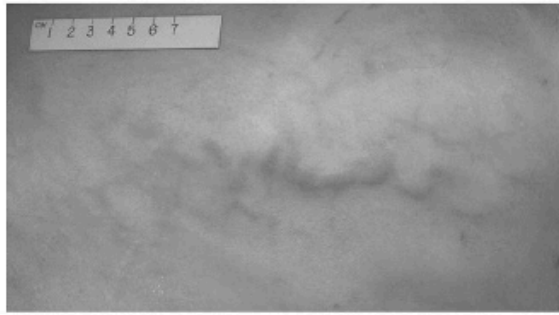


4

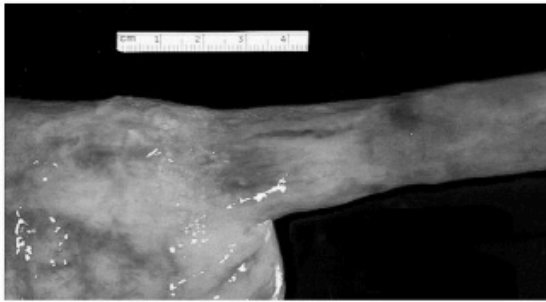Liver zones



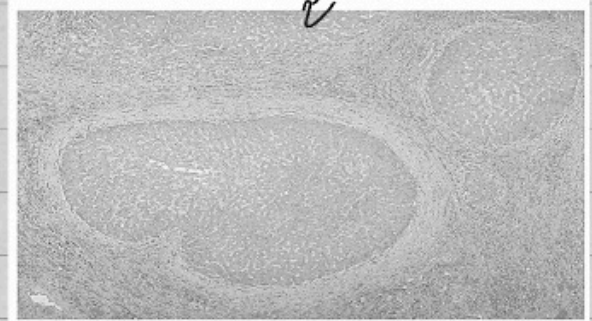
Caput medusae-abdominal skin



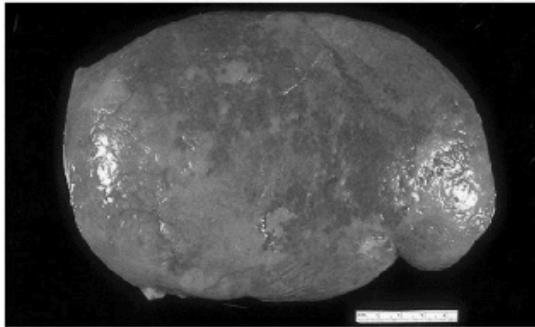
Esophageal varicies



Fatty changes

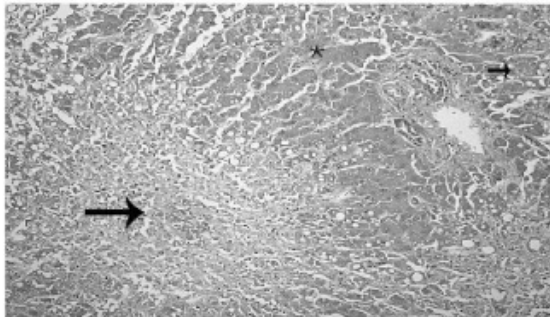


Splenomegaly

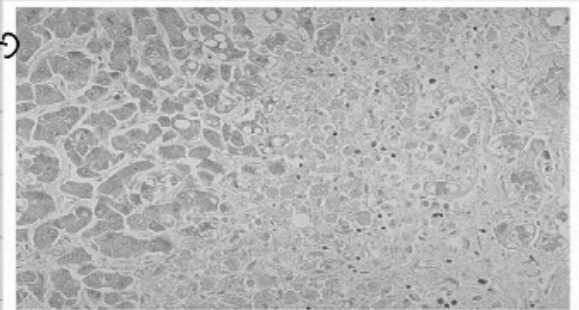


Hepatocellular necrosis caused by acetaminophen overdose. Confluent necrosis is seen in the perivenular region (zone 3; large arrow). (There is little inflammation. The residual normal tissue is indicated by the

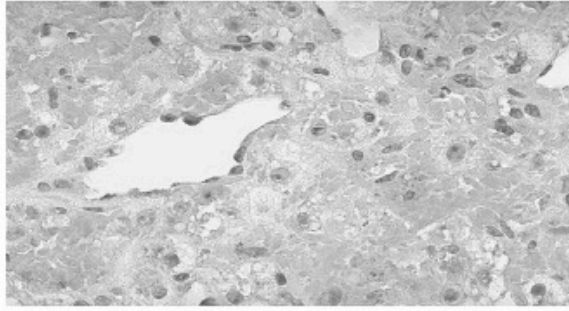
asterisk



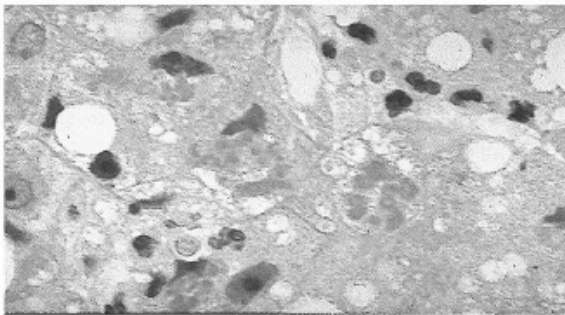
Hepatocellular necrosis




Necrosis of liver



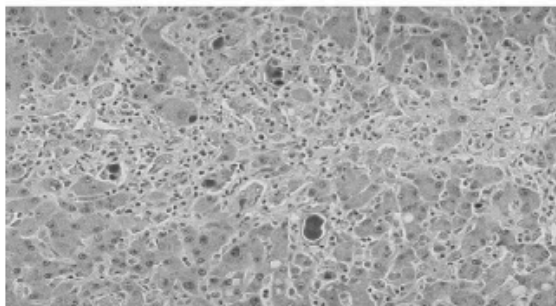
Mallory-hayline bodies



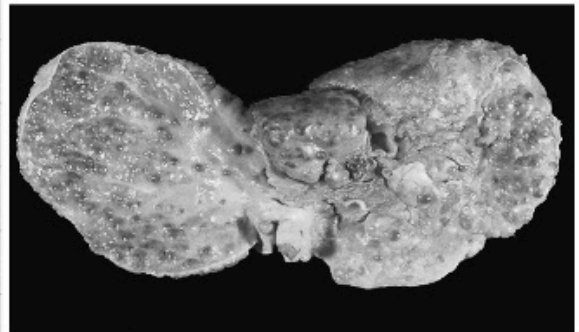
Liver cirrhosis




Cholestasis



Macronodular cirrhosis



Micronodular cirrhosis



Alcoholic hepatitis

