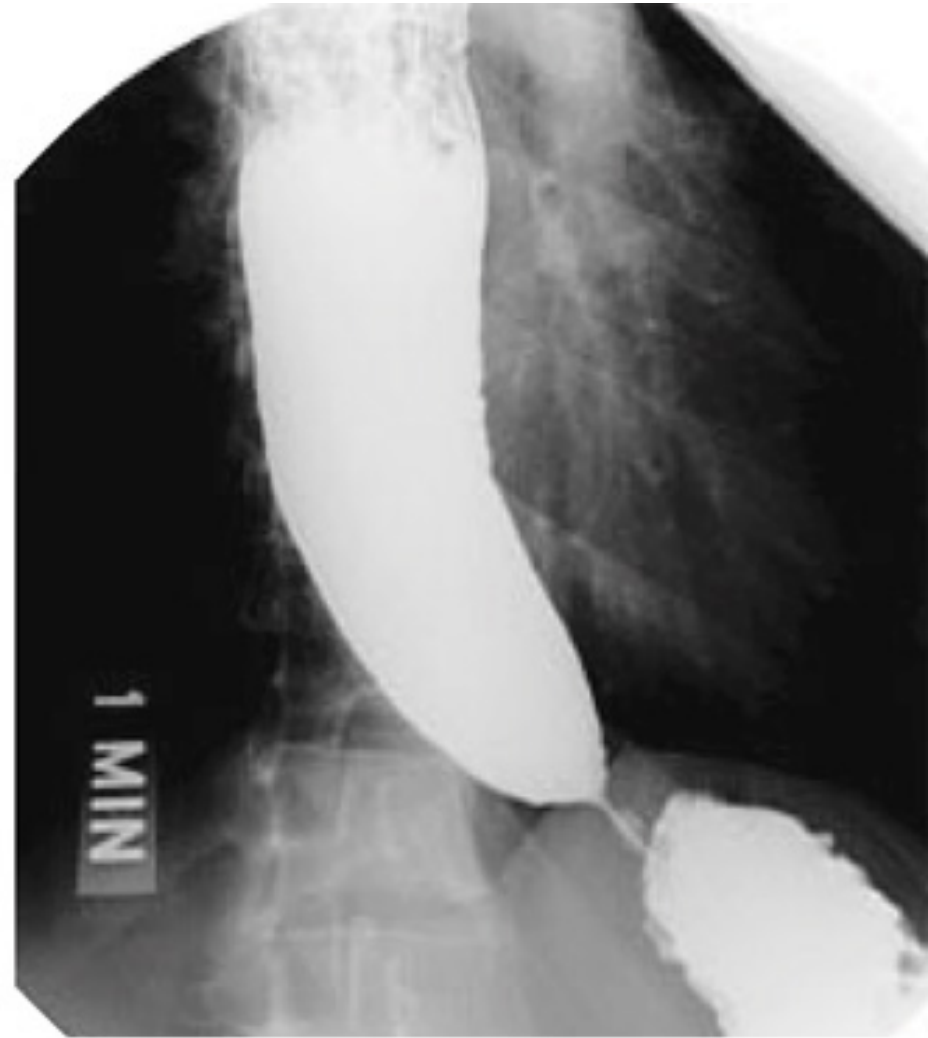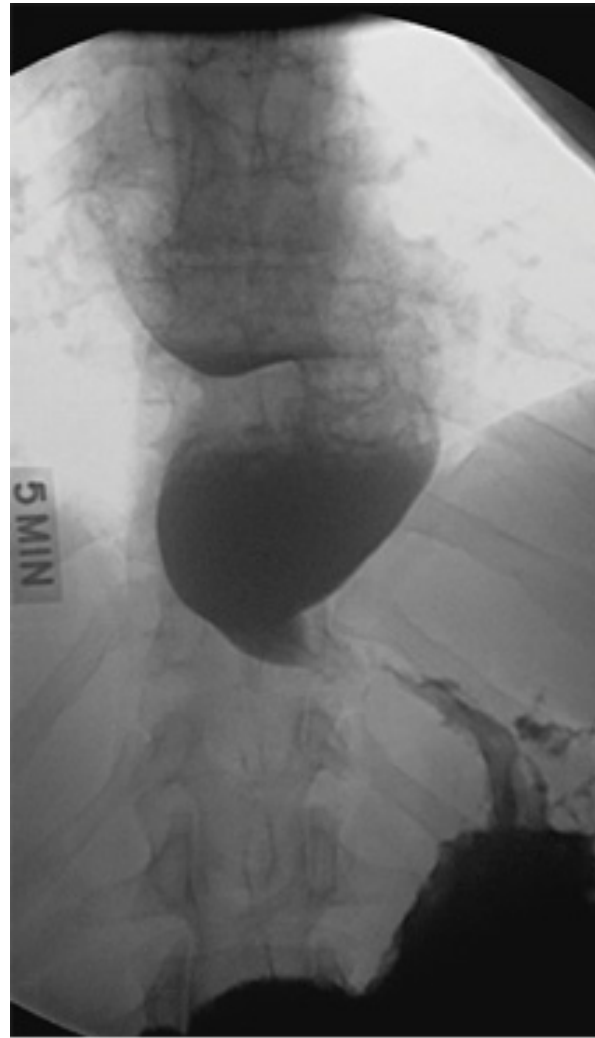


Pathology lab slides

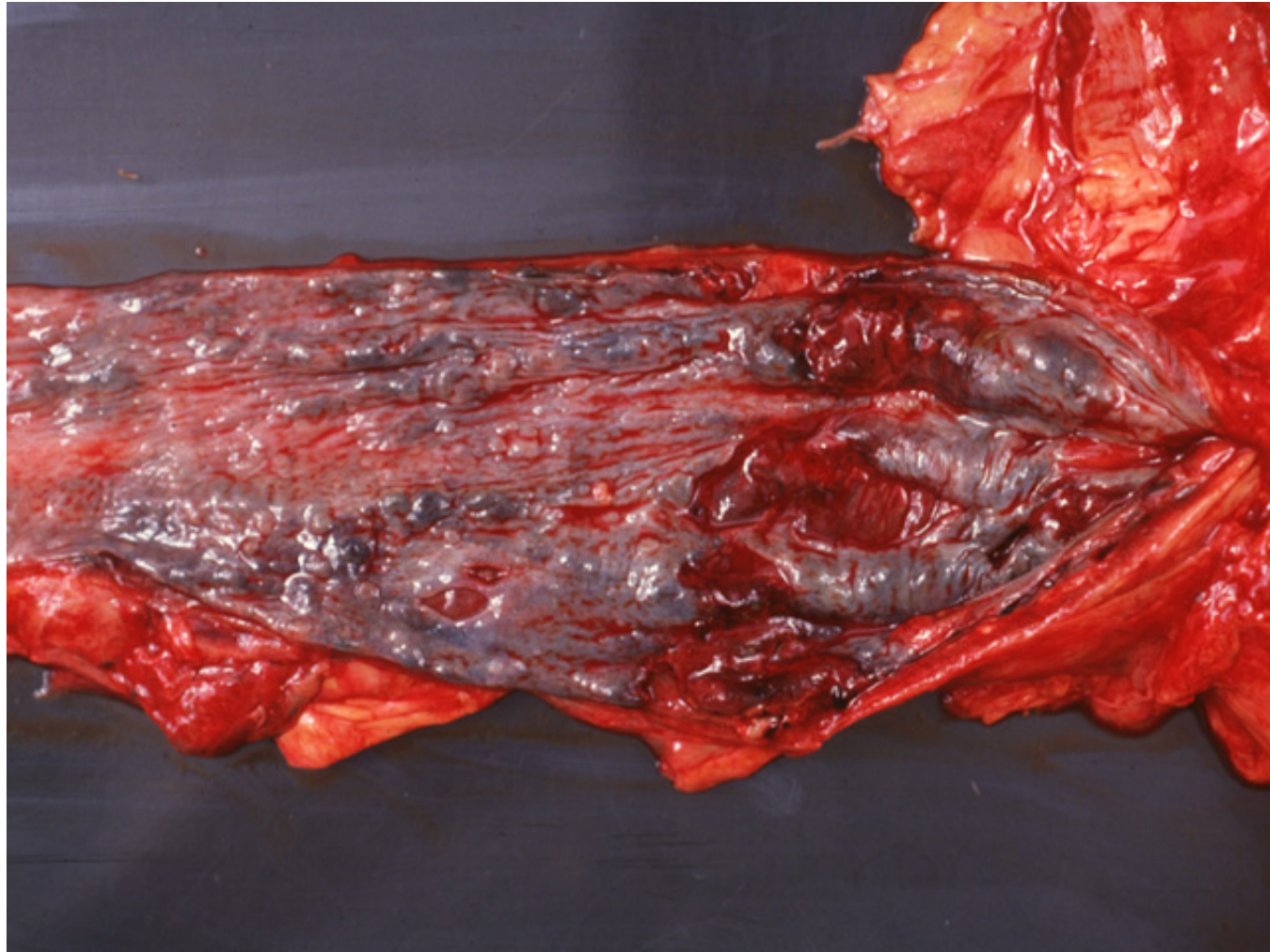achalasia

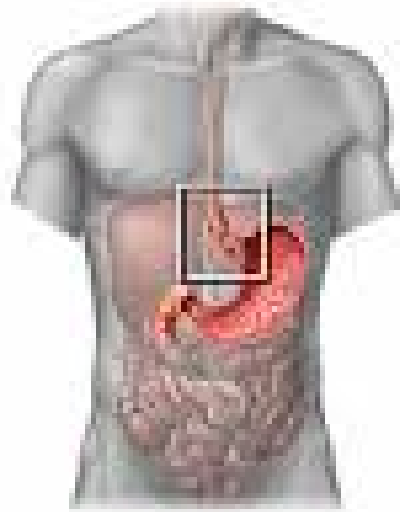


Source: Longo DL, Fauci AS, Kasper DL, Hauser SL, Jameson JL, Loscalzo J: *Harrison's Principles of Internal Medicine, 18th Edition*: www.accessmedicine.com

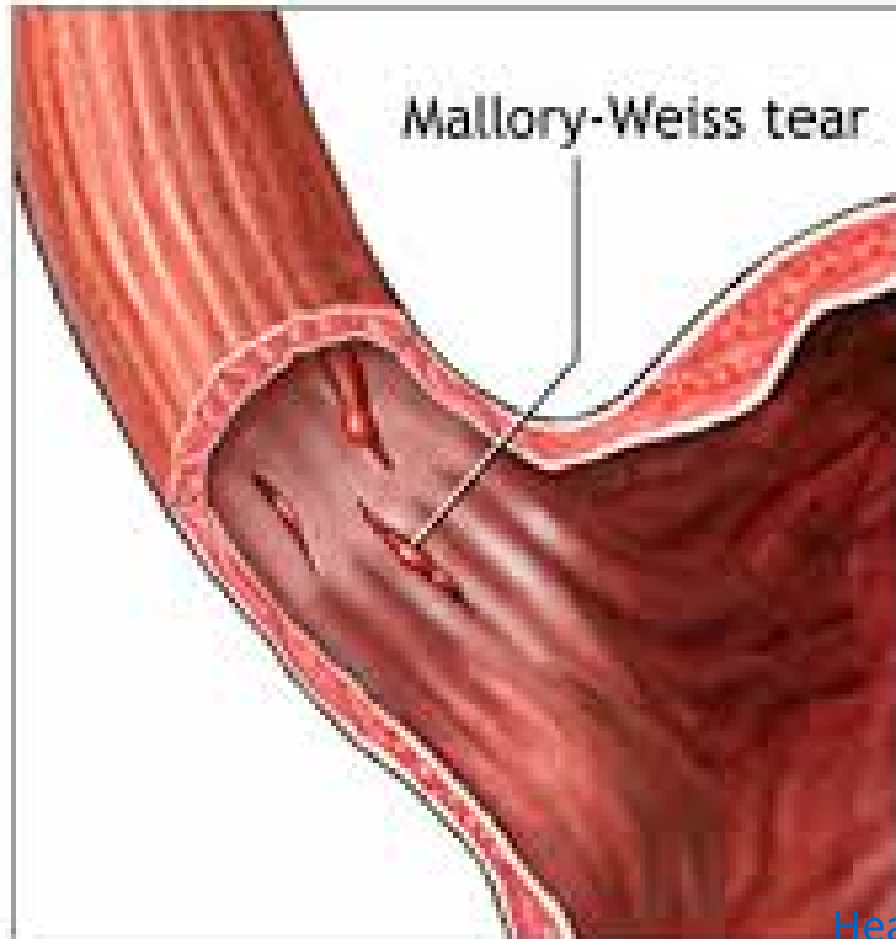
Copyright © The McGraw-Hill Companies, Inc. All rights reserved.

varices

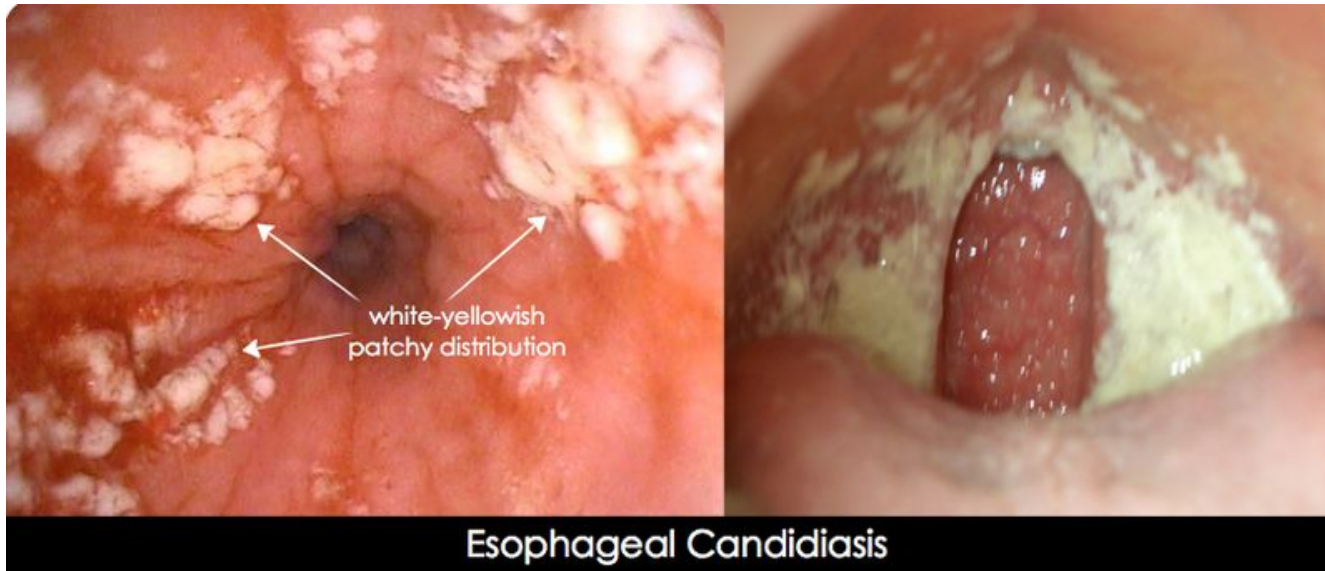




Mallory-Weiss tear is a tear in the mucosal layer at the junction of the esophagus and stomach

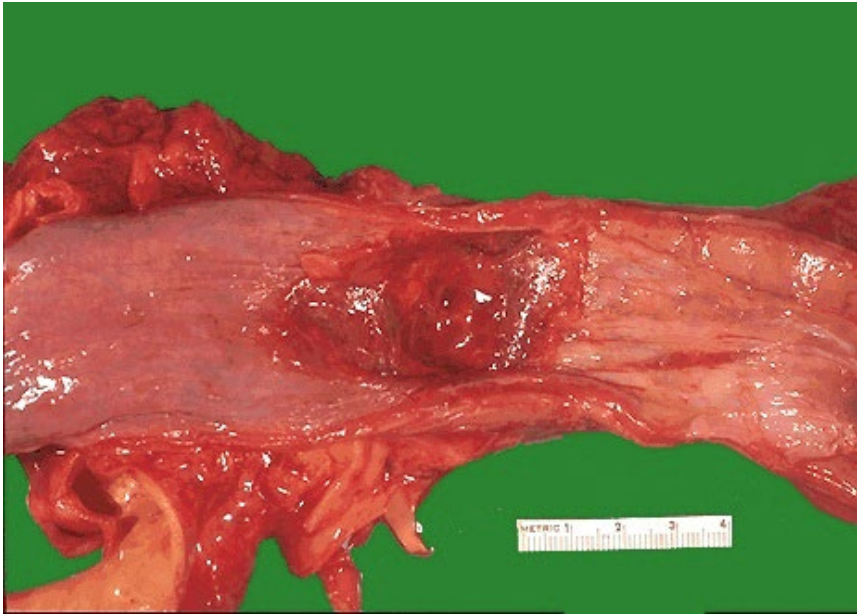

candidiasis




<https://www.pinterest.com/pin/374291419013418659/>

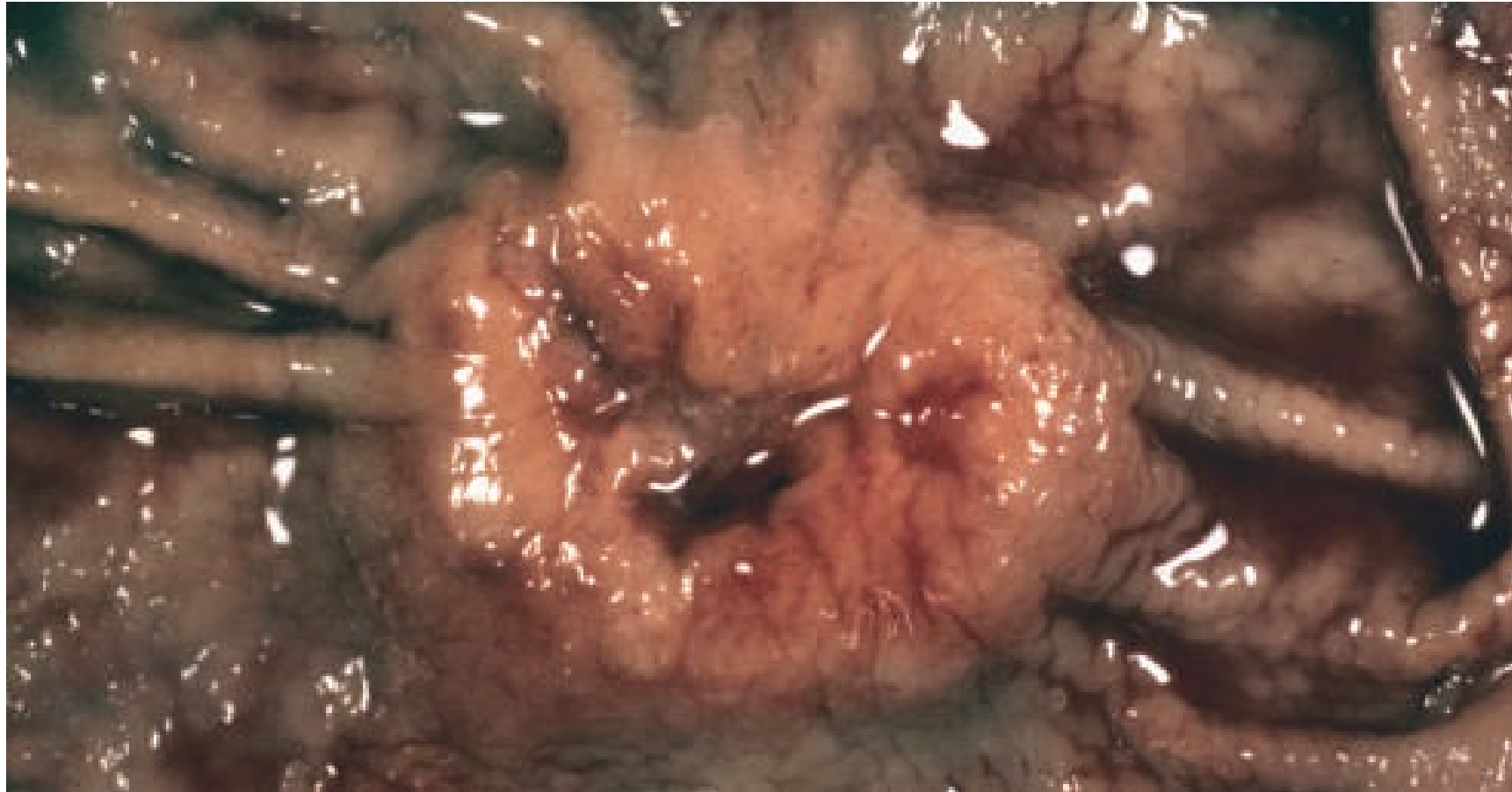
Mid esophagus tumor, squamous cell carcinoma



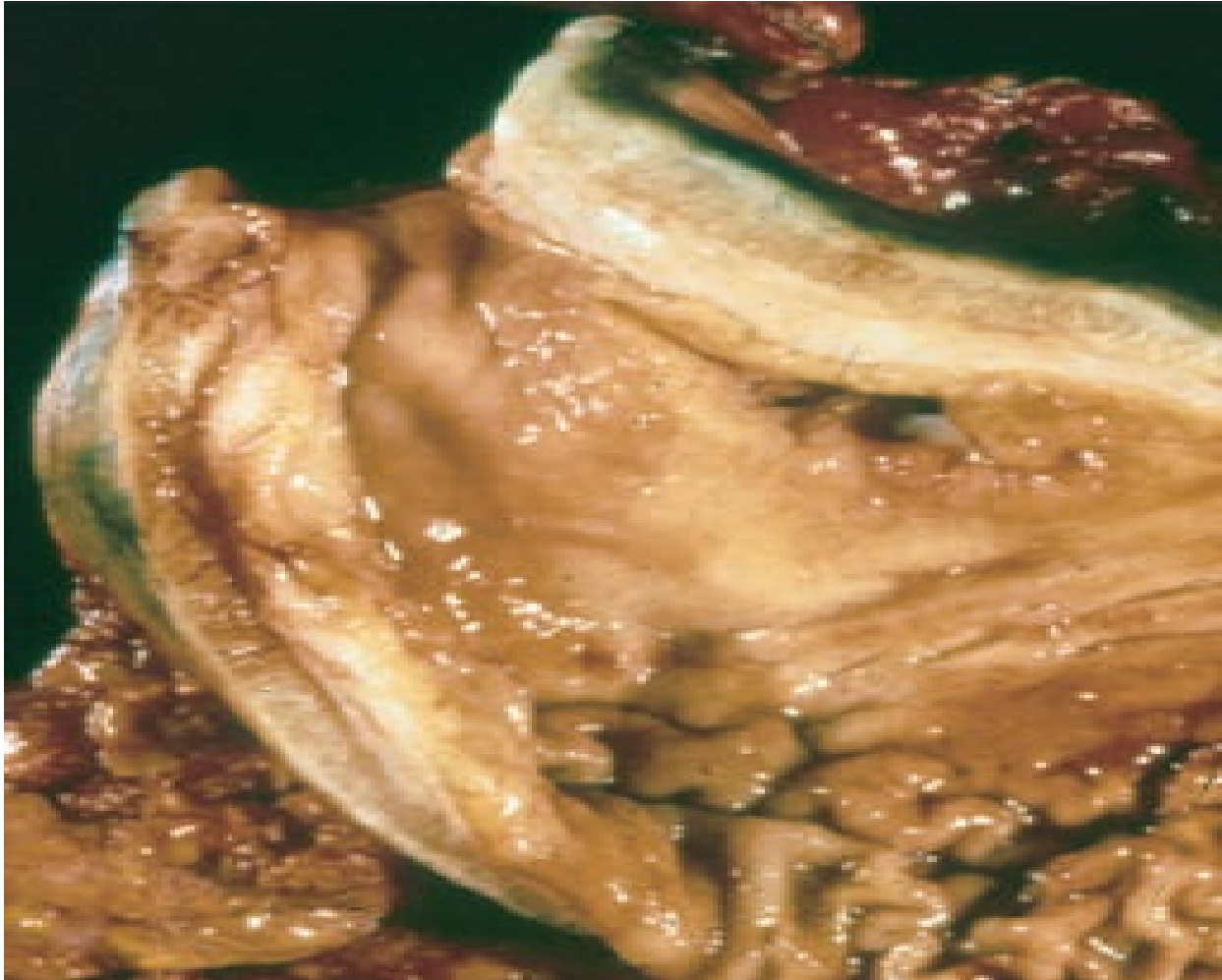
Stress ulcers, stomach



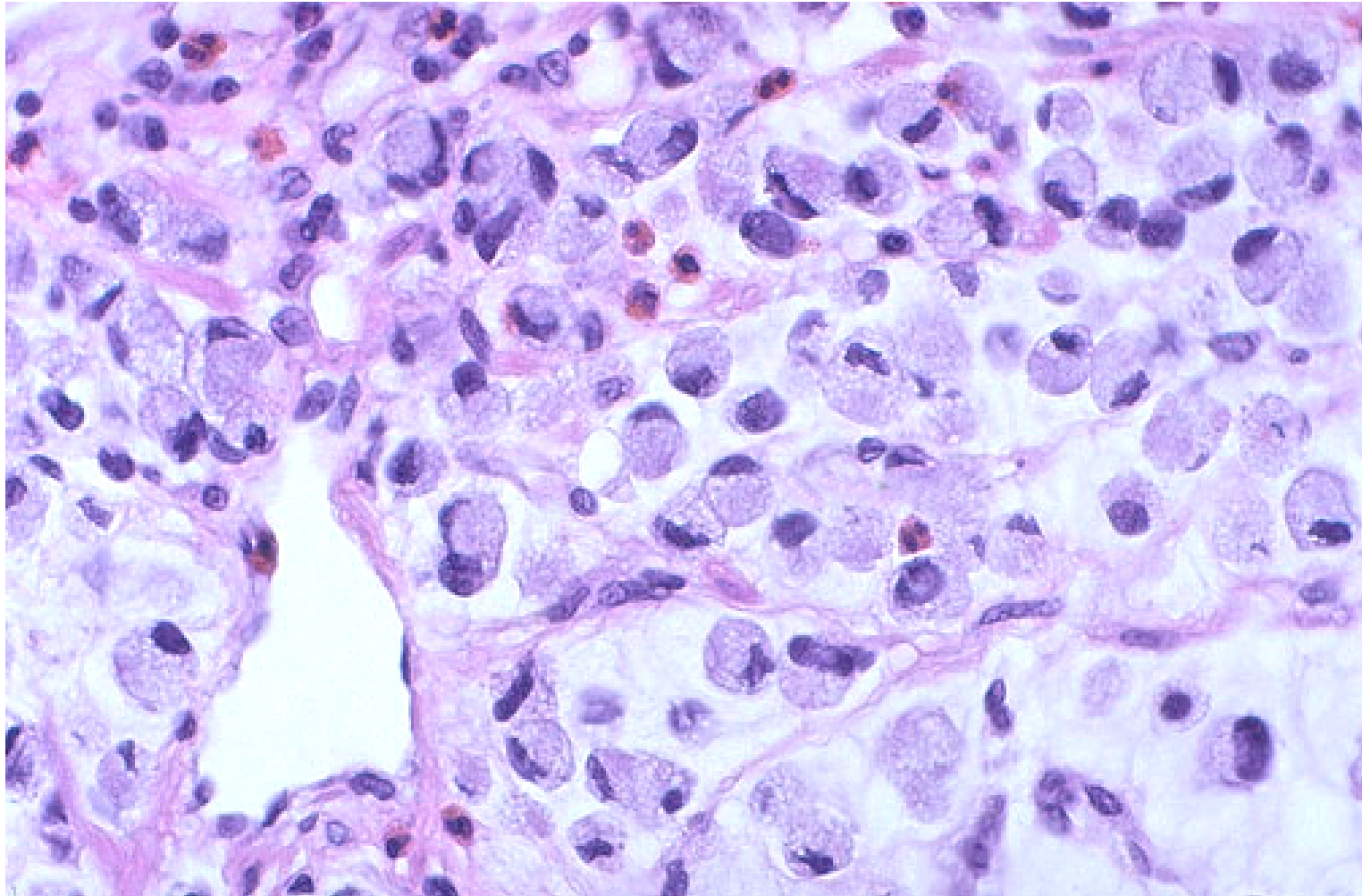
Intestinal type gastric cancer



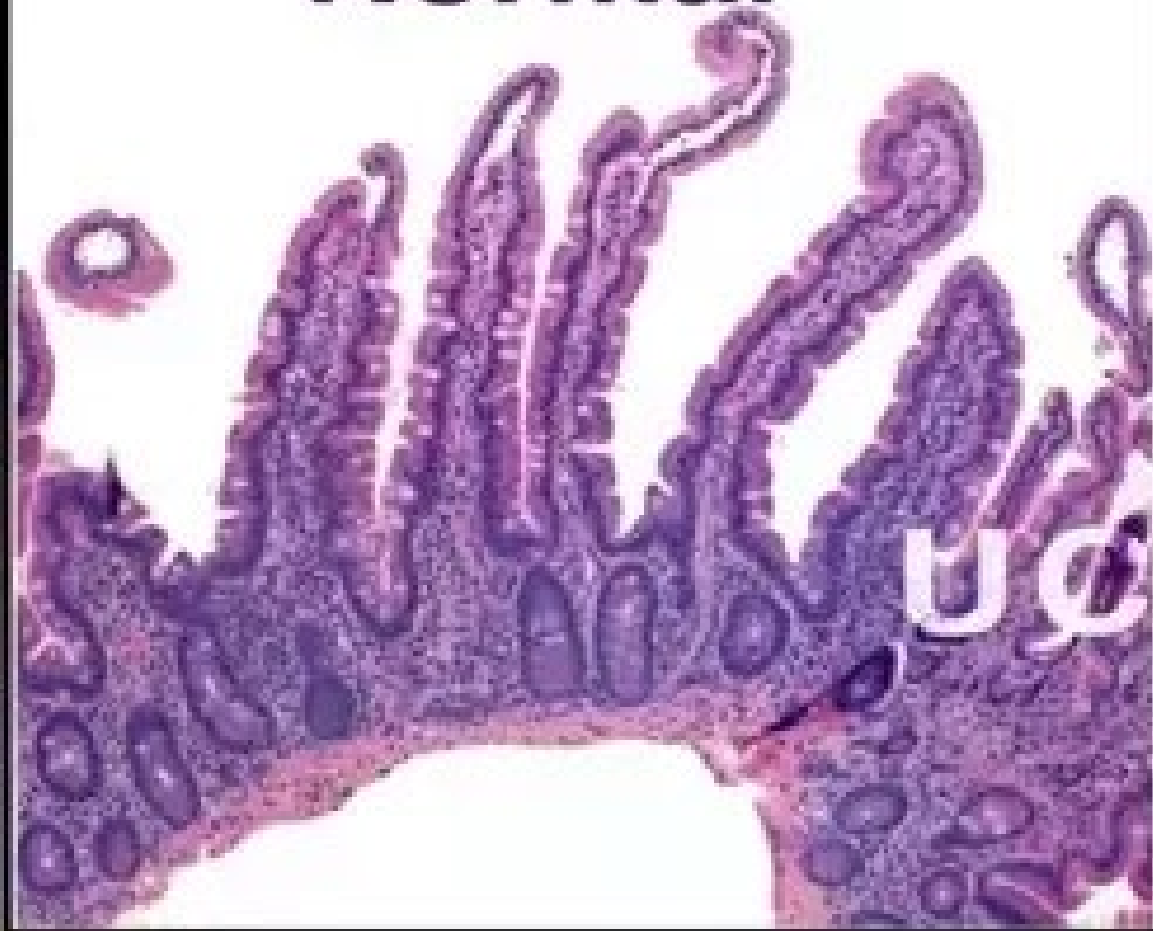Linitis plastica, diffuse type gastric cancer



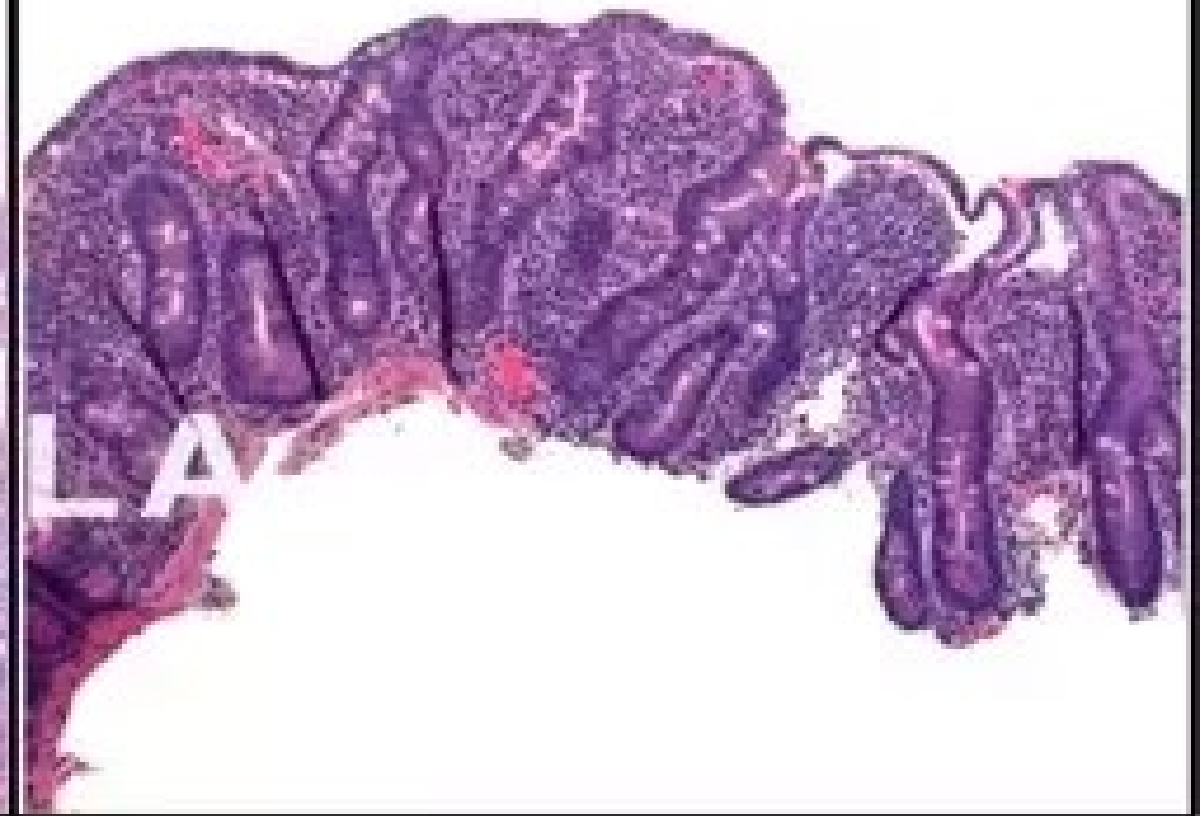
Diffuse type gastric cancer, signet ring cells



Normal

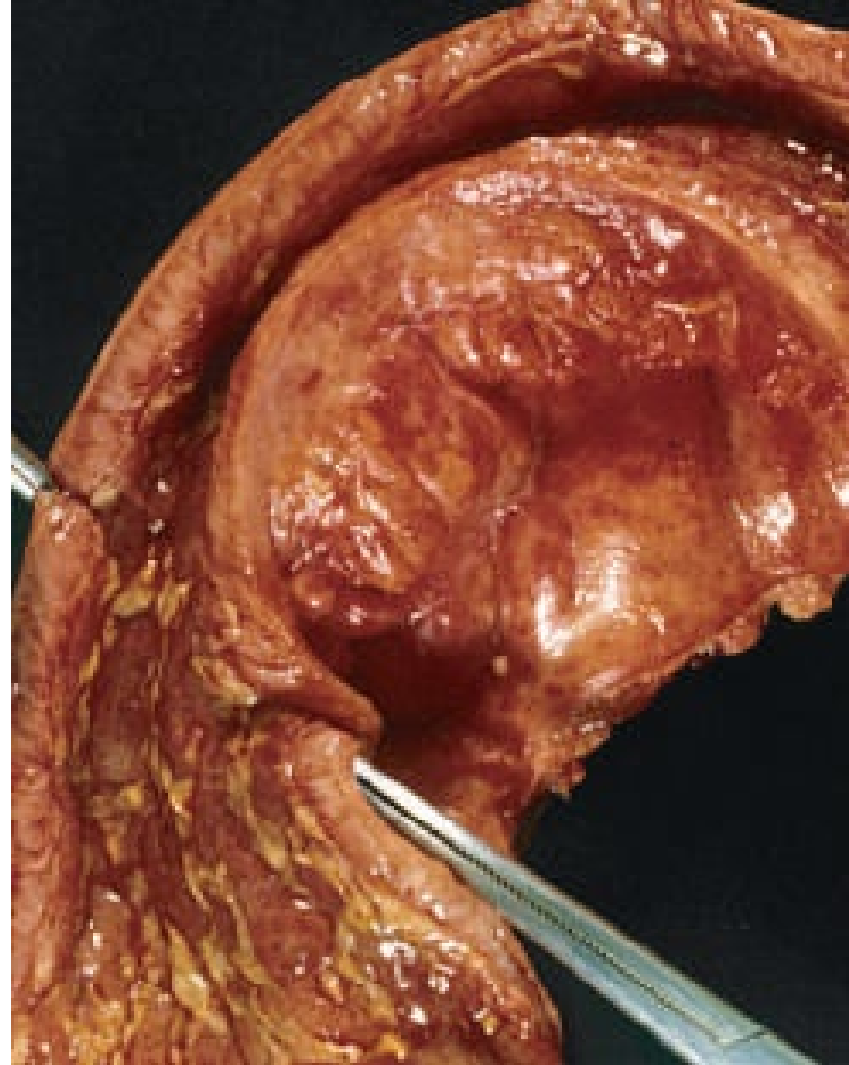


Celiac Disease

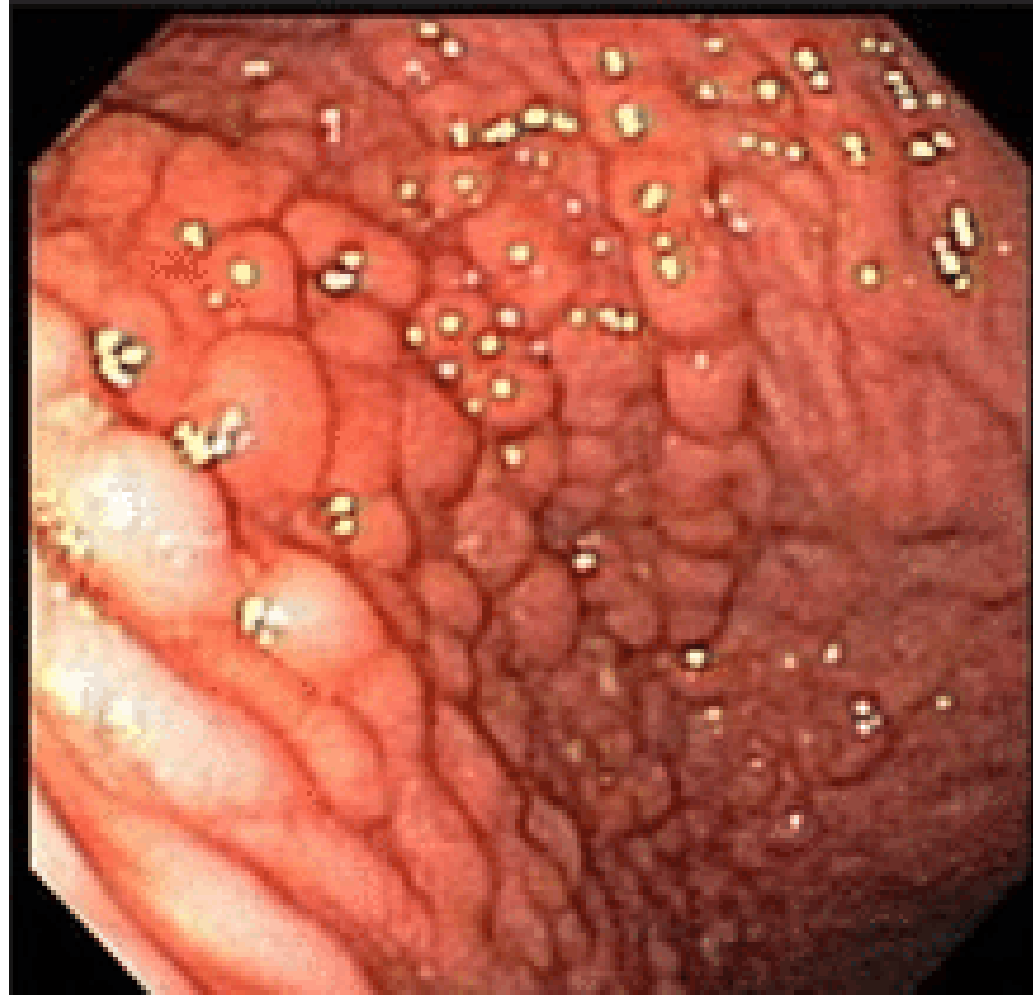

UC LA

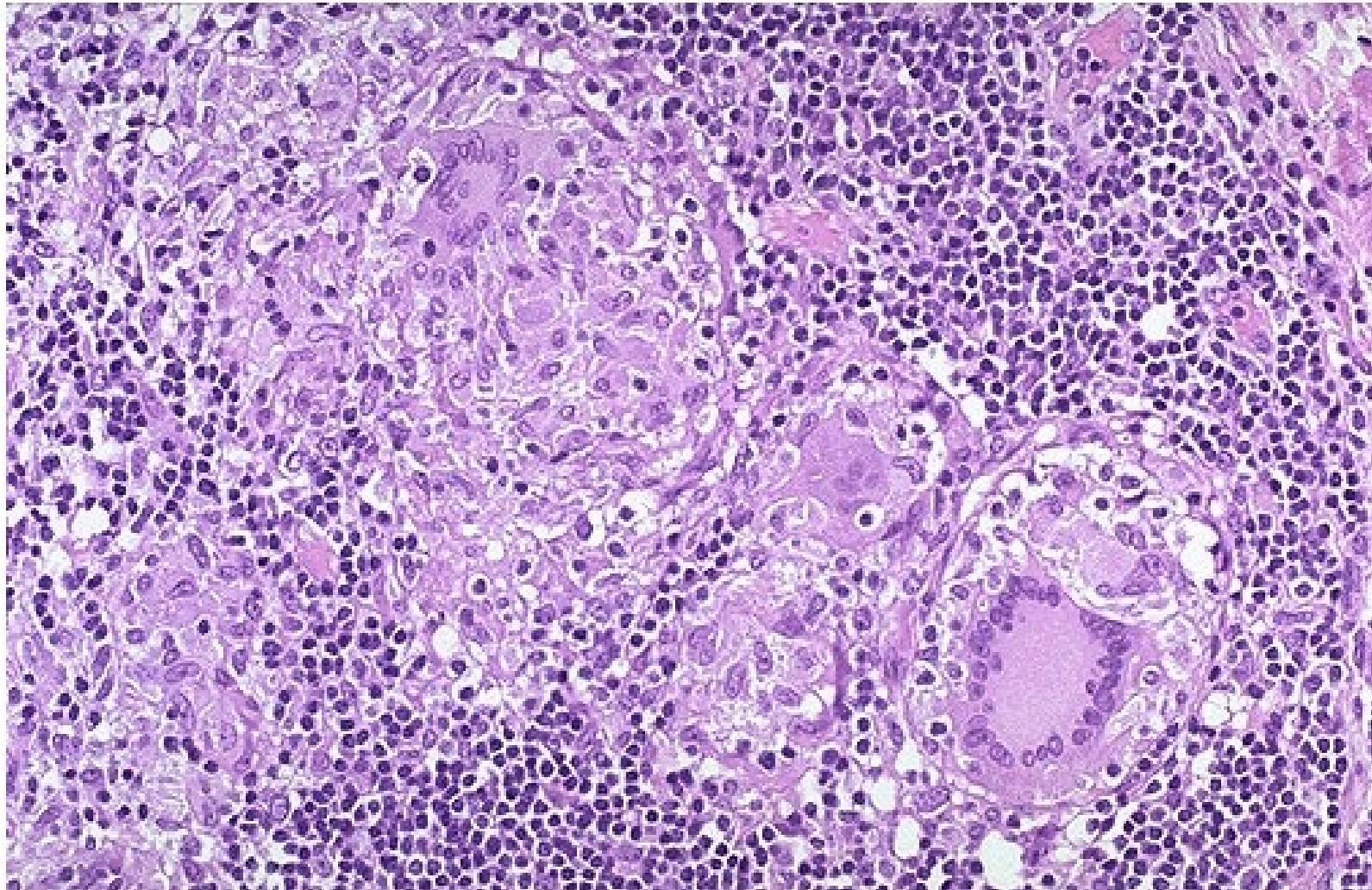
Small bowel stricture, crohn disease.



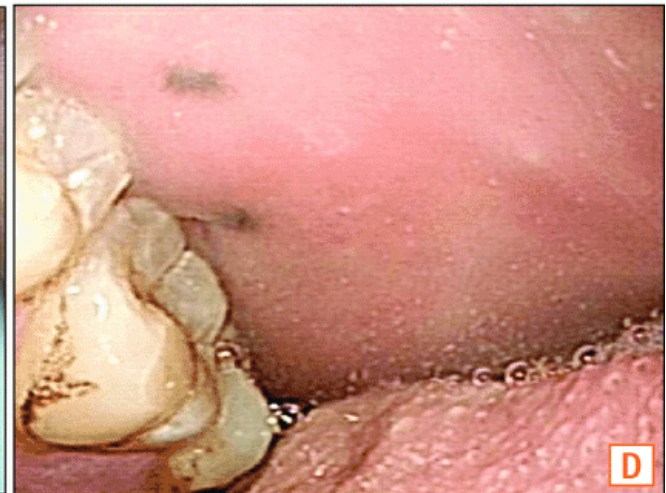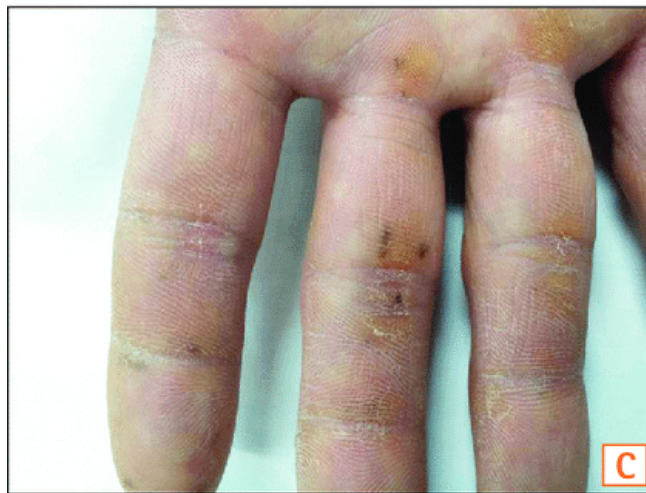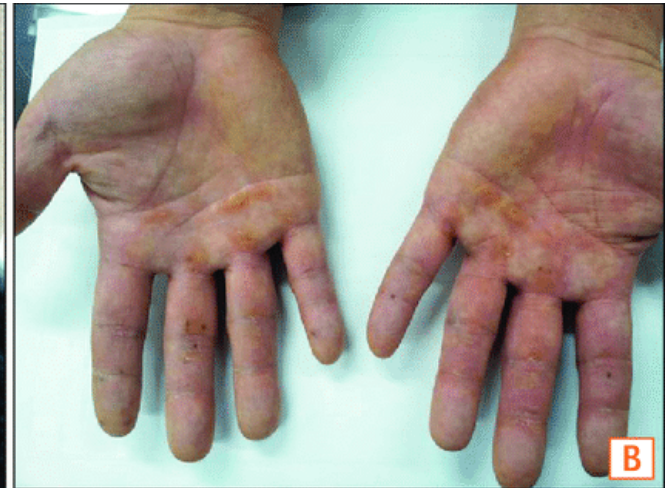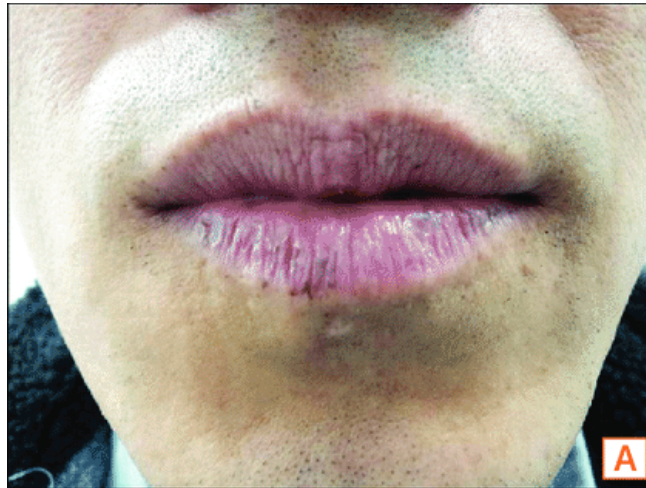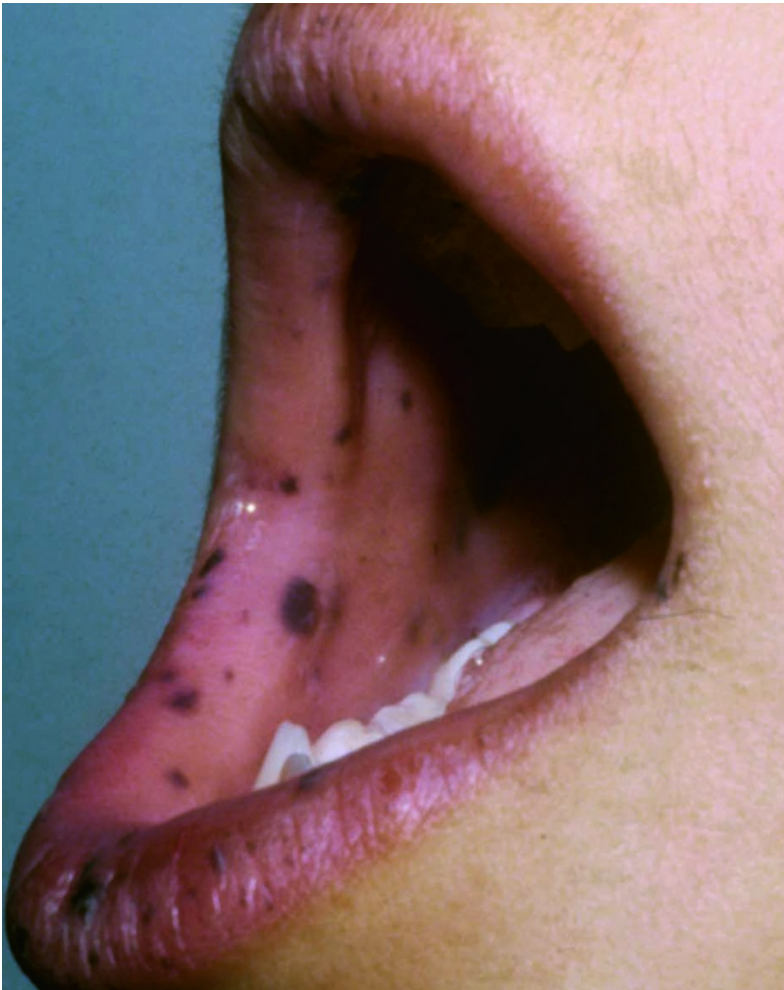Cobble stone bowel mucosa, crohn disease



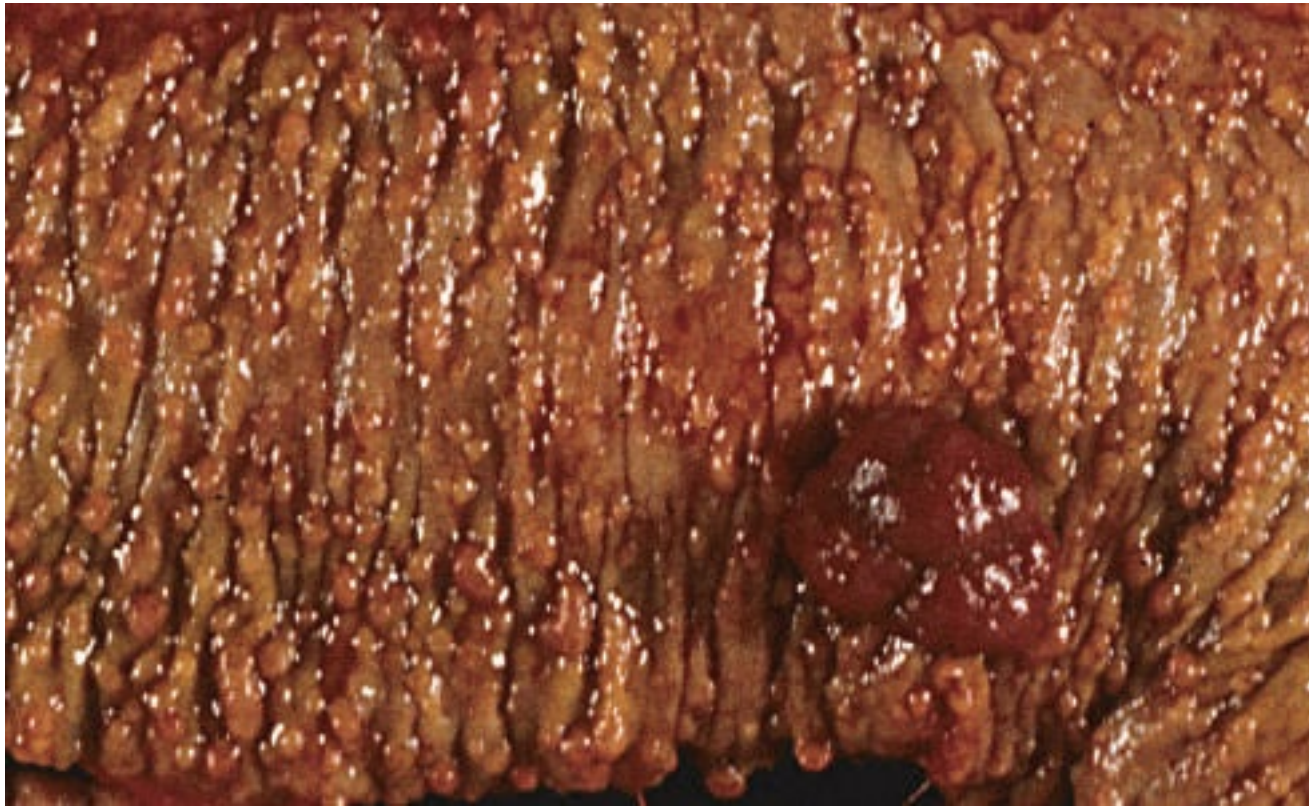Non-caseating granuloma, crohn disease



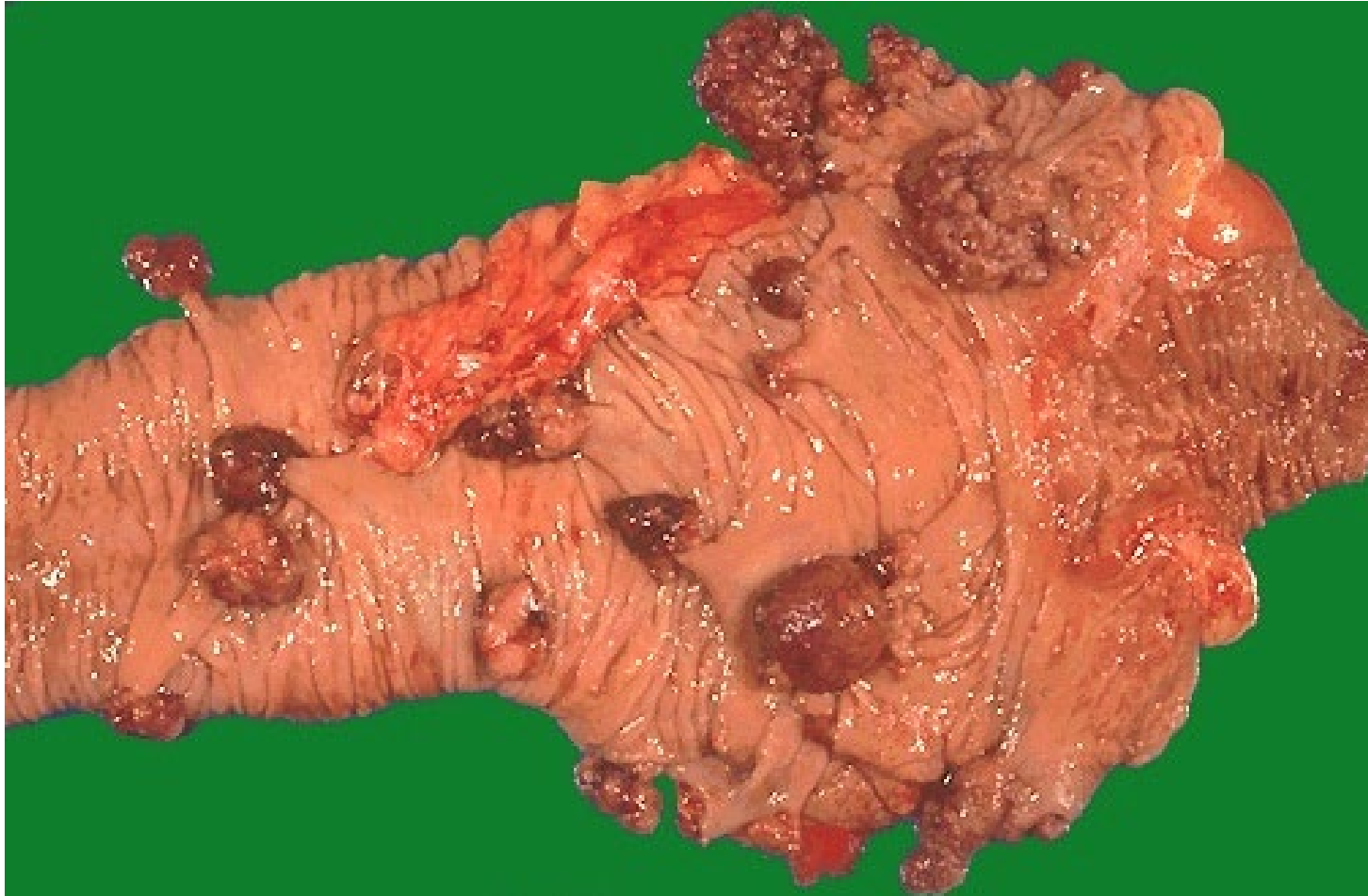
Mucocutaneous pigmentation, Peutz Jegher syndrome



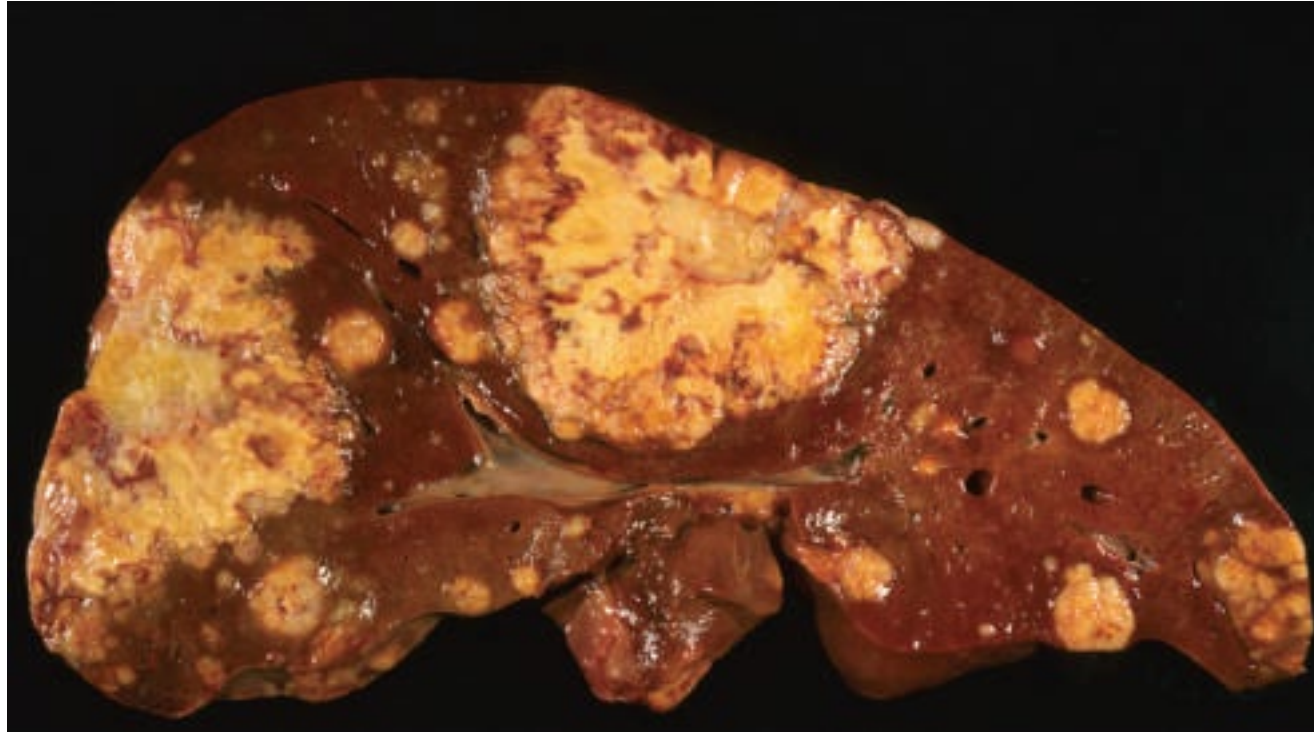
FAP



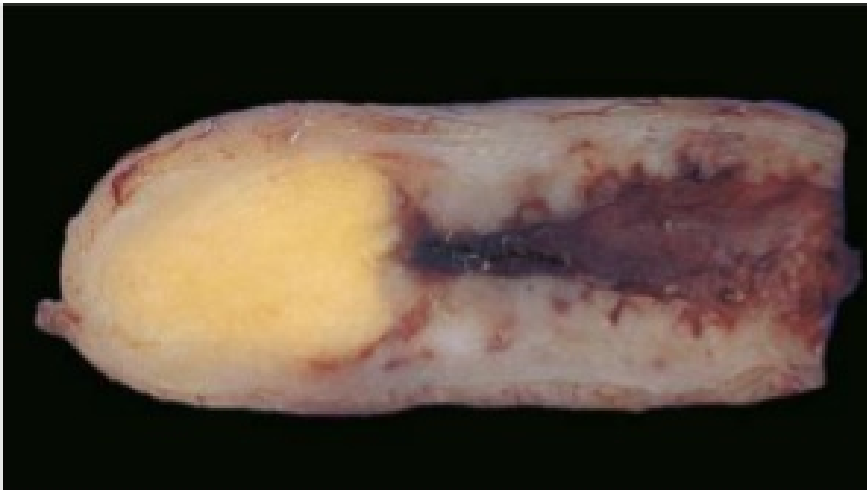
Cecal polyps in HNPCC.



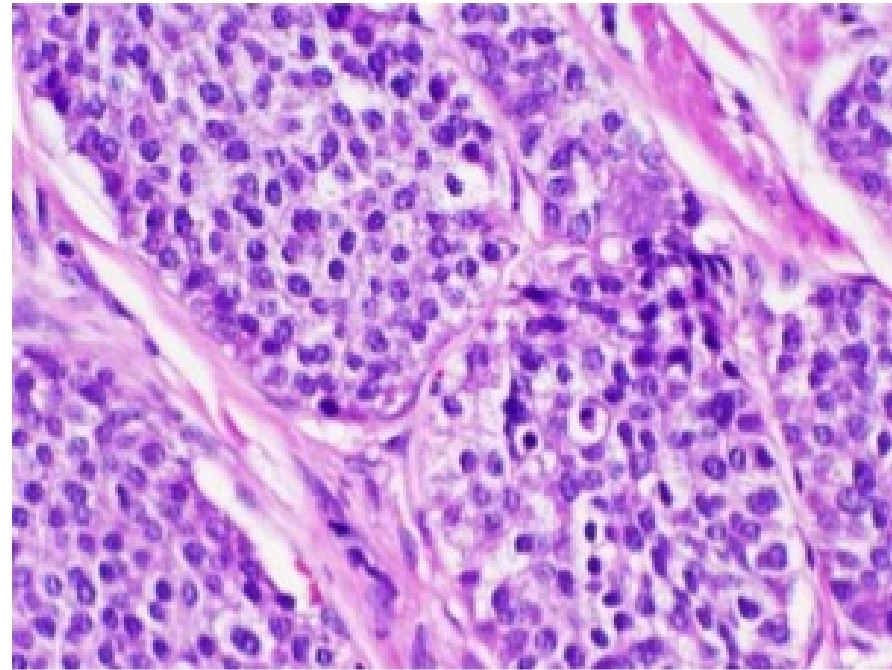
Liver metastasis from colon cancer.



Carcinoid tumor

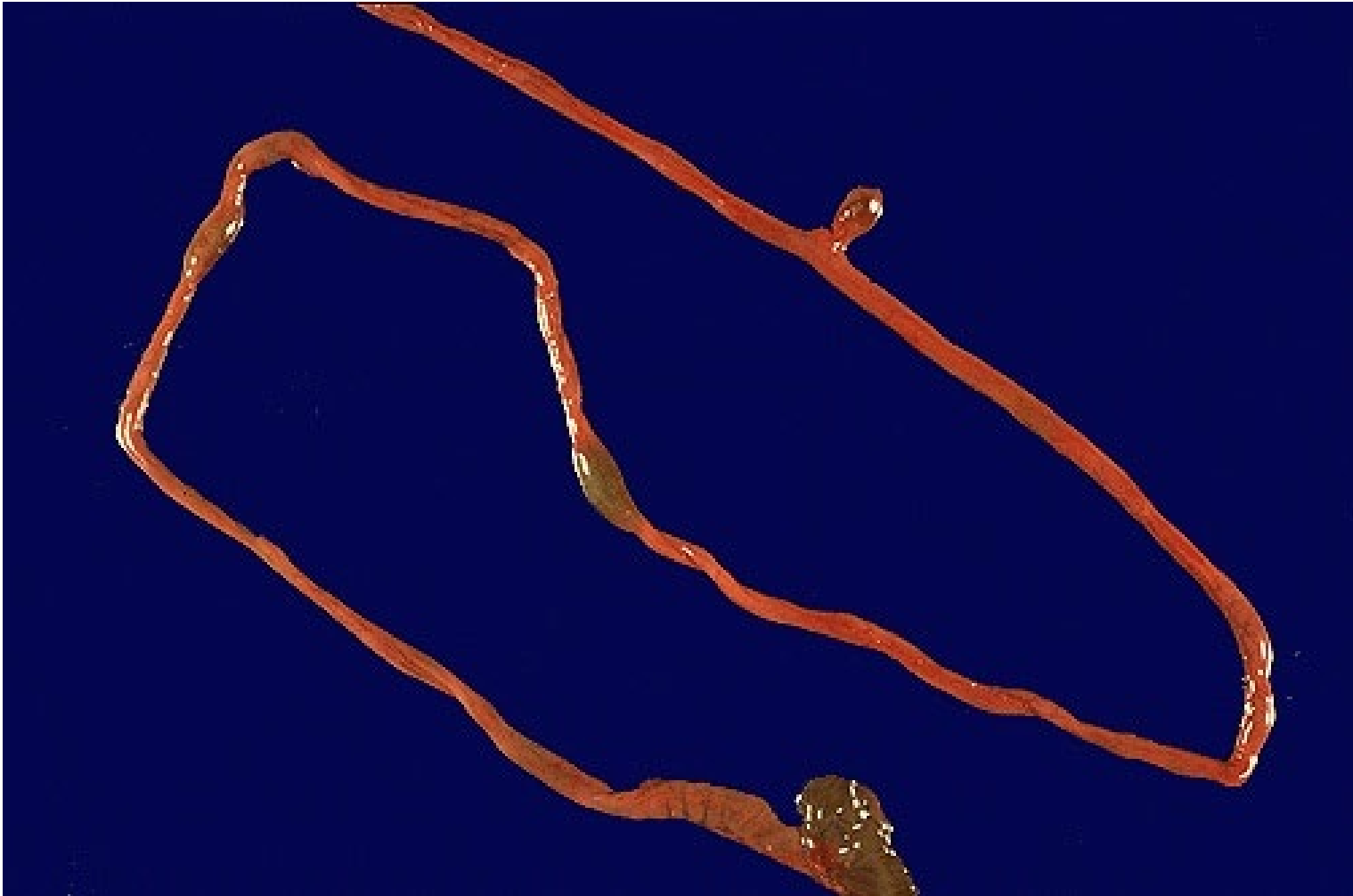

Gross

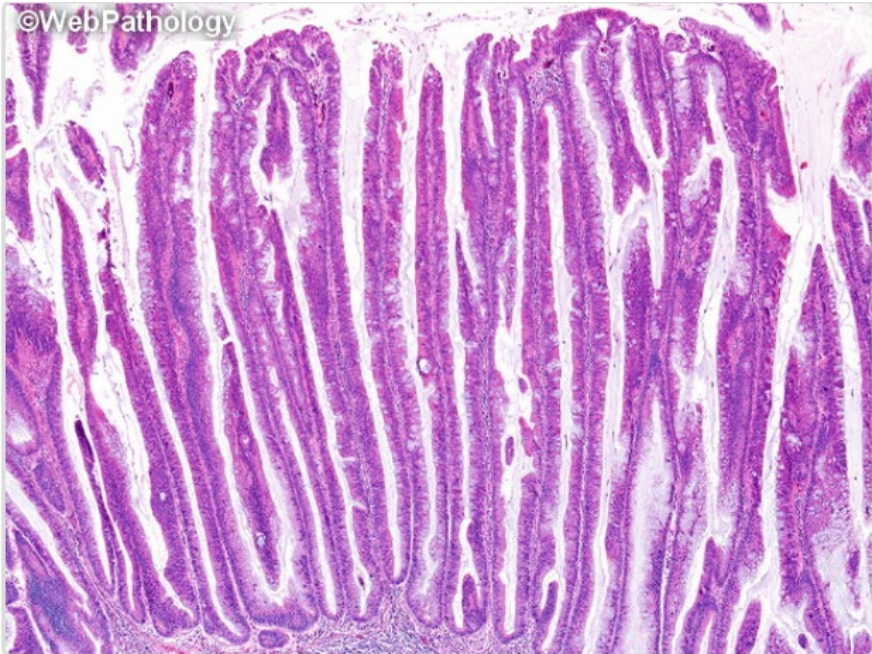


Microscopic

Meckel's diverticulum



Villous adenoma.



- Long slender villi.
- More frequent invasive foci

- **Architecture:**
- **Tubular.**
- **Tubulovillous.**
- **Villous.**