

# Acute liver failure

viral hepatitis

drugs **massive necrosis**

fast encephalopathy

# Alcoholic liver disease

CYP2E1

chinese  
facial flushing, tachycardia &  
hyperventilation




# Hepatic steatosis

soft yellow & greasy  
reversible

# Alcoholic cirrhosis

Irreversible Laennec

 lower dehydrogenase

Less than 10% unchanged  
Chinese facial flushing

# cirrhosis

Portal hypertension

Diffuse

I & III collagen in space of Disse

**Upper GIT bleeding = death**

**Splenomegaly = thrombocytopenia**

# Chronic liver disease

ending in cirrhosis

# Hepatic dysfunction

tetracycline pregnancy

Reye syndrome

Fetor hepaticus bleeding ↓ 2-7-9-10

Palmar erythema

**albumin** ↓ **ammonia** ↑ **estrogen** ↓

# Alcoholic hepatitis

swelling & necrosis

Mallory-hayline bodies

Neutrophilic reaction

# portal hypertension

Massive fatty change Cirrhosis sarcoidosis, TB

Ascitis encephalopathy

caput medusae

# Hepatic encephalopathy

**Asterixis** Seizures Rigidity

Brain edema

# Unpredictable drugs

الو؟ هلو! سيلفي كلو مثل الضيوف

Chlorpromazine

Halothane

Sulfonamides

Methyldopa

Allopurino

## massive necrosis

Acetaminophen, halothane

هلو مس! الست امينة؟

chronic necrosis : TB : Isoniazid

## Fibrosis & cirrohsis

Methotrexate, isoniazid, enalapril

misen



needs fiber

## Sinusoidal obstruction

syndrome (veno- occlusivedisease)

High-dose chemotherapy bush teas  
cyclophosphamide

high obstruction need bush

## HCC

Cholangiocarcinoma

Angiosarcoma



Thorotrast,  
vinyl chloride

## Cholestatic



Contraceptive and anabolic steroids

## Cholestatic hepatitis

with inflammation =antibiotics; phenothiazines

## Spotty hepatocyte necrosis

Methyldopa, phenytoin  
سبوت ميت! فين؟

## Steatosis

Ethanol, methotrexate,  
corticosteroids,  
total parenteralnutrition



meet paco steak

Steatohepatitis: Mallory bodies : Amiodarone, ethanol

Granulomas :non-caseating : Sulfonamides

adenoma

Budd-Chiari = Oral contraceptives



شيري

dilatation

## Peliosis hepatis

Anabolic steroids tamoxifen  
oral contraceptive danazol



## Reye's Syndrome

salicylate encephalopathy  
after viral illness

## Budd – Chiari Syndrome

Hepatomegaly Thrombotic  
abdominal pain, ascites, and liver enlargement  
**hepatic vein**

## Primary sclerosing cholangitis

UC alkaline phosphatase

Antinuclear cytoplasmic

**onion-skin fibrosis**

cholangiocarcinoma

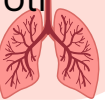**Ischemia of biliary tree**

## Sinusoidal Obstruction Syndrome

Jamaican bush-tea  
pyrrolizidine alkaloids

**bone marrow**

radiation cyclophosphamide  
emboli



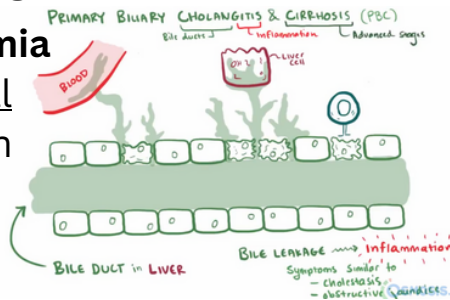
## Primary biliary Cirrhosis

Non-suppurative granulomatous

**Hyperbilirubinemia**

Antimitochondrial

florid duct lesion



## Secondary biliary cirrhosis

extrahepatic biliary tree

## Peliosis Hepatis

hemorrhage danazol

# Liver tumors

