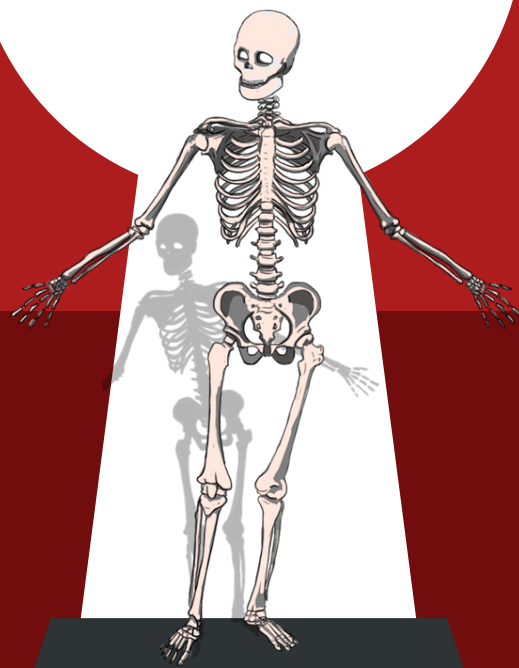


TEST BANK

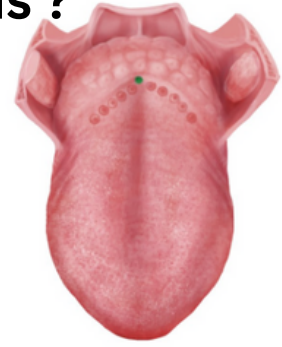# GI-ANATOMY LAB



Prepared by:  
Anad Alsabeelah  
Ebaa al-zubi  
*yasmin Alshabatat*

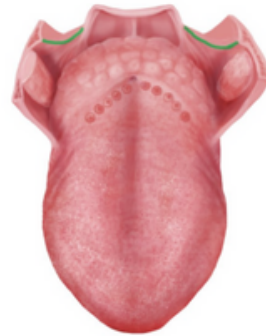
**1-the highlighted structure of the tongue is ?**

- A-Foramen cecum
- B-Sulcus terminalis
- C-Median sulcus
- D-Circumvallate papilla



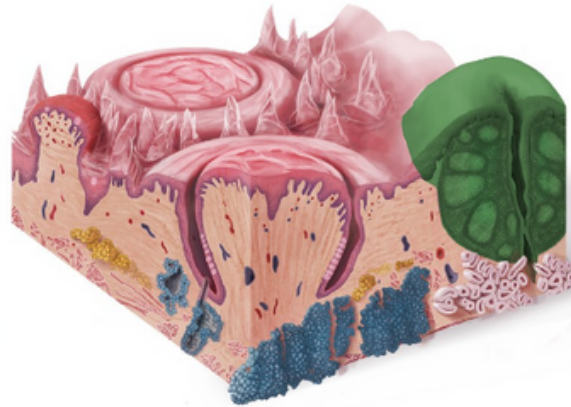
**2-the highlighted structure of the tongue is ?**

- A-Palatopharyngeal
- B-palatoglossal arches
- C-Lingual tonsils
- D- palatine tonsils



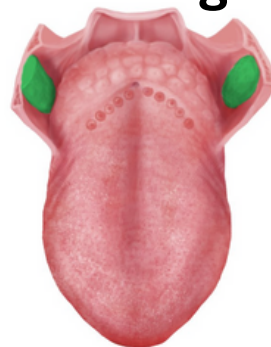**3-the highlighted structure of the tongue is ?**

- A-Palatopharyngeal
- B-palatoglossal arches
- C-Lingual tonsils
- D- palatine tonsils



**4-the highlighted structure of the tongue is ?**

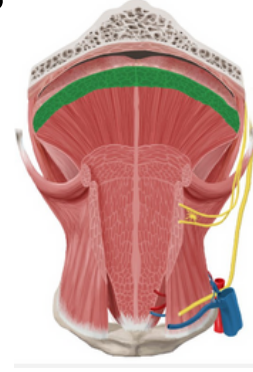
- A-Palatopharyngeal
- B-palatoglossal arches
- C-Lingual tonsils
- D- palatine tonsils



- 1=A
- 2=A
- 3=C
- 4=D

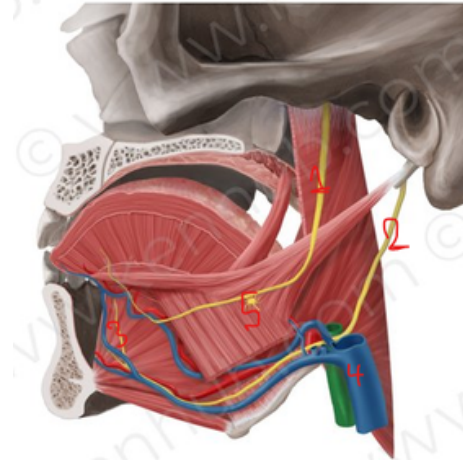
5-the highlighted structure of the tongue is ?

- A-Superior longitudinal muscle of tongue
- B-Transverse muscle of the tongue
- C-Genioglossus muscle
- D-Palatoglossus muscle



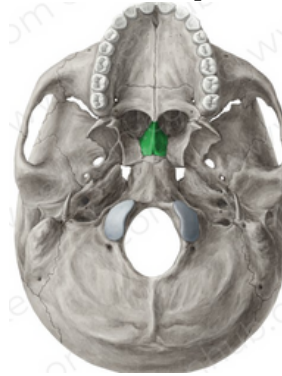
6-Which number represents hypoglossal nerve ?

- A-3
- B-4
- C-2
- D-1



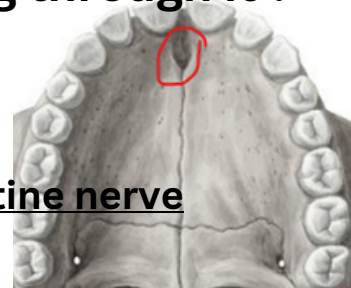
7-name this bone which is apart of hard palate ?

- A-choana
- B-stylomastoid foramen
- C-vomer
- D-maxillary



8- Define the pointed structure and what is passing through it ?

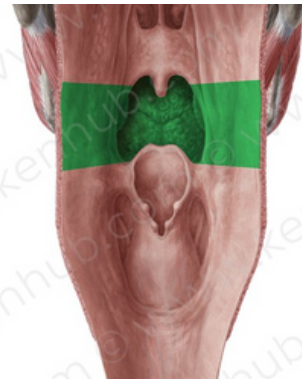
- A- foramen ovale - mandibular nerve
- B-Incise foramen - The nasopalatine nerve
- C- Lesser and greater palatine foramen -greater&lesser palatine nerve



- 5=A
- 6=C
- 7=C
- 8=B

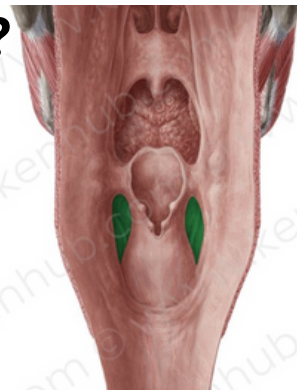**9-THE highlighted structure is ?**

- A-Nasopharynx**
- B-Oropharynx**
- C-Laryngopharynx**



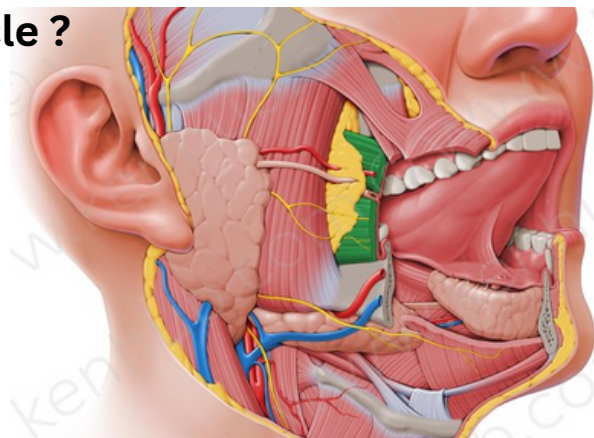
**10-THE highlighted structure is ?**

- A-Pharyngeal raphe**
- B-Piriform fossa**
- C-epiglottis**
- D-vallecula**



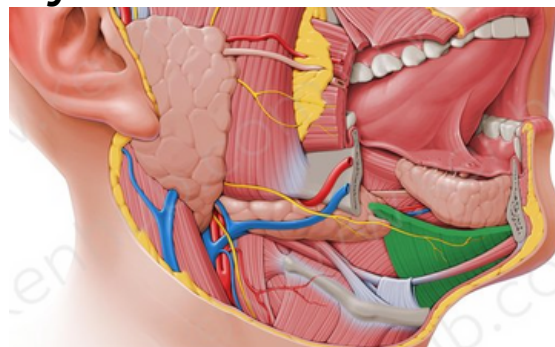
**11-parotid duct pierce which muscle ?**

- A-Masseter muscle**
- B-Buccinator muscle**
- C-Mylohyoid muscle**



**12-Submandibular gland is divided by which muscle ?**

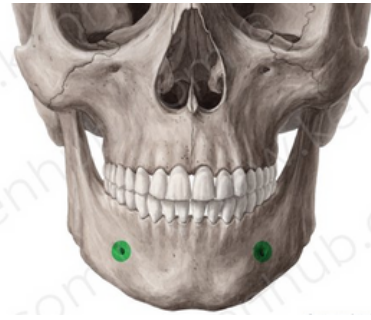- A-Masseter muscle**
- B-Buccinator muscle**
- C-Mylohyoid muscle**



**9=B**  
**10=B**  
**11=B**  
**12=C**

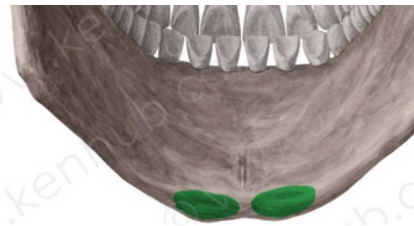**13- the highlighted structure is ?**

- A-Mandibular foramen
- B-Mylohyoid groove
- C-Mental foramen
- D-Digastric fossa



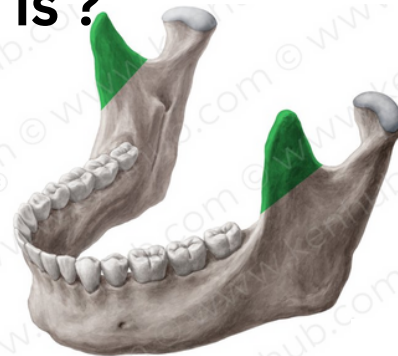**14- the highlighted structure is ?**

- A-Mandibular foramen
- B-Mylohyoid groove
- C-Mental foramen
- D-Digastric fossa



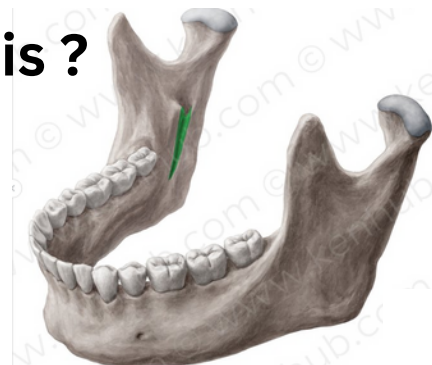
**15- the highlighted structure is ?**

- A-chondylar process
- B-coronoid process
- C-Mandibular foramen
- D- Mandibular notch



**16- the highlighted structure is ?**

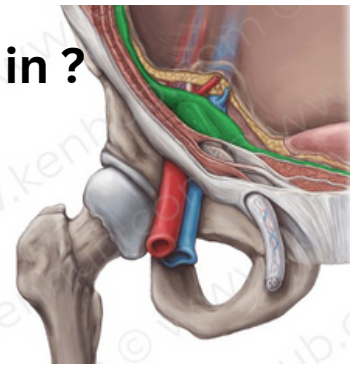
- A-Mandibular foramen
- B-Mylohyoid groove
- C-Mental foramen
- D-Digastric fossa



13-C  
14-D  
15-B  
16-B

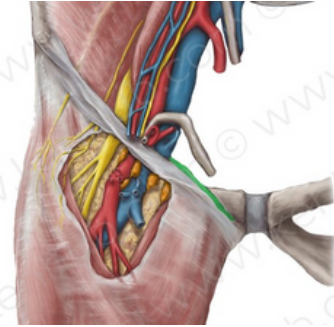
**17-Deep inguinal ring is an oval opening in ?**

- A-internal oblique
- B- fascia transversalis
- C-External spermatic fascia
- D-internal spermatic fascia



**18-pectineal ligament IS A continuation of?**

- A-Inguinal ligament
- B-lacunar ligament
- C-pectineal ligament



**19- NOT true about indirect inguinal hernia ?**

- A-common in young , unilateral .
- B-can reach the scrotum .
- C- reduced upward & lateral .
- D-lateral to epigastric vessels.
- E- feel impulse on the side of finger

**20-Which structure forms the inferior wall (floor) of the inguinal canal?**

- A-Transversus abdominis
- B-Inguinal ligament
- C-Internal oblique aponeurosis
- D-External oblique aponeurosis

**21-What is the correct position of the deep inguinal ring in relation to the inferior epigastric vessels?**

- A-It lies medial to the inferior epigastric vessels.
- B-It lies superior to the inferior epigastric vessels.
- C-It lies lateral to the inferior epigastric vessels.

**17=B**

**18=B**

**19=E**

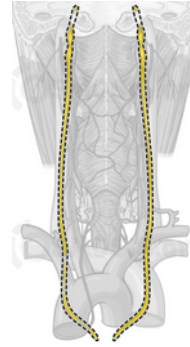
**20=B**

**21=C**

# second lab

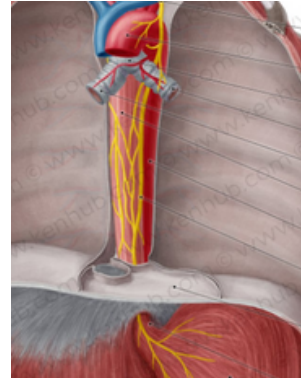
1-which structure is indicated ?

- A- piriform fossa
- B- vagus nerve
- C- descending thoracic aorta



2- the middle part of esophagus is supplied by ?

- A- left vagus nerve
- B- inferior thyroid artery
- C- descending thoracic aorta

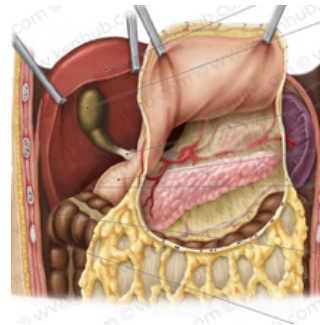


3- the lower third of esophagus drains lymph in ?

- A- posterior mediastinal
- B- inferior thyroid
- C- left gastric

4- not a part of stomach bed :

- A- the Lt. crus of diaphragm
- B- The lesser sac
- C- the transverse mesocolon
- D- the splenic vein
- E- the body of pancreas



5- Through which part of the stomach does the nutrition normally leave the stomach?

- A- pylorus
- B- body
- C- fundus

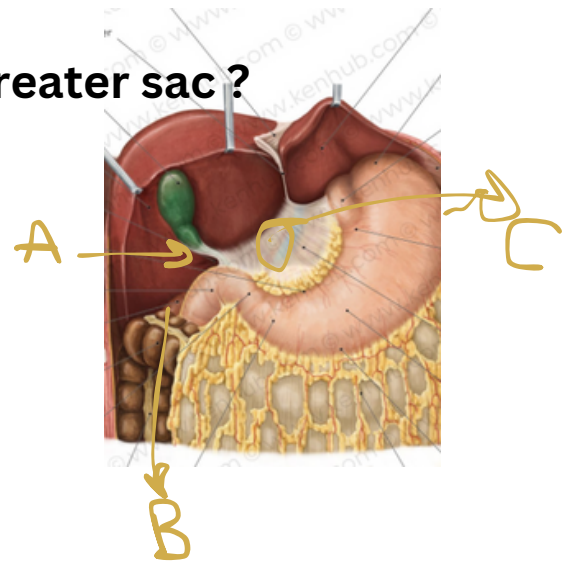
- 1=B
- 2=C
- 3=C
- 4=D
- 5=A

6-which structure connects lesser sac & greater sac ?

A- A

B- B

C- C



7-Which structure lies at the left-posterior side the stomach?

A-aorta

B-pancreas

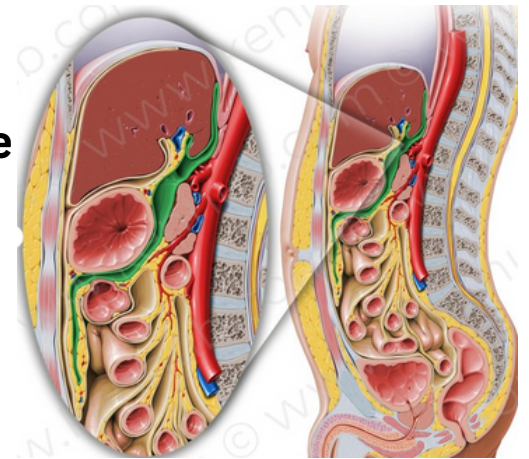
C-spleen

8- which covers the highlighted structure anteriorly ?

A-spleen

B-stomach

C-pancreas

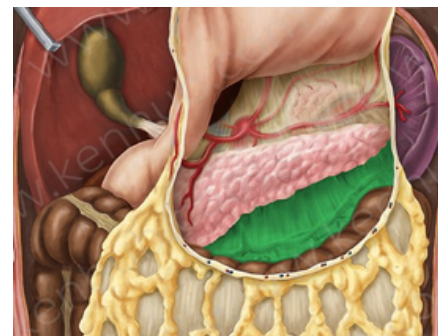


9- the highlighted structure is ?

A-greater omentum

B-lesser sac

C- mesocolon



6=A

7=C

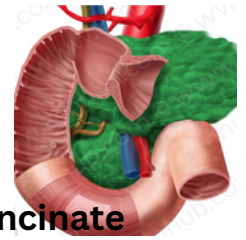
8=B

9=C



10-One of the following is true about the small intestine

- A-The ileum is wider than the jejunum
- B-The jejunum is light red appearance
- C-The ileum is supplied with long terminal branches
- D-The jejunum has thicker wall

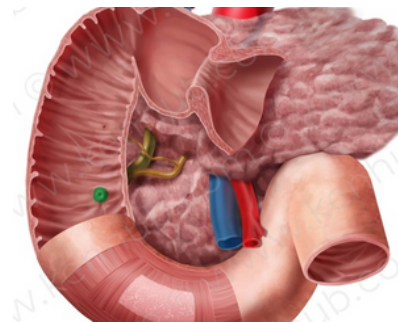


11- One of the following not a true about the pancreas

- A-The part which is posterior to the superior mesenteric vessels called uncinata process
- B-The blood supply is splenic and the superior and inferior pancreaticoduodenal arteries
- C-Posteriorly there is the bile duct
- D-Posteriorly there is transverse colon

12-This opening from inside called ?

- A-Sphincter of oddi
- B-minor duodena papilla
- C-Ampulla of vater
- D-Major duodenal papilla

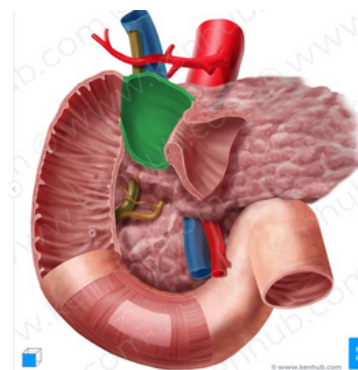


13-Not true about first part of duodenum ?

- A-It is runs upward and backward at the level L1 to the right
- B-Interiorly there is a gallbladder
- C-Posteriorly there is epiploic foramen

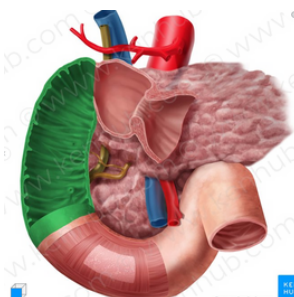
14-not related laterally to the pointed part ?

- A- The right ureter
- B-right colic flexure
- C-ascending colon
- D-right lobe of the liver



15-It is anterior to the pointed structure ?

- A-Coils of jejunum
- B-head of pancreas
- C-The right ureter
- D-the root of mesentery



- 10=D
- 11=B
- 12=C
- 13=D
- 14=C
- 15=B

16-Not true about the fourth part of duodenum ?

A-It is 1 in .

G-Ends in the duodenojejunal junction at the level of the L2

B-Superiorly there is uncinete process of pancreas

C-Anteriorly the root of the mesentery

D-Posteriorly coils of the jejunum

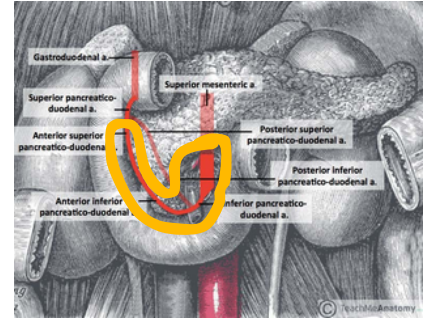
17-The pointed structure is the supply of the one of the following ?

A-Liver

B-duodenum

C-stomach

D-Small intestine



16=D

17=B

**GOOD  
LUCK!**