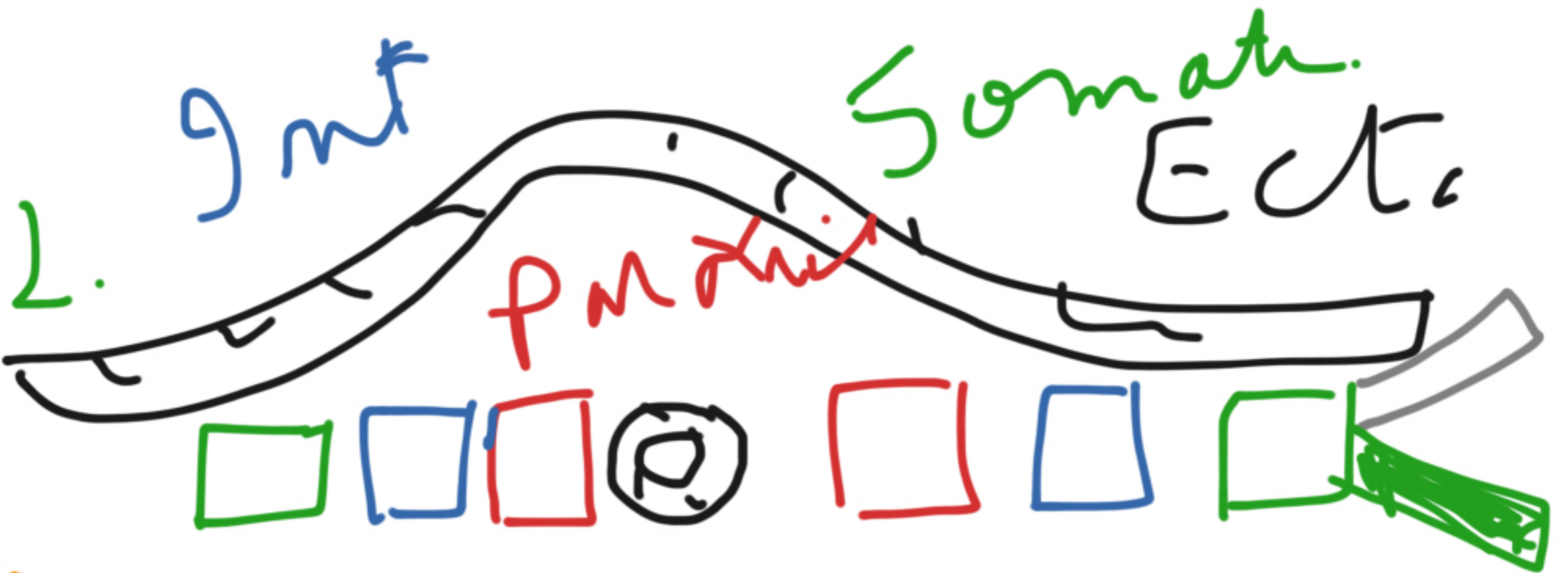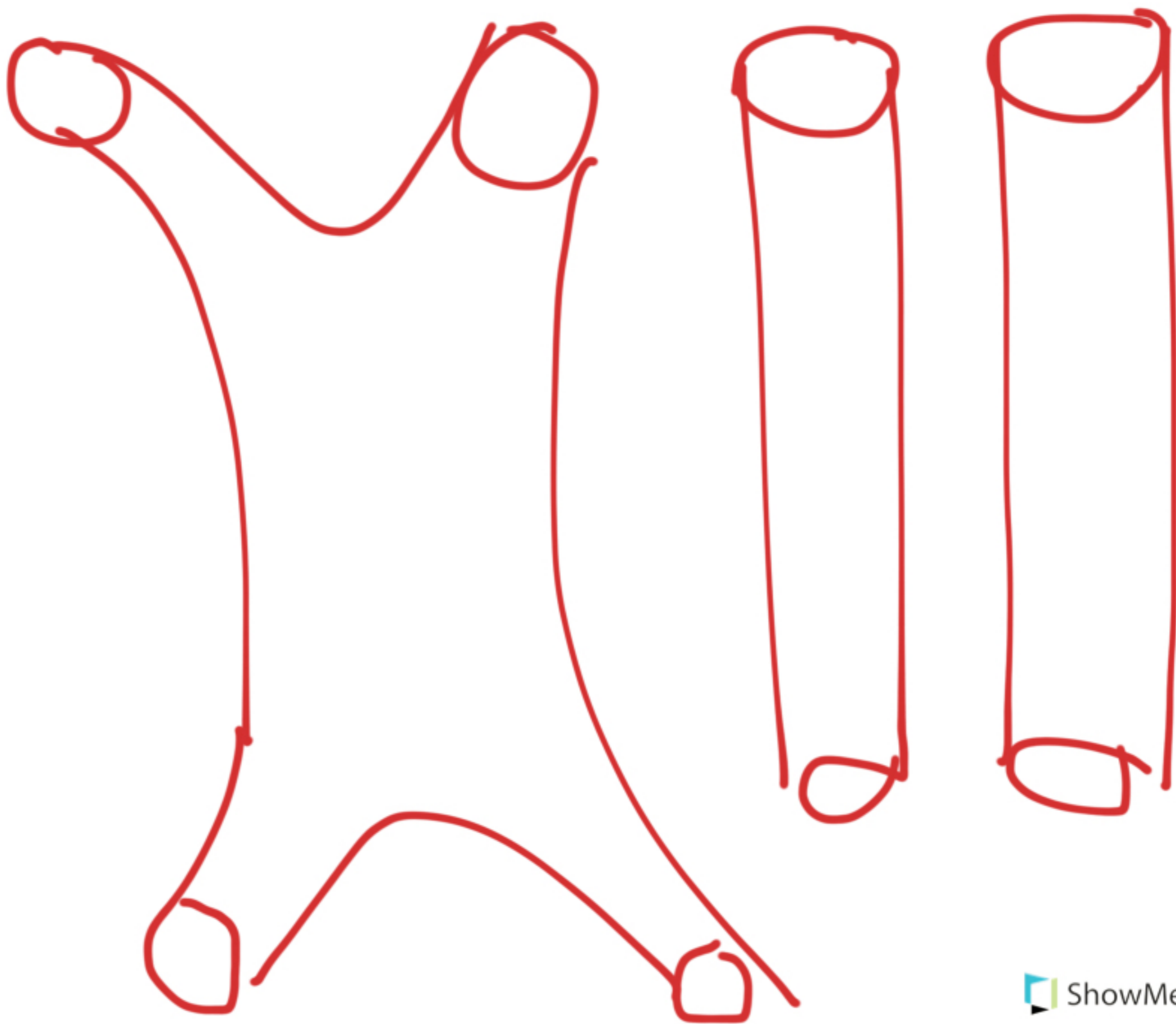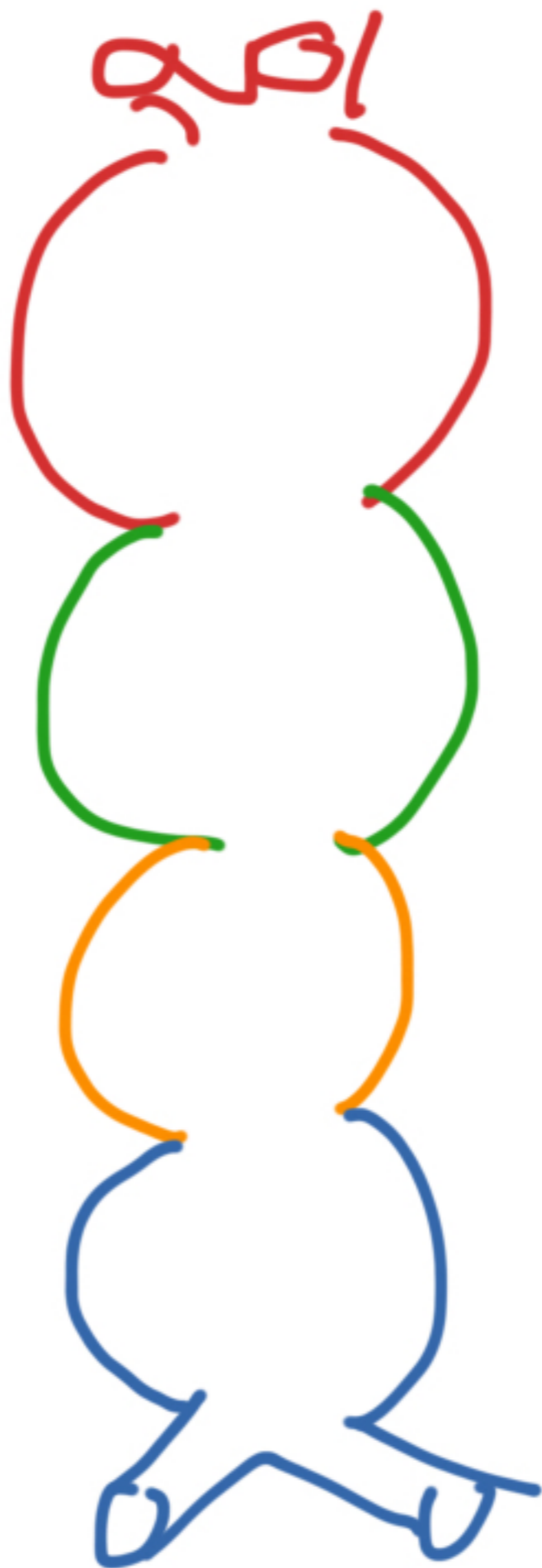


Cranial  
Emb. bus  
medis

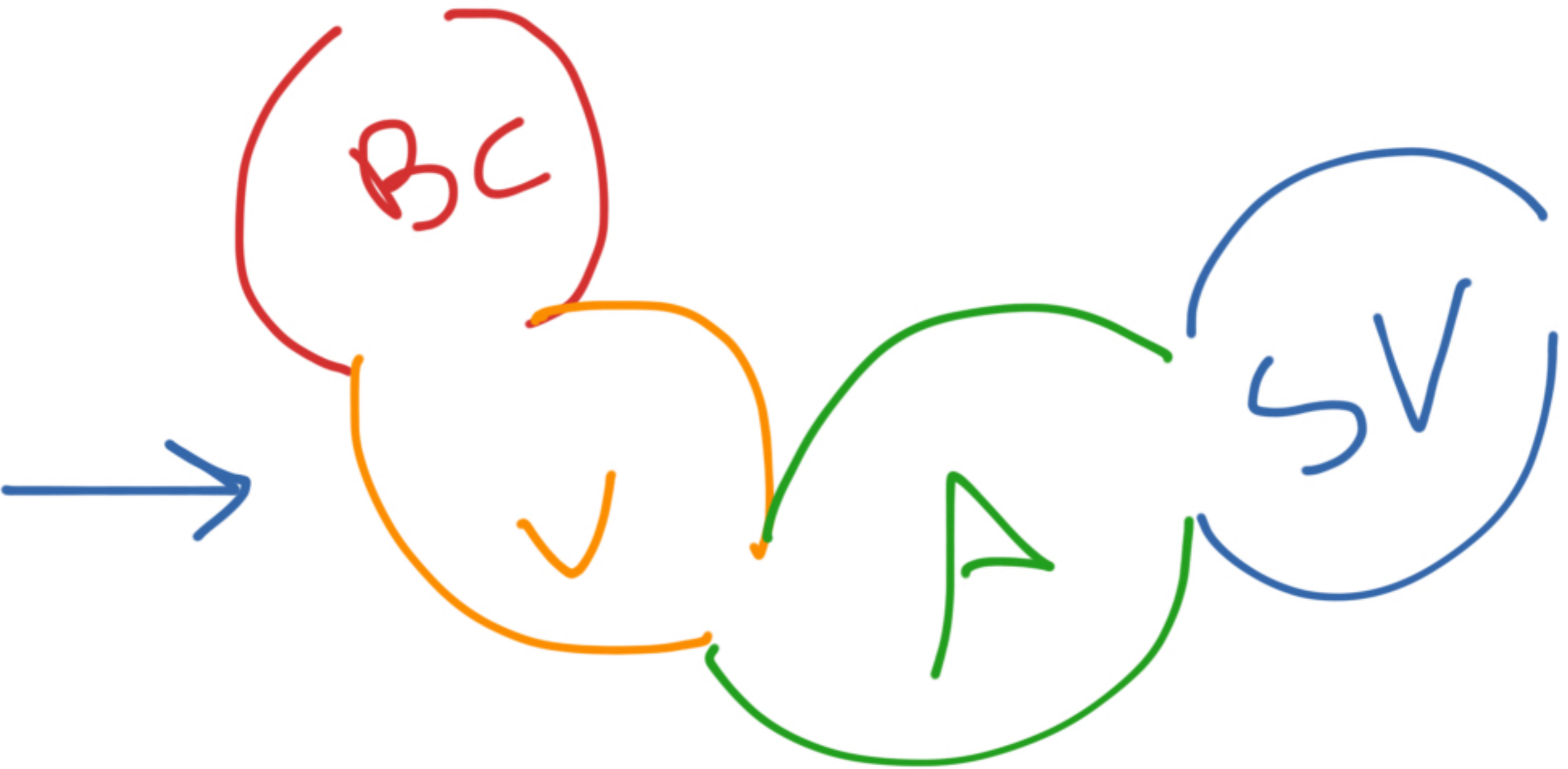


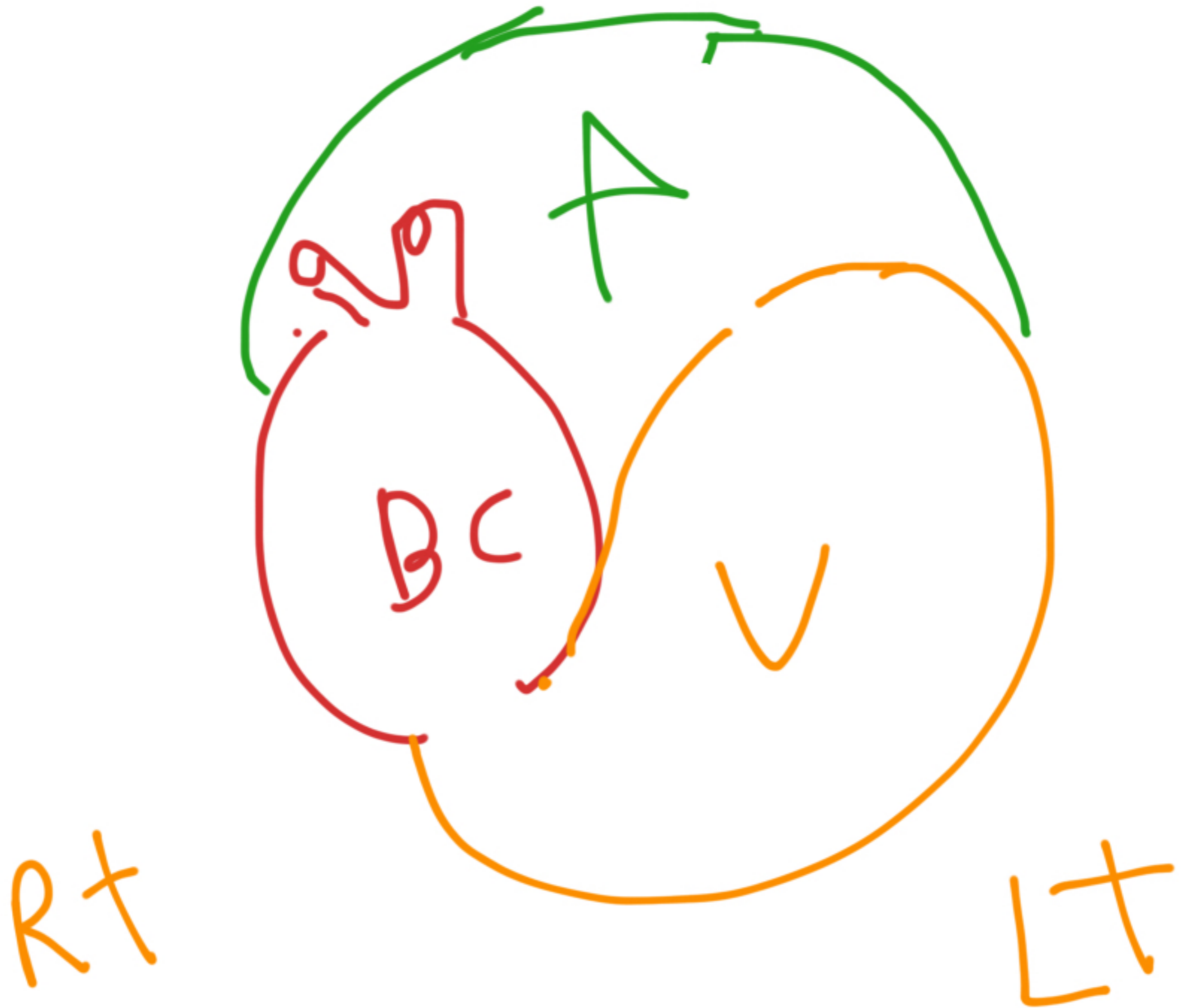P.V

PA

S.V

Caudal





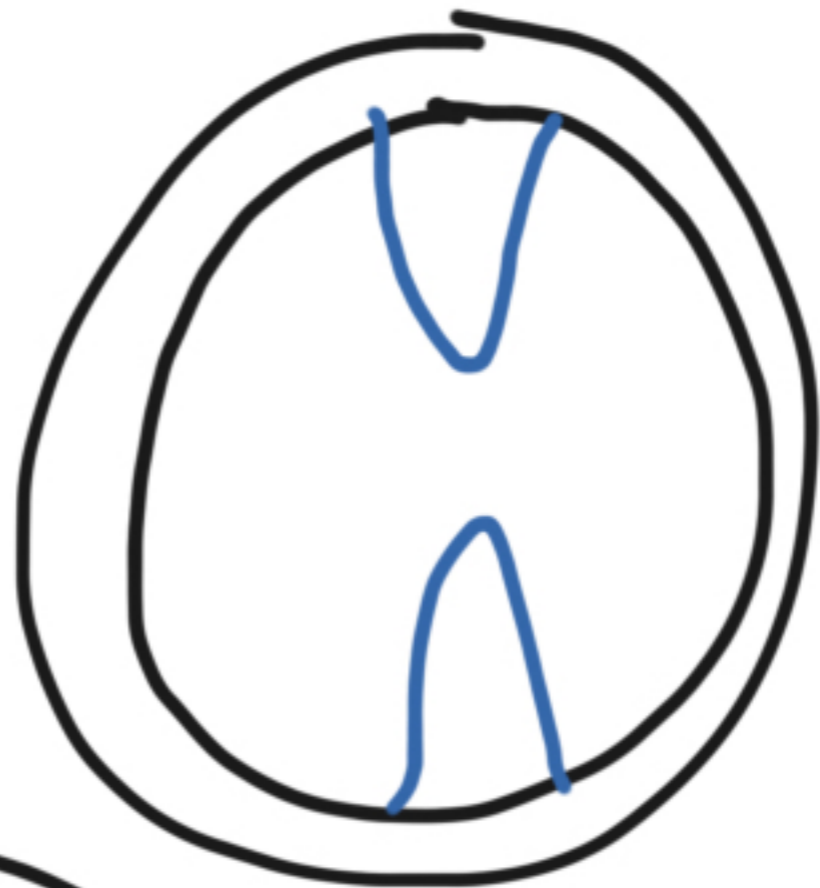
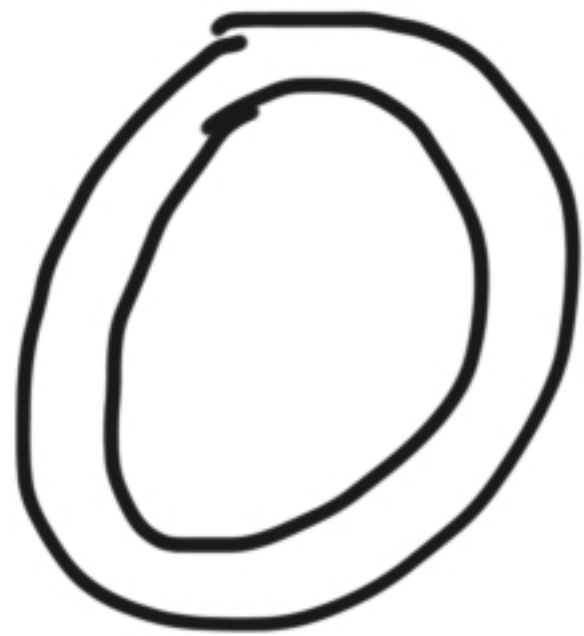
Atrio



Ventriale

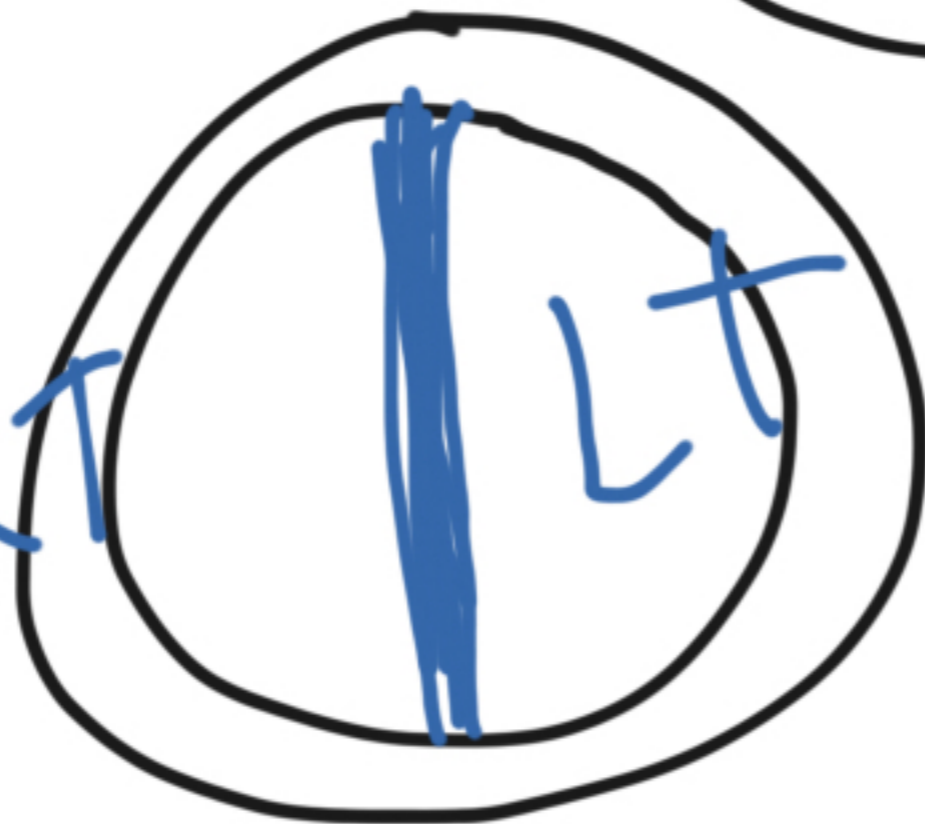



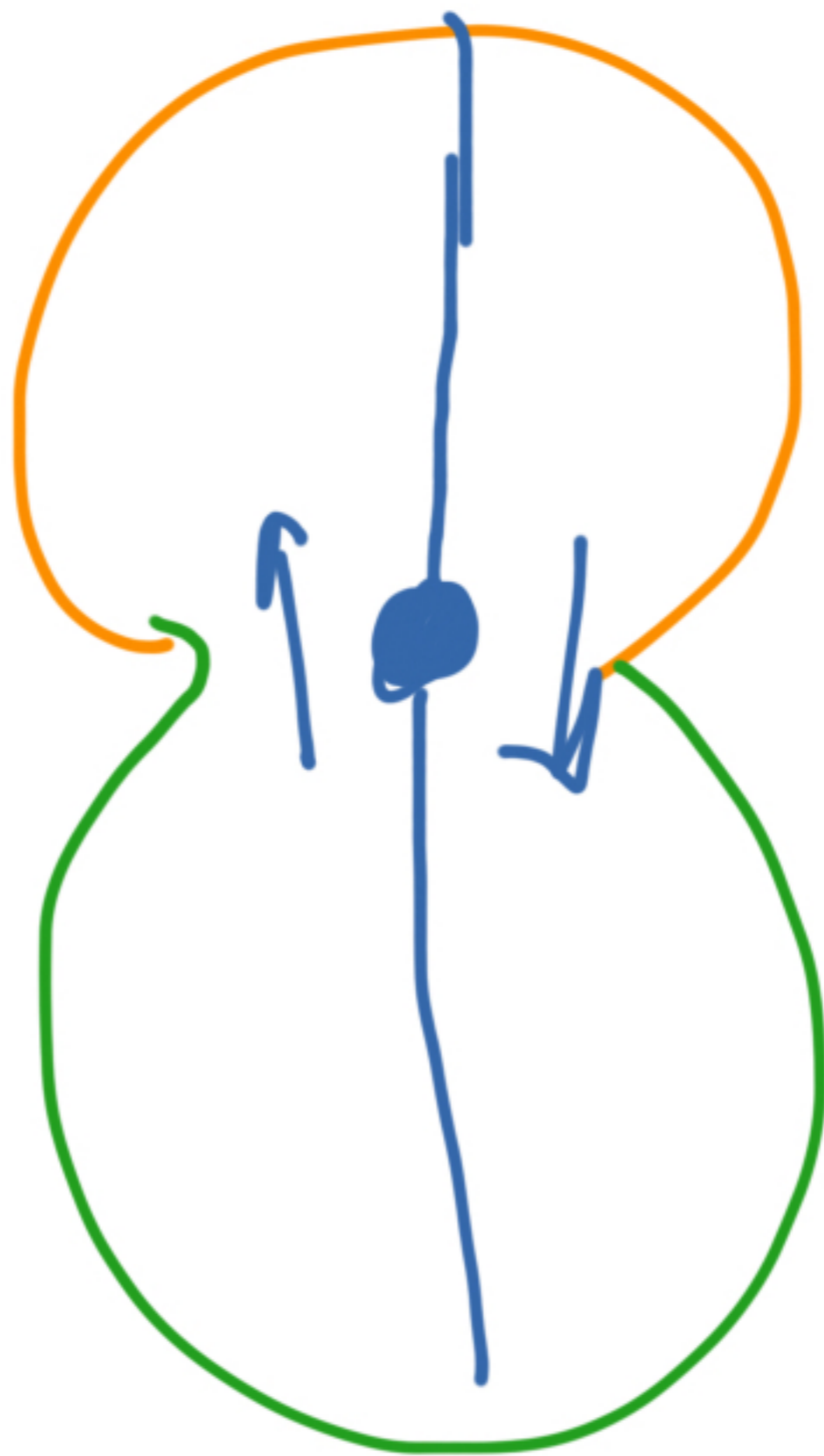


AZ

RT



S.gant

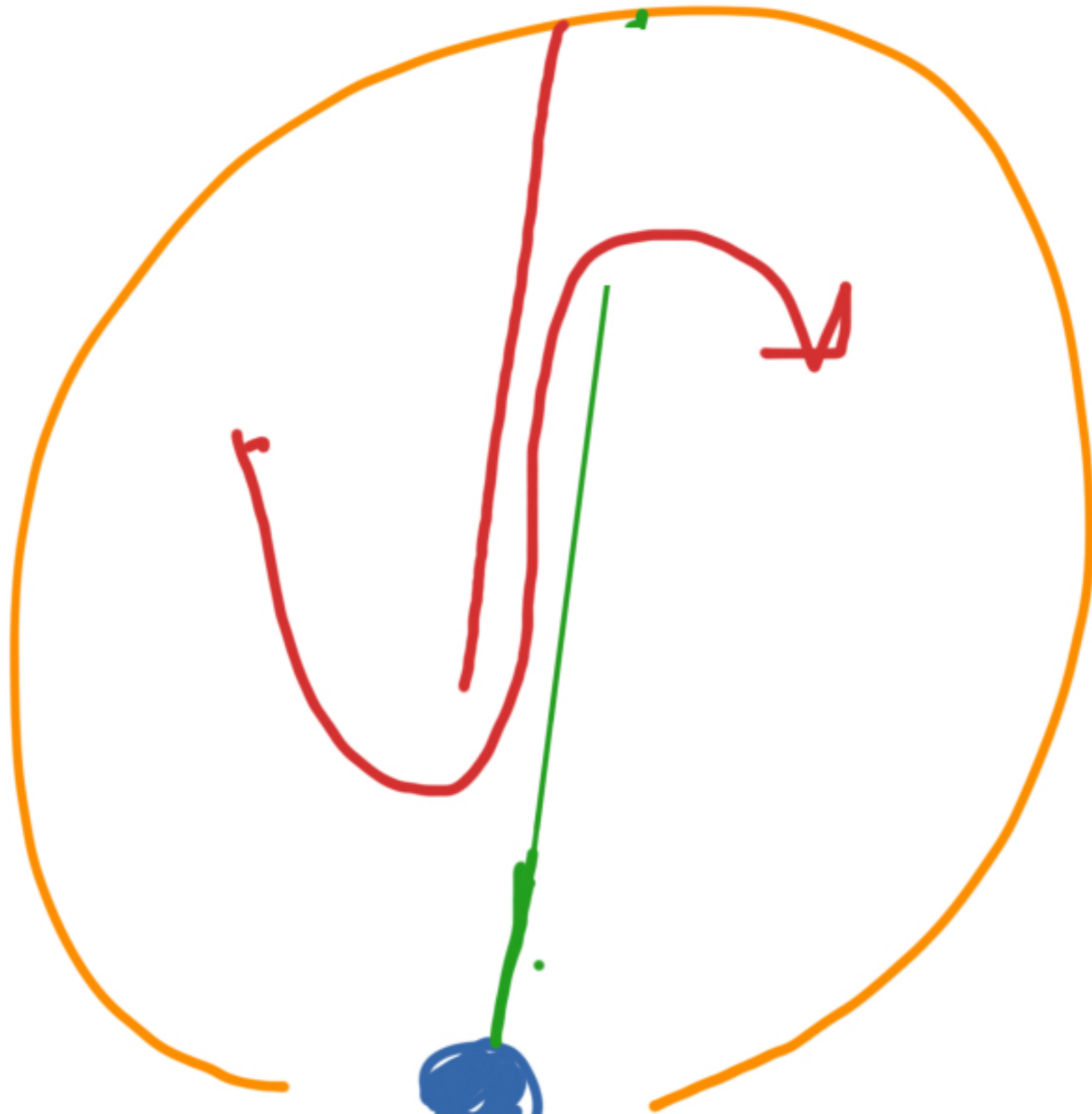




S.P

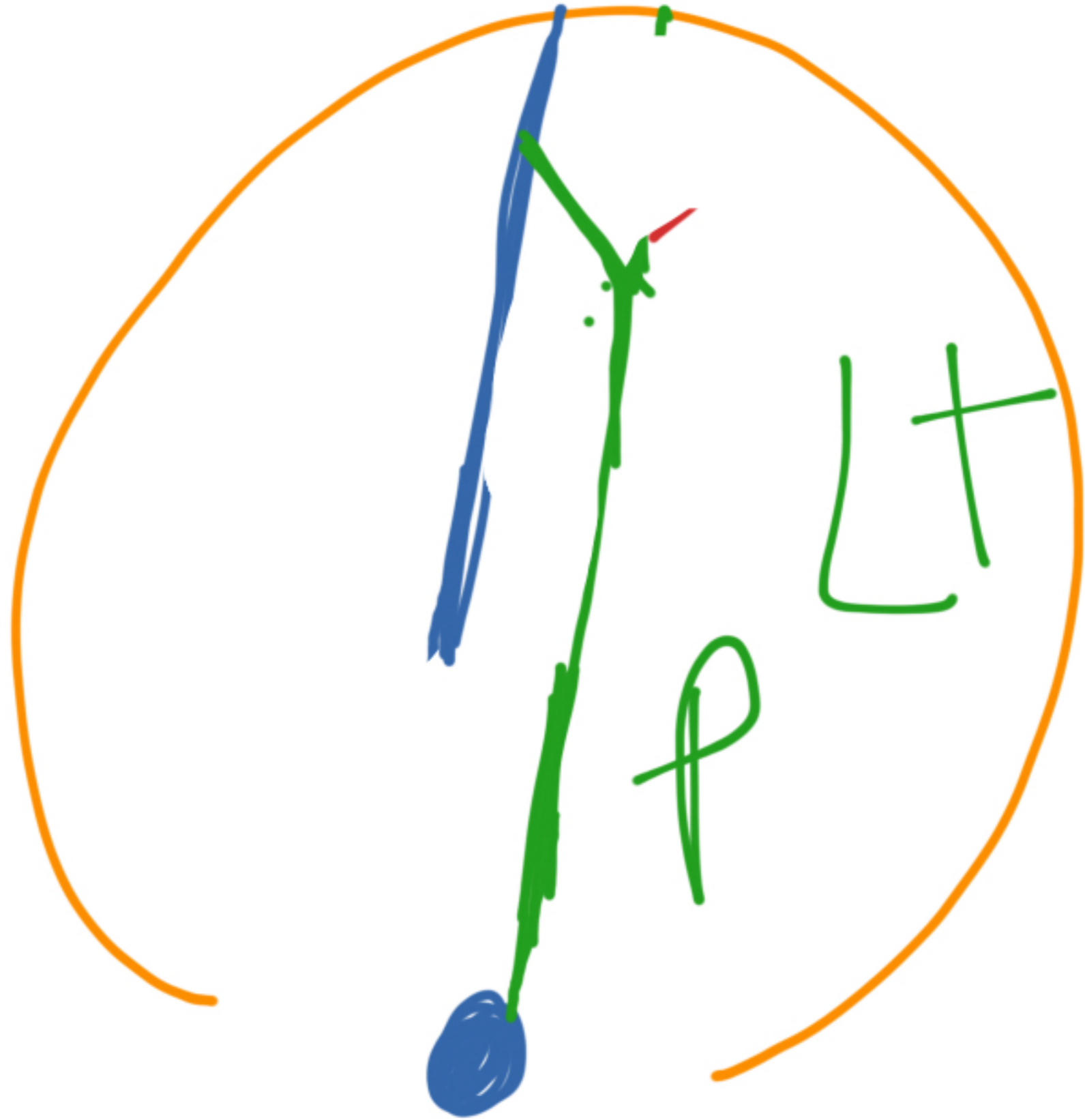
OS

SS

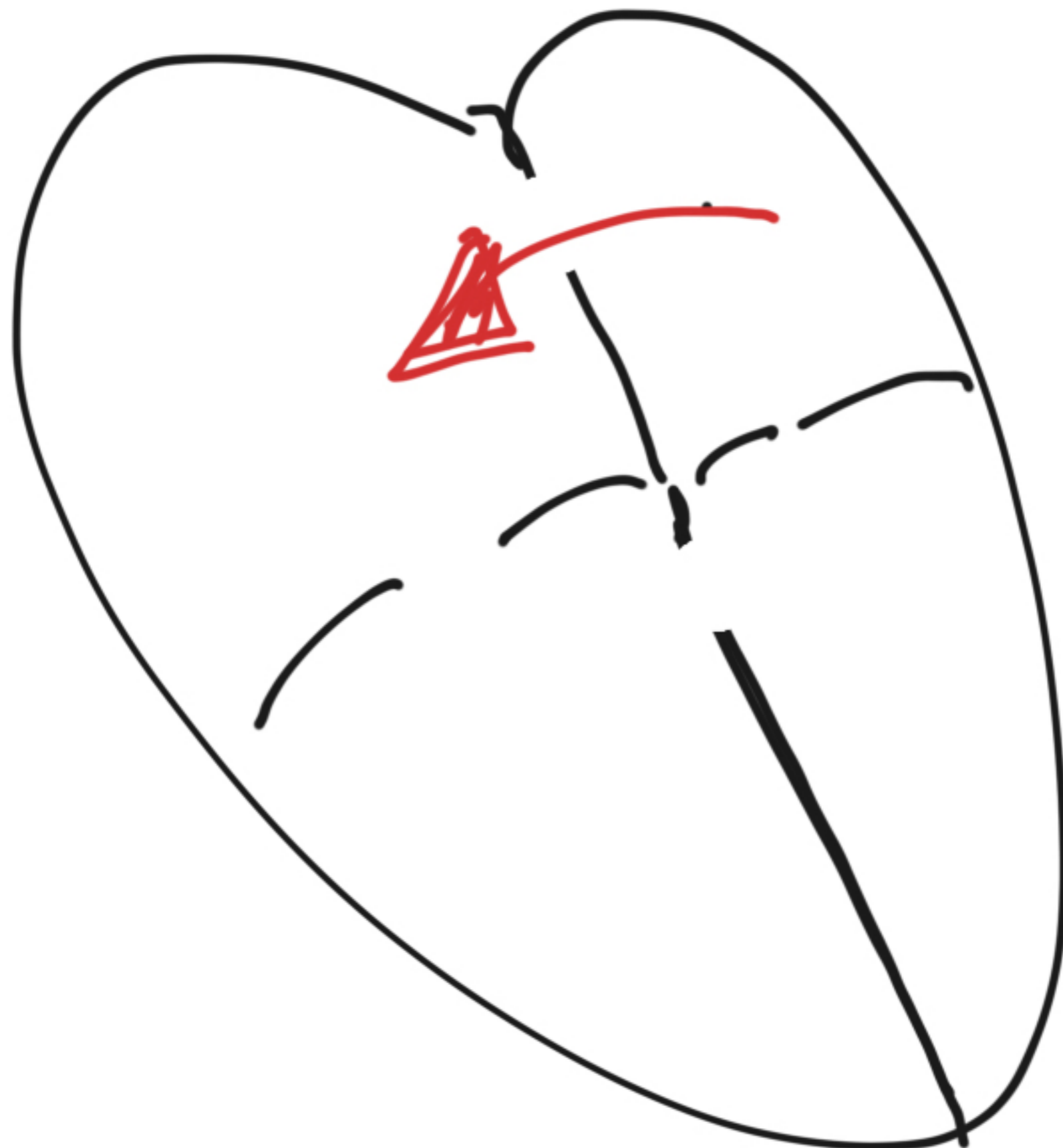


of

S.

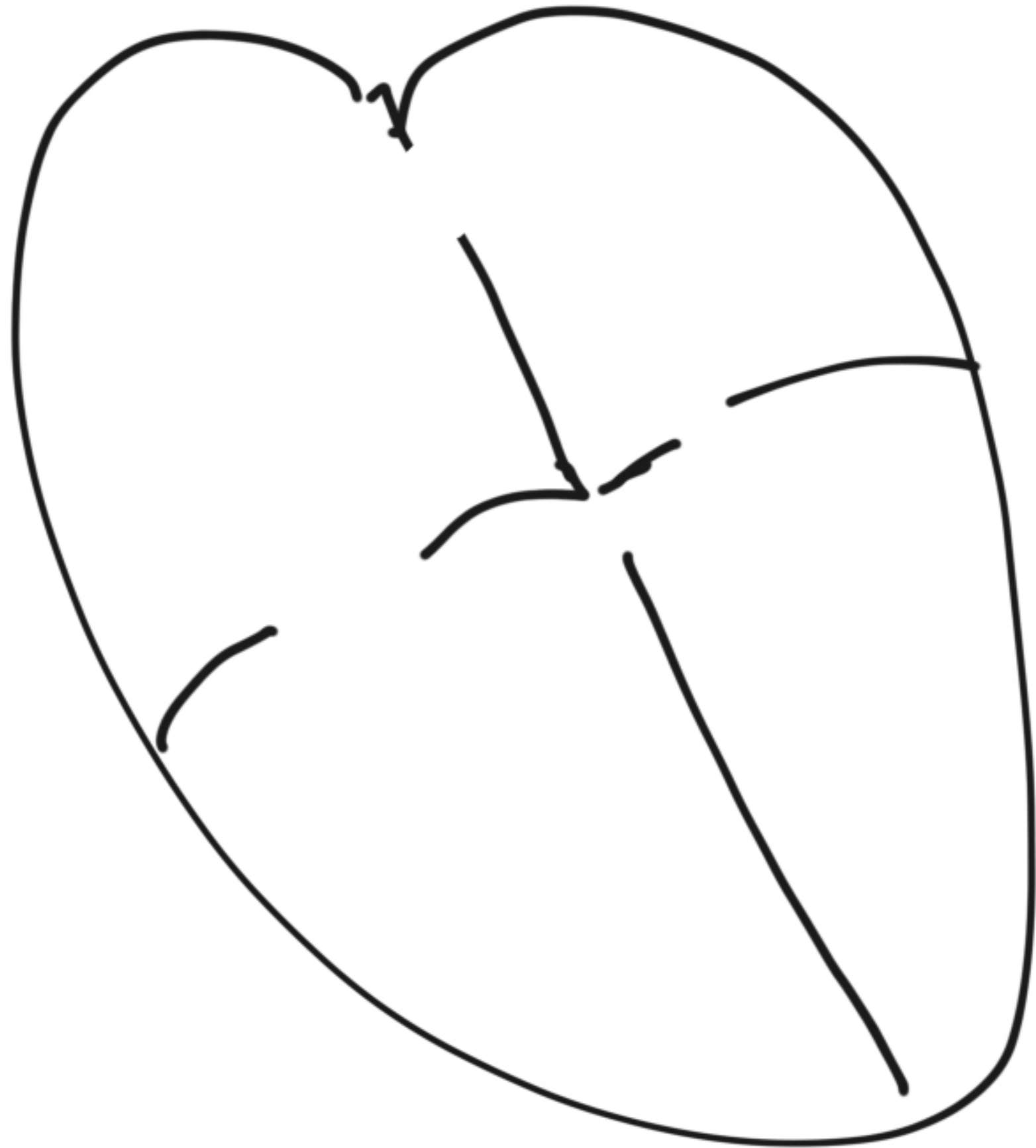


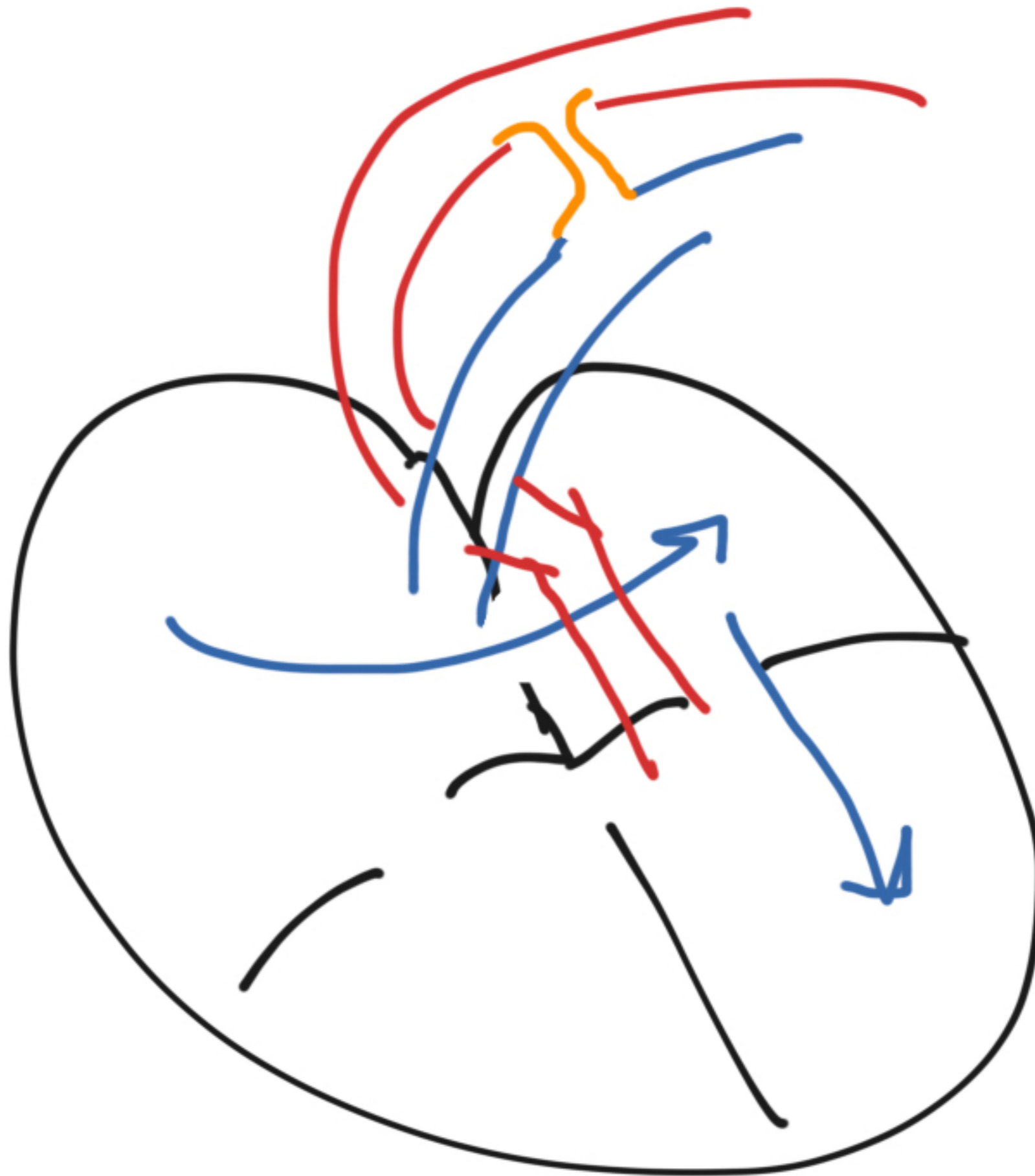
$R^+$



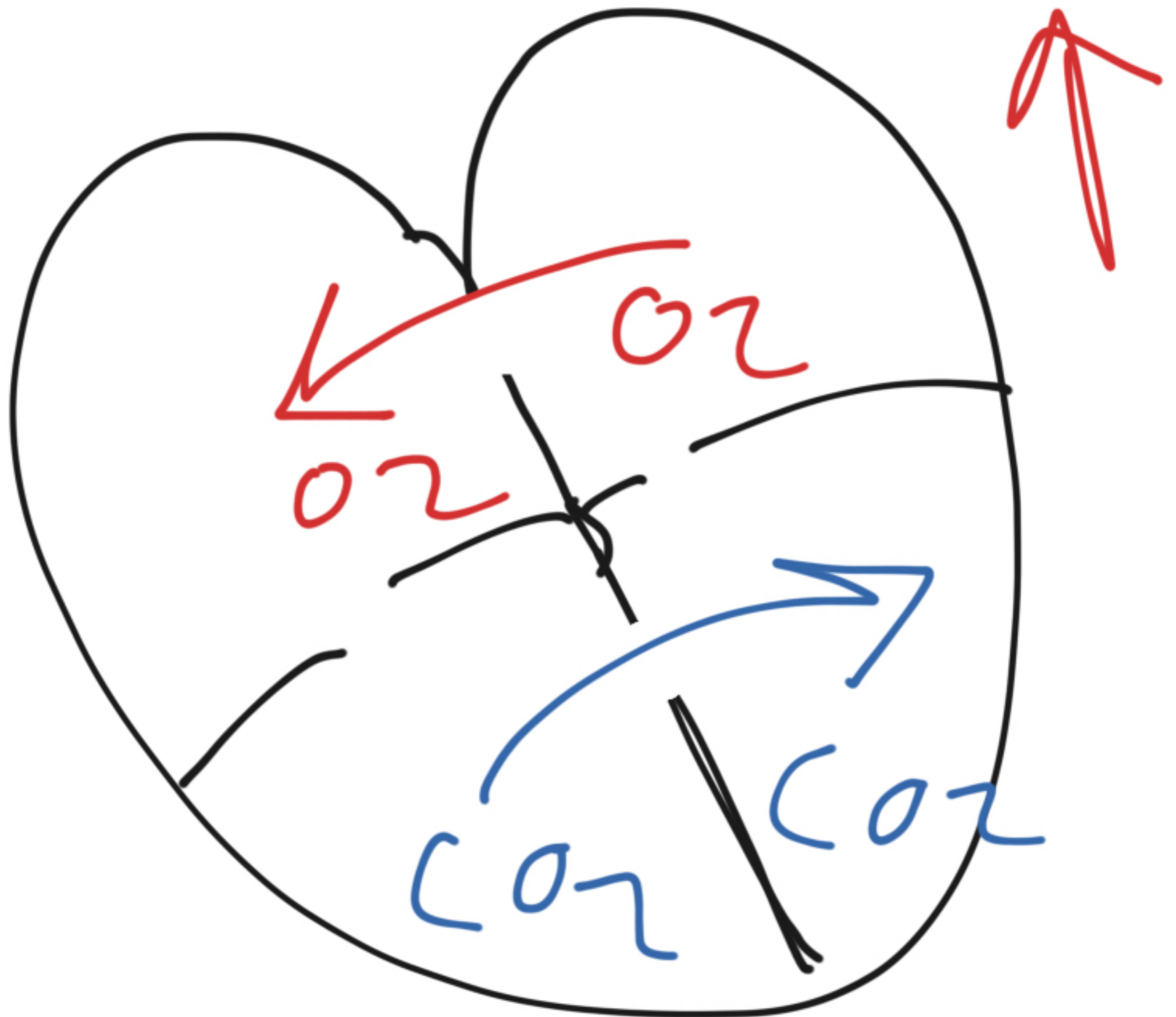
$U^+$

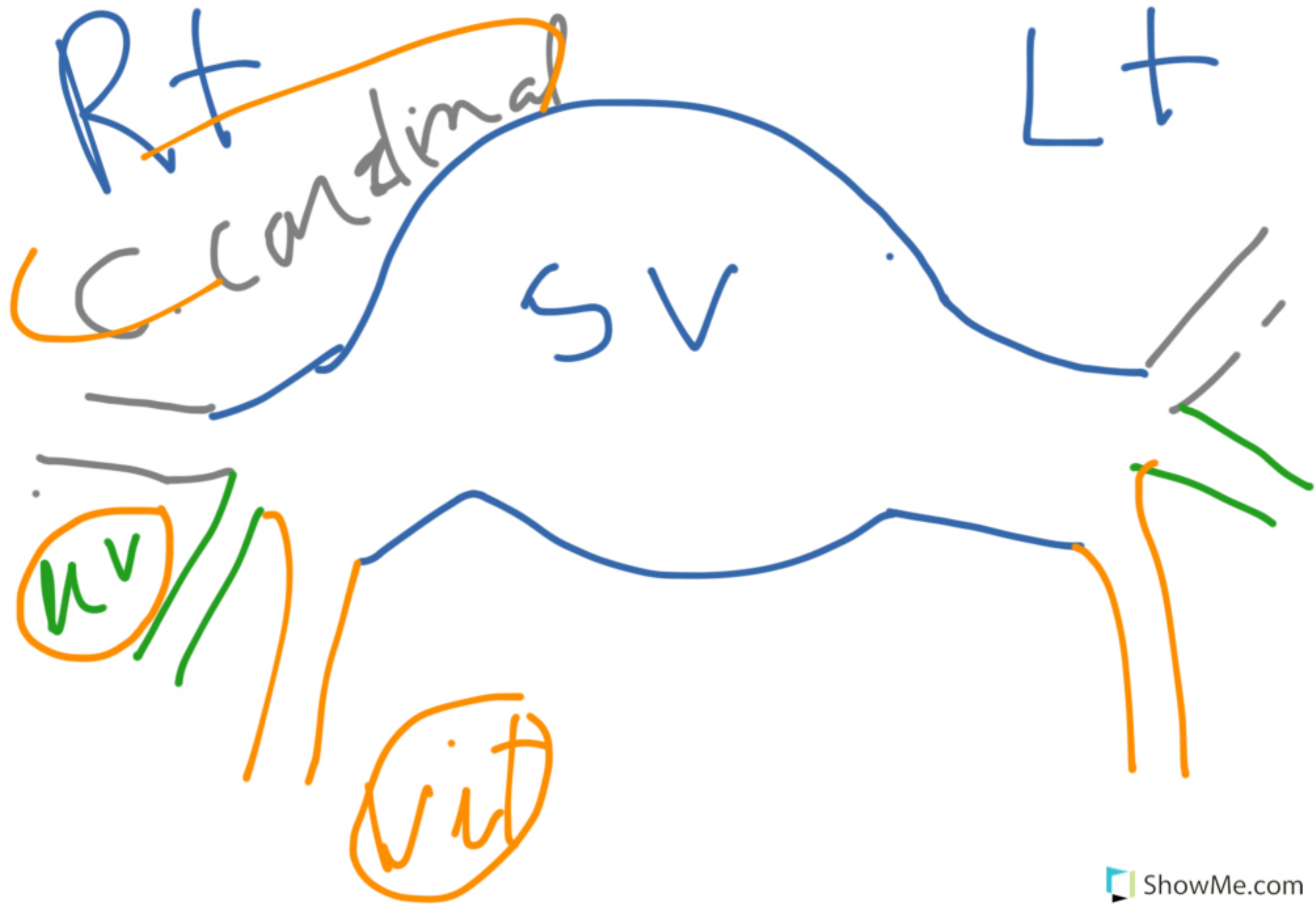
$L^+$   $\rightarrow$   $R^+$   
Automatic  
 $R^+$   $\rightarrow$   $L^+$   
Automatic

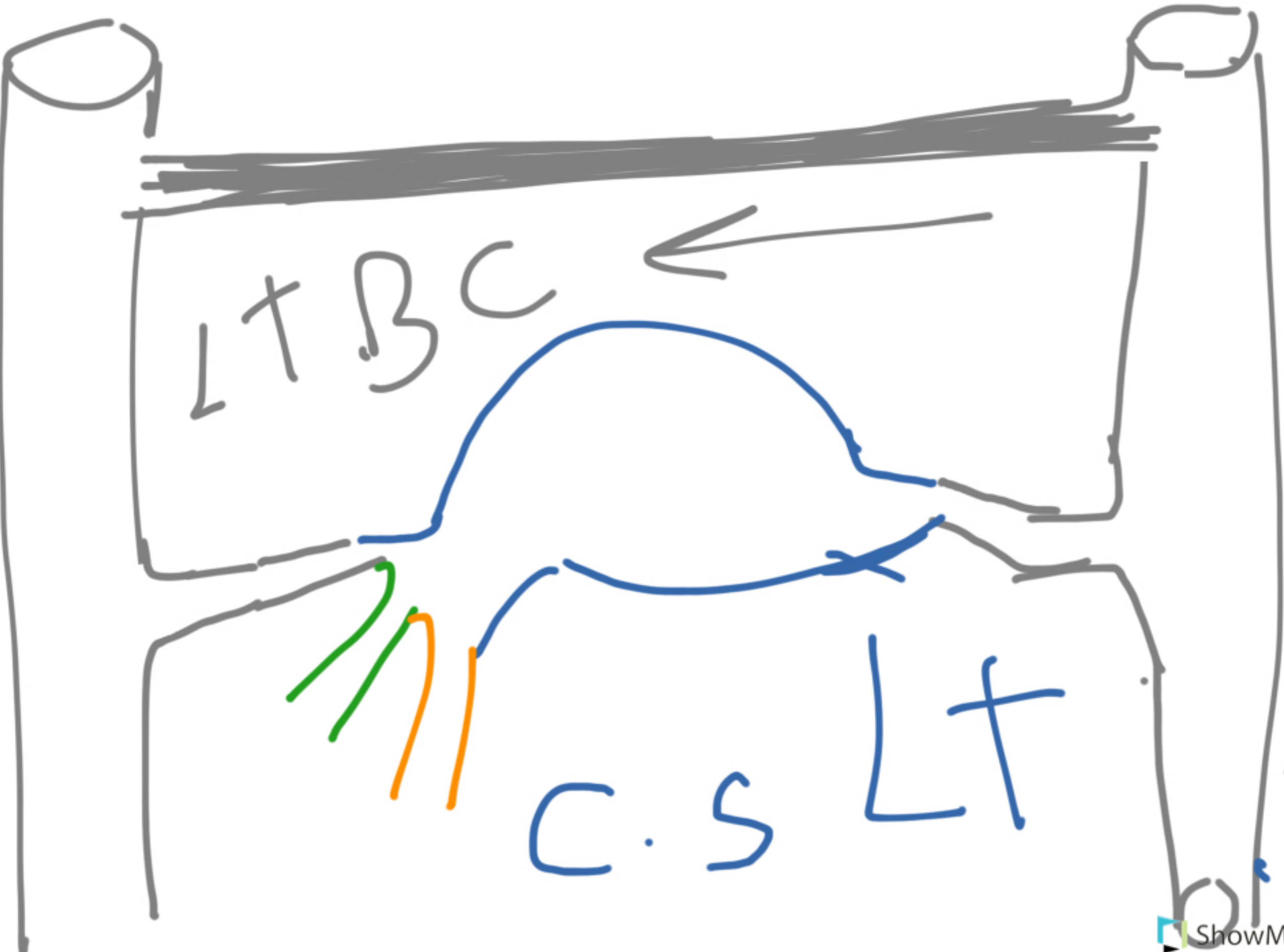






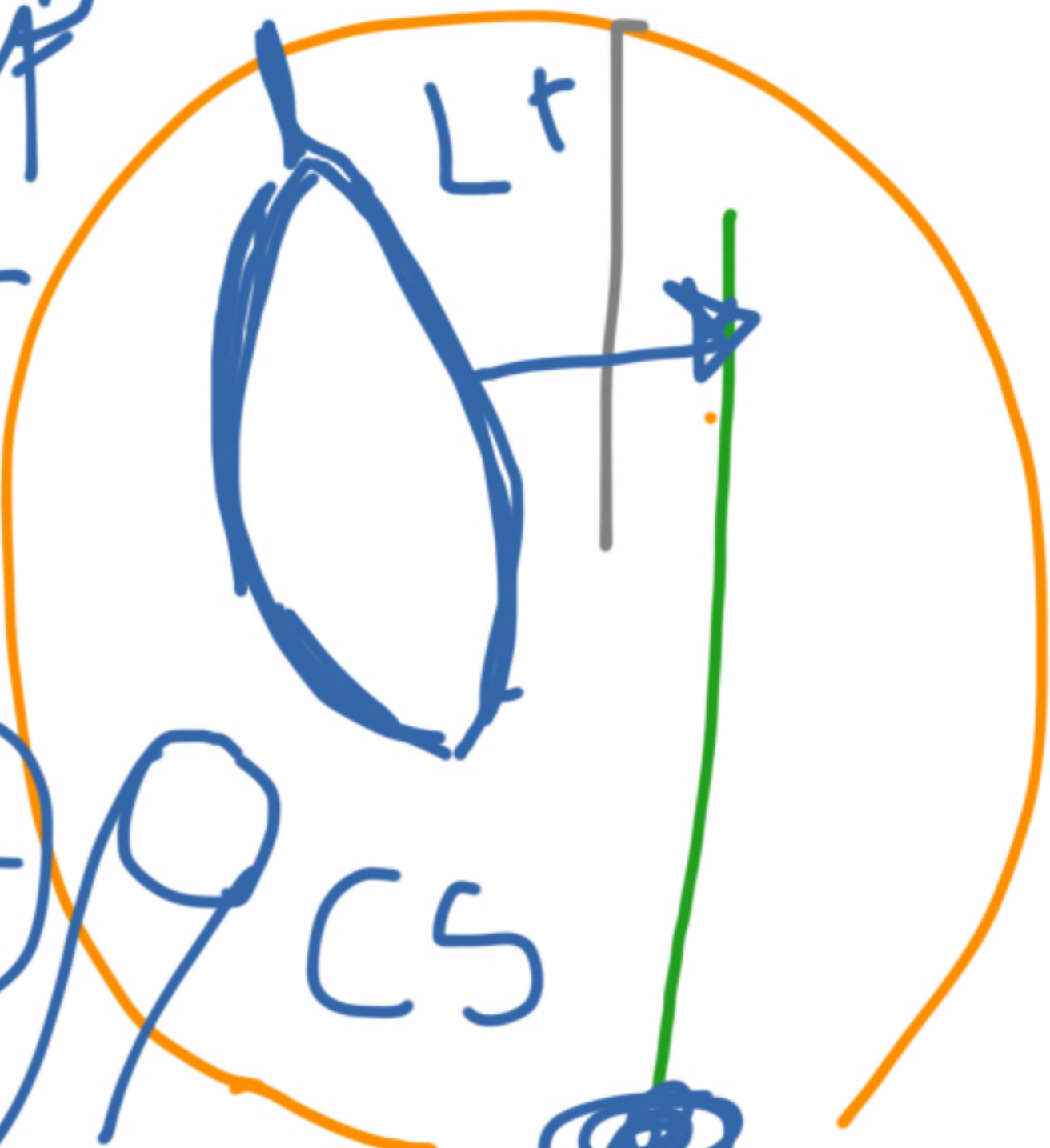






S. Samp

C.T



L+

g v l

CS

Simone A. Train

