



Histology

past papers

By yaqeen Arabiat.

1. Fenestrated capillaries in:

- A. Kidney
- B. Spleen
- C. Liver.
- D. Bone

Answer : A

2. Internal elastic lamina is prominent in:

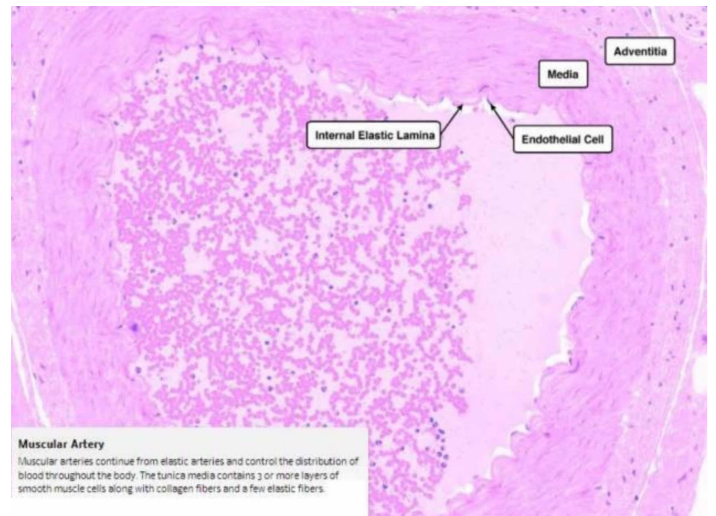
- A. Radial artery
- B. Common carotid artery
- C. Descending thoracic aorta
- D. Arterioles.

Answer: A

LAB

1. what type of vessel could this be ?

- a. radial artery
- b. aorta
- c. inferior vena cava
- d. iliac artery

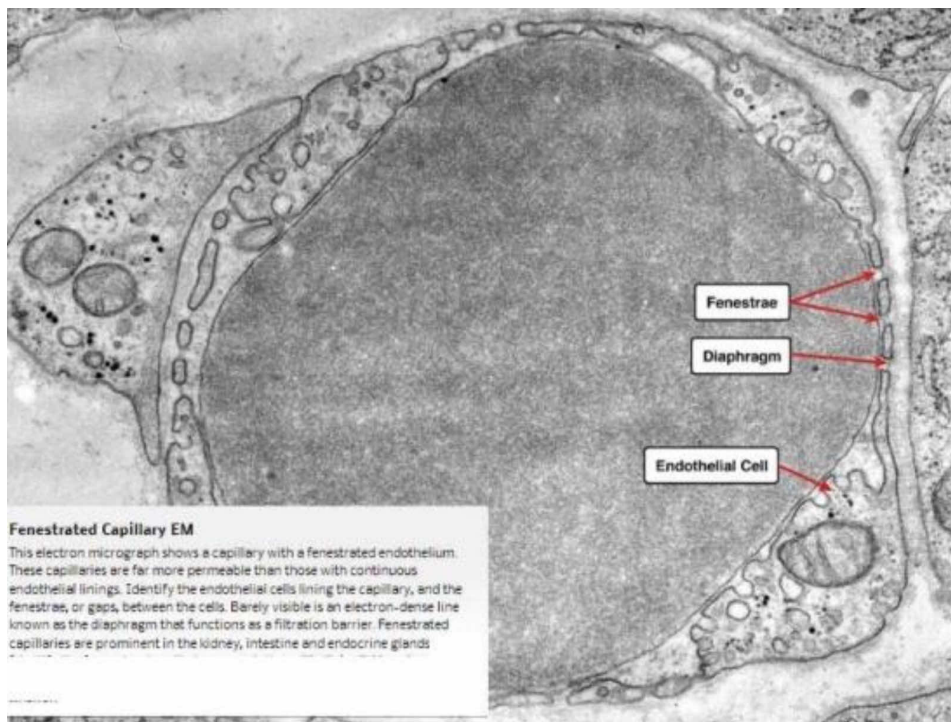


Answer: A

2. Identify

- a. Fenestrated capillary
- b. Continuous capillary

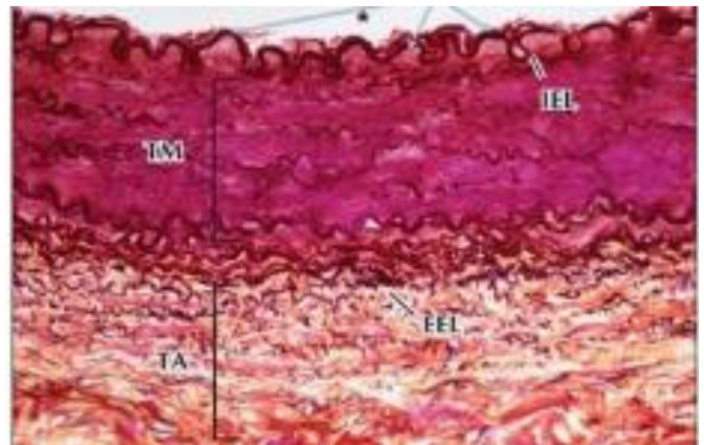
Answer: A



Dr. Amjad Shatarat

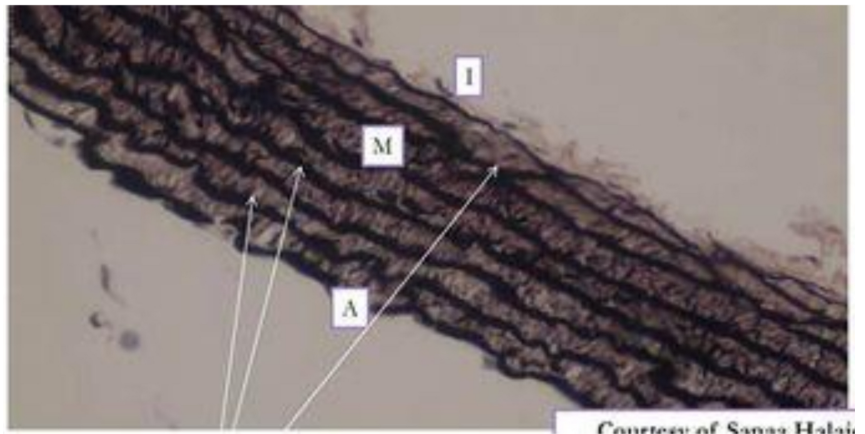
1. the following photo represents?

Answer: Radial artery



2.the following represents?

Answer:aorta



Good Luck