



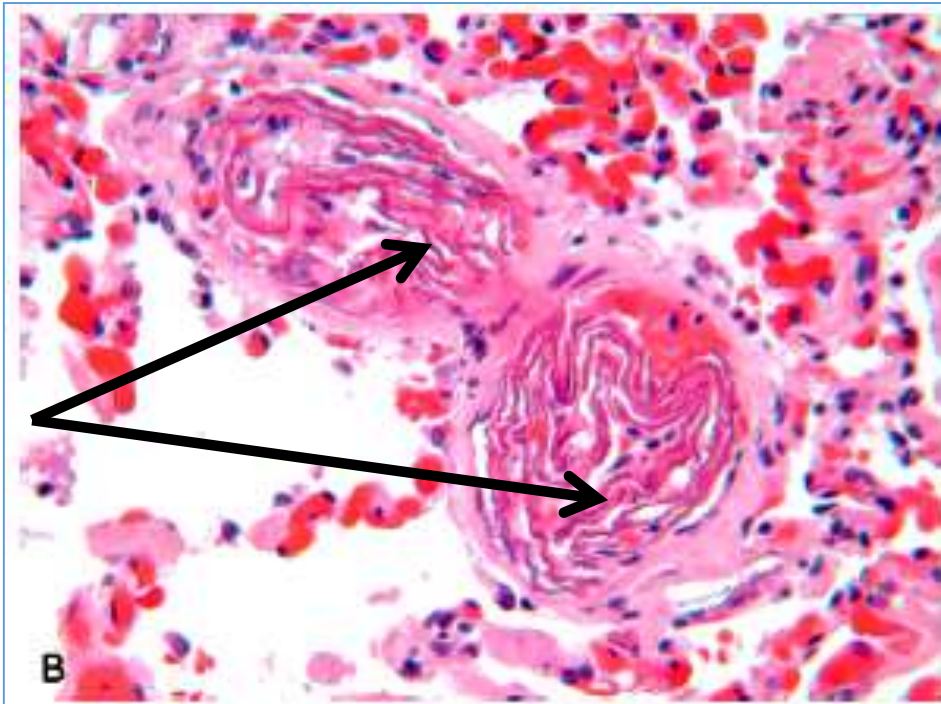
# Cardiovascular System - Pathology Practical 2023-24

**3<sup>rd</sup> year medical students**

Dr. Nisreen Abu Shahin

**A 26 years old pregnant woman had a complicated Caesarian section. 12 hours after delivery of her baby, she started to develop shortness of breath, decreased consciousness, and seizures. She died a few hours later. Autopsy was performed. This is a microscopic section from her lung. What is the most likely cause of her death?**

**Amniotic fluid embolus:  
keratin and fetal  
squamous epithelial cells  
in pulmonary arterioles**

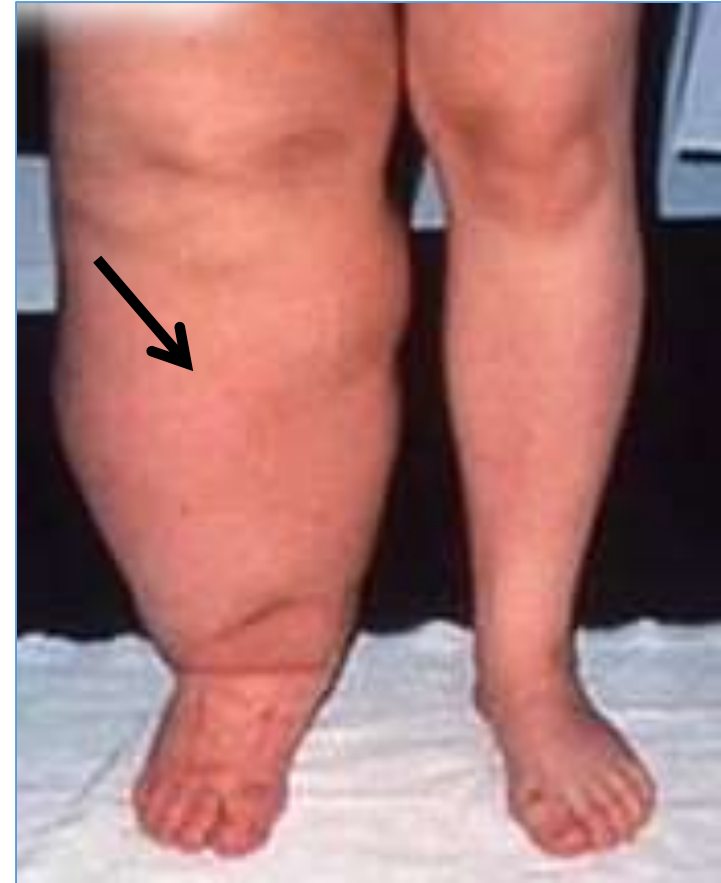

# *Lymphedema*

- Types? Give examples on causes :

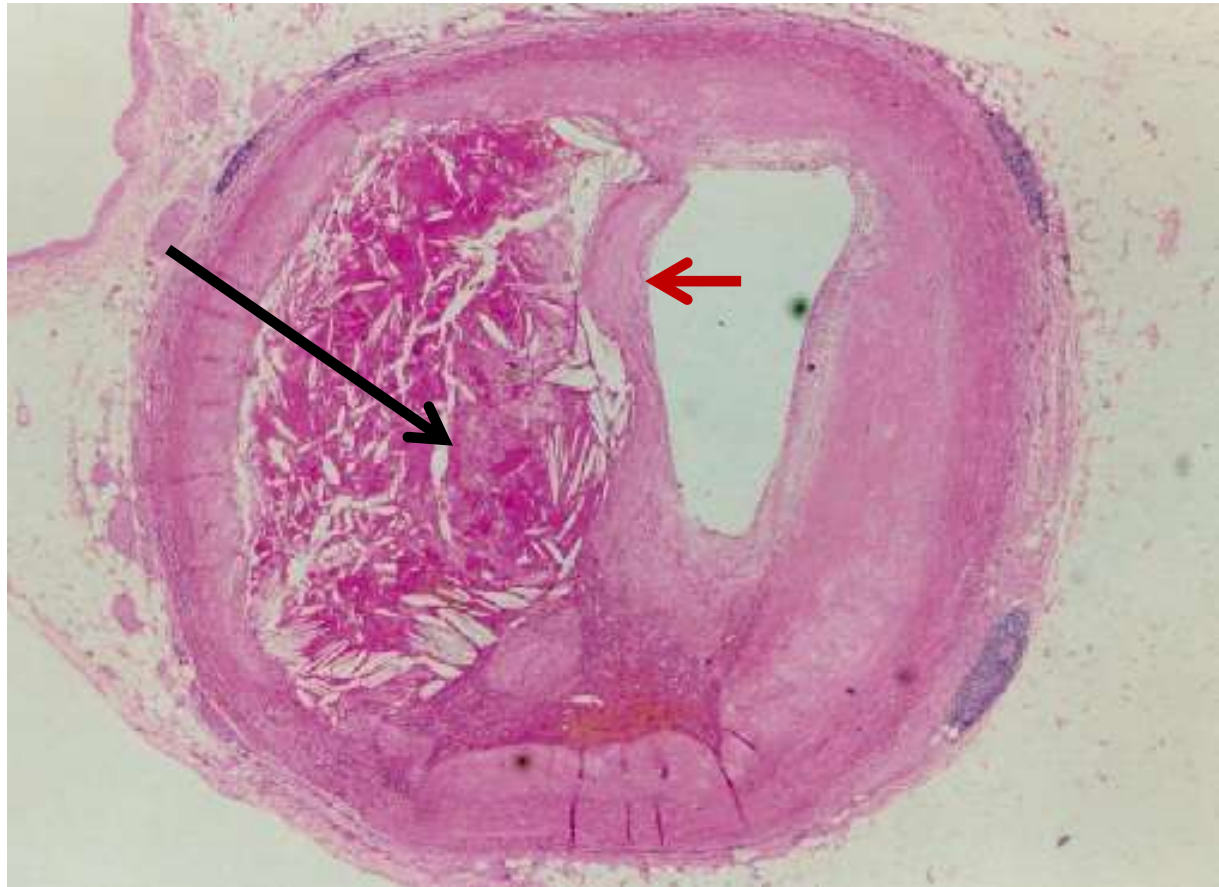1- Primary: congenital  
( example is cystic hygroma)

2- secondary: neoplasms;  
filariasis; fibrosis; post  
treatment effect .....



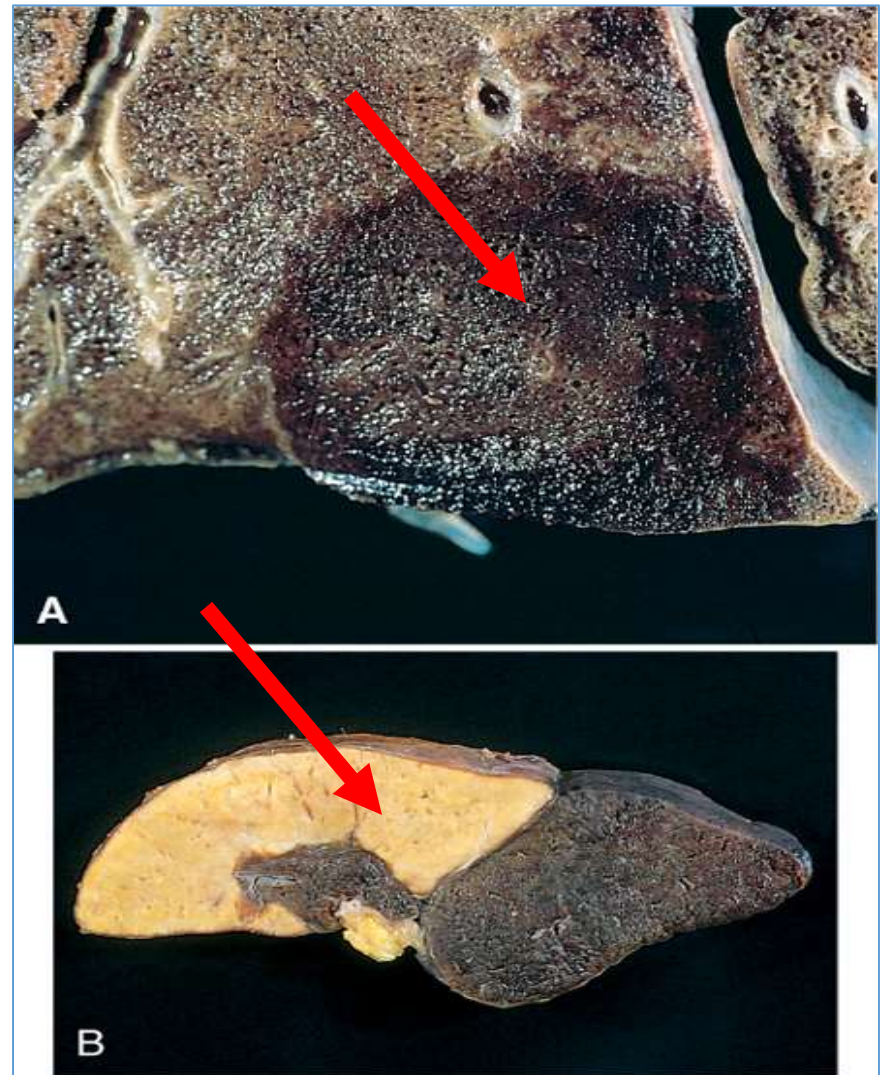
# Atherosclerosis- atheroma

- Red arrow?  
**Fibrous cap**
- **black arrow?**  
**lipid** or  
necrotic **center**
- What do the  
whitish needle-  
like structures  
represent?  
**Cholesterol  
crystals**



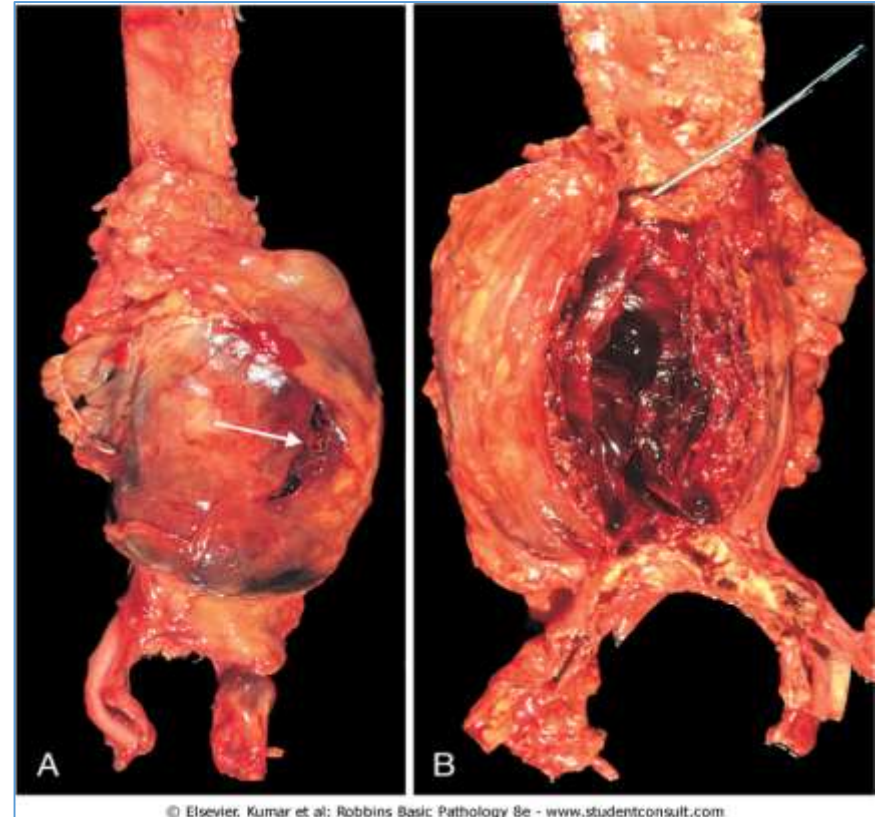
# Infarction

- lung (A), and spleen (B)
- What type of infarct do you see in
- A? **red**
- B? **white**



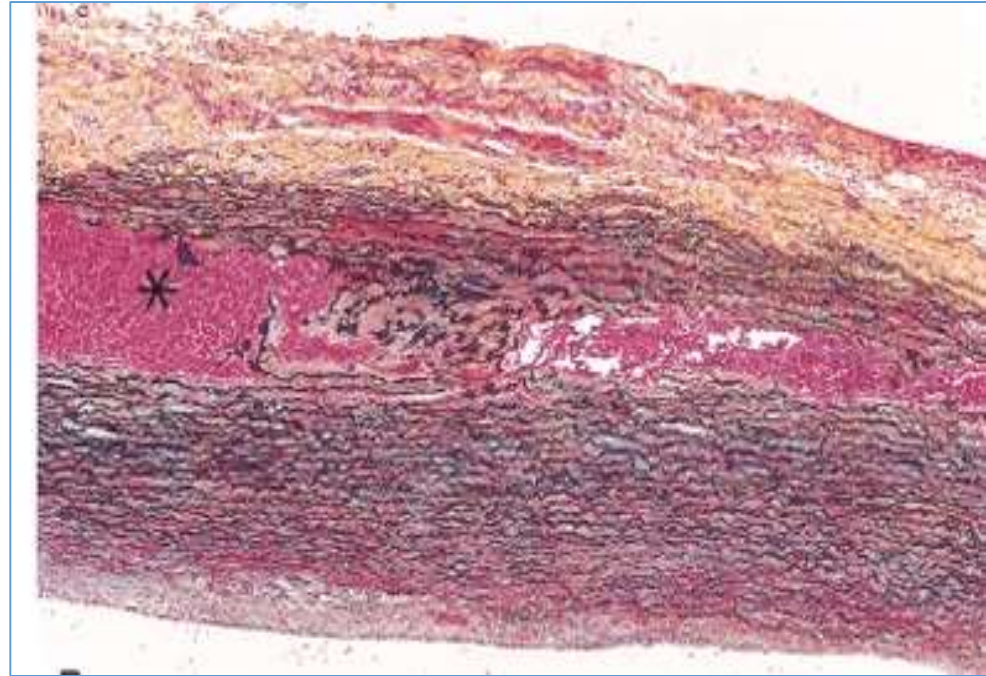
# Aortic aneurysm

- What part of aorta is involved ?  
**abdominal**
- Name complications that you recognize in :
- Picture A, white arrow? **rupture**
- picture B? **thrombosis**



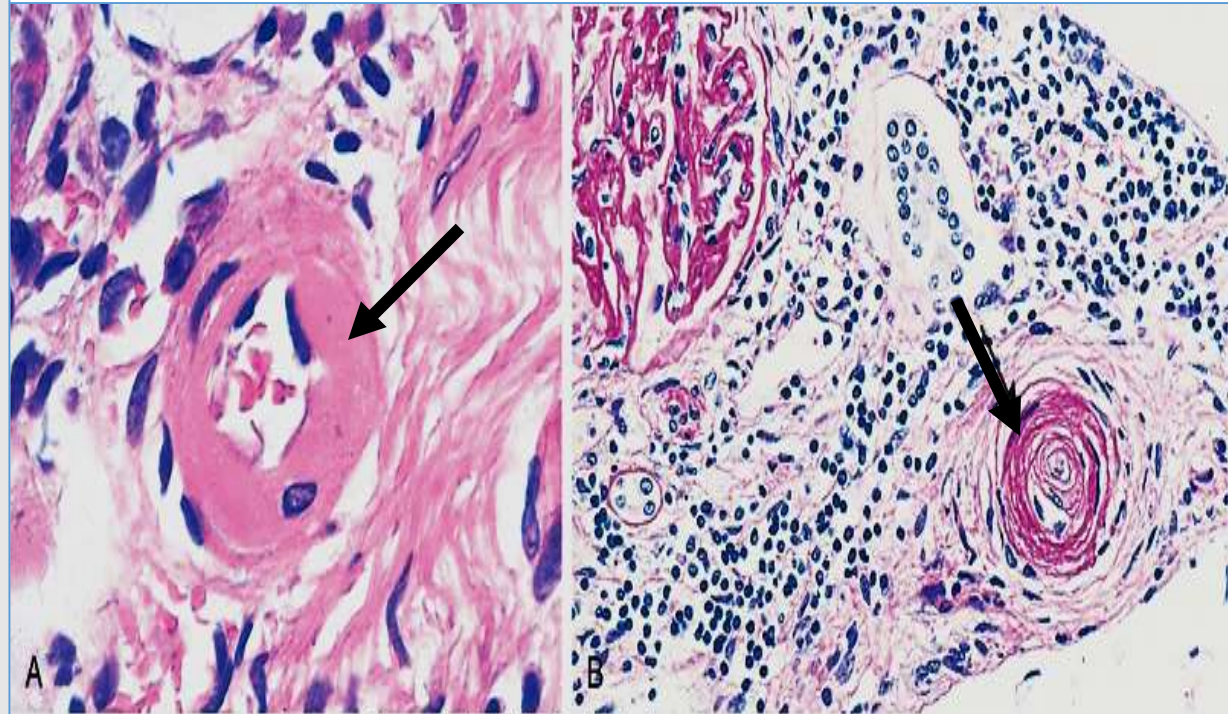
# Aortic dissection

- A microscopic section from the aorta:
- The special histochemical stain in this microscopic section of aorta shows elastic fibers in black color.
- What is the most likely diagnosis?  
**Aortic dissection**
- What does the star represents?  
**Blood collecting within the media**
- Name a major precipitating factor ?  
**hypertension**



## Arteriolosclerosis: types

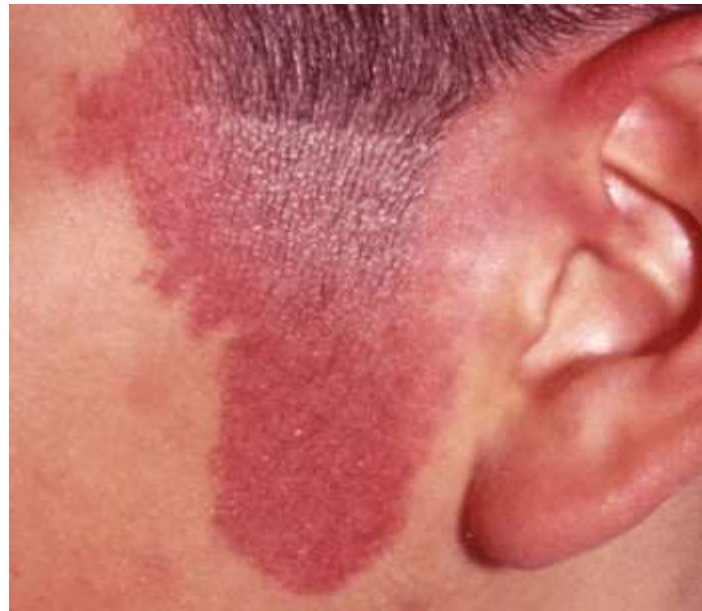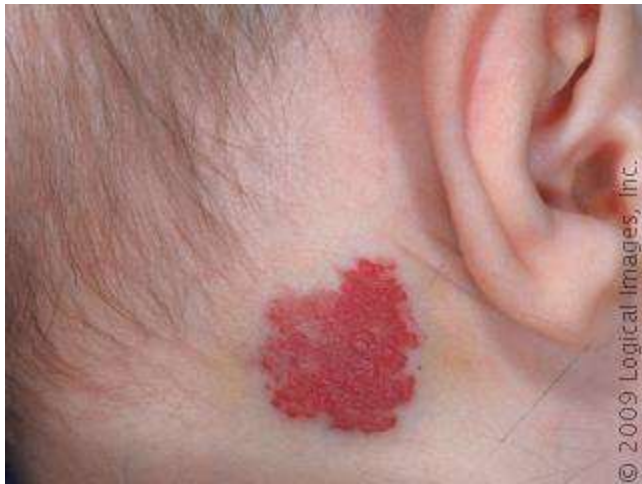- arrow in A? **hyaline arteriolosclerosis**
- causes? **HTN, DM, Aging**
  
- arrow in B?  
**(onion skin)**  
**Hyperplastic arteriolosclerosis**
- causes? **Malignant HTN**



Kumar et al: Robbins Basic Pathology, 9e.  
Copyright © 2013 by Saunders, an imprint of Elsevier Inc.



A lady is bringing her 1- year old baby girl to a paediatrics clinic. She is worried about a reddish lesion that is present posterior to the baby's ear. The mother describes the lesion as a blood colored plaque, present since birth, and its colour is fading as the baby grows up. What is the most likely diagnosis? **Strawberry hemangioma of newborn**



A 38 years old (HIV + ) man is going to a dermatologist complaining of multiple red-purple skin plaques and nodules on his feet; he said that the skin lesions increased in size and number and spread proximally overtime. Below are pictures of the lesions (A) and microscopic features (B). What is the most likely diagnosis?

**Kaposi sarcoma**

