




Prof. Mohammad Alsalem, PhD

The Nervous System



- A network of billions of nerve cells linked together in a highly organized fashion to form the rapid control center of the body.

Basic Functions of the Nervous System



1. Sensation

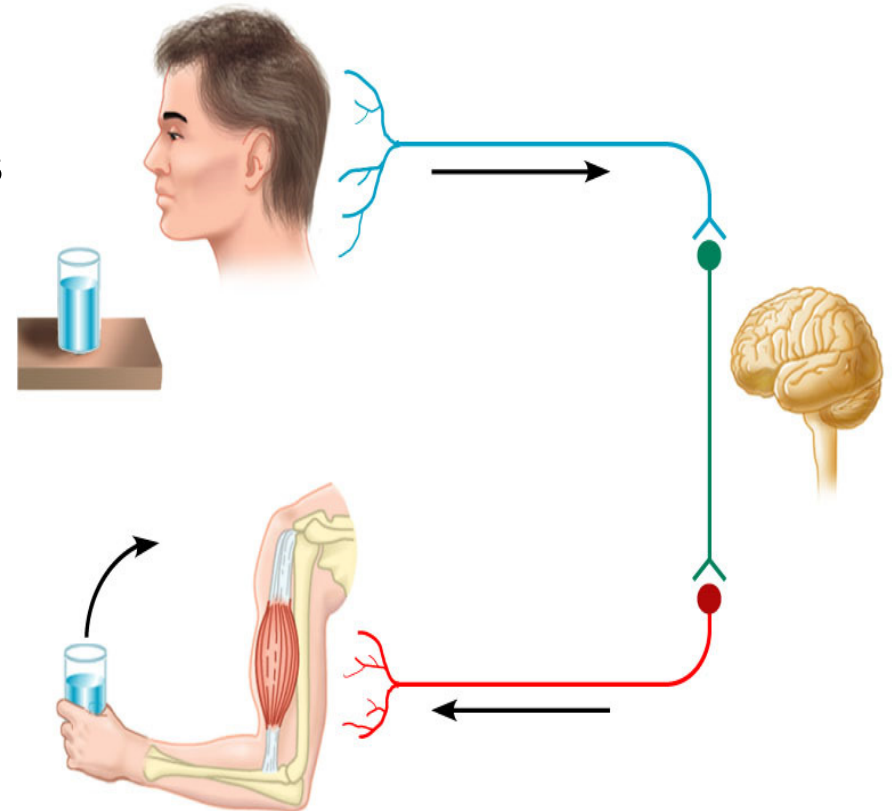
- Monitors changes/events occurring in and outside the body. Such changes are known as *stimuli* and the cells that monitor them are *receptors*.

2. Integration

- The parallel processing and interpretation of sensory information to determine the appropriate response


3. Reaction

- Motor output.
 - The activation of muscles or glands (typically via the release of neurotransmitters (NTs))

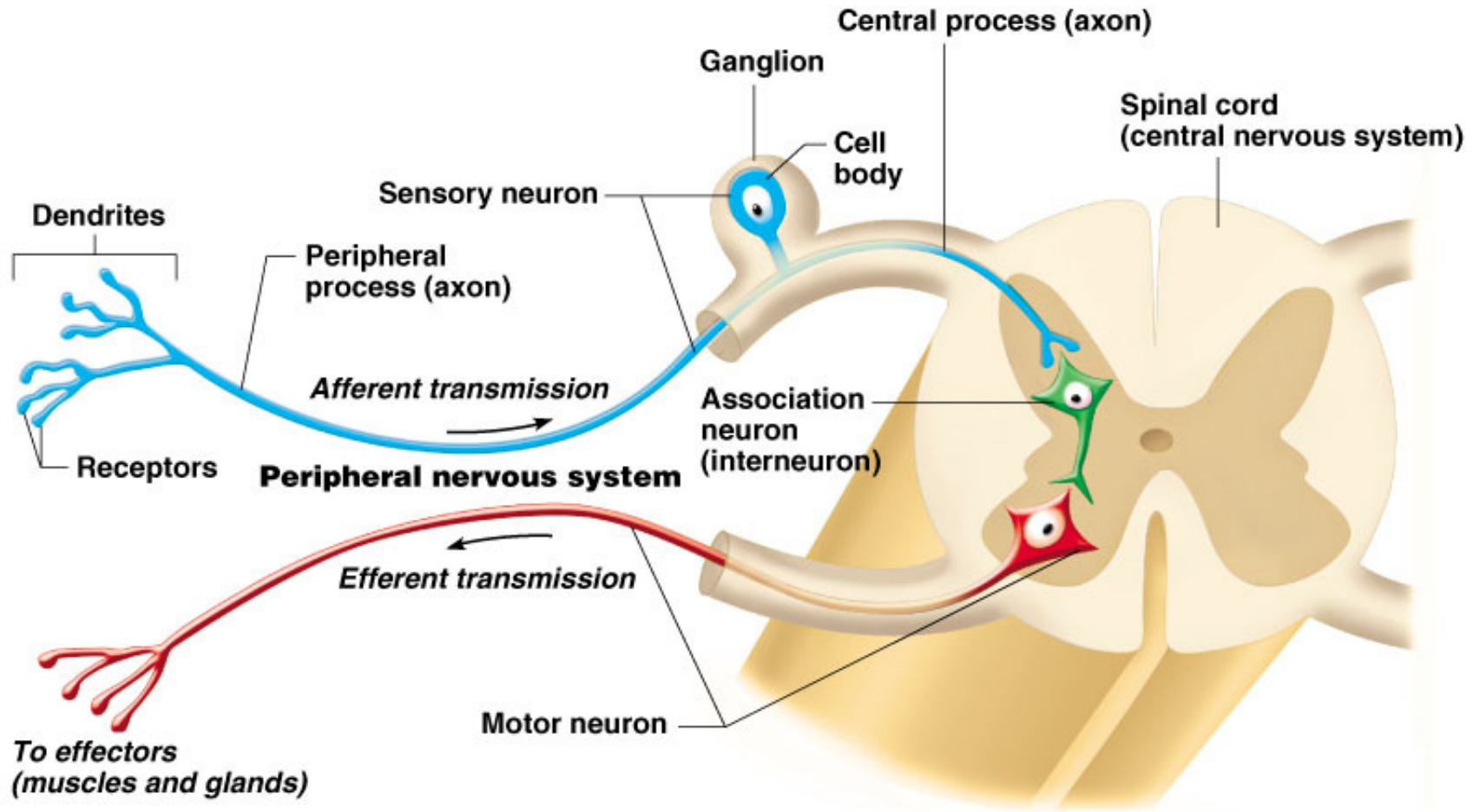


Nervous Tissue

- Highly cellular
- 2 cell types
 1. Neurons
 - Functional, signal conducting cells
 - Do not divide
 - Long lived
 - High metabolic activity
 - Electrically excitable
 2. Neuroglia
 - Support, nourish, and protect neurons
 - Divide
 - Smaller cells but they greatly outnumber neurons by about 5 to 50
 - 6 types of supporting cells: (4 are found in the CNS, and 2 are found in the PNS.



Functional Classification of Neurons



- **White matter:** aggregations of myelinated and unmyelinated axons of many neurons
- **Gray matter:** contains neuronal cell bodies, dendrites, unmyelinated axons, axon terminals, and neuroglia

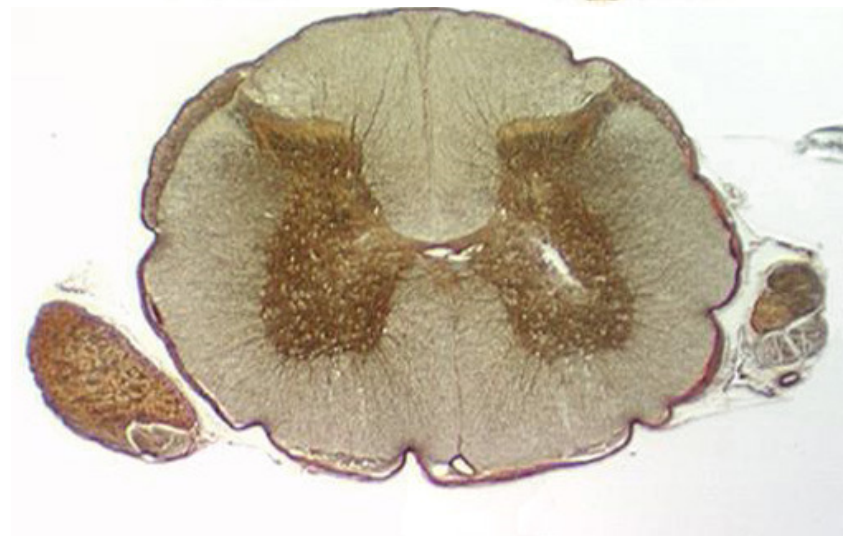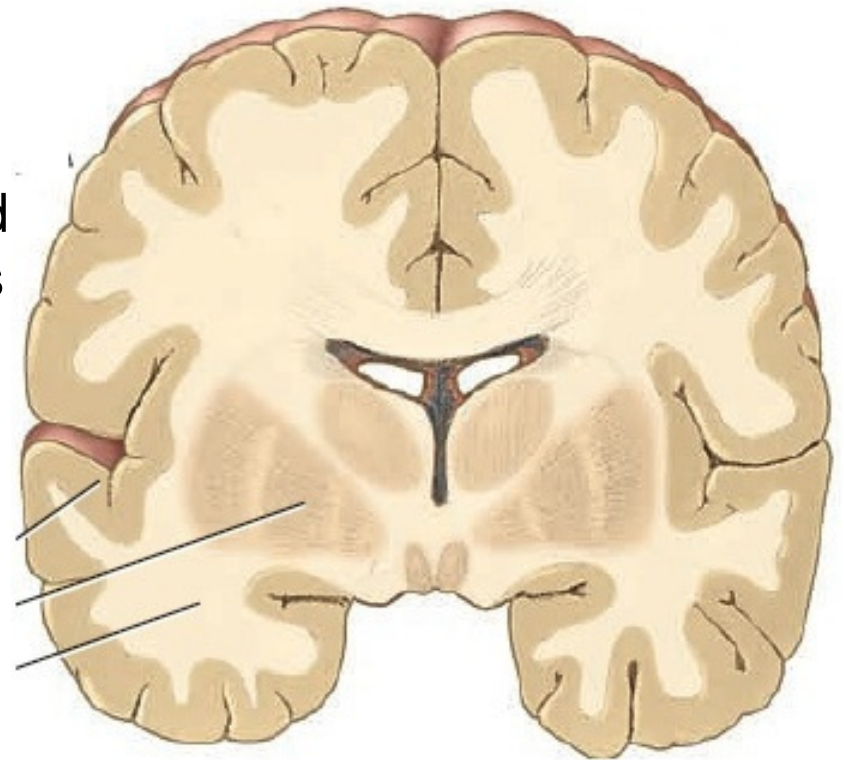
▪ **Nerves:** Bundles of processes in the PNS

▪ **Tracts:** Bundles of processes in the CNS (No Connective tissue)

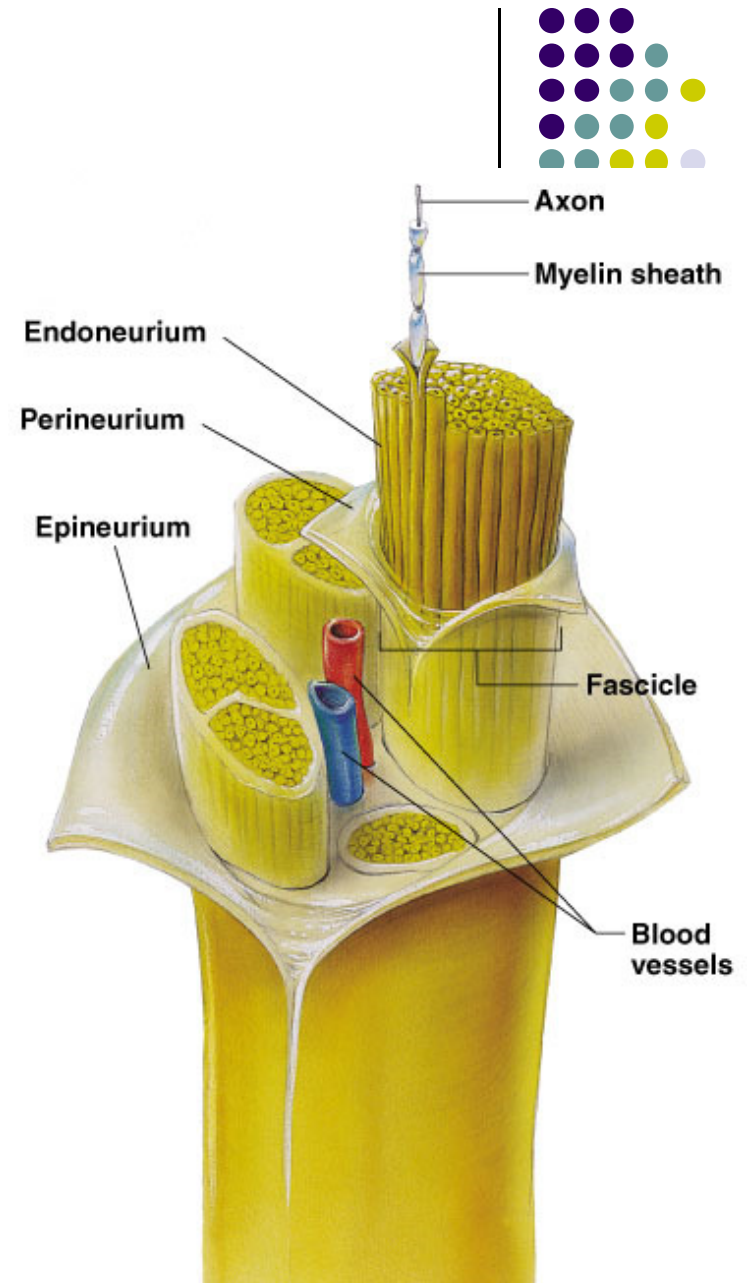
▪ **Ganglion:** cluster of nerve cell bodies in PNS

▪ **Nucleus:** cluster of nerve cell bodies in CNS (surrounded by white matter)

➤ If not surrounded (Cortex)

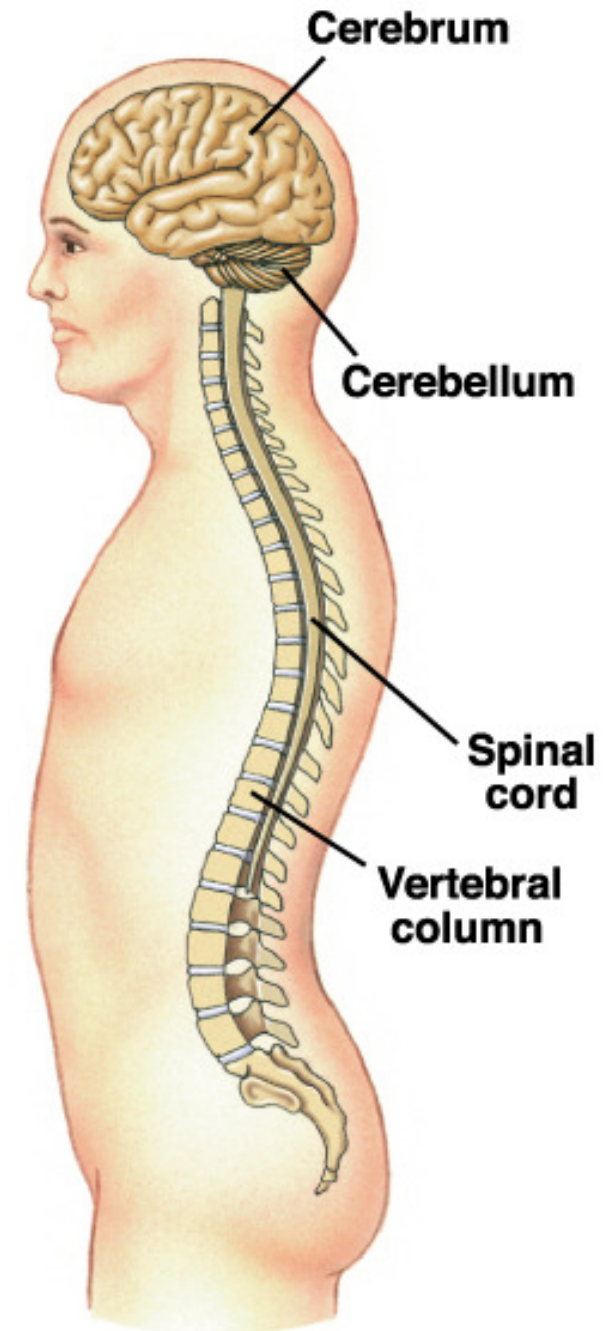


- A bundle of processes in the PNS is a **nerve**.
- Within a nerve, each axon is surrounded by an **endoneurium**
- Groups of fibers are bound together into bundles (fascicles) by a **perineurium**
- All the fascicles of a nerve are enclosed by a **epineurium**



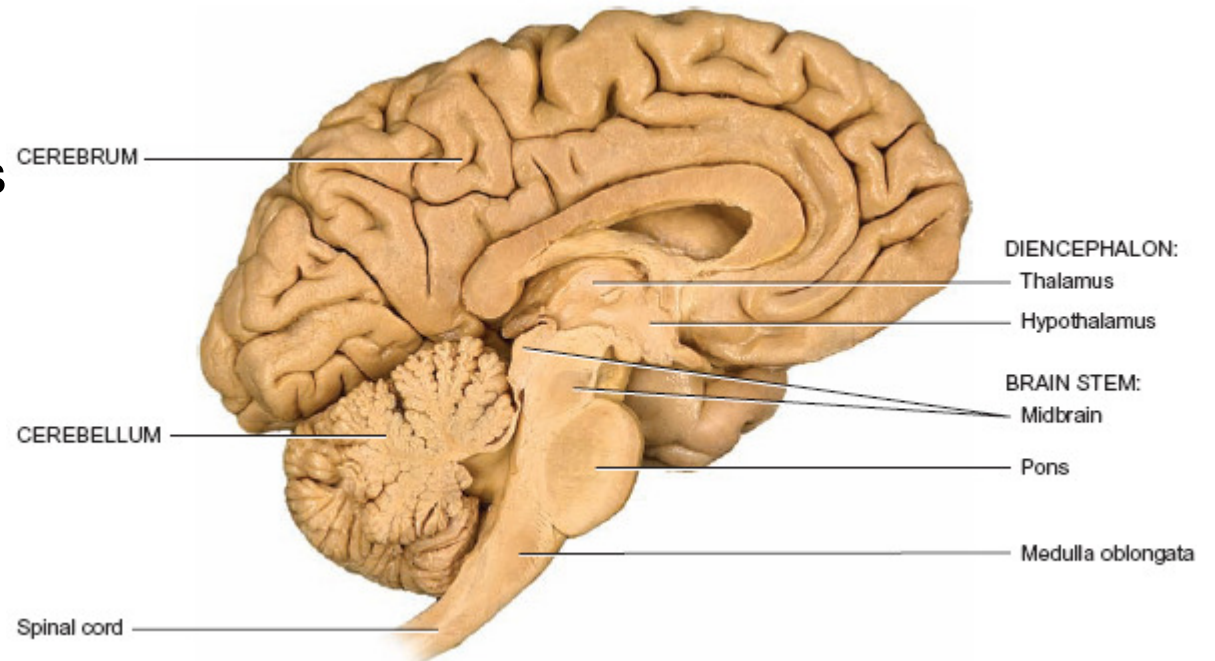
Organization of the Nervous System

- Anatomical divisions:
 1. Central Nervous System →
 - The brain + the spinal cord
 - The center of integration and control
 2. Peripheral Nervous System
 - The nervous system outside of the brain and spinal cord
 - Consists of:
 - 31 Spinal nerves
 - Carry info to and from the spinal cord
 - 12 Cranial nerves
 - Carry info to and from the brain



Brain

- **Forebrain:**
(Prosencephalon)
 - Cerebrum:
(Telencephalon)
 - Diencephalon
 - Thalamus
 - Hypothalamus
 - Epithalamus
 - Subthalamus
- **Midbrain:**
(Mesencephalon)
- **Hindbrain:**
(Rhombencephalon)
 - Pons
 - Medulla oblongata
 - Cerebellum



Peripheral Nervous System



- Responsible for communication between the CNS and the rest of the body.
- Can be divided into:
 - Sensory Division
 - Afferent division
 - Conducts impulses from receptors to the CNS
 - Informs the CNS of the state of the body interior and exterior
 - Sensory nerve fibers can be **somatic** (from skin, skeletal muscles or joints) or **visceral** (from organs within the body cavity)
 - Motor Division
 - Efferent division
 - Conducts impulses from CNS to effectors (muscles/glands)
 - Motor nerve fibers

Peripheral Nervous System



- Somatic nervous system


- 1) Sensory neurons: (*somatic sensory neurons*)

- convey information to the CNS from sensory receptors in the skin, skeletal muscles, and joints, and from the receptors for the special senses.

- 2) Motor neurons: (*somatic motor neurons*)

- VOLUNTARY
- conduct impulses from the CNS to skeletal muscles

Peripheral Nervous System


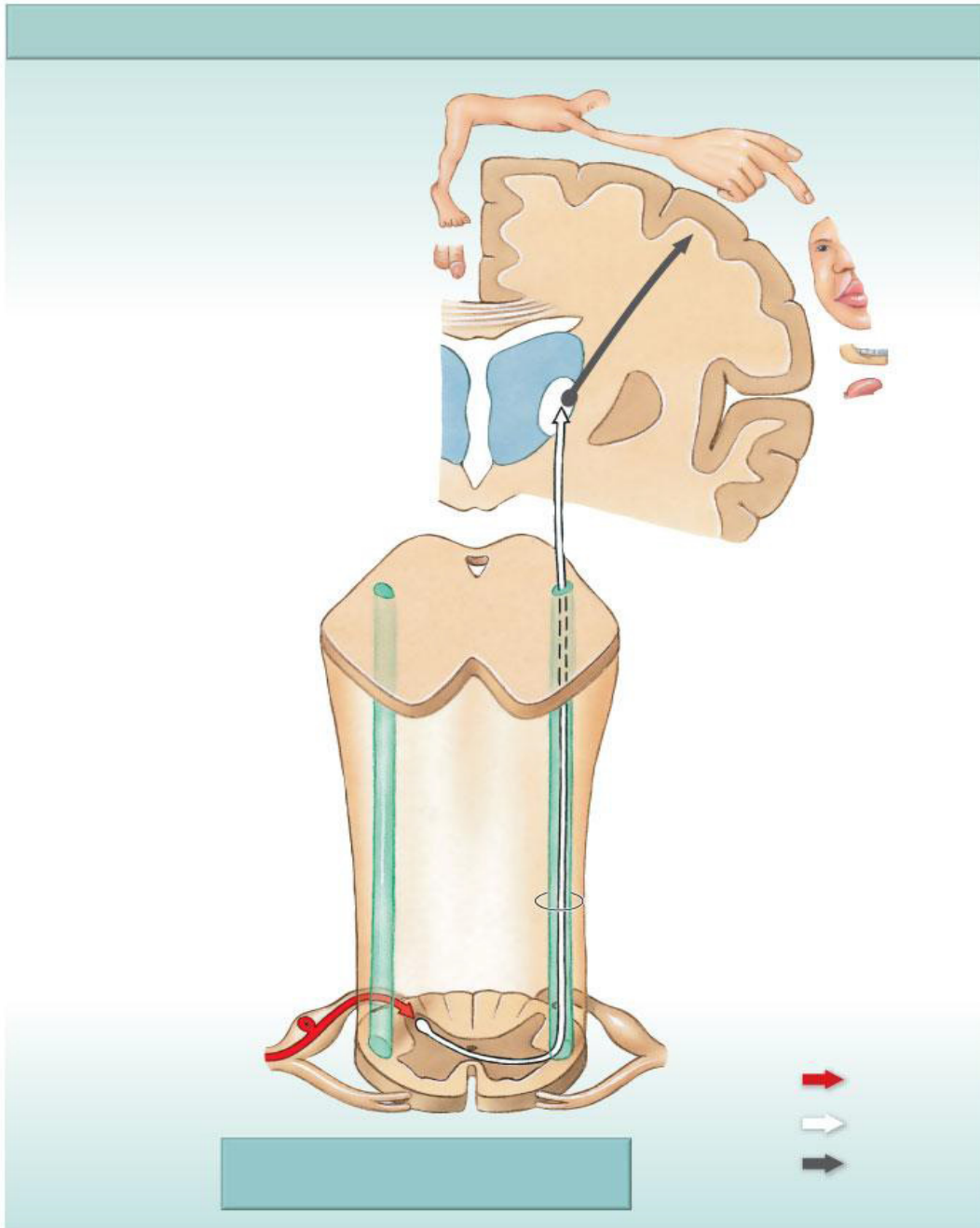


- Autonomic nervous system

1) Sensory neurons: Autonomic (visceral) sensory neurons convey information to the CNS from autonomic sensory receptors, located primarily in the visceral organs (smooth muscle organs in the thorax, abdomen, and pelvis)

2) Motor neurons: Autonomic motor neurons

- INVOLUNTARY (generally)
- Conducts impulses from the CNS to smooth muscle, cardiac muscle, and glands.



c

Upper motor neurons in primary motor cortex

Somatic motor nuclei of brain stem


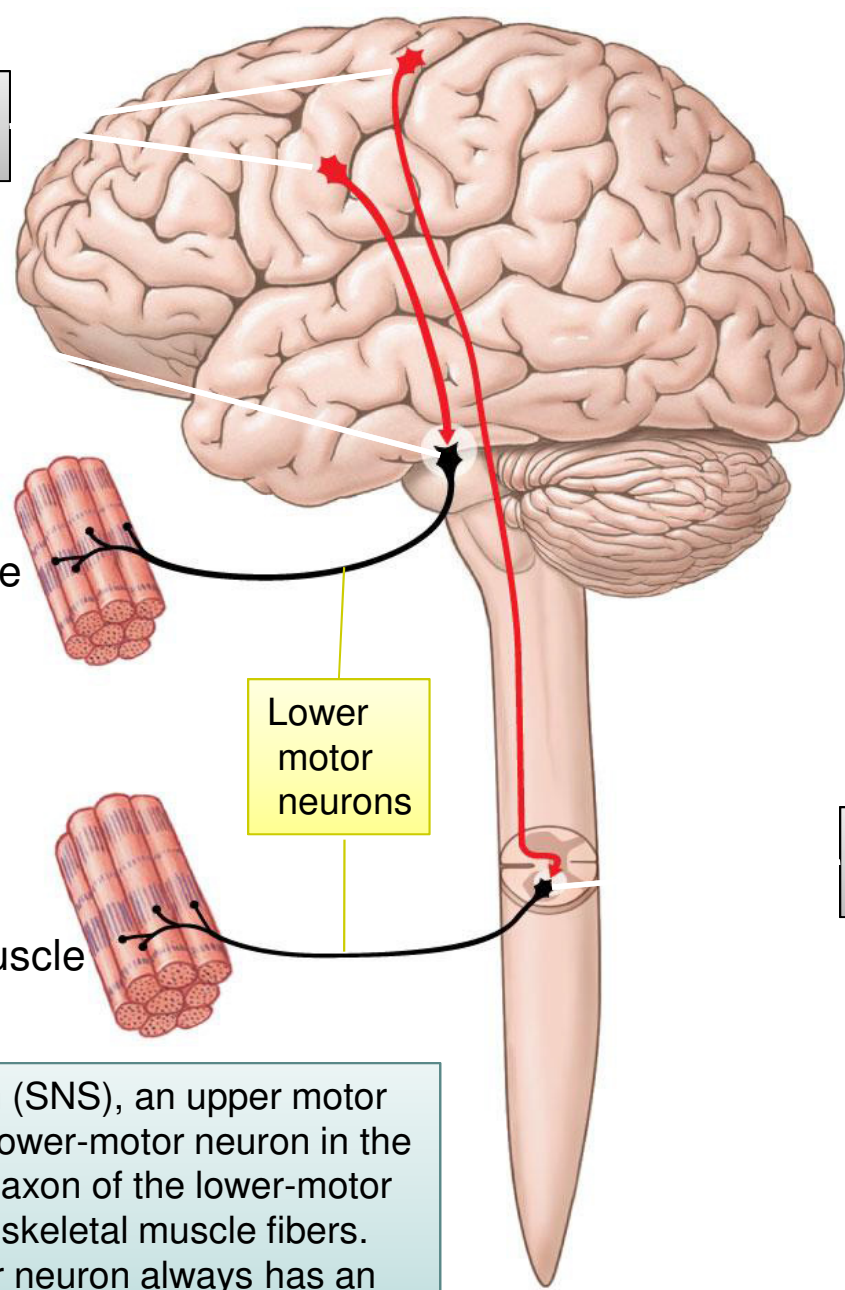
Skeletal muscle

Lower motor neurons

Skeletal muscle

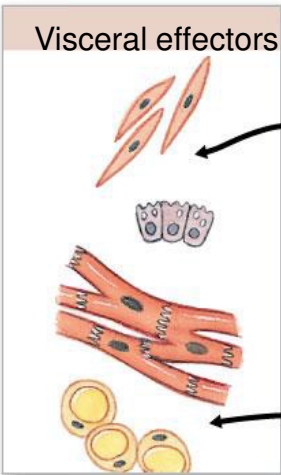
Somatic motor nuclei of spinal cord

In the somatic nervous system (SNS), an upper motor neuron in the CNS controls a lower-motor neuron in the brain stem or spinal cord. The axon of the lower-motor neuron has direct control over skeletal muscle fibers. Stimulation of the lower- motor neuron always has an excitatory effect on the skeletal muscle fibers.



Visceral motor nuclei in hypothalamus

Preganglionic neuron



Autonomic nuclei in brain stem

Autonomic nuclei in spinal cord

Preganglionic neuron

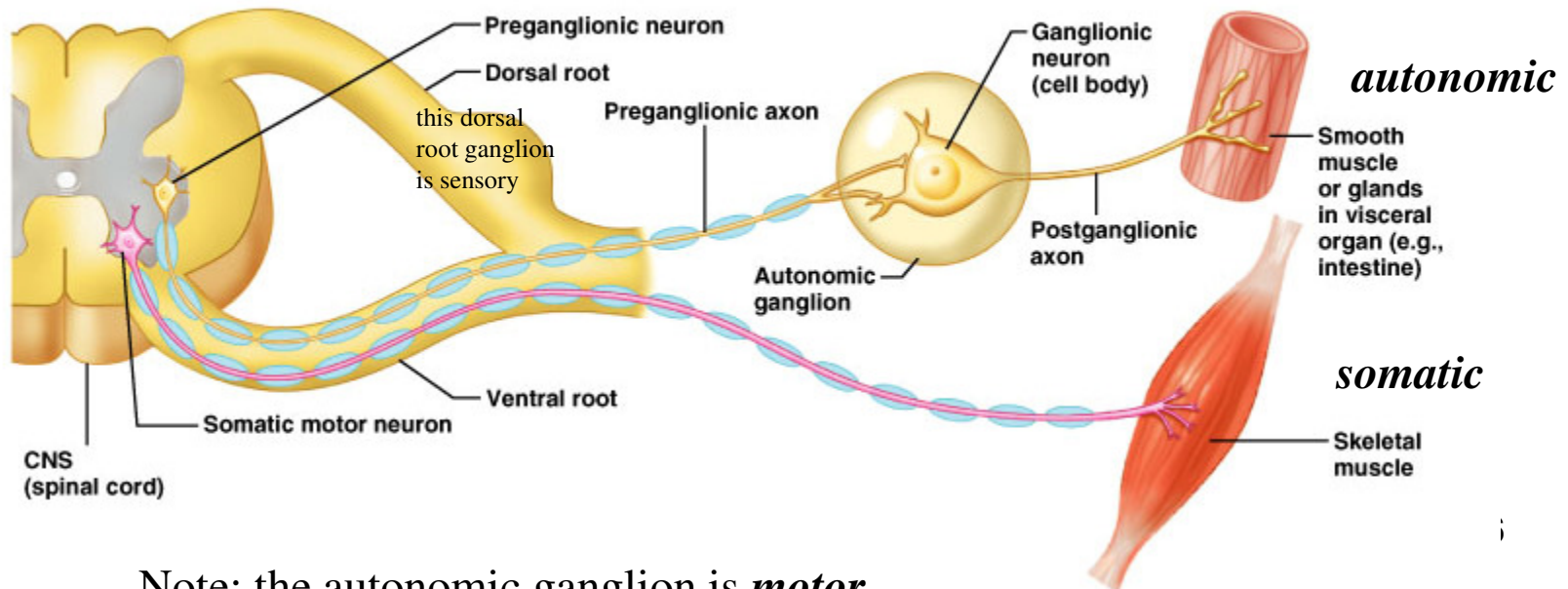
In the autonomic nervous system (ANS), the axon of a preganglionic neuron in the CNS controls ganglionic neurons in the periphery. Stimulation of the ganglionic neurons may lead to excitation or inhibition of the visceral effector innervated





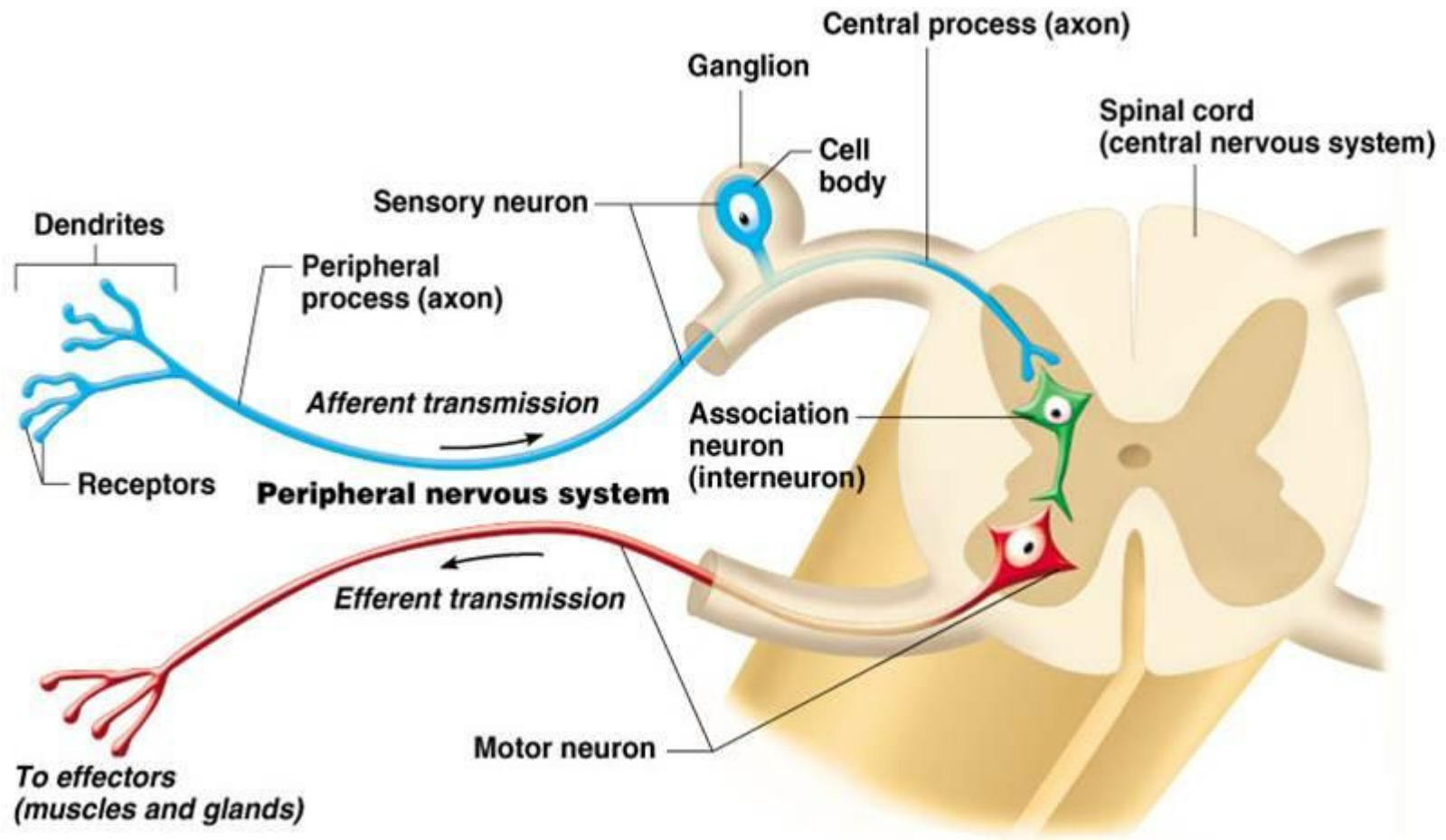
- Axon of 1st (*preganglionic*) neuron leaves CNS to synapse with the 2nd (*ganglionic*) neuron
- Axon of 2nd (*postganglionic*) neuron extends to the organ it serves

Diagram contrasts somatic (lower) and autonomic:



Note: the autonomic ganglion is *motor*

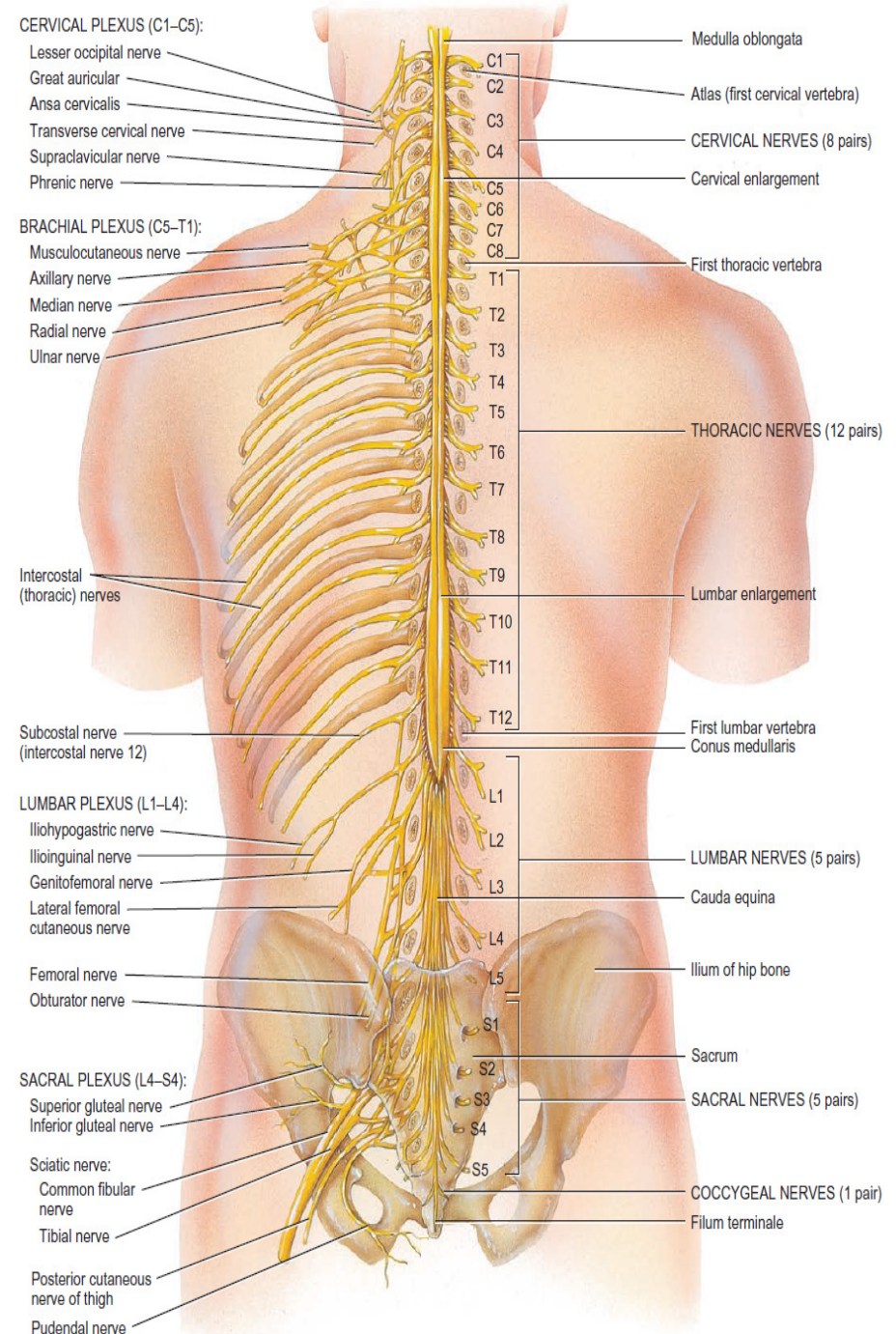
Sensory ganglion



Ganglion cells in dorsal root ganglia do not receive synapses

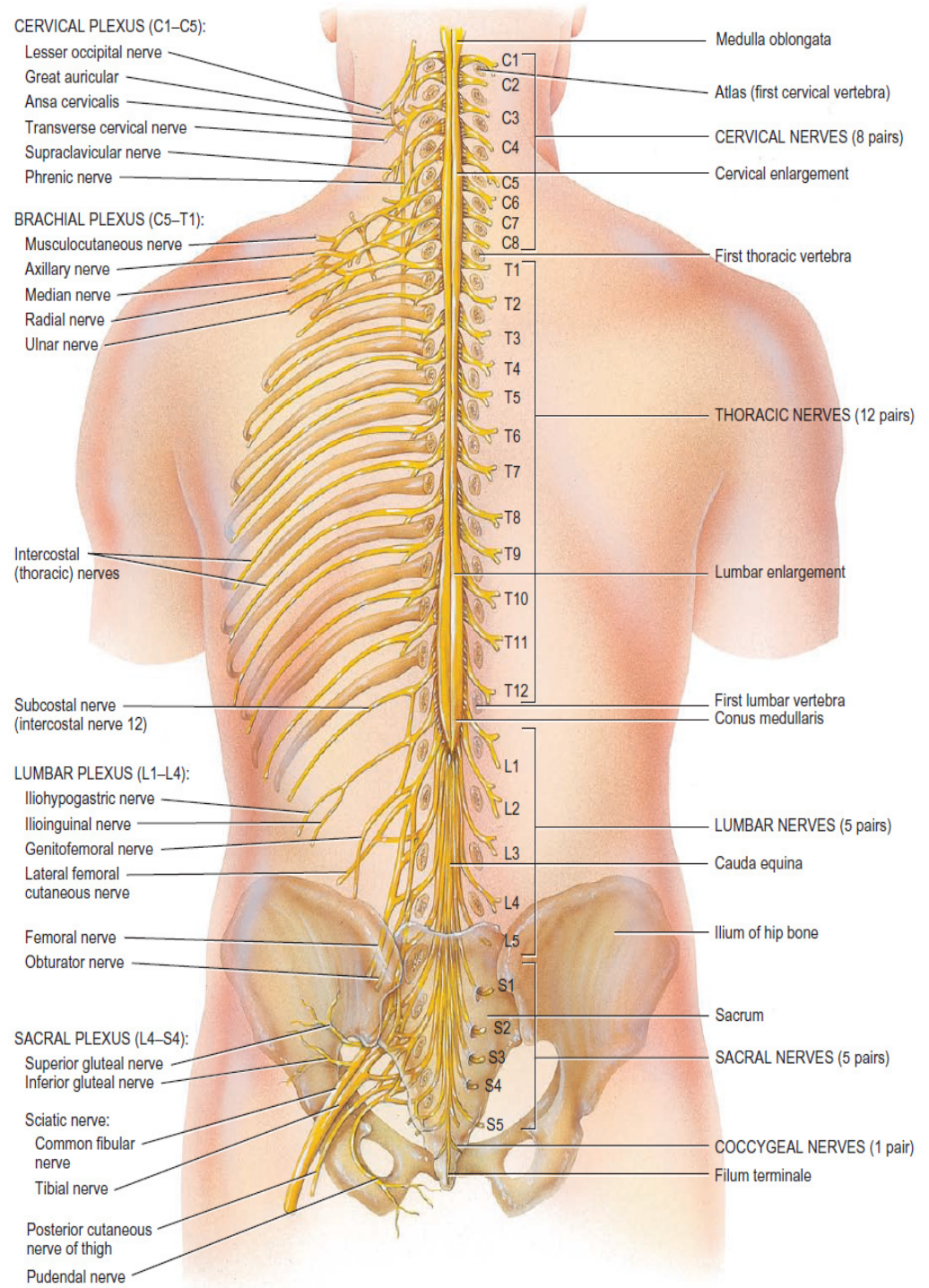
External anatomy of Spinal Cord

- Runs through the vertebral canal
- Extends from foramen magnum to second lumbar vertebra
- Regions
 - Cervical (8)
 - Thoracic (12)
 - Lumbar (5)
 - Sacral (5)
 - Coccygeal (1)
- Gives rise to (31) pairs of spinal nerves
 - All are *mixed* nerves
- Not uniform in diameter
 - Cervical enlargement: supplies upper limbs
 - Lumbar enlargement: supplies lower limbs



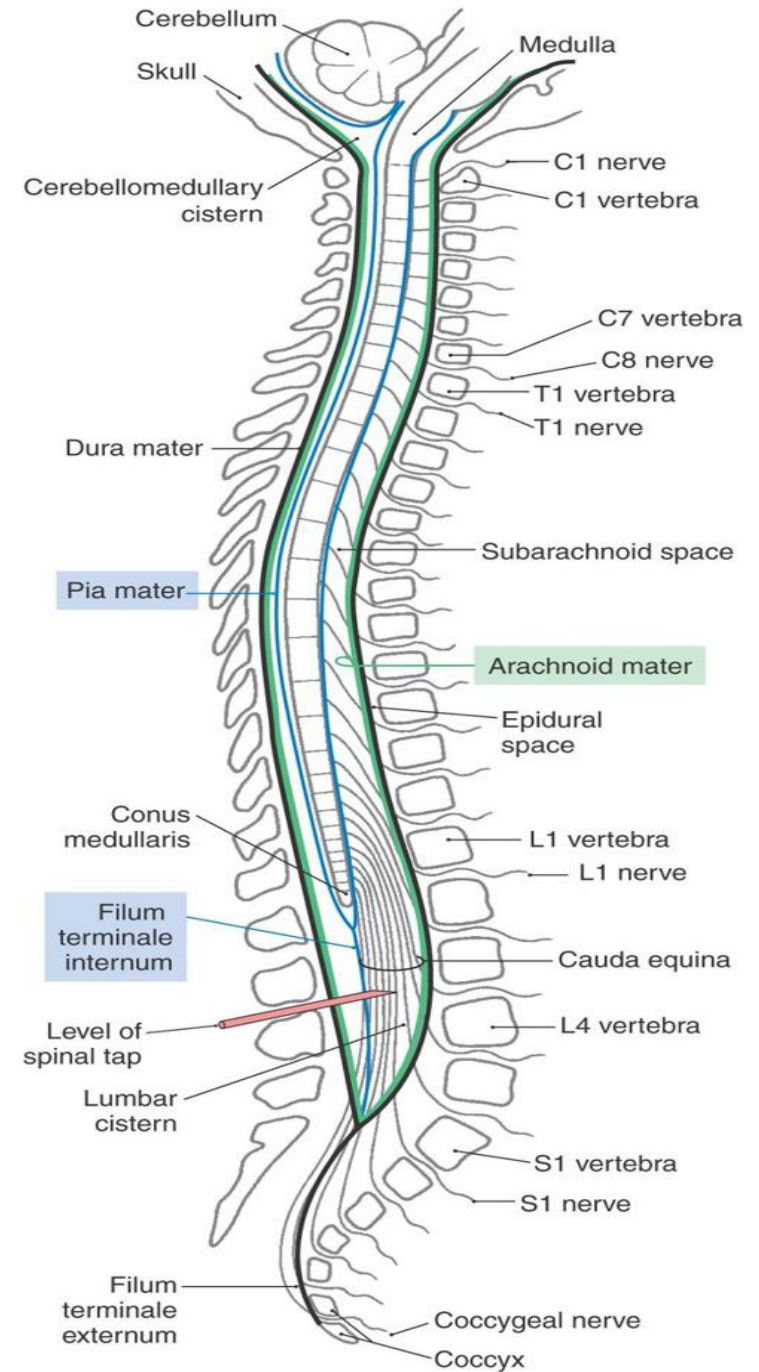
External anatomy of Spinal Cord

- Flattened slightly anteriorly and posteriorly
- length of the adult spinal cord ranges from 42 to 45 cm
- Conus medullaris- tapered inferior end (conical structure)
 - Ends between L1 and L2
- Cauda equina - origin of spinal nerves extending inferiorly from conus medullaris.



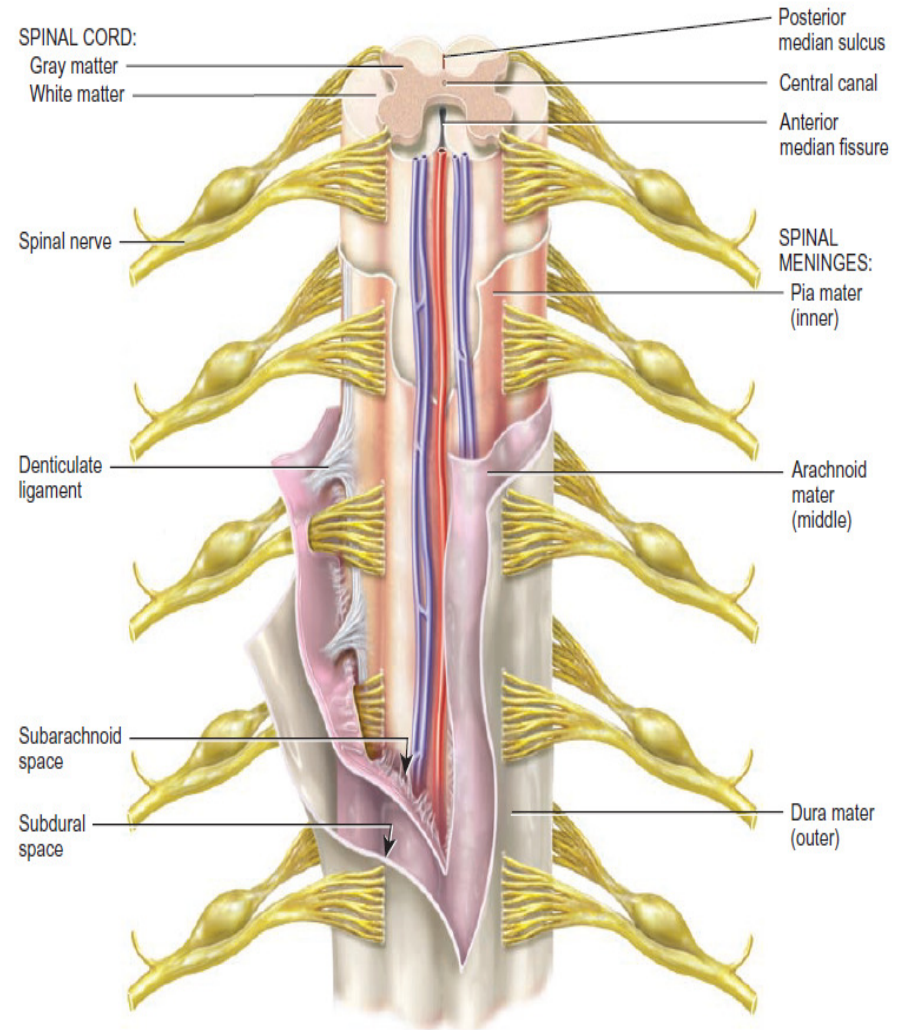
Meninges

- Connective tissue membranes
 - **Dura mater:**
 - ❑ Outermost layer; continuous with epineurium of the spinal nerves
 - ❑ Dense irregular connective tissue
 - ❑ from the level of the foramen magnum to S2
 - ❑ Closed caudal end is anchored to the coccyx by the **filum terminale externum**
 - **Arachnoid mater:**
 - ❑ Thin web arrangement of delicate collagen and some elastic fibers.
 - ❑ Adheres to the inner surface of the dura mater



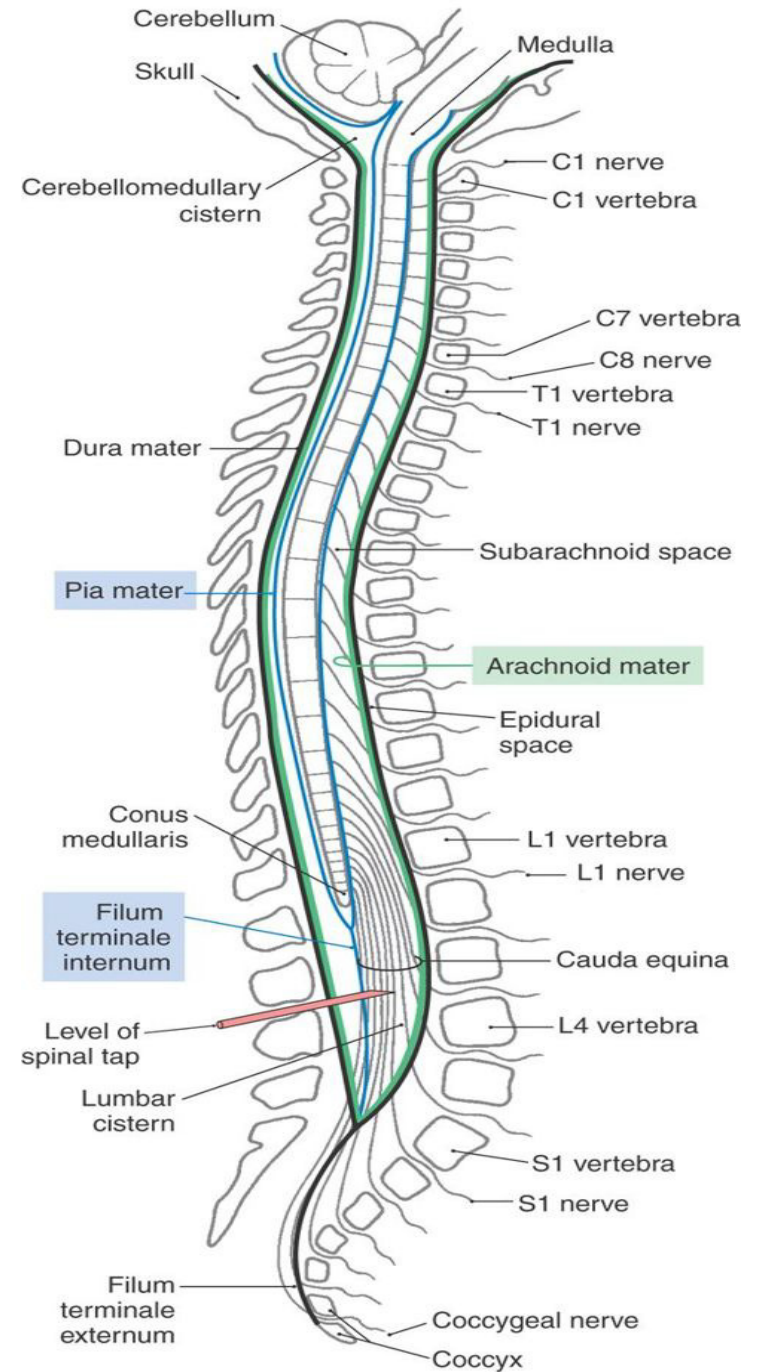
Meninges

- Connective tissue membranes
- Pia mater:
 - Bound tightly to surface
 - Thin transparent connective tissue layer that adheres to the surface of the spinal cord and brain
- Forms the filum terminale
 - anchors spinal cord to coccyx
- Forms the denticulate ligaments that attach the spinal cord to the arachnoid mater and inner surface of the dura mater



Spaces

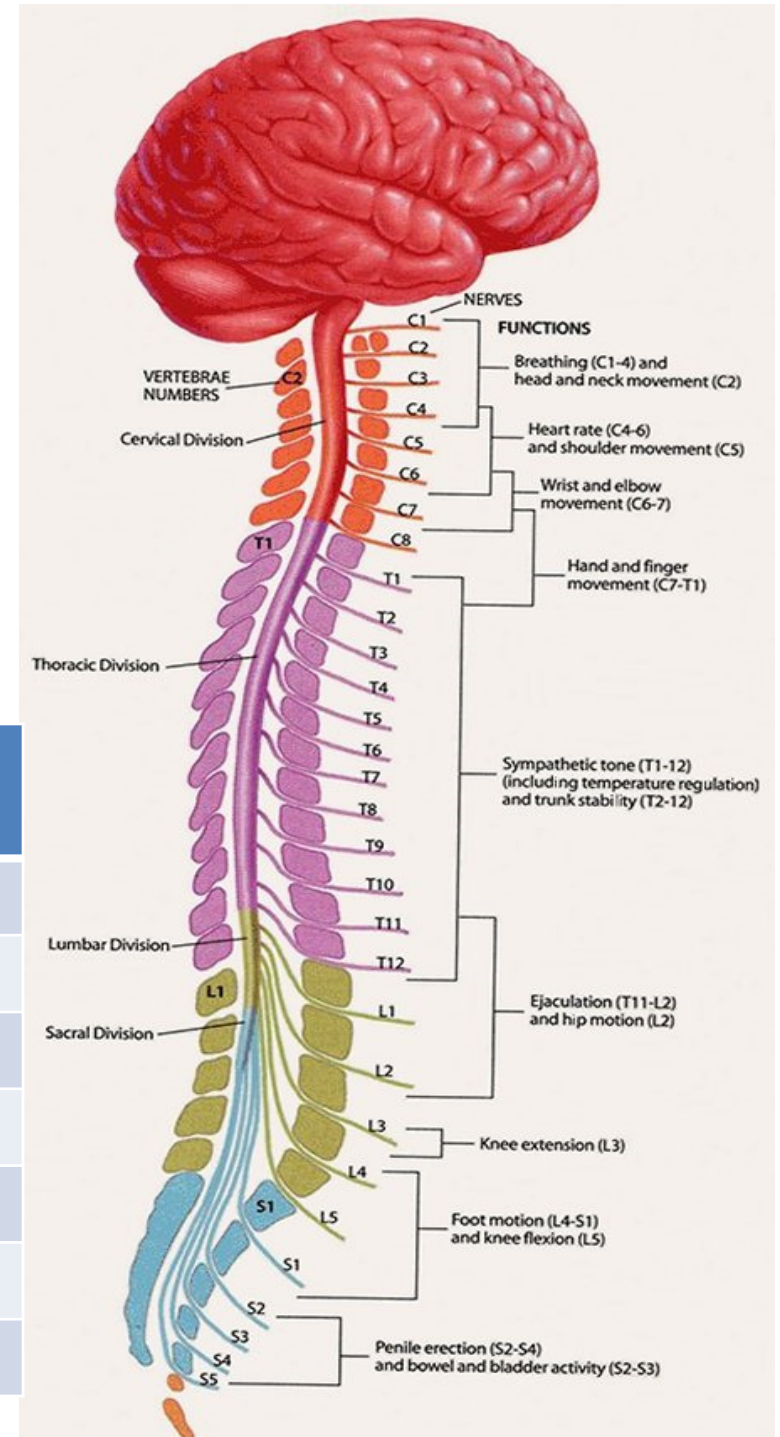
- **Epidural:** space between the dura mater and the wall of the vertebral canal.
 - Anesthetics injected here
 - Fat-fill
- **Subdural space:** serous fluid
- **Subarachnoid:** between pia and arachnoid
 - Filled with CSF
 - Lumbar puncture
 - supracristal line
 - L3-L4



Spinal cord segment

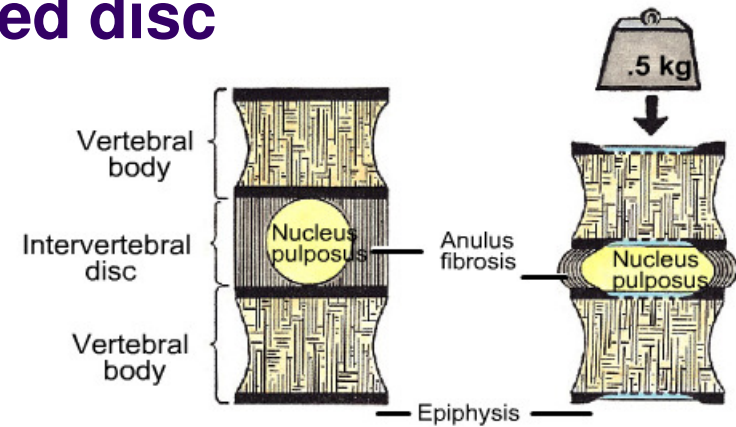
- The segments of the spinal cord are not in line with the corresponded vertebrae and the difference increases as we go downward.
- The roots increase in length as you go downward.
- Every spinal nerve emerges from the spinal column through the intervertebral foramen under its corresponding vertebra
- first 7 cervical nerves pass above their corresponding vertebrae

Spinous process	spinal cord segment
C7	C8
T3	T5
T9	T12
T10	L1-2
T11	L3-4
T12	L5
L1	S1-end



Herniated Disc/ ruptured disc/ slipped disc

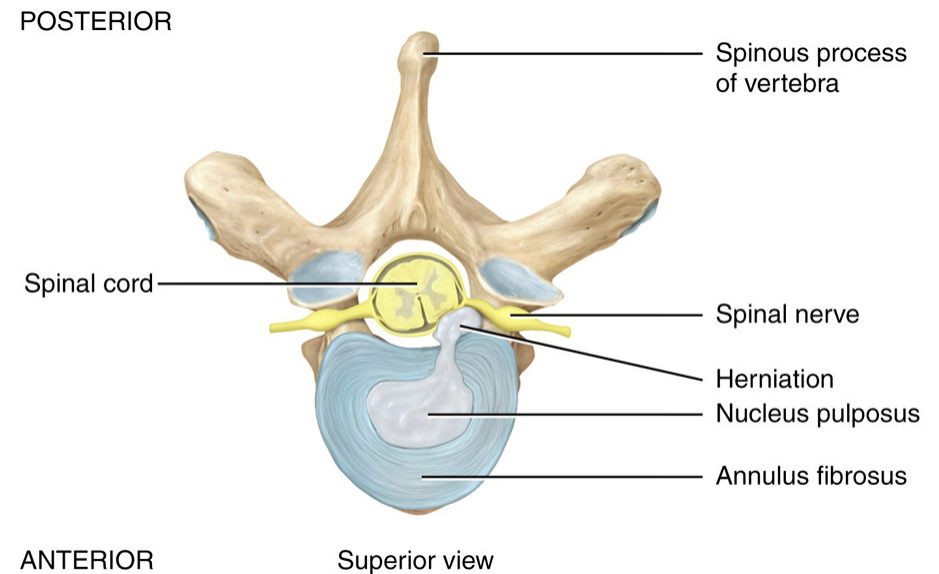
protrusion (leakage) of the gelatinous nucleus pulposus through the annulus fibrosus of IV disc



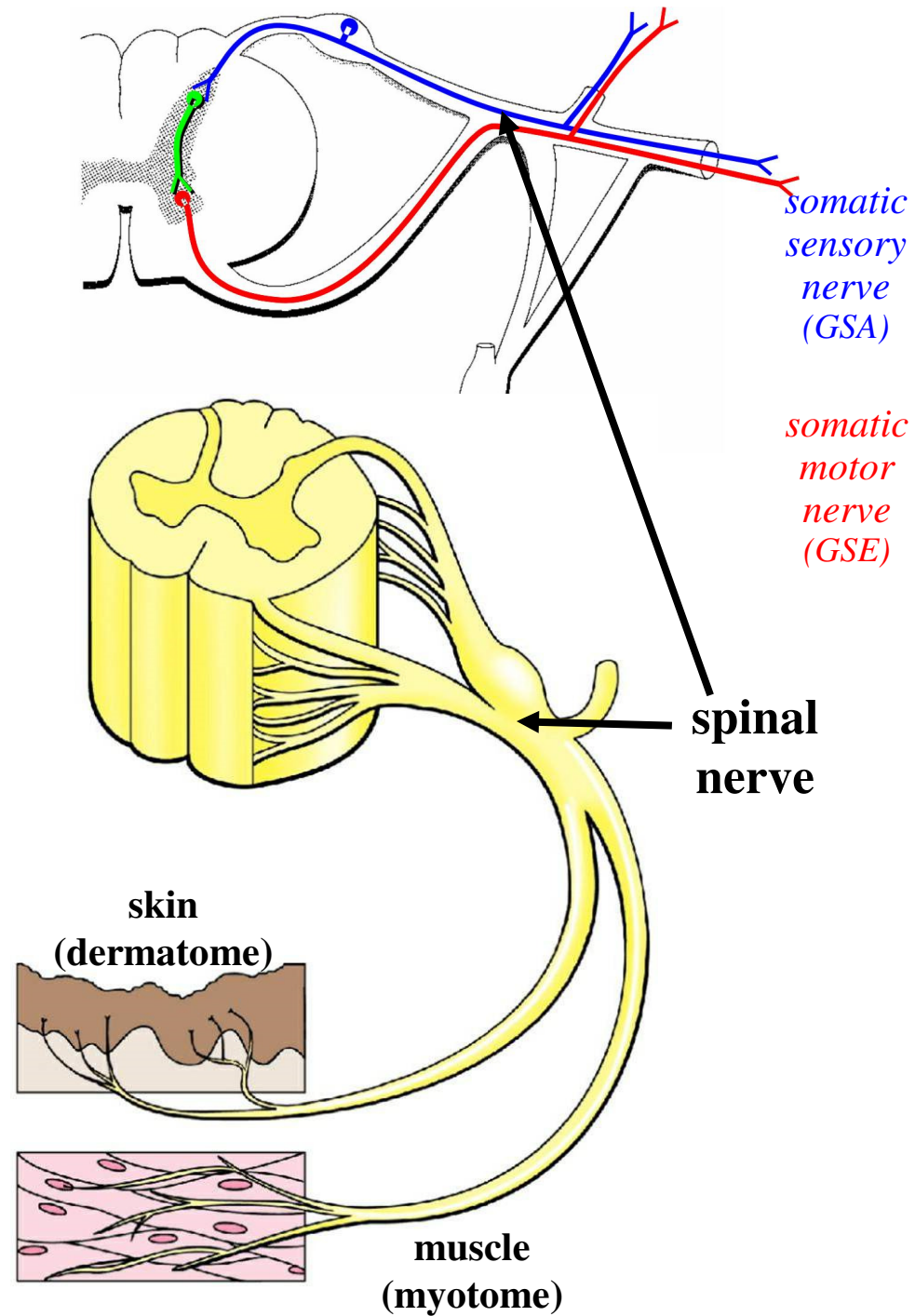
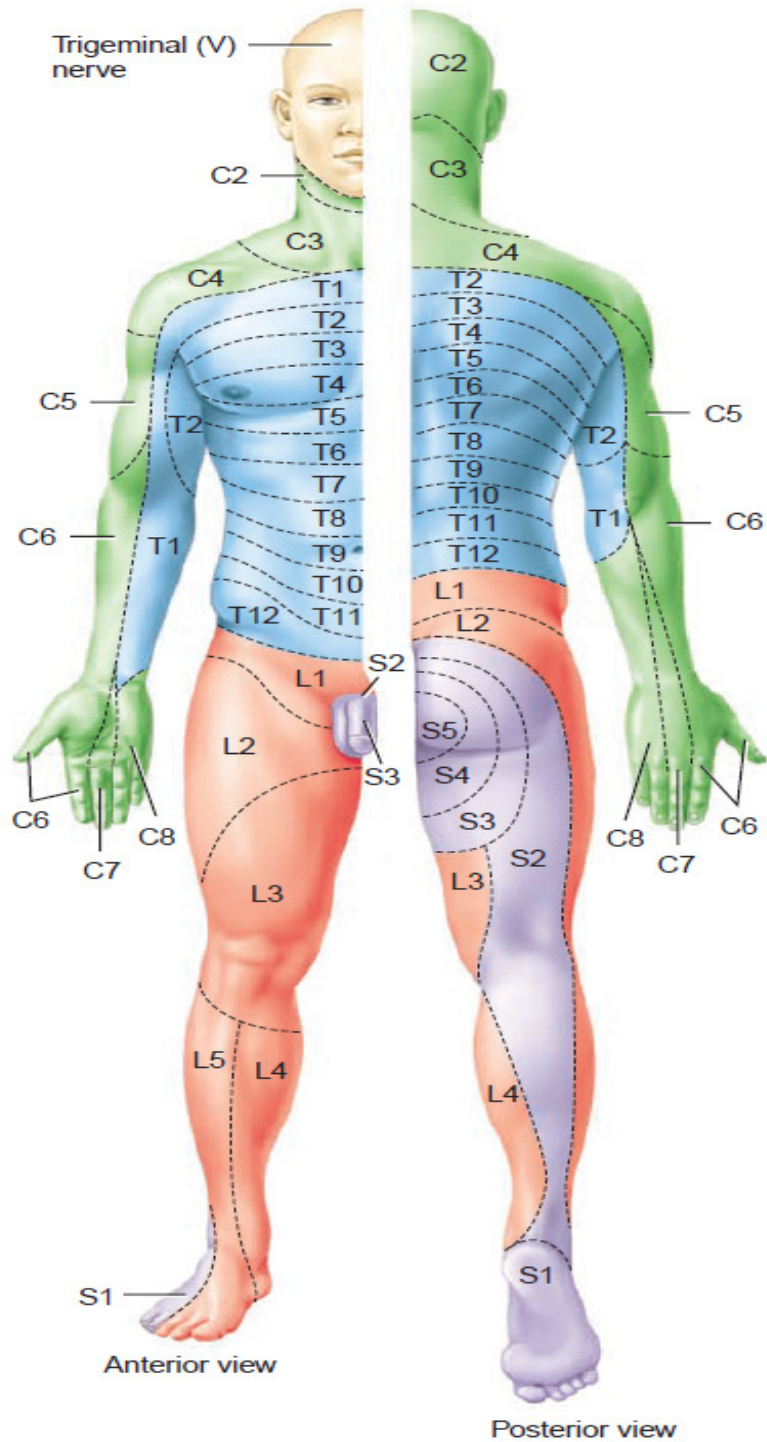
Posterolateral direction:

Thinner annulus fibrosus

95% in L4/L5 or L5/S1



Copyright © John Wiley & Sons, Inc. All rights reserved.



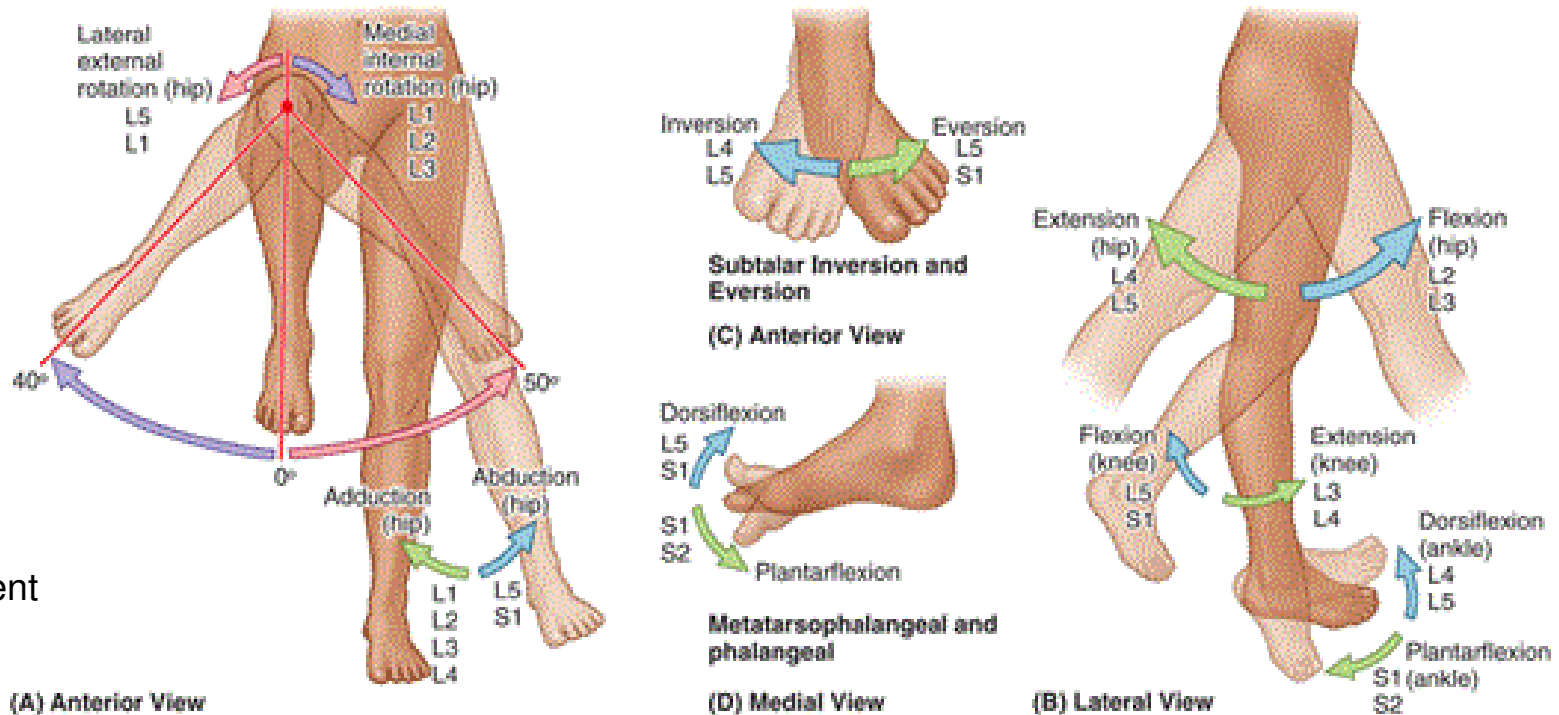
Common lumbar disc problems

Disc	Root	Percentage	Motor weakness	Sensory changes	Reflex affected
L3-L4	L4	3-10%	Knee extension (Quadriceps femoris)	Anteromedial leg (saphenous)	Knee jerk
L4-L5	L5	40-45%	Big toe dorsiflexion (EHL) and TA	Big toe , anteriolateral leg (Common P)	Hamstring jerk
L5-S1	S1	45-50%	Foot planter flexion (Gastrocnemius)	Lateral border of foot (sural)	Ankle jerk

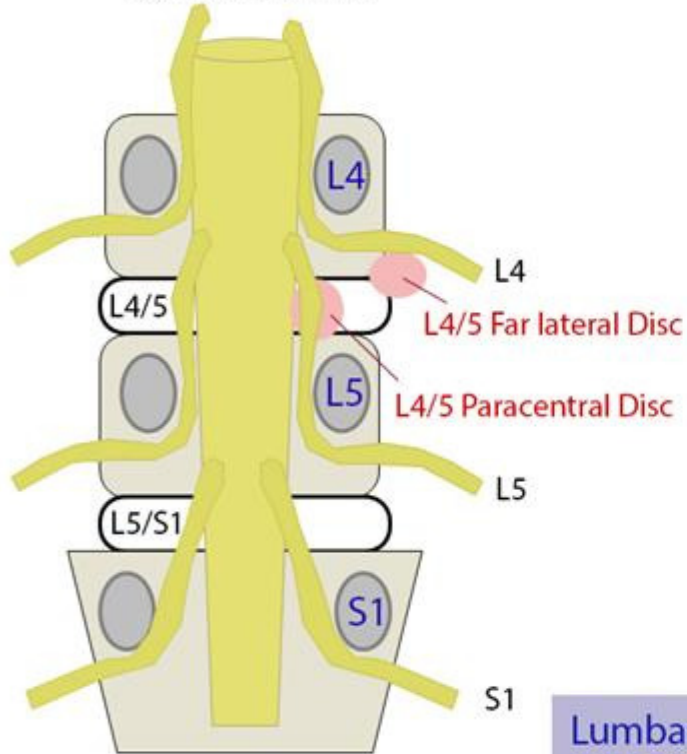
Important myotomes of lower limb

❑ **Test L5:** by asking the patient to stand on his heels

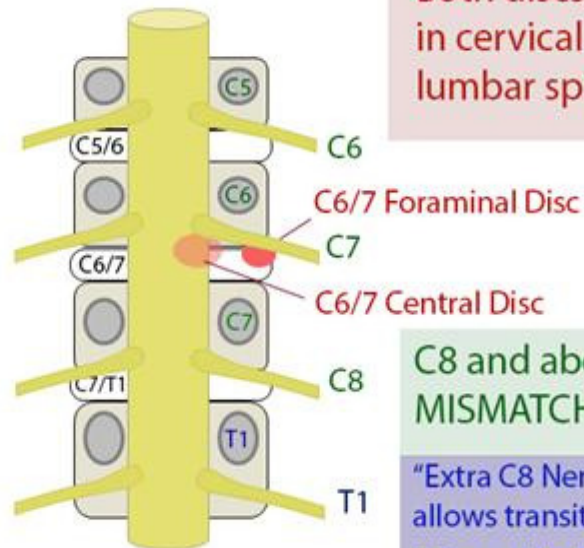
❑ **Test S1:** by asking the patient to stand on his tiptoes



LUMBAR SPINE



CERVICAL SPINE



Both discs affect same nerve root in cervical spine, different than lumbar spine

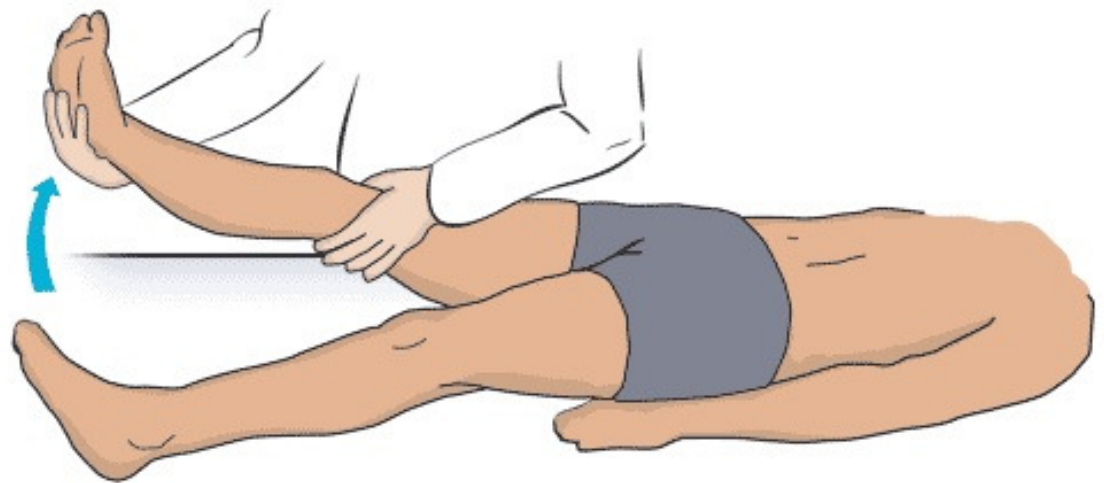
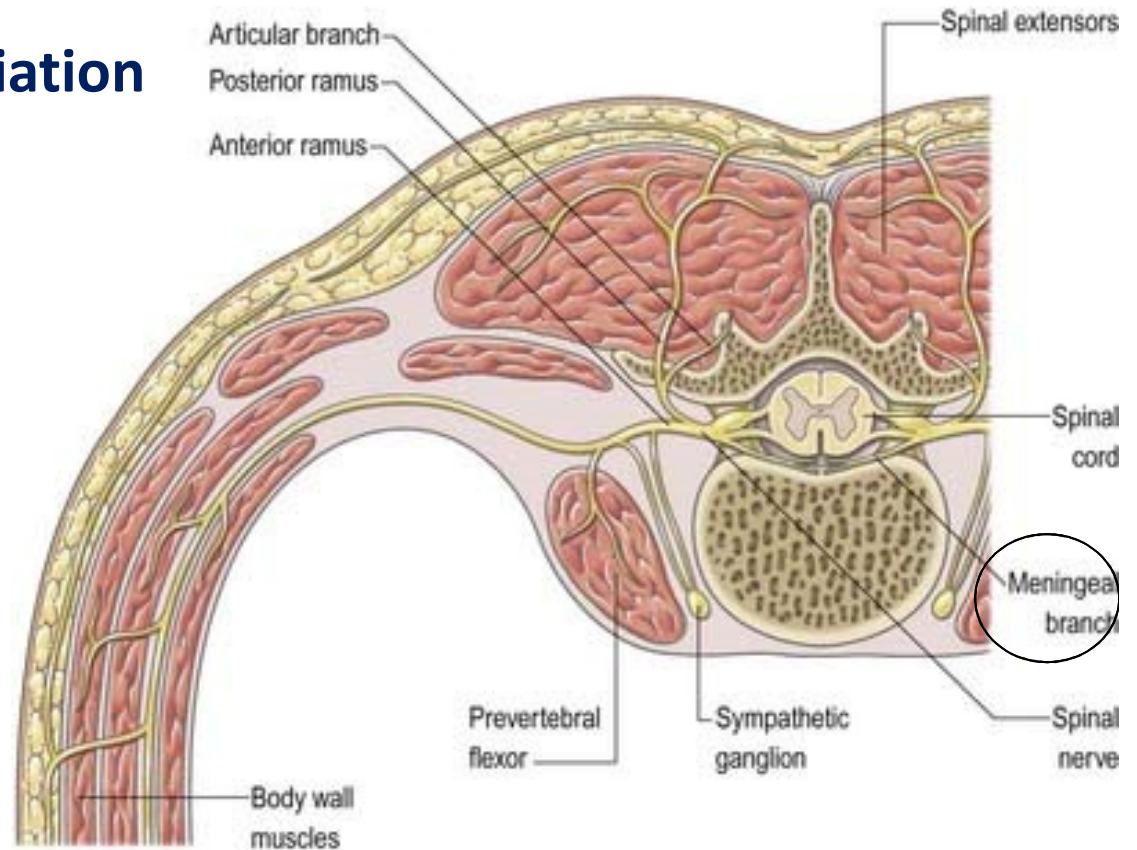
C8 and above Pedicle / Nerve Root MISMATCH

"Extra C8 Nerve Root (without C8 pedicle) allows transition from MISMATCH to MATCH
T1 and below Pedicle / Nerve Root MATCH

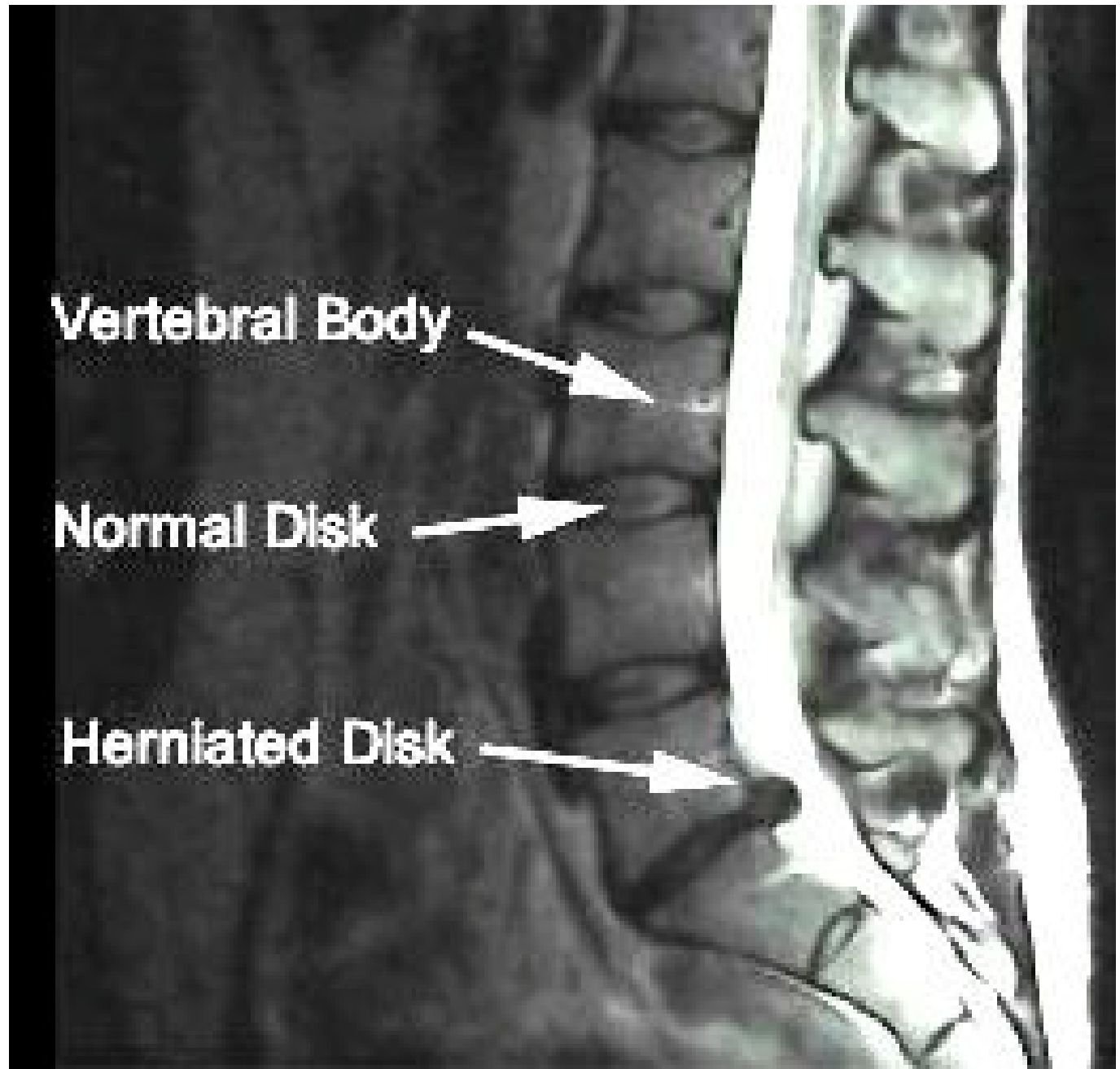
Lumbar Spine Pedicle/nerve Root MATCH

Major symptoms of disc herniation

- **Low back pain:** radiating to the gluteal region, the back of the thigh and back of the leg
- spinal nerve gives a meningeal branch bring sensation from the dura matter
- Dura matter is sensitive to stretch
- Pain is diffused due to overlapping dermatomes
- **Straight Leg Raise Test (SLR)**

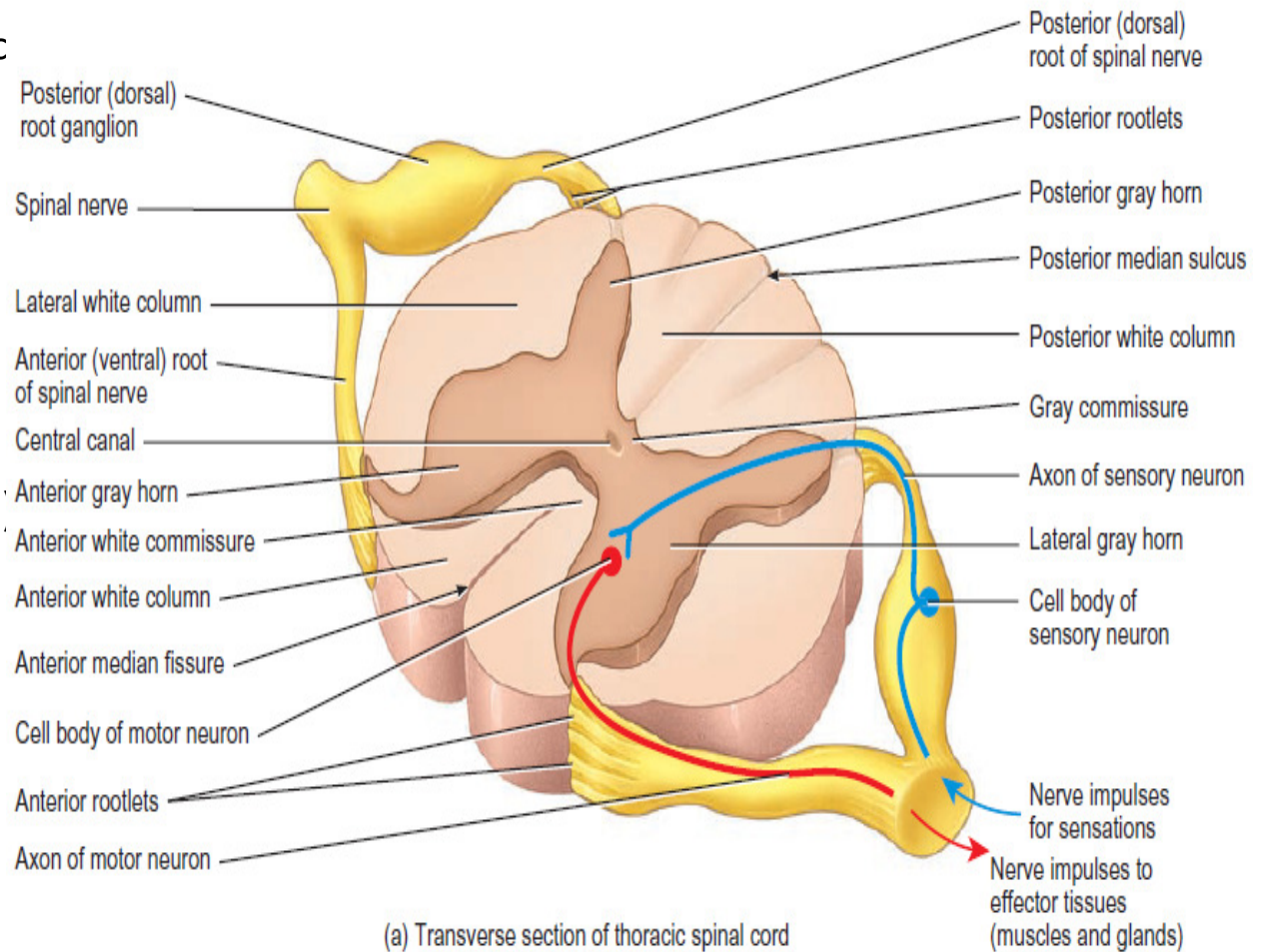


□ MRI is commonly used to aid in making the diagnosis of a herniated disc



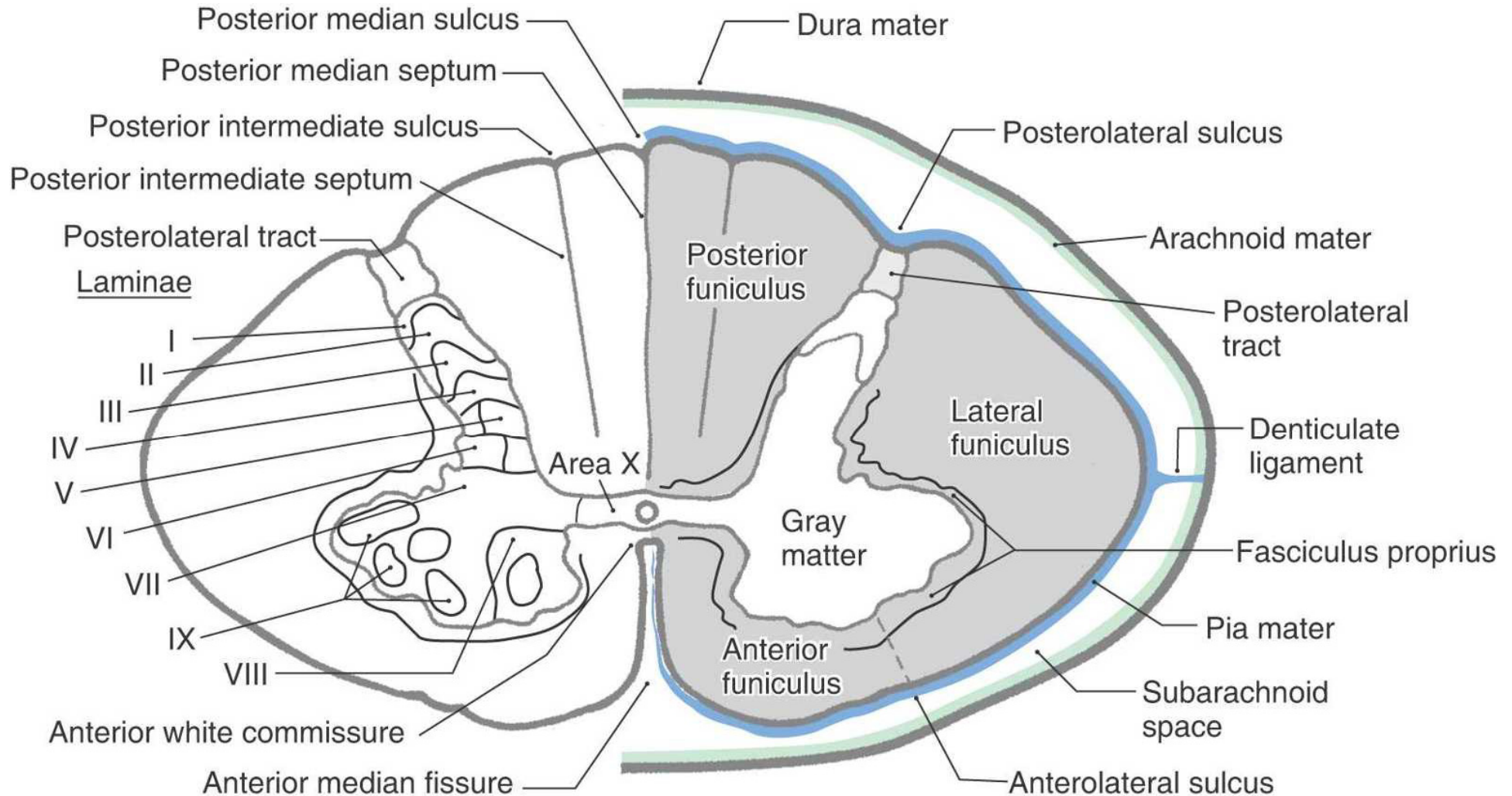
Cross Section of Spinal Cord

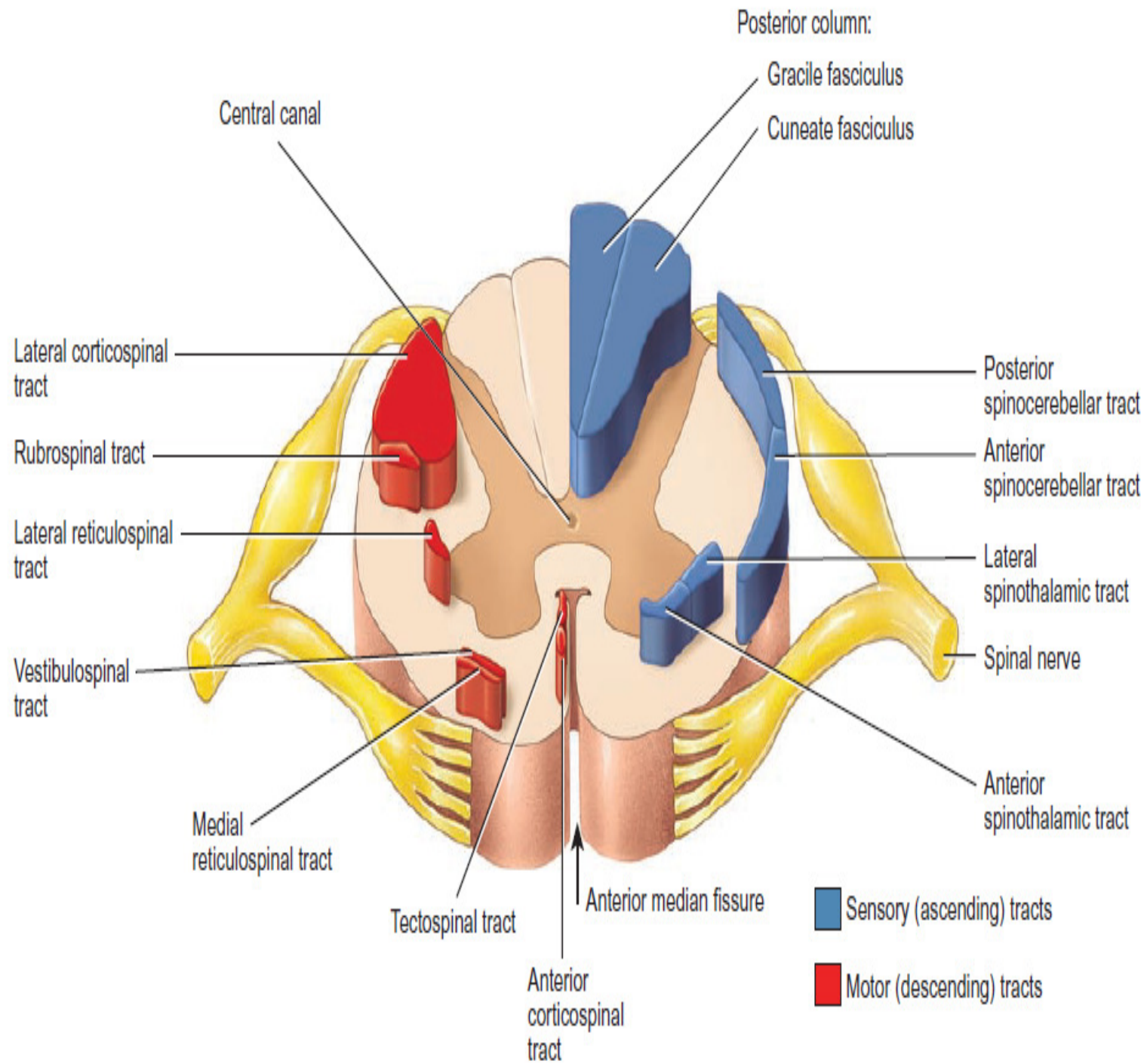
- Anterior median fissure: wide groove on the Anterior aspect
- posterior median sulcus: Narrow groove on the posterior aspect
- Gray matter: neuron cell bodies, dendrites, axons
 - Divided into *horns*
 - **Posterior (dorsal) horn** (cell body of sensory N)
 - **Anterior (ventral) horn** (cell body of motor N to skeletal M)
 - **Lateral horn** (cell body of motor N to cardiac M, smooth M, glands)



Cross Section of Spinal Cord

- I





Read Only

☐ Mechanoreceptors

❖ Meissner's corpuscle

- Respond to touch, pressure and low frequency vibration (low frequency)
- rapidly adapting

❖ Merkel's disc (Tactile Disc)

- Discriminative touch
- Slowly adapting

❖ End organ of Ruffini

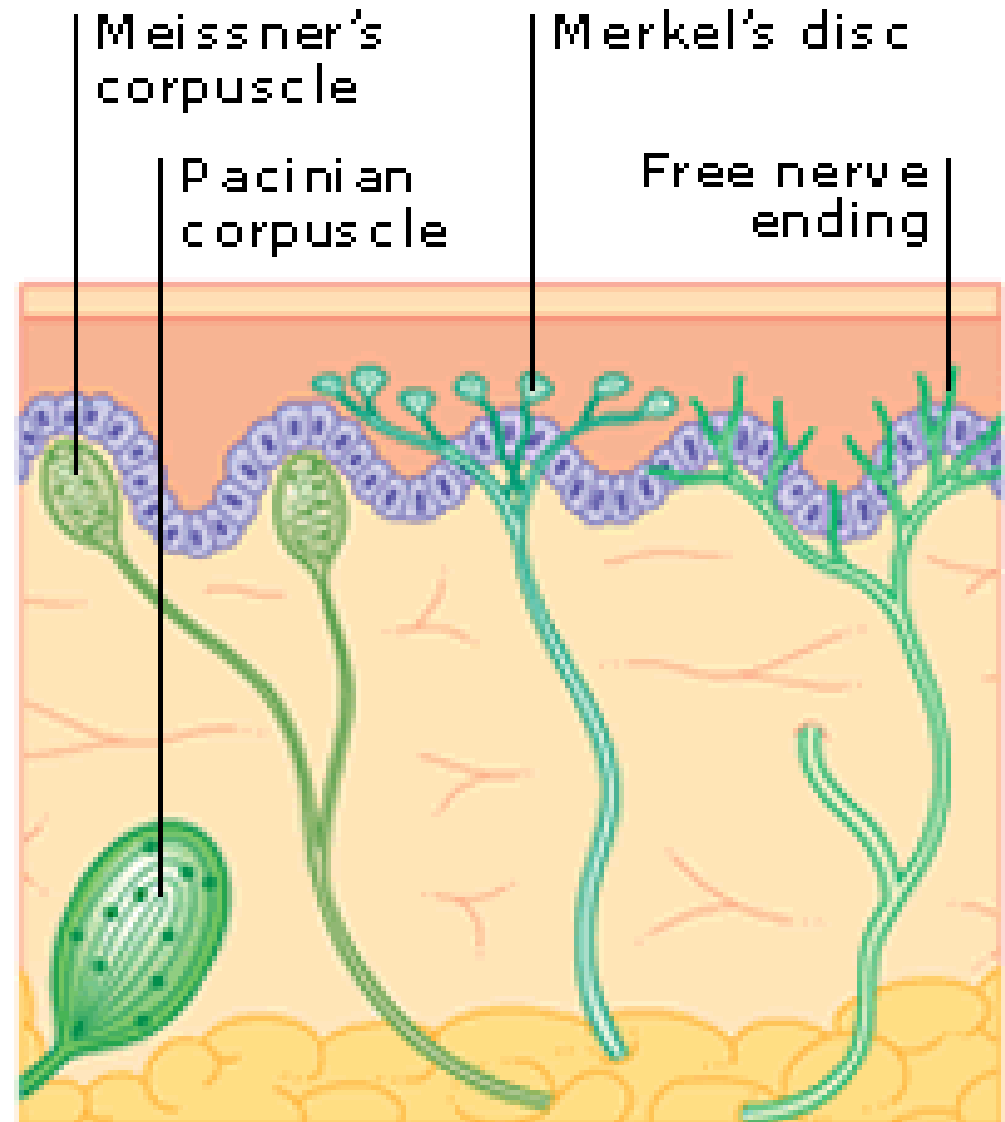
- sensitive to skin stretch
- Slowly adapting

❖ Pacinian corpuscles

- Vibrations (high frequency)
- rapidly adapting

➤ **Rapidly adapting:** signals fade away after stimulus exposure

➤ **Slow adaptation:** signals is transmitted as long as the stimulus is present



Adaptation of receptors occurs when a receptor is continuously stimulated. Many receptors become less sensitive with continued stimuli. Rapidly adapting receptors are best at detecting **rapidly changing signals**, while slowly adapting receptors are capable of detecting **a long, continuous signal**

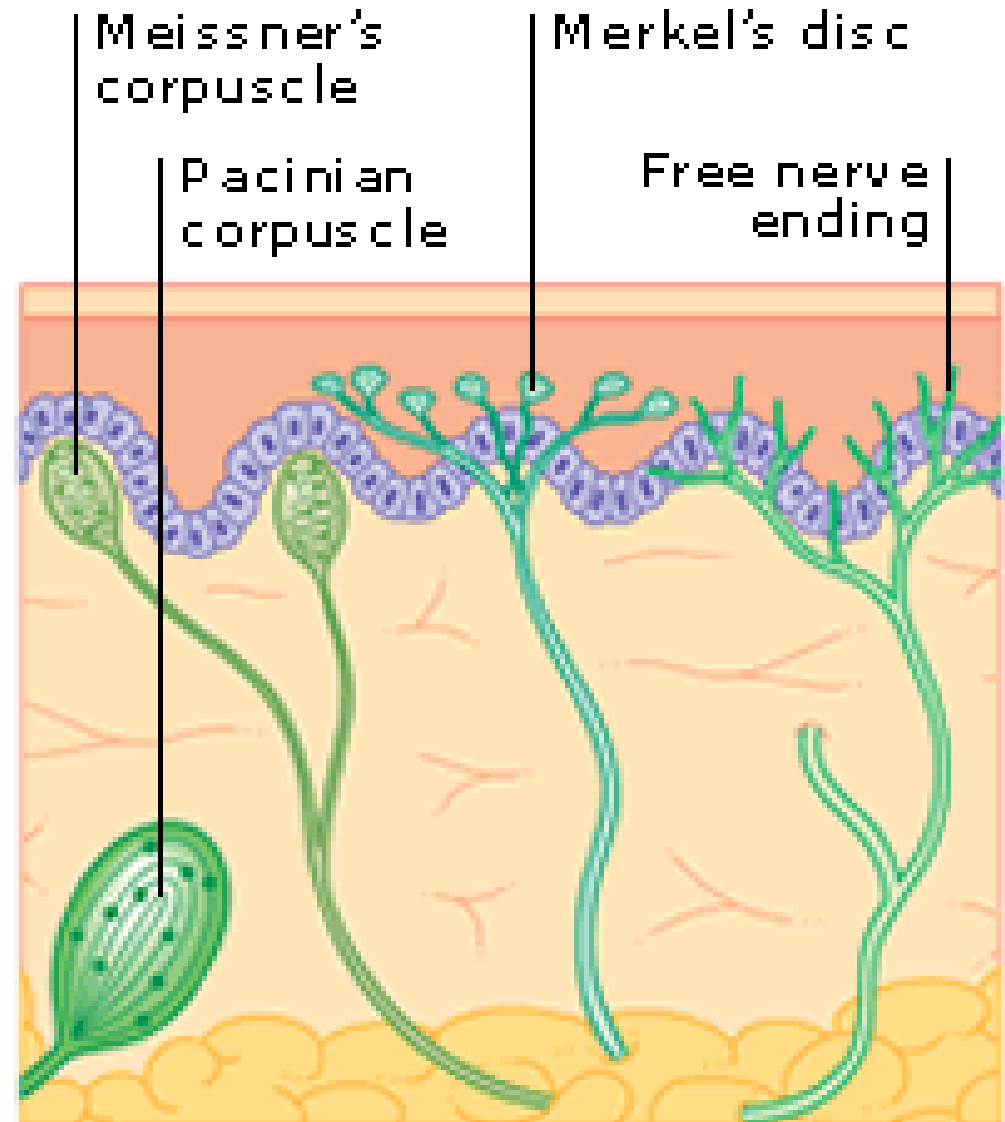
Read Only

❑ Thermoreceptors

- ❖ Free nerve endings
- ❖ Detect change in temperature
- ❖ TRP channels

❑ Nociceptors

- ❖ Free nerve endings
- ❖ Detect damage (pain receptors)
- ❖ Multimodal



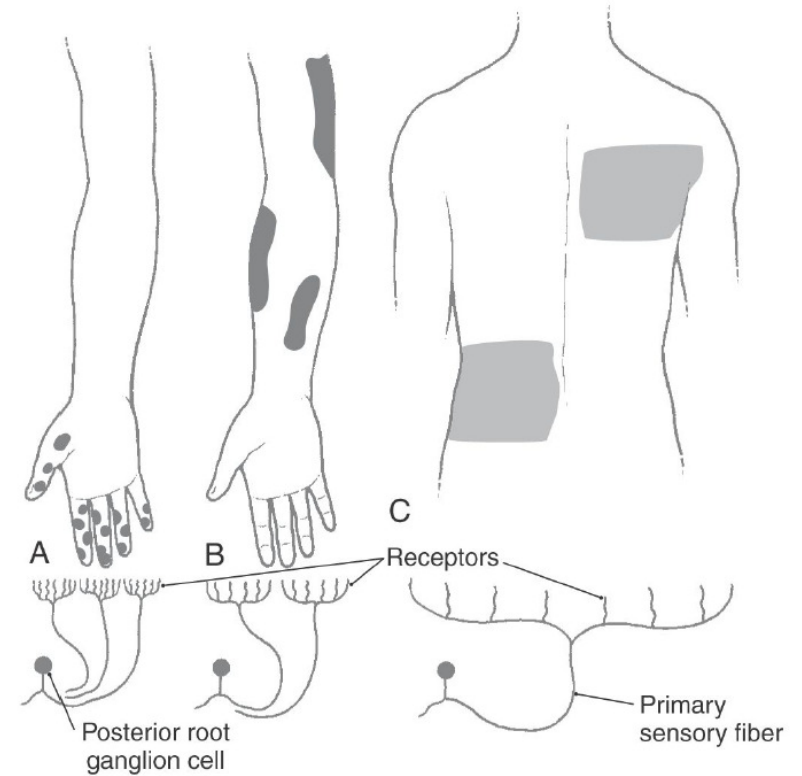
Adaptation of receptors occurs when a receptor is continuously stimulated. Many receptors become less sensitive with continued stimuli. Rapidly adapting receptors are best at detecting rapidly changing signals, while slowly adapting receptors are capable of detecting a long, continuous signal

ELECTROPHYSIOLOGIC CLASSIFICATION OF PERIPHERAL NERVES	CLASSIFICATION OF AFFERENT FIBERS ONLY (CLASS/GROUP)	FIBER DIAMETER (μm)	CONDUCTION VELOCITY (m/s)	RECEPTOR SUPPLIED
Sensory Fiber Type				
A α	Ia and Ib	13-20	80-120	Primary muscle spindles, Golgi tendon organ
A β	II	6-12	35-75	Secondary muscle spindles, skin mechanoreceptors
A δ	III	1-5	5-30	Skin mechanoreceptors, thermal receptors, and nociceptors
C	IV	0.2-1.5	0.5-2	Skin mechanoreceptors, thermal receptors, and nociceptors
Motor Fiber Type				
A α	N/A	12-20	72-120	Extrafusal skeletal muscle fibers
A γ	N/A	2-8	12-48	Intrafusal muscle fibers
B	N/A	1-3	6-18	Preganglionic autonomic fibers
C	N/A	0.2-2	0.5-2	Postganglionic autonomic fibers

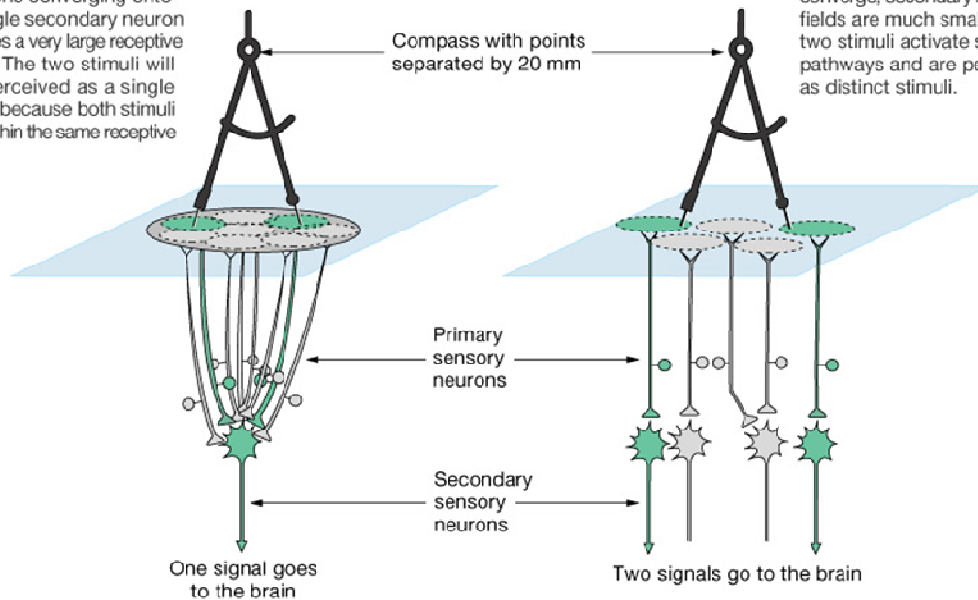
□ Receptive field

Read Only

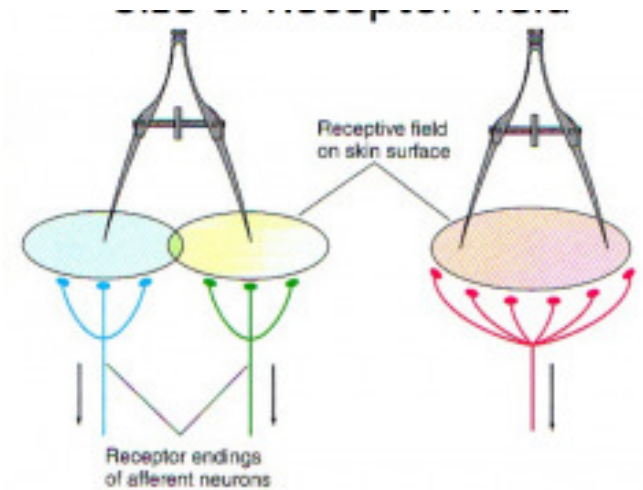
- Every receptor receives sensation from a certain area of the skin, (**receptive field**)
- The greater the density of receptors, the smaller the receptive fields of individual afferent fibers
- The smaller the receptive field the greater is the acuity or the discriminative touch



(a) Many primary sensory neurons converging onto a single secondary neuron creates a very large receptive field. The two stimuli will be perceived as a single point because both stimuli fall within the same receptive field.



(b) When fewer neurons converge, secondary receptive fields are much smaller. The two stimuli activate separate pathways and are perceived as distinct stimuli.



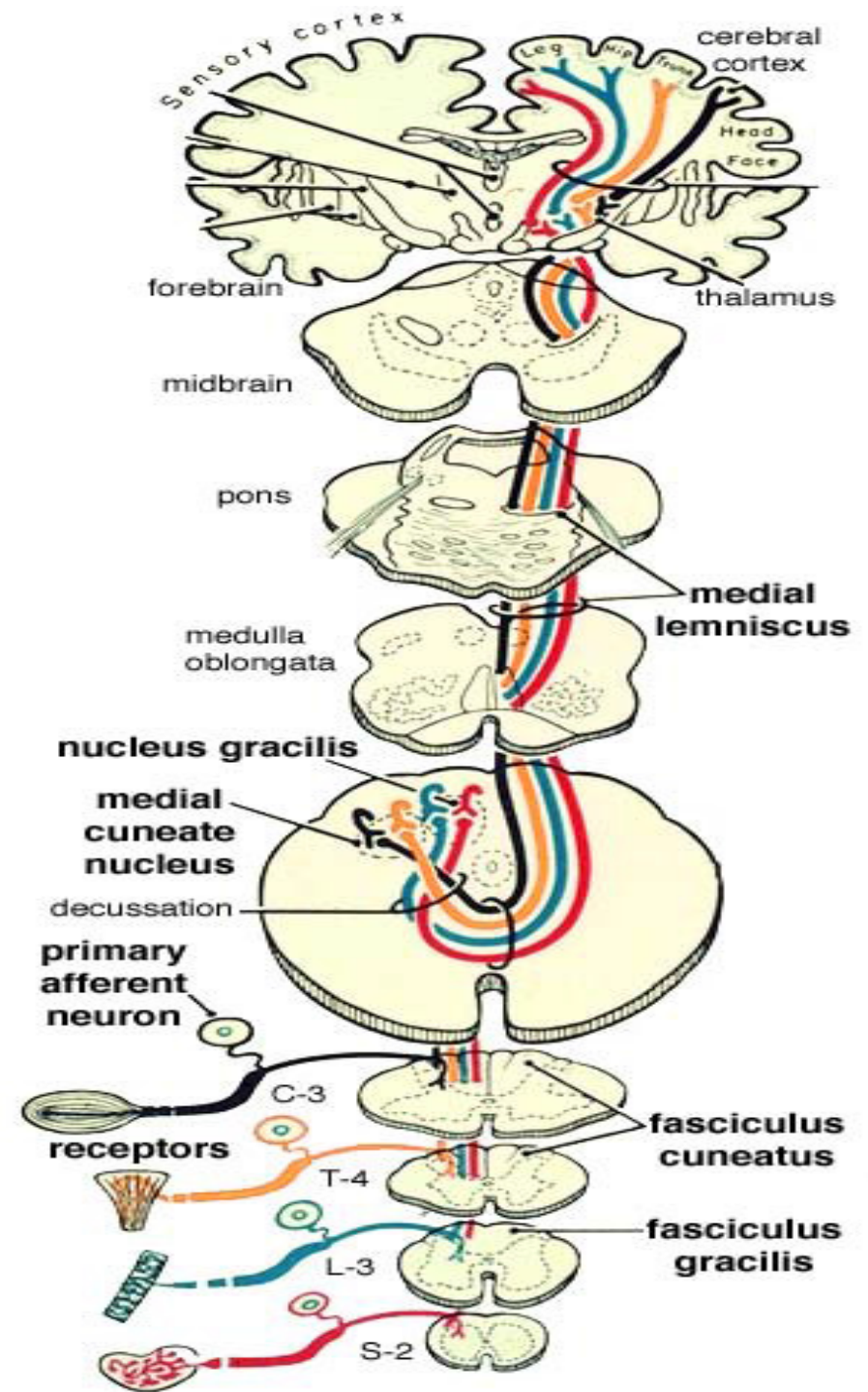
Labelled line theory

Read Only

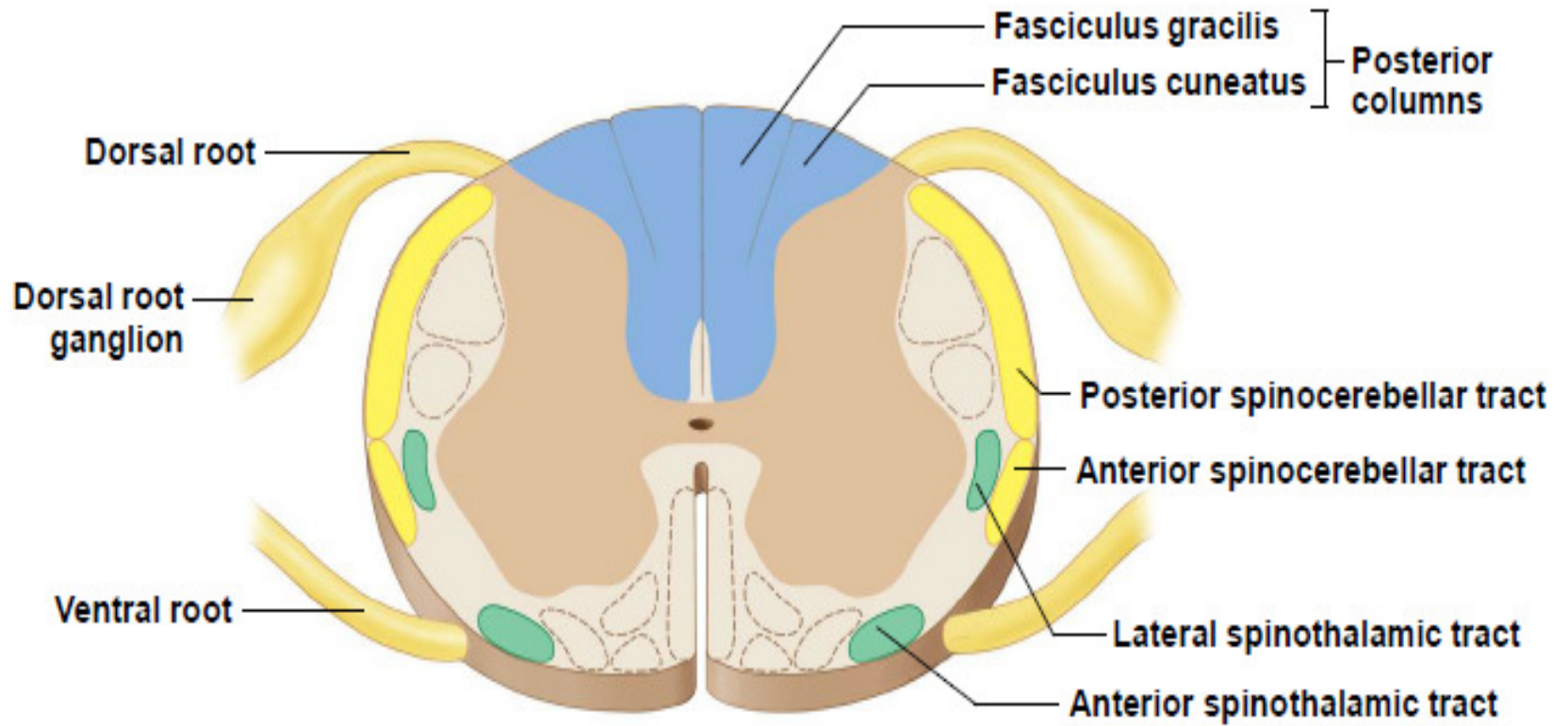
- ❑ individual receptors preferentially transduce information about an **adequate stimulus**
- ❑ individual primary afferent fibres carry information from a single type of receptor
- **Conclusion:**
- pathways carrying sensory information centrally are therefore also specific, forming a "labelled line" regarding a particular stimulus
 - **Note: The adequate stimulus is the amount and type of energy required to stimulate a specific sensory organ**
- ❑ **Sensation:**
 - Modality
 - Locality
 - Intensity

Posterior White Column-Medial Lemniscal Pathway

- Modality: Discriminative Touch Sensation (include Vibration) and Conscious Proprioception
- Receptor: Most receptors except free nerve endings
- 1st Neuron: Dorsal Root Ganglion
- 2nd Neuron: Dorsal Column Nuclei (Nucleus Gracilis and Cuneatus)
 - Internal Arcuate Fiber -
 - Lemniscal Decussation
 - Medial Lemniscus
- 3rd Neuron: Thalamus (VPL) Internal Capsule ----- Corona Radiata
- Termination: Primary Somesthetic Area (S I)



Posterior White Column-Medial Lemniscal Pathway



Discriminative touch, vibratory sense, and conscious muscle-joint sense

•**Posterior Column tract consists of:**

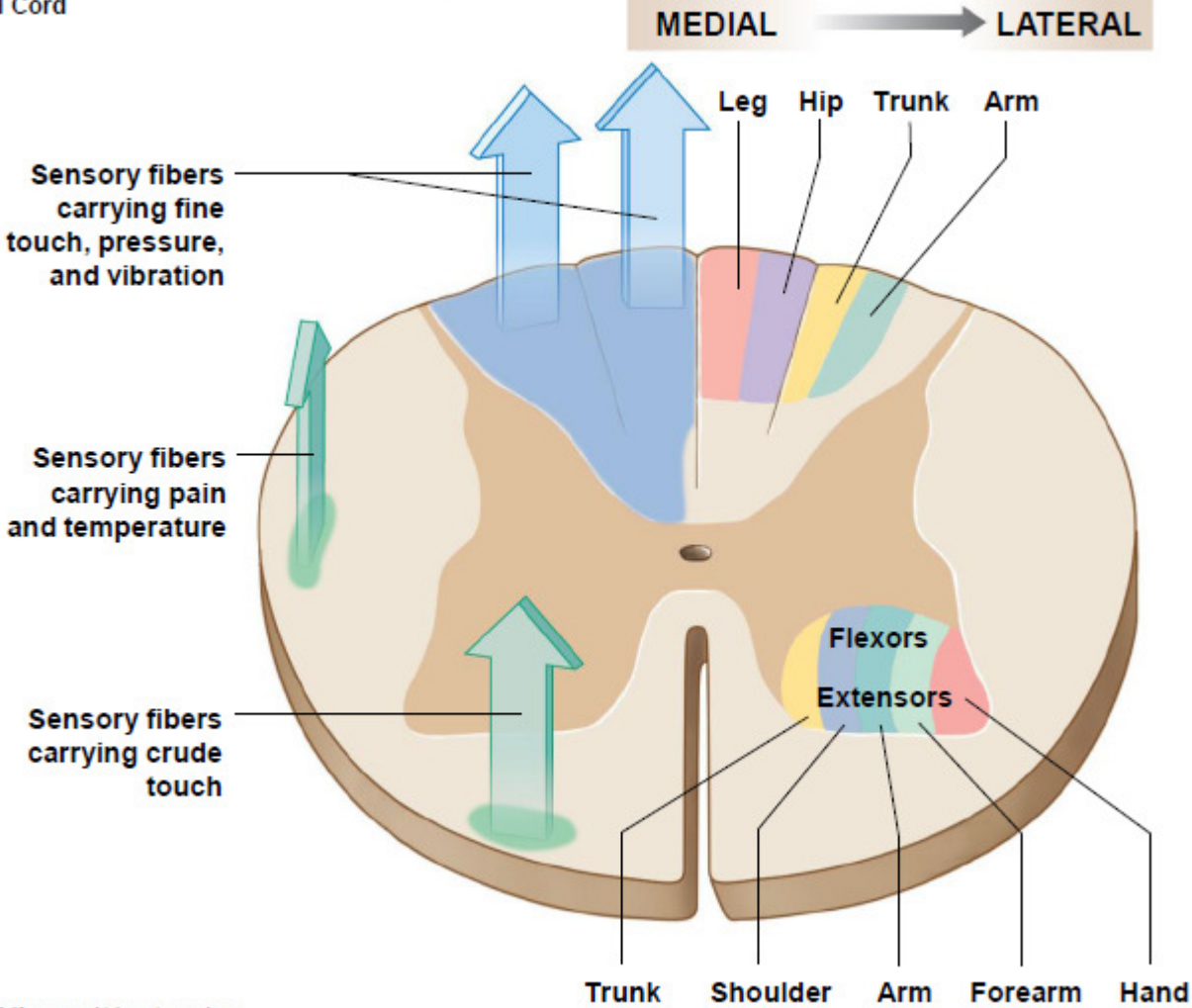
•**Fasciculus gracilis**

•Transmits information coming from areas inferior to T6

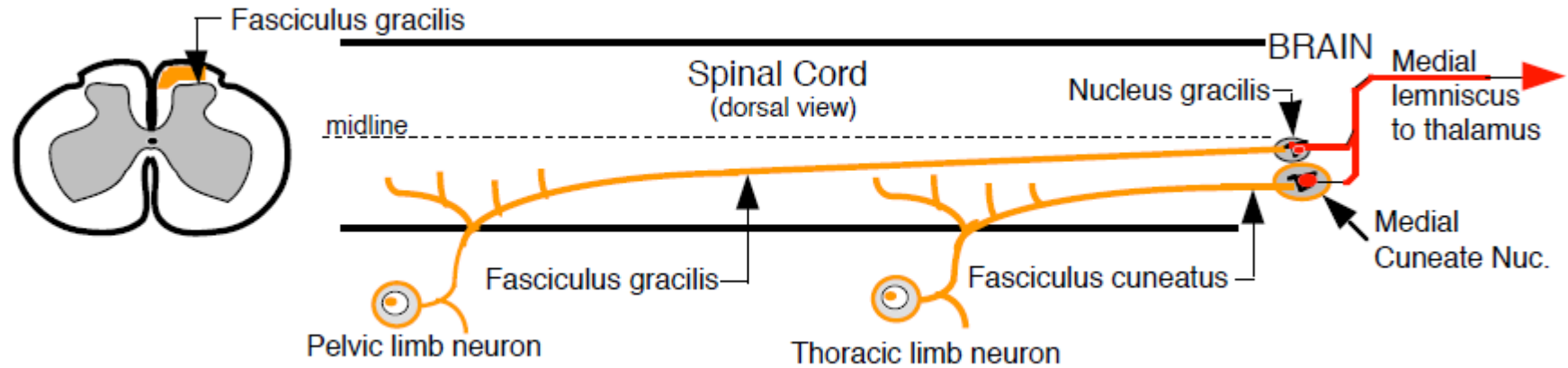
•**Fasciculus cuneatus**

•Transmits information coming from areas superior to T6

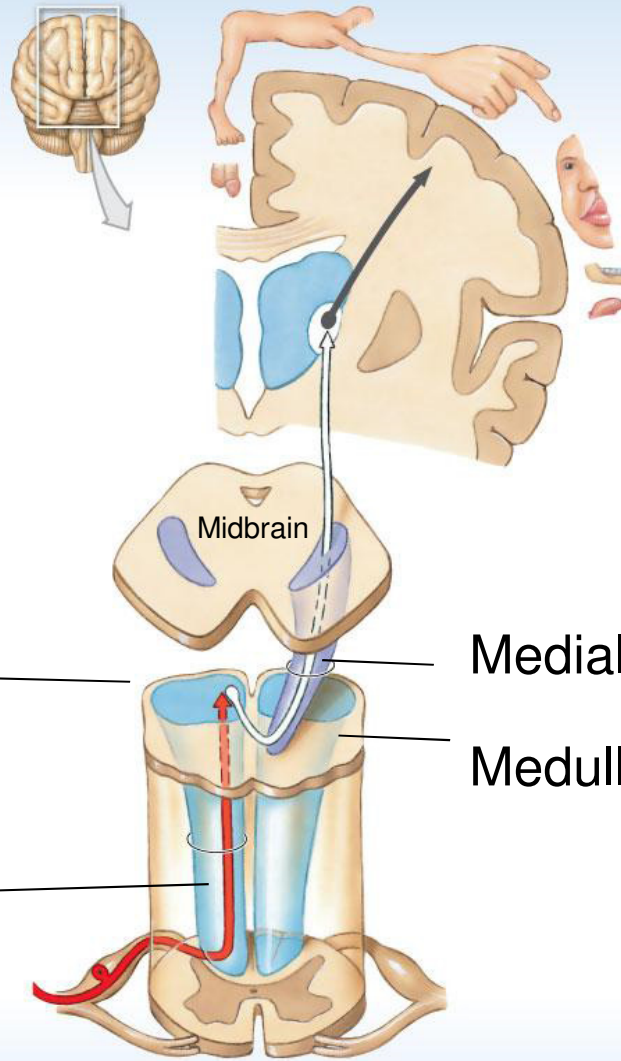
Figure 15.1 Anatomical Principles for the Organization of the Sensory Tracts and Lower-Motor Neurons in the Spinal Cord



Discriminative Touch Spinal Pathway



Posterior Columns



Nucleus gracilis
nucleus cuneatus

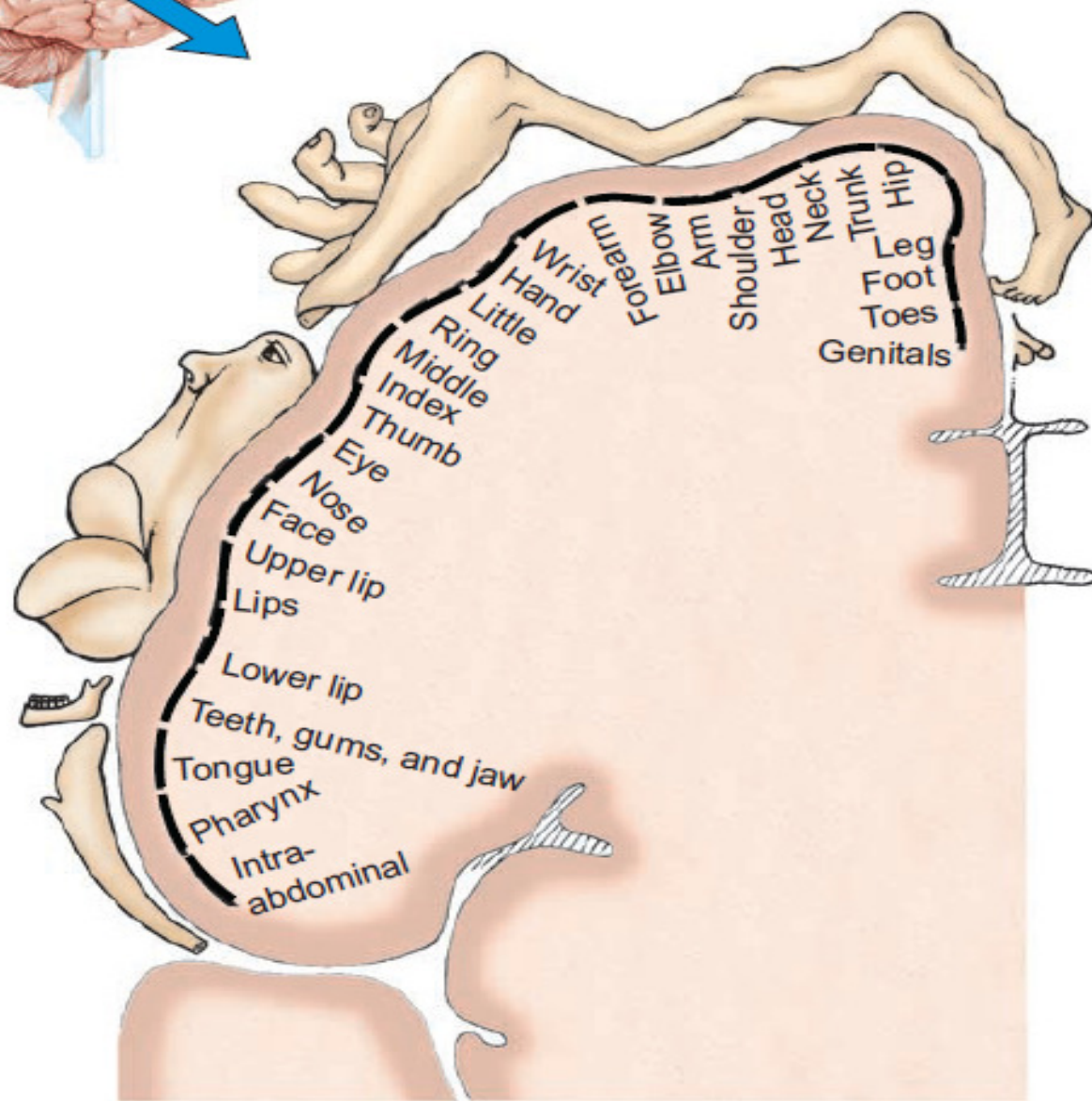
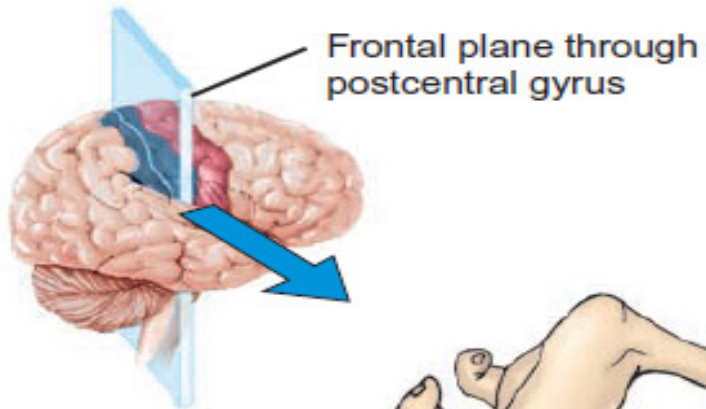
Medial lemniscus

Medulla oblongata

Fasciculus cuneatus
fasciculus gracilis

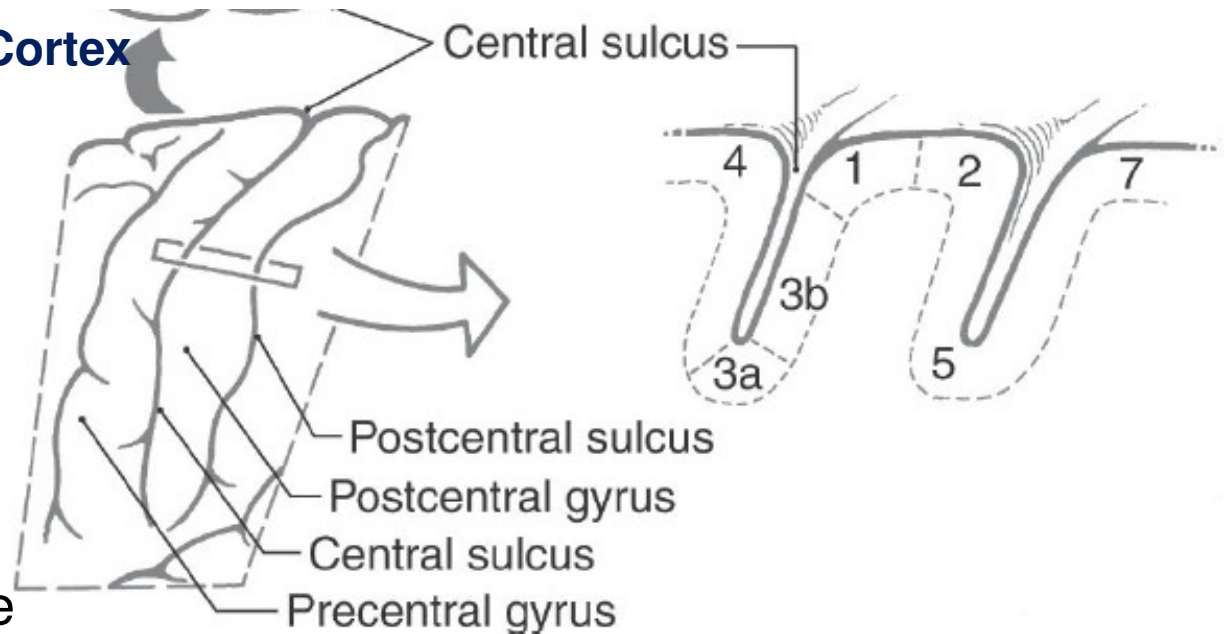
Fine-touch, vibration, pressure, and proprioception
sensations from right side of body

ELECTROPHYSIOLOGIC CLASSIFICATION OF PERIPHERAL NERVES	CLASSIFICATION OF AFFERENT FIBERS ONLY (CLASS/GROUP)	FIBER DIAMETER (μm)	CONDUCTION VELOCITY (m/s)	RECEPTOR SUPPLIED
Sensory Fiber Type				
A α	Ia and Ib	13-20	80-120	Primary muscle spindles, Golgi tendon organ
A β	II	6-12	35-75	Secondary muscle spindles, skin mechanoreceptors
A δ	III	1-5	5-30	Skin mechanoreceptors, thermal receptors, and nociceptors
C	IV	0.2-1.5	0.5-2	Skin mechanoreceptors, thermal receptors, and nociceptors
Motor Fiber Type				
A α	N/A	12-20	72-120	Extrafusal skeletal muscle fibers
A γ	N/A	2-8	12-48	Intrafusal muscle fibers
B	N/A	1-3	6-18	Preganglionic autonomic fibers
C	N/A	0.2-2	0.5-2	Postganglionic autonomic fibers



Primary Somatosensory (SI) Cortex

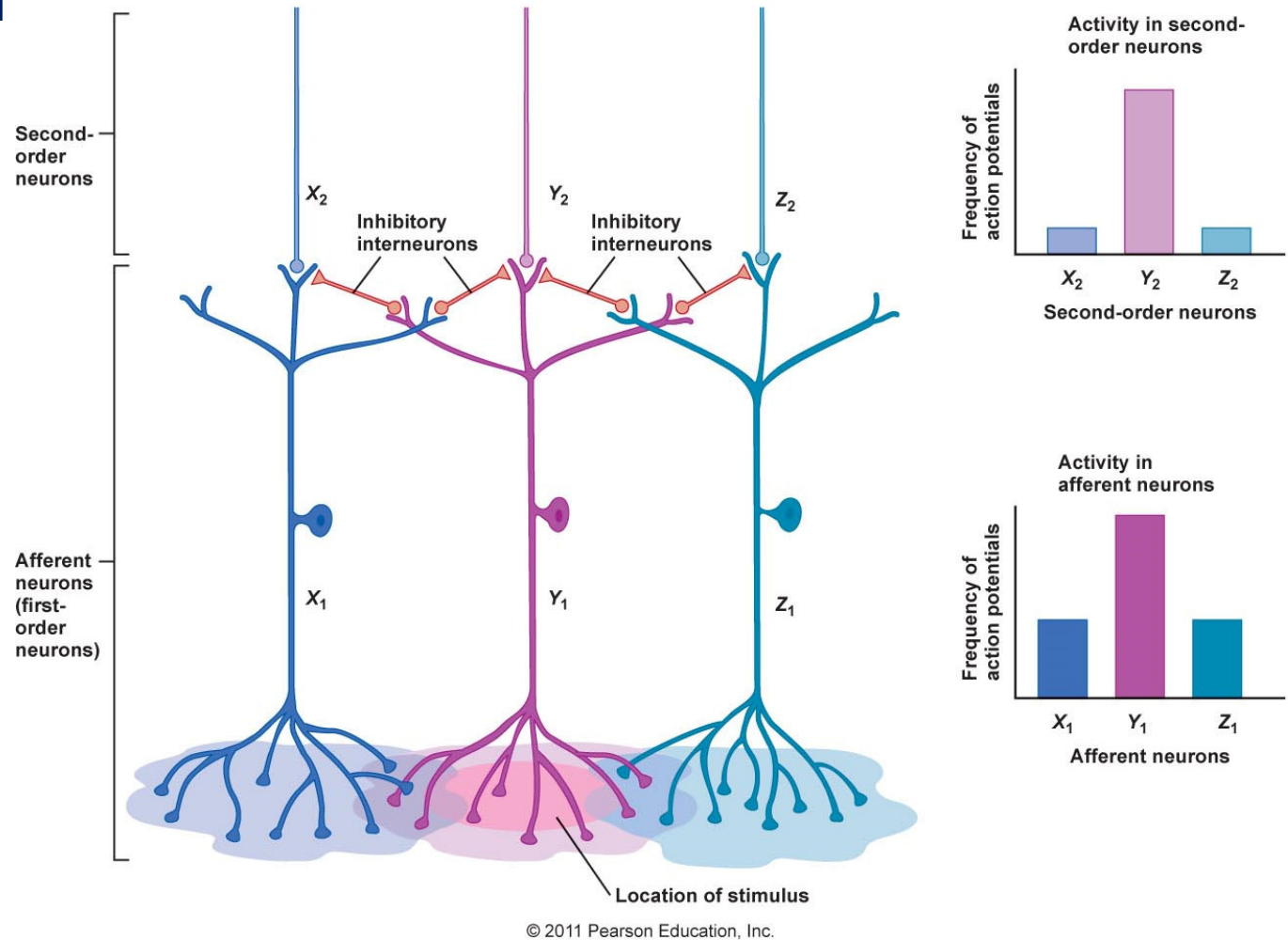
- ❑ Axons from third-order thalamic neurons terminate in the **primary somatosensory (SI) cortex**
- ❑ subdivided into four distinct areas; from anterior to posterior, these are **Brodmann areas 3a, 3b, 1, and 2**



- **Area 3a:** muscle spindle afferents (mainly)
- **Area 2:** Golgi tendon organs, and joint afferents (mainly).
- **Areas 3b and 1:** They receive cutaneous afferents from receptors such as Meissner corpuscles and Merkel cells). also receive input from cutaneous receptors that transmit pain and temperature

Lateral inhibition

- ❑ The receptor at the site of most intense stimulation is activated to the greatest extent. Surrounding receptors are also stimulated but to a lesser degree
- ❑ The most intensely activated receptor pathway halts transmission of impulses in the less intensely stimulated pathways through lateral inhibition

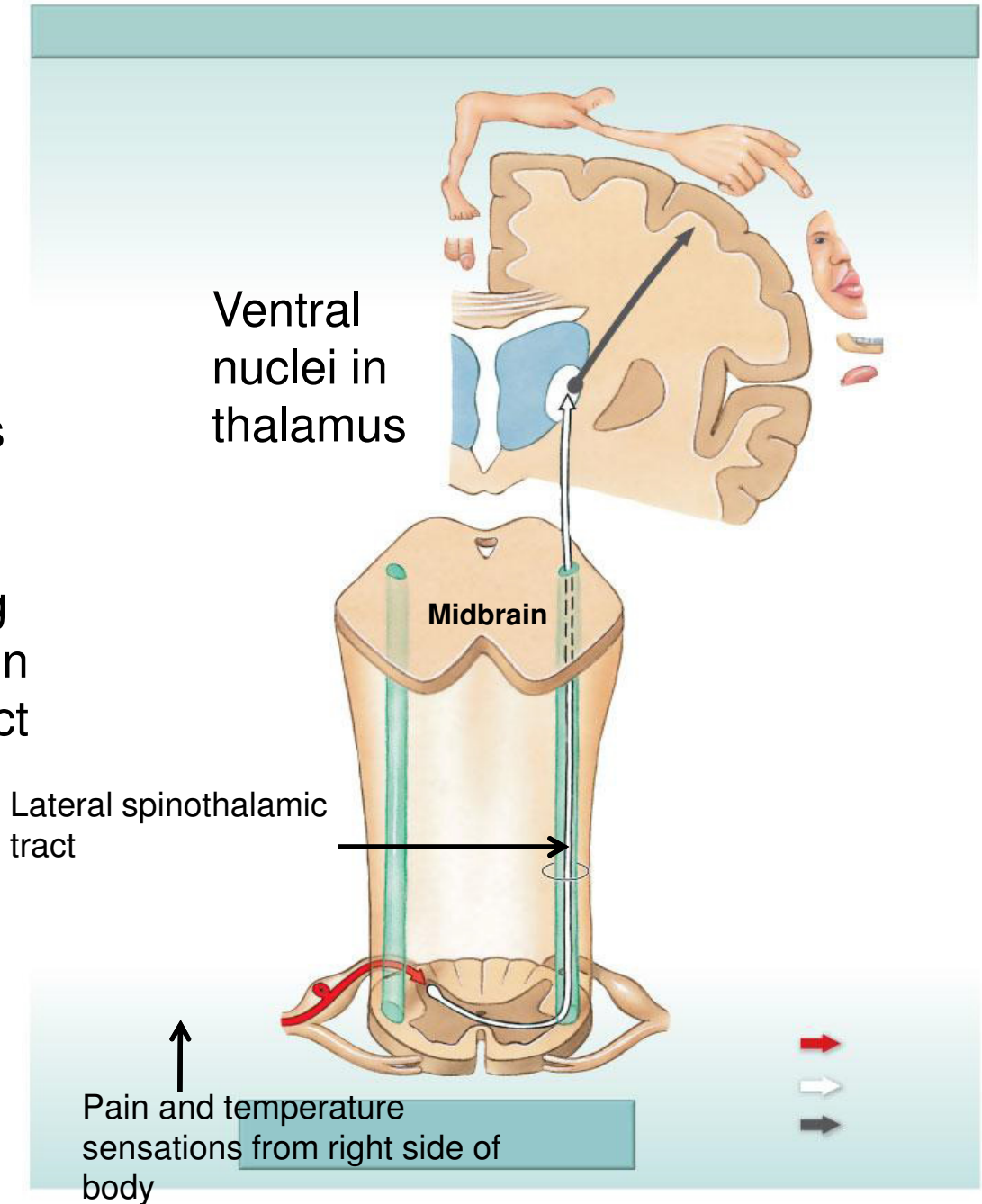


- ❑ This process facilitates the localization of the site of stimulation

Read Only

lateral spinothalamic tract

- Modality: pain and temperature
- Receptors: free nerve endings
- 1st Neuron: Dorsal root ganglia
- 2nd Neuron: the posterior gray column (substantia gelatinosa)
The axons of 2nd order neurons cross obliquely to the opposite side in the anterior gray and white commissures, ascending in the contralateral white column as the lateral spinothalamic tract
- 3rd Neuron: Thalamus (VPL)
Internal Capsule ----- Corona Radiata
- Termination: Primary Somesthetic Area (S I) and Widespread Cortical Region



Rexed laminae

- **Lamina 1** relay information related to pain and temperature
- **Lamina 2:** relay information related to pain and temperature (**pain modulation**)
- **Lamina 3 and 4:** nucleus proprius; these laminae have many interneurons

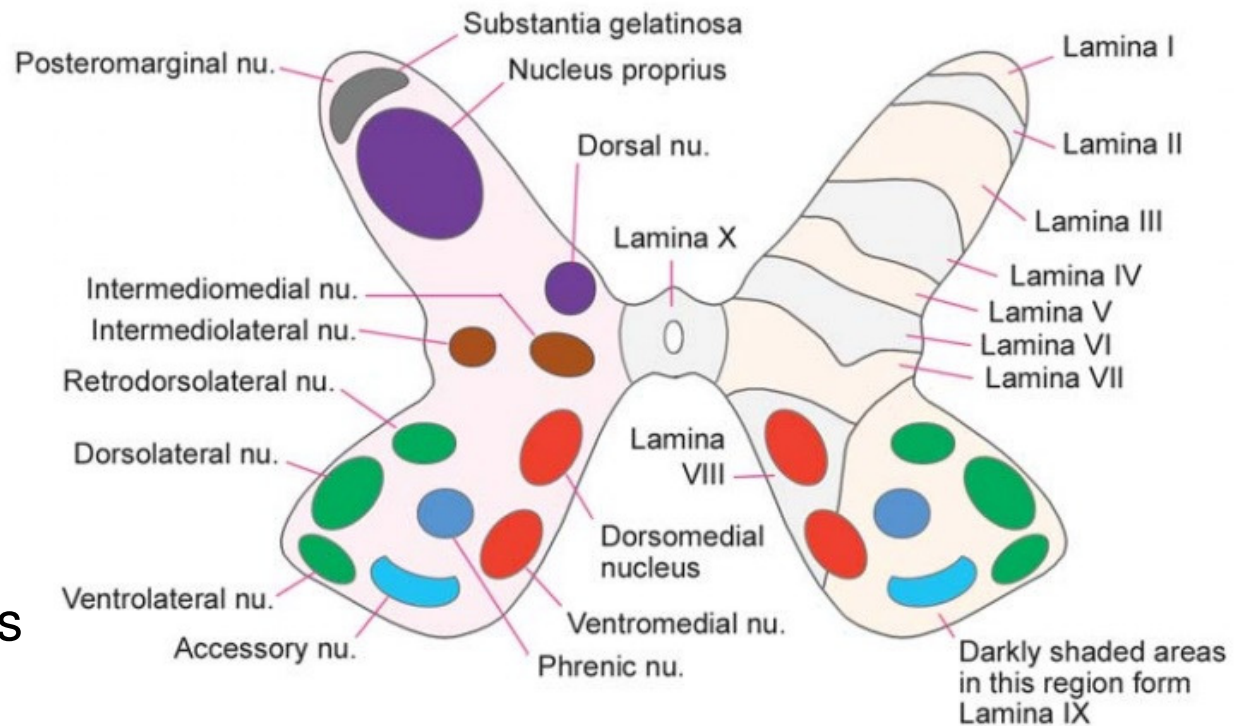
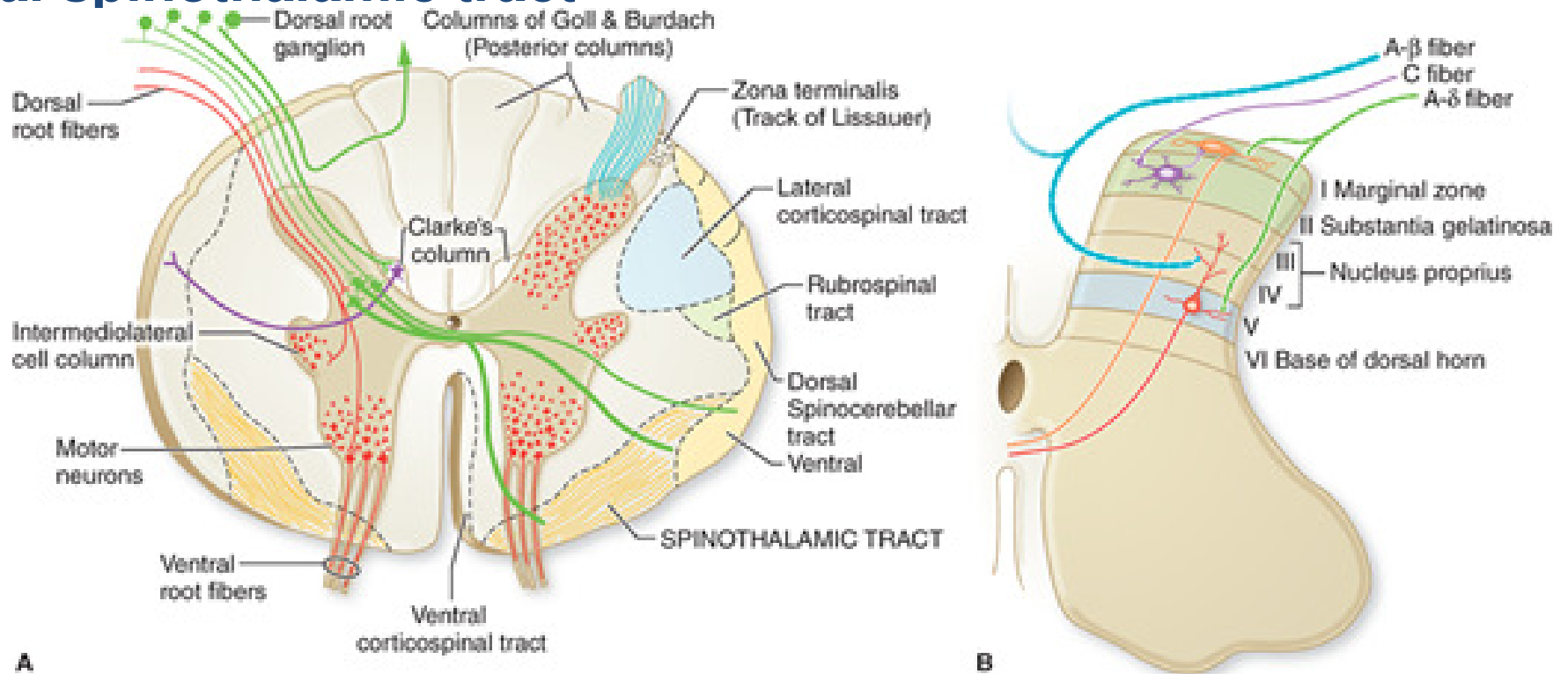


Fig. 5.2. Subdivisions of the grey matter of the spinal cord. The left half of the figure shows the cell groups usually described. The right half shows the newer concept of laminae.

- **Lamina 5:** relay information related to pain and temperature
- **Lamina 6:** presents only at the cervical and lumbar enlargements and receives proprioception
- **Lamina 7: Intermedio-lateral** nucleus, contains preganglionic fibers of sympathetic (T1 -L2). **Intermedio-medial nucleus**, all over the spinal cord, receive visceral pain. **Dorsal nucleus of Clark's** presents at (C8 – L2 or T1-L4), relay center for **unconscious proprioception**

lateral spinothalamic tract

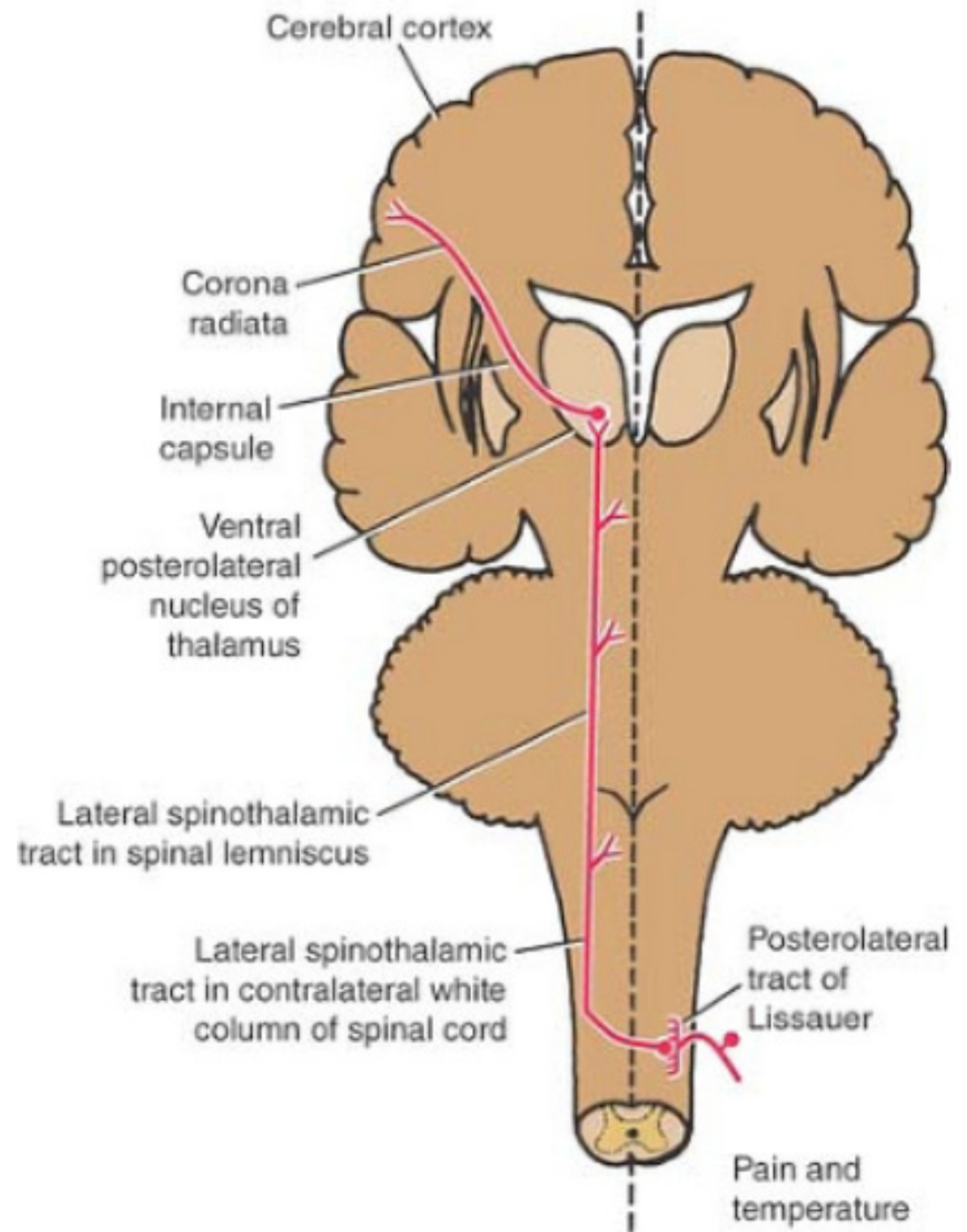
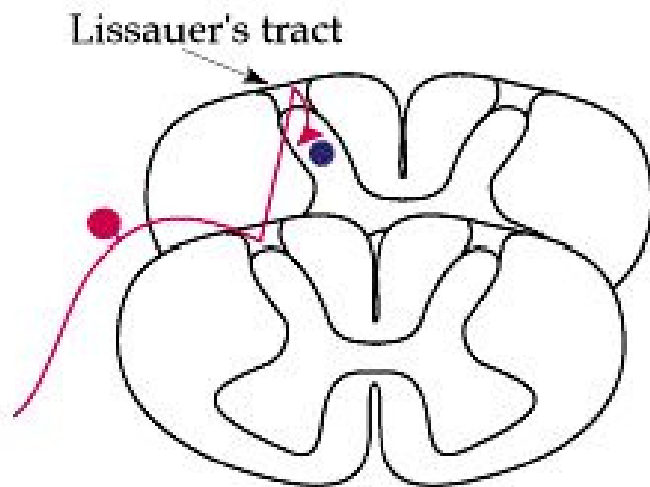


Source: Ropper AH, Samuels MA, Klein JP: Adams and Victor's Principles of Neurology, Tenth Edition; www.accessmedicine.com
Copyright © The McGraw-Hill Companies, Inc. All rights reserved.

- Lamina 1+ 5: the spinothalamic tract ascend which transmit pain, temperature and touch. (A delta fibers)
- Lamina 1+ 2: the spinothalamic tract ascend (C fibers).

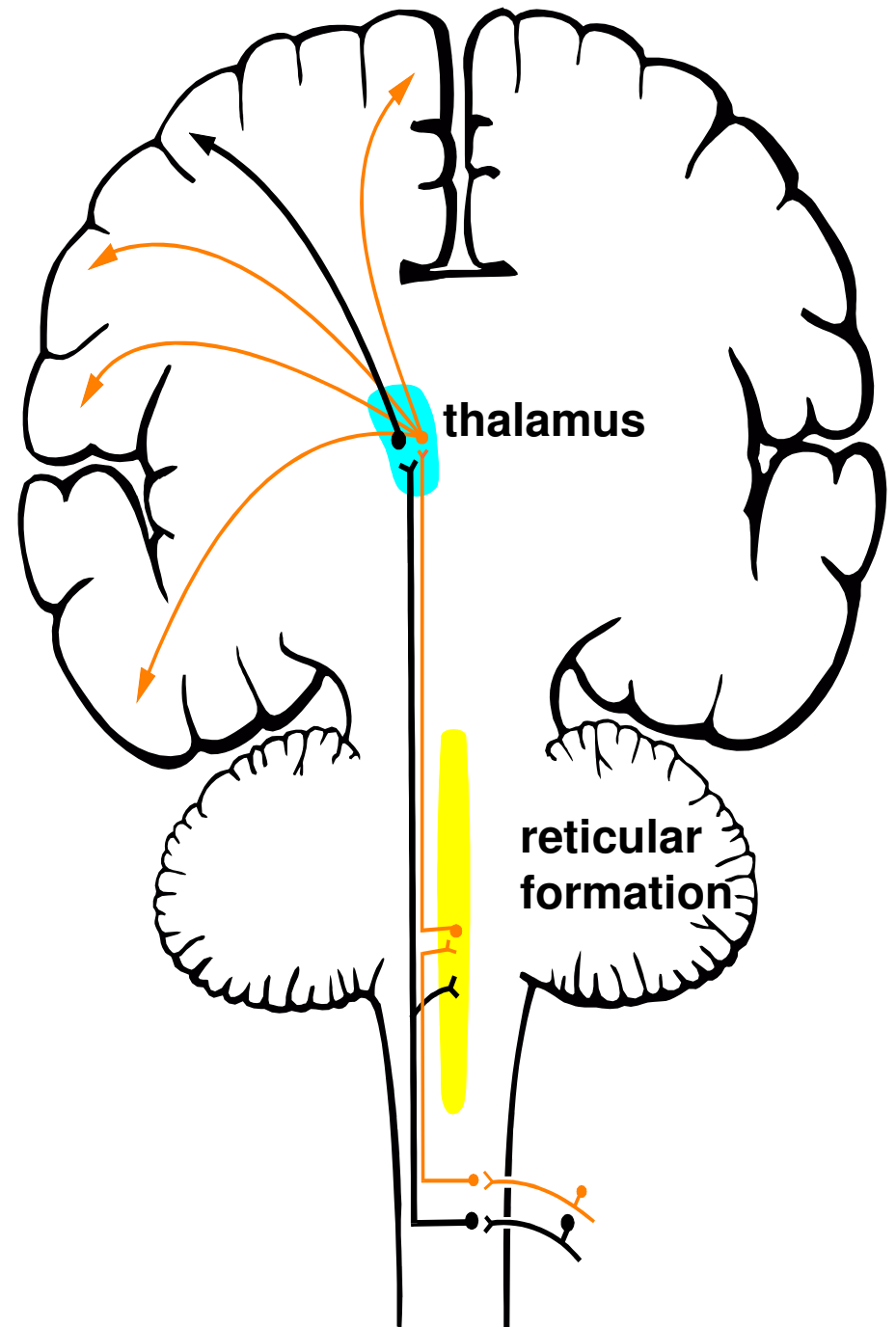
Posterolateral tract of Lissauer

- located between the posterior white column and the lateral white column



Other Terminations of the Lateral Spinothalamic Tract

- **Reticular formation:**
(majority of the slow pain fibers) individual becomes aware of the pain
- **Cingulate gyrus:**
interpretation of the emotional aspect of pain
- **Insular gyrus:** concerned with the interpretation of pain stimuli from the internal organs of the body and brings about an autonomic response



Pain classifications slow and fast

Read Only

Fast Pain

Slow Pain

Sharp, pricking

Dull, burning

(A δ) fiber

(C) fiber

Short latency

Slower onset

Well localized

Diffuse

Short duration

Long duration

Less emotional

Emotional, autonomic response

Mostly from superficial structures

Superficial & deep structures

Spinothalamic

Spinoreticular

lamina I & V

lamina I & II

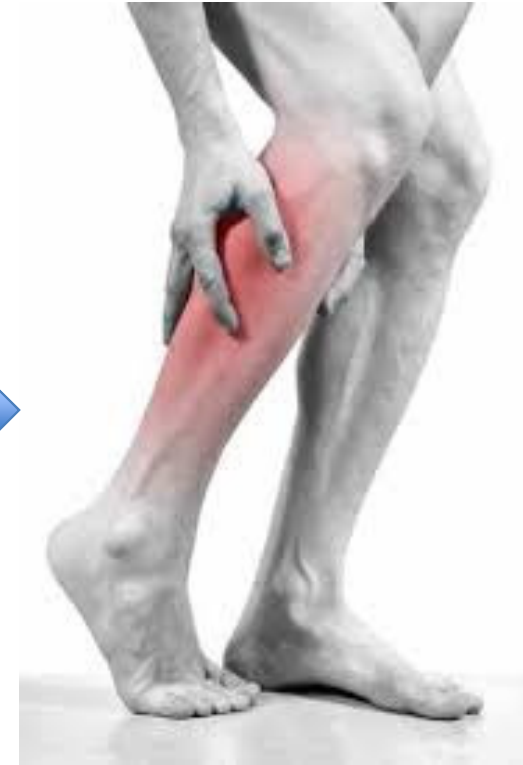VPL nucleus

VPL & intraluminar nucleus

Pain According to origin

- ❑ **Cutaneous:** skin
- ❑ **Deep somatic:** muscles , bones , joints & ligaments , dull diffuse
- **Intermittent claudication:** muscle pain which occurs during exercise classically in the calf muscles due to peripheral artery disease (blood supply is not enough to remove the metabolites esp. lactic acid)
- ❑ **Visceral:** poorly localized & transmitted via C fibers
 - Chemoreceptors, baroreceptors, osmoreceptors, and stretch receptors
 - Sensitive to ischemia, stretching, and chemical damage
 - **Often referred**

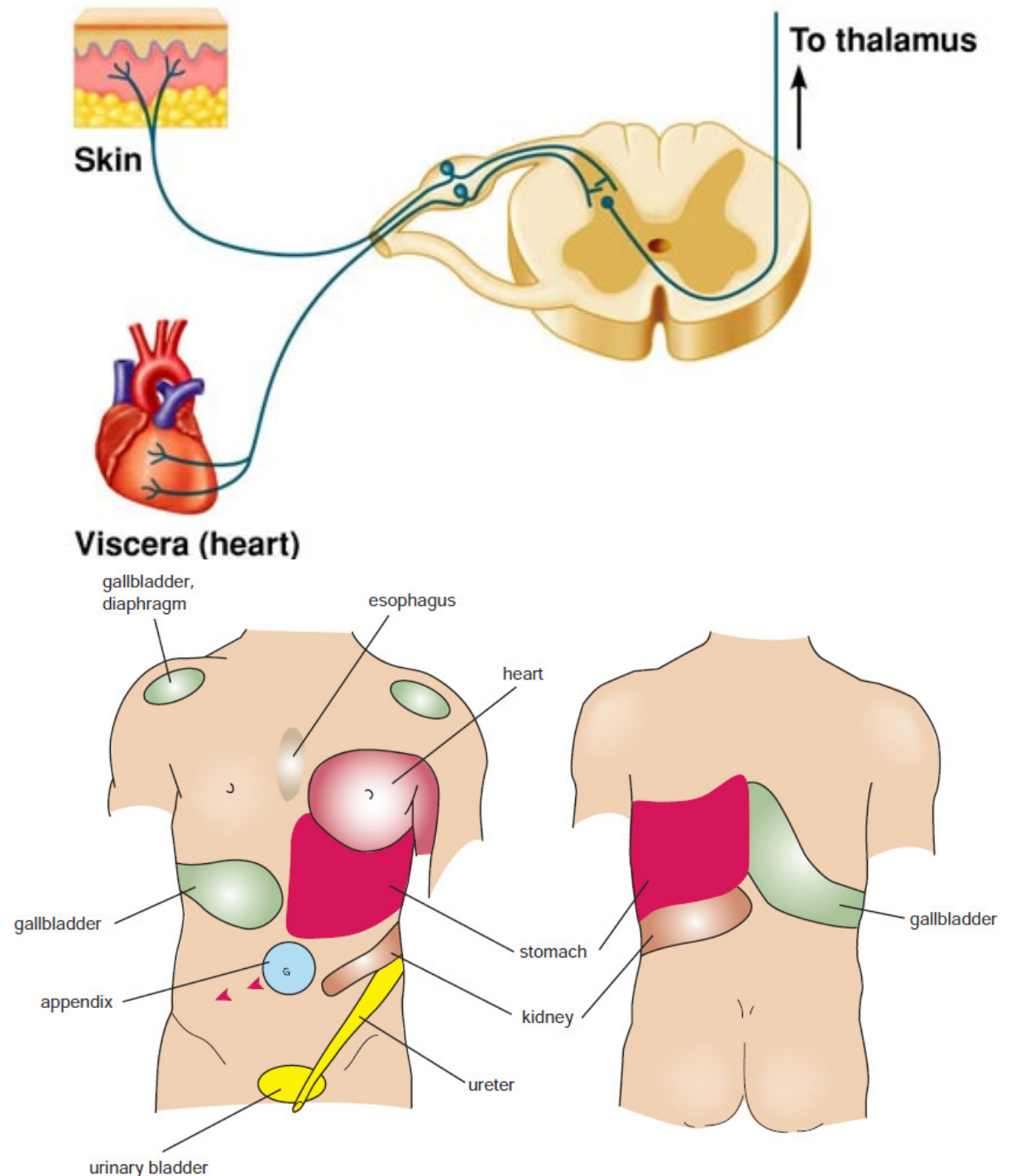
Read Only

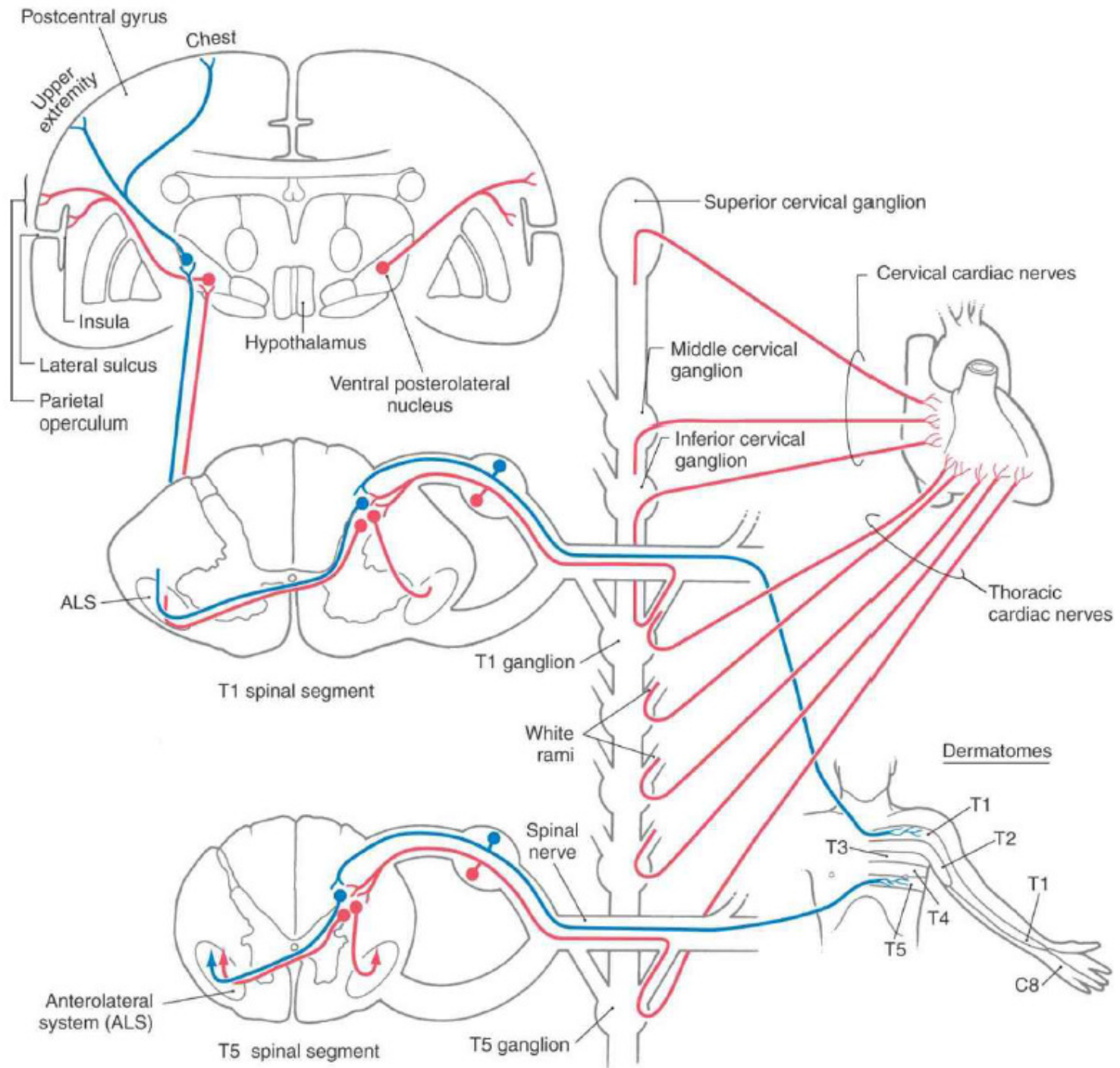


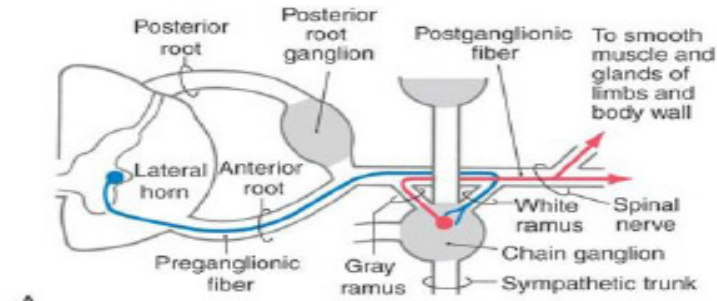
- ❑ **Causes of visceral pain**
 - Distention of bladder and abdominal viscera
 - Ischemia
 - Spasm: leads to blood vessels compressions and accumulation of metabolites.
 - Chemical damage :HCl from perforated ulcer

Referred pain mechanism *convergence theory*

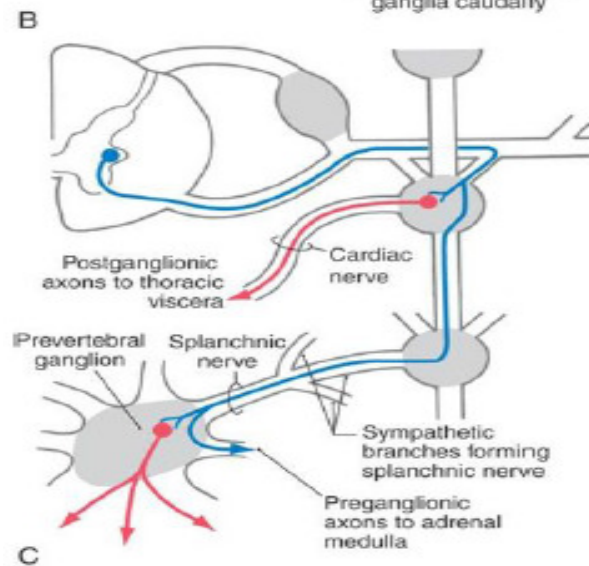
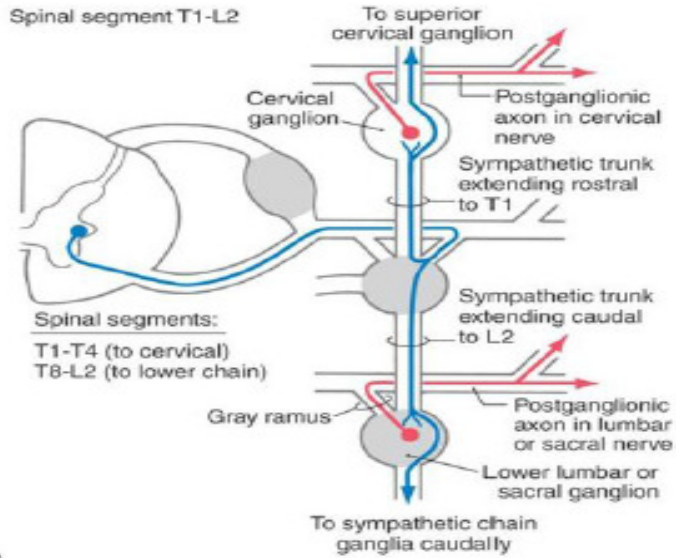
- ❑ Referred pain is presumed to occur because the information from multiple nociceptor afferents converges onto individual spinothalamic tract neurons
- ❑ The brain therefore interprets the information coming from visceral receptors as having arisen from receptors on the body surface, since this is where nociceptive stimuli originate more frequently







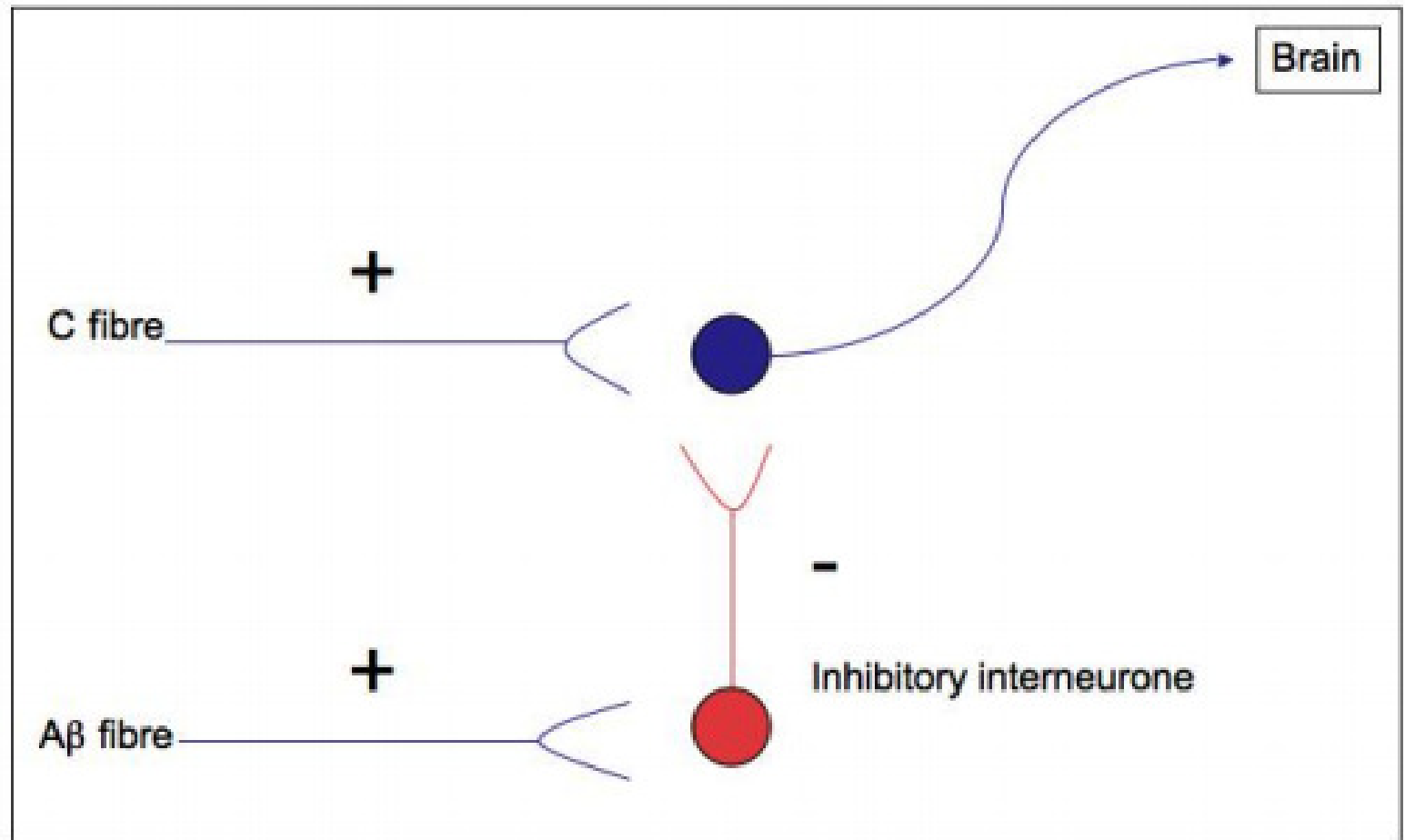
A
Spinal segment T1-L2



C

Pain Control in the Central Nervous System

The Gating Theory



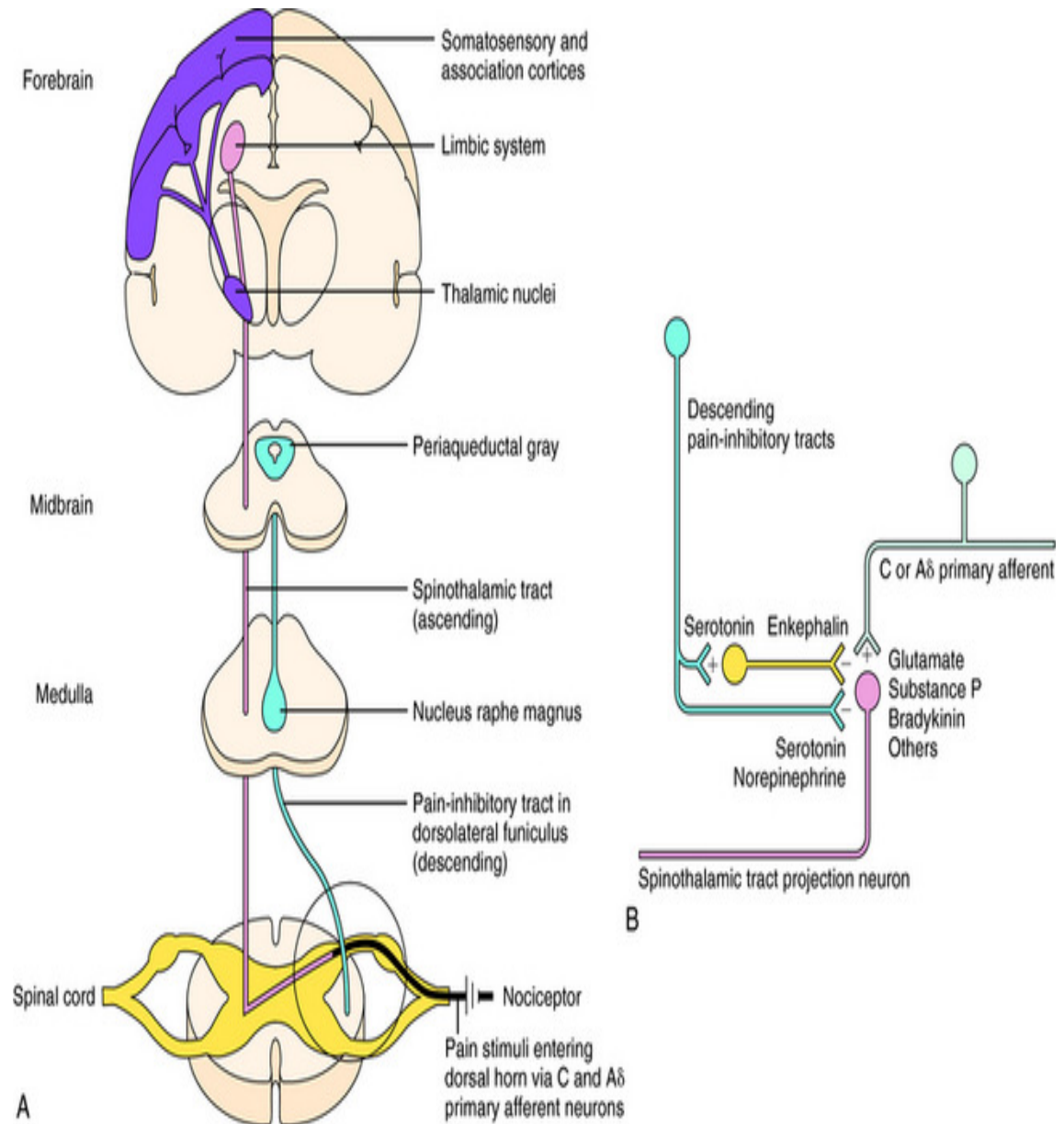
- At the site where the pain fiber enters the central nervous system, inhibition could occur by means of connector neurons excited by large, myelinated afferent fibers carrying information of nonpainful touch and pressure

Pain Control in the Central Nervous System

Descending control of pain

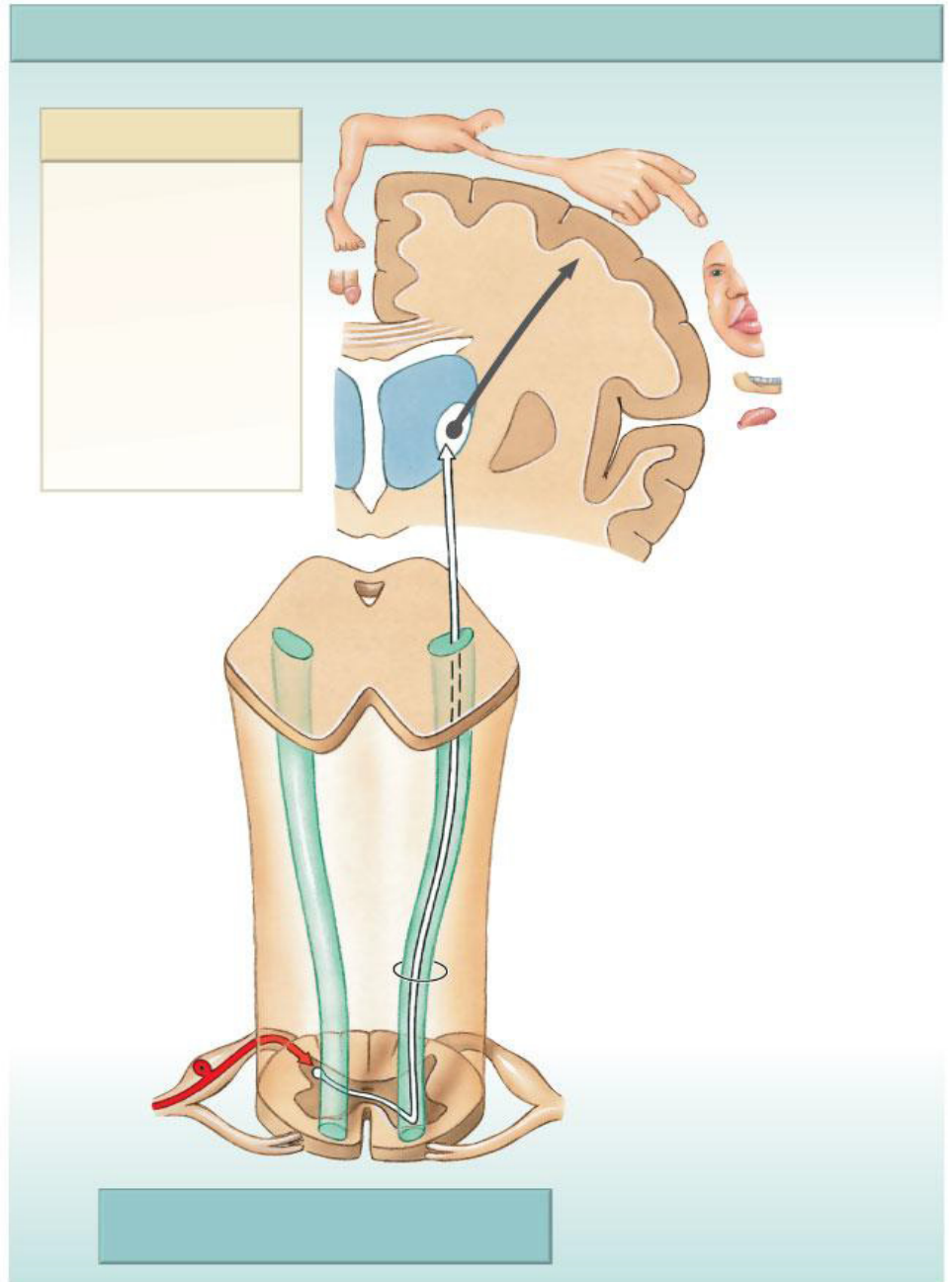
- Spinoreticular fibers stimulates **periaqueductal gray (PAG)**
- Excitatory neurons of PAG projects to Nucleus raphe magnus (NRM)
- (NRM) neurons produces serotonin which activates inhibitory neurons that secretes **enkephalins and the endorphins** (morphinelike actions) in substantia gelatinosa

□ **Locus coeruleus** (in Pons), thought to directly inhibit substantia gelatinosa neurons



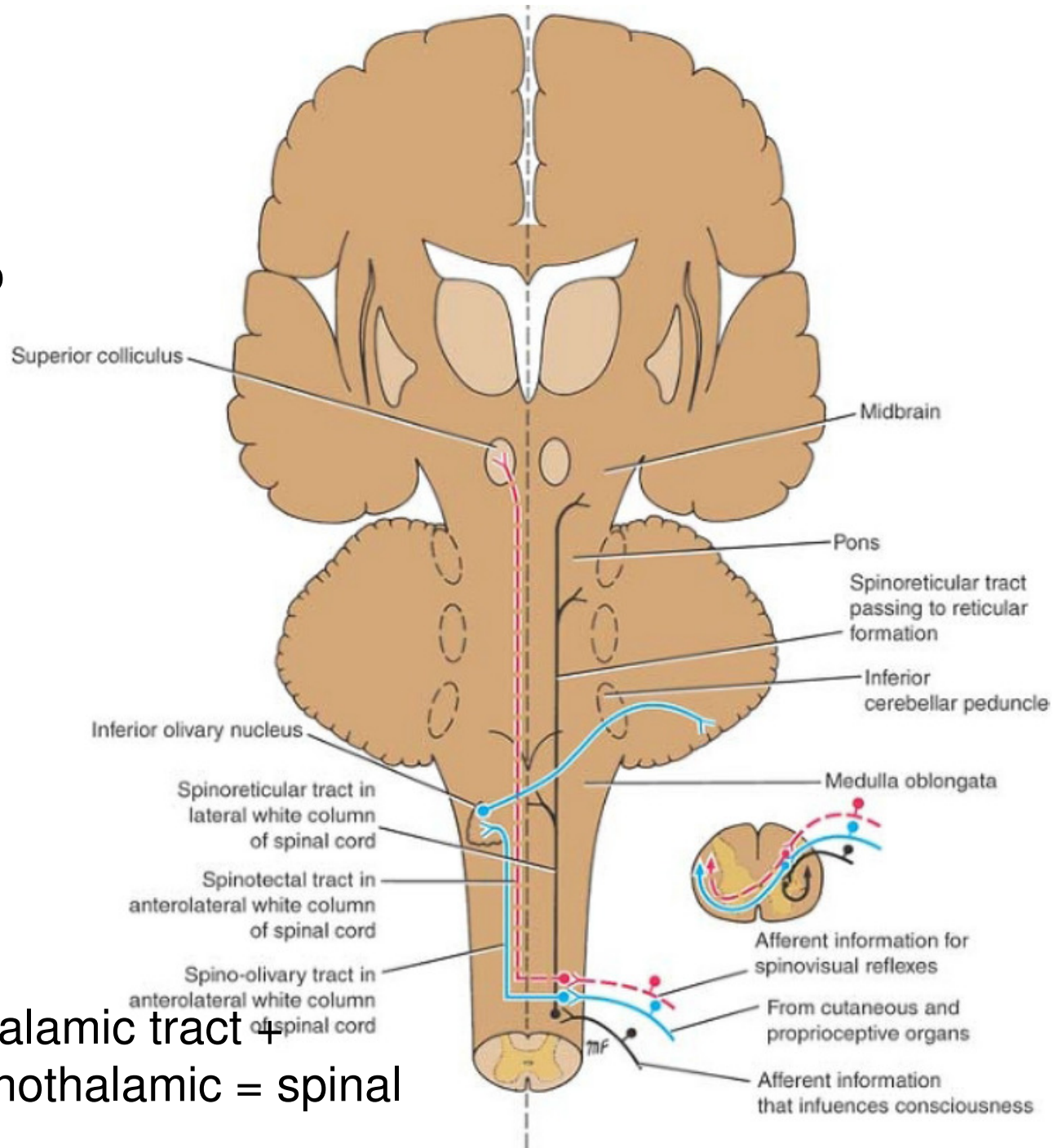
Anterior spinothalamic tract

- Modality: crude touch and pressure
- Receptors: free nerve endings
- 1st Neuron: Dorsal root ganglia
- 2nd Neuron: the posterior gray column (**nucleus proprius**)
The axons of 2nd order neurons cross obliquely to the opposite side in the anterior gray and white commissures, ascending in the contralateral white column as the Anterior spinothalamic tract
- 3rd Neuron: Thalamus (VPL)
Internal Capsule ----- Corona Radiata
- Termination: Primary Somesthetic Area (S I)



Spinotectal Tract

- ascend in the anterolateral white column lying close to the lateral spinothalamic tract
- Terminate: superior colliculus
- Provides afferent information for spinovisual reflexes

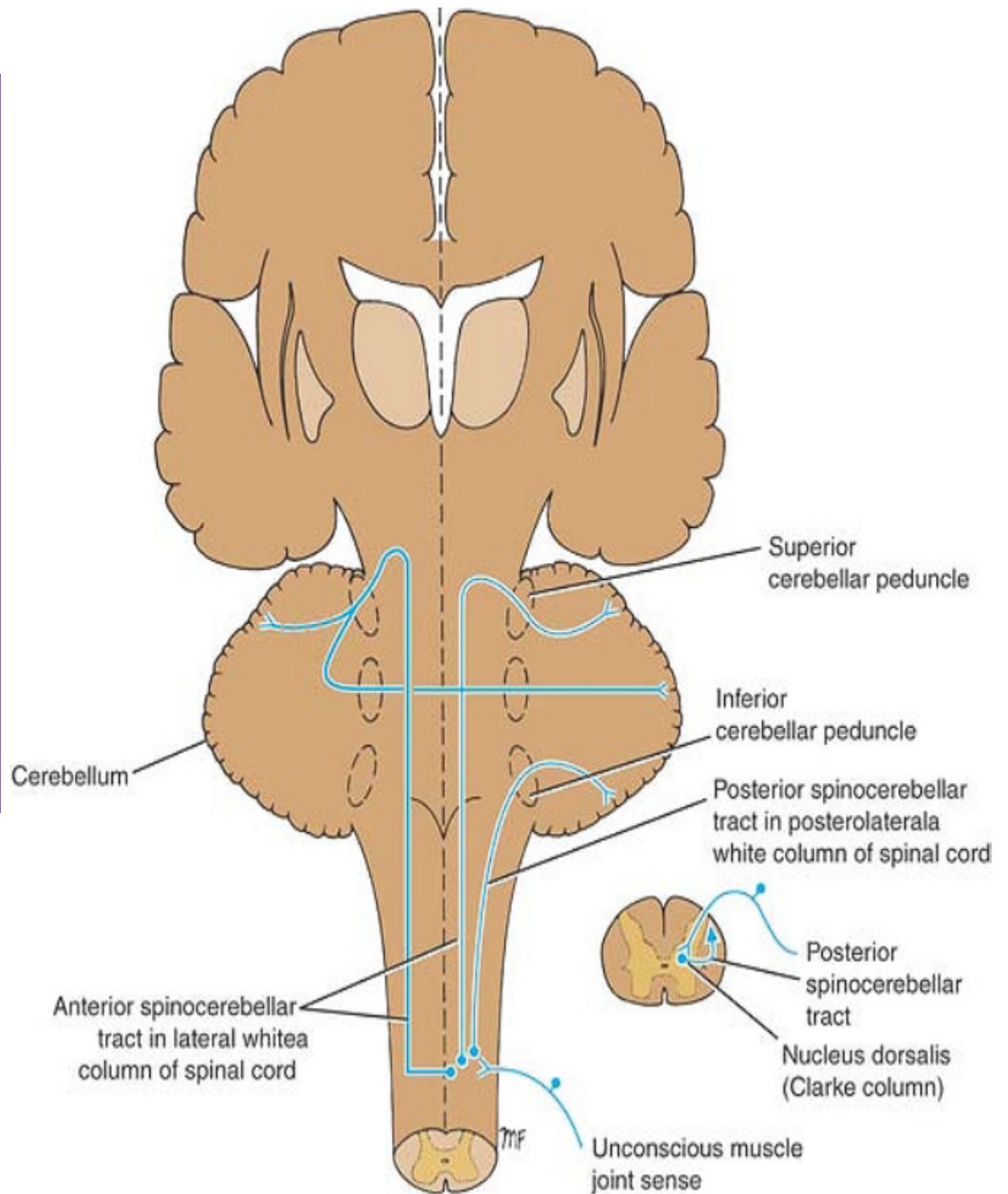


In Medulla: ant spinothalamic tract + spinotectal + lateral spinothalamic = spinal lemniscus

Posterior spinocerebellar

- muscle and joint sensation
- 1st order neuron axons terminate at the base of post gray column (nucleus dorsalis or **Clarke's nucleus**)
- the axons of 2nd order neurons enter posterolateral part of the lateral white matter on the **same side**
- ascend as the posterior spinocerebellar tract to medulla oblongata
- Terminates in cerebellar cortex (through inferior cerebellar peduncle)

➤ *note: axons of lower lumbar and sacral spinal nerves ascend in the posterior white column until they reach L3 or L4 segments where they synapse with nucleus dorsalis*



Rexed laminae

- **Lamina 1** relay information related to pain and temperature
- **Lamina 2:** relay information related to pain and temperature (**pain modulation**)
- **Lamina 3 and 4:** nucleus proprius; these laminae have many interneurons

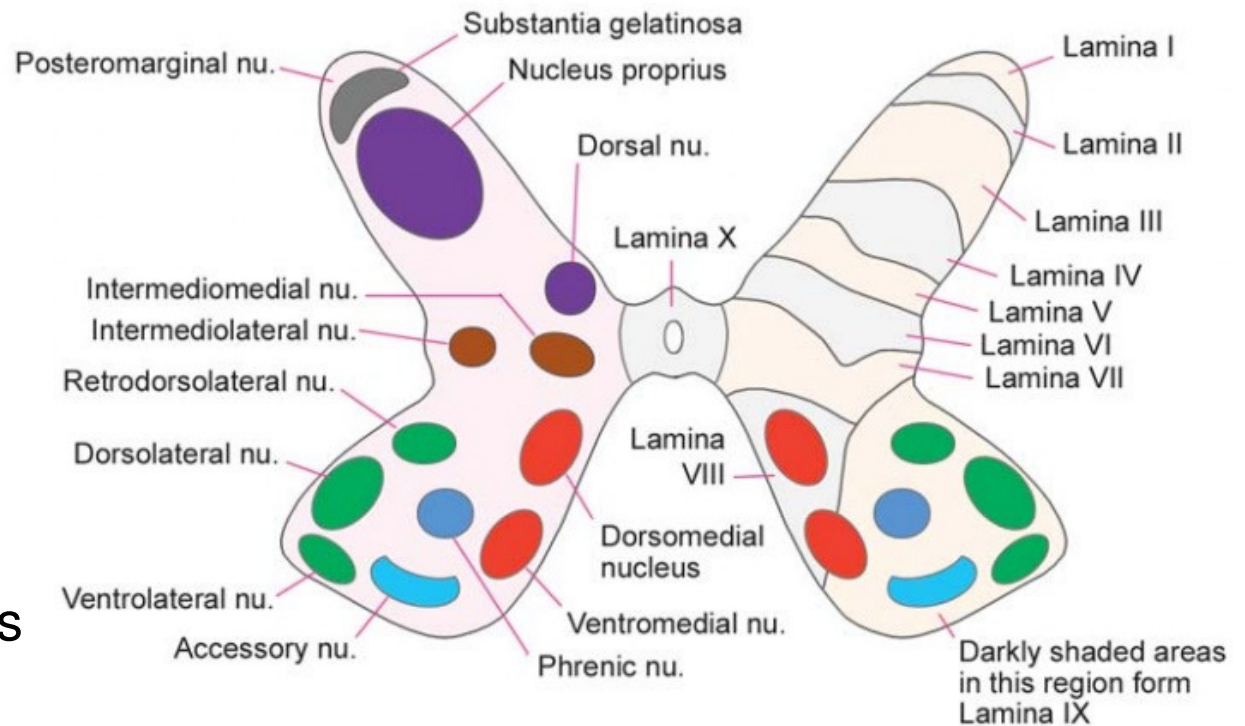
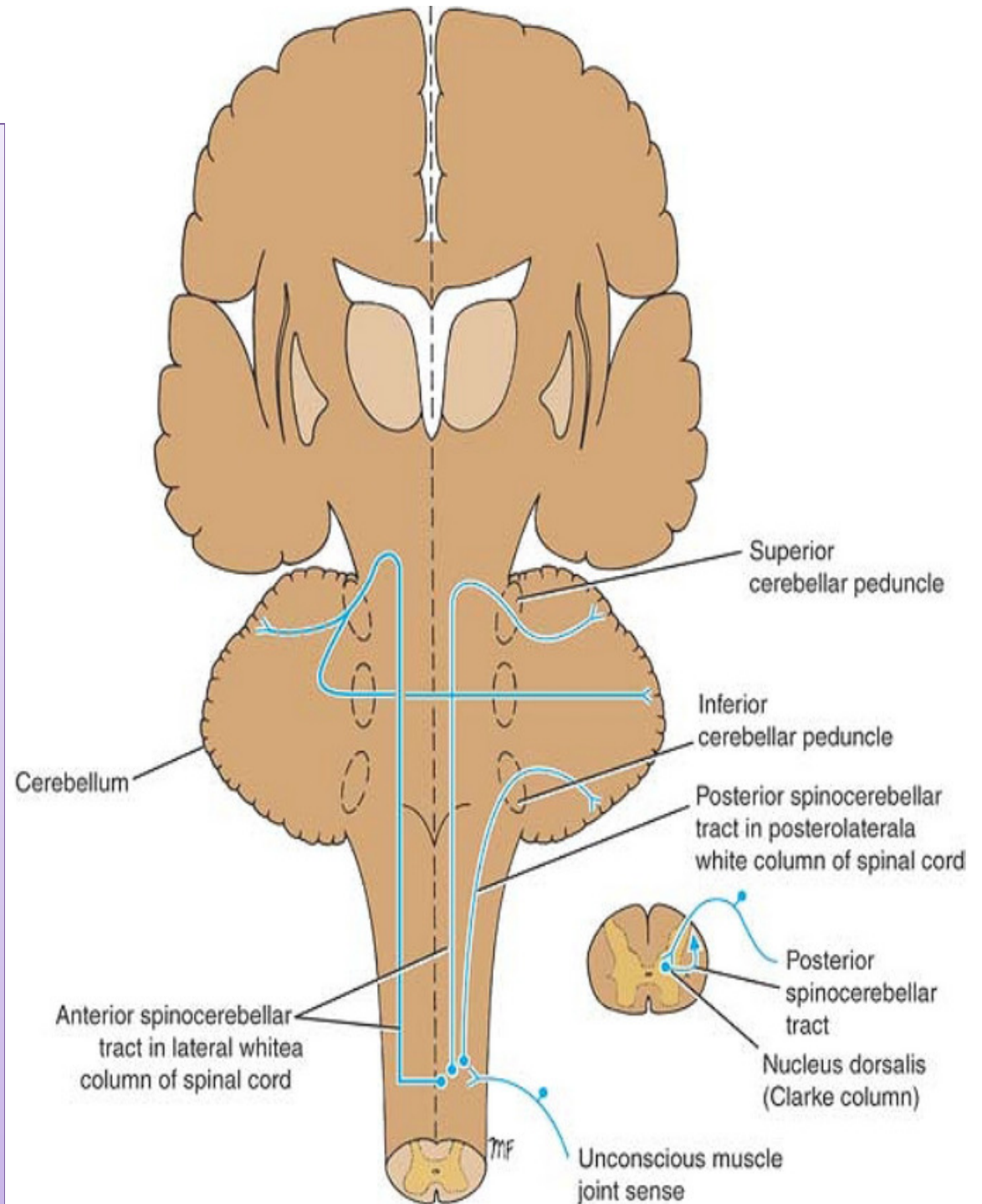


Fig. 5.2. Subdivisions of the grey matter of the spinal cord. The left half of the figure shows the cell groups usually described. The right half shows the newer concept of laminae.

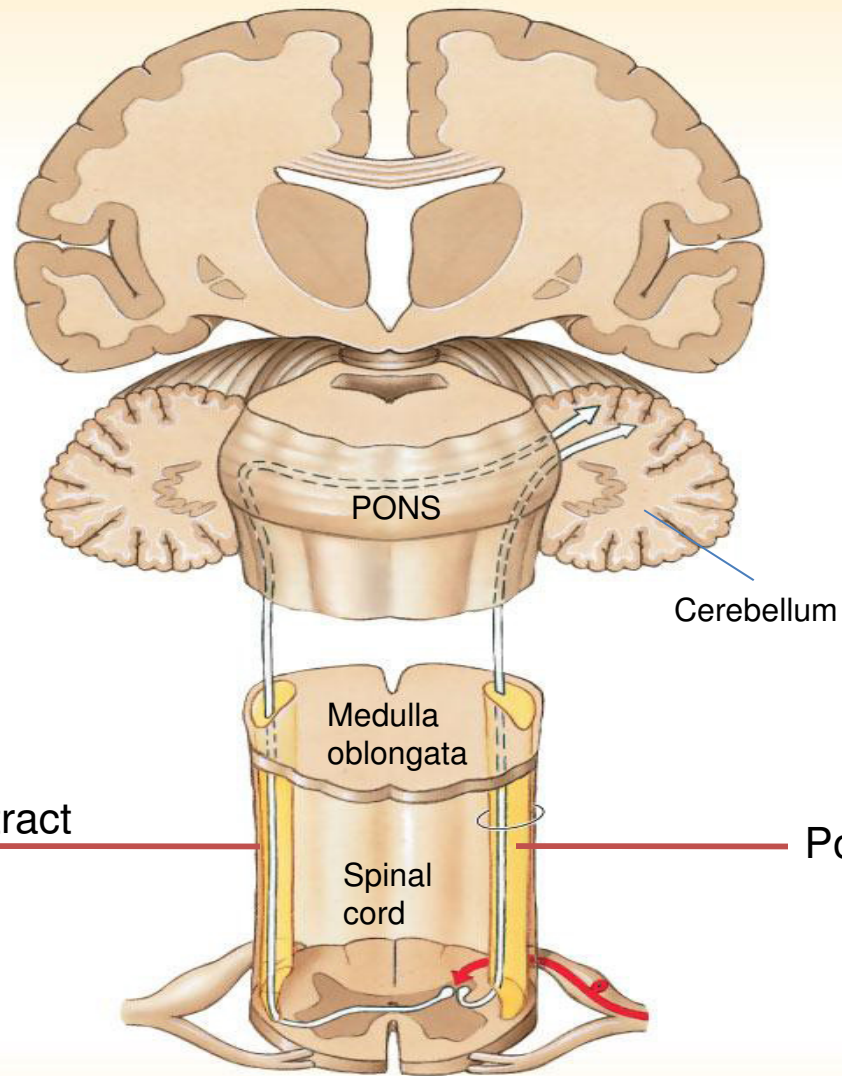
- **Lamina 5:** relay information related to pain and temperature
- **Lamina 6:** presents only at the cervical and lumbar enlargements and receives proprioception
- **Lamina 7: Intermedio-lateral** nucleus, contains preganglionic fibers of sympathetic (T1 -L2). **Intermedio-medial nucleus**, all over the spinal cord, receive visceral pain. **Dorsal nucleus of Clark's** presents at (C8 – L2 or T1-L4), relay center for **unconscious proprioception**

Anterior spinocerebellar tract

- muscle and joint sensation
- 1st order neuron axons terminate at the base of post gray column (nucleus dorsalis)
- the majority of axons of 2nd order neurons cross to opposite side and ascend as anterior spinocerebellar tract in the contralateral white column
 - *the minority of axons ascend as anterior spinocerebellar tract in the lateral white column of the same side*
- ascend as anterior spinocerebellar tract to medulla oblongata and pons
- Terminates in cerebellar cortex (through superior cerebellar peduncle)
- *the fibers that **crossed over** in spinal cord **cross back** within cerebellum*



Spinocerebellar Tracts



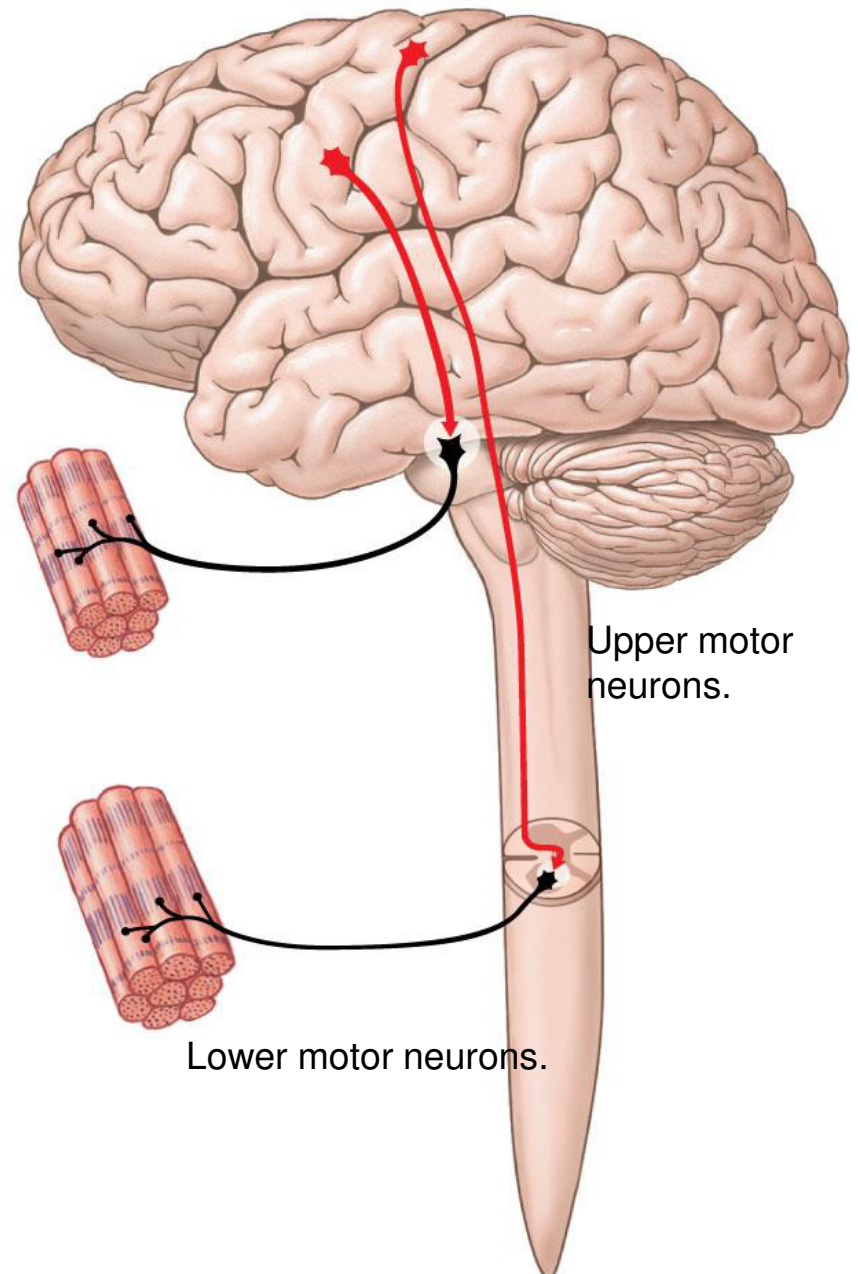
Anterior spinocerebellar tract

Posterior spinocerebellar tract

Proprioceptive input from Golgi tendon organs, muscle spindles, and joint capsules

Motor tracts

- ❑ There are two major descending tracts
- **Pyramidal tracts** (Corticospinal) : Conscious control of skeletal muscles
- **Extrapyramidal:** Subconscious regulation of balance, muscle tone, eye, hand, and upper limb position:
- ❖ **Vestibulospinal tracts**
- ❖ **Reticulospinal tracts**
- ❖ **Rubrospinal tracts**
- ❖ **Tectospinal tracts**



Extrapyramidal tracts arise in the brainstem, but are under the influence of the cerebral cortex

Rexed laminae

- **Lamina 8:** motor interneurons, Commissural nucleus
- **Lamina 9:** ventral horn, LMN, divided into nuclei:
 - **Ventromedial:** all segments (extensors of vertebral column)
 - **Dorsomedial:** (T1-L2) intercostals and abdominal muscles
 - **Ventrolateral:** C5-C8 (arm) L2-S2 (thigh)
 - **Dorsolateral:** C5-C8 (Forearm), L3-S3 (Leg)
 - **Reterodorsolateral:** C8-T1 (Hand), S1-S2 (foot)
 - **Central:** Phrenic nerve (C3-C5)
- **Lamina X:** Surrounds the central canal – the grey commissure

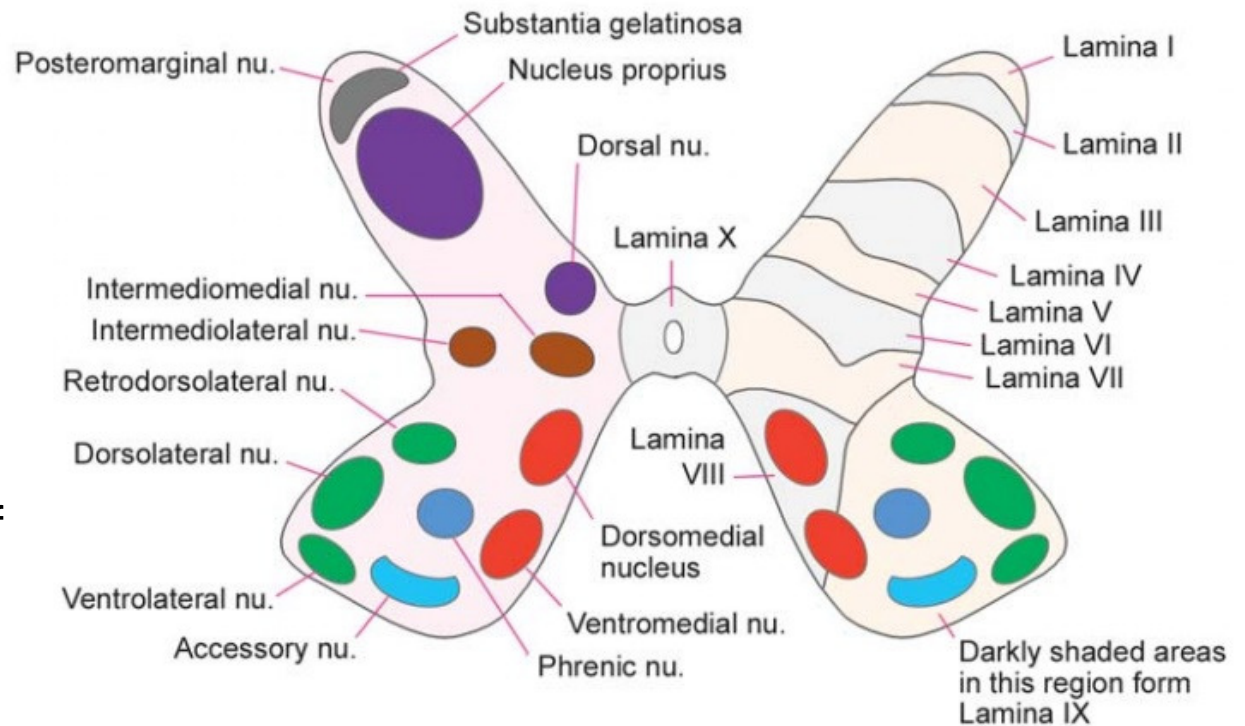
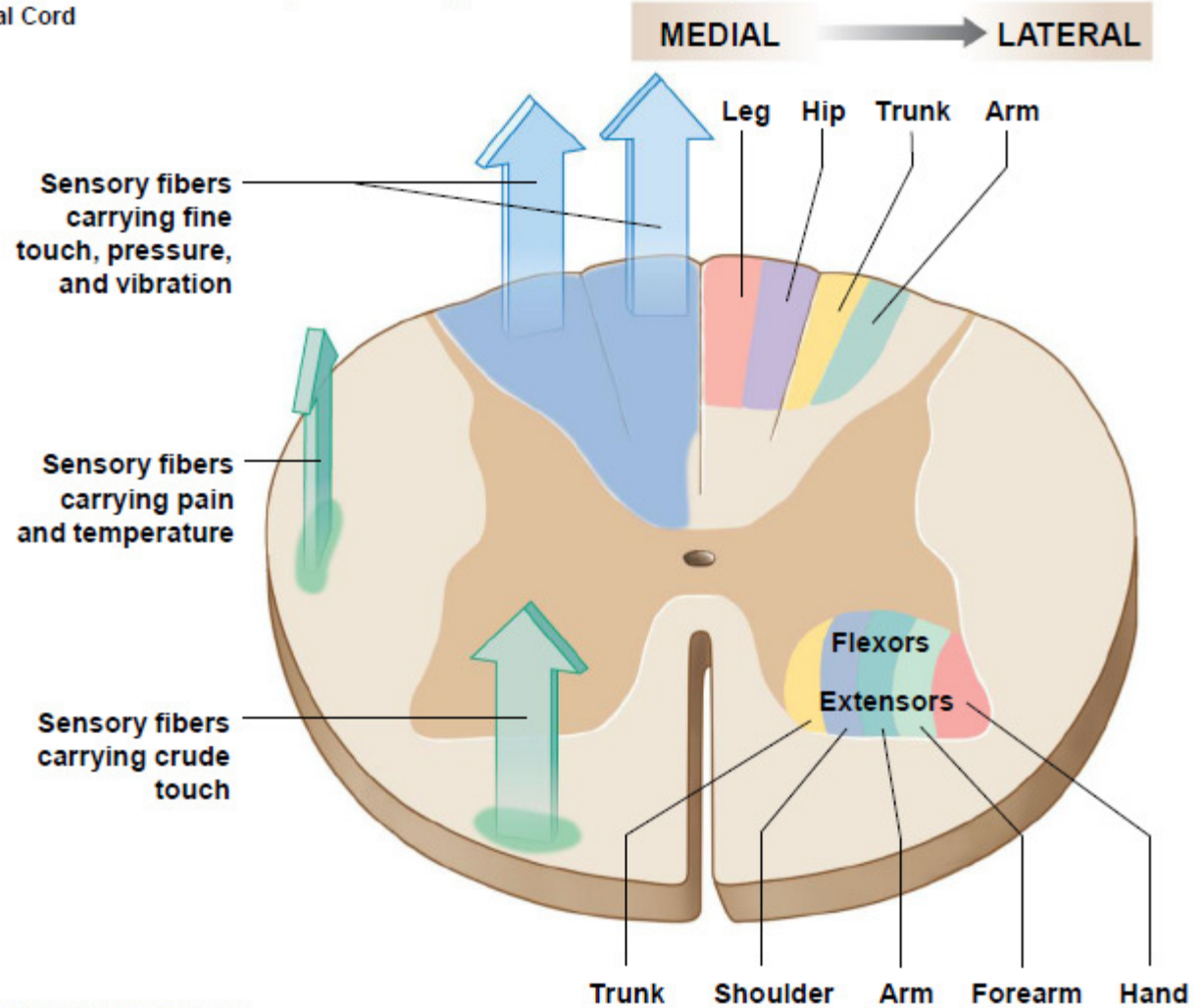


Fig. 5.2. Subdivisions of the grey matter of the spinal cord. The left half of the figure shows the cell groups usually described. The right half shows the newer concept of laminae.

Figure 15.1 Anatomical Principles for the Organization of the Sensory Tracts and Lower-Motor Neurons in the Spinal Cord



© 2012 Pearson Education, Inc.

- ❑ Motor neurons of anterior horn
- **Medial group:** (All segments)
- **Lateral group:** only enlargements

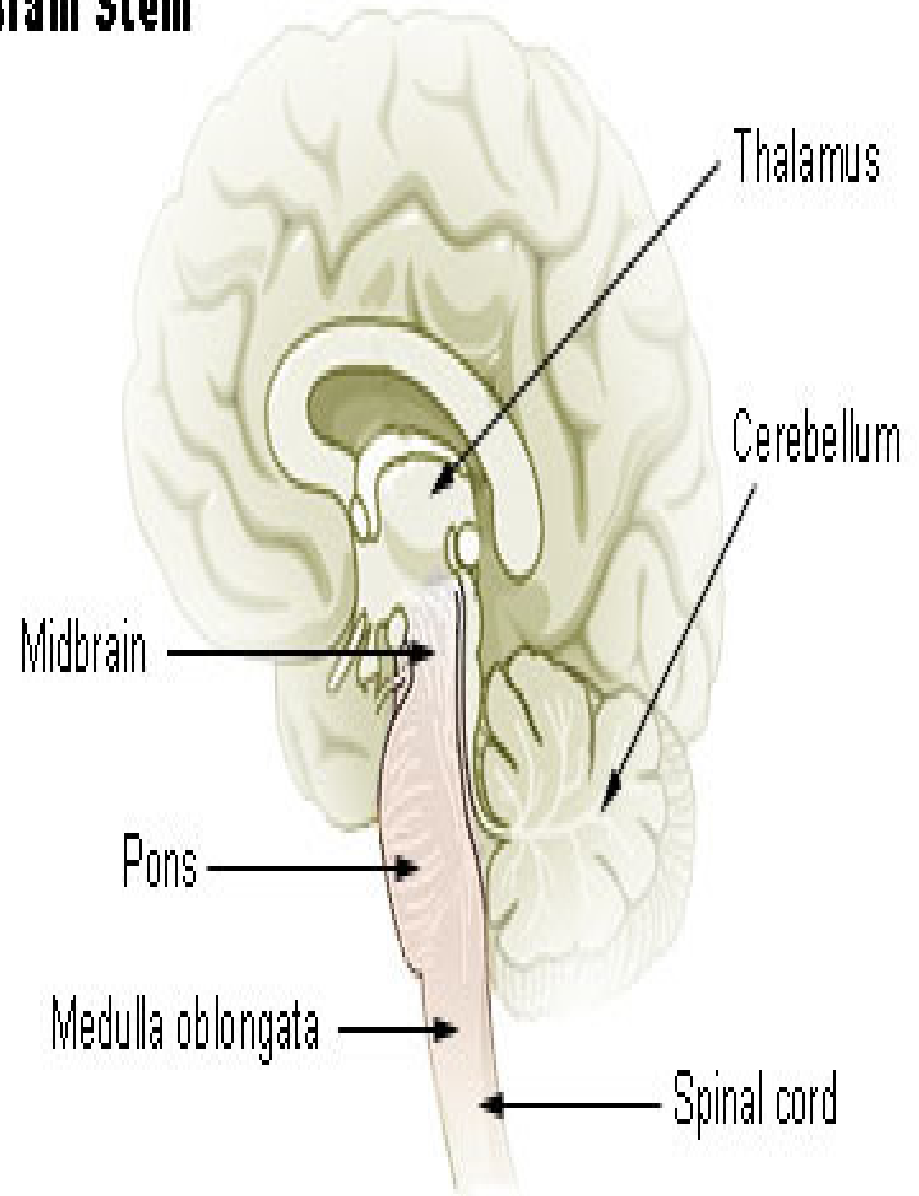
Brain stem

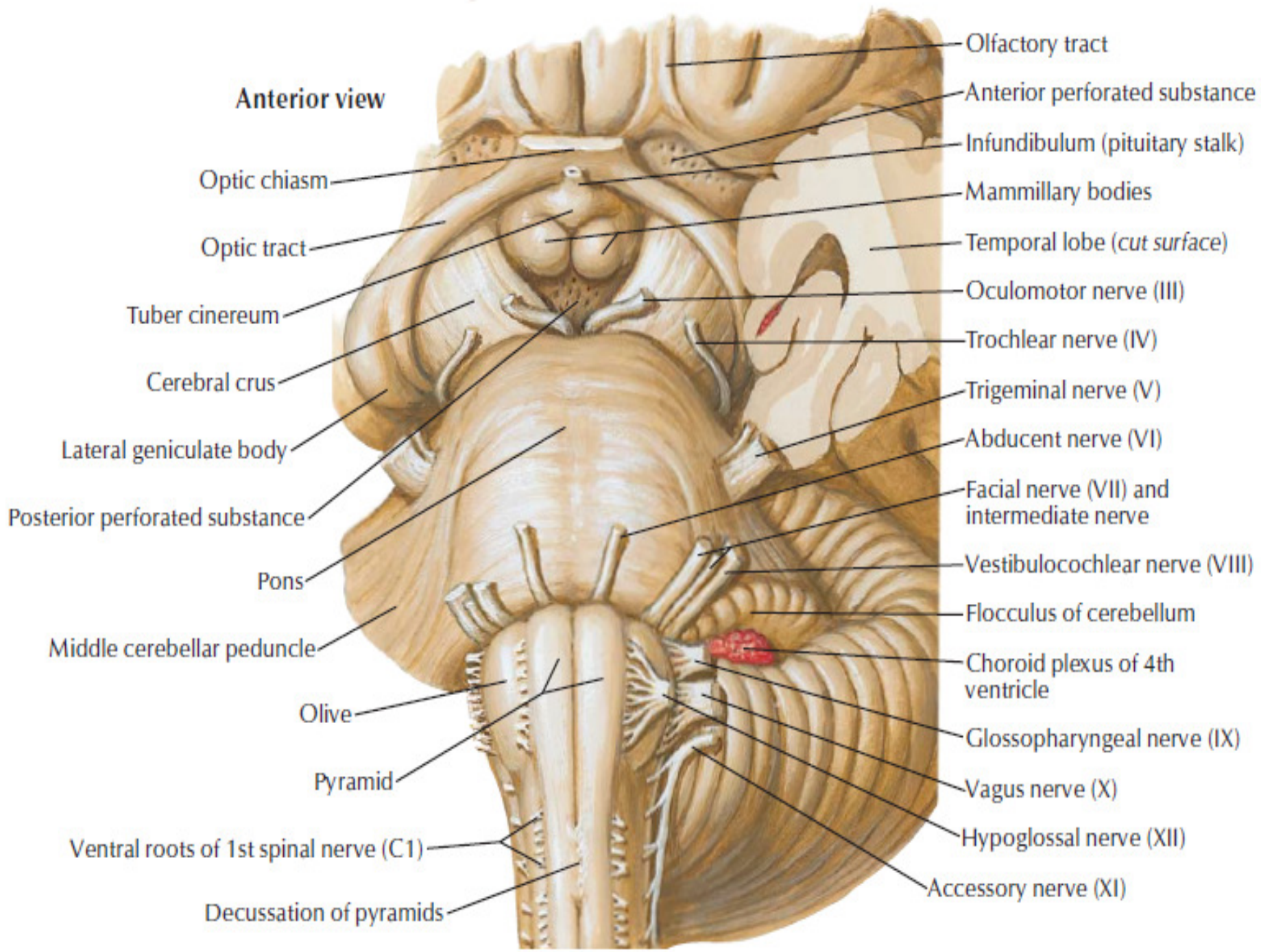
- Stalk like in shape
- Connects spinal cord forebrain

Parts:

1. Medulla oblongata
2. Pons
3. Midbrain

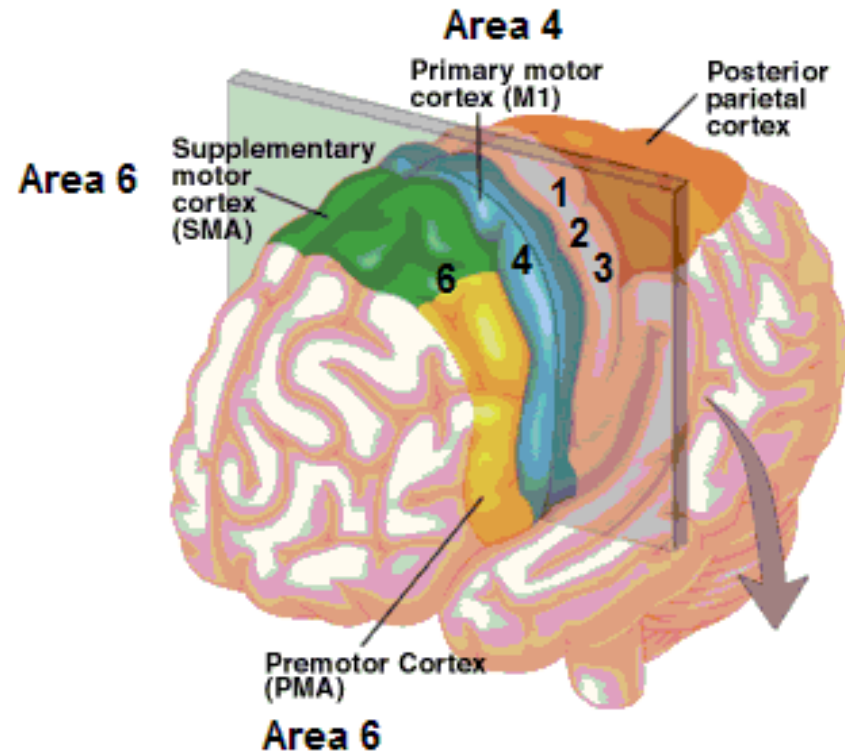
Brain Stem





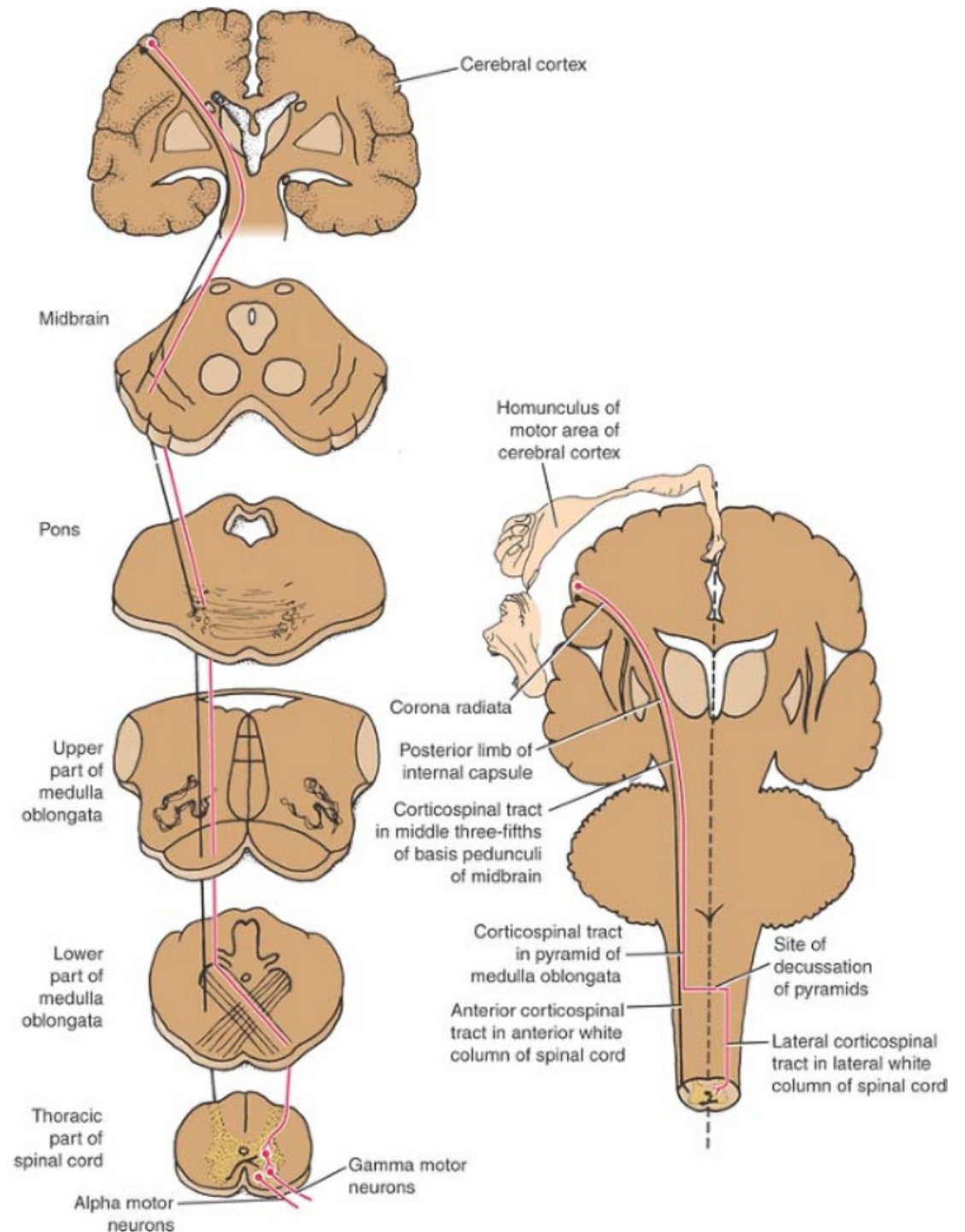
Motor tracts

- ❑ Both pyramidal tracts and extrapyramidal both starts from cortex:
 - Area 4
 - Area 6
 - Area 312
- ❖ Pyramidal: mainly from area 4
- ❖ Extrapyramidal: mainly from area 6
 - ❑ area 6
 - **Premotor area:** uses external cues
 - **Suplemantary motor area:** uses internal cues

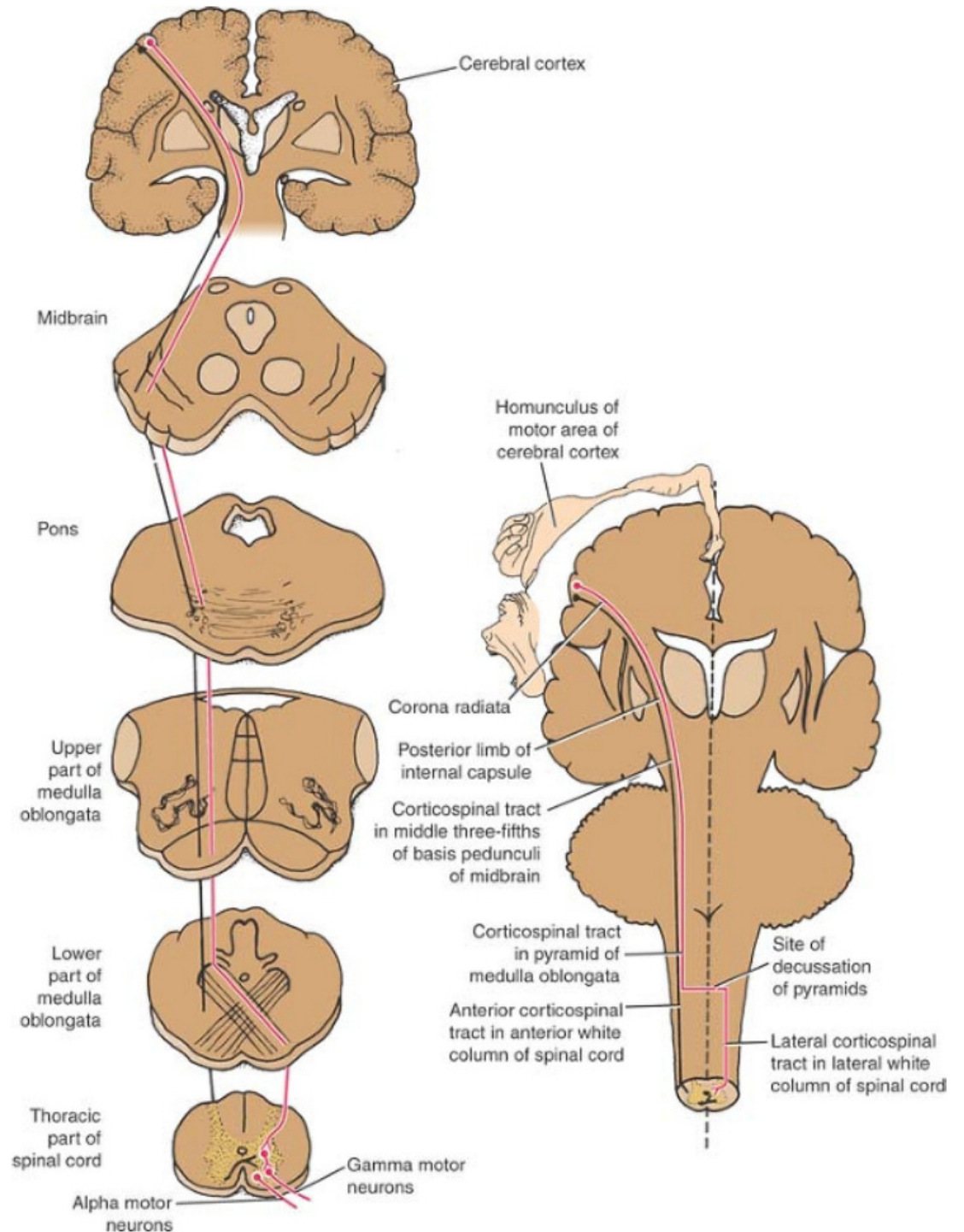


Lateral corticospinal tract

- The upper motor neurons of these tracts originate in the precentral gyrus of the cerebral cortex
- In midbrain: middle three-fifths of the **basis pedunculi of the midbrain**
- In medulla oblongata: pyramids
- Most of the fibers (85 percent) cross over (decussate) to the opposite side in the pyramidal decussation, where they continue to descend in the **lateral funiculus** of the spinal cord as the **lateral corticospinal tract (LCST)**.

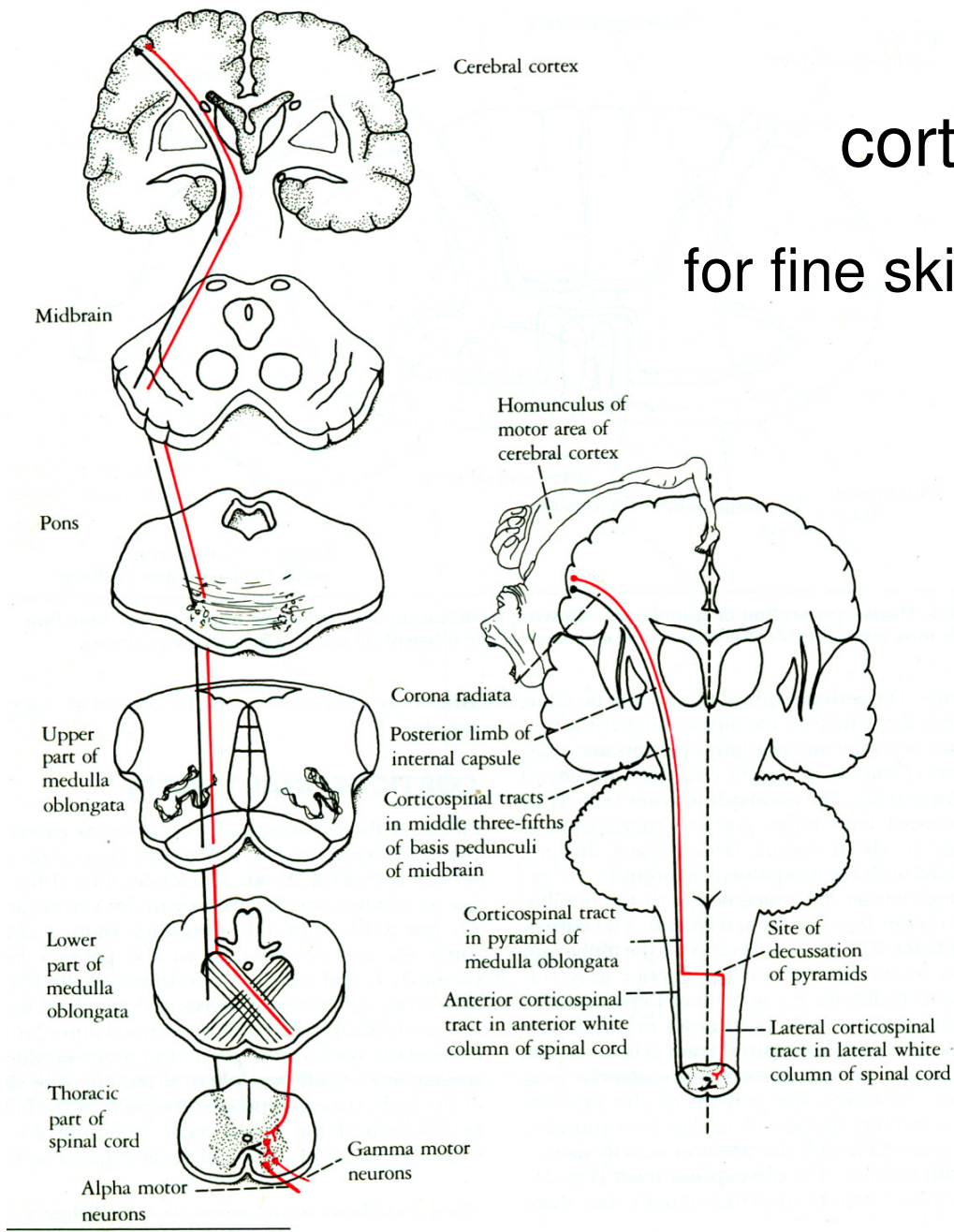


- The tract descends all the way of spinal cord with fibers continually leaving it in order to synapse on interneurons in the anterior gray horn. (Some even synapse directly on alpha and gamma motor neurons)
- *Those corticospinal fibers which do not decussate in the medulla continue descending on the same (ipsilateral) side of the cord and become the anterior corticospinal tract (ACST).*



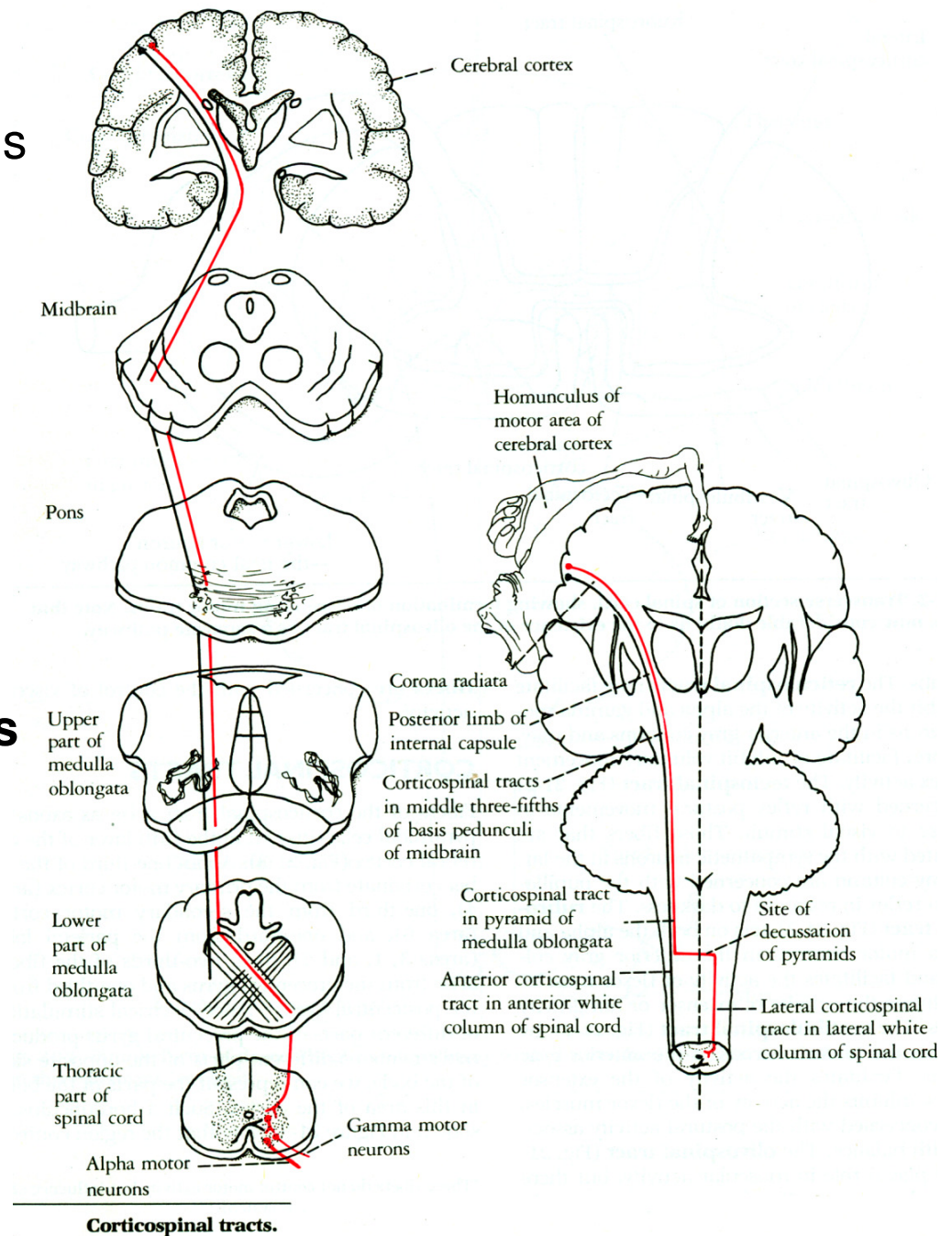
corticospinal tract

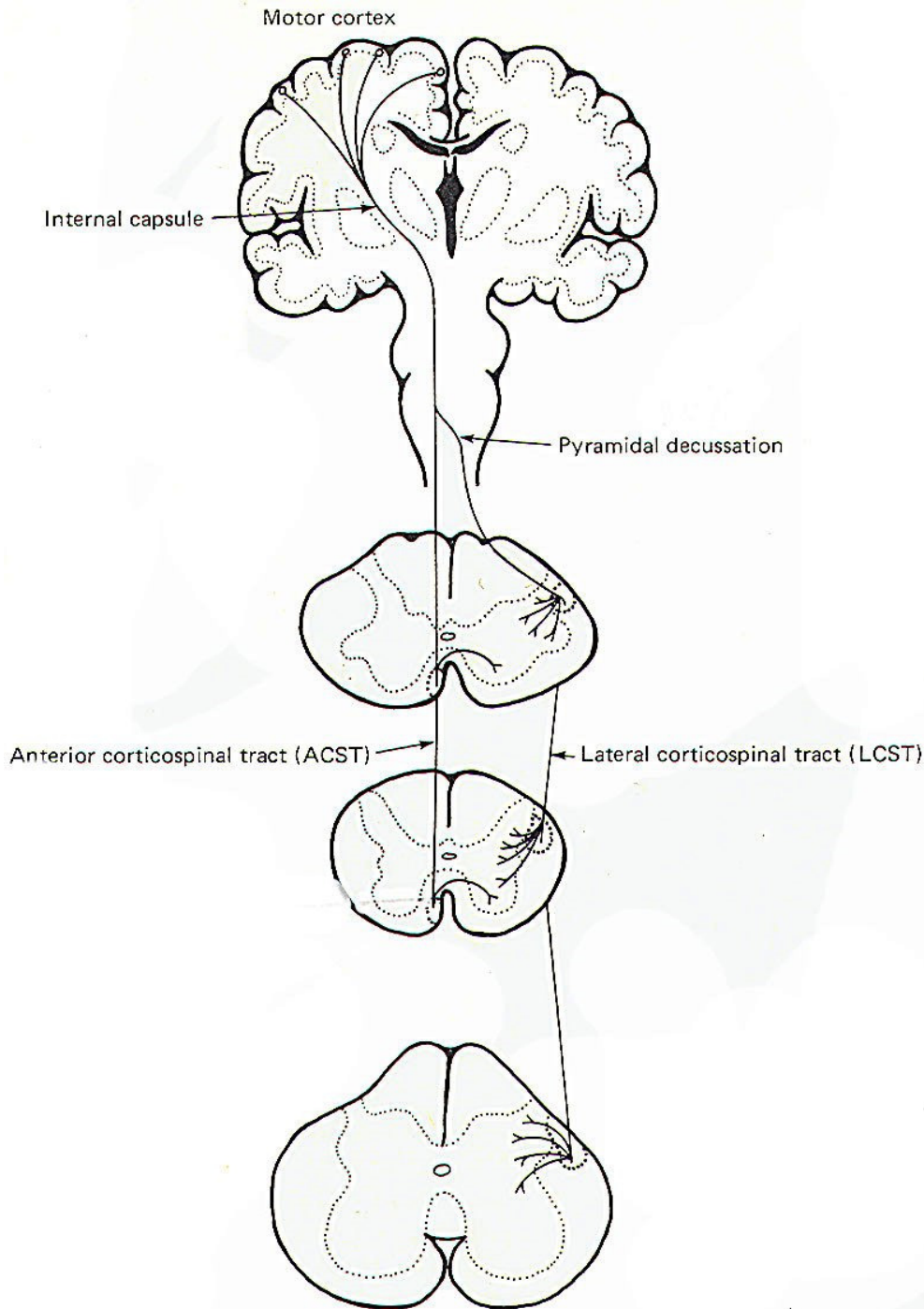
for fine skilled movements



Corticospinal tracts.

- Lateral corticospinal tract descends the full length of the spinal cord
- LCST fibers synapse with alpha and gamma nuclei of the
 - Cervical region (**55%**) (great effect on the upper limb)
 - Thoracic 20%
 - Lumbar and Sacral 25%
- The lateral corticospinal tract synapses **mainly by interneurons** in laminae IV, V, VI, VII, VIII
- **Exception:** 3% originate from the fifth layer of area 4 (giant cells of Betz) synapse directly. (Accurate movements)





The anterior corticospinal tract

acts on the proximal muscles of upper limb (shoulder muscle) of the ipsilateral and contralateral sides

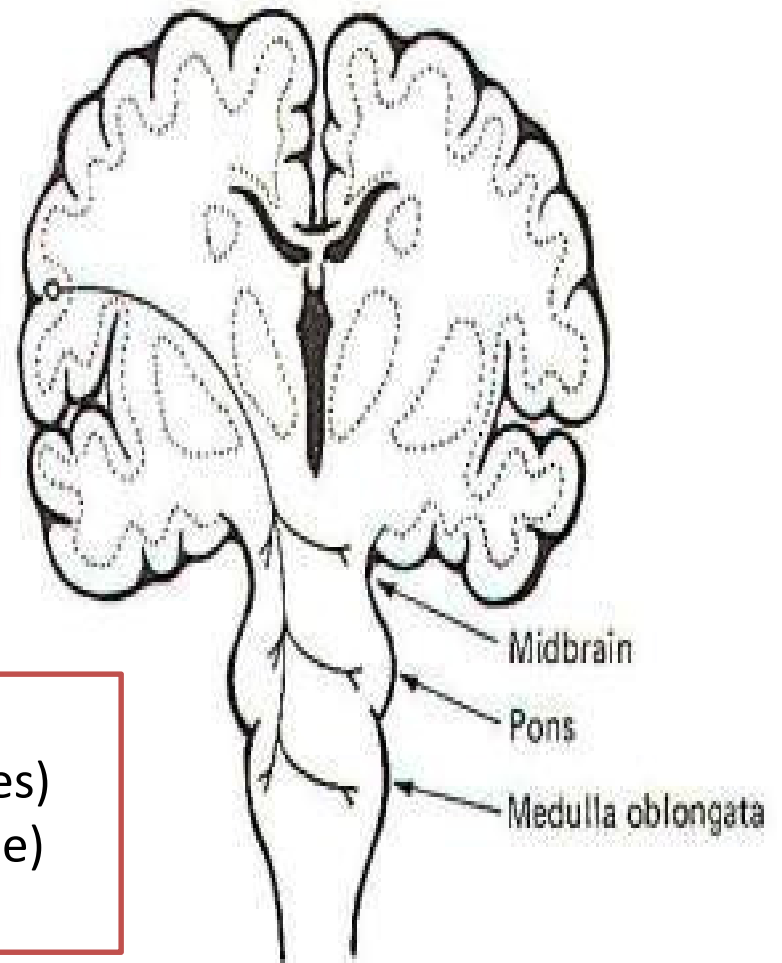
Fibers leave the tract at various levels to cross over in the anterior white commissure to synapse on interneurons in the anterior gray horn.

The Corticoneuclear Tract (fibers)

- This tract is composed of fibers originating in the precentral gyrus of the lower quarter of the motor cortex.
- The descending fibers terminate in the motor nuclei of cranial nerves III and IV in the midbrain; V, VI, and VII in the pons; and IX, X, XI, and XII in the medulla.
- The corticobulbar fibers from one side of the brain project to the motor nuclei on both sides of the brainstem (bilateral input)

The corticoneuclear input is bilateral **Except** :

- 1- Part of 7th (which supplies LOWER facial muscles)
- 2- Part of 12th (which supplies genioglossus muscle)



The Subconscious Motor Tracts

- Consists of four tracts involved in monitoring the subconscious motor control
- **Vestibulospinal tracts**
- **Tectospinal tracts**
- **Reticulospinal tracts**
- **Rubrospinal tracts**

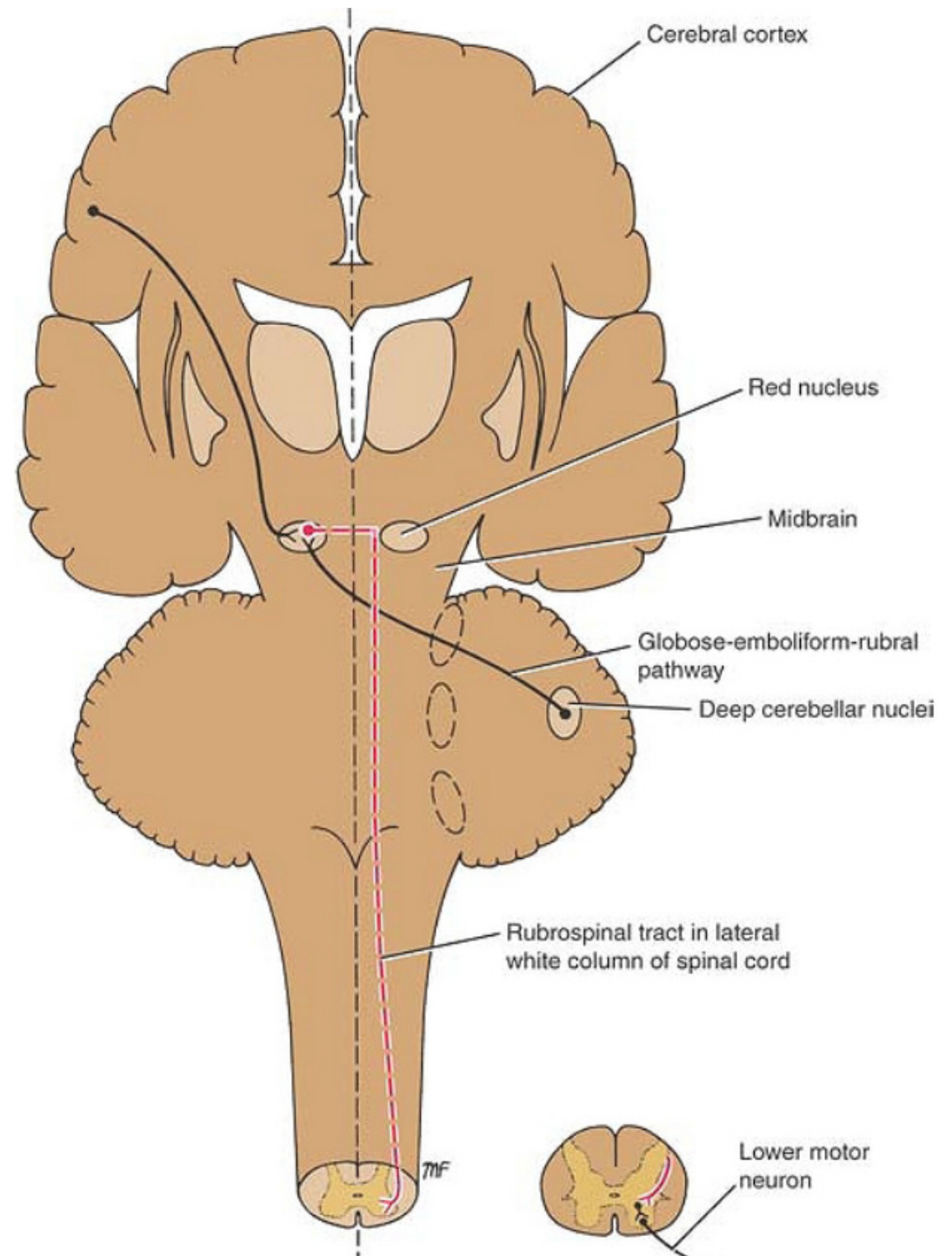
Extrapyramidal tracts arise in the brainstem, but are under the influence of the cerebral cortex

These motor pathways are complex and multisynaptic, and regulate:

- Axial muscles that maintain balance and posture
- Muscles controlling coarse movements of the proximal portions of limbs
- Head, neck, and eye movement

Rubrospinal tract

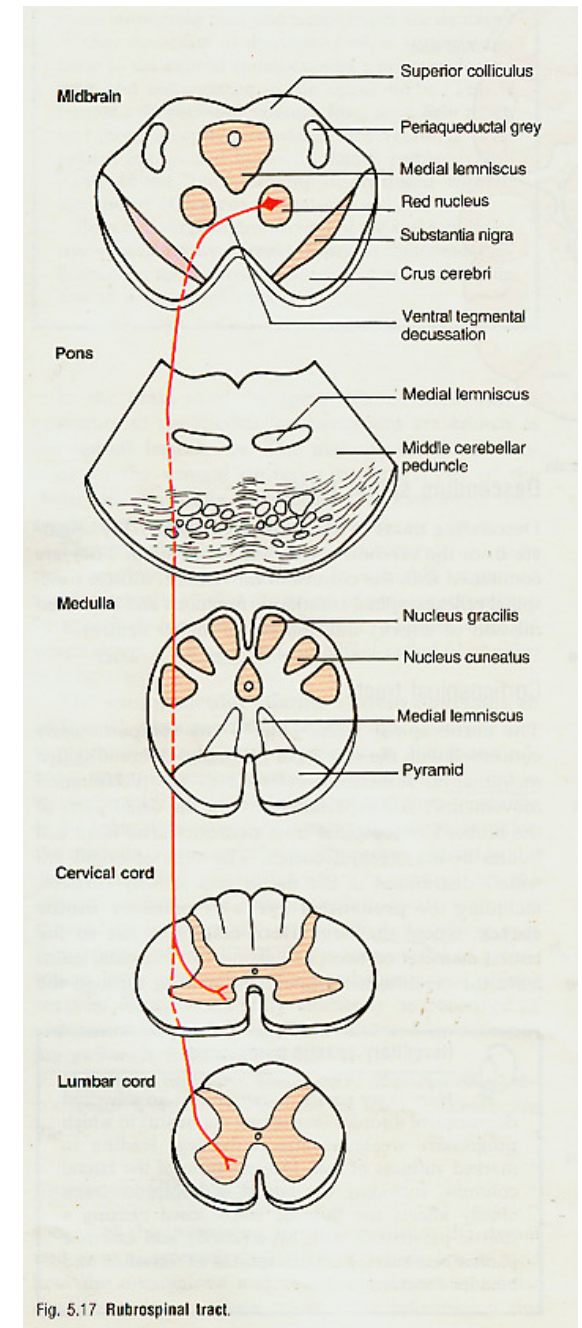
- **Red nucleus**
 - In the midbrain at the level of superior colliculus
 - Receives afferent fibers from cerebral cortex and the cerebellum
- **Crossed** (at the level of the nucleus)
- Lateral white column
- **Function:**
 - facilitate the activity of flexors and inhibit the activity of extensors



Rubrospinal tract

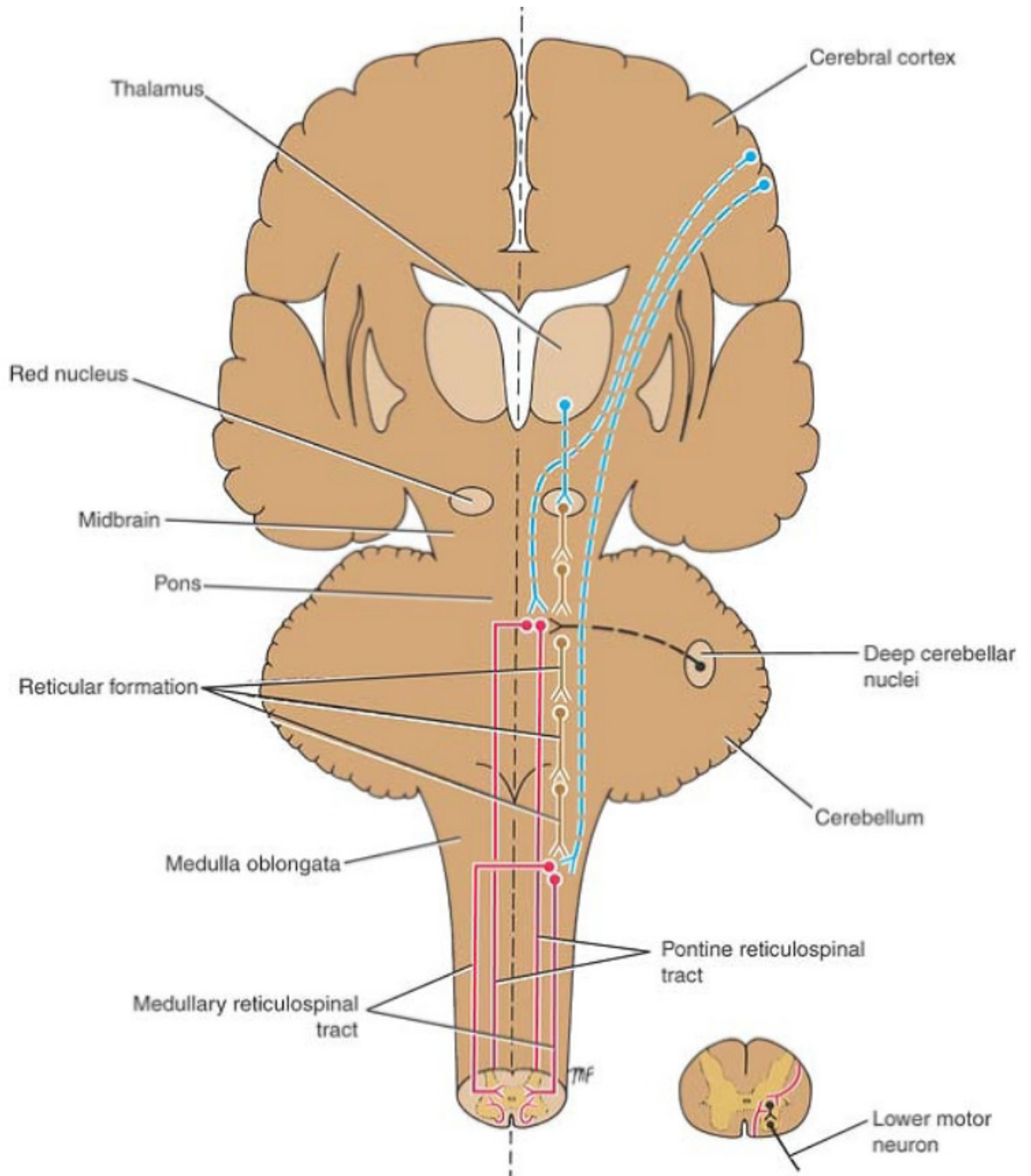
- rubrospinal tract is very close to the lateral corticospinal tract in the spinal cord. They form the **lateral motor system**
- synapses with alpha and gamma through interneurons
- Excitatory to flexors and inhibitory to extensors
- supply the distal flexors muscles mainly with little effect on the proximal muscles

(facilitate the activity of flexor muscles)



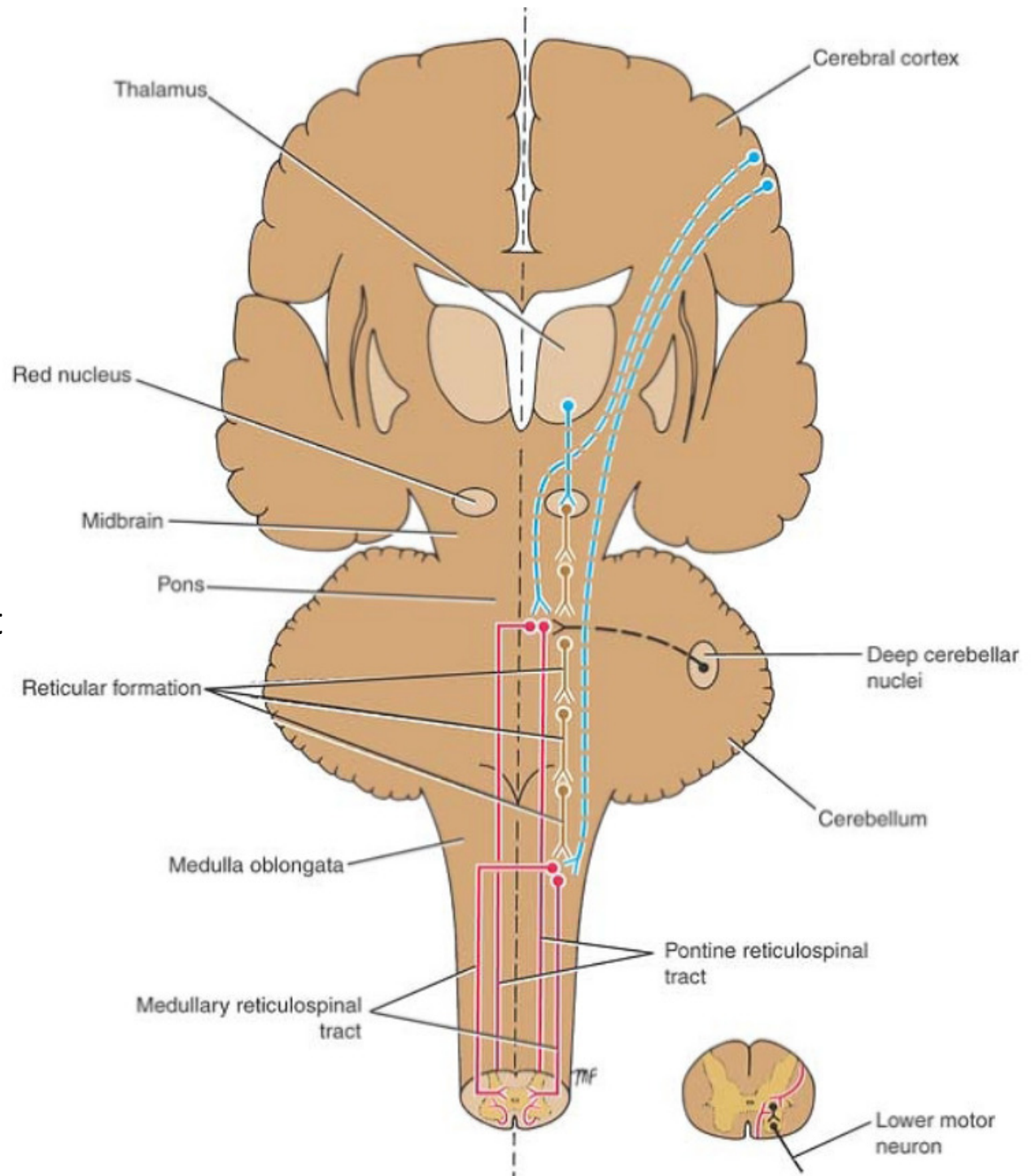
Pontine reticulospinal tract

- From pons:
- axons of RF neurons descend **uncrossed** into the spinal cord
- Anterior white column
- medial reticulospinal tract (MRST)
- **tonically active**
- normally under **inhibition from cortex**
- **Function:**
- activate the axial and proximal limb extensors



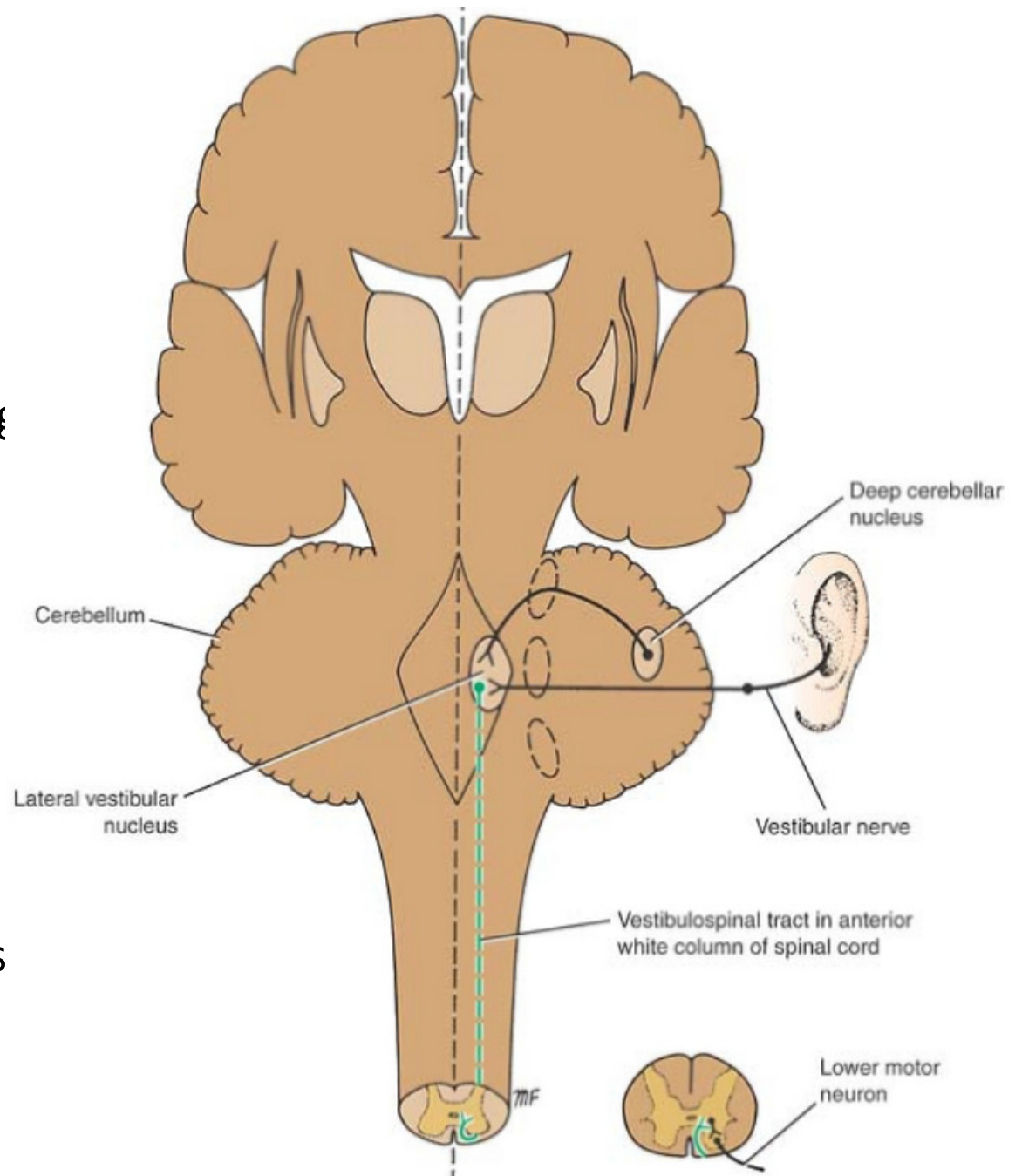
Medullary reticulospinal tracts

- From medulla
- axons of RF neurons descend **crossed and uncrossed** into the spinal cord
- Lateral white column
- Lateral reticulospinal tract (LRST)
- NOT tonically active
- normally under **stimulation**
- **Function:**
Inhibit the axial and proximal limb extensors



Vestibulospinal Tract

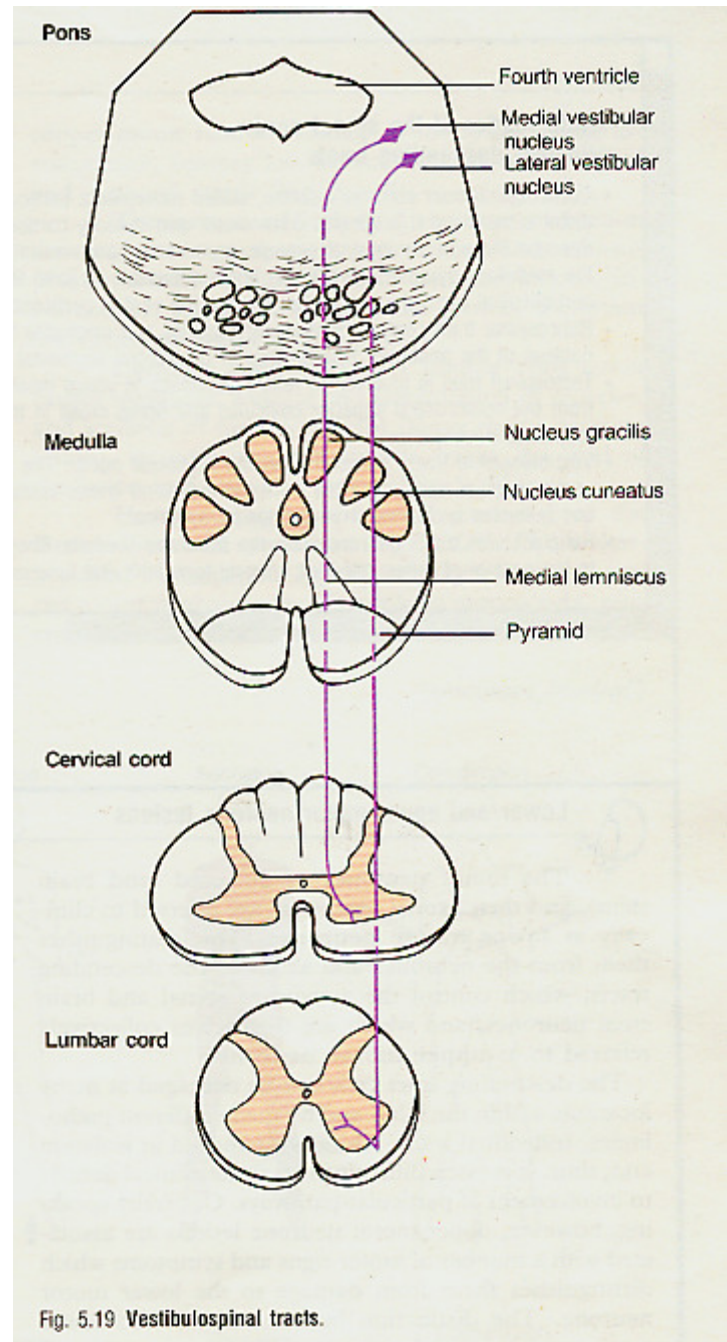
- **Vestibular nuclei**
 - in the pons and medulla beneath the floor of 4th ventricle
 - Receives afferent fibers from the inner ear through the vestibular nerve and from the cerebellum
- **Uncrossed**
- Anterior white column
- **Function:**
facilitate the activity of extensor muscles and inhibit the activity of flexor muscles association with the maintenance of balance



Vestibulospinal tract

- nerve cells in vestibular nucleus (in the pons and medulla oblongata)
 - received afferents from inner ear and cerebellum
- axons descend uncrossed
 - through medulla and through the length of spinal cord
- synapse with neuron in the anterior gray column of the spinal cord

(balance by facilitate the activity of the extensor muscles)



Motor and descending (efferent) pathways (red)



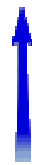Pyramidal tracts

- Lateral corticospinal tract
- Anterior corticospinal tract

Extrapyramidal Tracts

- Rubrospinal tract
- Reticulospinal tracts
- Olivospinal tract
- Vestibulospinal tract

Sensory and ascending (afferent) pathways (blue)



Dorsal Column Medial Lemniscus System

- Gracile fasciculus
- Cuneate fasciculus

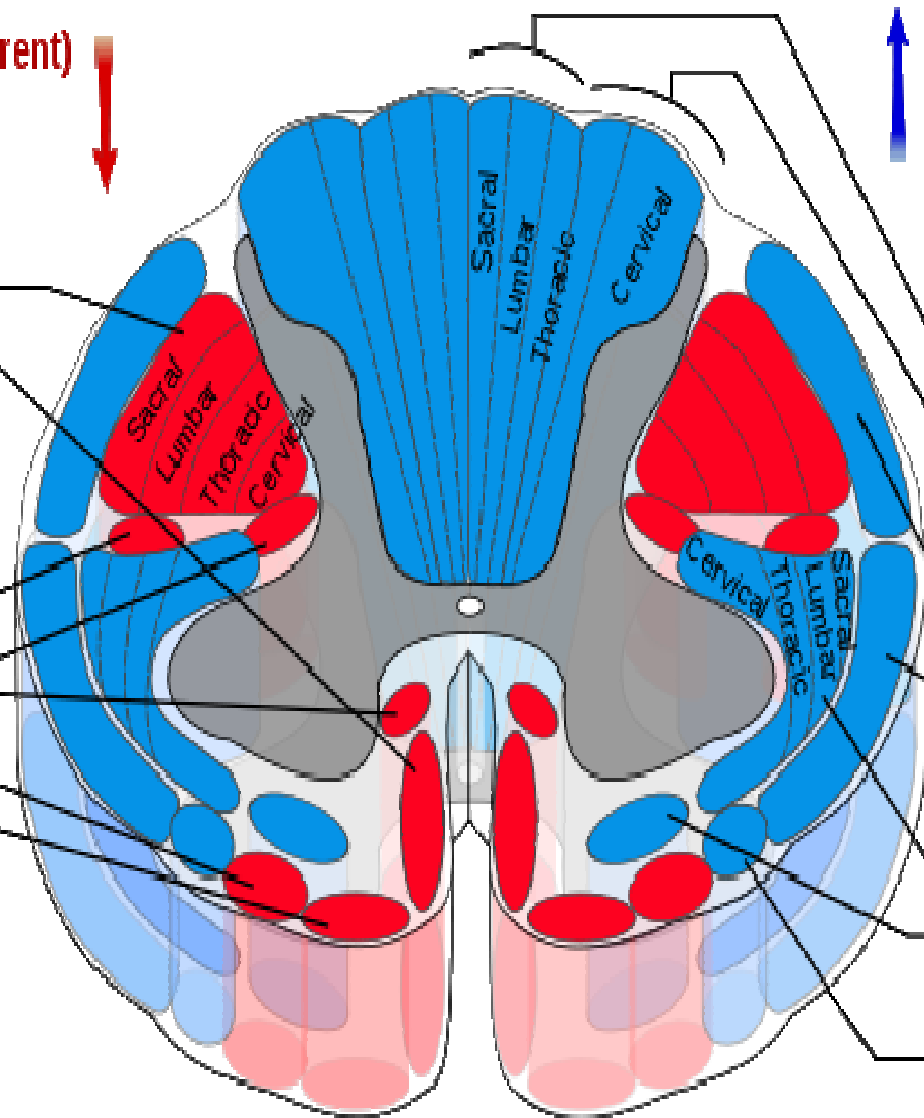
Spinocerebellar Tracts

- Posterior spinocerebellar tract
- Anterior spinocerebellar tract

Anterolateral System

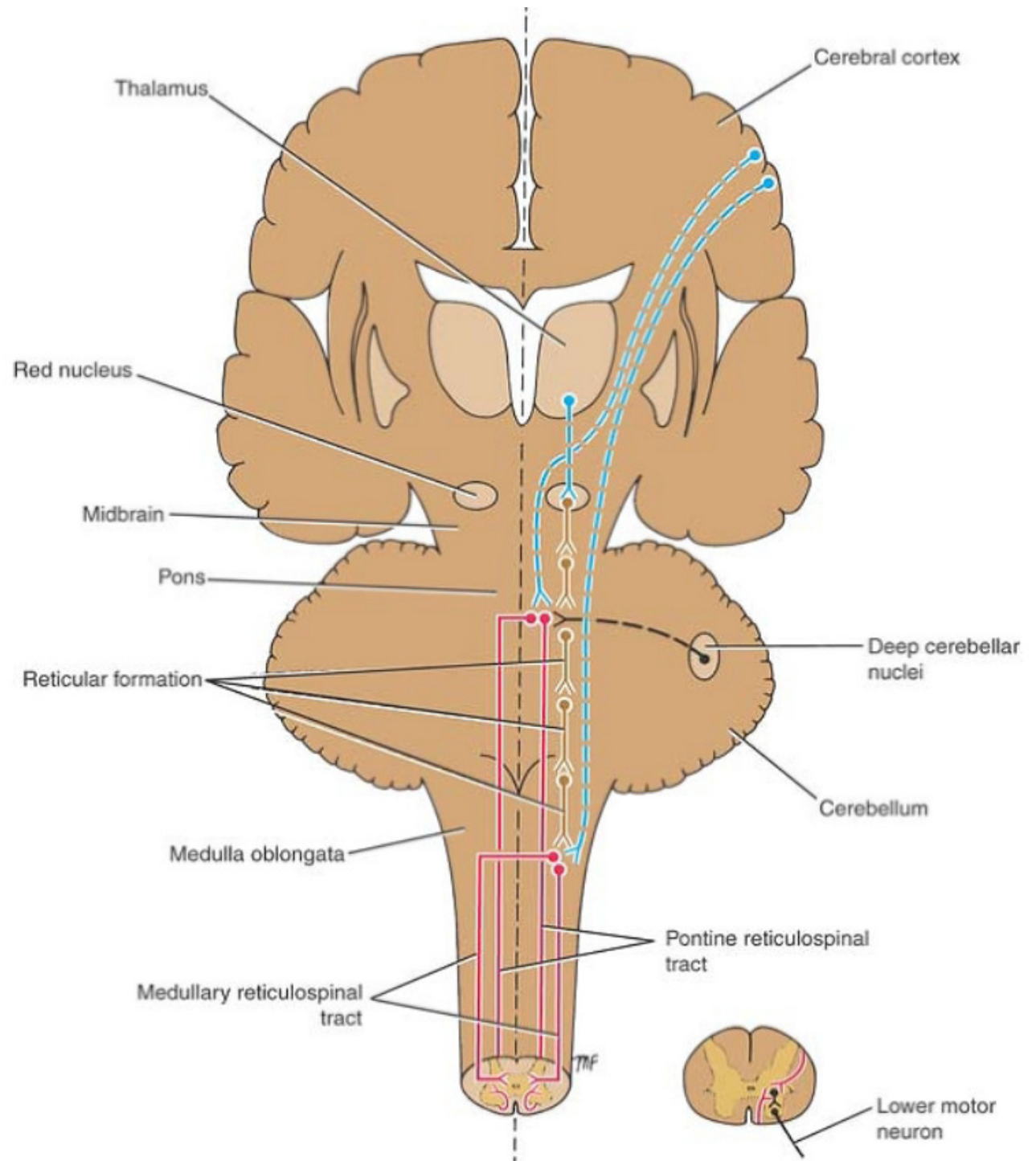
- Lateral spinothalamic tract
- Anterior spinothalamic tract

Spino-olivary fibers



Reticulospinal tracts

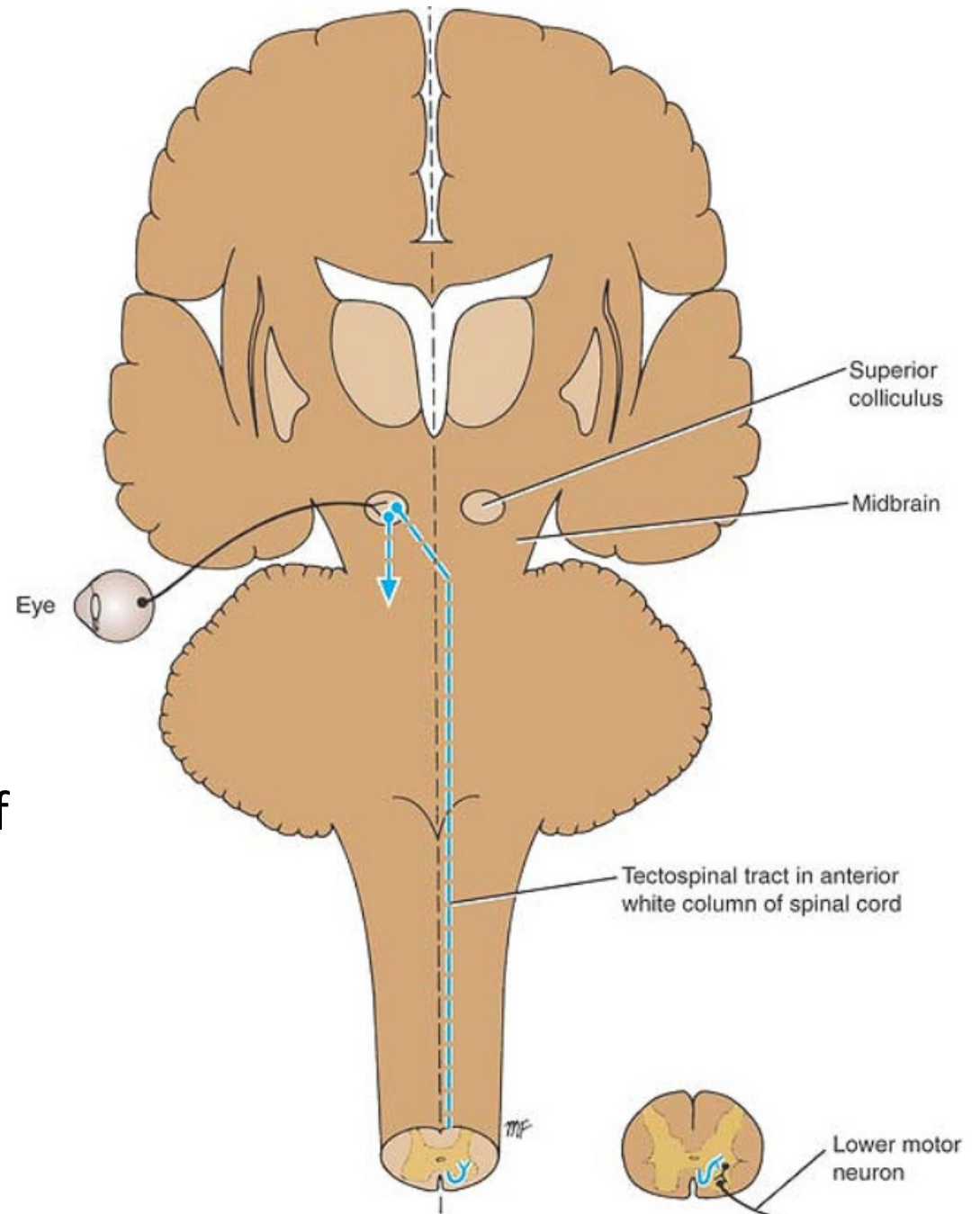
- Has also descending autonomic fibers providing a pathway by which the hypothalamus can control the sympathetic and sacral parasympathetic outflow.
- Most of these fibers are derived from *the lateral reticulospinal tract*



Tectospinal tract

- nerve cells in superior colliculus of the midbrain
- **Crossed**
- The tract descends in the anterior white column close to Anterior median fissure
- Majority of fibers terminate in the anterior gray column of upper cervical segments of spinal cord

(responsible for reflex movement of head & neck in response to visual stimuli)



The motor pathways are classified into

- ❑ **Medial Motor system:** axial & proximal muscles. Medial Motor system include:
 - Anterior corticospinal tract.
 - Extrapyramidal pathway in general
- ❑ **Lateral Motor system:** distal muscles mainly, lateral Motor system include
 - lateral corticospinal tract
 - Rubrospinal tract distal muscles mainly (and proximal).

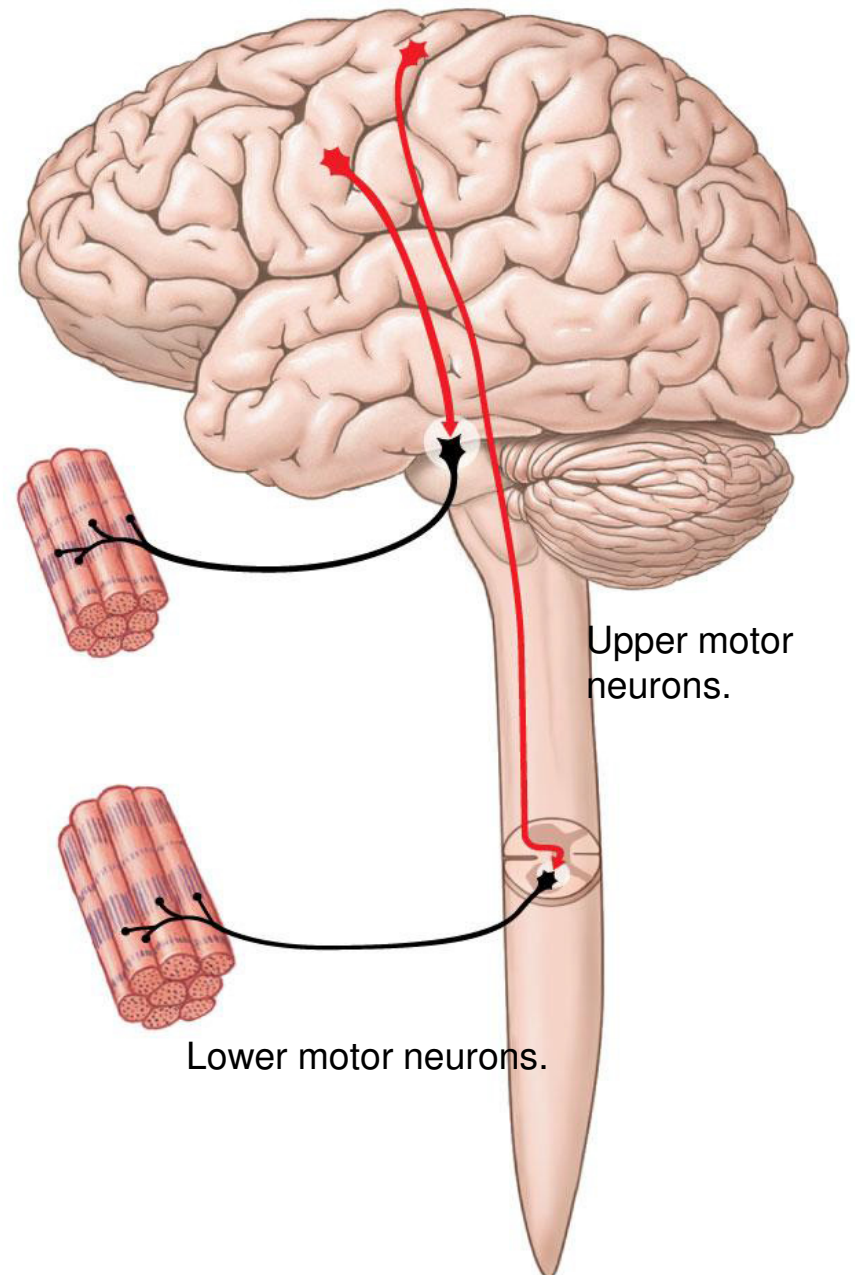
COMPARISON BETWEEN UMN AND LMN

Features	Upper motor neuron lesions(UMN)	Lower motor neuron lesion(LMN)
	UMN starts from motor cortex to the cranial nerve nuclei in brain and anterior horn cells in spinal cord	LMN is the motor pathway from anterior horn cell(or Cranial nerve nucleus)via peripheral nerve to the motor end plate
Bulk of muscles	No wasting	Wasting of the affected muscles (atrophy)
Tone of muscles	Tone increases (Hypertonia)	Tone decreases (Hypotonia)
Power of muscles	Paralysis affects movements of group of muscles Spastic/ clasp knife	Individual muscles is paralyzed Flaccid (flaccid paralysis)
Reflexes	Exaggerated. (Hyperreflexia)	diminished or absent. (Hyporeflexia)
Fasciculation	Absent	Present
Babinski sign	Present	Absent
clasp-knife reaction	Present	Absent
Clonus	Present	Absent

hypertonia and hyperreflexia, is the result of an increase in gamma motor neurons activity

Motor tracts

- ❑ There are two major descending tracts
- **Pyramidal tracts** (Corticospinal) : Conscious control of skeletal muscles
- **Extrapyramidal:** Subconscious regulation of balance, muscle tone, eye, hand, and upper limb position:
- ❖ **Vestibulospinal tracts**
- ❖ **Reticulospinal tracts**
- ❖ **Rubrospinal tracts**
- ❖ **Tectospinal tracts**



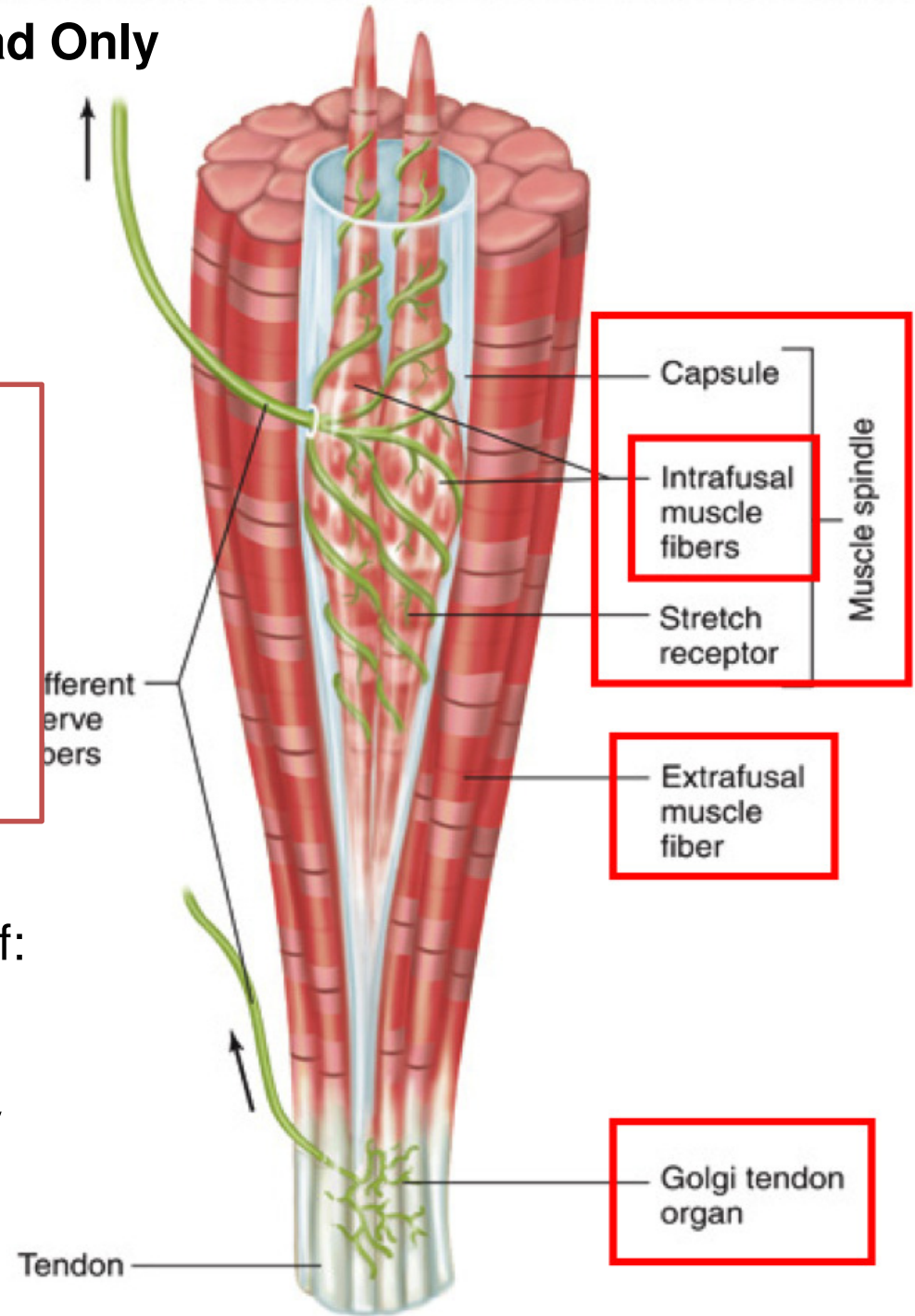
Extrapyramidal tracts arise in the brainstem, but are under the influence of the cerebral cortex

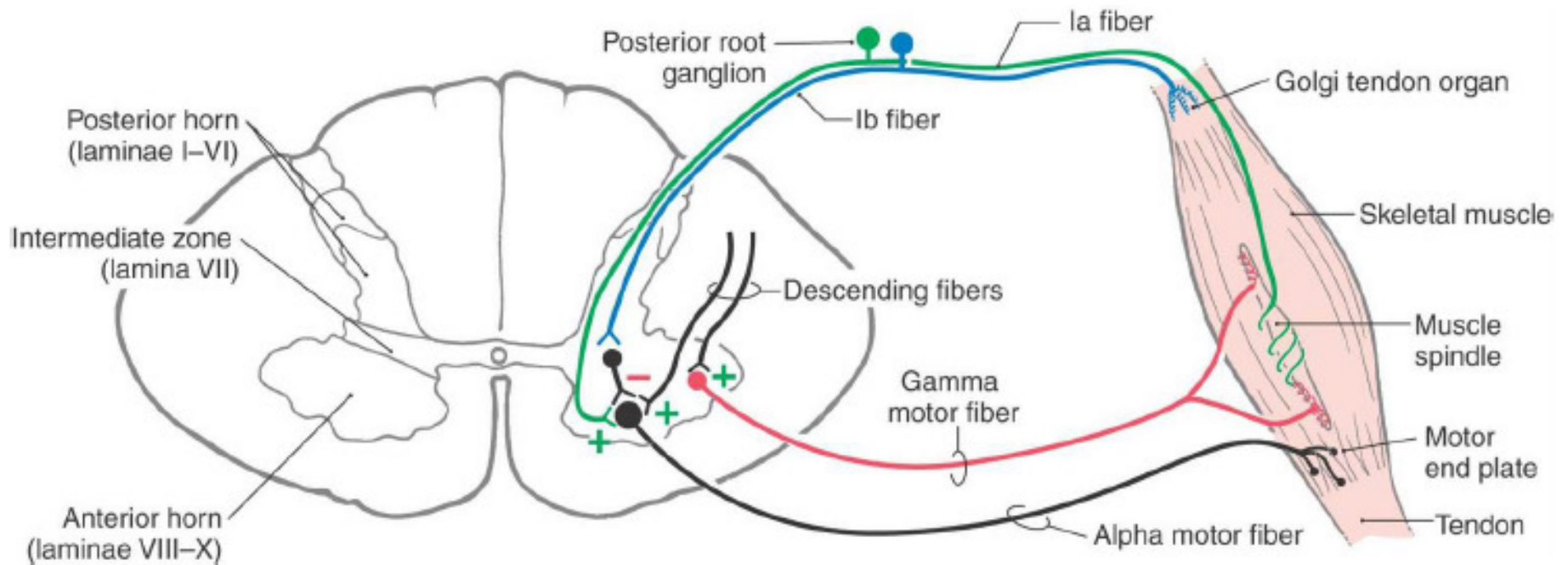
Muscle spindles are sensory receptors within the belly of a muscle that primarily detect changes in the length of this muscle.

Each muscle spindle consists of an encapsulated cluster of small striated muscle fibers ("**intrafusal muscle fibers**") with somewhat unusual structure (e.g., nuclei may be concentrated in a cluster near the middle of the fiber's length).

- ❑ The skeletal muscle is composed of:
 - Extrafusal fibers (99%): innervated by **alpha motor neurons**.
 - Intrafusal fibers (1%): innervated by **gamma motor neurons**. depend on the muscle spindle receptors

Read Only



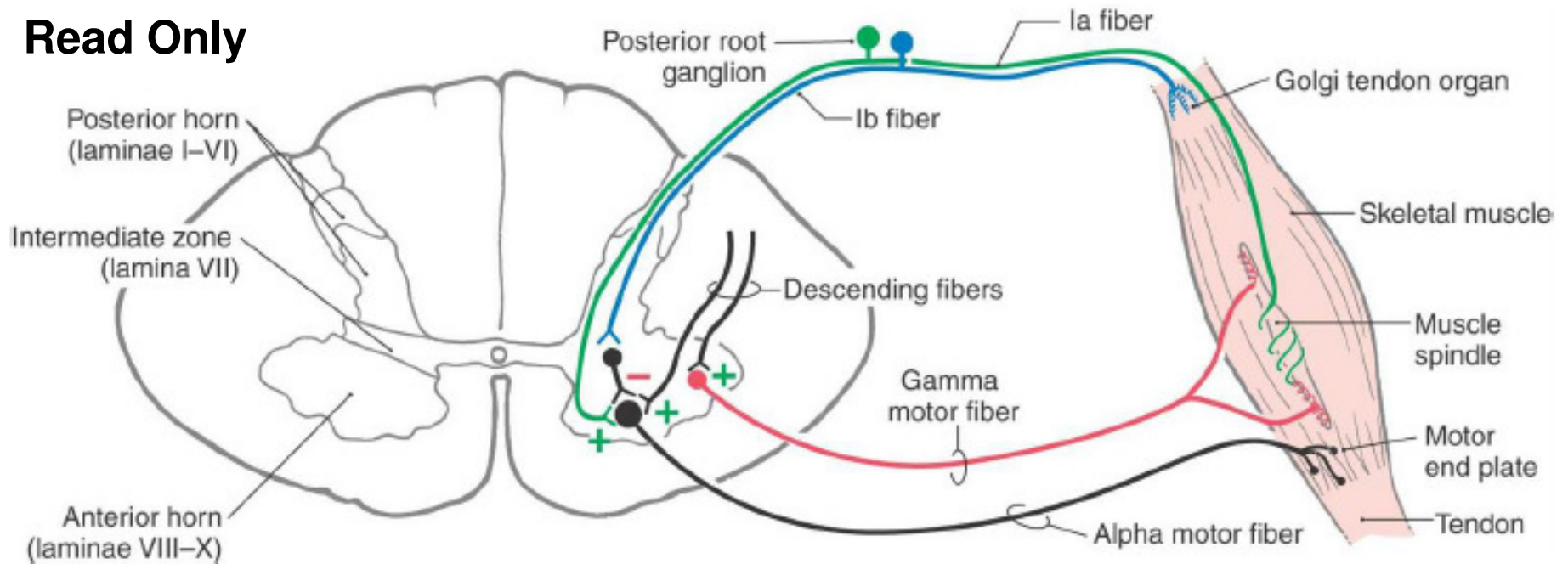


❑ Activating alpha motor neurons

- Directly through supraspinal centers: Descending motor pathways (UMN)
- Indirectly through Muscle spindles
 - Stretch reflex: skeletal muscles are shorter than the distance between its origin and insertion
 - Gamma loop

Read Only

Read Only



- ❑ Gamma fibers activate the muscle fibers indirectly, while alpha fibers do it directly.
- ❑ Alpha fibers give faster but short contraction
- ❑ Gamma fibers give slow but long contraction.
- ❖ For fast contraction: stimulate alpha.
- ❖ For muscle tone: stimulate gamma.
- ❖ For continuous contraction and a certain movement: stimulate both.

Read Only

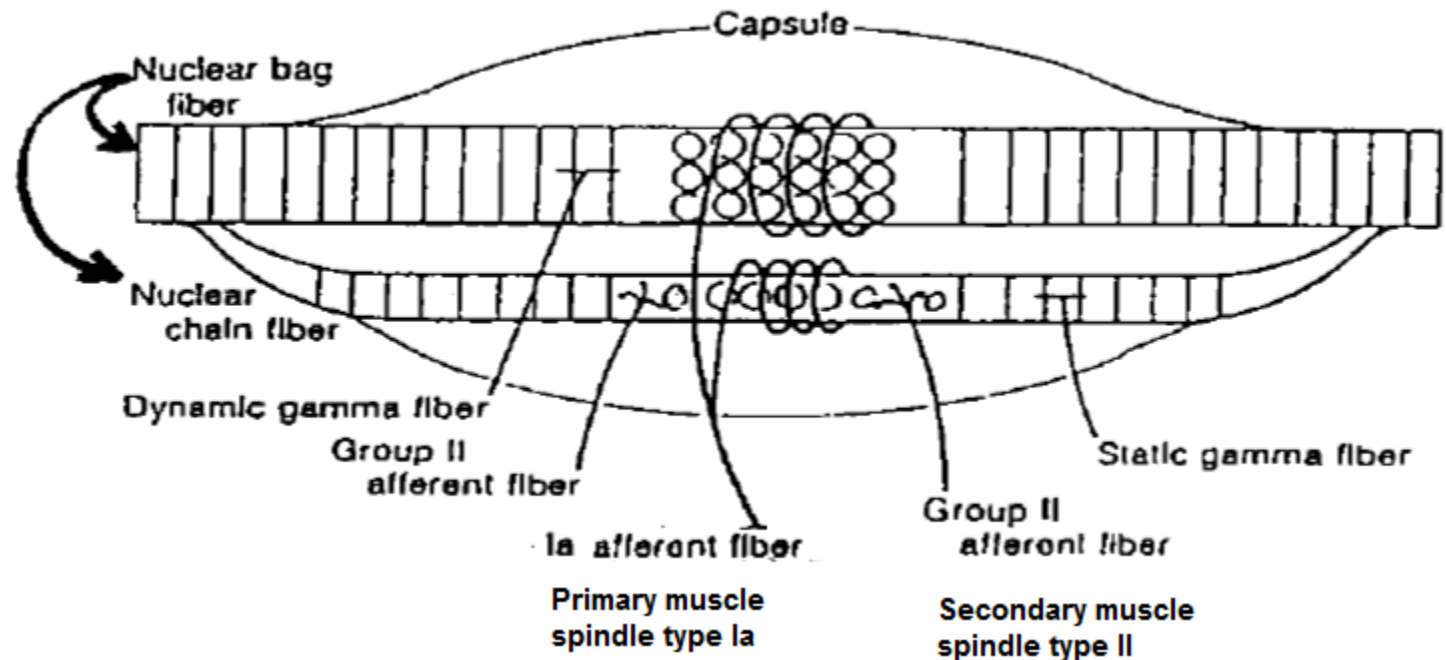
Intrafusal fibers

➤ **Nuclear Bag**

Fibers: supplied by dynamic Gamma

➤ **Nuclear chain**

fibers: supplied by static Gamma



❖ **Both Nuclear bag and chain Don't contain sarcomeres**

Primary afferent: type Ia,

➤ Around both nuclear bag and chain fibers

➤ Rapidly adapting

➤ Dynamic stretch reflex: e.g jerk (Knee, ankle quadriceps)

Secondary afferent: type II

➤ Found only in nuclear chain fibers.

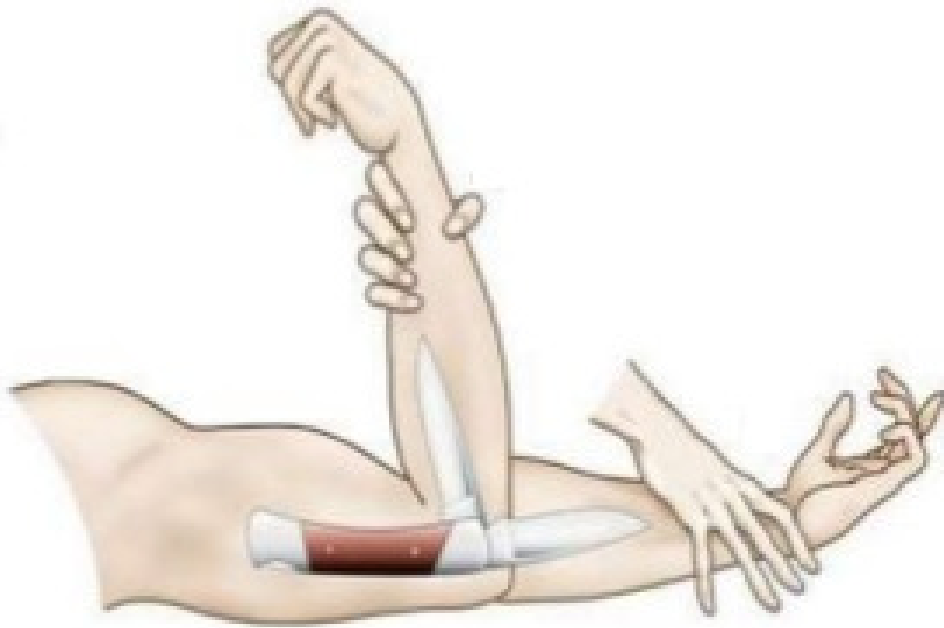
➤ Slowly adapting

➤ Static stretch reflex. Important for muscle tone

ELECTROPHYSIOLOGIC CLASSIFICATION OF PERIPHERAL NERVES	CLASSIFICATION OF AFFERENT FIBERS ONLY (CLASS/GROUP)	FIBER DIAMETER (μm)	CONDUCTION VELOCITY (m/s)	RECEPTOR SUPPLIED
Sensory Fiber Type				
A α	Ia and Ib	13-20	80-120	Primary muscle spindles, Golgi tendon organ
A β	II	6-12	35-75	Secondary muscle spindles, skin mechanoreceptors
A δ	III	1-5	5-30	Skin mechanoreceptors, thermal receptors, and nociceptors
C	IV	0.2-1.5	0.5-2	Skin mechanoreceptors, thermal receptors, and nociceptors
Motor Fiber Type				
A α	N/A	12-20	72-120	Extrafusal skeletal muscle fibers
A γ	N/A	2-8	12-48	Intrafusal muscle fibers
B	N/A	1-3	6-18	Preganglionic autonomic fibers
C	N/A	0.2-2	0.5-2	Postganglionic autonomic fibers

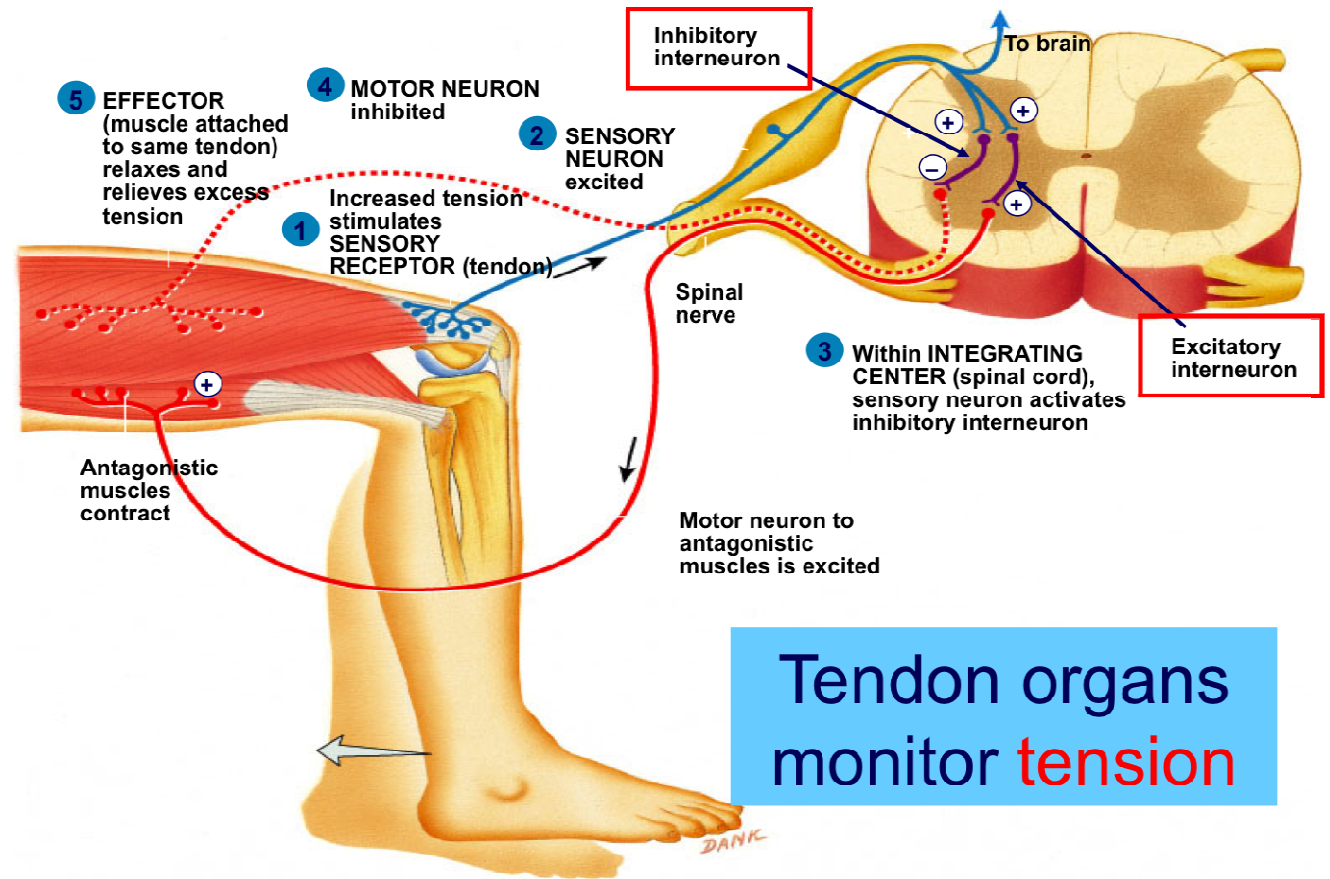
Clasp knife reaction

- Overactivity of the pointine excitatory system (spasticity)
- **Initial resistance:** Exaggerated stretch reflex
- **Sudden release:** After applying pressure, the tension in the muscle will increase and will be enough to activate the **Golgi tendon organs** which will cause the relaxation

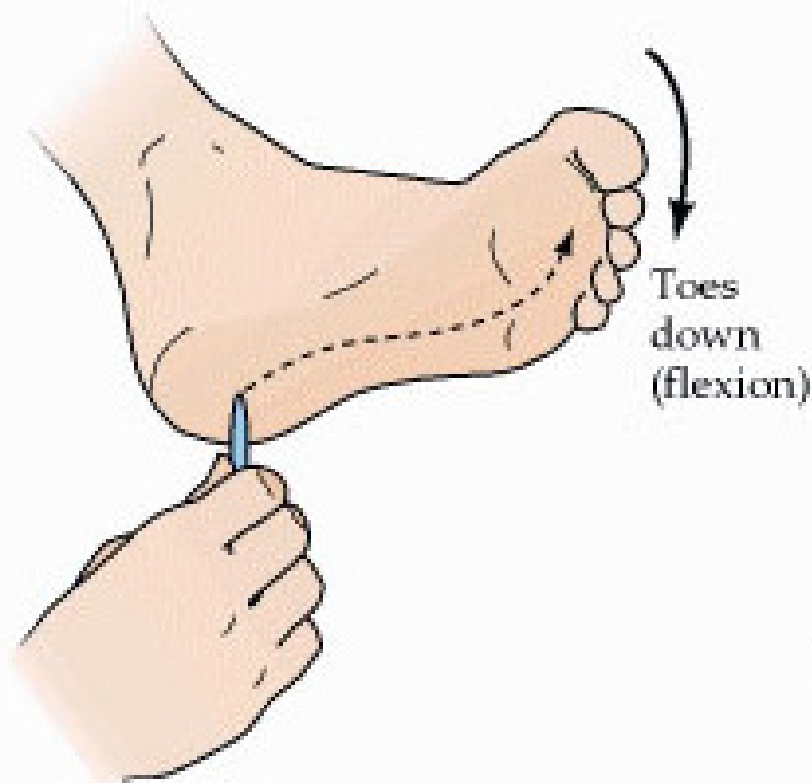


Tendon reflex

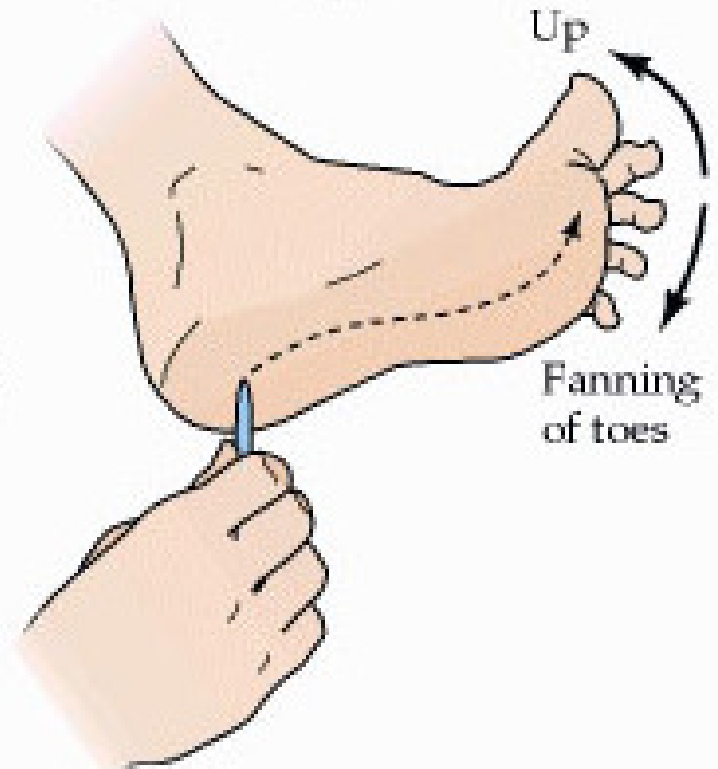
- Polysynaptic reflex arc
- law of reciprocal innervation



(A) Normal plantar response

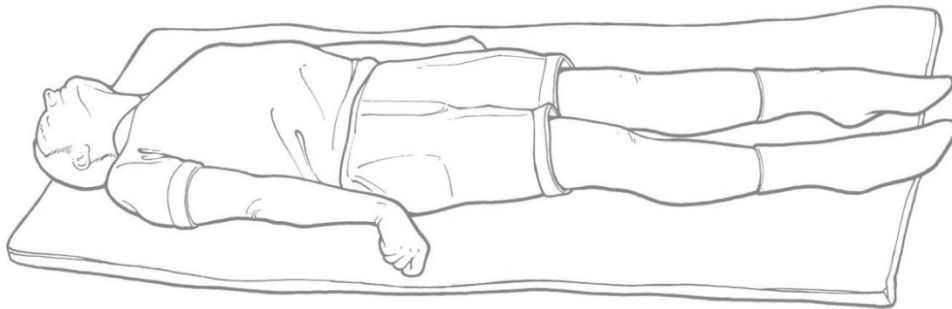
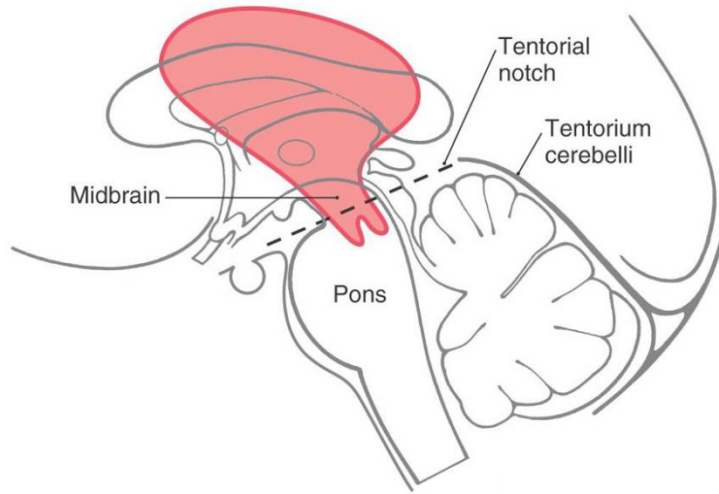


(B) Extensor plantar response (Babinski sign)

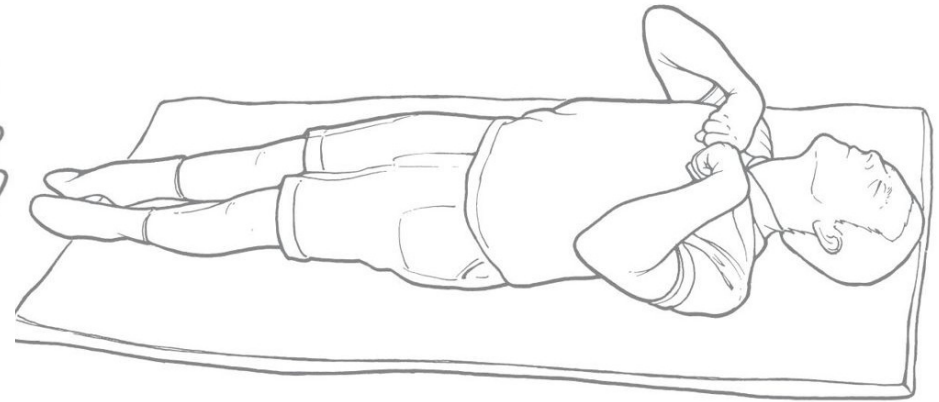
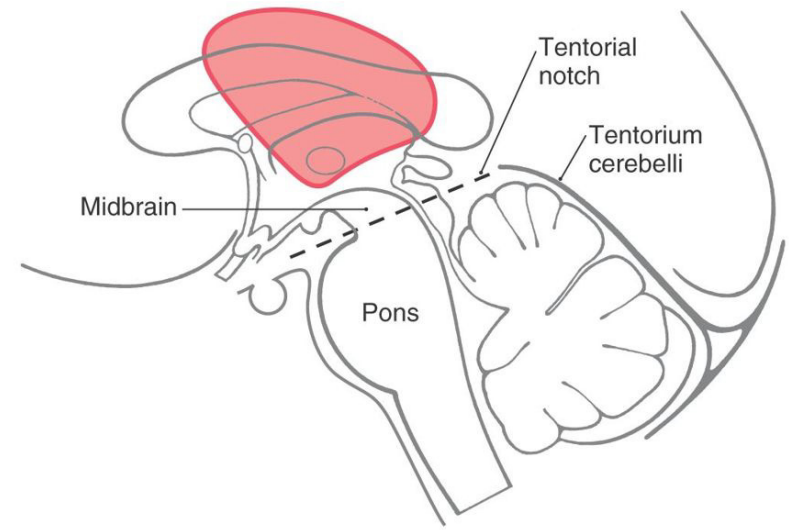


When the corticospinal tracts are nonfunctional, the influence of the other descending tracts on the toes becomes apparent, and a kind of withdrawal reflex takes place in response to stimulation of the sole, with the great toe being dorsally flexed and the other toes fanning out.

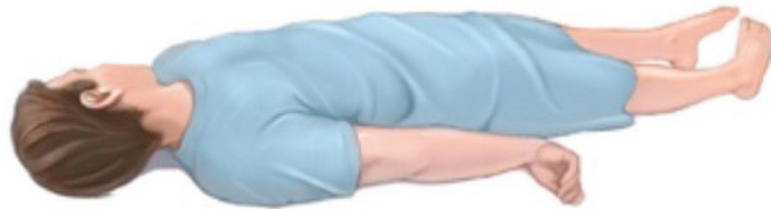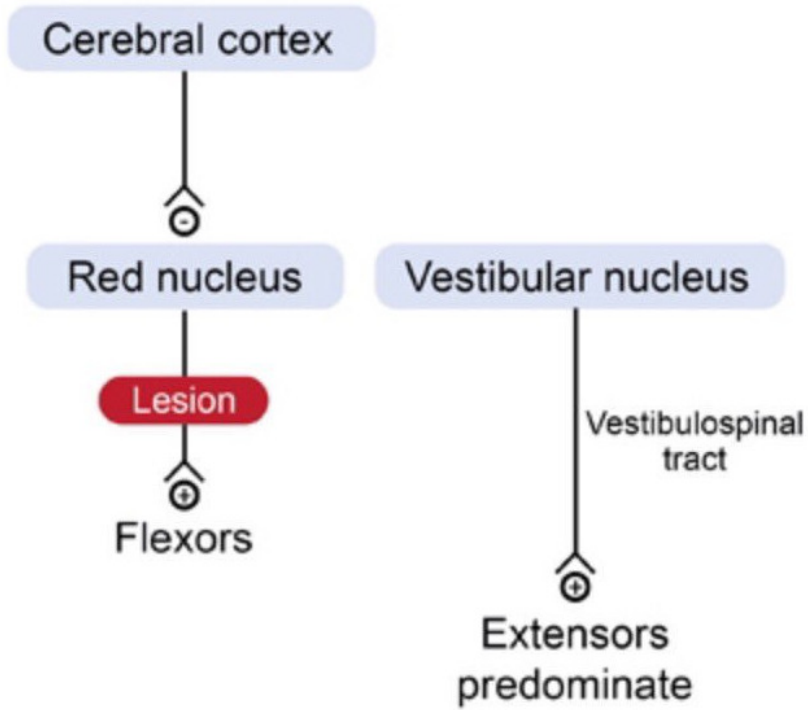
Decerebrate rigidity



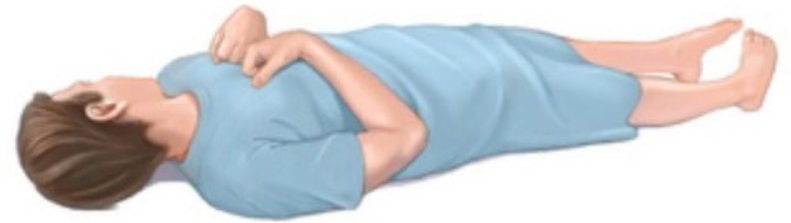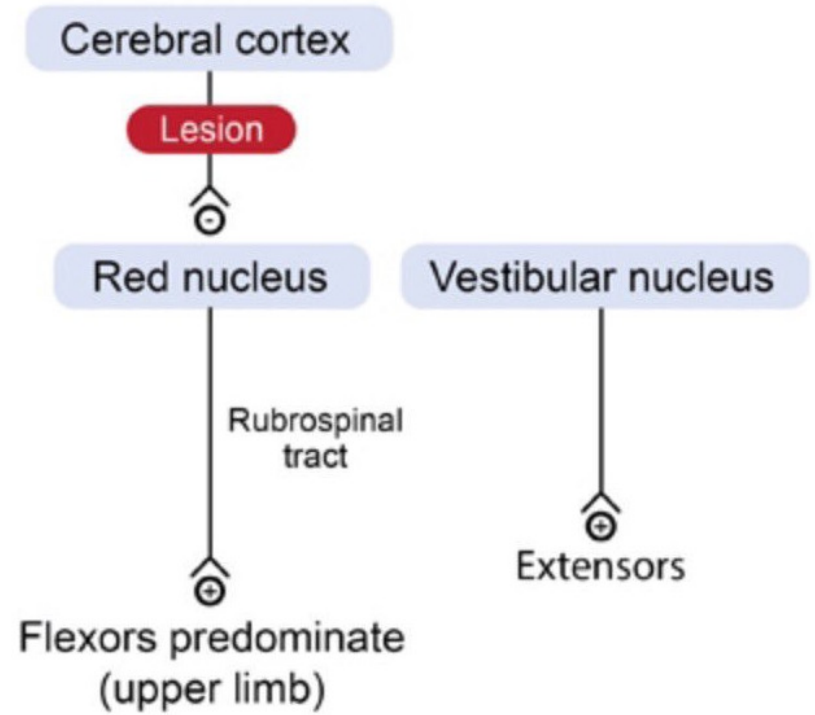
Decorticate rigidity



Decerebrate posture



Decorticate posture



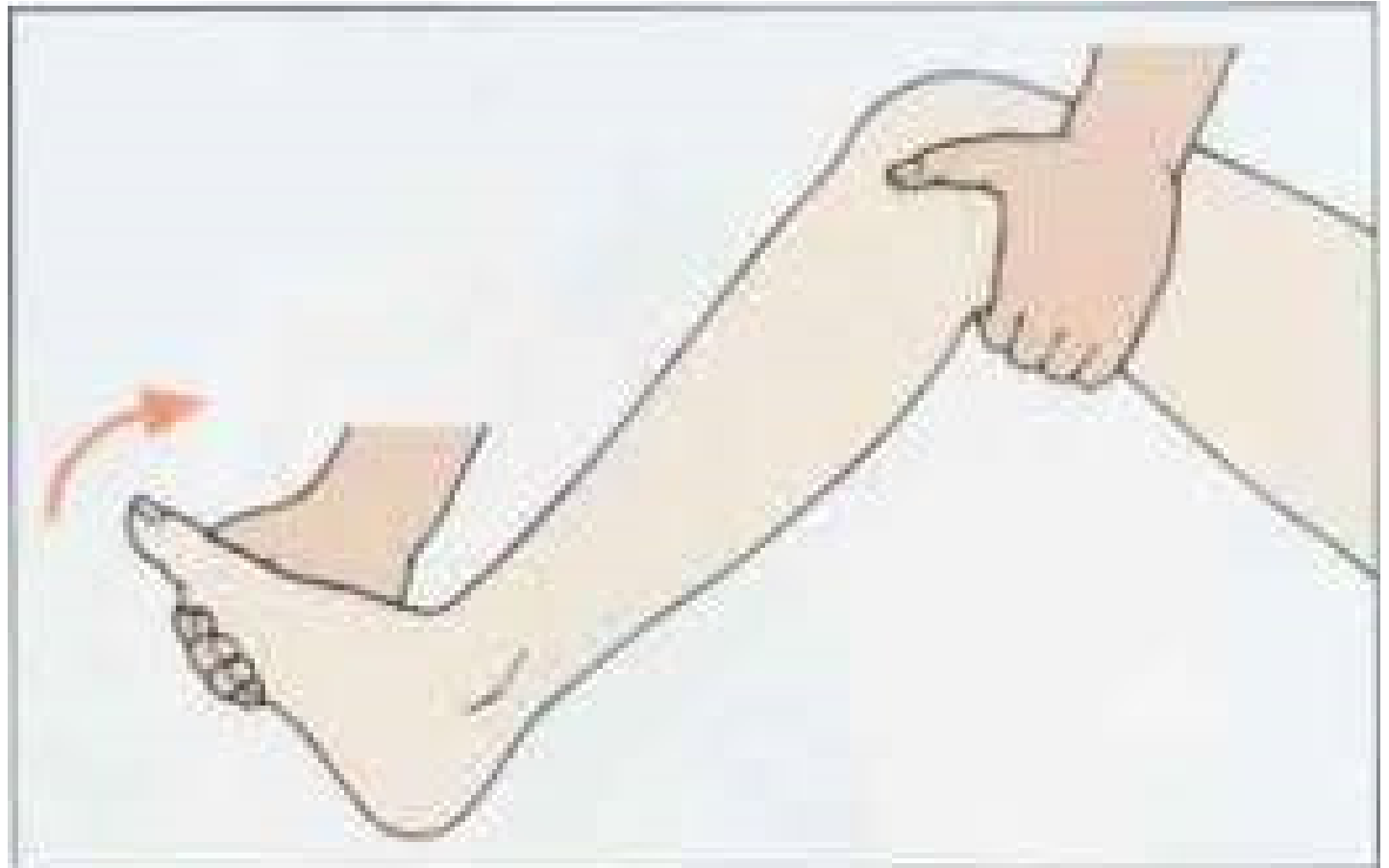


Fig. 6.29 Testing for ankle clonus.

Rhythmic contractions and relaxation of muscles when they are subjected to sudden sustained stretch

COMPARISON BETWEEN UMN AND LMN

Features	Upper motor neuron lesions(UMN)	Lower motor neuron lesion(LMN)
	UMN starts from motor cortex to the cranial nerve nuclei in brain and anterior horn cells in spinal cord	LMN is the motor pathway from anterior horn cell(or Cranial nerve nucleus)via peripheral nerve to the motor end plate
Bulk of muscles	No wasting	Wasting of the affected muscles (atrophy)
Tone of muscles	Tone increases (Hypertonia)	Tone decreases (Hypotonia)
Power of muscles	Paralysis affects movements of group of muscles Spastic/ clasp knife	Individual muscles is paralyzed Flaccid (flaccid paralysis)
Reflexes	Exaggerated. (Hyperreflexia)	diminished or absent. (Hyporeflexia)
Fasciculation	Absent	Present
Babinski sign	Present	Absent
clasp-knife reaction	Present	Absent
Clonus	Present	Absent

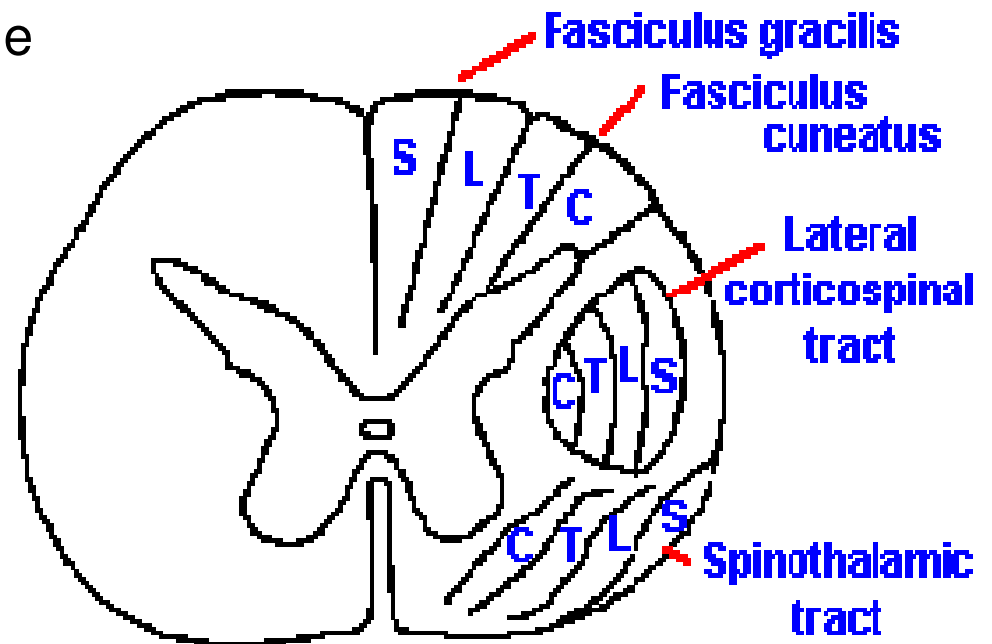
hypertonia and hyperreflexia, is the result of an increase in gamma motor neurons activity

Clinical significance of lamination of the ascending tracts

- Any external pressure exerted on the spinal cord in the region of the spinothalamic tracts will first experience a loss of pain and temperature sensations in the sacral dermatome of the body
- If pressure increases the other higher segmental dermatomes will be affected

❖ Remember that in the spinothalamic tracts the cervical to sacral segments are located medial to lateral

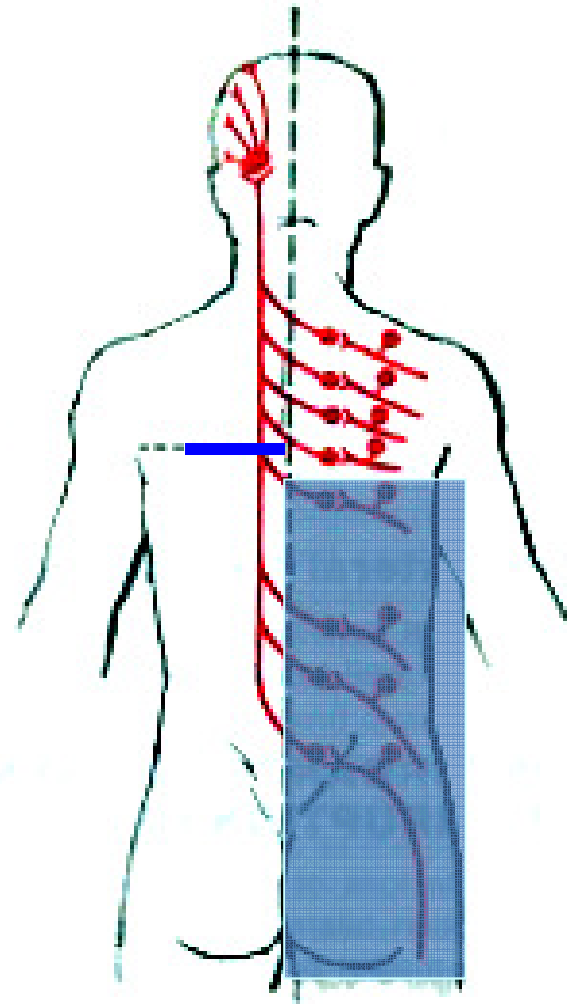
- **Intramedullary tumor:** affect the cervical fibers (Medial)
- **Extramedullary tumor** would affect lower limb fibers (lateral).
- ❑ **Sacral sparing:** Occur at intramedullary tumor



Clinical application destruction of LSTT

- loss of
 - pain and thermal sensation
 - on the contralateral side
 - below the level of the lesion

patient will not
recognize hot and cold

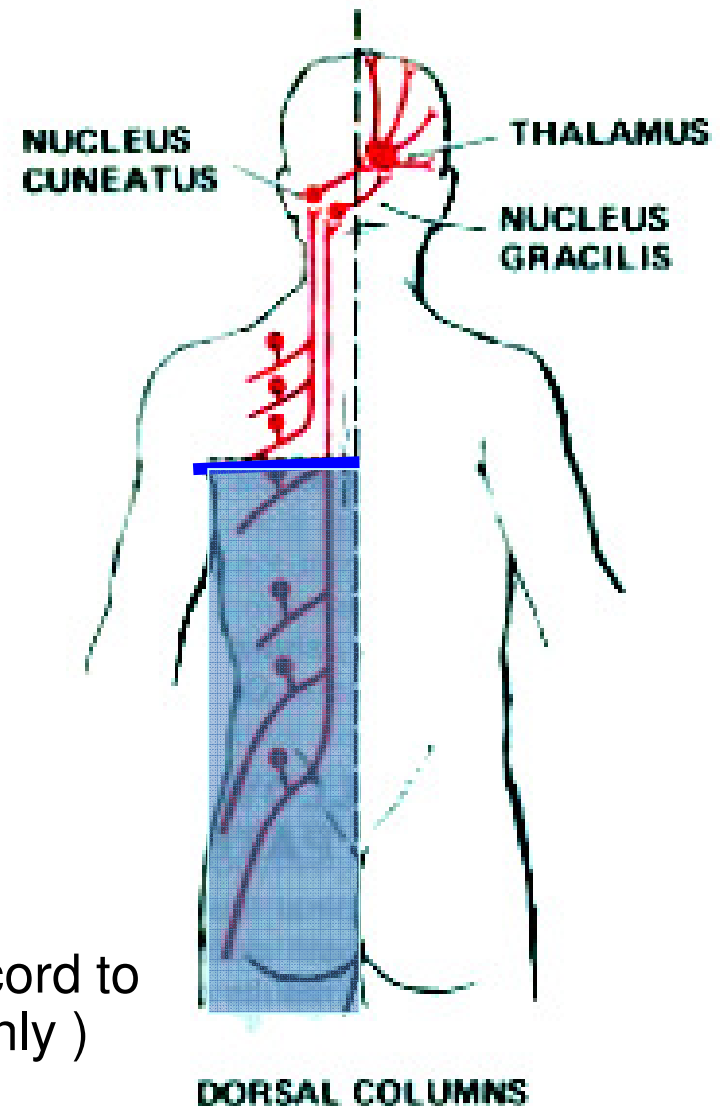


**LATERAL SPINOTHALAMIC
TRACT**

Clinical application
destruction of
fasciculus gracilia and cuneatus

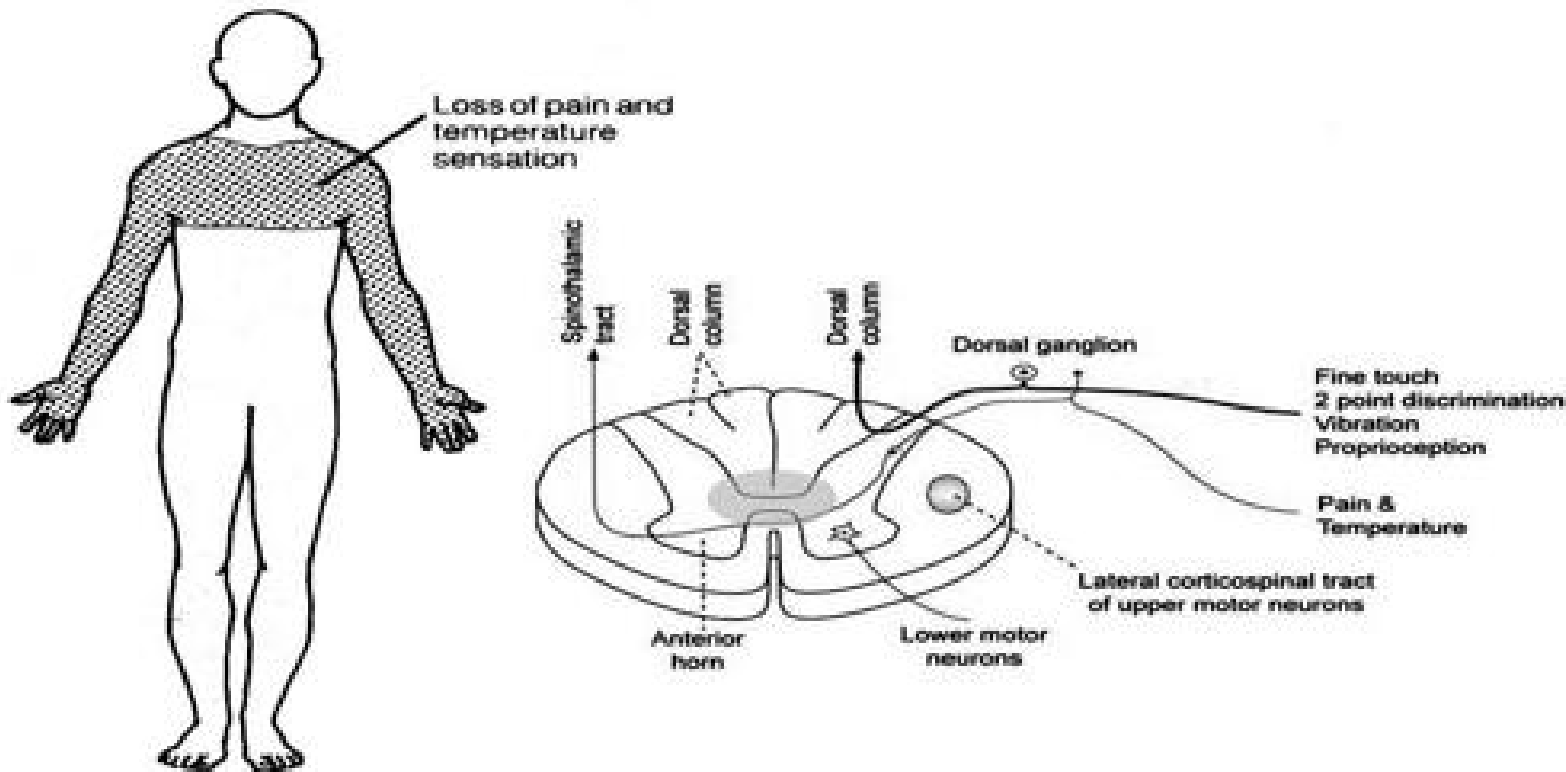
- loss of muscle joint sense, position sense, vibration sense and tactile discrimination
- on the same side
- below the level of the lesion

(extremely rare to have a lesion of the spinal cord to be localized as to affect one sensory tract only)



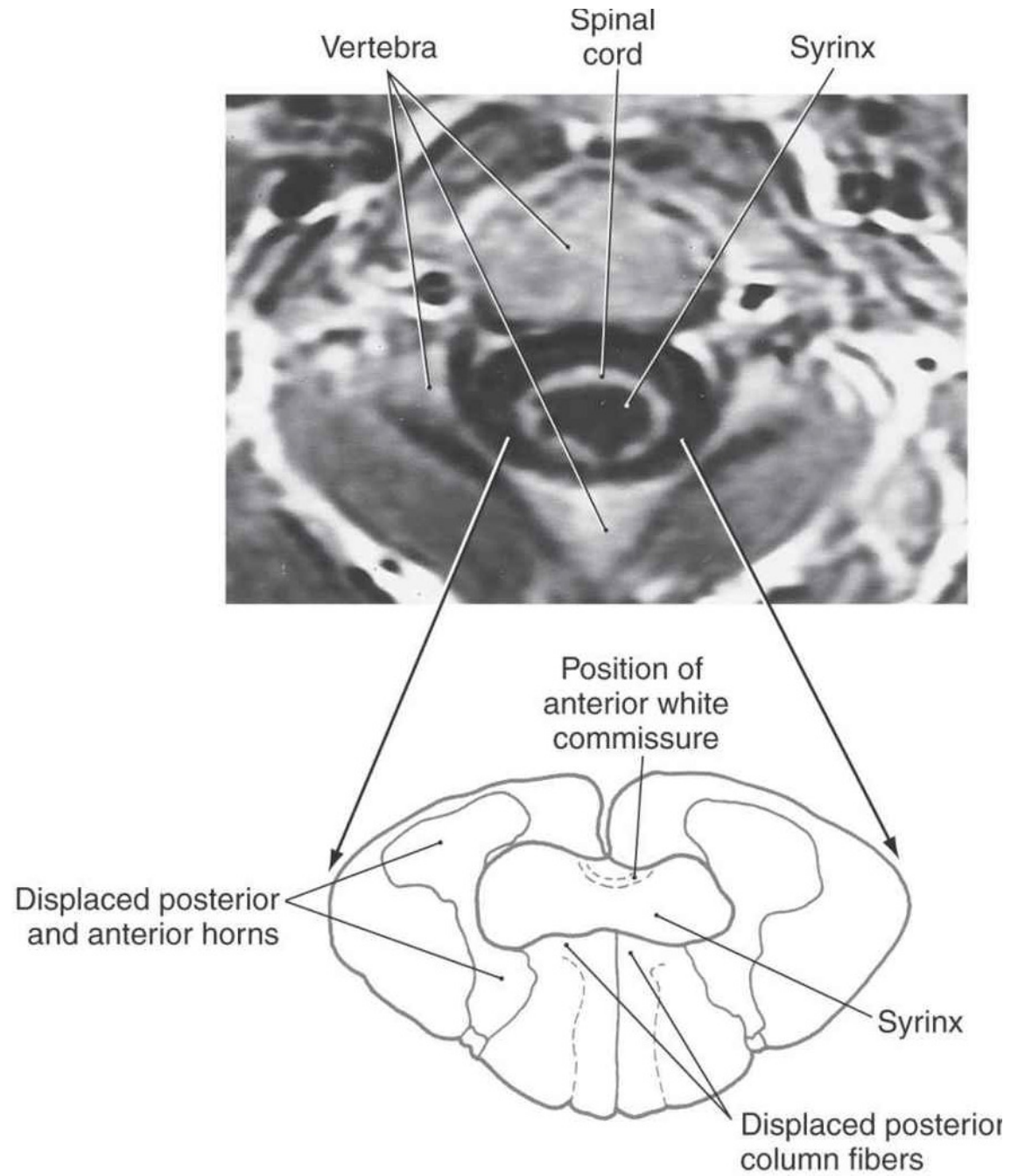
Syringomyelia

- Cavitation of the central regions of the spinal cord
- Damage fibers crossing in the anterior white commissure in both directions
- Bilateral loss of pain and thermal sensations
- When it is located at the C4 to C5 levels of the spinal cord sensory losses in the configuration of a cape draped over the shoulders and extending down to nipple level



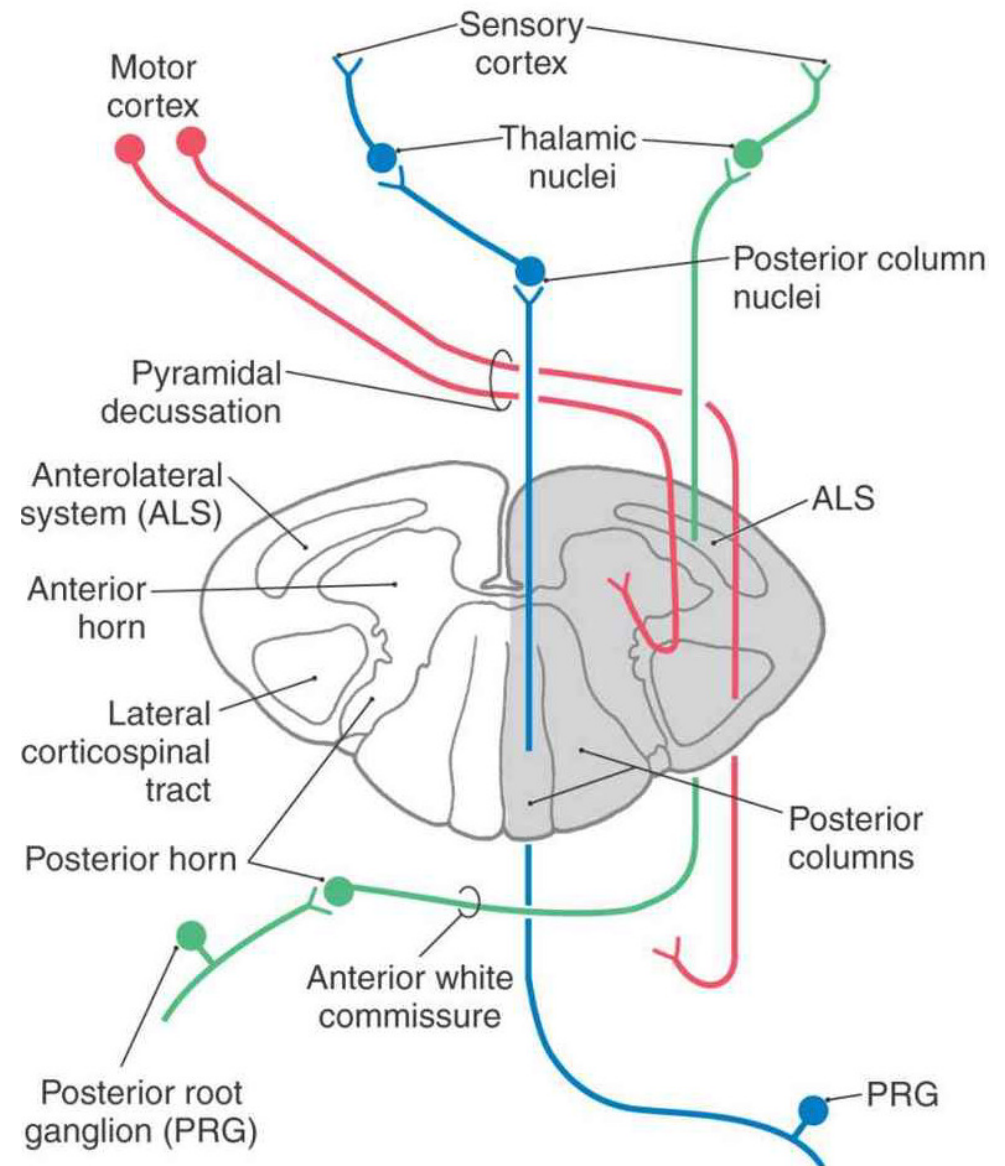
Syringomyelia

- If a **cyst extends into** the anterior horn results it will cause:
 - bilateral sensory loss
 - weakness of the corresponding extremity
- extension of the syrinx into one anterior horn results in an ipsilateral weakness of the upper extremity
- if both anterior horns are involved, the weakness is bilateral



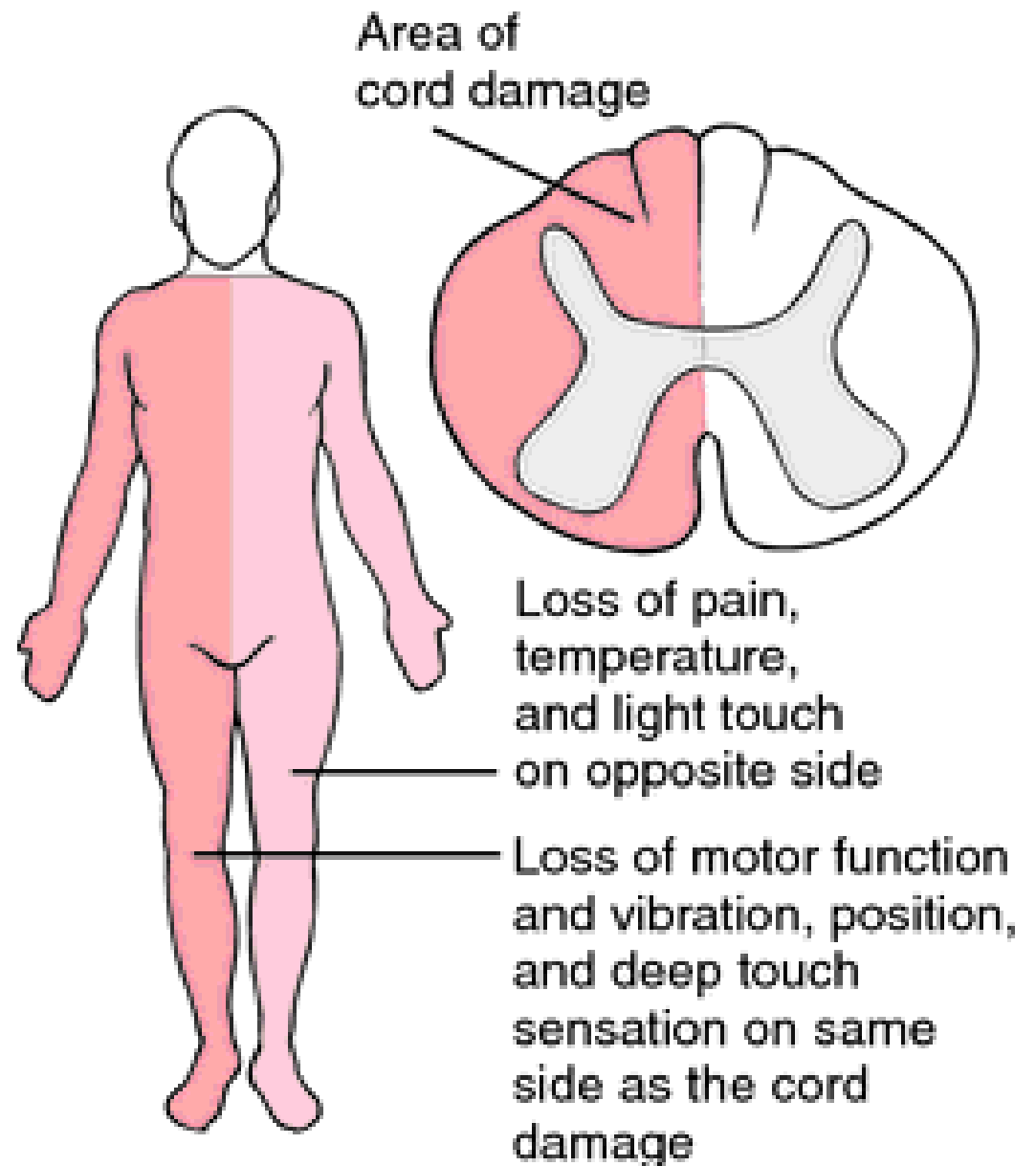
Brown-Séquard Syndrome

- Functional hemisection of the spinal cord results in:
 - ❖ damage to the lateral corticospinal tract, ALS, posterior columns
- Example: A lesion on the right at C4 to C5 will result in:
 - muscle weakness or paralysis (hemiparesis, hemiplegia) on the right side
 - loss of pain and thermal sensations on the left side
 - loss of proprioception, vibratory sense, and discriminative touch on the right



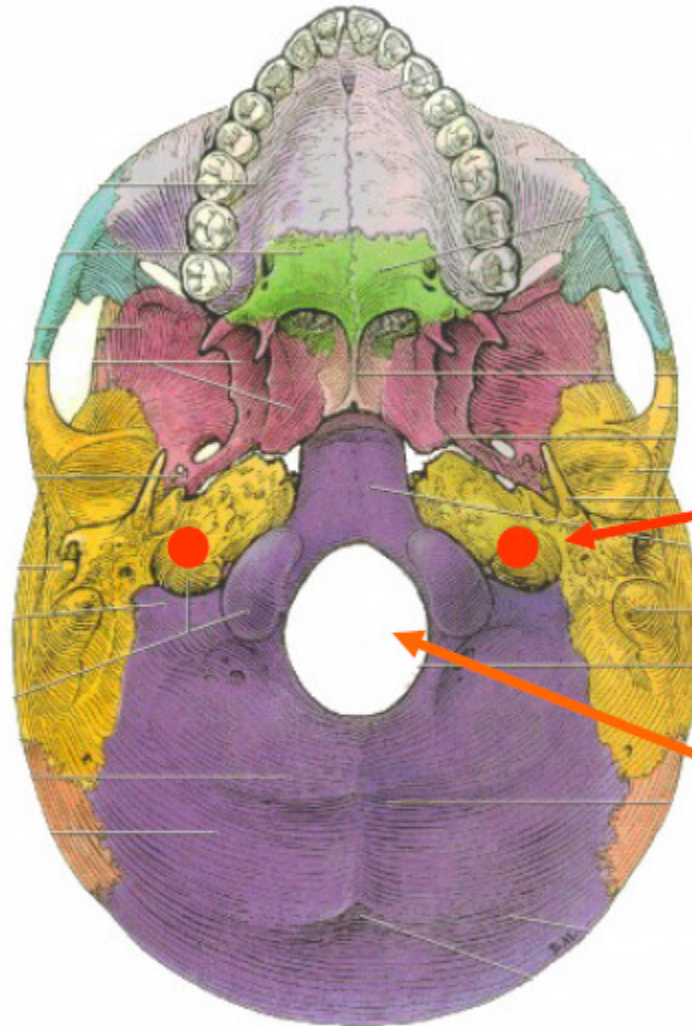
Brown-Séquard Syndrome

- **Contralateral** loss of nociceptive and thermal sensations over the body below the level of the lesion
- **Ipsilateral** loss of discriminative tactile, vibratory, and position sense over the body below the level of the lesion
- **Ipsilateral** paralysis of the leg or leg and arm, depending on the level of the hemisection



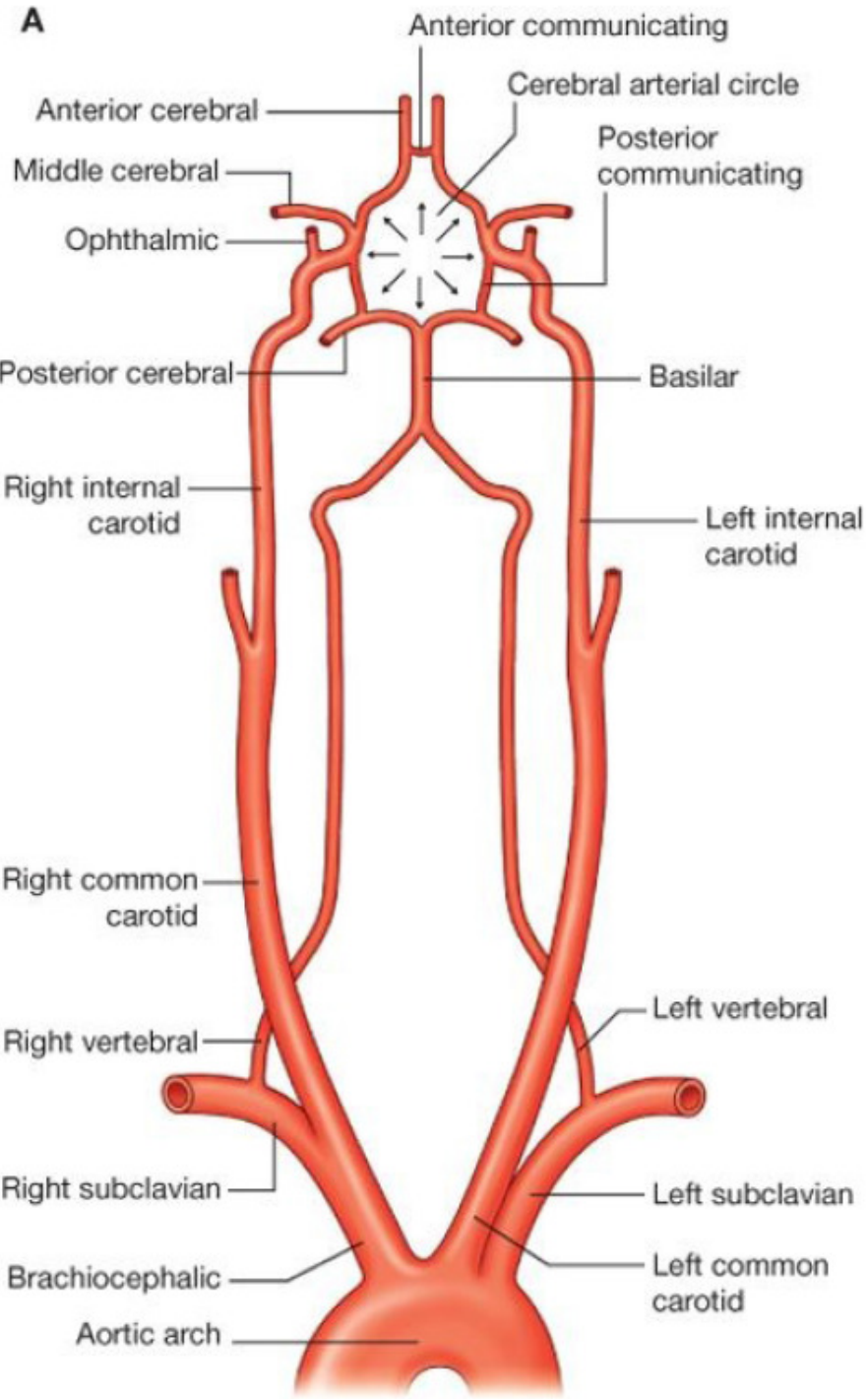
Arterial Blood Supply

- Brain is supplied by pairs of internal carotid artery and vertebral artery.
- The four arteries lie within the subarachnoid space
- Their branches anastomose on the inferior surface of the brain to form the **circle of Willis**

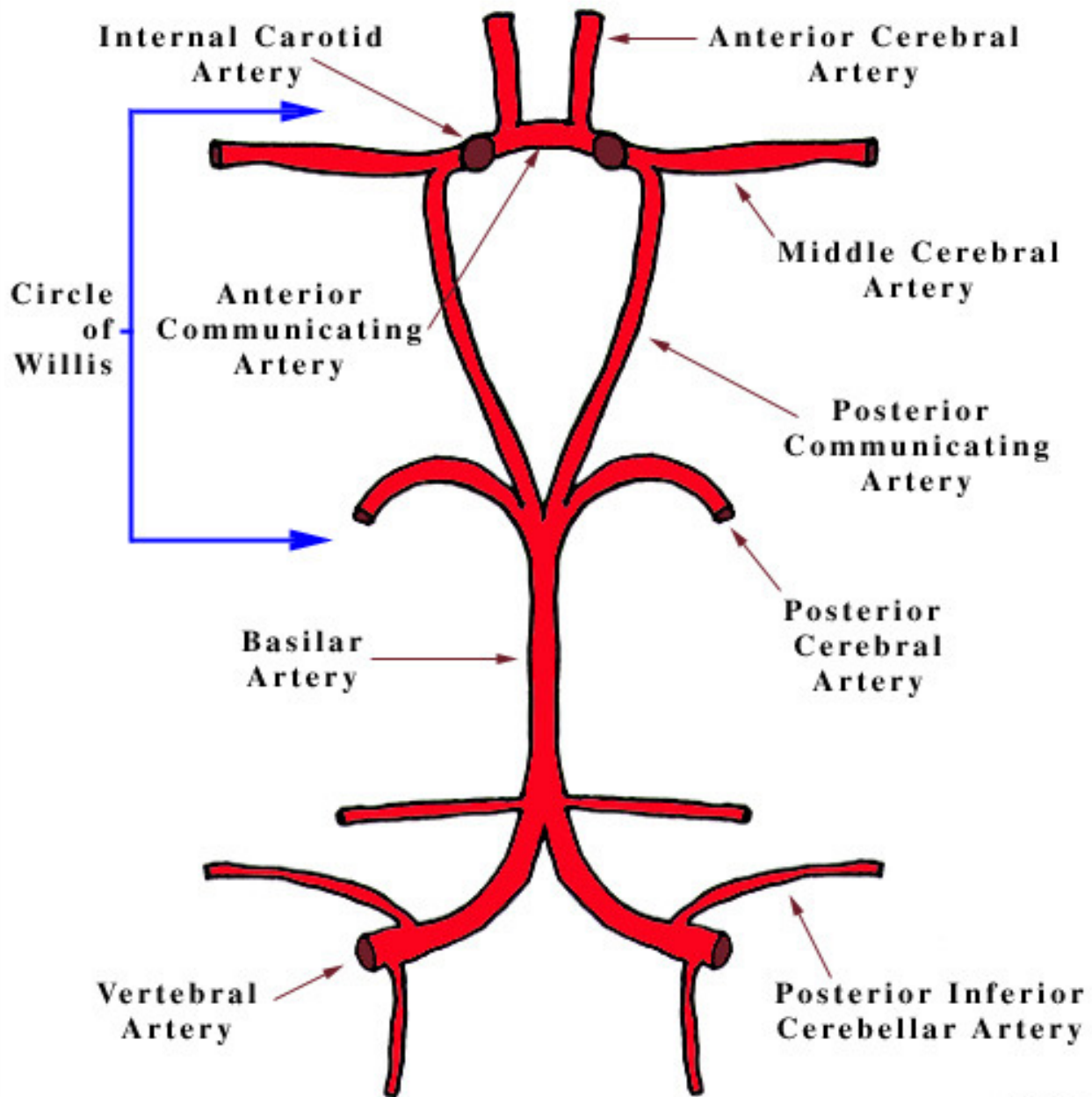


A. Internal Carotid Artery- enters skull via Carotid Canal And Foramen Lacerum

B. Vertebral artery- enters skull via Foramen Magnum



CIRCLE OF WILLIS

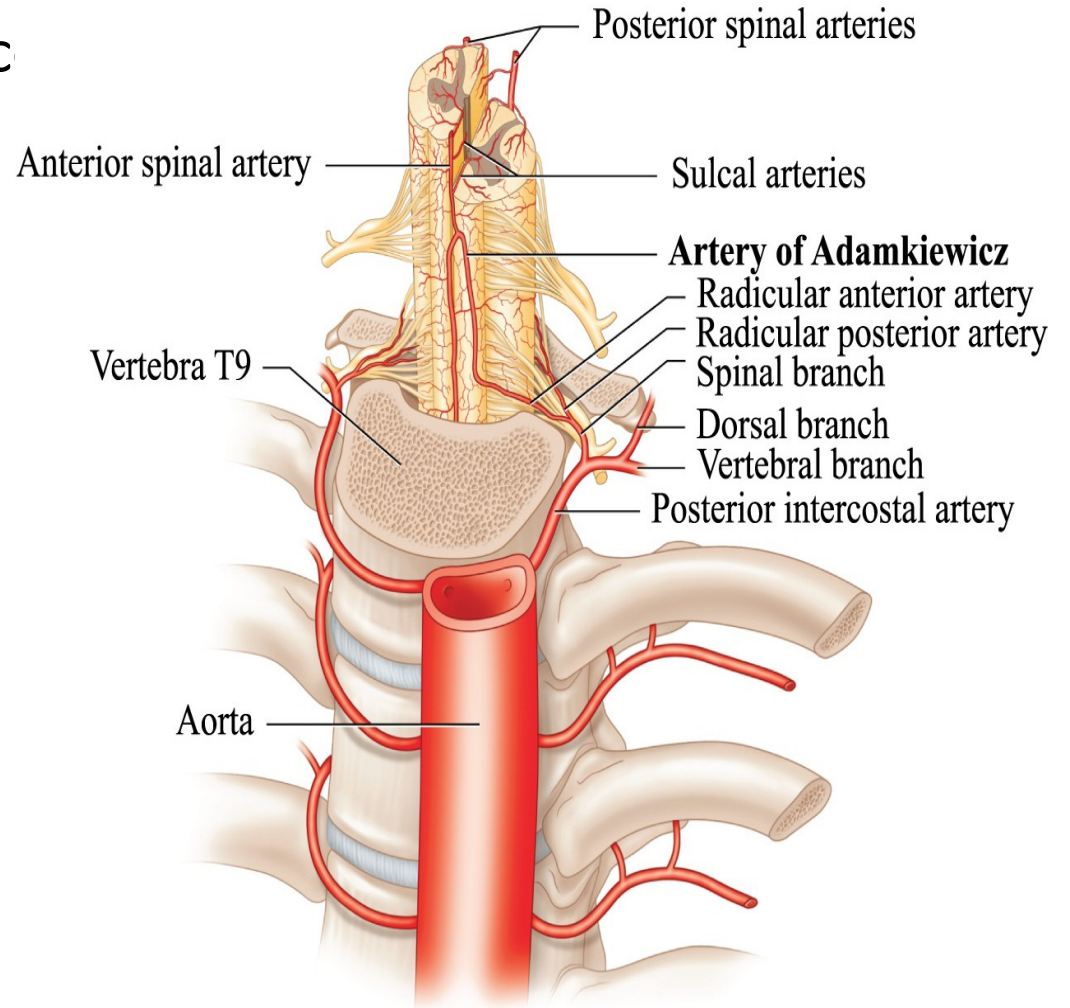
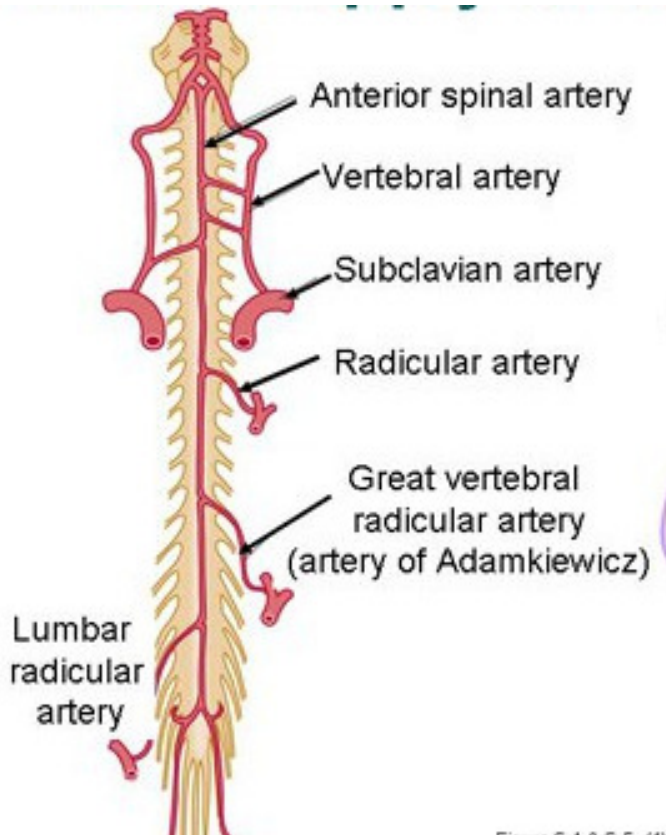


WALTER CRANE

Blood supply of spinal c

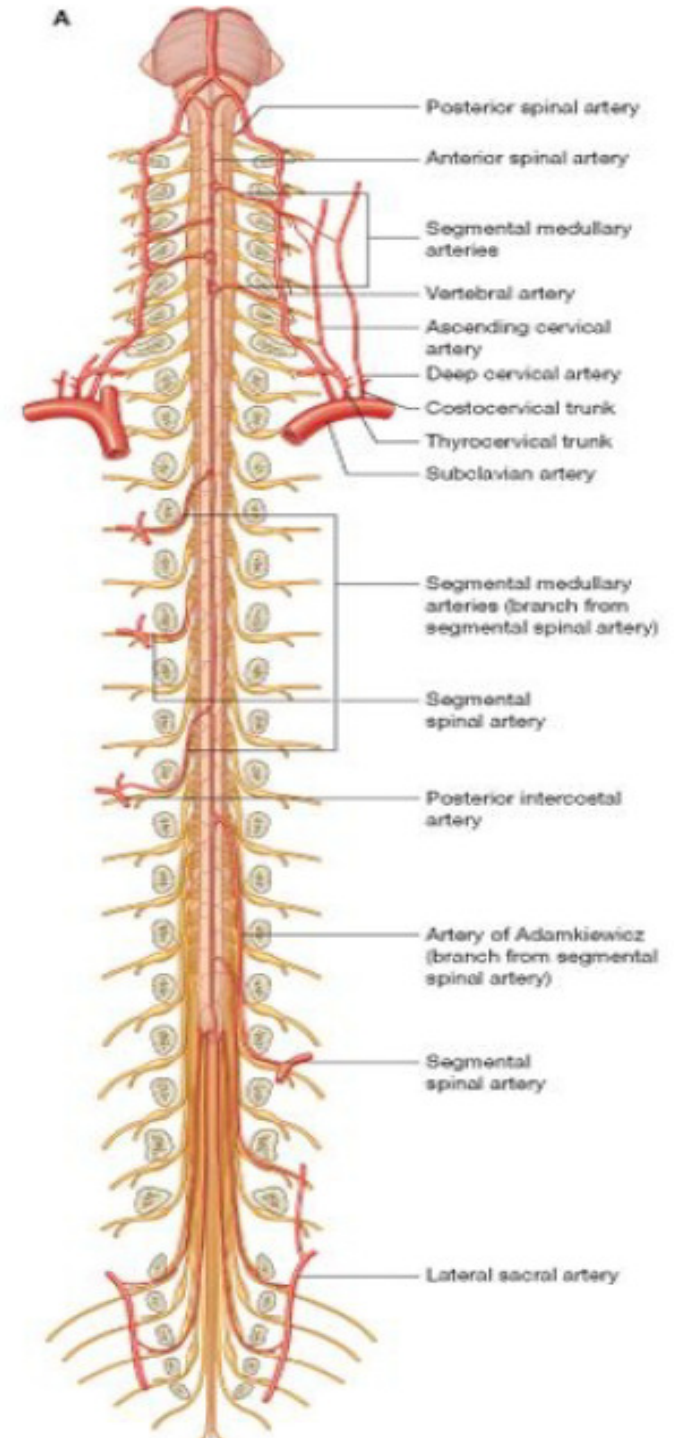
- **Longitudinal arteries:**

- **One anterior spinal artery:** arise from the vertebral arteries (in anterior median fissure)
- **Two posterior spinal arteries:** arise from the posterior inferior cerebellar artery (in the posterolateral sulcus)



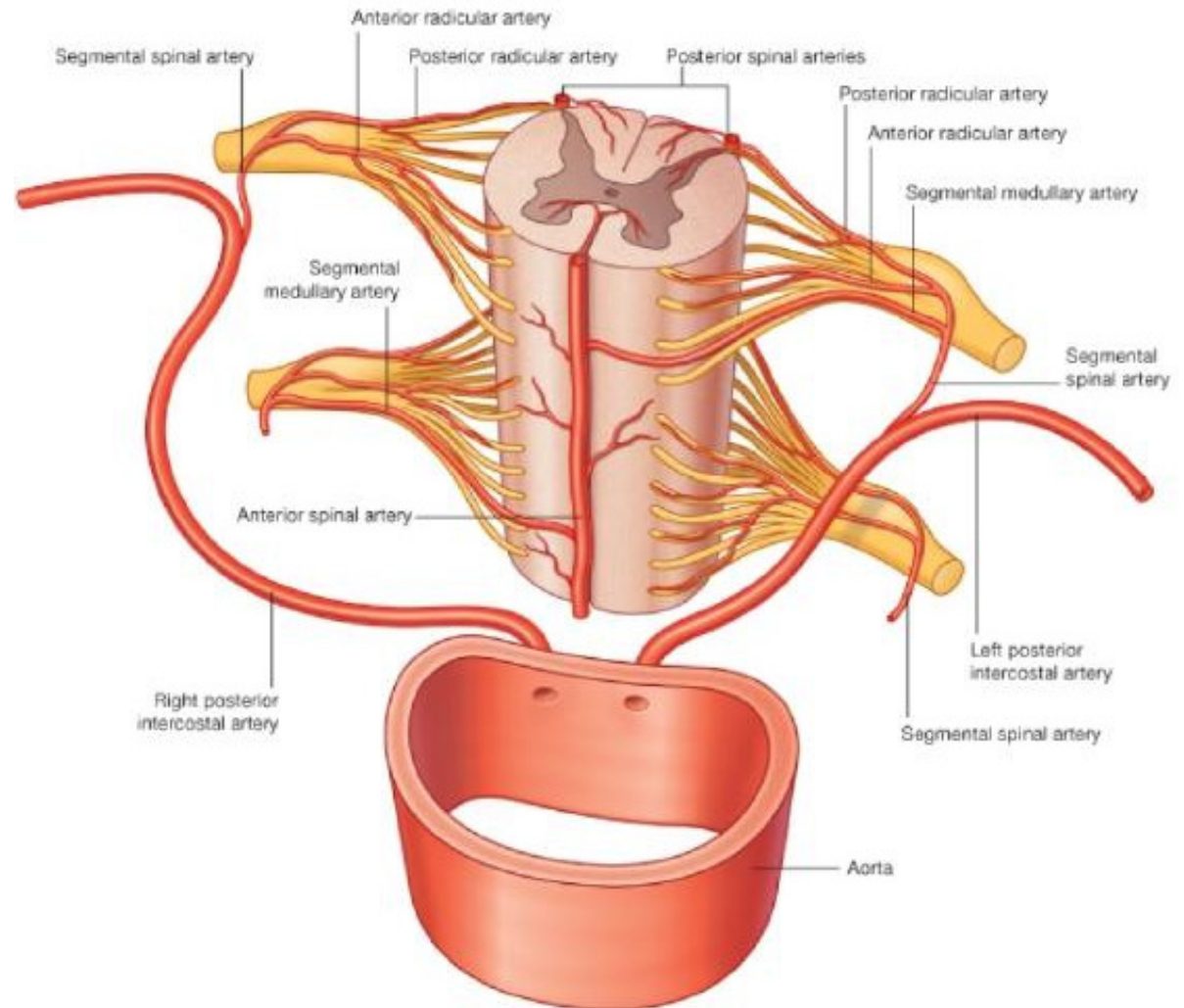
Blood supply of spinal cord

- **segmental spinal arteries**, arise from:
 - Vertebral arteries
 - Deep cervical arteries in the neck
 - Posterior intercostal arteries in the thorax
 - lumbar arteries in the abdomen
- **Branches :**
 - **Anterior radicular arteries**
 - **Posterior radicular arteries**
 - **Segmental medullary arteries**
- **Artery of Adamkiewicz**
 - usually on the left side,
 - reinforces the arterial supply to the lower portion of the spinal cord
 - From Left posterior intercostal artery at the level of the 9th to 12th intercostal artery, which branches from the aorta, and supplies the lower two thirds of the spinal cord
 - Anastomose with anterior spinal artery



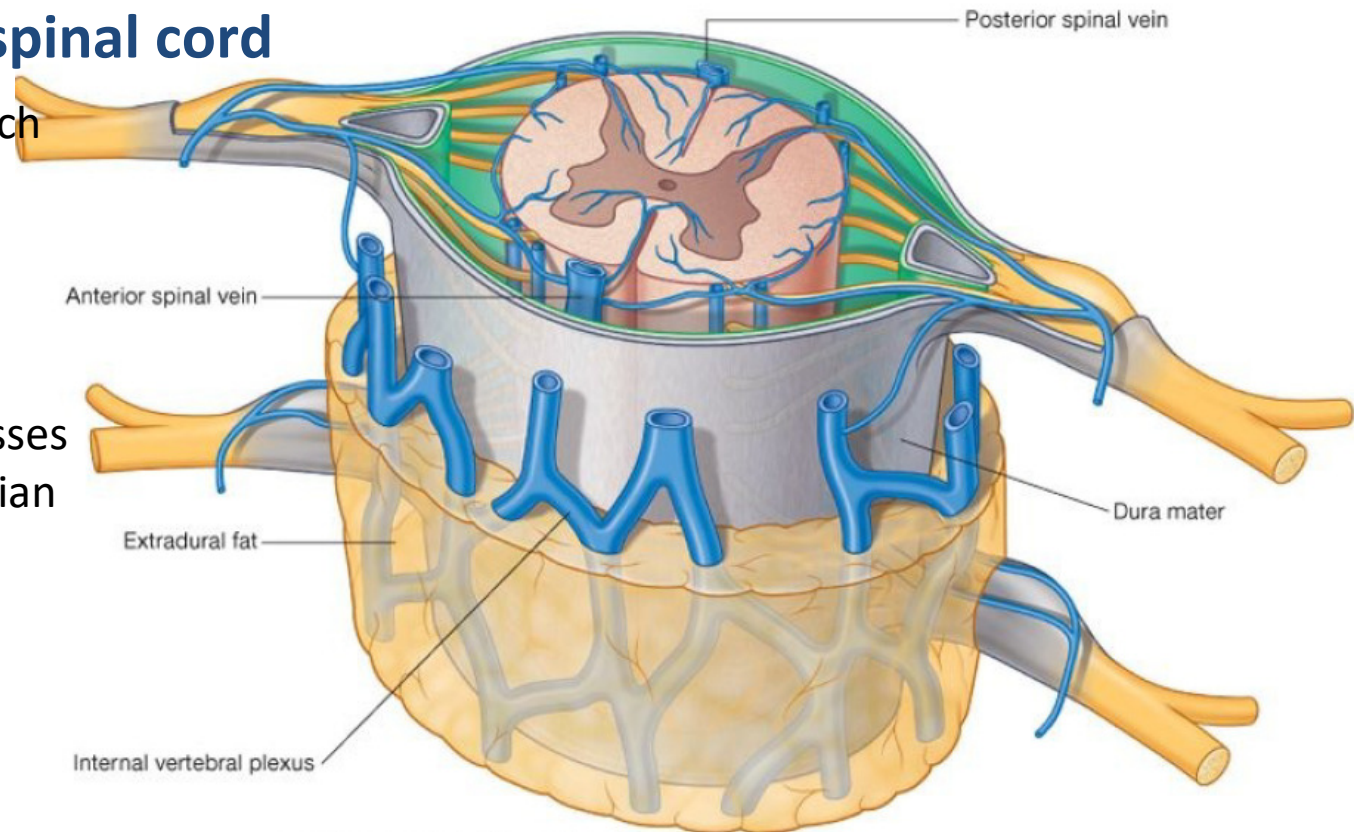
Blood supply of spinal cord

- **segmental spinal arteries, arise from:**
 - Vertebral arteries
 - Deep cervical arteries in the neck
 - Posterior intercostal arteries in the thorax
 - lumbar arteries in the abdomen
- **Branches :**
 - **Anterior radicular arteries**
 - **Posterior radicular arteries**
 - **Segmental medullary arteries**
- **Artery of Adamkiewicz**



Venous drainage of spinal cord

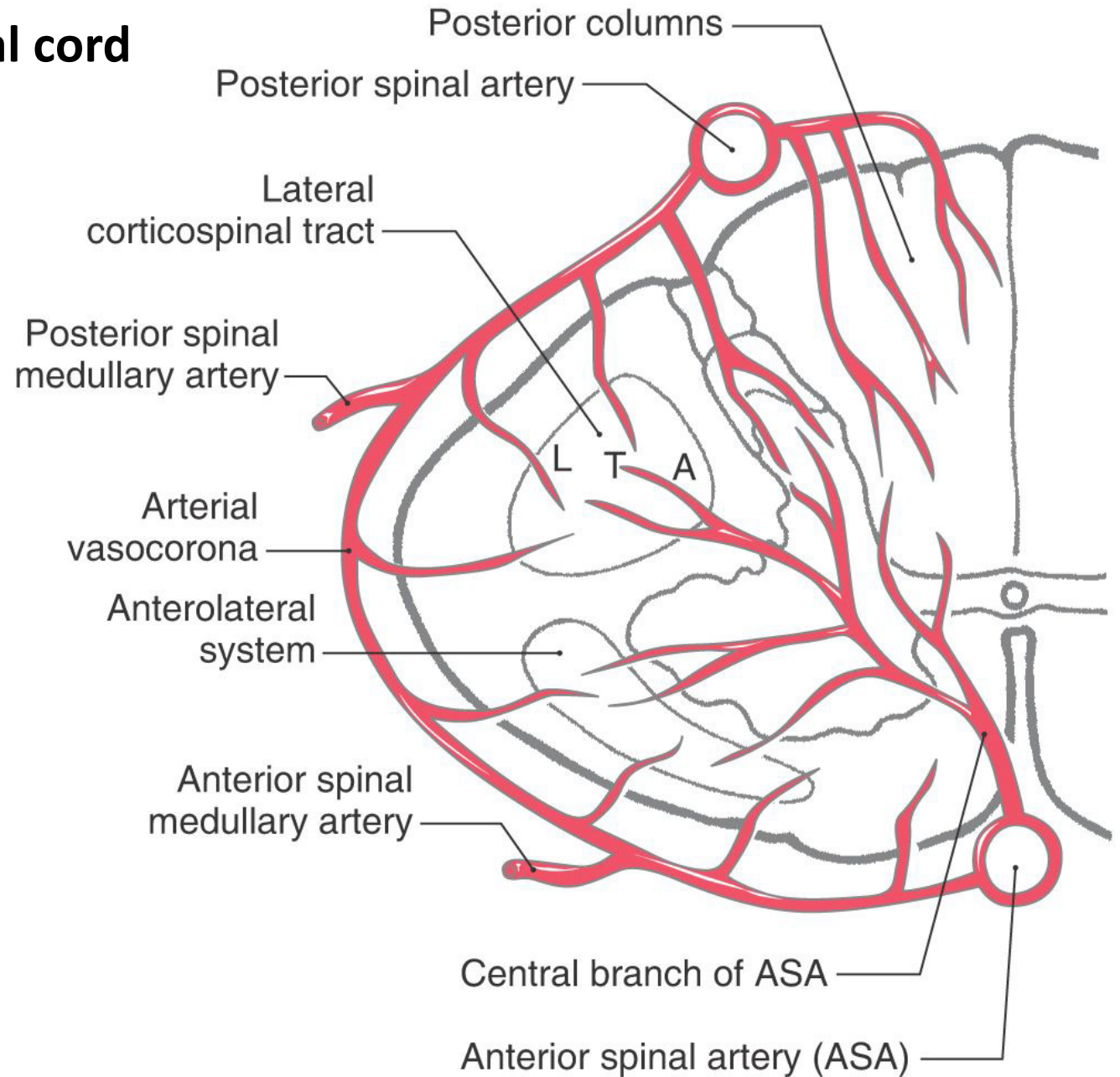
- Two pairs of veins on each side
- One midline channel parallels the anterior median fissure
- One midline channel passes along the posterior median sulcus



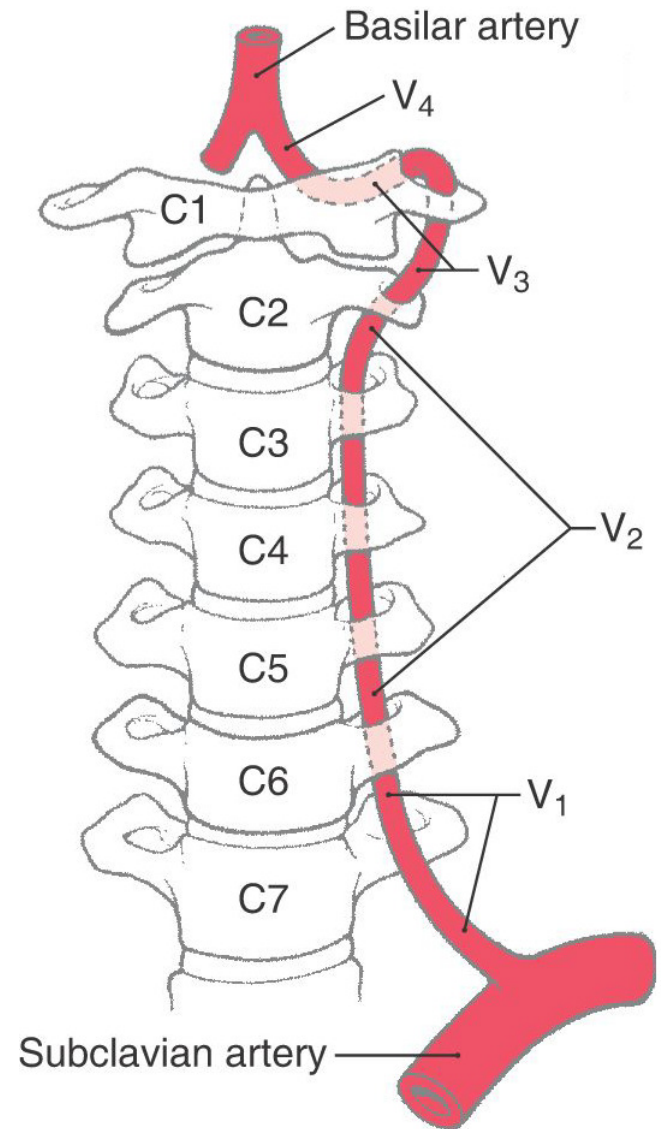
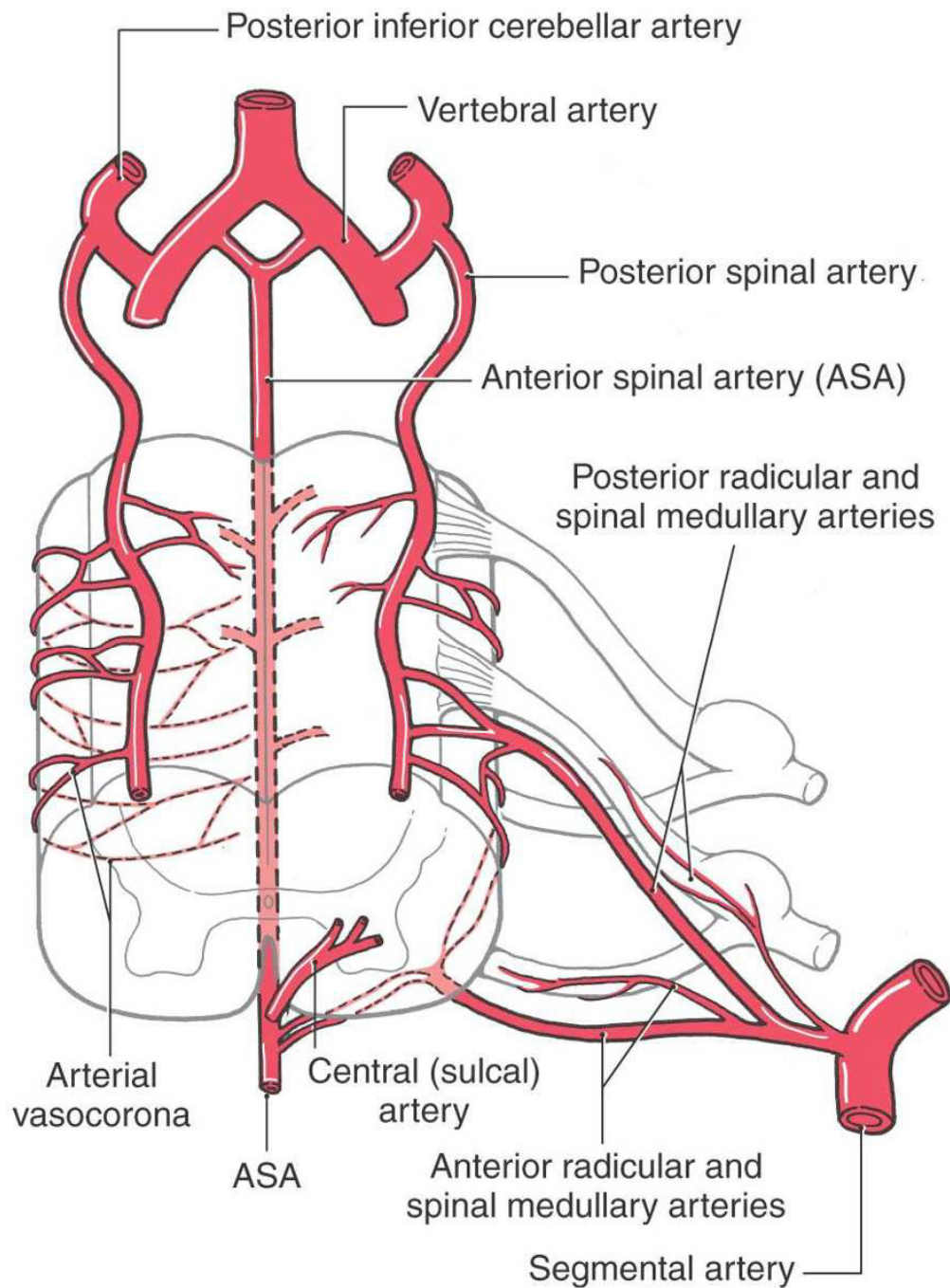
- Drain into an extensive internal vertebral plexus in the extradural (epidural) space of the vertebral canal
- Then drains into segmentally arranged vessels that connect with major systemic veins
 - Azygos system in the thorax.
 - The internal vertebral plexus
 - Intracranial veins

Blood supply of spinal cord

- Terminal branches of the spinal medullary arteries join to form **arterial vasocorona**.
- **The posterior spinal arteries and arterial vasocorona** : The posterior columns and peripheral parts of the lateral and anterior funiculi
- **The anterior spinal artery**: Most of the gray matter and the adjacent parts of the white matter

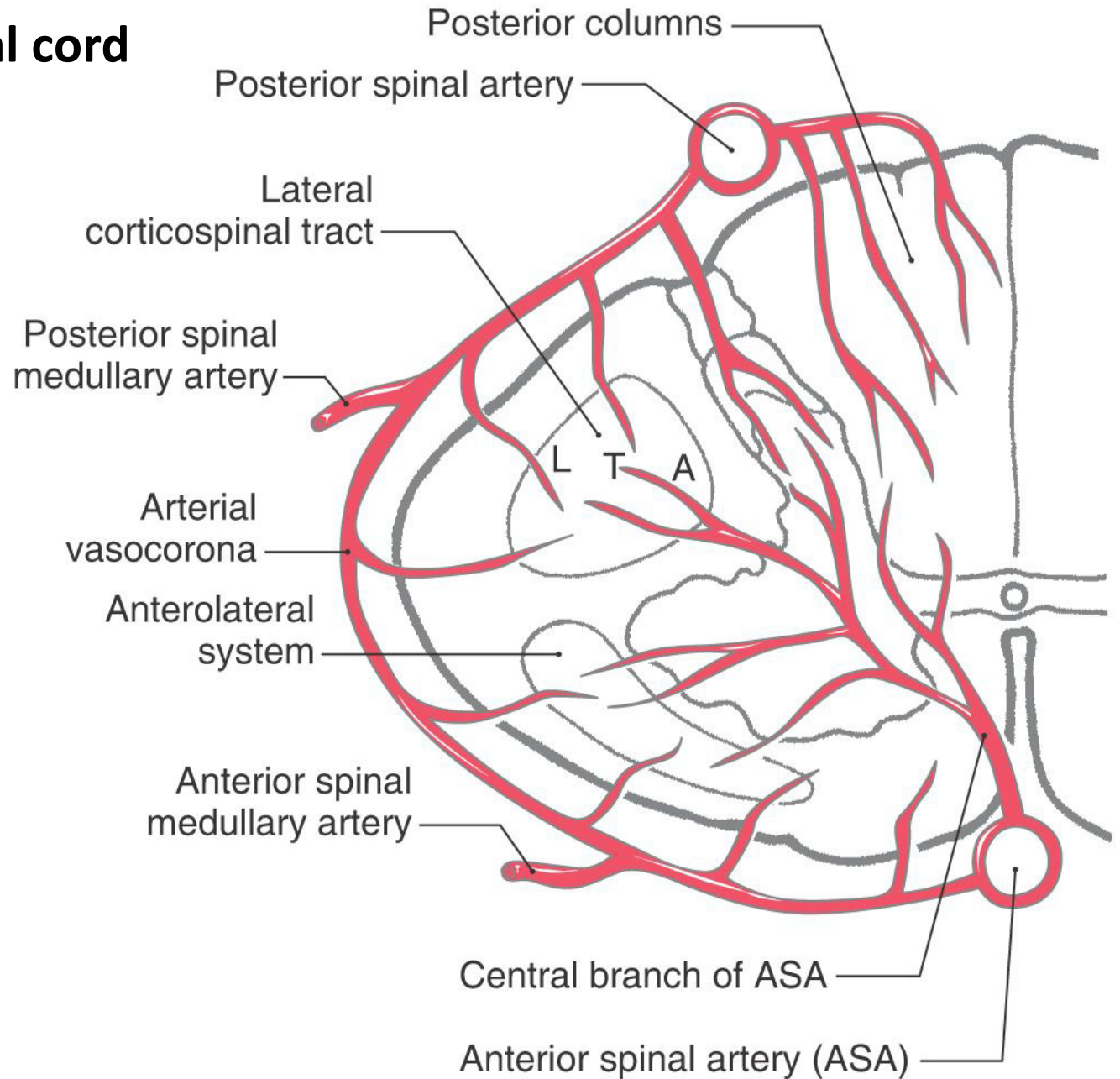


Blood supply of spinal cord



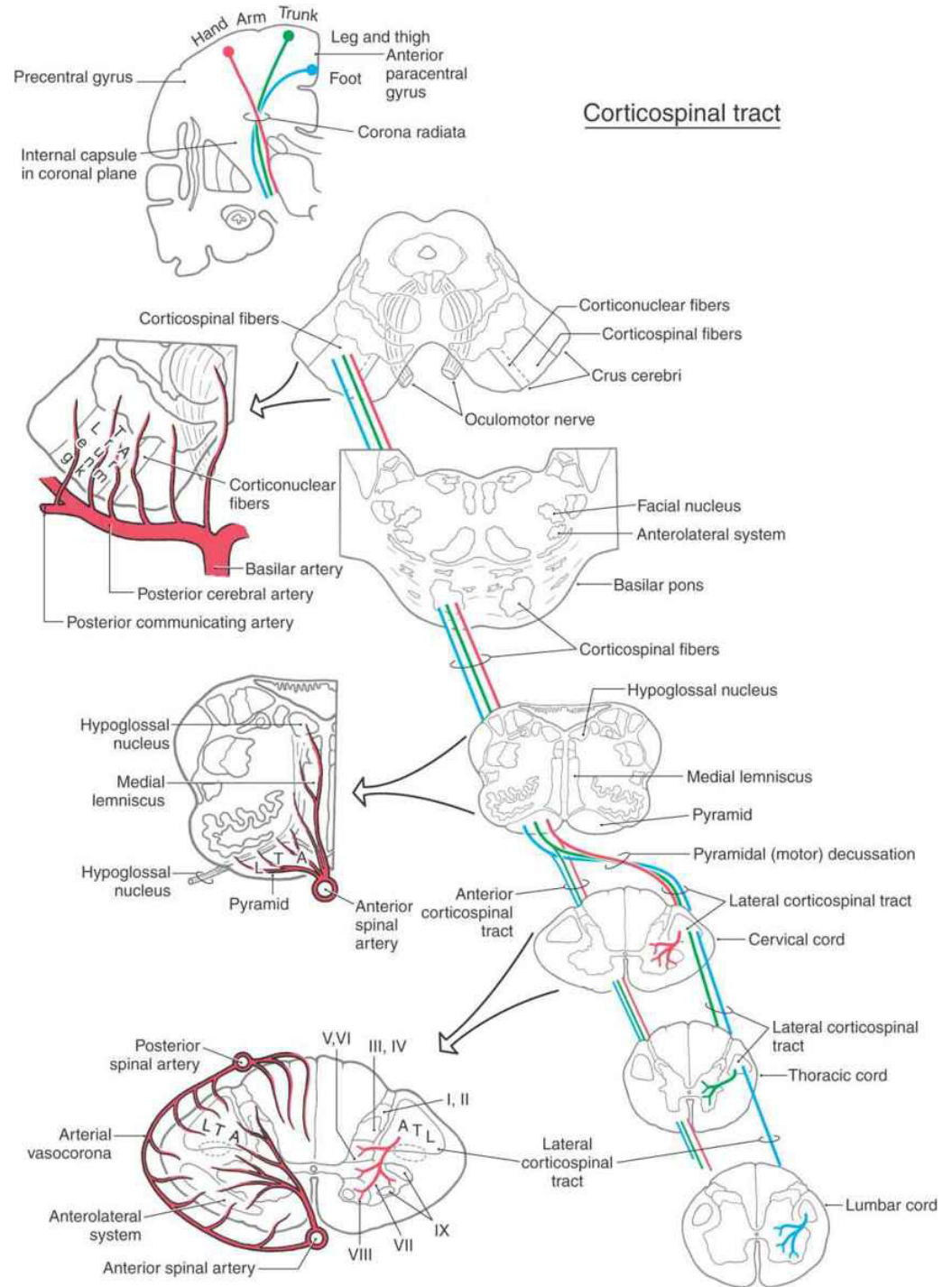
Blood supply of spinal cord

- Terminal branches of the spinal medullary arteries join to form **arterial vasocorona**.
- **The posterior spinal arteries and arterial vasocorona** : The posterior columns and peripheral parts of the lateral and anterior funiculi
- **The anterior spinal artery**: Most of the gray matter and the adjacent parts of the white matter



Central Cord Syndrome

- may result from hyperextension of the neck
- Occludes blood supply to the cord via the anterior spinal artery
- bilateral weakness of the extremities (more so of the upper than of the lower)
- pain and thermal sensation loss, and bladder dysfunction



- Compromise of blood flow in the **posterior spinal artery** results in:
- **Ipsilateral reduction or loss of discriminative, positional, and vibratory tactile sensations at and below the segmental level of the injury**

