

1st Practical

I-Sacrum

1- Promontory

2- **Ala** is related to

Sympathetic chain, lumbosacral trunk, obturator nerve and iliolumbar artery

3- **Ventral surface of body** is related to

- a) Median sacral vessels
- b) Sympathetic chain
- c) Piriformis which arises from the middle 3 pieces

4-The ventral sacral foramina transmit :

- Ventral rami of the upper 4 sacral nerves.
- The lateral sacral arteries.

5-The Dorsal sacral foramina transmit :

- Dorsal rami of the upper 4 sacral nerves.
- The lateral sacral arteries.

6- Sacral Canal (contents)

- Filum terminale : a prolongation of the pia mater, extends from the apex of the spinal cord down to be attached to the back of coccyx.
- Spinal dura and arachnoid; end at S2 vertebra,
- Subdural and subarachnoid spaces end at level of S2 vertebra,
- The roots of five pairs of sacral nerves and one pair of coccygeal nerves
- Internal vertebral venous

6-Sacral Hiatus

- a. Filum terminale.
- b. The 5th pair of sacral nerves.

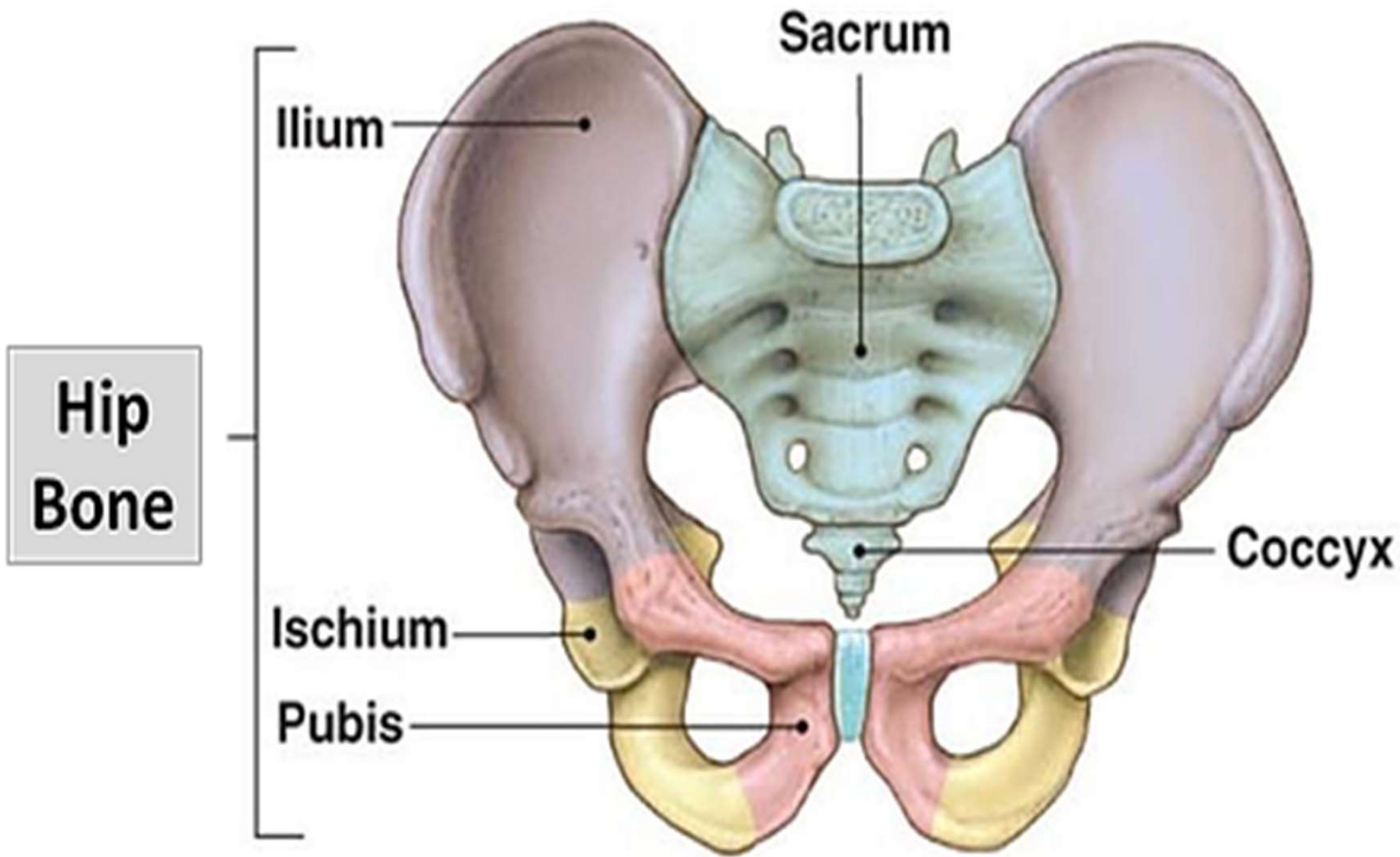
c. A pair of coccygeal nerves.

II-Hip bone

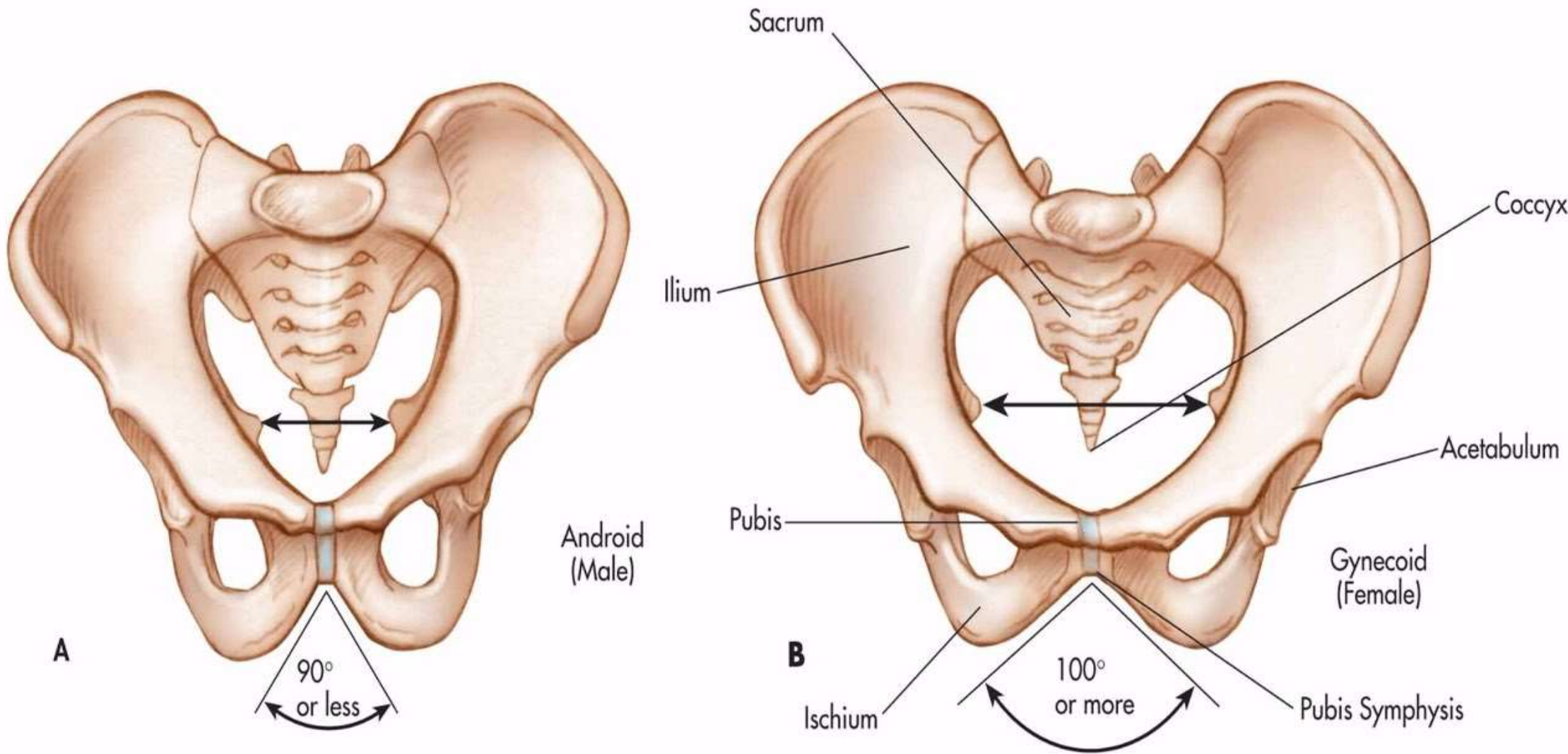
1. Arcuate line
2. Iliopubic eminence
3. Pectineal line
4. Pubic crest
5. Symphysis pubis
6. Sacro-iliac joint
7. Pubic Arch
8. Coccyx
9. Ischial tuberosity
10. Ischial spine
11. Ischiopubic rami
12. Sacrotuberous ligaments
13. Identify boundaries of pelvic inlet ,outlet and their diameters
14. Differentiate between male and female pelvis

III-Levator ani muscle (parts , attachment ,nerve supply ,action)

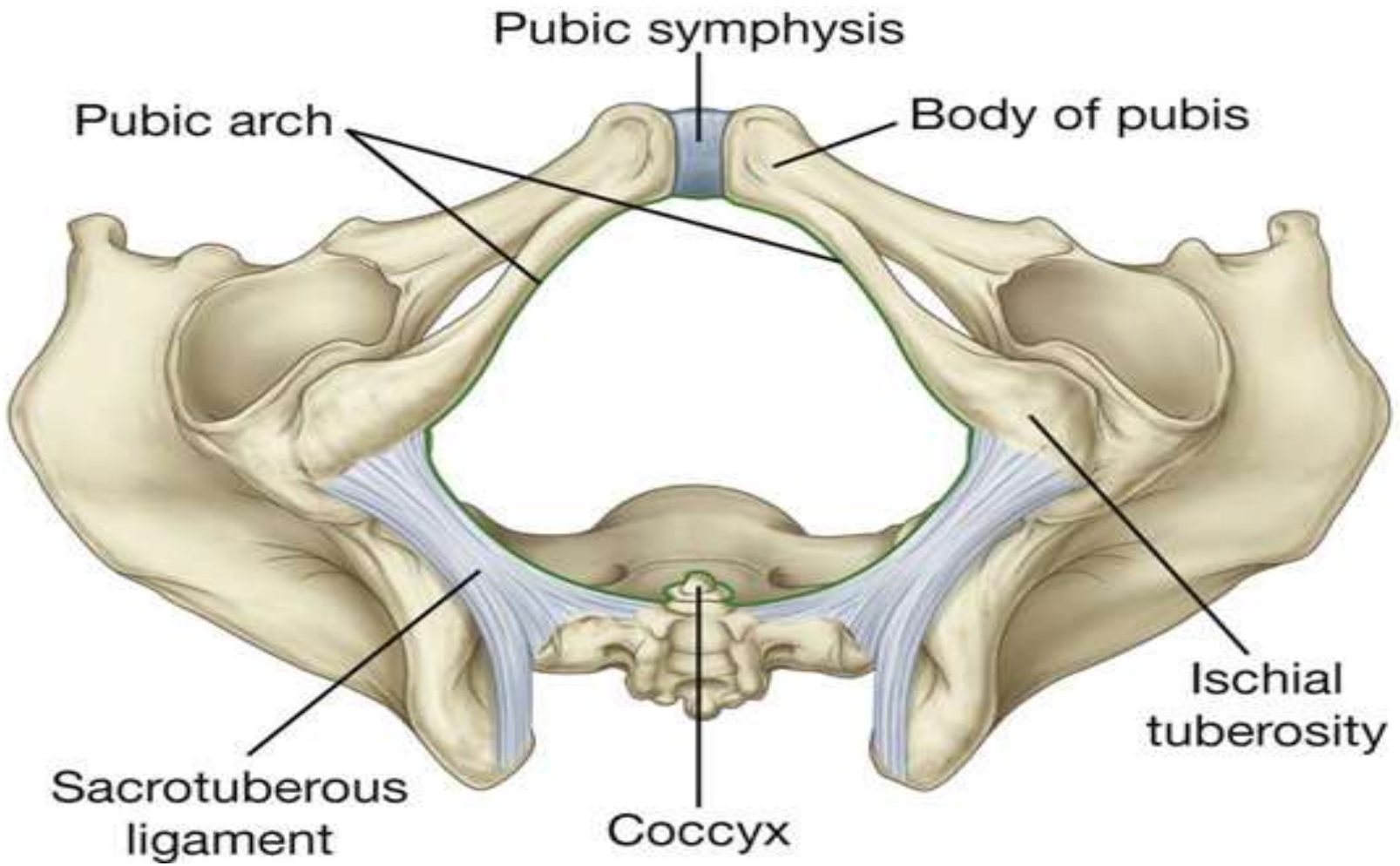
IV- Internal iliac artery (beginning ,termination ,branches)



- **Mark and mention boundaries of pelvic inlet**
- **Differentiate between true and false pelvis**



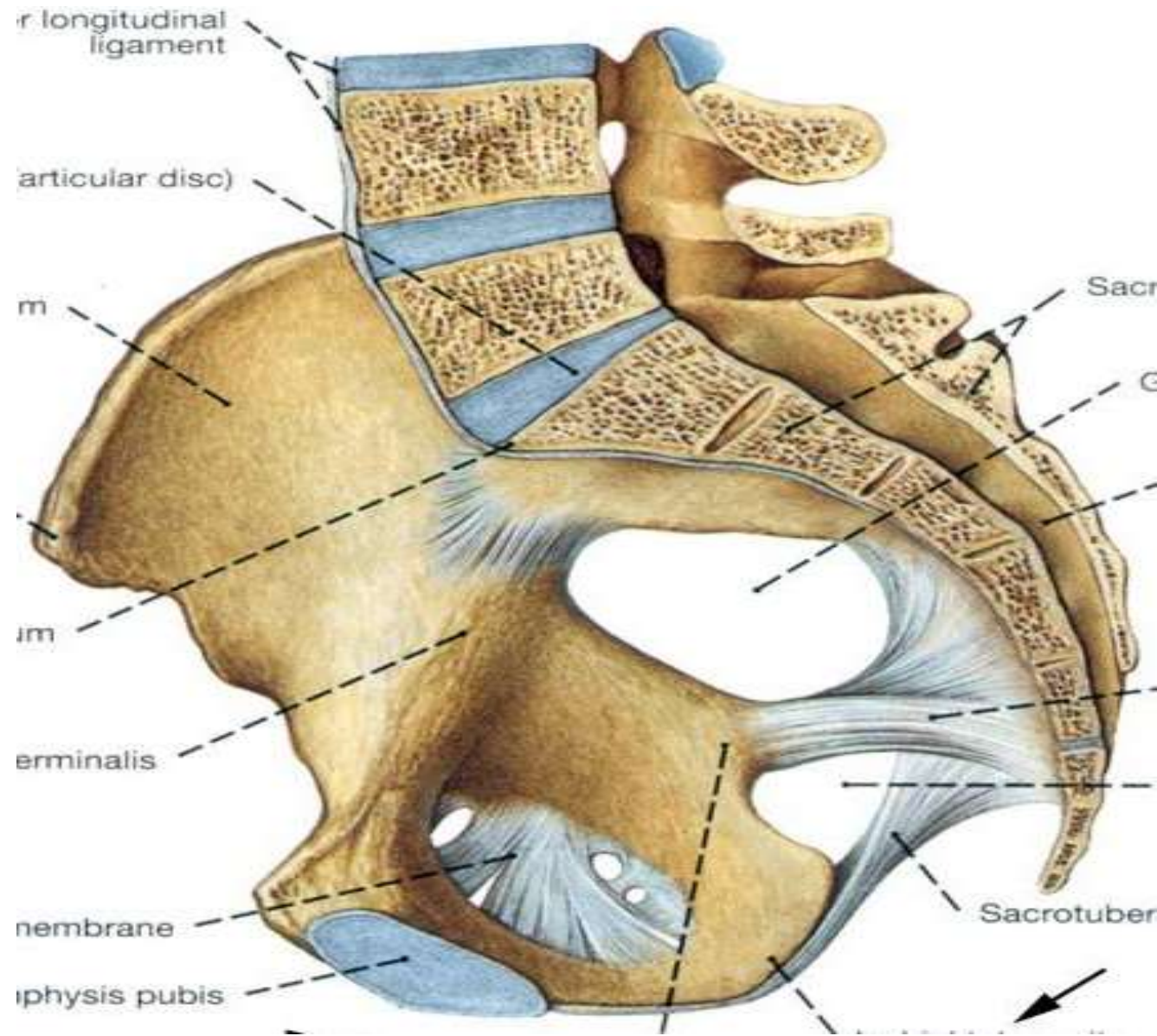
- Which is a male pelvis ?
- Mark the difference between the two pelvis



Mark and mention boundaries of pelvic outlet

Mark

- **Diagonal conjugate**
- **Obstetric conjugate**



Iliolumbar artery

lumbosacral trunk

Obturator nerve

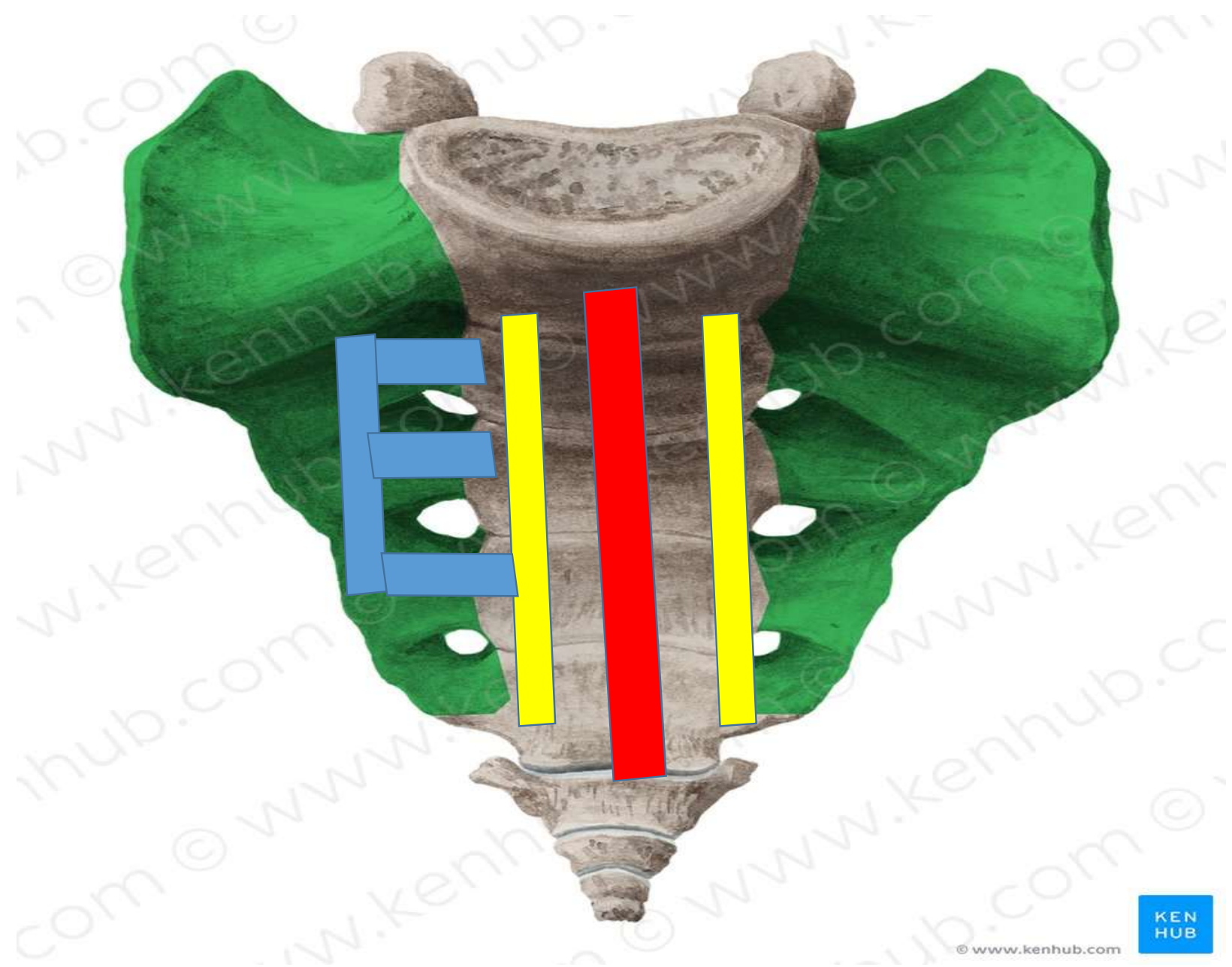Sympathetic chain

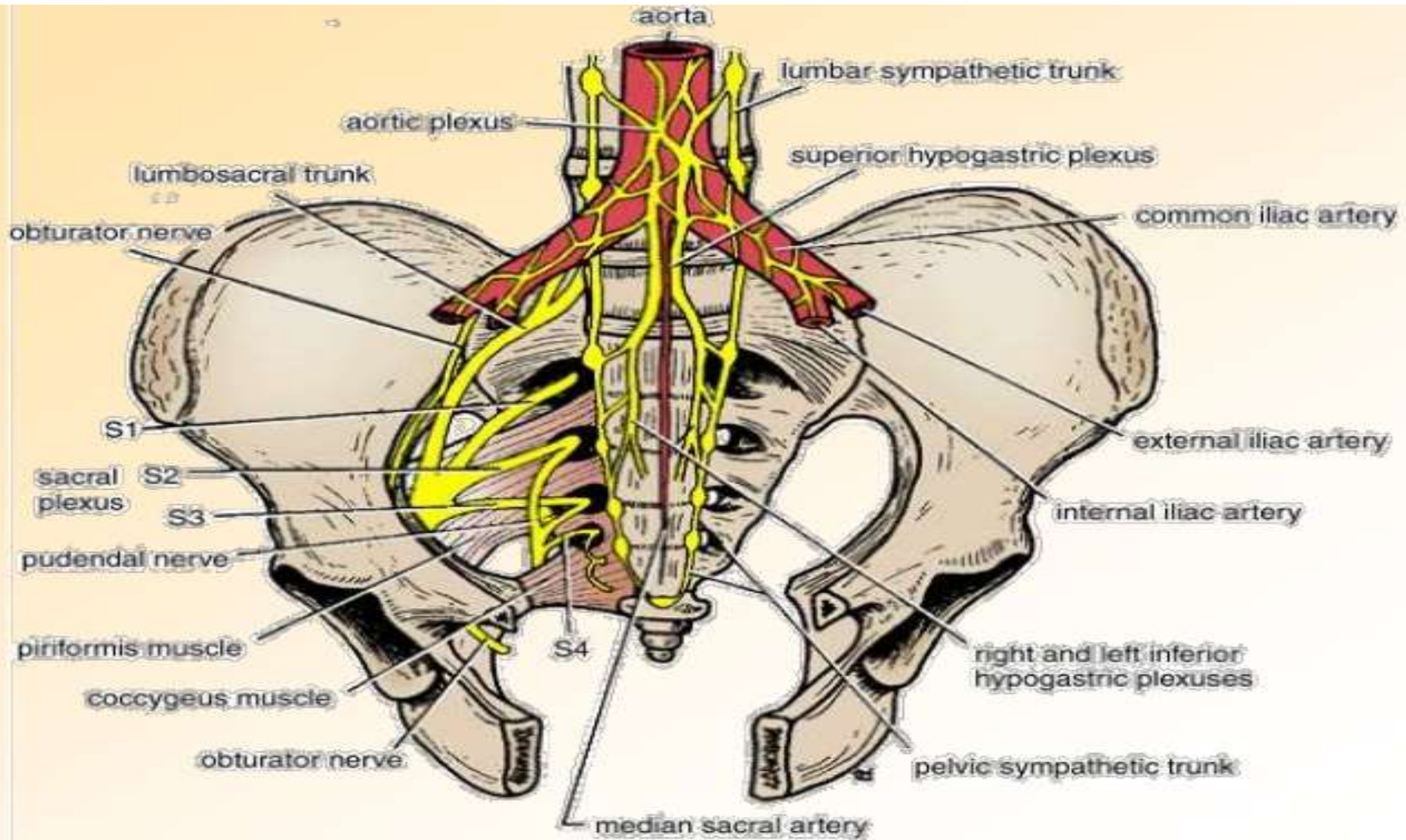


Median Sacral artery

Sympathetic chain

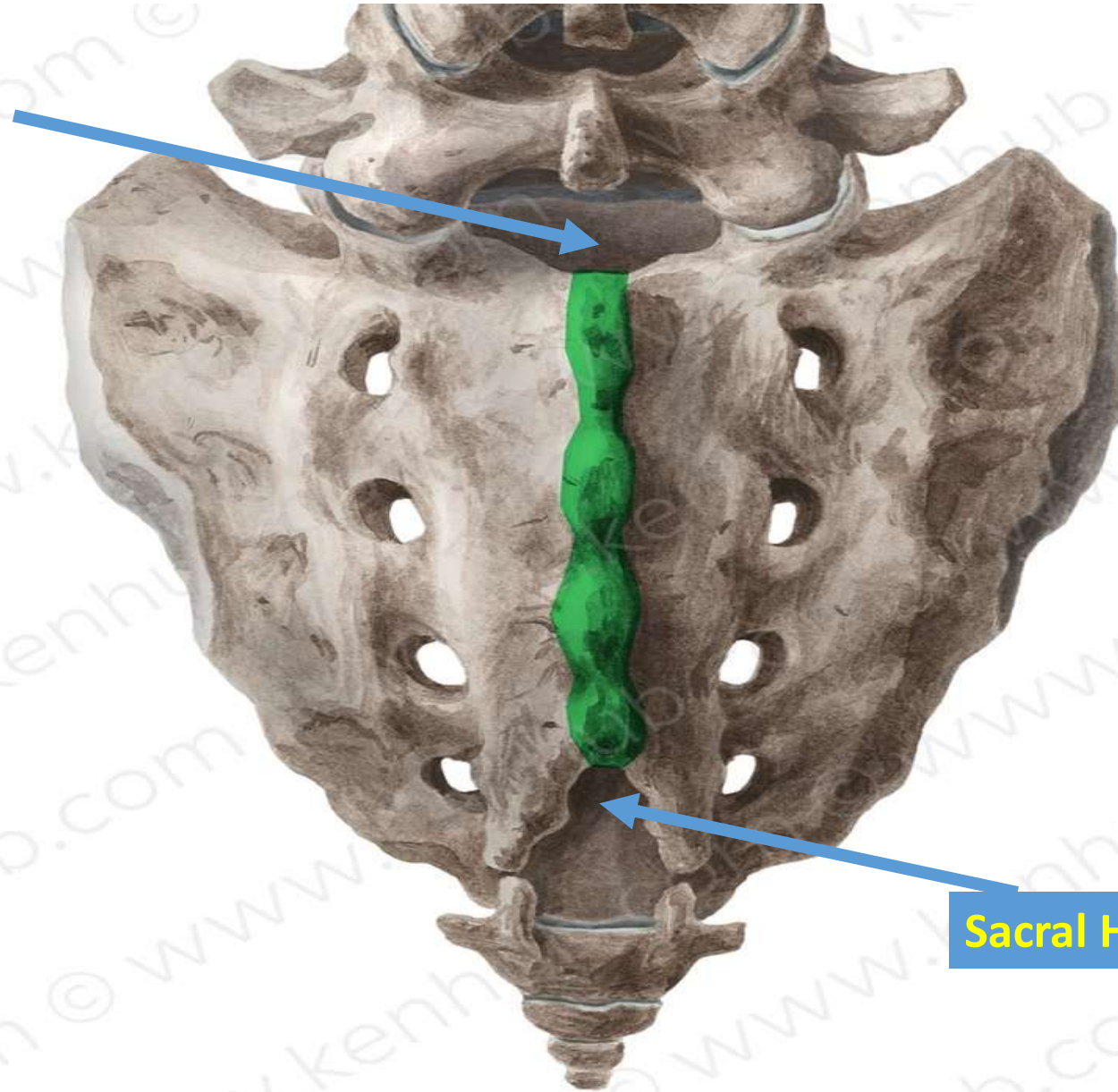
Piriformis muscle





Sacral Canal

- Filum terminal
- Spinal dura and arachnoid
- Subdural and subarachnoid
- The roots of five pairs of sacral nerves and one pair of coccygeal nerves
- Internal vertebral venous

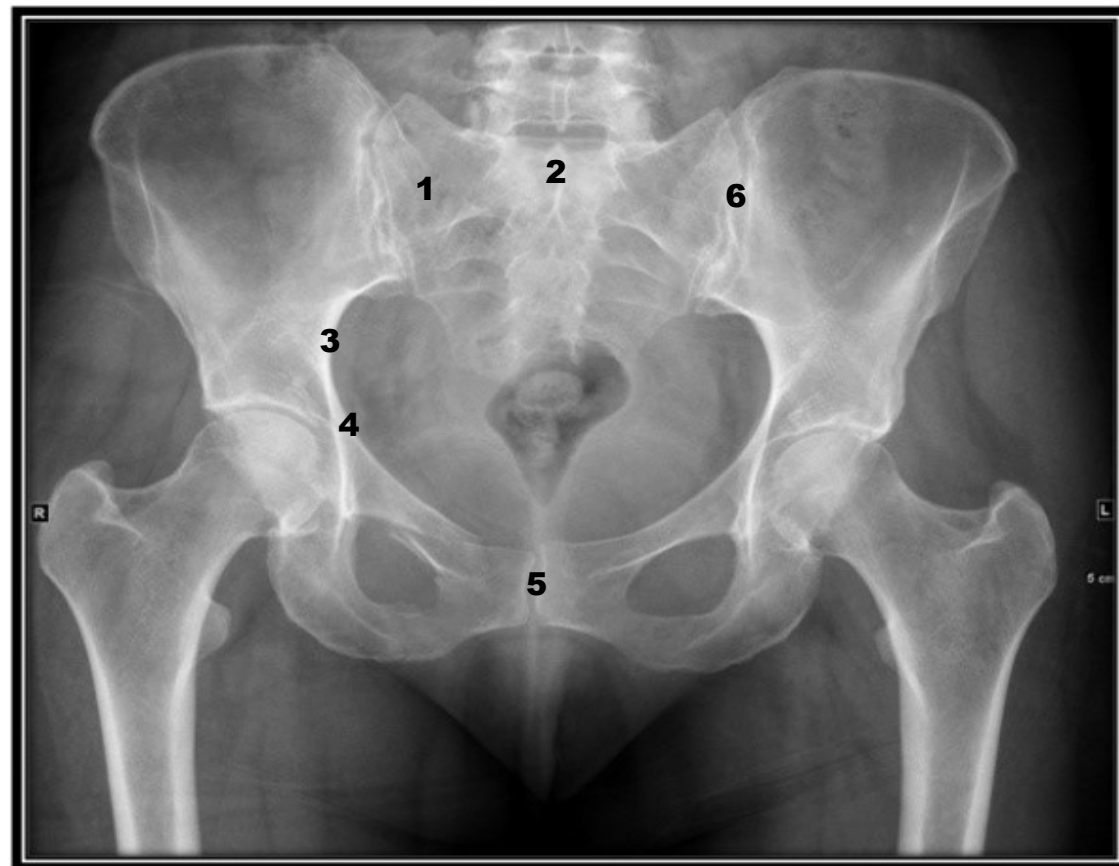
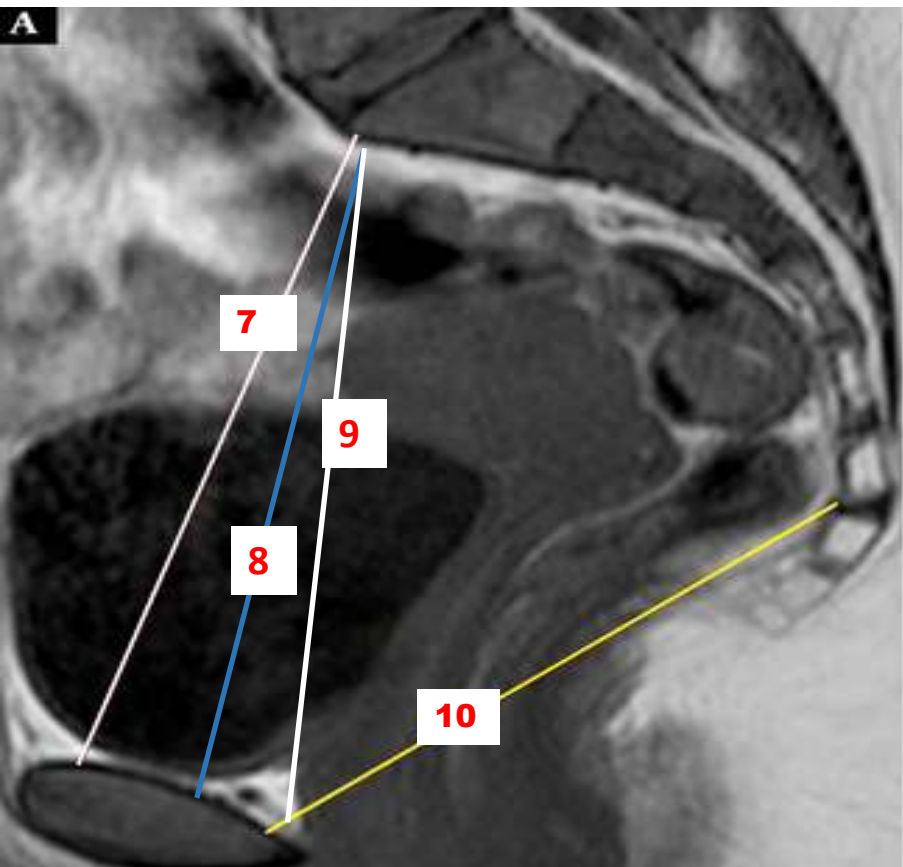


- Filum terminale.
- The 5th pair of sacral nerves.
- A pair of coccygeal nerves.

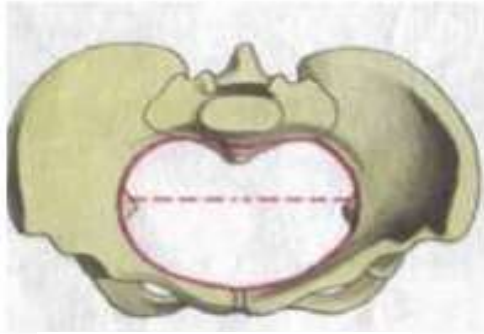
Sacral Hiatus

KEN
HUB

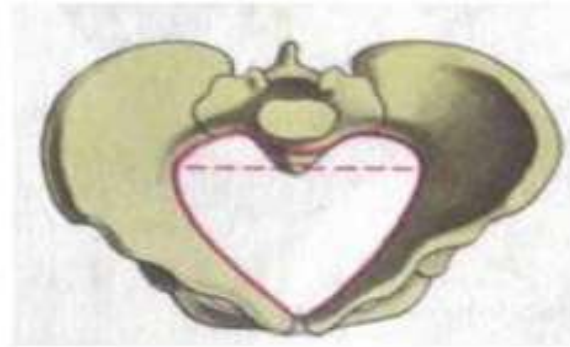
© www.kenhub.com



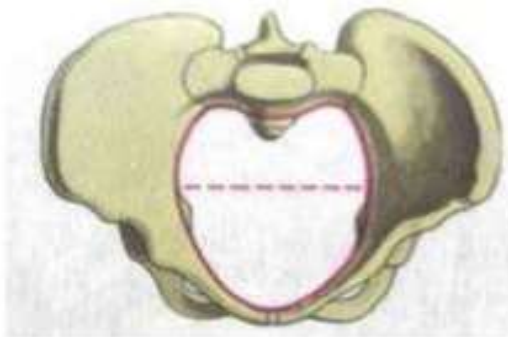
Types of pelvises



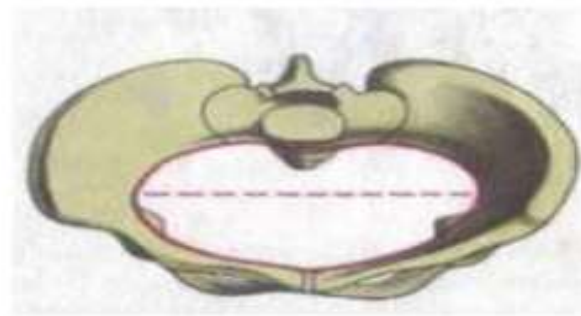
A



B

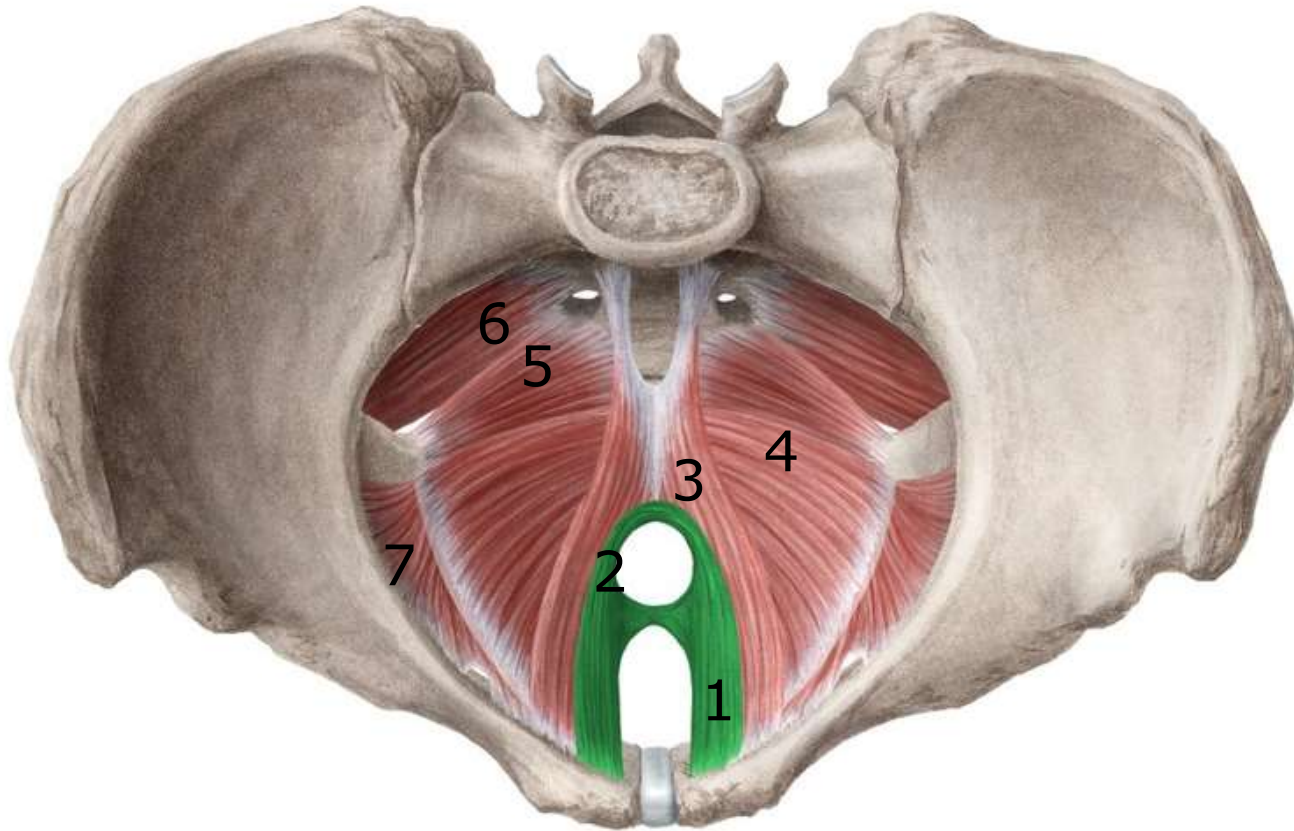


C



D

Identify type of each pelvis



Identify the labelled structure

Identify the
labelled
structure

