

Jordan University
Faculty Of Medicine

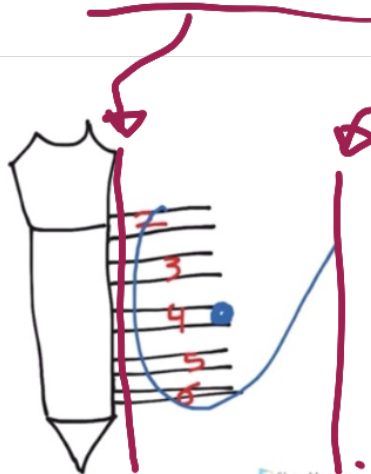


Anatomy of the Breast

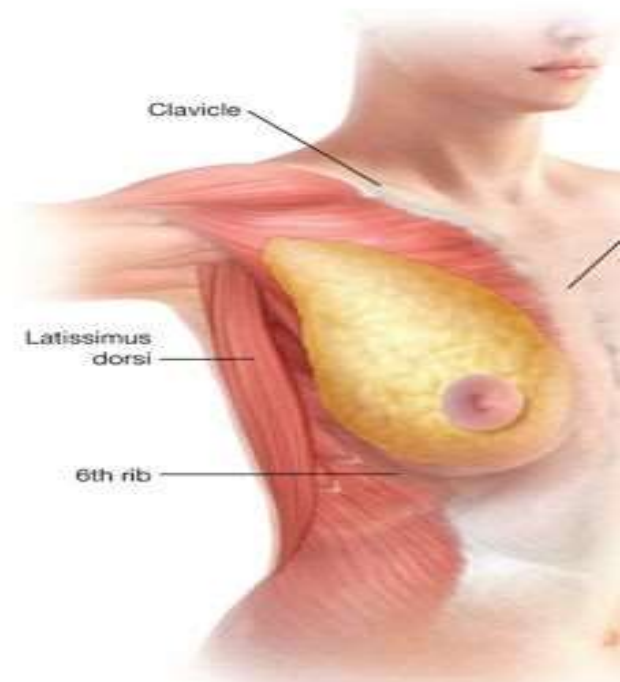
Dr. Ahmed Salman

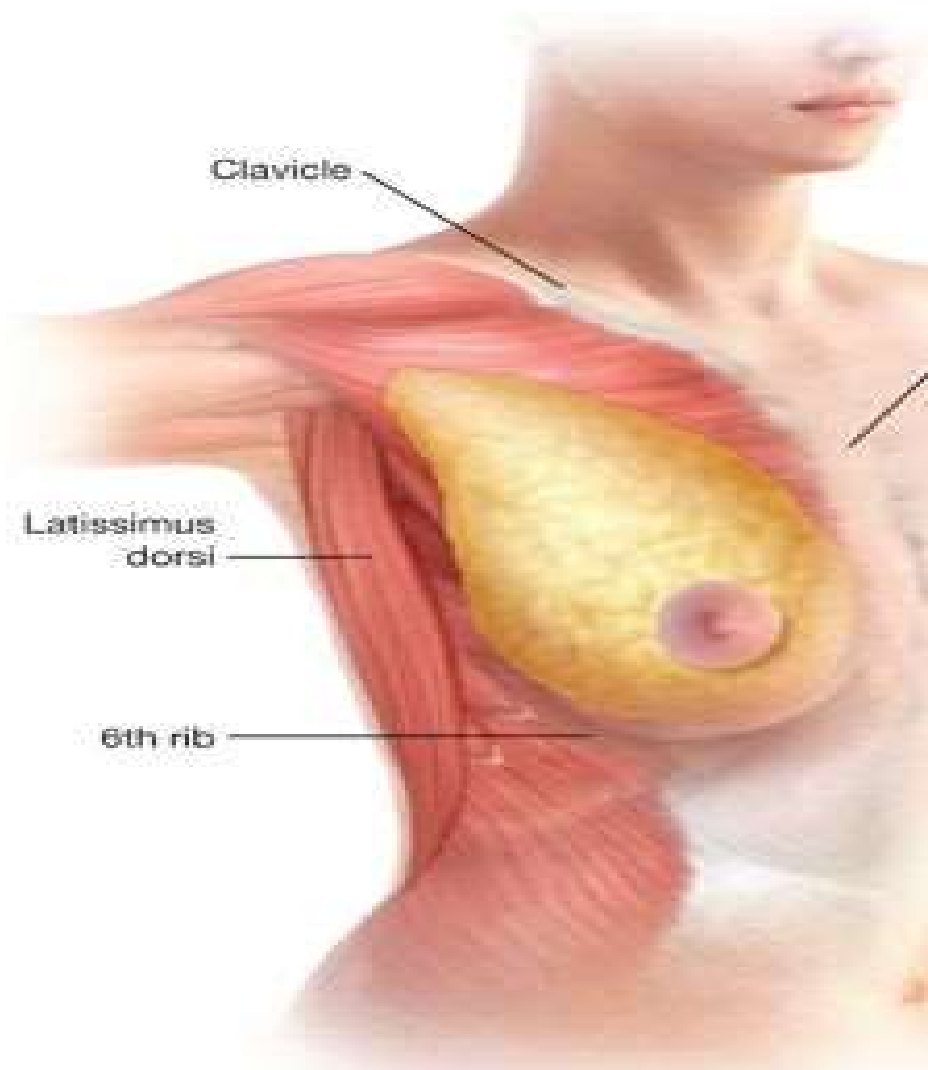
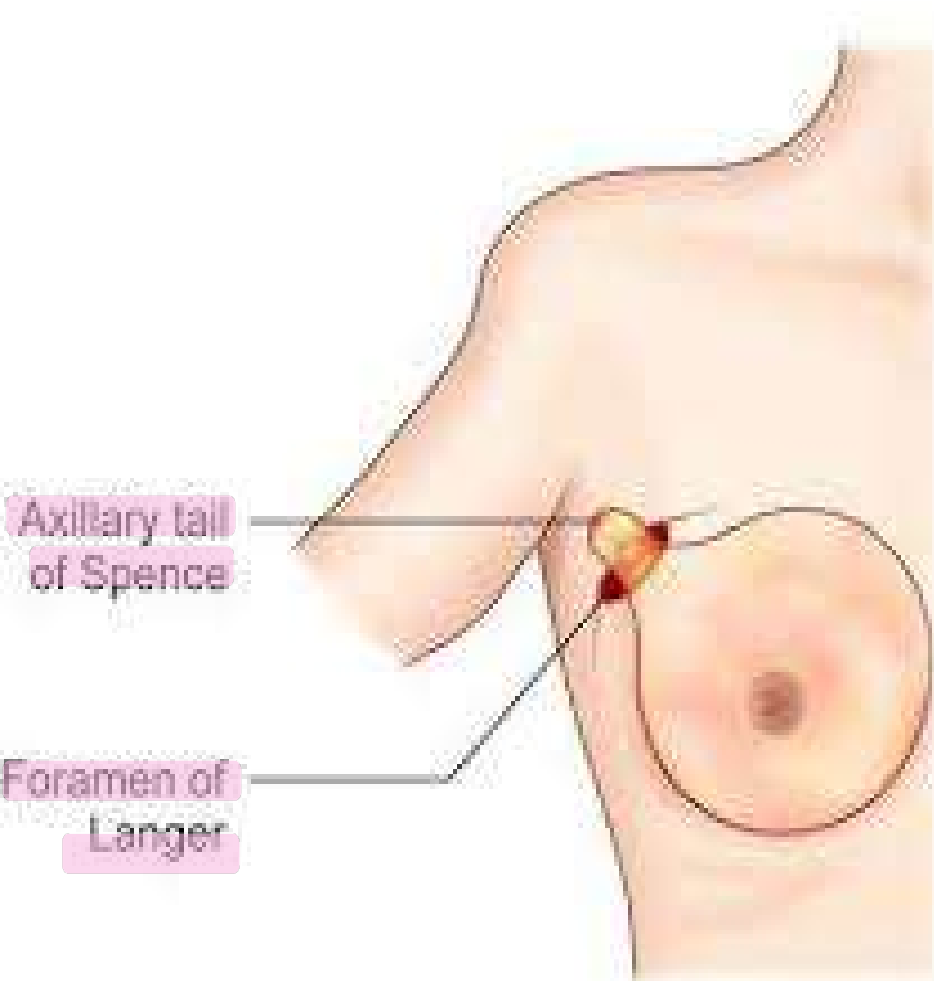
Associate professor of anatomy & embryology

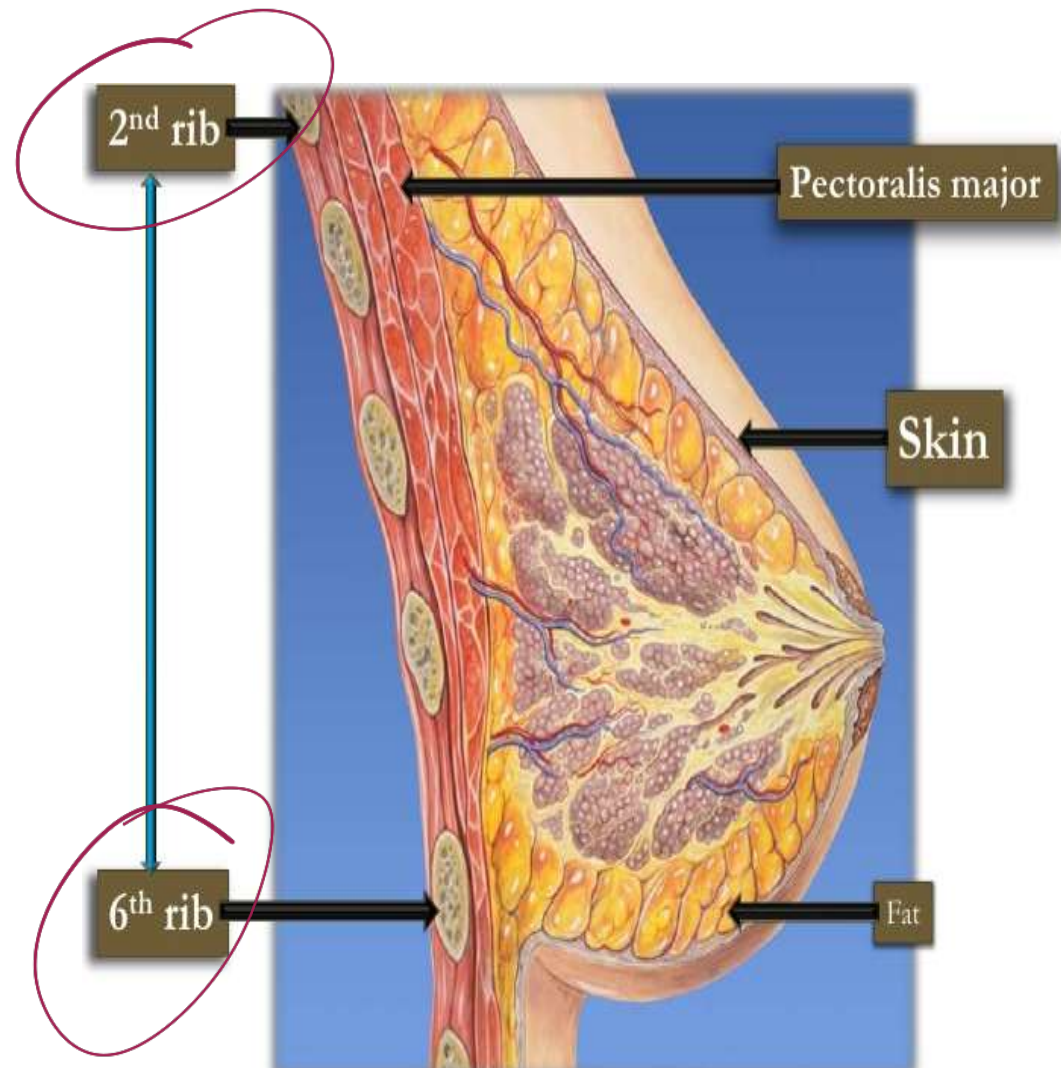
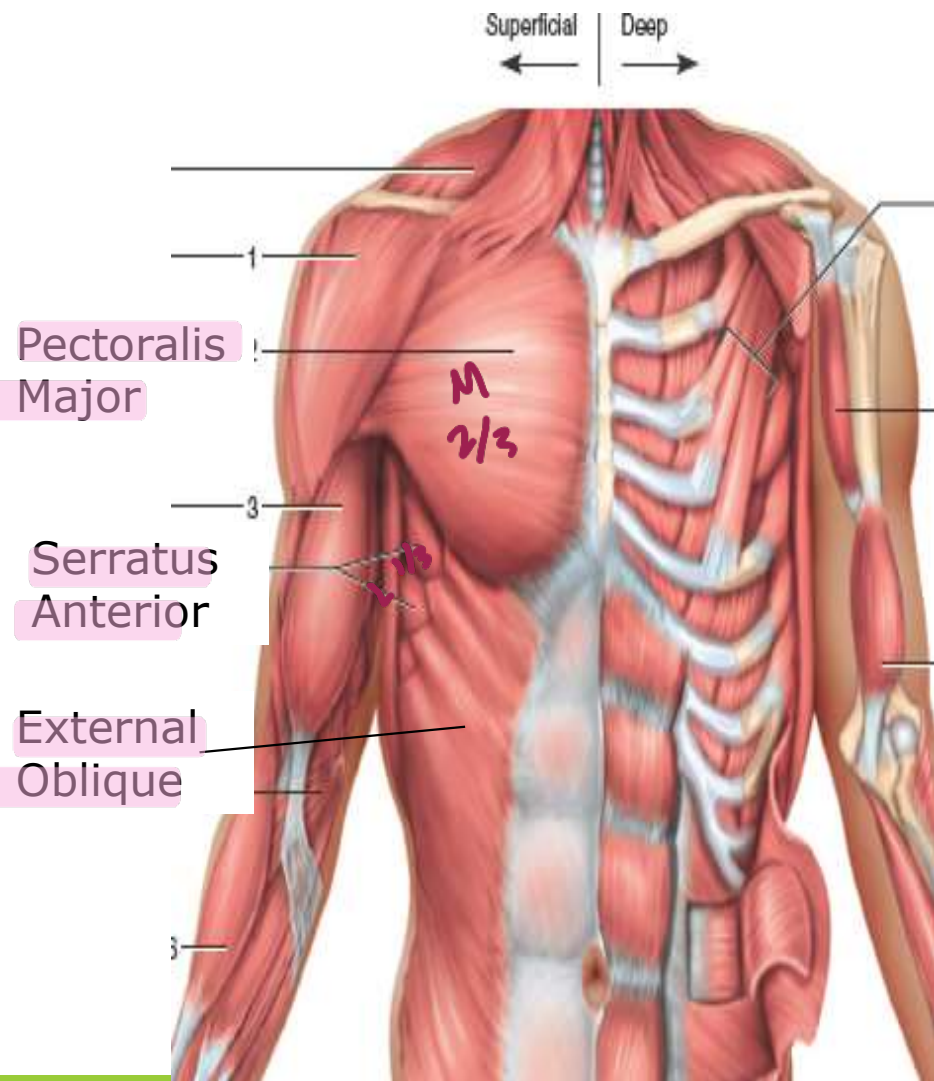
- ❖ The breasts are specialized accessory glands of the skin that secrete milk .
- ❖ They are present in both sexes.
- ❖ It is located in superficial fascia of pectoral region.
- ❖ It is axillary tail (**axillary tail of Spence**) extends upward and laterally, pierces the deep fascia and enters the axilla. It passes through an opening in the deep Pectoral fascia is known as (**foramen of langer**)
- ❖ The base of the breast extends from the **2nd to 6th rib**
- ❖ From the **lateral margin of the sternum** to the **mid axillary line** .



mid axillary





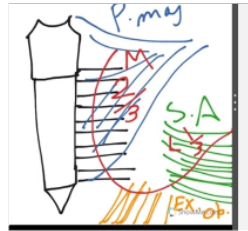


Deep Relations:

The deep surface of the breast is related to the following structures in that order :

1) The retromammary space:

- It is loose areolar tissue between the gland and deep fascia (pectoral fascia)
- Allows the free mobility of the breast over the deep fascia.



2) The deep fascia : covering the pectoralis major muscle

3) The flat base of the breast lies on the pectoralis major (medial 2/3) and serratus anterior (lateral 1/3).

4) The lower lateral part of the gland rests on the external oblique muscle of the abdomen

Structure of the breast

includes the skin, parenchyma and stroma.

1) Skin: covers the gland and fascia.

a) Nipple

conical projection from just below the centre of the breast , Lies in the 4th intercostal space

Contains

a. Circular smooth muscle erect the nipple.

b. Longitudinal smooth muscle flatten the nipple.

- Carries the opening of lactiferous ducts (15-20 openings).

b) Areola:

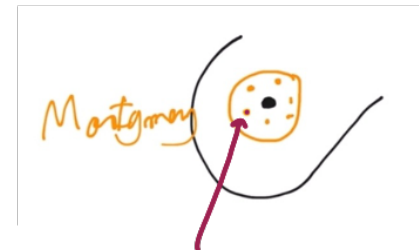- Pigmented area of skin that surrounds the base of the nipple.

- It is rich in modified sebaceous gland particularly at the outer margin.

These become enlarged during pregnancy and lactation to form raised tubercles "tubercles of Montgomery"

These glands secrete oily secretin, which has a great importance to lubricate the nipple and areola and prevents them from cracking during lactation

➤ Fat and hair are absent under the areola and nipple .



2) The stroma : The gland has no capsule. The stroma is divided into :

1) Fibrous stroma

- Forms fibrous septa known as **suspensory ligaments of Cooper.**
- The septa divide the gland into 15-20 lobules.
- The septa anchor the skin and the gland to the pectoral fascia.

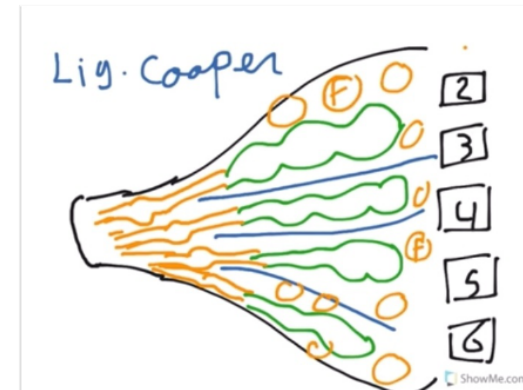
2) Fatty stroma:

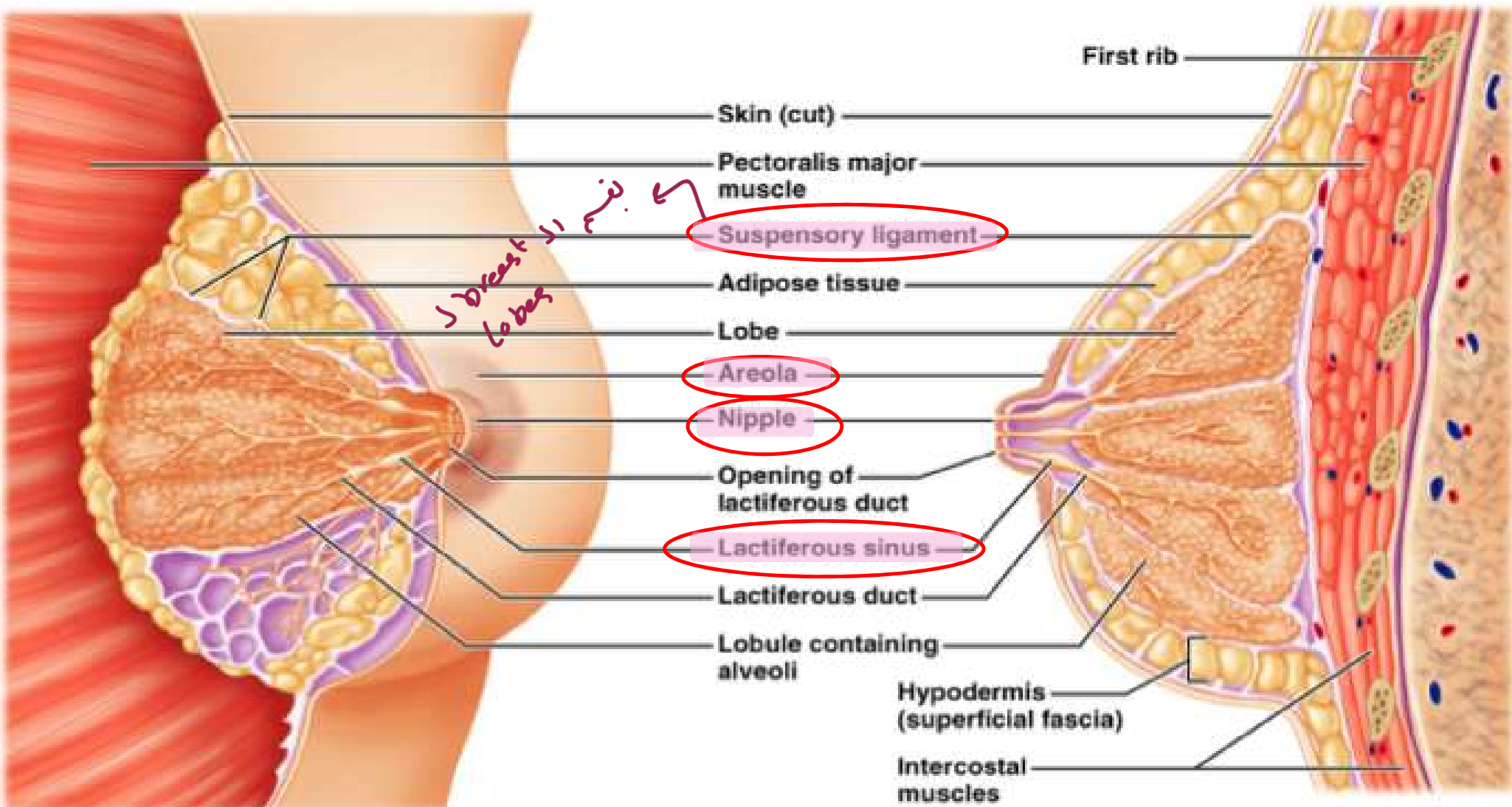
- Forms the main bulk of the gland , The gland is embedded into it
- It is responsible of the smooth contour of the breast.

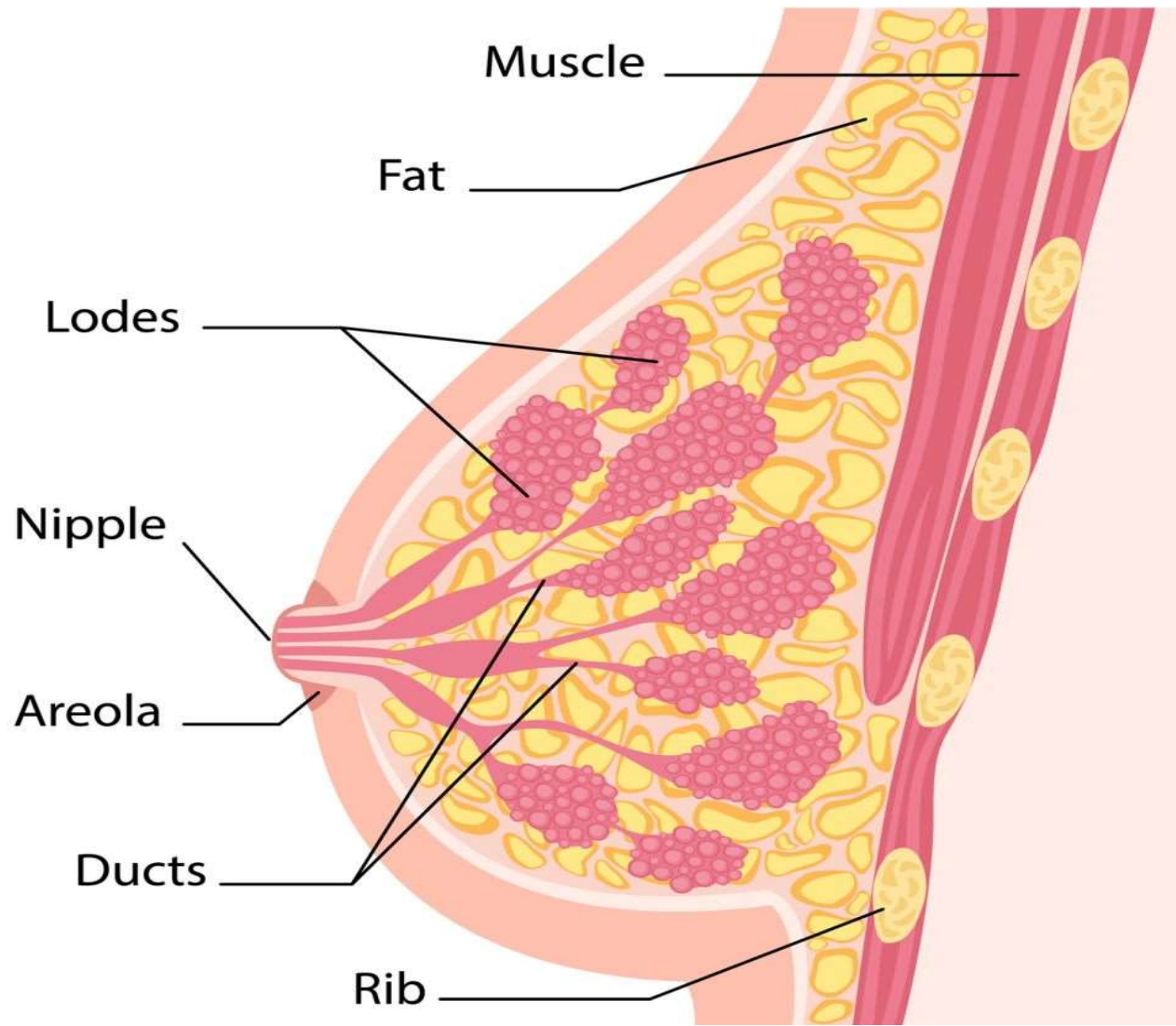
3) Parenchyma (mammary gland):

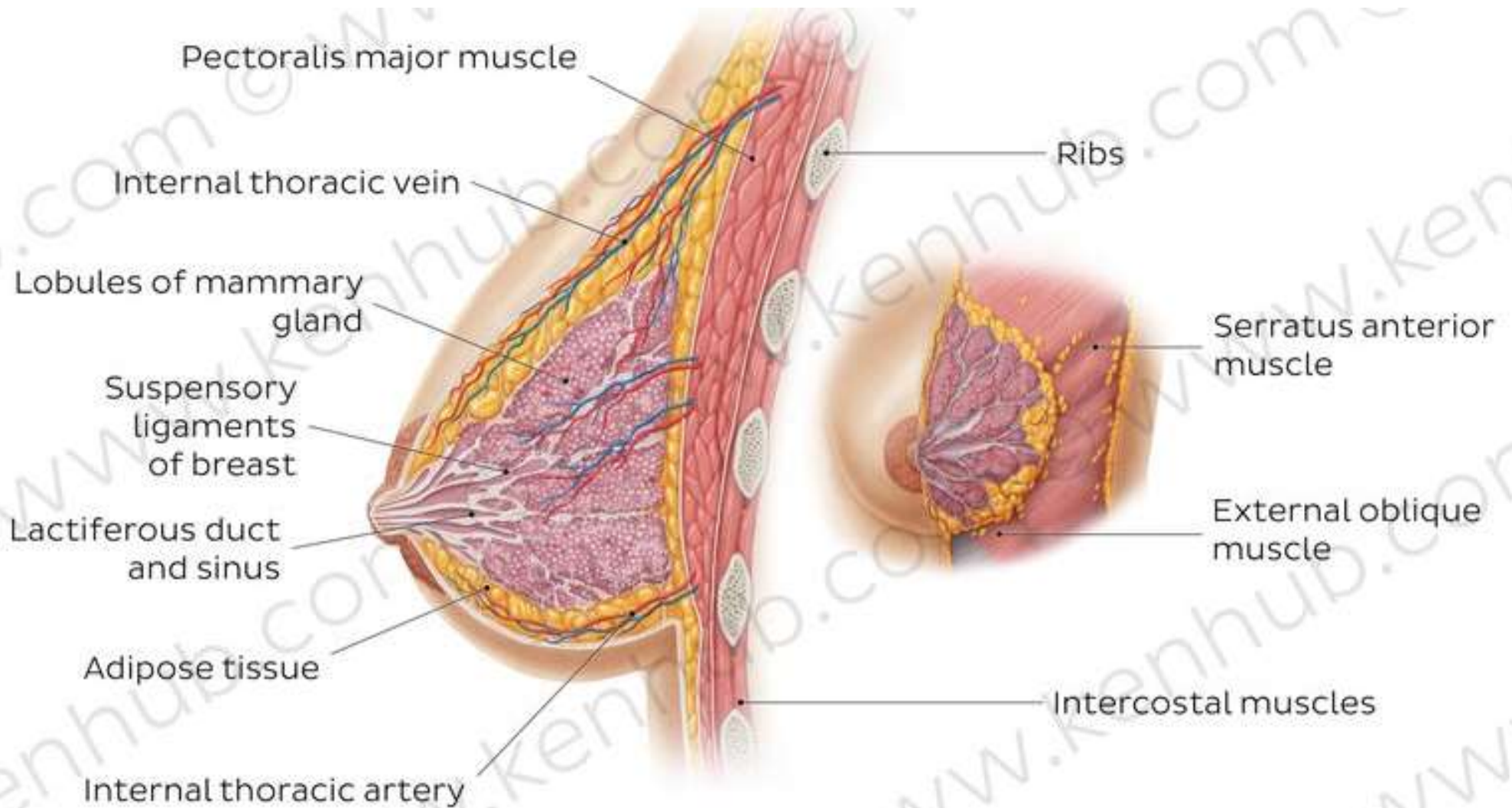
- Consists of the glandular tissue which secretes milk.
- The glandular tissue is divided into 15-20 lobules
- Each lobule has a **lactiferous duct.**

The **lactiferous duct dilates under the areola to form to lactiferous sinus** then become narrow again to **open on the summit of the nipple.**









زِي الساعَة

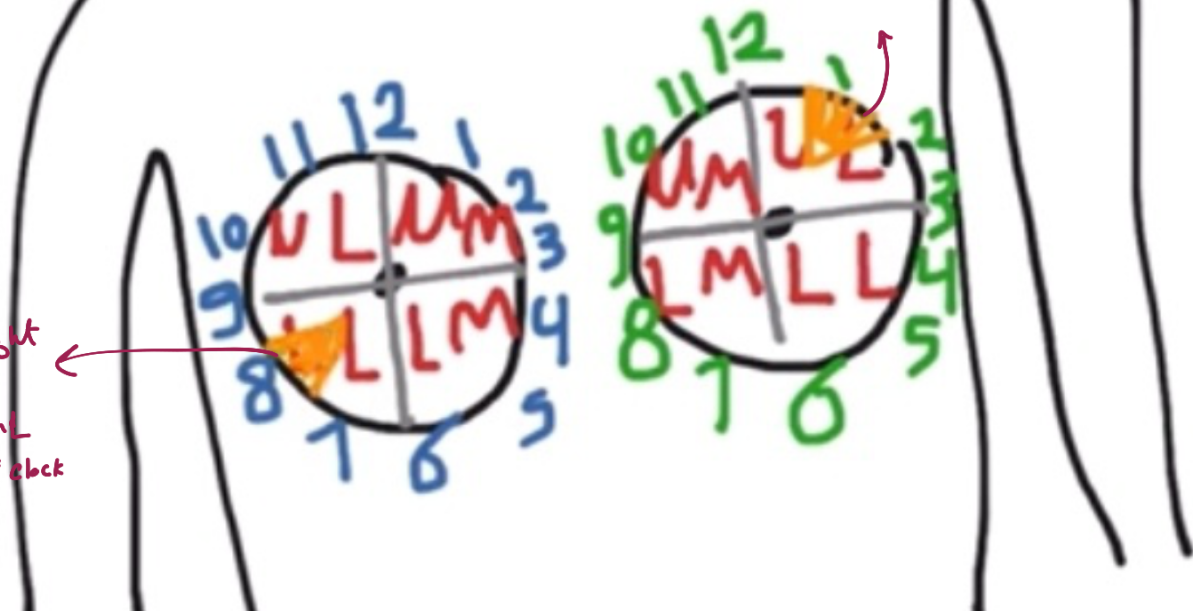R+

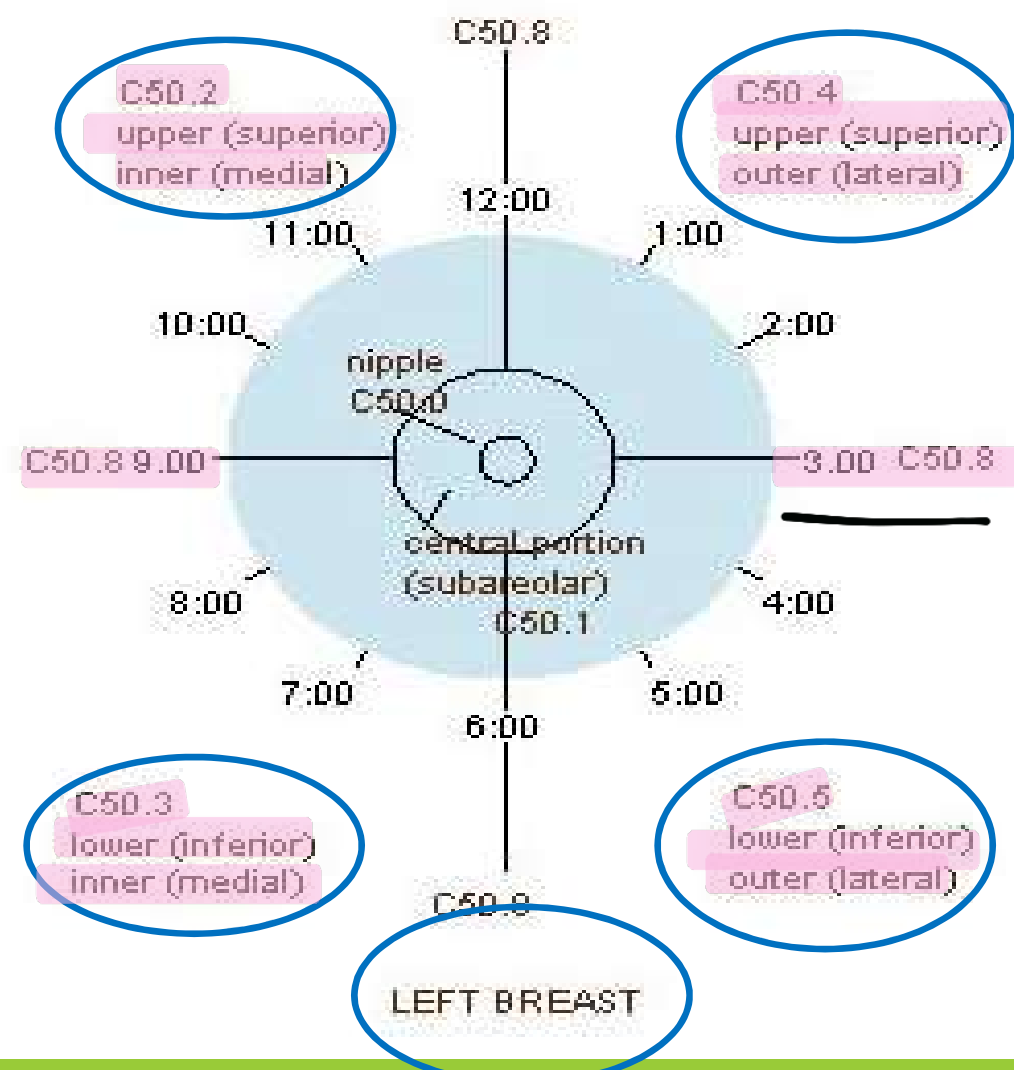
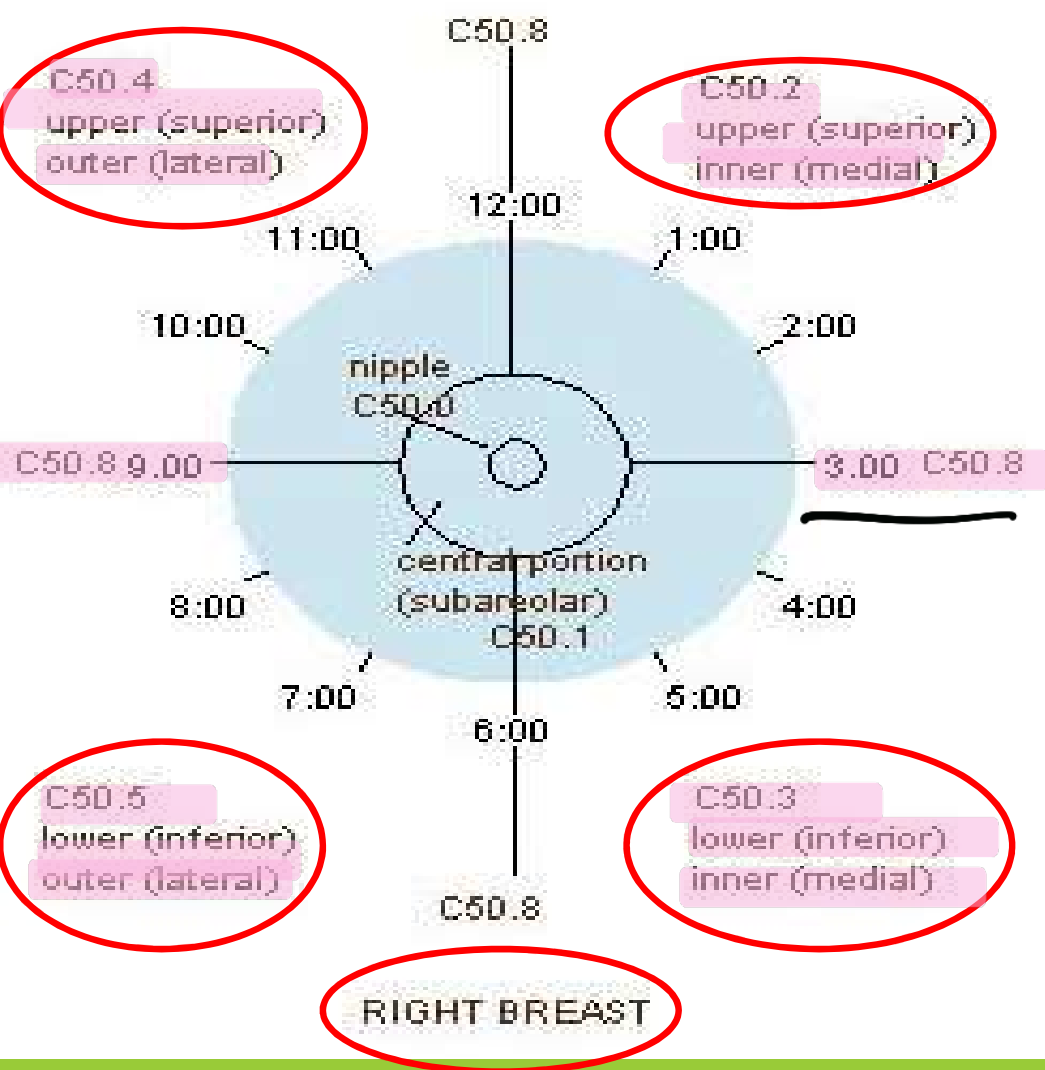
L+

لو عينا mass كيف نوصفها؟

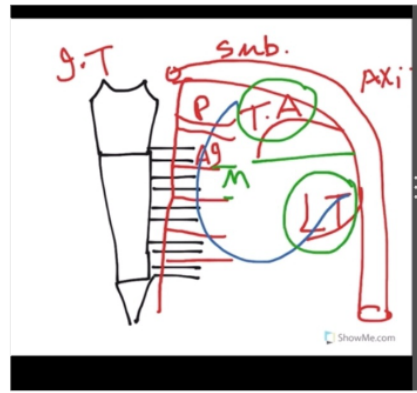
بنحكي عينا mass بل
upper lateral بل left breast
at 1 Clock

mass in Right
breast in
lower lateral
quadrant at 8 o'clock





علاج
سرطان
الثدي



Arterial supply:

1) The medial part.

- Perforating branches of the internal mammary artery
- Anterior intercostal arteries from 2-6

2) The upper lateral part

Pectoral branch of the thoracoacromial artery. (branch of 2nd part of axillary artery).

3) The lower lateral part:

Lateral thoracic artery (branch of 3rd part of axillary artery).

Venous drainage :

- The subcutaneous tissues → venous circle at the base
- The gland and stroma → small veins that accompany the arteries → internal mammary and axillary veins

Pectoral branch thoracoacromial artery

Lateral

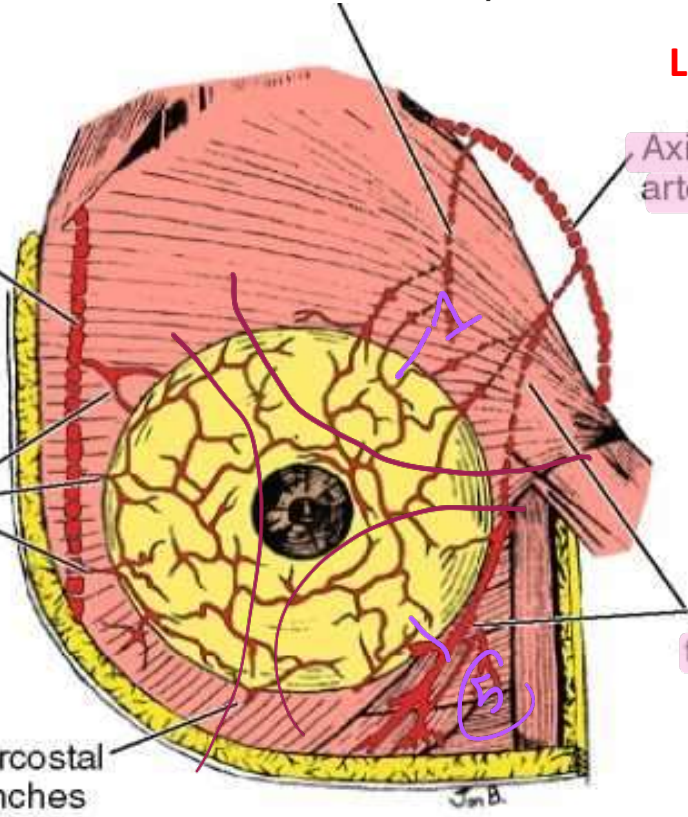
Axillary artery

Internal mammary artery

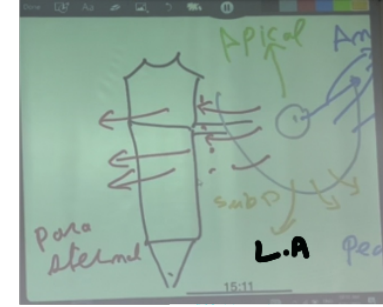
Anterior intercostal perforating arteries

Lateral thoracic artery

Intercostal branches of arteries



* 2/1 *



Lymphatic drainage of the female breast:

The superficial lymphatics, form a dense plexus deep to the areola which is called the *subareolar plexus*

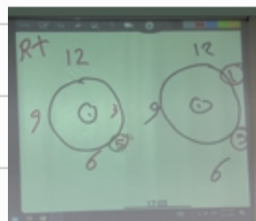
The deep lymphatics form a plexus on the deep fascia of pectoralis major which is called the *deep lymphatic plexus*

- **The central and lateral parts of the gland** drain into the **pectoral (anterior)** group of axillary lymph nodes
- One or two large lymphatics from the **upper part of the gland** pierce the clavicular head of pectoralis major and the clavipectoral fascia to end in the **apical group of axillary lymph nodes**
- Lymphatics from the **medial part** of the gland pass through the intercostal spaces with the perforating branches of the internal mammary artery to end in the **internal mammary (parasternal)** lymph nodes
- Lymphatics from the **medial part** of the gland also cross the middle line to **anastomose** with the lymphatics of **the opposite breast**
- Lymphatics from the **inferomedial** part of the gland anastomose the lymphatics of the **rectus sheath, linea alba and subdiaphragmatic lymphatics**

⚠️ بالسنوات كيتزني انه المنطقه

كحاي ايتن ار lymph او Artery ناسها

بدها ندير بالنس عليهم، تمام؟



17:00
2020



كيف الاسئلة في السنة



* ايتن اد lymphatic draining من الـ 3 بالجهة اليسار؟! anterior LN

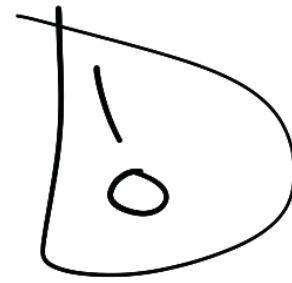
* // // // // // 3 باليمين؟! parasternal LN

* ايتن اد blood supply من الـ 1 باليسار؟! Pectoral (TA)

* // // // // // 5 باليسار؟! Lateral Thoracic artery

* // // // // // 5 باليمين؟

anterior intercostal artery + Internal mammary artery

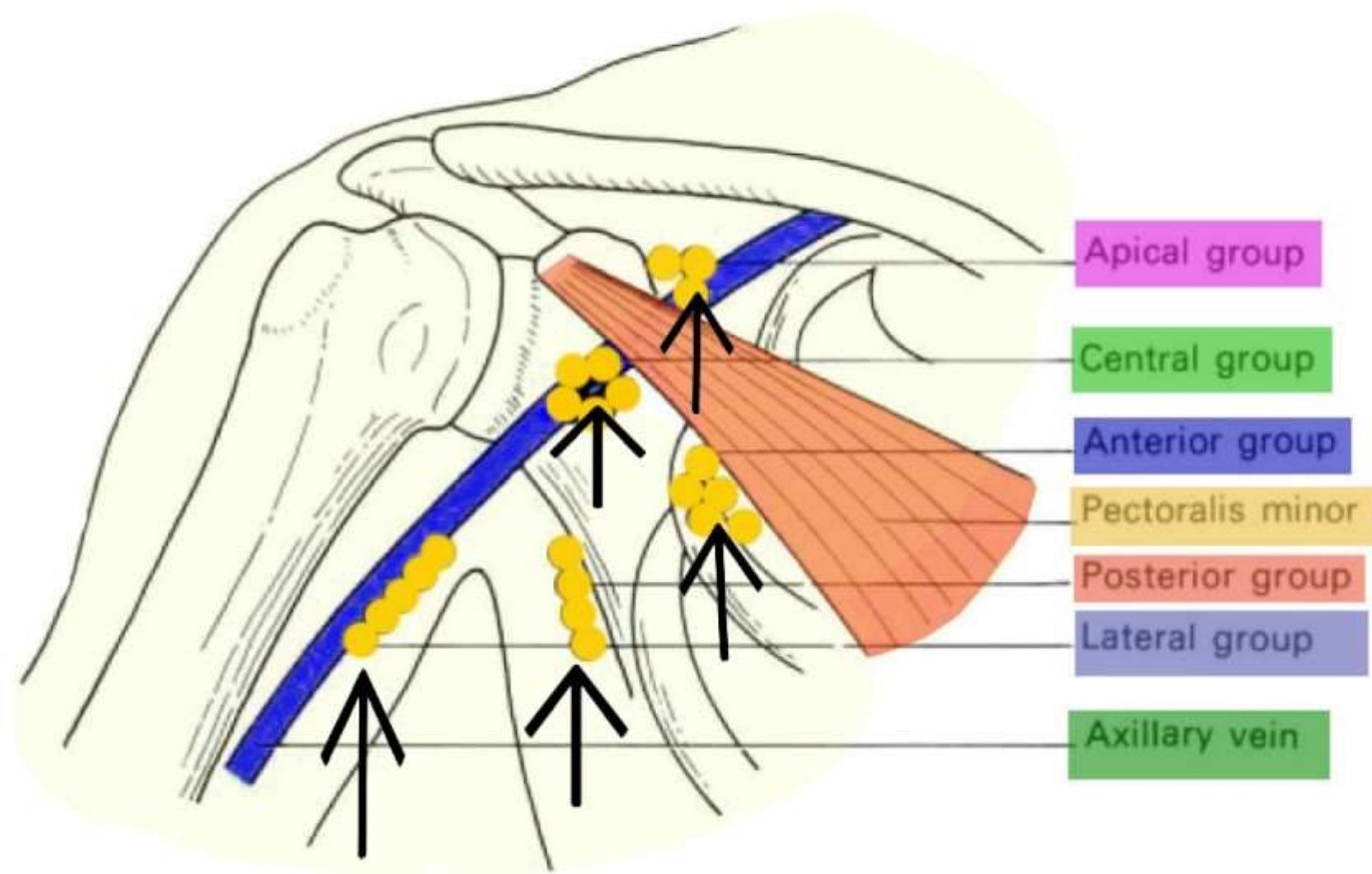


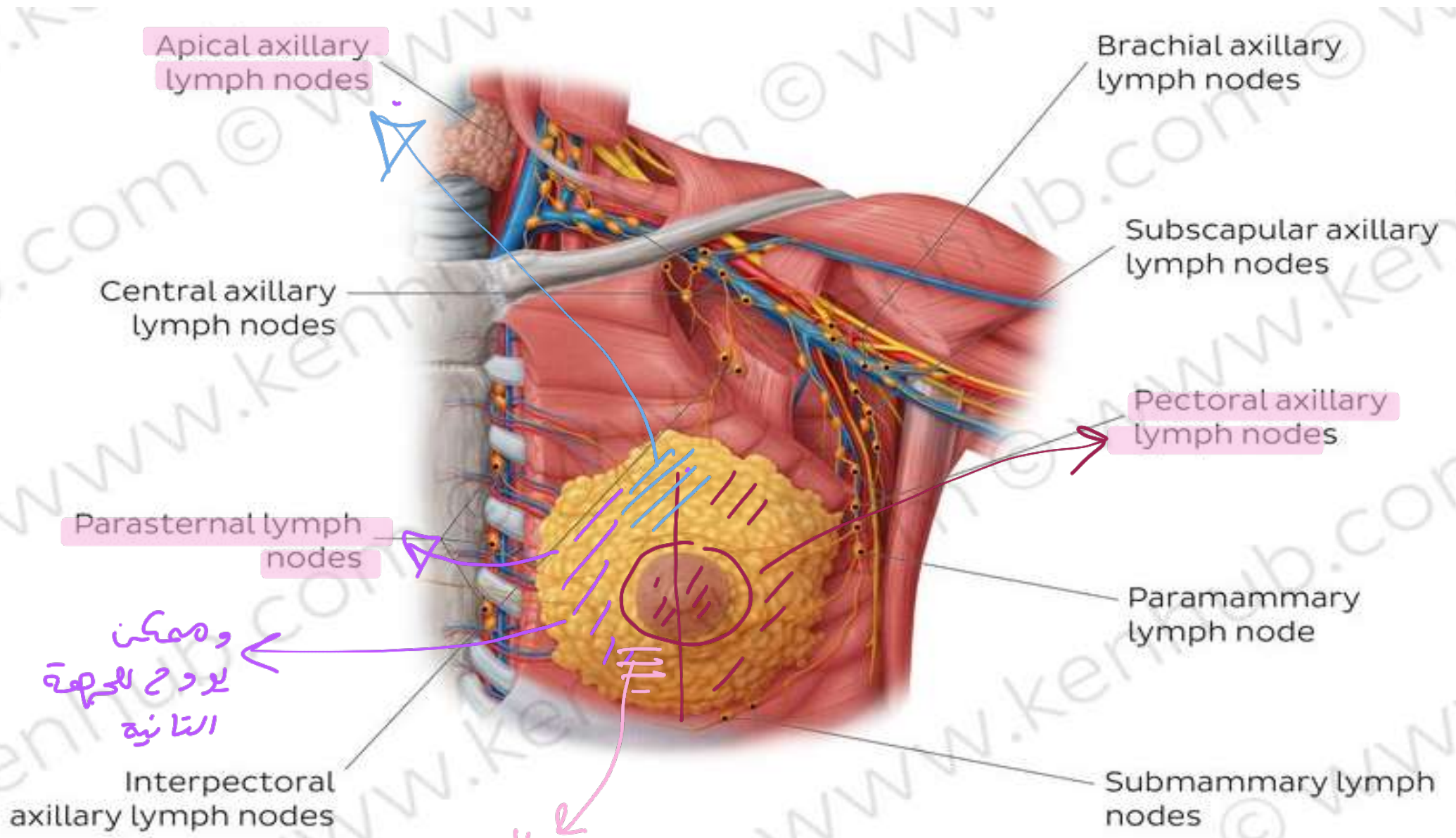
عالية سنوفاز
كبيره

Lymphatic drainage of the female breast:

Area	Lymph Group
Central and lateral parts	Pectoral (anterior) group of axillary lymph nodes
Upper part	Apical group of axillary lymph nodes
Medial part	Internal mammary (parasternal) lymph nodes Cross to opposite breast
Inferomedial part	Lymphatics of the rectus sheath, linea alba and subdiaphragmatic lymphatics

Lymphatic Drainage Of Breast





ويمكن
 لدرج الحصة
 الثانية

inferior
 medial
 Sub diaphragmic or diaphragm
 LN

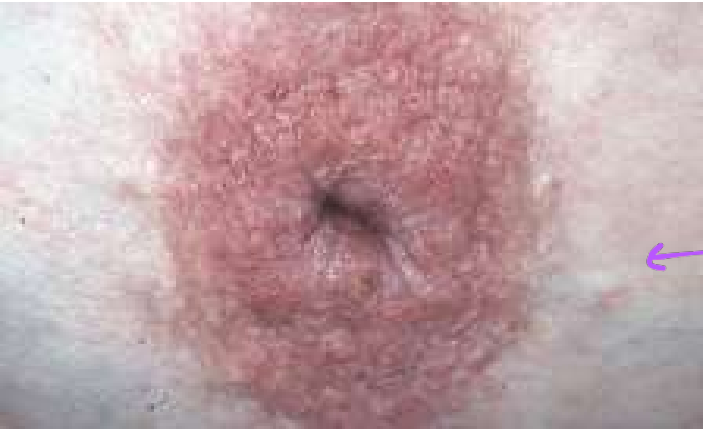Carcinoma of the breast may give rise to the following features :

- 1) Retraction or puckering of the skin due to invasion of the ligament of Cooper.
- 2) Peau d'orange or oedema with pitting oedema is due to obstruction of cutaneous lymphatics by cancer cells and pitting due to fixation of the hair follicles to subcutaneous tissue.
- 3) Retraction of the nipple is due to extension of the growth along the lactiferous ducts with accompanying fibrosis.
- 4) Breast may become fixed with the deep fascia, pectoral muscle and chest wall due to direct spread to the subjacent structures.
- 5) Axillary lymph nodes may be involved, these are stony, hard and fixed

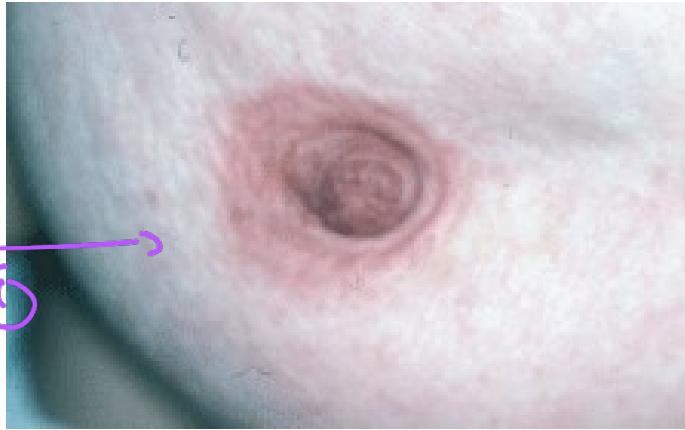Mammography

- ❖ Mammography is a radiographic examination of the breast.
- ❖ This technique is extensively used for screening the breasts for benign and malignant tumors and cysts.

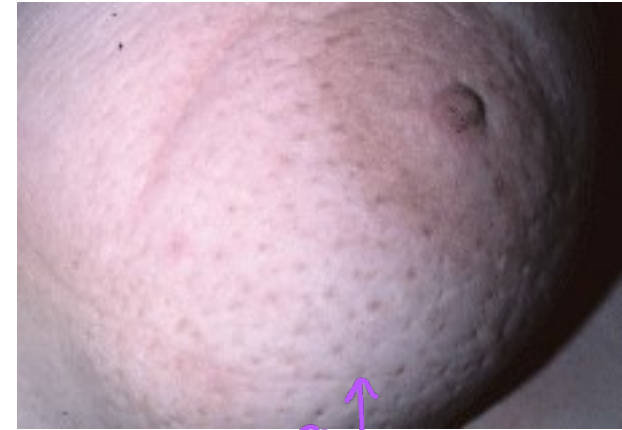



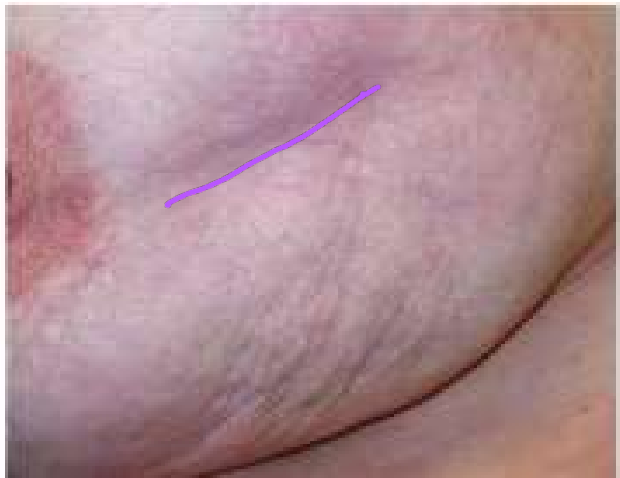Inverted nipple (Sever)



Retracted nipple



3



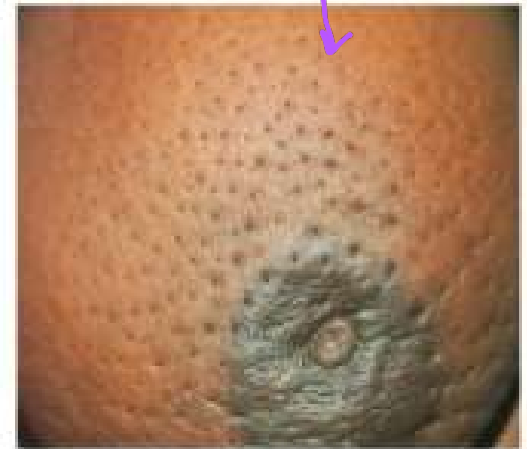puckering of the skin

(Cooper's sign)

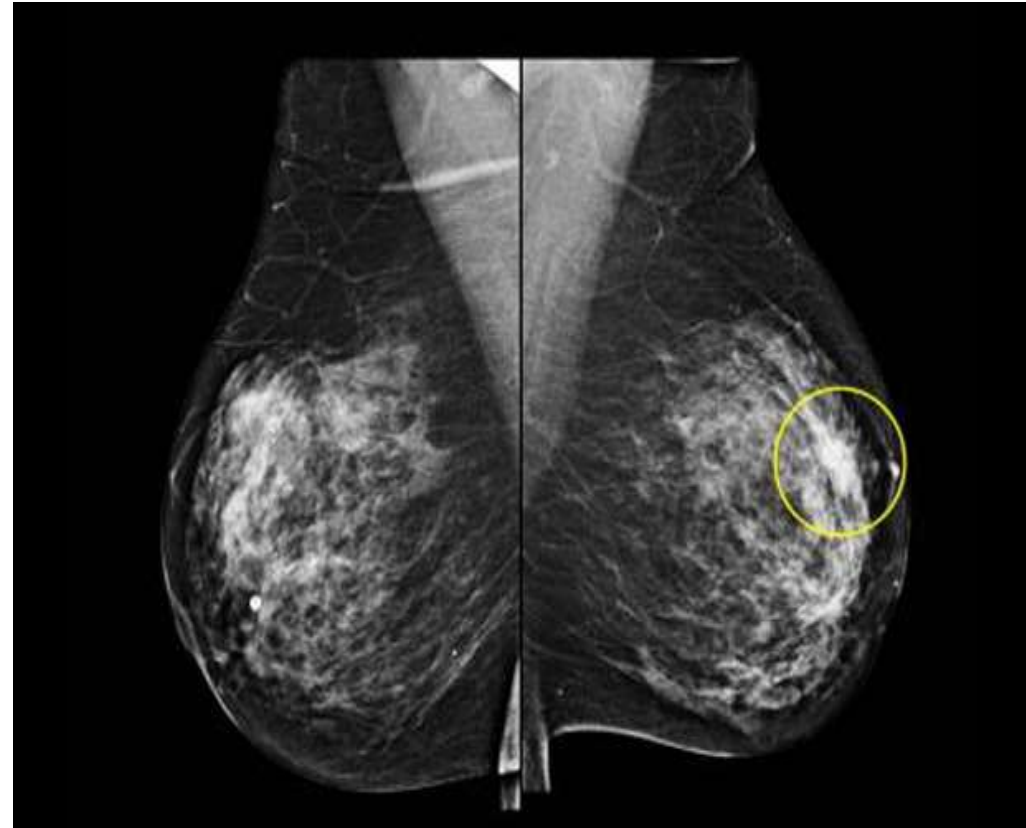
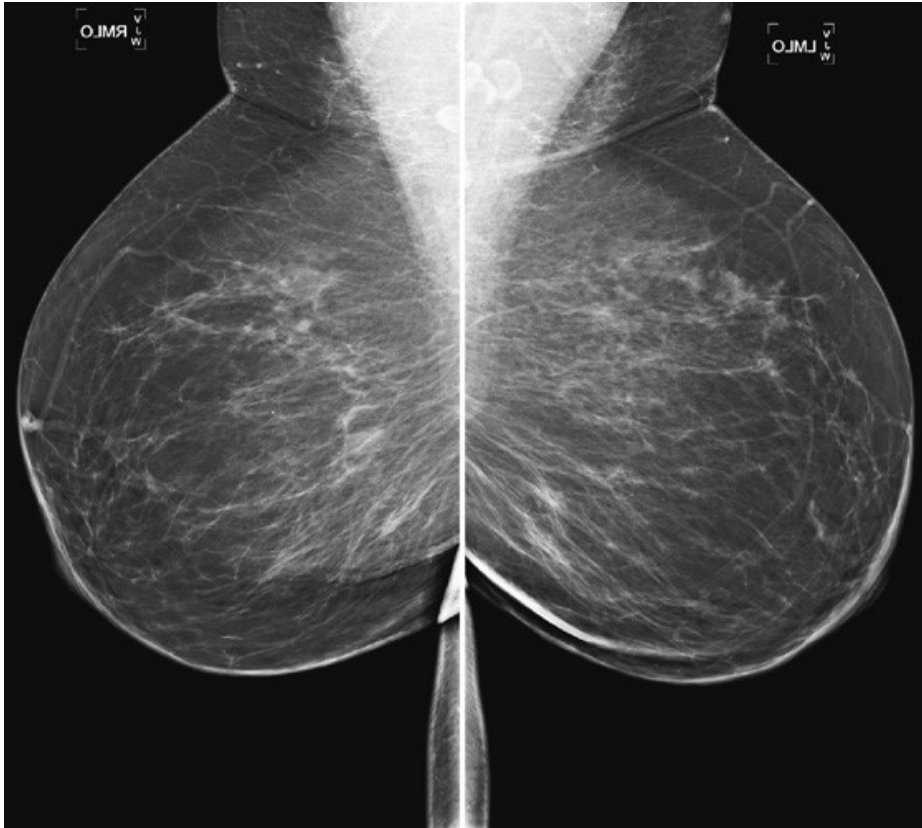
2

hair follicle
عابو + edema

fixed



Peau d'orange



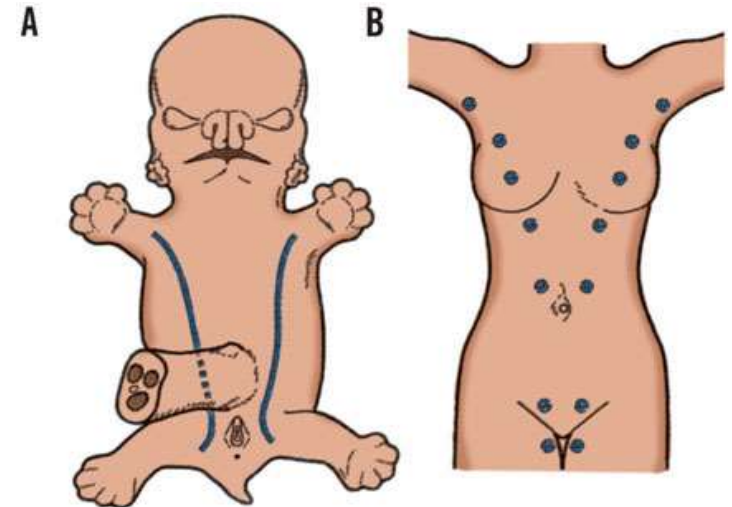
Normal Mammography

Development of the Breasts

- A linear thickening of ectoderm appears called the **milk ridge**, which extends from the axilla obliquely to the inguinal region.
- the ridge disappears except for a small part in the pectoral region.
- This localized area thickens, becomes slightly depressed, and sends off 15 to 20 solid cords, which grow into the underlying mesenchyme.
- The underlying mesenchyme proliferates, and the depressed ectodermal thickening becomes raised to form the **nipple**.
- At the fifth month, the **areola** is recognized as a circular pigmented area of skin around the future nipple.

or mamillary line

سبحان الله



Copyright ©2006 by The McGraw-Hill Companies, Inc.
All rights reserved.

Histology of the breast

The mammary gland is a compound tubule alveolar, formed of lobes and lobules. The lobules are separated by dense & fatty C.T.

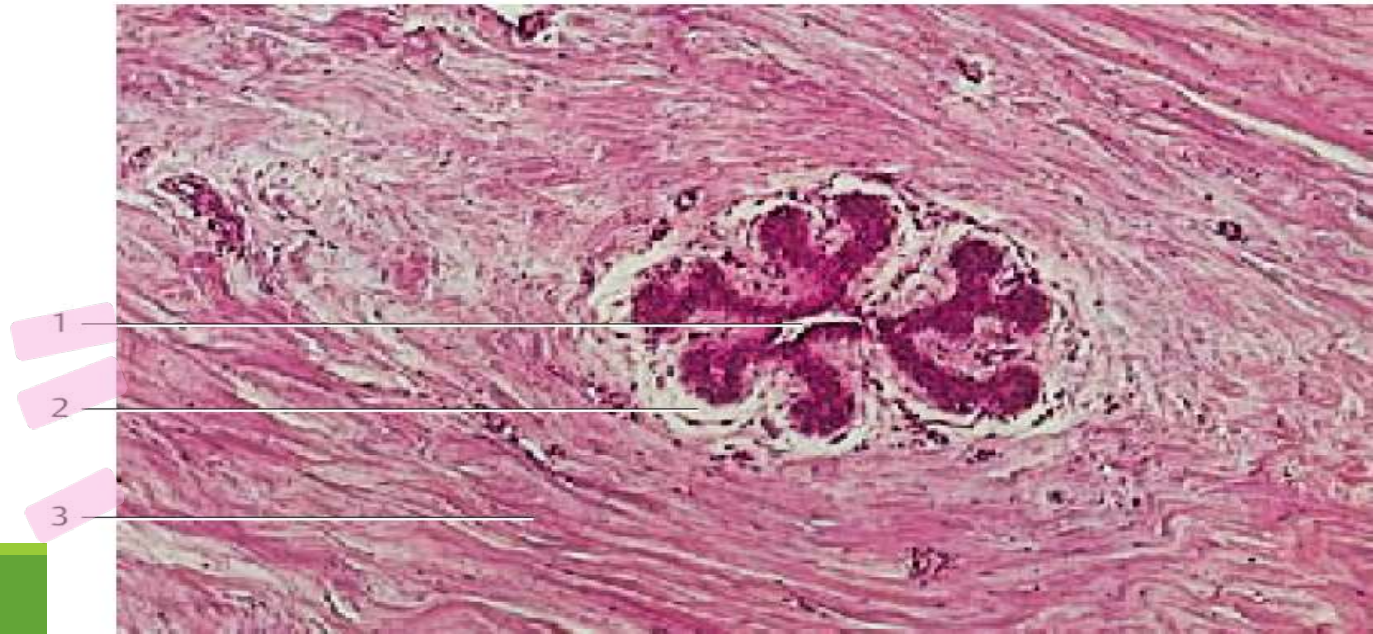
Resting gland:

- Ducts (lactiferous ducts) are embedded in abundance of fatty C.T. and are considered the principal glandular elements
- The ductule epithelium cells show small alterations and vacuolation during the menstrual cycle.
- Alveoli are collapsed and represented by solid cords of cells.

1- Sinus lactiferi

2- Connective tissue sheath

3- Coarse fibrous collagenous connective tissue

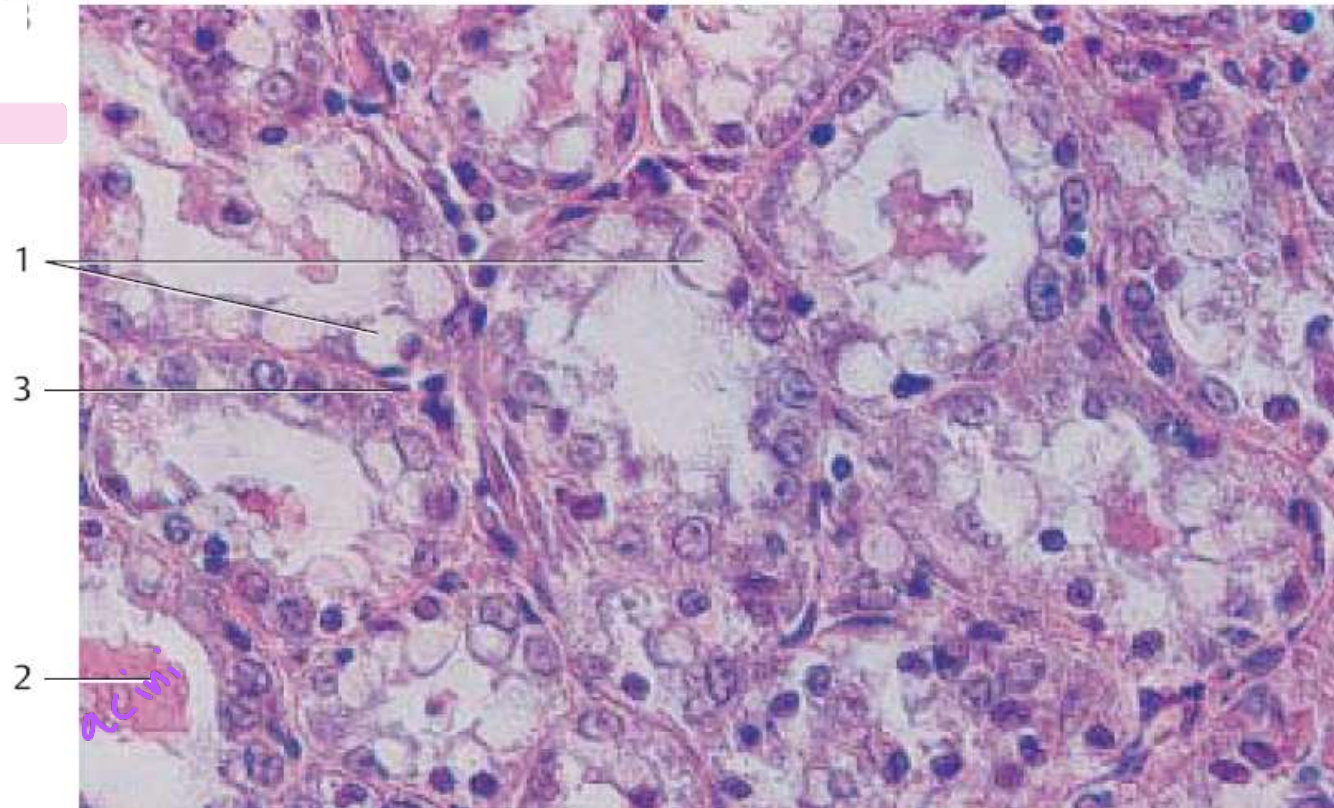


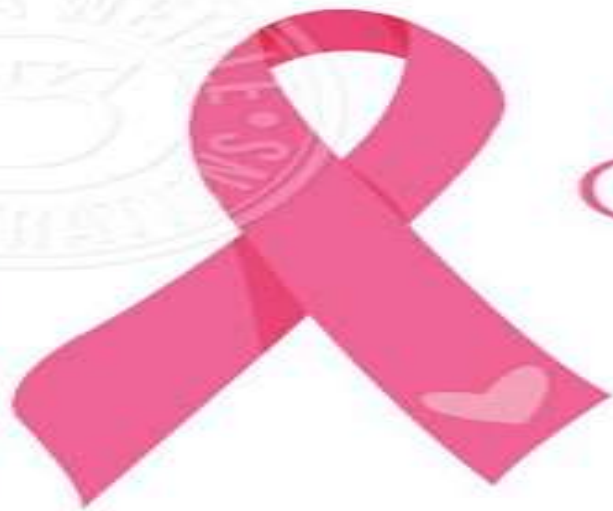Connective tissue

Lactating gland:

- Little amount of C.T. and many secretory acini and ducts.
- Some acini and ducts are distended with milk others are empty.
- The acini are lined by either tall columnar or low cuboidal cells depending on the state of activity
- Milk in acini appears interrupted with vacuoles of dissolved fat.
- Myoepithelial cells are found around the acini and beneath the terminal ductule epithelium.

- 1-Secretory product in gland cells (vacuoles)
- 2 -Secretory product
- 3 -Myoepithelial cells





Thank
You



JWILLUSTRATIONS

DR AHMED SALMAN

Anatomy of the breast

✓ 1. The area at 5 o'clock of the left breast is drained by:

- A. Pectoral (anterior) group of axillary lymph nodes
- B. Apical group of axillary lymph nodes
- C. Internal mammary (parasternal) lymph nodes
- D. Lymphatics of the rectus sheath, linea alba and subdiaphragmatic lymphatics

Answer: A

* ✓ 2. Tubercles of Montgomery are found in:

- A. Nipple
- B. Areola
- C. Fatty stroma

Answer: B

* ✓ 3. Choose the **WRONG** statement from the following:

- A. The upper lateral part of the breast is supplied by pectoral branch of thoraco acromial artery
- B. Retraction of the nipple in cancer breast is due to extension of the growth along the lactiferous ducts
- C. Tubercles of Montgomery is sebaceous gland in the areola which enlarged during pregnancy and lactation
- D. Puckering of the skin in cancer breast is due to invasion of ligament of Cooper
- E. Lymphatics from the medial part of the breast is drained by apical group of axillary lymph nodes

Answer: E

⊘ 4. Which of the following is wrong about the breast?

- A. The lateral part of the breast is supplied by branches of axillary artery only
- B. Nipples lie in 4th intercostal space
- C. Its carcinoma spreads to anterior and posterior axillary lymph nodes but not to central and lateral groups
- D. Axillary veins are an important station in breast venous drainage

Answer: C

5. The area at 7 o'clock of the right breast is drained by.....Lymph nodes:

- A. Right parasternal
- B. Left parasternal
- C. Anterior group of axillary
- D. Sub diaphragmatic
- E. Apical group of axillary

Answer: C

Kahoot

The lower lateral part of breast lies superficial to:

- A. Pectoralis major
- B. Pectoralis minor
- C. Serratus anterior
- D. External oblique muscle

Answer: D