

Male genital system part 2

□ **Ductus Deferens (Vas Deferens)**

- It is thick walled muscular tube which springs from the lower end of the epididymis
- It ends behind the base of the bladder, by joining the duct of the seminal vesicle to form the ejaculatory duct

- **Length** : about 45 cm, the same length of the following :

- a. Thoracic duct
- b. Spinal cord
- c. Adult femur
- d. The distance from the incisor teeth to the cardiac end of the stomach.

- **Function** : transmit the spermatozoa from the epididymis to the ejaculatory duct, which in turn opens in the prostatic urethra.

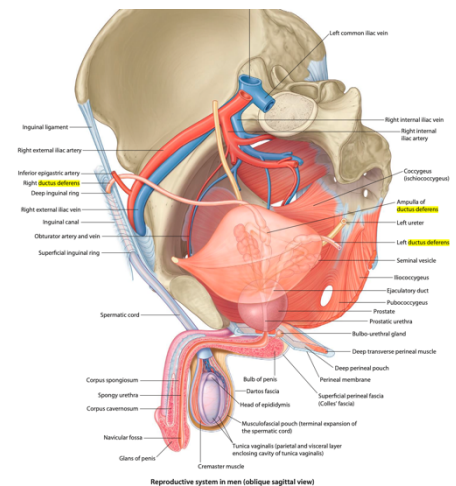
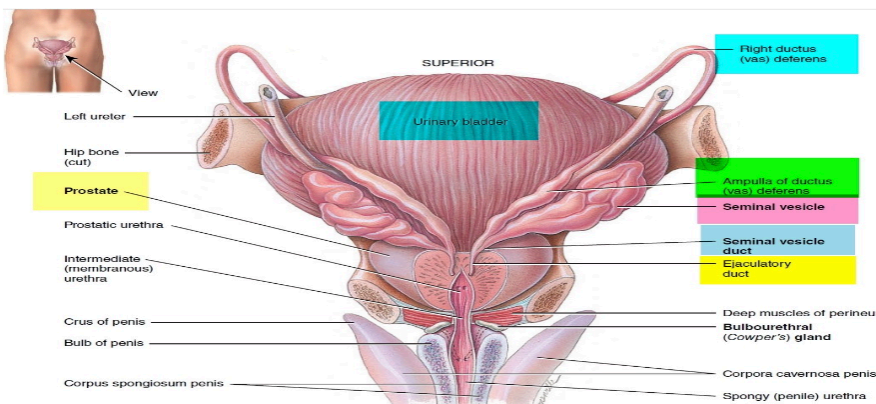
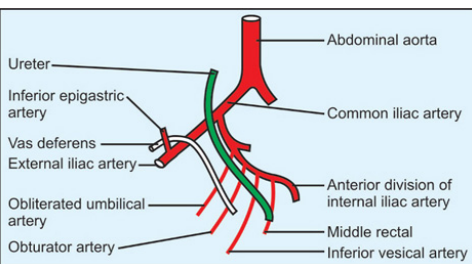
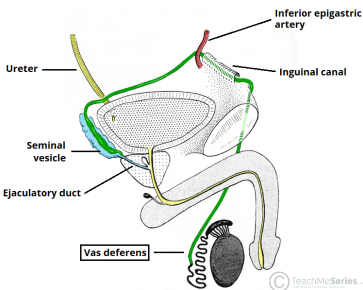
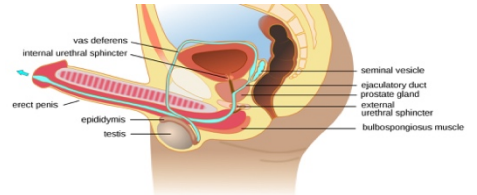
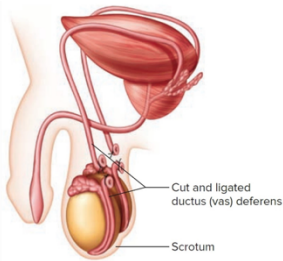
- **Course and Relations of the Vas** : Its distal part lies in the scrotum and inguinal canal, its proximal part runs in the pelvis.

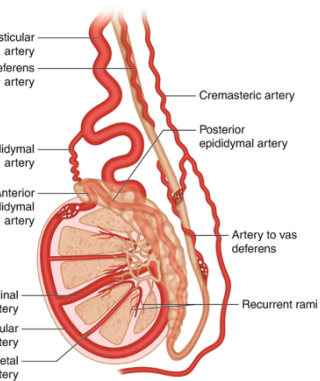
▪ **A. Of its distal part in the scrotum and inguinal canal:**

- From the tail of the epididymis, it ascends along the posterior aspect of the testis, medial to the epididymis.
- Then, it ascends in the posterior part of the spermatic cord to traverse the inguinal canal.
- At the deep inguinal ring, it leaves the cord and curves around the lateral side of the **inferior epigastric artery** to enter the pelvis.

▪ **B. Of its proximal part (in the pelvis) :**

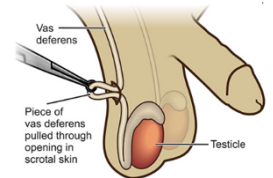
- The vas descends posteriorly external to the peritoneum, crossing these structures in the side wall of the pelvis :- external iliac vessels, obliterated umbilical artery, obturator nerve and obturator vessels.
- Then, it turns medially and crosses the **ureter** near the superolateral angle of the base of the bladder .
- Behind the bladder base, it runs superior to, then medial to the seminal vesicle and expands to form ampulla of the vas, below which it narrows to join the duct of the seminal vesicle to form the ejaculatory duct .





○ **Vessels of the Vas:**

- Artery of the vas is derived from inferior vesical artery.
- It runs in the spermatic cord and anastomoses with the testicular artery.
- **Veins** : join the vesical venous plexus.
- **Nerves** : are derived from prostatic nerve plexus which comes from the inferior hypogastric plexus.
 - Fibers are mainly sympathetic for the process of ejaculation.

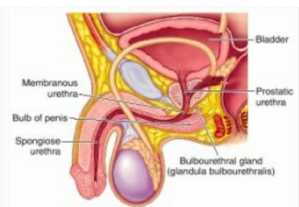


Applied Anatomy: bilateral vasectomy is a common operation for male sterilization

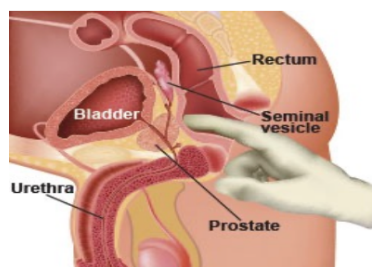
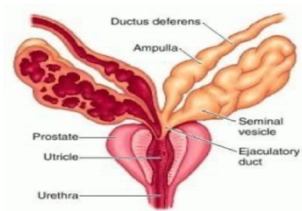
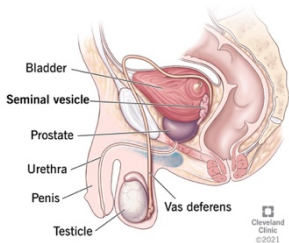
□ **Seminal vesicles, Ejaculatory ducts and Bulbourethral glands**

○ **Seminal Vesicles**

- It is a sacculated tube, about 5 cm long.
- **Site and relations** : it lies behind base of the bladder and has the following relations;
 - Anteriorly : Base of the bladder.
 - Posteriorly : Rectum and rectovesical fascia.
 - Superiorly : Its upper end is covered by peritoneum of rectovesical pouch and related to the vas deferens.
 - Medially : ampulla of the vas.
- **Termination** : inferiorly, it narrows into a small duct which joins the vas to form ejaculatory duct.
- **Arterial supply** : from inferior vesical and middle rectal arteries.
- **Veins** : to vesical venous plexus.
- **Nerves**: from prostatic nerve plexus (mainly sympathetic).
- **Functions** :
 - the seminal vesicle produces an alkaline secretion rich in fructose and mucus.
 - The secretion is added to the spermatozoa in ejaculation.
- **Applied Anatomy** :
 - The seminal vesicles when enlarged, could be felt on rectal examination.
 - Abscess in the seminal vesicle may rupture into the peritoneal cavity.



Seminal vesicle



Screen Draghmeh

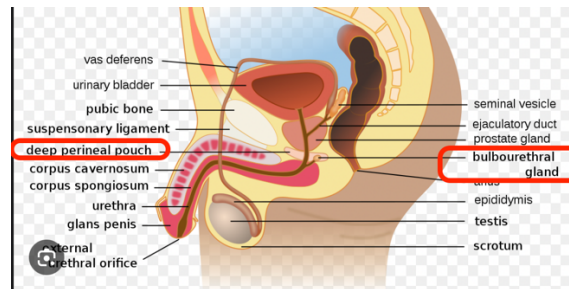
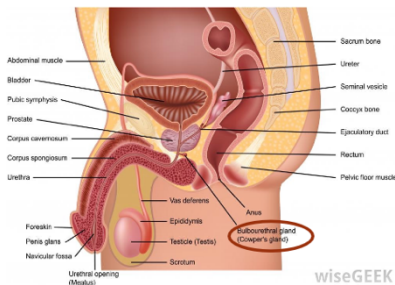
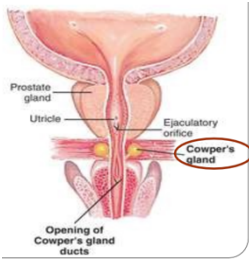
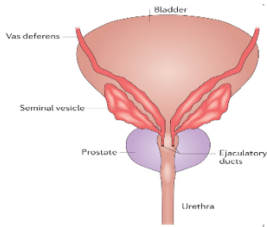
○ Ejaculatory Ducts :

- Each is about 2 cm long, formed by union of the ductus deferens and the duct of the seminal vesicle.
- The two ducts run antero-inferiorly between median and posterior lobes of the prostate along the sides of the prostatic utricle to open on the seminal colliculus of the prostatic urethra.

○ Bulbourethral Glands :

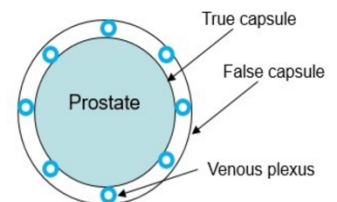
- These small glands lie lateral to the membranous urethra in the **deep perineal pouch**
- Each gives rise to a long duct (3 cm) which pierces the perineal membrane to open on the floor of the spongy part of the urethra.
- **Blood supply:** by artery of the bulb of the penis. It is innervated by prostatic nerve plexus

Function : It secretes an alkaline mucous secretion known as pre-ejaculate .



□ The Prostate

- **Site :** it lies in the lower part of the lesser pelvis behind the inferior border of the pubic symphysis in front of the rectum, below neck of the bladder.
- **The prostatic capsules:**
 - 1. Inner true capsule : it is fibromuscular in structure.
 - 2. Outer false capsule (prostatic sheath): it is a condensed visceral pelvic fascia. Between the two capsules, lies the prostatic venous plexus.



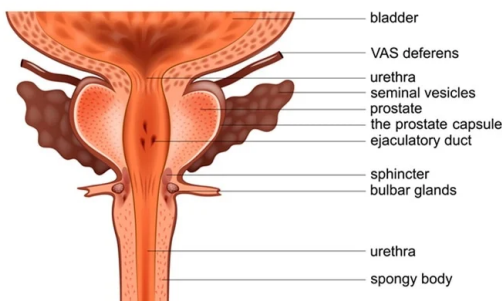
○ Shape and Description:

- It simulates an inverted cone which has a base (directed superiorly); an apex (directed inferiorly), four surfaces: anterior, posterior, and two inferolateral surfaces.

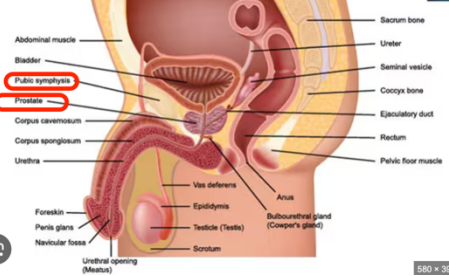
□ 1- Base of the prostate :

- It is directed upwards, separated from the bladder by a groove contains part of the prostatic venous plexus.
- It is pierced by the urethra.

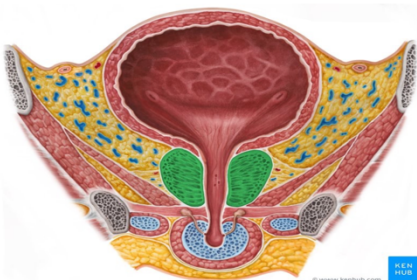
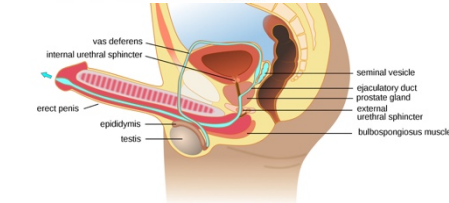
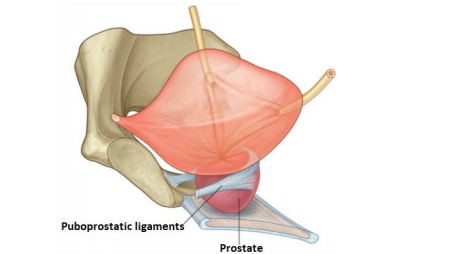
PROSTATE



Male Reproductive System



580 x 394



□ **2- Apex of the prostate:**

- Is directed downwards
- It rests on the perineal membrane (floor of the deep perineal pouch).
- The urethra emerges from the prostate anterosuperior to the apex.

□ **3-Anterior surface:**

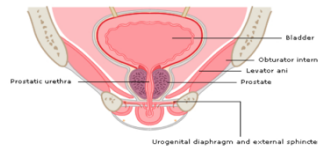
- It is convex and lies behind the lower part of the symphysis pubis.
- Its upper part is connected to the pubic bodies by puboprostatic ligaments.
- The urethra emerges from this surface a little above and in front of the apex of the gland.

□ **4- Posterior surface:**

- It is nearly flat and is related to ampulla of the rectum separated from it by rectovesical fascia (fascia of Denonvilliers)
- The prostate is easily palpated by a finger in the rectum
- Near its upper border, this surface is pierced by the two ejaculatory ducts.

□ **5- Right and left inferolateral surfaces:**

- Are convex and related to levator prostatae parts of levator ani muscle.



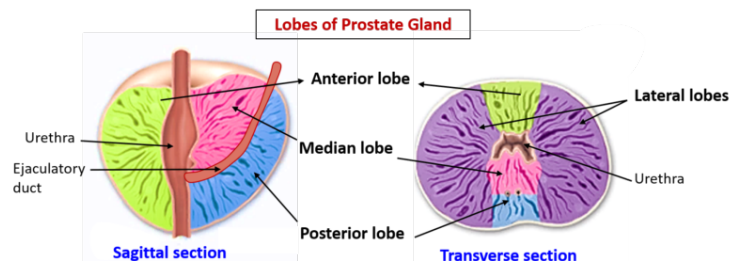
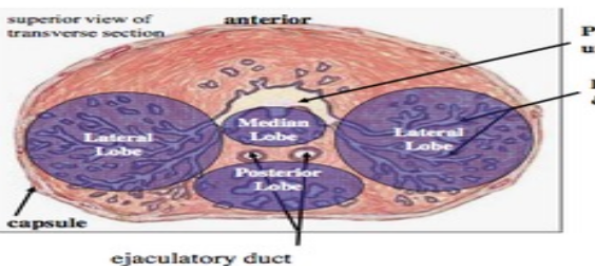
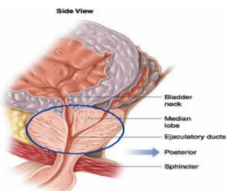
- **N.B** Fascia of Denonvilliers is attached above to the floor of rectovesical pouch and below to the perineal body).

○ **Structures that traverse the prostate :**

- Prostatic urethra.
- The two ejaculatory ducts descend anteroinferiorly to open in the prostatic urethra
- The gland contains the utricle.

○ **Lobes of the prostate:**

- By means of the prostatic urethra and the two ejaculatory ducts, the prostate is divided into five lobes



□ **Anterior lobe (isthmus):**

- lies in front of the prostatic urethra.
- It consists a fibromuscular tissue with little glandular tissue.

□ **Right and left lateral lobes :**

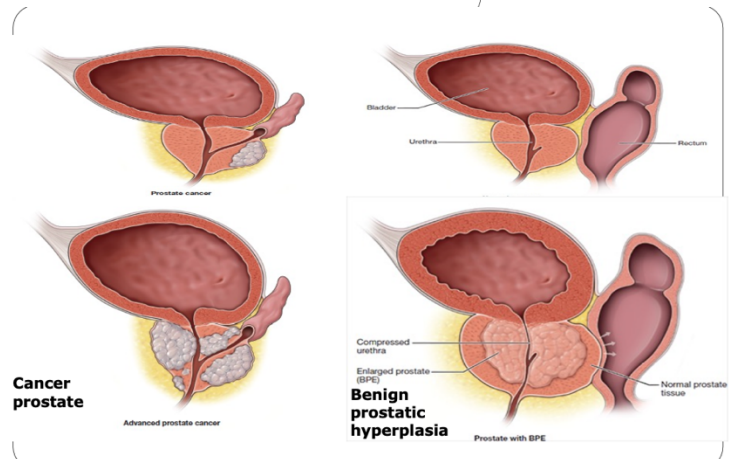
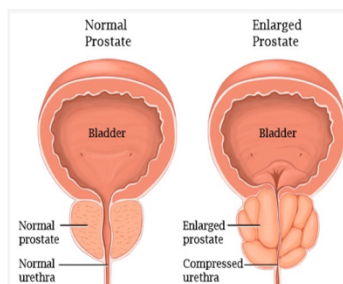
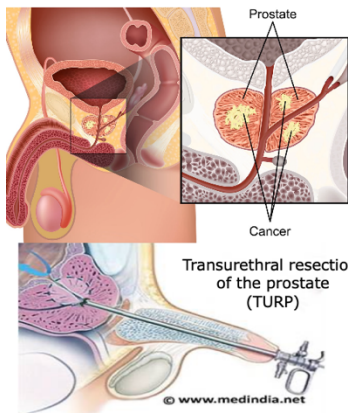
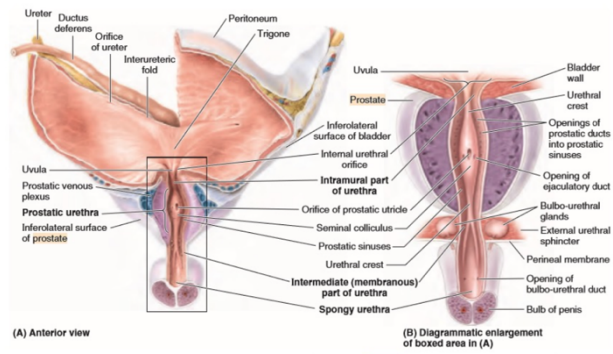
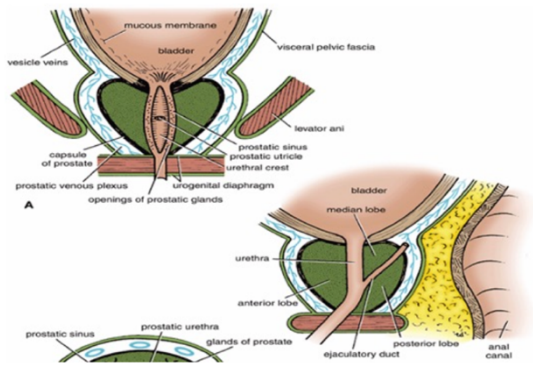
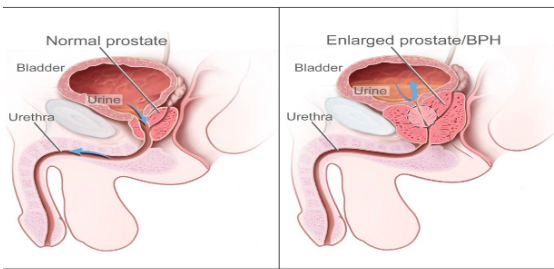
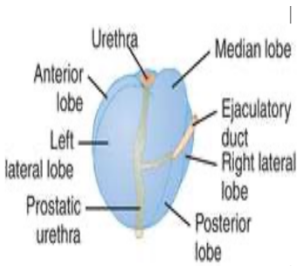
- one on each of the prostatic urethra.
- They are the usual sites for the senile enlargement of the prostate.

□ **Posterior lobe :**

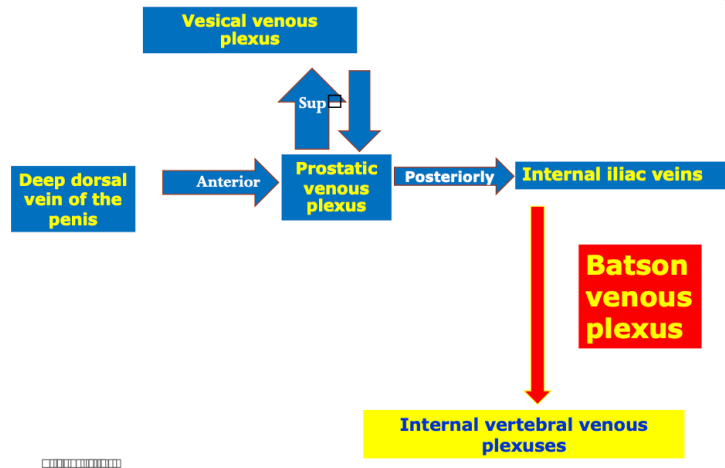
- lies behind the prostatic urethra, but below the two ejaculatory ducts.
- It is the usual site for cancer prostate.

□ **Median lobe:**

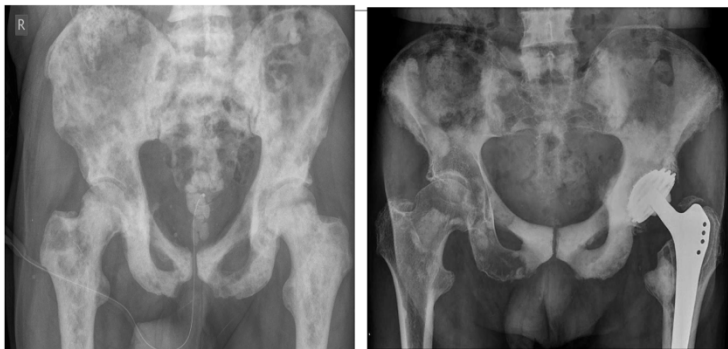- Lies between the upper part of prostatic urethra and the two ejaculatory ducts.
- After middle age, it produces uvula vesicae, in the lower part of the bladder trigone. It is also a common site for senile enlargement of the prostate. (BPH)
- The uvula vesicae may obstruct the flow of urine at the internal urethral meatus.



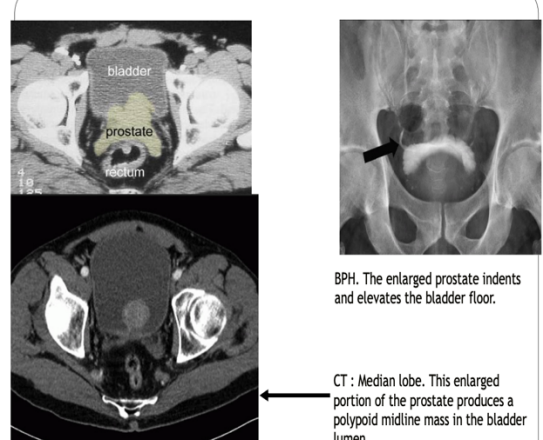
- **Blood Supply of the Prostate:**
 - Arteries are derived from inferior vesical and middle rectal arteries.
- **Venous drainage of the Prostate :**
 - the veins form the prostatic venous plexus which has the following features :
 - It is embedded between the two capsules of the prostate.
 - It is present only in front and sides of the gland
 - Superiorly, it is continuous with the vesical venous plexus.
 - Anteriorly : it receives the deep dorsal vein of penis.
 - Posterolaterally : the plexus is drained to the internal iliac veins which in turn communicates with the internal vertebral venous plexuses by the Batson venous plexus.
 - These veins are valveless and responsible for spread of cancer prostate to lumbar vertebrae



- **Lymphatic Drainage:**
 - to internal, external iliac lymph nodes.
- **Nerve Supply:**
 - by prostatic nerve plexus derived from the inferior hypogastric plexus.
- Acid phosphatase and Prostate-Specific Antigen (PSA) are markedly elevated in prostatic disease especially carcinoma



Bone metastases



□ Penis

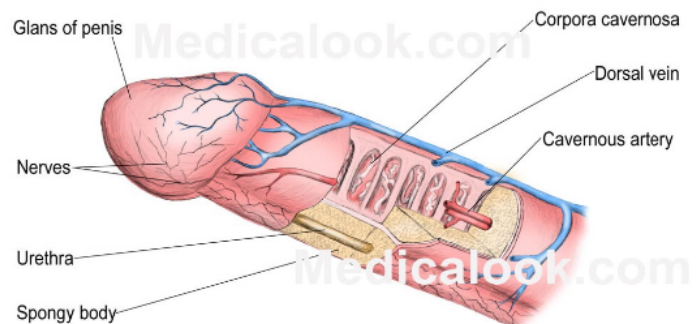
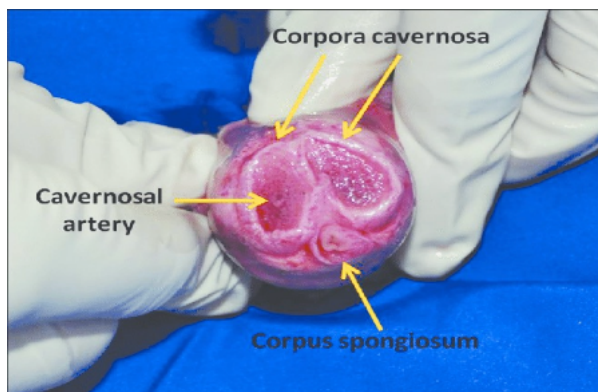
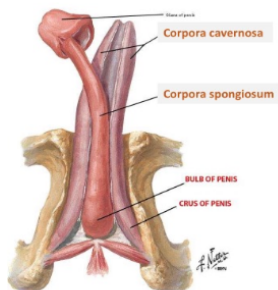
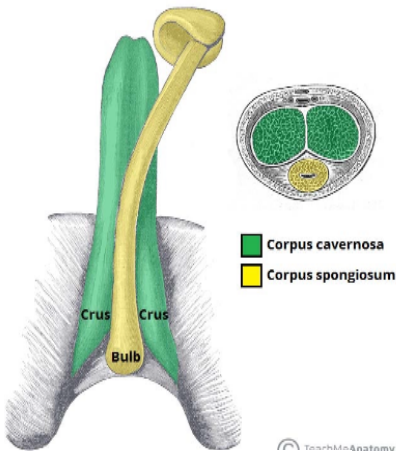
- It has a root (or attached portion) and a shaft (or free portion).
- The root is formed of 3 parts; two crura (right and left) and bulb of penis, all are present in the superficial perineal pouch of perineum .
- The **bulb** is covered on its outer surface by the **bulbospongiosus** muscles. The shaft is formed of 3 columns of erectile tissue; two corpora cavernosa (right and left) and a median corpus spongiosum.
- Each **crus** is attached to the side of the pubic arch and is covered on its outer surface by the **ischiocavernosus** muscle.
- **The shaft of the penis**
 - The body of the penis is essentially composed of three cylinders of erectile tissue enclosed in a tubular sheath of fascia (Buck's fascia).

▪ **A- The two corpora cavernosa:-**

- They lie dorsally side by side in the shaft of penis.
- The corpora cavernosa contain many irregular cavernous spaces which become filled by blood during erection.
- Each is firmly surrounded by fibrous tissue called tunica albuginea which also sends a median septum between the two .
- Followed distally, the corpora cavernosa end in pointed projections within the glans penis .
- Followed proximally (towards the root of the penis), the two corpora cavernosa diverge from each and continue as the crus penis, which becomes firmly attached to the ischio pubic ramus

B- The corpus spongiosum

- It is median and lies in the ventral surface of the two corpora cavernosa. It is also surrounded by a separate sheath of tunica albuginea
- Followed distally, it forms glans penis ,The base of the glans penis is called the corona glandis
- Followed proximally (towards the root of the penis), it forms bulb of penis which is attached to the perineal membrane.
- The corpus spongiosum is traversed by the penile part of the urethra. It also contains cavernous tissue capable of erection.



○ **The skin of the penis**

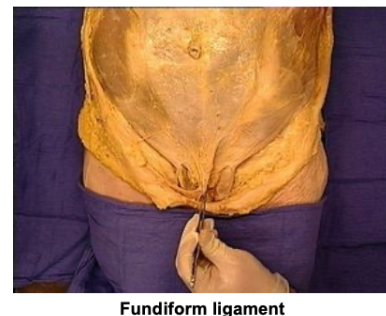
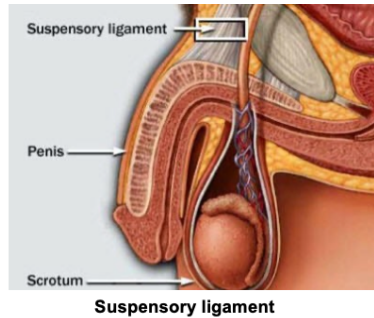
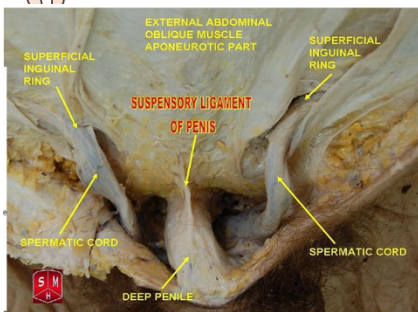
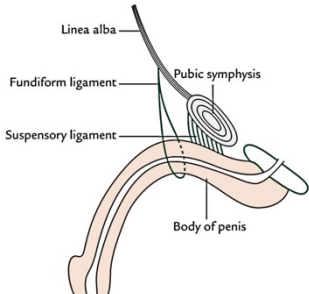
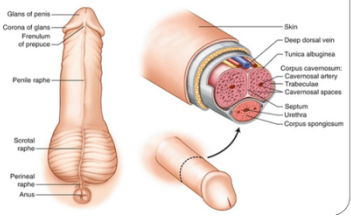
- Followed distally, the skin forms a loose fold called the prepuce or foreskin which covers the glans.
- The deep layer of this fold is attached to the coronary sulcus of the glans by frenulum followed proximally.

○ **The fascia of the penis**

- The superficial penile fascia is devoid of fat (like the scrotum) but rich in loose connective tissue to allow free movement of skin over the shaft of penis.

○ **The ligaments of the penis**

- **Fundiform ligament:** arise from the lower part of the linea alba, its fibers split to surround the proximal part of the penile shaft to insert into the midline raphe of the scrotum.
- **Suspensory ligament:** (deep to the fundiform ligament), extends from the symphysis pubis and blends below with fascia penis.

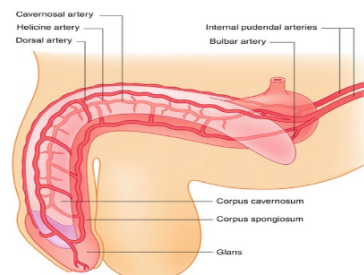
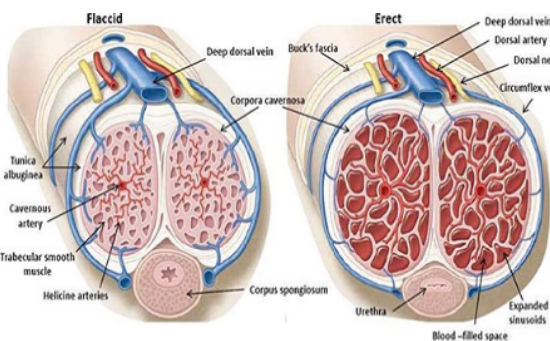


○ **Arteries of the penis**

- All are branches of internal pudendal artery and all are paired (right and left).
 - **Dorsal artery** of the penis supplies the skin, fascia, and glans .
 - **Deep artery** of the penis supplies the corpus cavernous with convoluted helicine arteries
 - **Artery of the bulb** supplies the corpus spongiosum and glans penis

○ **Venous drainage**

- By 2 dorsal veins which are superficial and deep;
 - **1. Superficial dorsal vein** (superficial to the fascia penis); divides into right and left .Each ends in the corresponding superficial external pudendal vein.
 - **2. Deep dorsal vein of the penis** (deep to fascia penis), passes below symphysis pubis to terminate in prostatic venous plexus.



- **Lymph drainage**
 - From the penis into **superficial inguinal lymph nodes** (with the scrotum).
 - From glans penis, lymphatics drain **directly** to gland of **Cloquet** in the femoral canal.
- **Nerves of the penis**
 - **1. Dorsal nerve of the penis** (sensory), is a branch of pudendal nerve, runs **lateral** to the dorsal artery of the penis
 - **2. Cavernous nerves** (autonomic) arise from the inferior hypogastric plexus, Parasympathetic fibers (S2,3,4) produce vasodilatation & erection of penis