



Perineum

Dr. Ahmed Salman

Associate Professor of Anatomy

It is the diamond-shaped lower end of the trunk

Glossary : **peri** : around, **ineo** - discharge, evacuate

Location : it lies below the pelvic diaphragm, between the upper parts of the thighs.

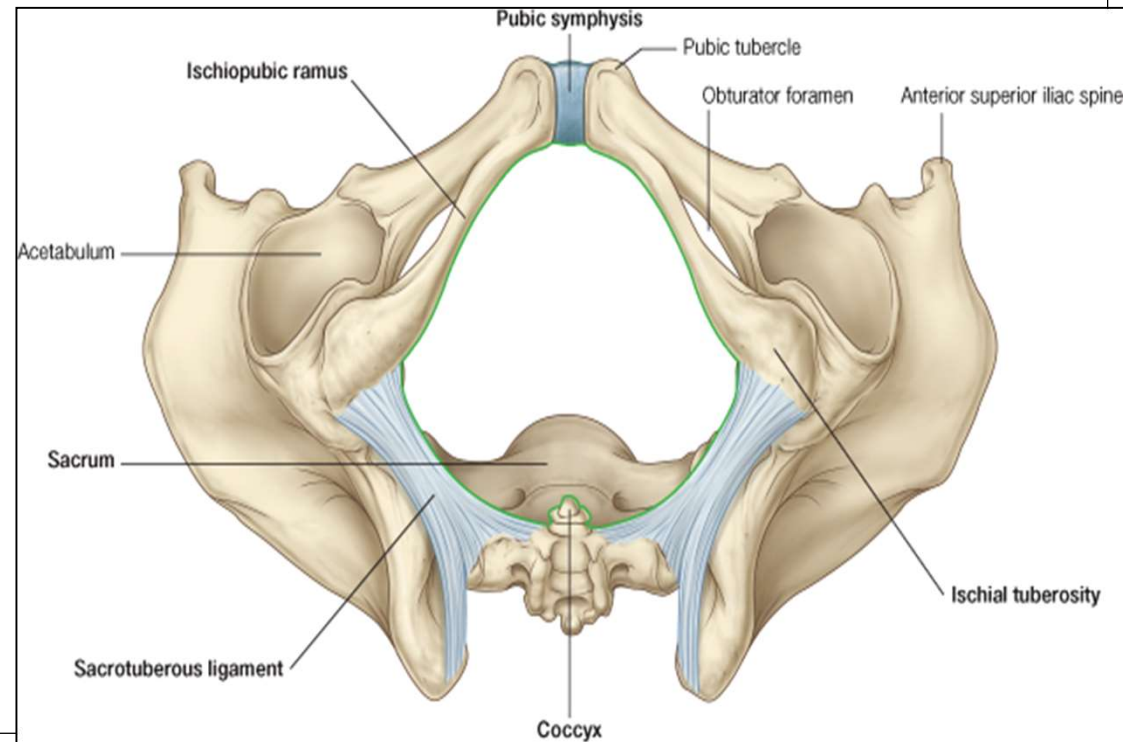
Boundaries :

Anteriorly : Inferior margin of symphysis pubis.

Posteriorly : Tip of coccyx.

Anterolateral : Fused rami of pubis and ischium and ischial tuberosity.

Posterolateral : Sacrotuberous ligaments.

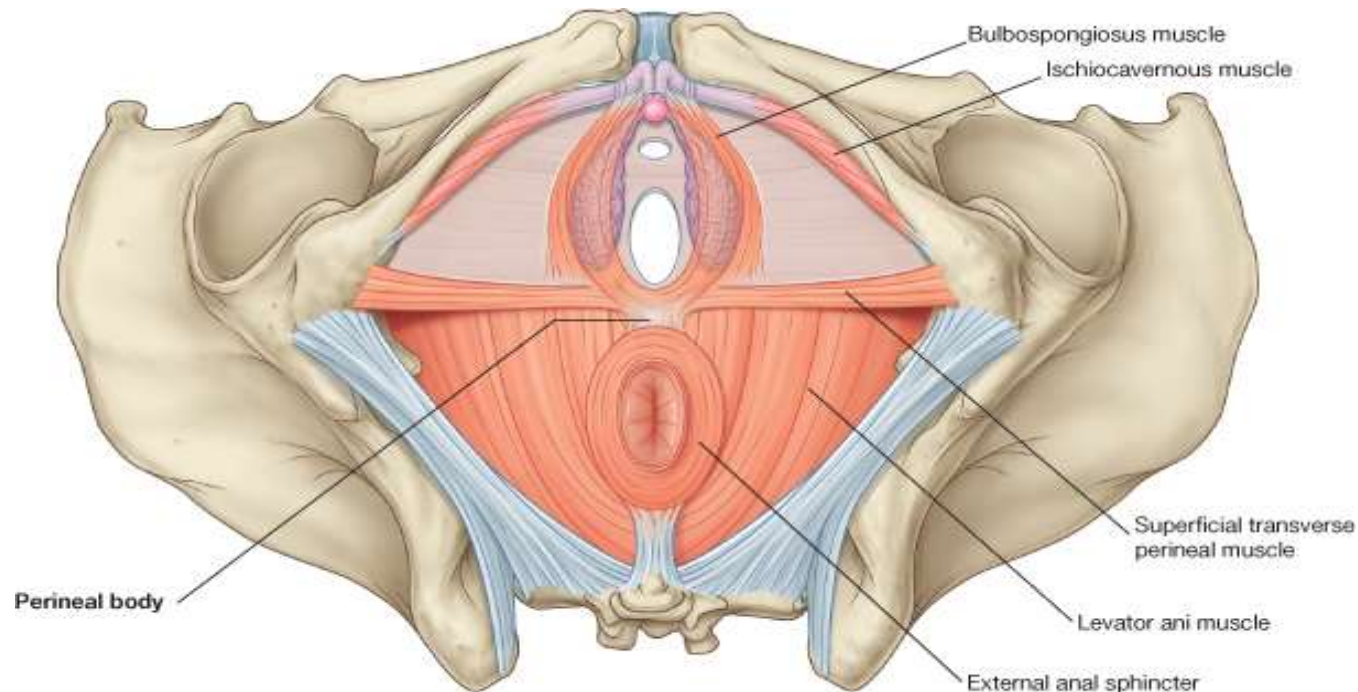


Divisions of the Perineum :

❖ By a line joining the anterior parts of the ischial tuberosities, the perineum is divided into two triangles :

❖ **Anteriorly** : Urogenital triangle

❖ **Posteriorly** : Anal triangle



© Elsevier. Drake et al: Gray's Anatomy for Students - www.studentconsult.com

Perineum

```
graph TD; A[Perineum] --> B[Urogenital triangle]; A --> C[Anal triangle]; B --> B1[1-External genitalia in male or female]; B --> B2[2-Superficial perineal pouch]; B --> B3[3-Deep perineal pouch]; C --> C1[1-Anal Canal in the median plane]; C --> C2[2-Ischiorectal fossa on either side of anal canal]; C --> C3[3- Pudendal canal in side wall of ischiorectal fossa];
```

Urogenital triangle Contains

- 1-External genitalia in male or female
- 2-Superficial perineal pouch
- 3-Deep perineal pouch

Anal triangle Contains

- 1-Anal Canal in the median plane
- 2-Ischiorectal fossa on either side of anal canal
- 3- Pudendal canal in side wall of ischiorectal fossa

Urogenital triangle:

Contains these fascial layers

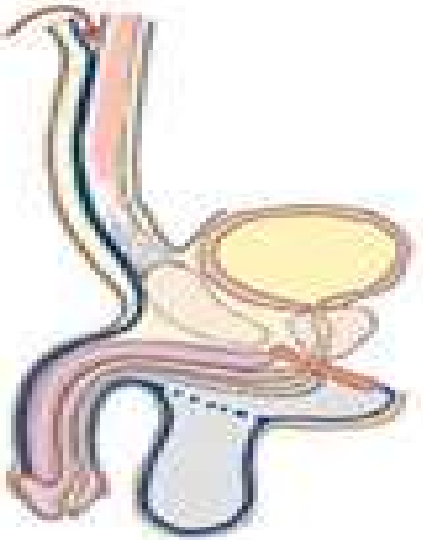
1-The membranous layer of the superficial fascia of the perineum (Colles fascia).

2-The perineal membrane

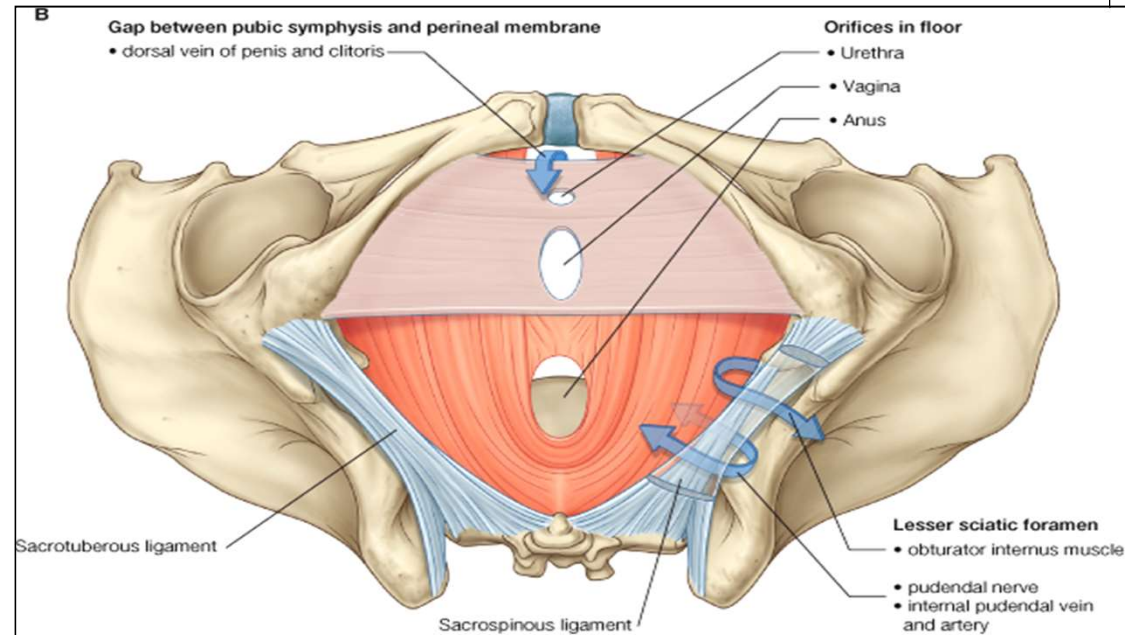
It is a triangular fibrous sheet which lies across the pubic arch.

The perineal membrane :

- Forms the floor of the deep perineal pouch.
- Forms the roof of the superficial perineal pouch

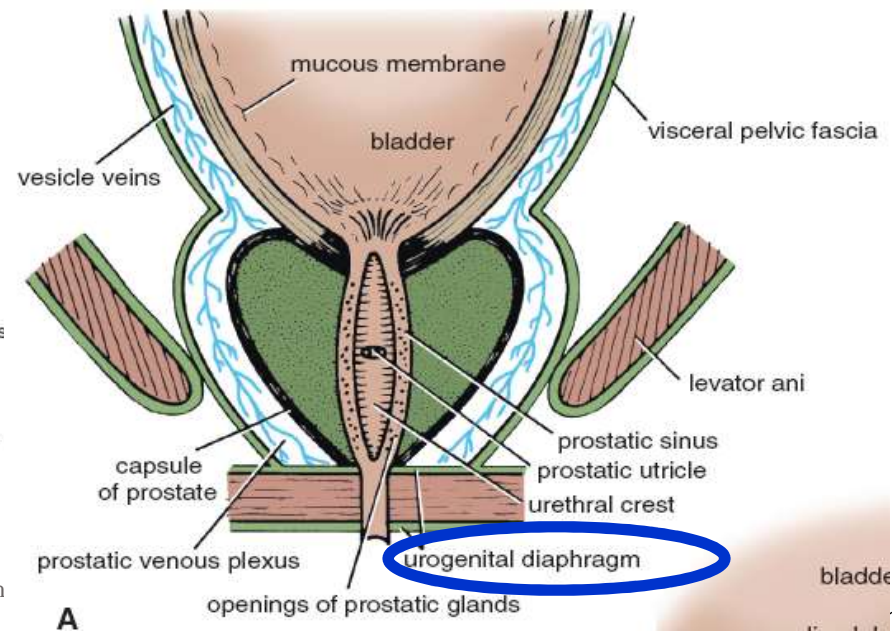
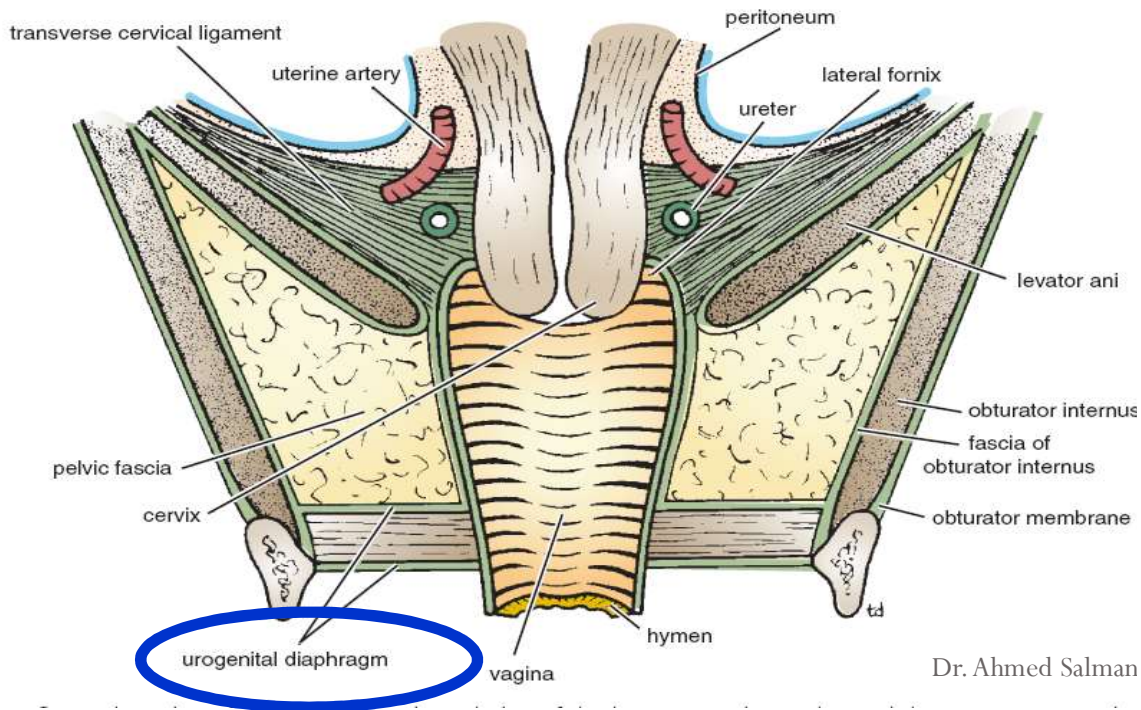


Dr. Ahmed Salman



Urogenital Diaphragm

- It is a triangular musculofascial diaphragm situated in the anterior part of the perineum
- It fills the gap of the pubic arch
- It is formed by the **sphincter urethrae** and the **deep transverse perineal** muscles
- These two muscles are enclosed between a superior and an inferior layer of fascia of the urogenital diaphragm.
- The inferior layer of fascia is the perineal membrane.



Perineum contains two fibro muscular masses which are :

A- Anococcygeal raphe (and body) :

- It is a fibromuscular mass which extends from the tip of coccyx to the recto anal junction.
- It is easily stretched during defaecation and labour and recoiled by the coccygeus muscles.
- It supports the lower part of the rectum.

B- Perineal body (central tendon of the perineum) : (remnant of urorectal septum)

- It is a fibromuscular mass situated in the median plane, in front of anus.

Relations :

- **In the male** : it lies between anal canal and bulb of the penis.
- **In the female** : it lies between anal canal and lower part of vagina.
- Importance : perineal body supports the uterus and vagina.
- Rupture of it during labour may result in prolapse of uterus

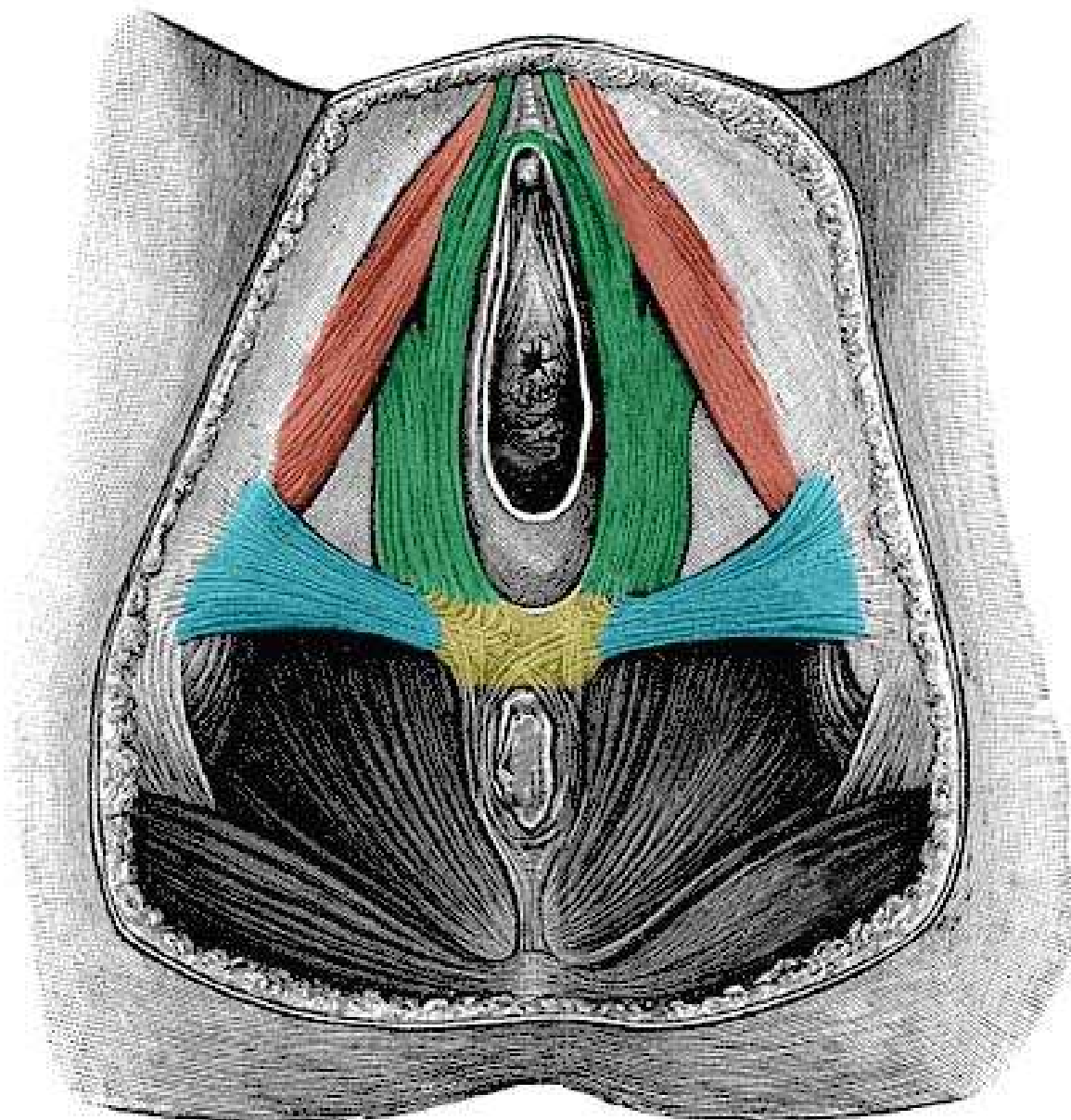
Muscles attached to the perineal body : 3 paired and 3 single muscles :



3 paired muscles

1. Superficial transverse perineal.
2. Deep transverse perineal.
3. Levator prostate or sphincter vaginae part of levator ani.

3 single muscles

1. Bulbospongiosus.
2. Superficial part of external urethral sphincter (sphincter urethrae).
3. Superficial part of external anal sphincter



-  Perineal body
-  Ischio-cavernosus
-  Bulbocavernosus
-  Transverse perineal

Muscles of perineum

Nerve Supply : All muscles in superficial and deep perineal pouches are supplied by perineal branch of pudendal nerve

❑ Muscles of Superficial Perineal Pouch :

1- Ischiocavernosus :

Site : Each covers the crus penis.

Action : it compresses crus penis to maintain erection of penis.

2- Bulbospongiosus :

Site : covers bulb of penis. In female, it is splitted into two parts to cover bulbs of vestibule.

Action : In Male , Assist in erection of penis and eject last drops of urine during micturition.

In Female: act as sphincter vagina and help in erection of clitoris

3- Superficial transverse perineal:

Site : on posterior edge of perineal membrane in front of anus.

Action : fixation the perineal body.

Muscles of the Deep perineal Pouch : *These muscles form the urogenital diaphragm.*

1- Sphincter urethrae :

Site : it surrounds membranous urethra.

Attachments : it is formed of two parts :

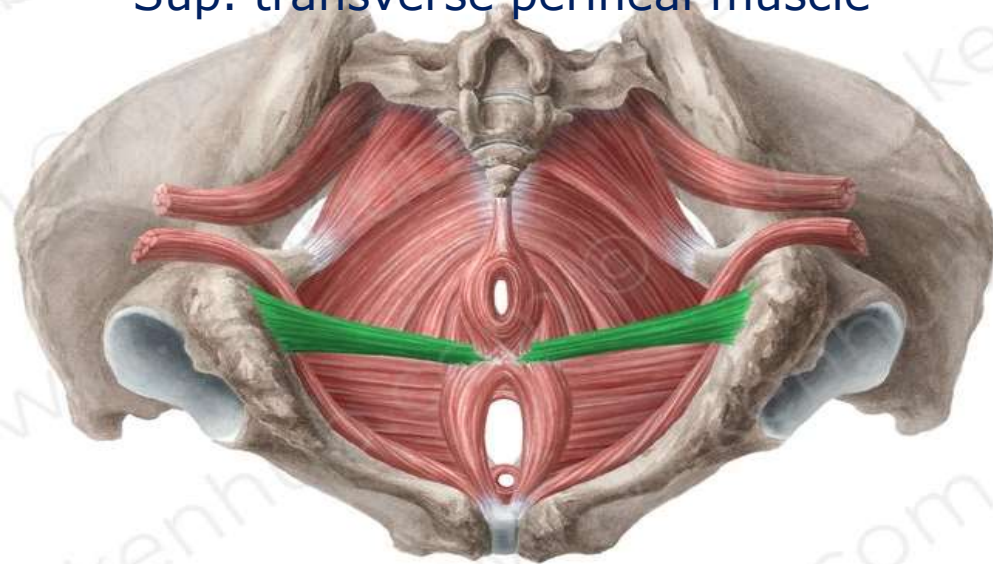
- **Inferior (or superficial) part :**
- **Superior (or deep) part :**
- **Action :** It represents the voluntary control of urethra.

2- Deep transverse perineal

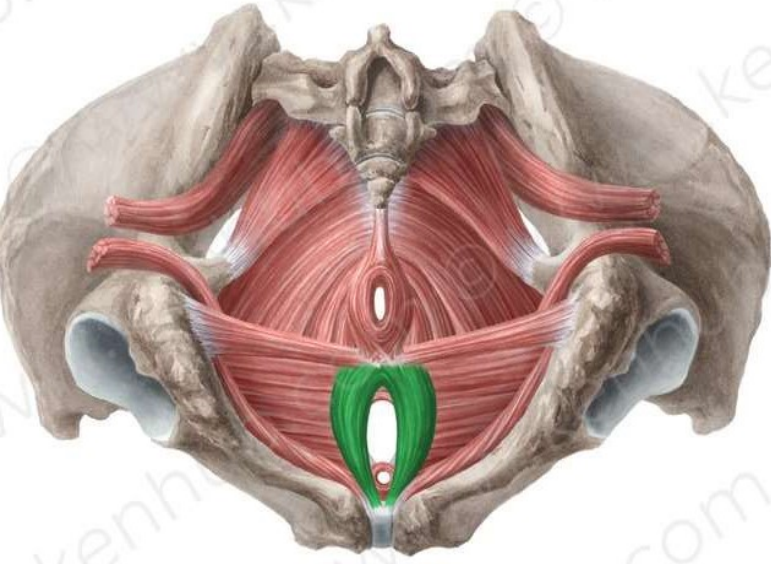
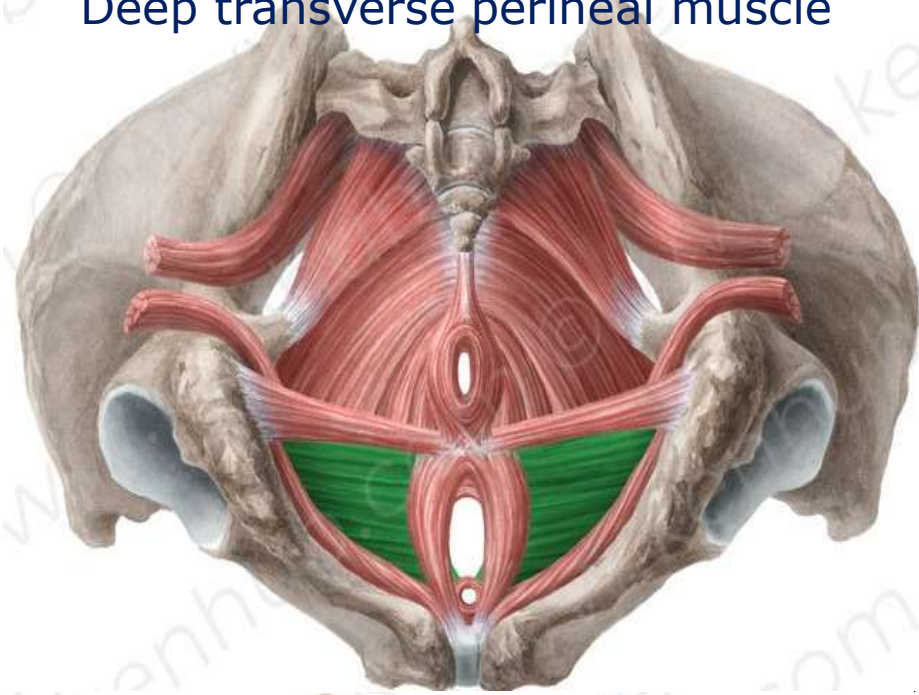
Site : on deep surface of posterior border of the perineal membrane.

Action : fixation of perineal body.

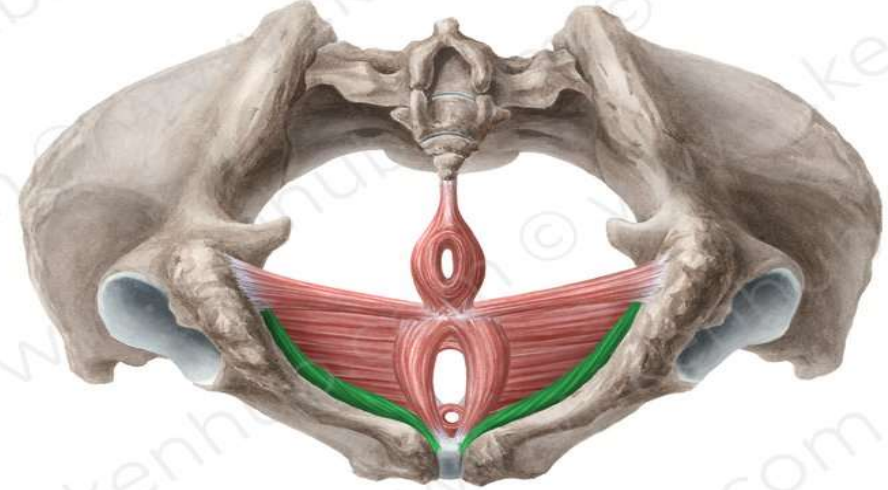
Sup. transverse perineal muscle



Deep transverse perineal muscle



Bulbospongiosus muscle



Ischiocavernosus muscle

Dr. Ahmed Salm:

The perineal fascia

consists of superficial and deep layers

Superficial perineal fascia, consists of a superficial fatty layer and a deep membranous layer (***Colles fascia***).

The superficial fatty layer

In females, It makes up the substance of the labia majora and mons pubis

It is continuous with the fatty layer of subcutaneous tissue of the abdomen

(Camper fascia)

In males, the fatty layer is replaced with smooth (*dartos*) muscle.

It is continuous with the fatty layer of subcutaneous tissue of the abdomen .

In both sexes, it is continuous posteriorly with the ischio-anal fat pad in the anal region .

The membranous layer (*Colles fascia*).

is attached To

Posteriorly : The posterior margin of the perineal membrane and the perineal body

Laterally, the *fascia lata* (deep fascia) of the upper medial aspect of the thigh.

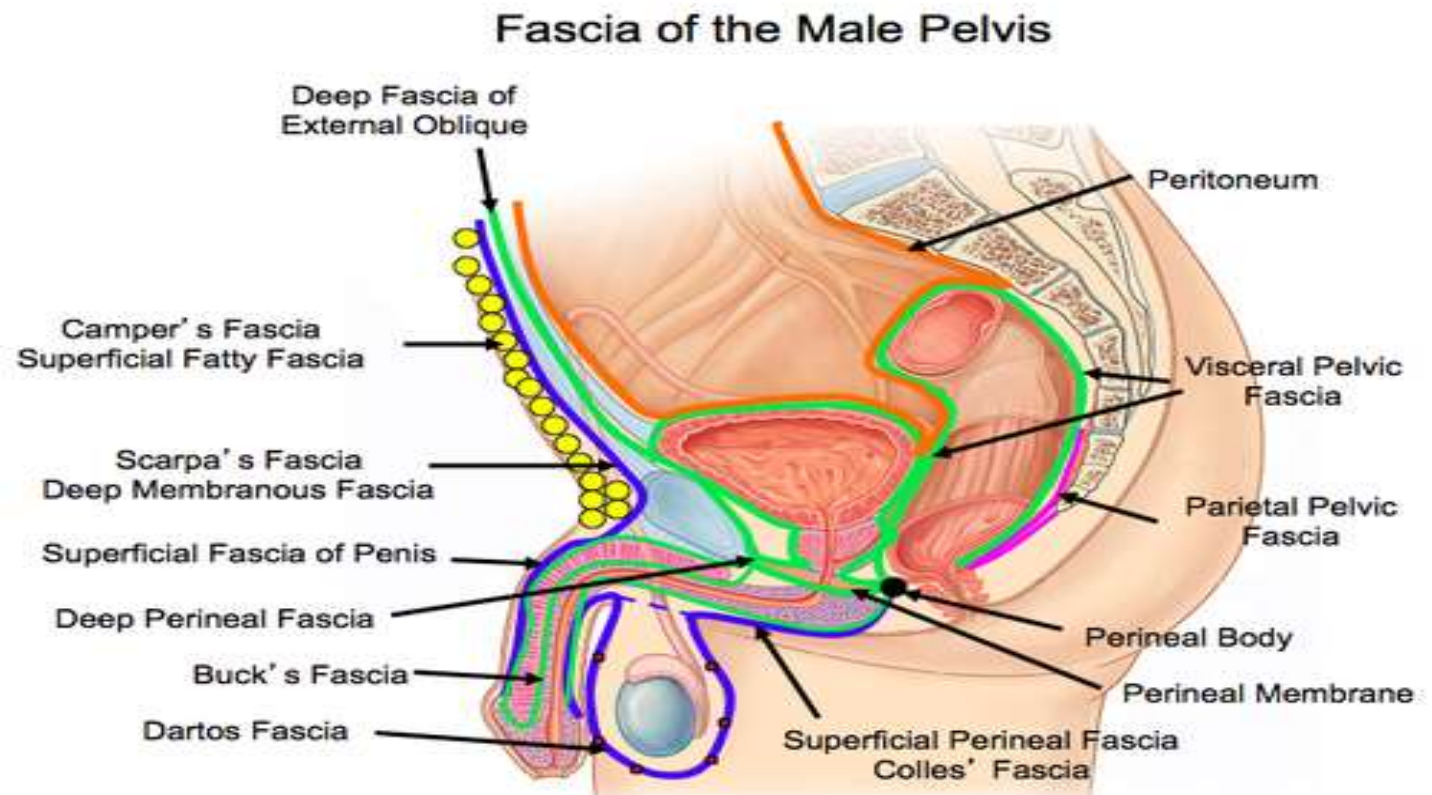
Anteriorly, in the male, the membranous layer of subcutaneous tissue is continuous with the fascia of the penis and scrotum

On each side of the scrotum, the membranous layer becomes continuous with the membranous layer of subcutaneous tissue of the abdomen (***Scarpa fascia***) .

.

The perineal fascia (deep perineal, investing, or Gallaudet fascia)

- Invests the ischiocavernosus, bulbospongiosus, and superficial transverse perineal muscles.
- It is also attached laterally to the ischio-pubic rami.
- Anteriorly, it is fused to the suspensory ligament of the penis



The perineal fascia

Superficial perineal fascia

Deep perineal (Gallaudet fascia)

The superficial fatty layer

It is continuous with (***Camper fascia***)

The membranous layer (***Colles fascia***)

It is attached to ***fascia lata***
It is continuous with (***Scarpa fascia***)

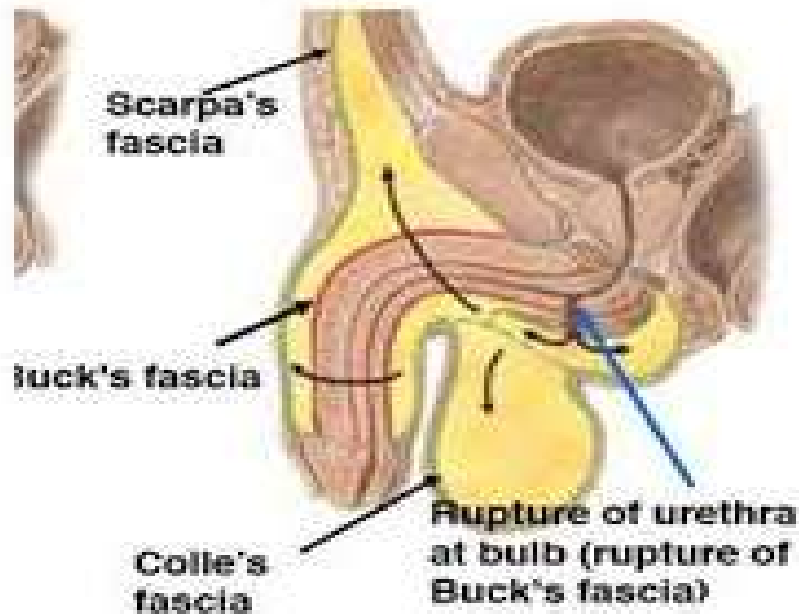
Rupture of the Urethra

1- Spongy Urethra

Cause : (Straddle injury)


- a) Sever blow to perineum
- b) Falling on metal beam

The urine extravasates into the superficial perineal pouch and then passes forward into loose connective tissue of the scrotum, around the penis beneath the membranous layer of the subcutaneous connective tissue of lower part of anterior abdominal wall.

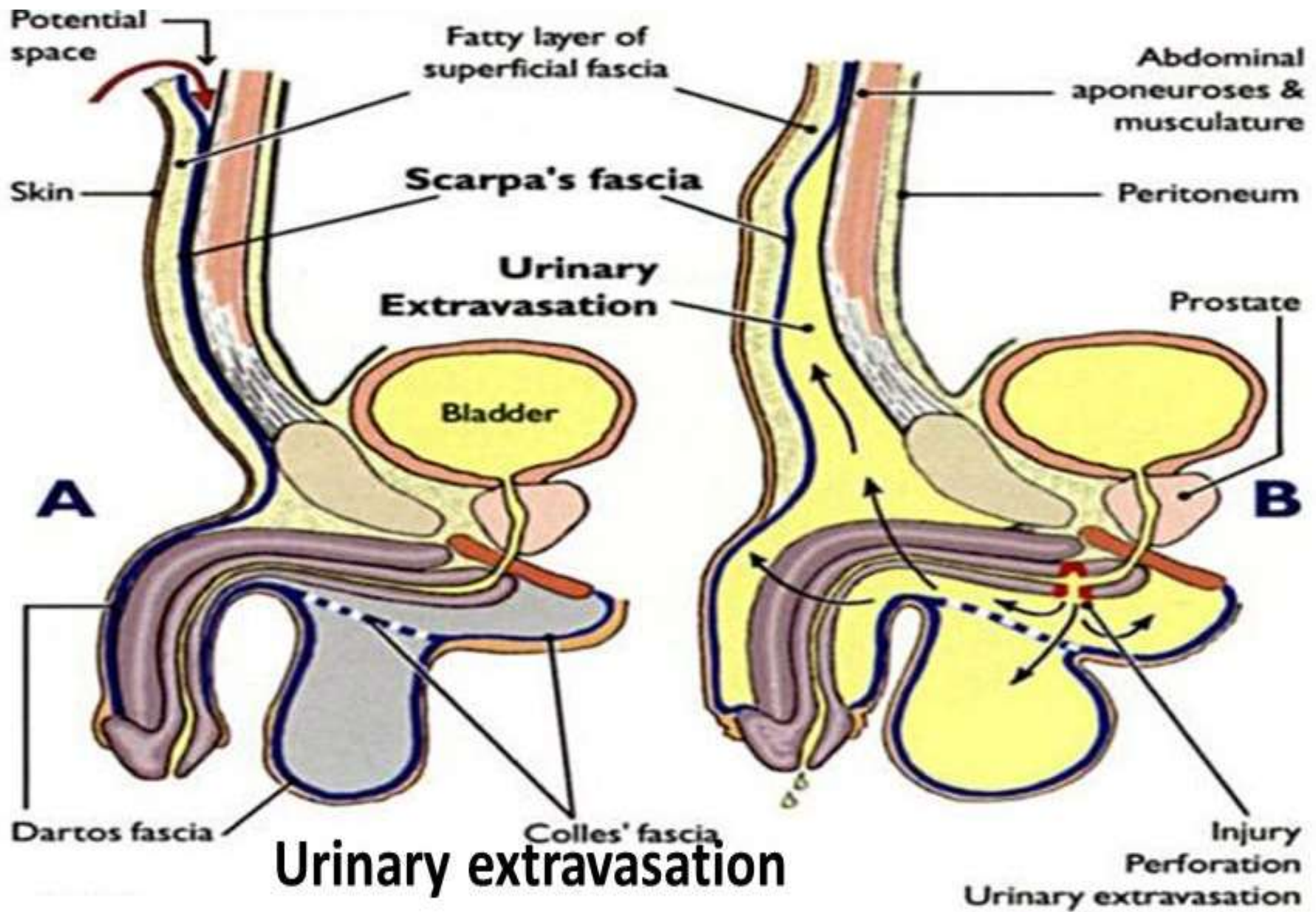


Dr. Ahmed Salman

Straddle Injuries



Lower GU Trauma



Site of rupture

2-Membranous part

Cause:

- a) Fracture Pelvis
- b) Fault catheterisation

The urine escapes into the deep perineal pouch and may be pass upward around the prostate and bladder (extra peritoneal) through urogenital hiatus.

IN BOTH CASES

The urine cannot passes into thigh because attachment of colles fascia with fasciae lata below inguinal ligament.

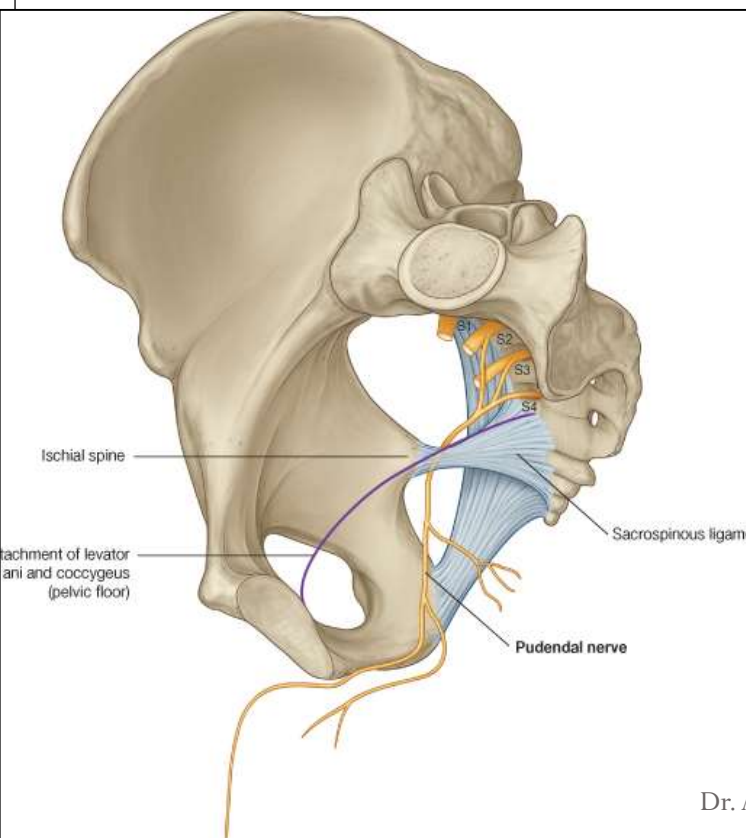
Also cannot passes posteriorly to anal triangle due to fusion of superficial and deep layer of perineal fascia around posterior edge of perineal membrane

Pudendal canal:

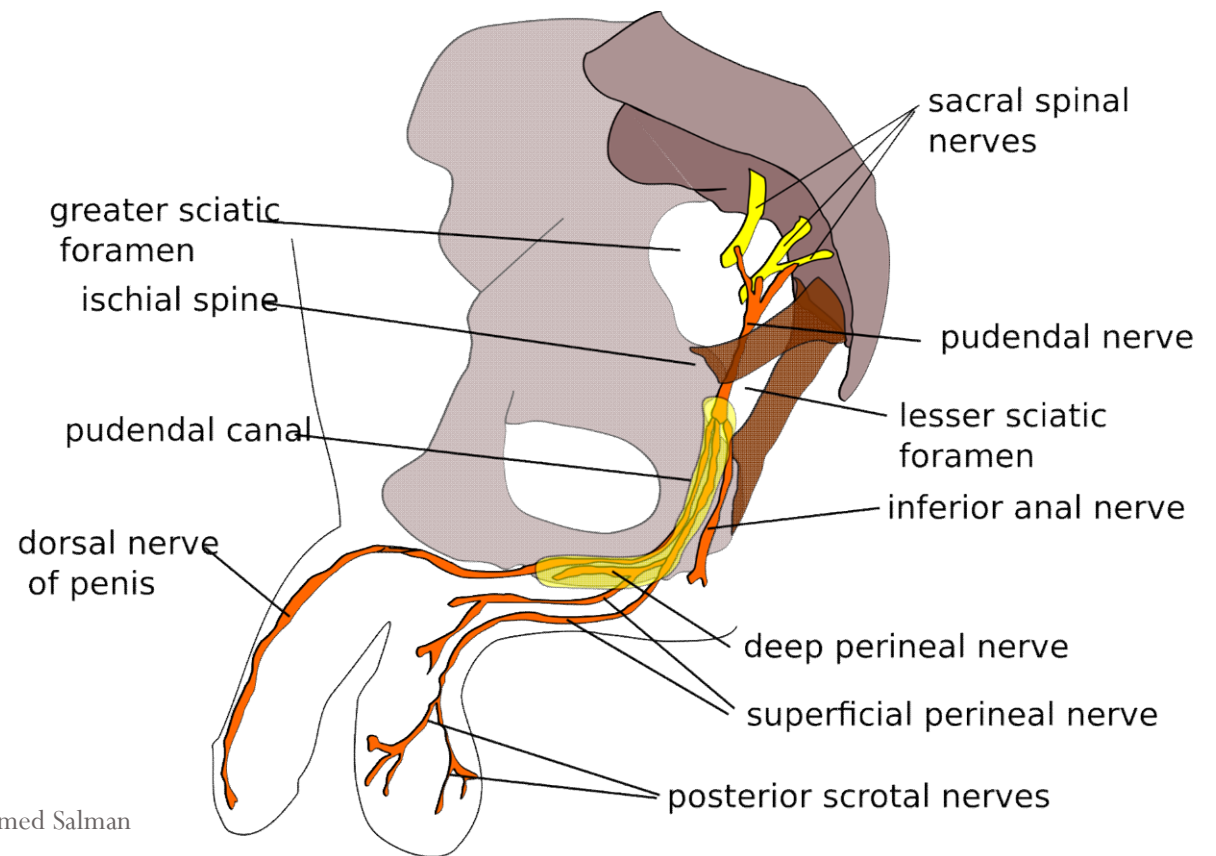
Location : Fascial canal in lower part of the lateral wall of ischiorectal fossa

Extend: From the lesser sciatic foramen to the posterior border of the perineal membrane.

contents: 1- pudendal nerve 2- internal pudendal vessels



Dr. Ahmed Salman



Pudendal Nerve :

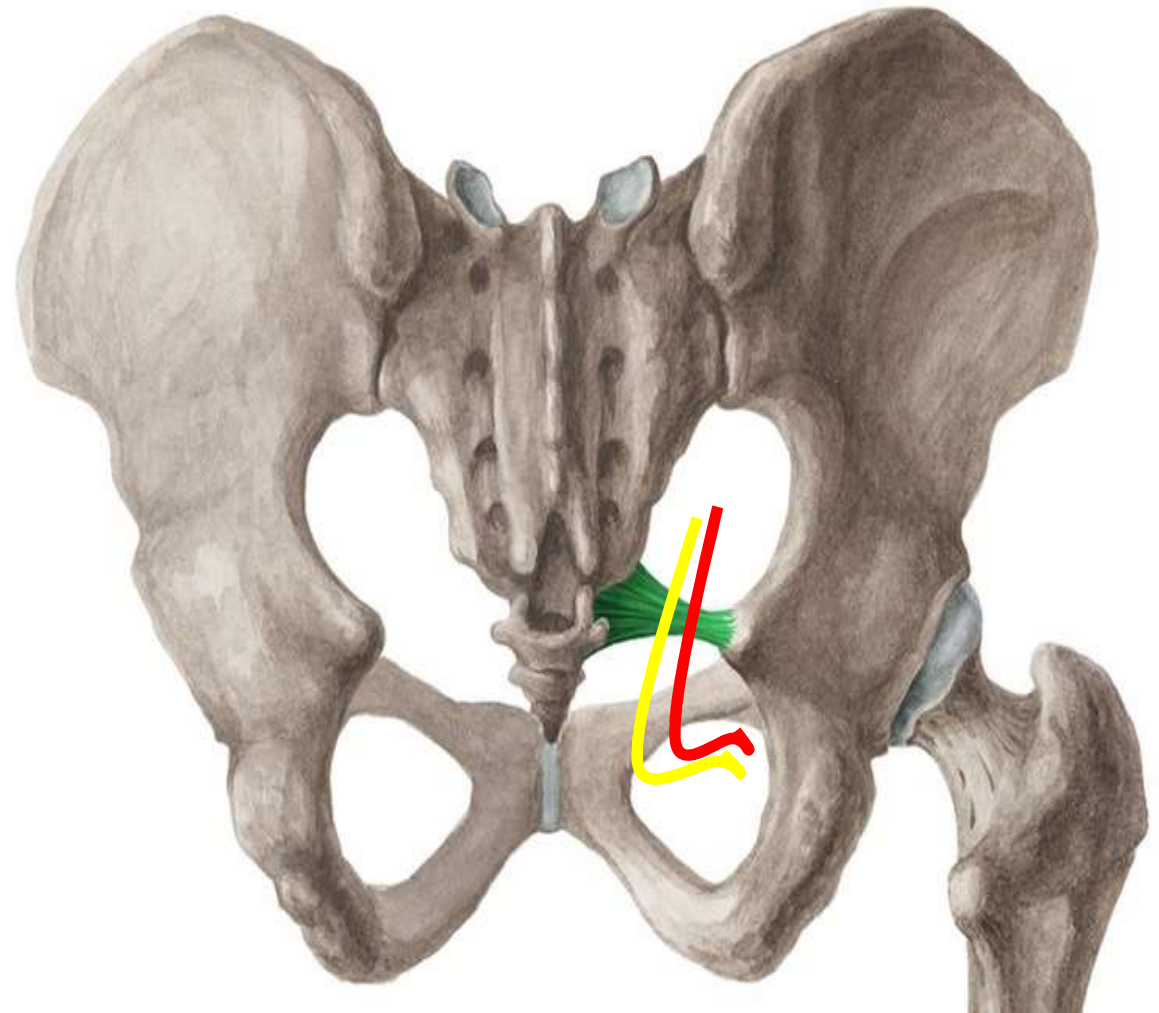
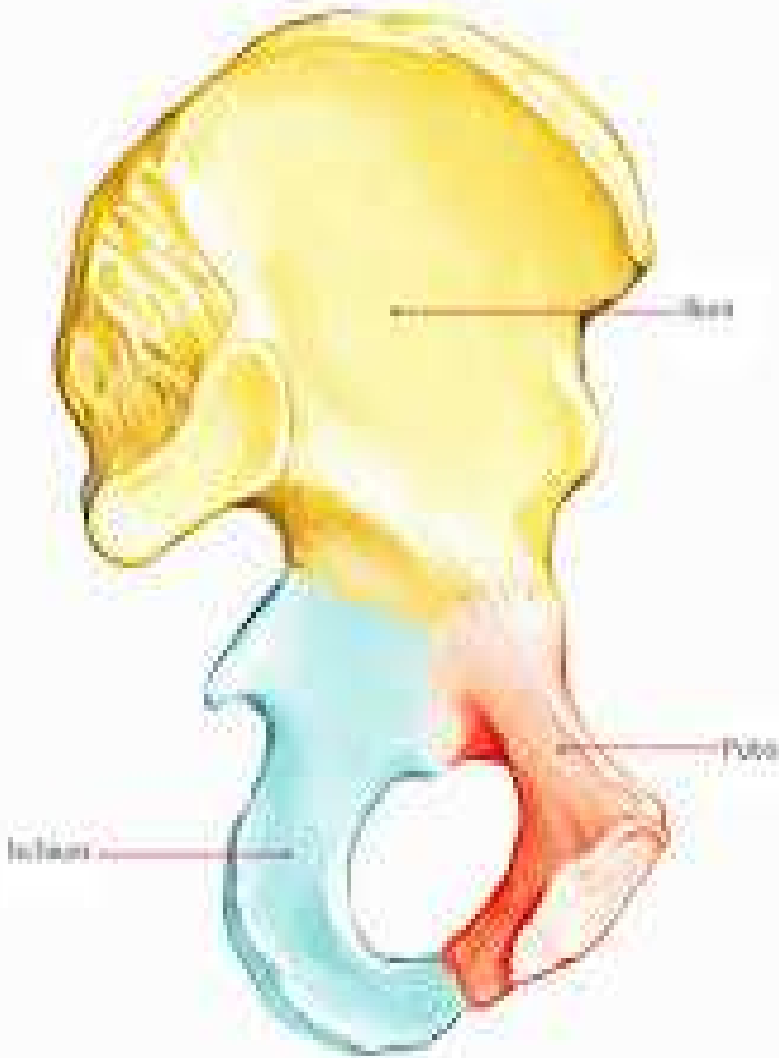
It is the *somatic* nerve of the *perineum* and external genitalia.

It arises from the sacral plexus; S2,3,4

Course and Relations :

- The nerve leaves the pelvis through the greater sciatic foramen *below* the piriformis to enter the gluteal region.
- In the **gluteal region**, the nerve crosses the **sacrospinous ligament** *medial* to the internal pudendal vessels which cross the ischial spine.
- The nerve and the vessels pass through the **lesser sciatic** foramen to enter the **pudendal canal** in side wall of ischiorectal fossa.
- In the posterior part of pudendal canal, the nerve gives inferior rectal N. and then divides into 2 terminal branches which are the perineal N. and dorsal nerve of penis (or clitoris).

Pudendal nerve (Yellow) crosses the **sacrospinous ligament *medial*** to the internal pudendal Artery (RED)



Branches and Distribution :

1- Inferior rectal N. (mixed)

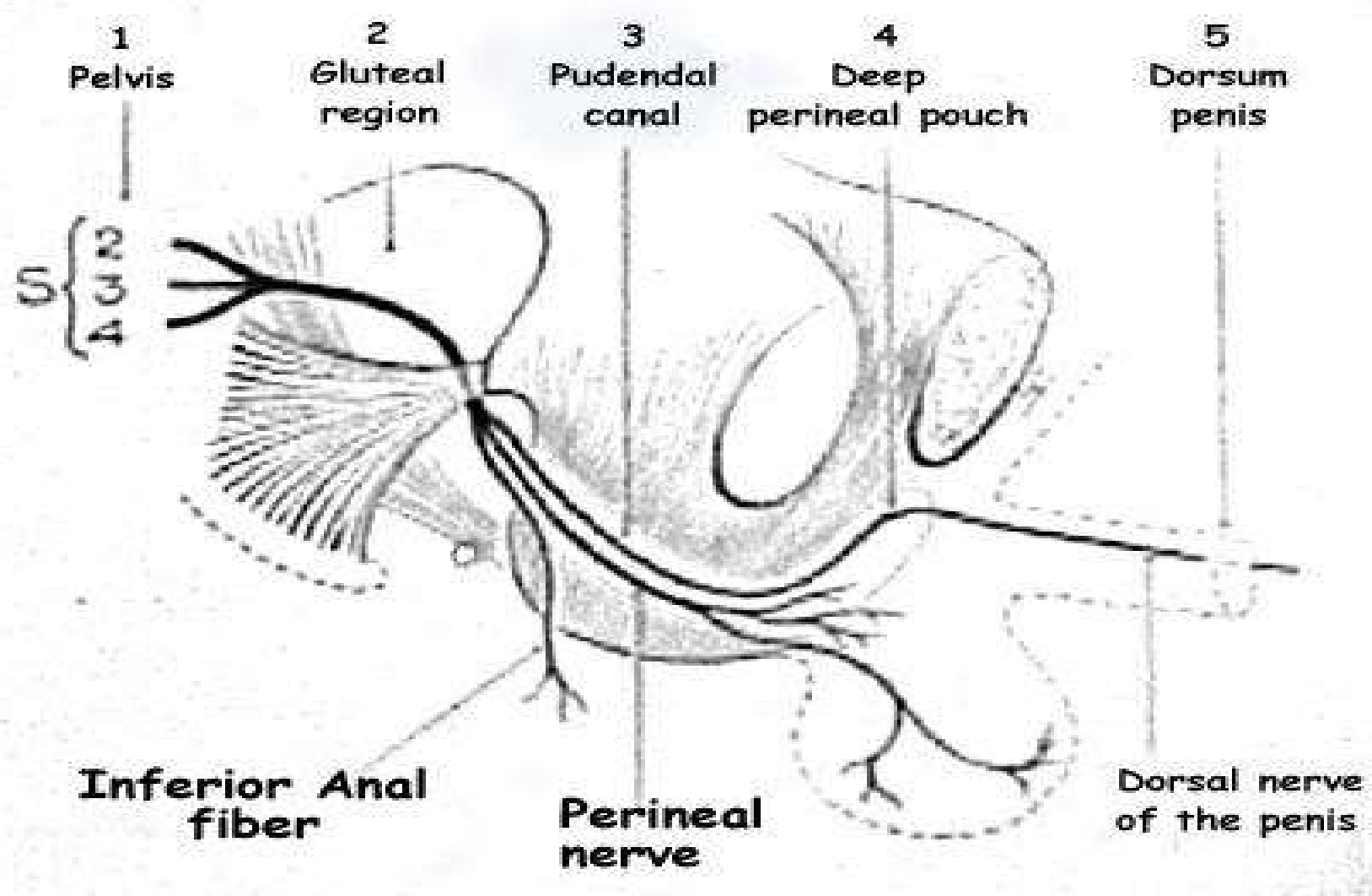
- **Motor** to external canal sphincter
- **Sensory** to anal canal *below* pectinate line, skin around the *anus* .

2- Perineal nerve (mixed) : it gives :

- **Motor** : to all muscles in the superficial and deep perineal pouches.
- **Sensory** : It gives 2 scrotal (labial) nerves, they pierce perineal membrane to supply posterior 2/3 of scrotum (or labium majora).

3- Dorsal nerve of penis or clitoris (sensory) :

- It enters the deep perineal pouch, then pierces the perineal membrane to enter the superficial perineal pouch.
- Then it runs on dorsum of penis, supplying its skin and glans.



1
Pelvis

2
Gluteal
region

3
Pudendal
canal

4
Deep
perineal pouch

5
Dorsum
penis

A.G.N.

Inferior Anal
fiber

Perineal
nerve

Dorsal nerve
of the penis

Internal Pudendal Artery:

It is the artery of perineum and external genital organs.

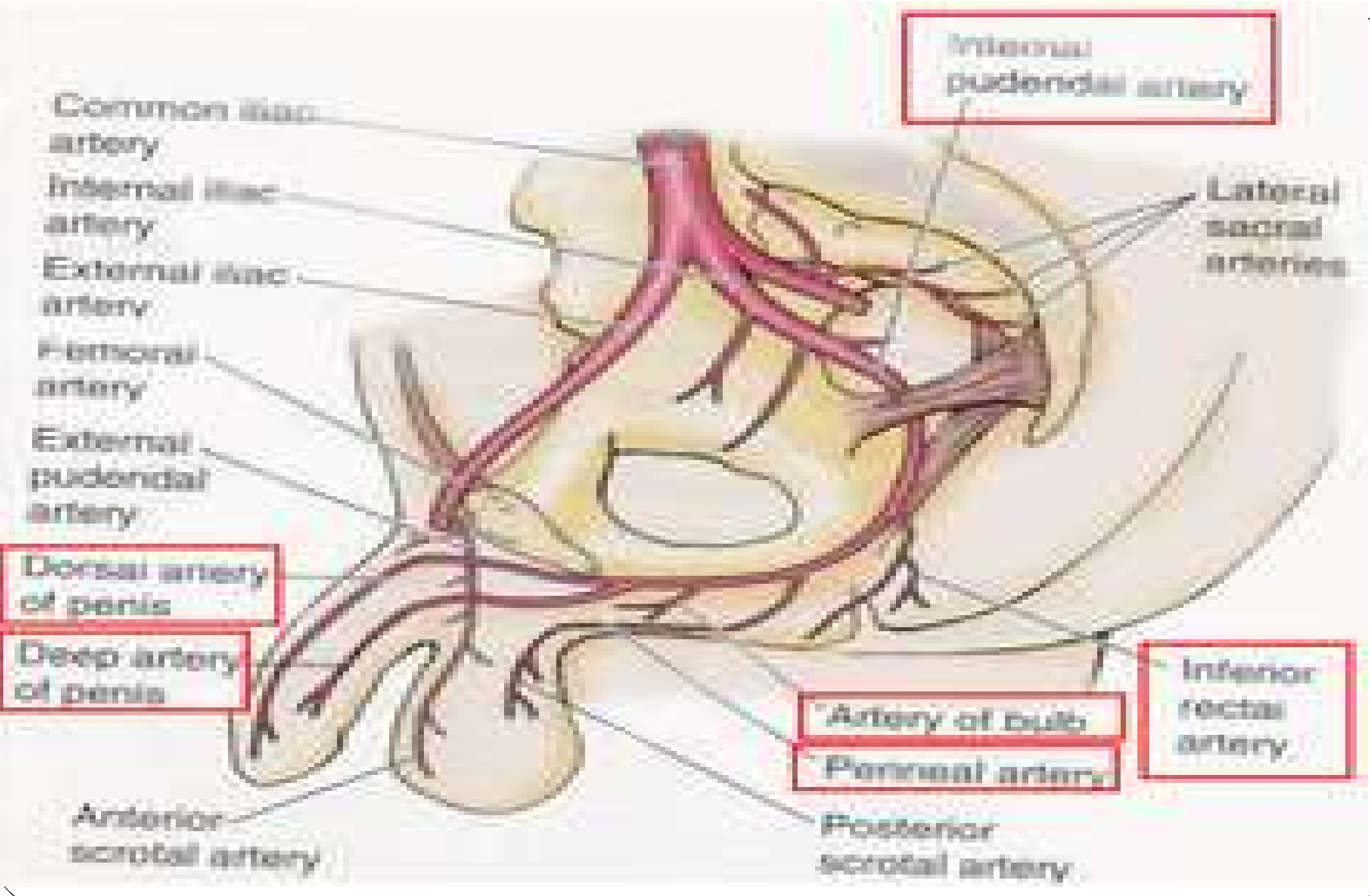
It is one of the two terminal branches of anterior division of internal iliac artery.

Course and Relations :

- **In the pelvis :** it descends in front of sacral plexus and piriformis and leaves the pelvis (with pudendal N.) below the piriformis to enter the gluteal region.
- In **gluteal region:** The artery crosses the tip of the ischial spine and passes through the lesser sciatic foramen to enter the **pudendal canal** in side wall of ischiorectal fossa.
- **In the pudendal canal and perineum :**

At the end of the pudendal canal, it enters the **deep perineal pouch** then pierces the perineal membrane to enter the **superficial perineal pouch** to run close to the side of pubic arch

It ends by dividing into dorsal and deep arteries of the penis



Internal pudendal artery

Lateral sacral arteries

Common iliac artery

Internal iliac artery

External iliac artery

Femoral artery

External pudendal artery

Dorsal artery of penis

Deep artery of penis

Artery of bulb

Penile arteries

Inferior rectal artery

Anterior scrotal artery

Posterior scrotal artery

Branches and Distribution :

two in the pudendal canal, **two** in the deep perineal pouch and **two** terminal in the superficial perineal pouch.

A. In the pudendal canal :

1-Inferior rectal A. : It supplies anal canal *below* the pectinate line.

2-Perineal A. : it gives

- Two scrotal (or labial) arteries to scrotum (or labia majora)
- Transverse perineal A. which anastomoses with its corresponding one .

B- In the deep perineal pouch :

3-Artery of bulb : supplies bulbourethral glands and pierces perineal membrane to supply bulb of root of penis (or bulb of vestibule).

4-Urethral A. : pierces perineal membrane to enter superficial perineal pouch to supply corpus spongiosum and urethra.

C-Superficial perineal pouch :

5-Dorsal A. of penis : runs on dorsum of penis, supplying its skin, fascia and glans of penis.

6-Deep A. of penis : runs in corpus cavernosum, supplying its cavernous tissue.

Internal pudendal artery

Internal pudendal nerve

Inferior rectal

Inferior rectal N

Perineal A

Perineal N

Two scrotal (or tibial)

Two scrotal (or tibial)

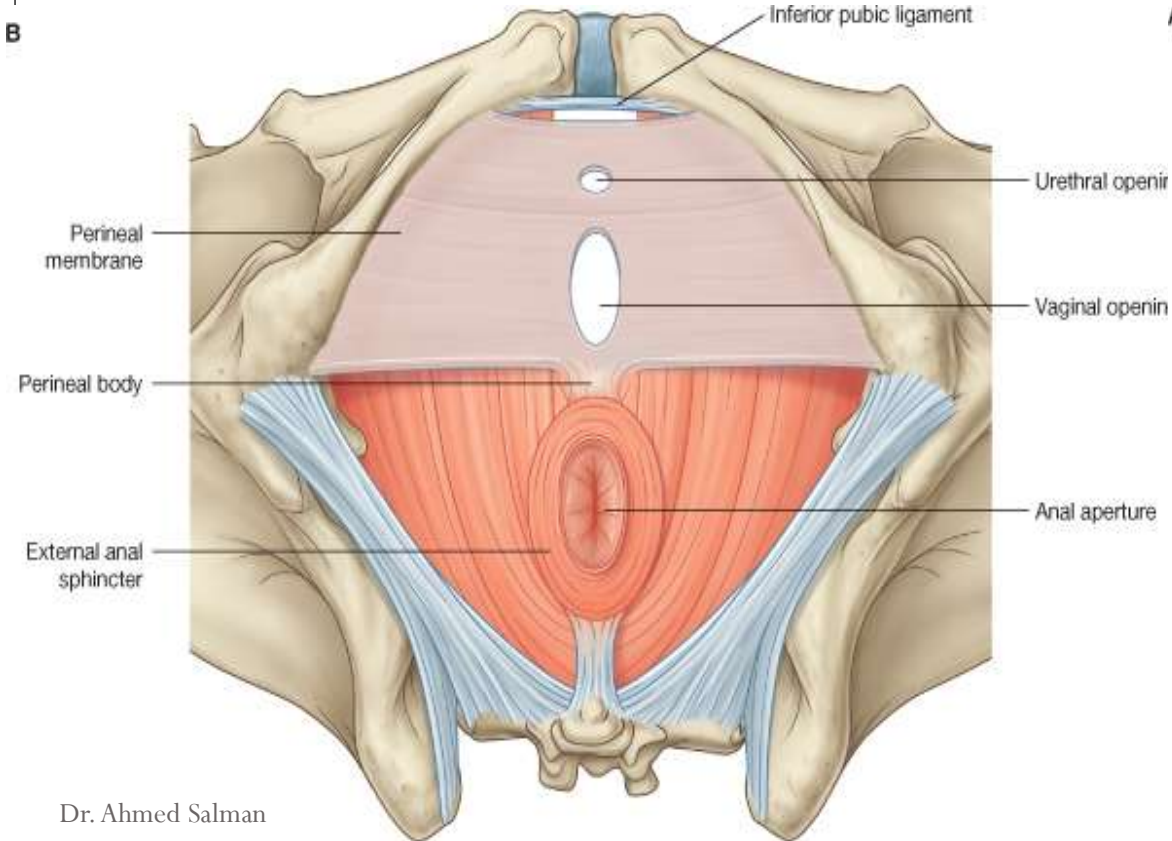
Transverse perineal A

Artery of the bulb
Urethral artery

Dorsal artery of the penis
Deep artery of the penis

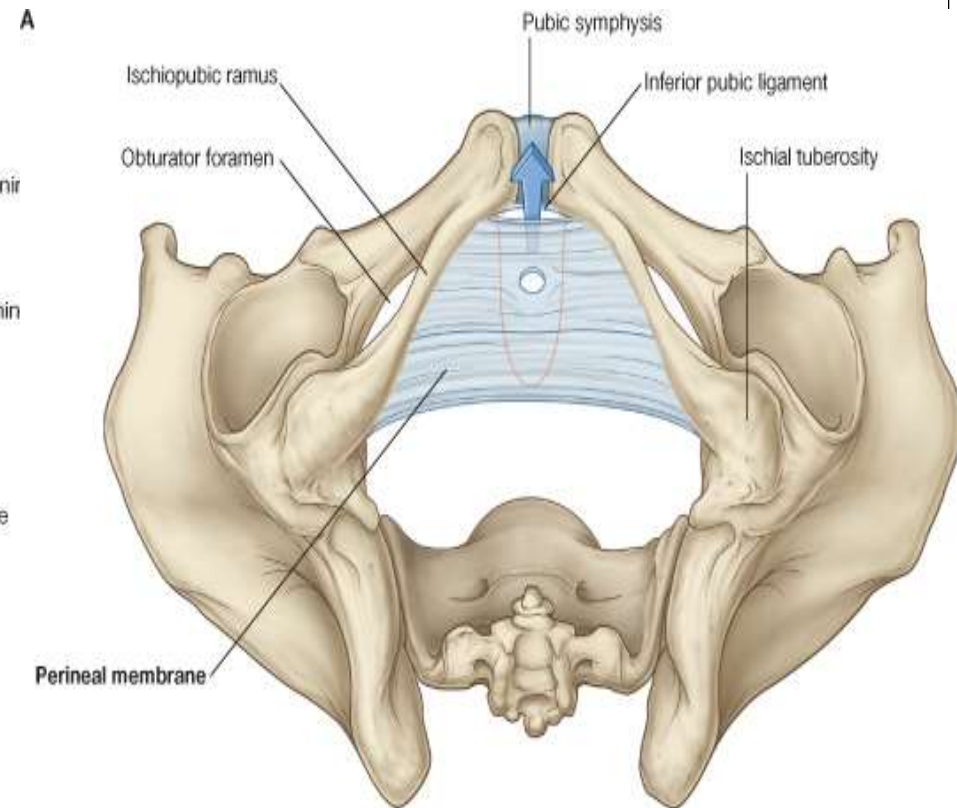
Dorsal nerve of penis or clitoris

Perineal pouches



Dr. Ahmed Salman

© Elsevier. Drake et al: Gray's Anatomy for Students - www.studentconsult.com



© Elsevier. Drake et al: Gray's Anatomy for Students - www.studentconsult.com

Deep Perineal pouch :

Boundaries :

Floor : Perineal membrane (inferior fascia of urogenital diaphragm)

Roof: Inferior fascia of pelvic diaphragm (levator ani)

On either side : Obturator fascia.

Posteriorly : The pouch is closed by union of roof and floor.

Anteriorly : The pouch is closed by union of roof and floor below symphysis pubis to form the transverse perineal ligament.

The transverse perineal ligament

Is separated from the symphysis pubis by an oval opening. Through this opening

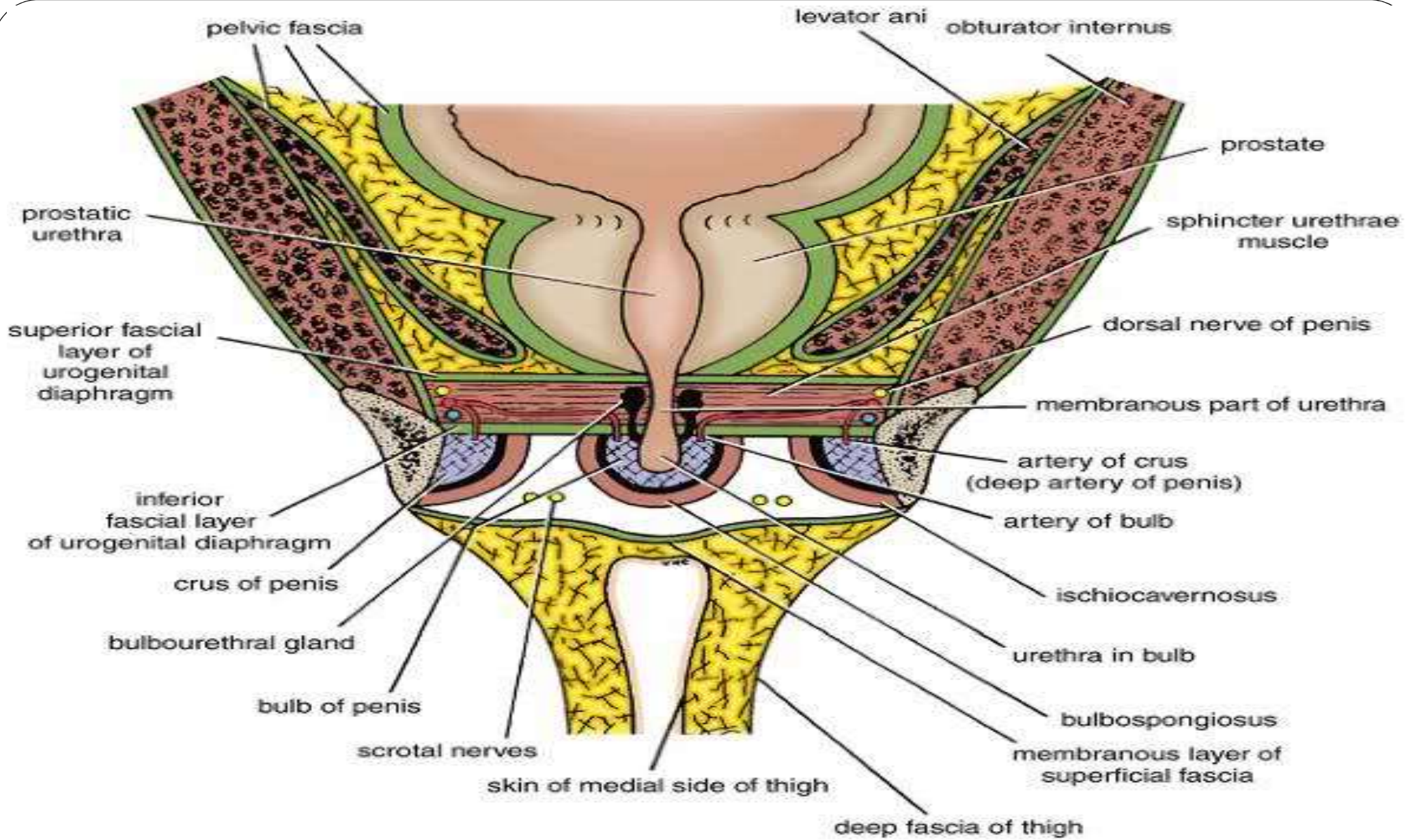
In male the deep dorsal vein of penis enters the pelvis to join the prostatic venous plexus.

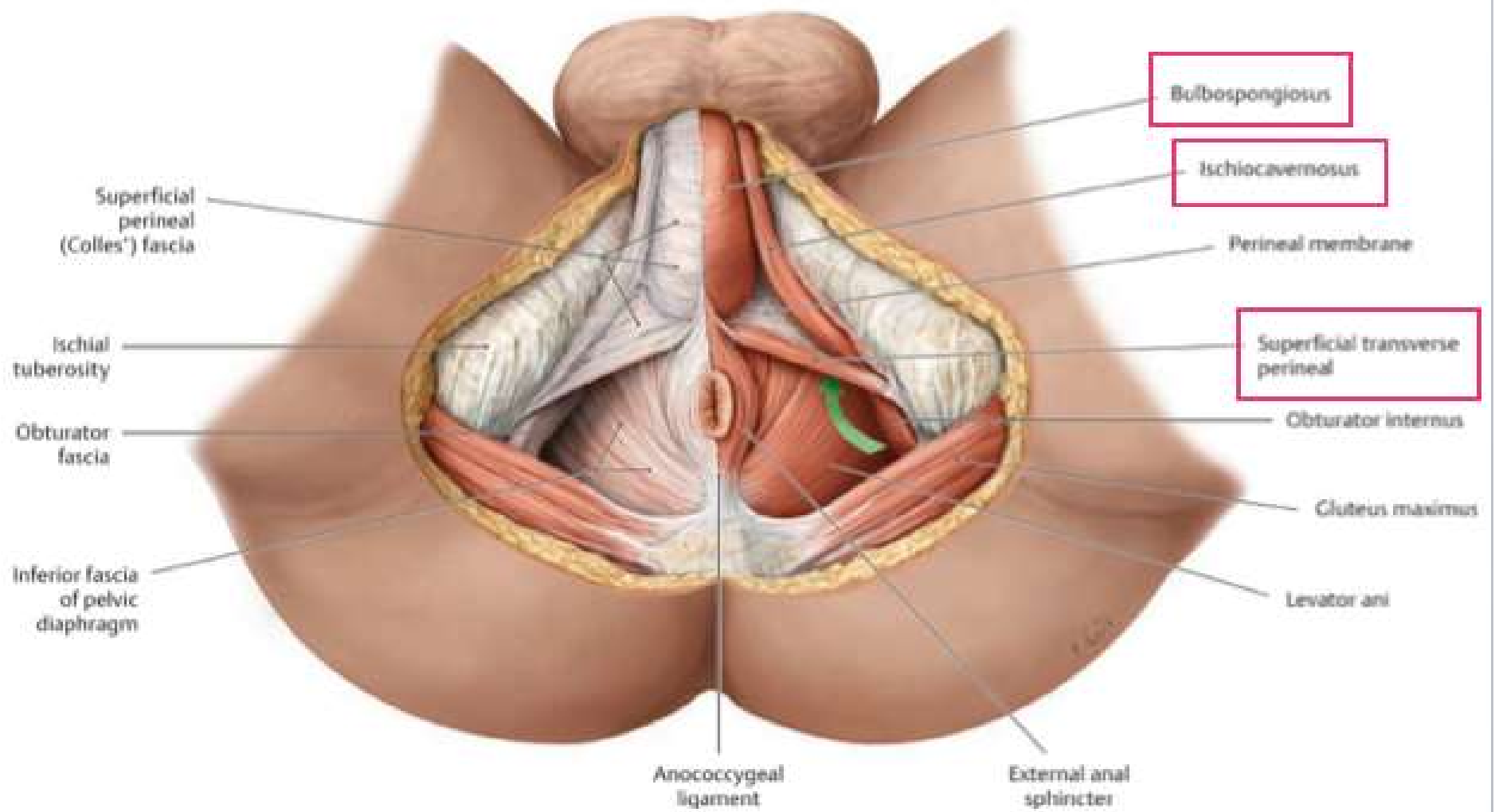
In female, the deep dorsal vein of clitoris joins the vesical venous plexus

Contents of Deep Perineal pouch

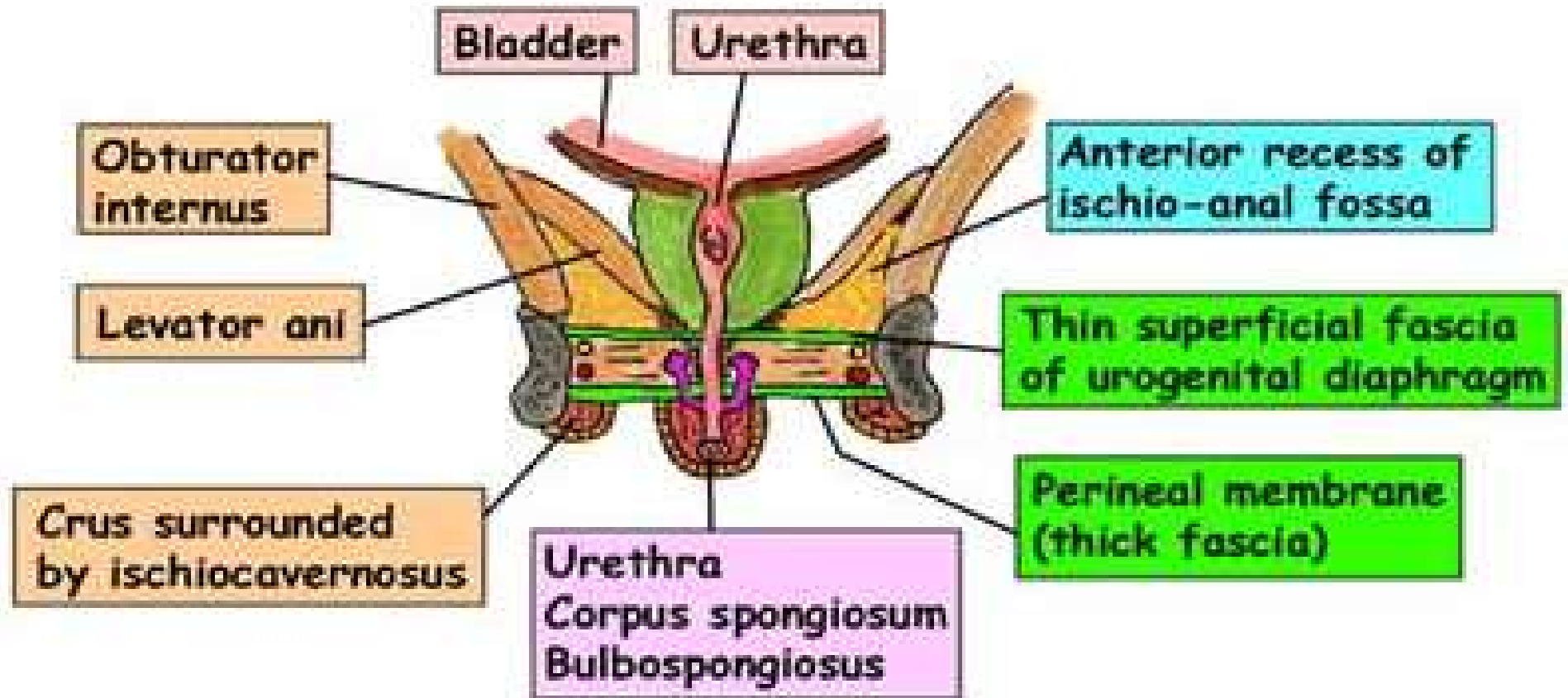
	Male	Female
Urogenital Structures	<ul style="list-style-type: none"> • Membranous urethra • Bulbourethral glands 	<ul style="list-style-type: none"> • Part of the urethra • Part of vagina
Muscles	<ul style="list-style-type: none"> • Sphincter urethrae • Deep transverse perineal muscles (These two muscles form the <i>urogenital diaphragm</i> .)	
Vessels	<ul style="list-style-type: none"> ▪ Internal pudendal A. ▪ Artery of bulb. ▪ Urethral A. ▪ Perineal A. 	<ul style="list-style-type: none"> ▪ Internal pudendal A. ▪ Artery of bulb of vestibule. ▪ Perineal A.
Nerves	<ul style="list-style-type: none"> ▪ Dorsal N. of penis. ▪ Perineal N. 	<ul style="list-style-type: none"> ▪ Dorsal N. of clitoris. ▪ Perineal N.

N.B. : the greater vestibular glands of the female lie in the *superficial* perineal pouch, the bulbourethral glands of the male lie in the *deep* perineal pouch

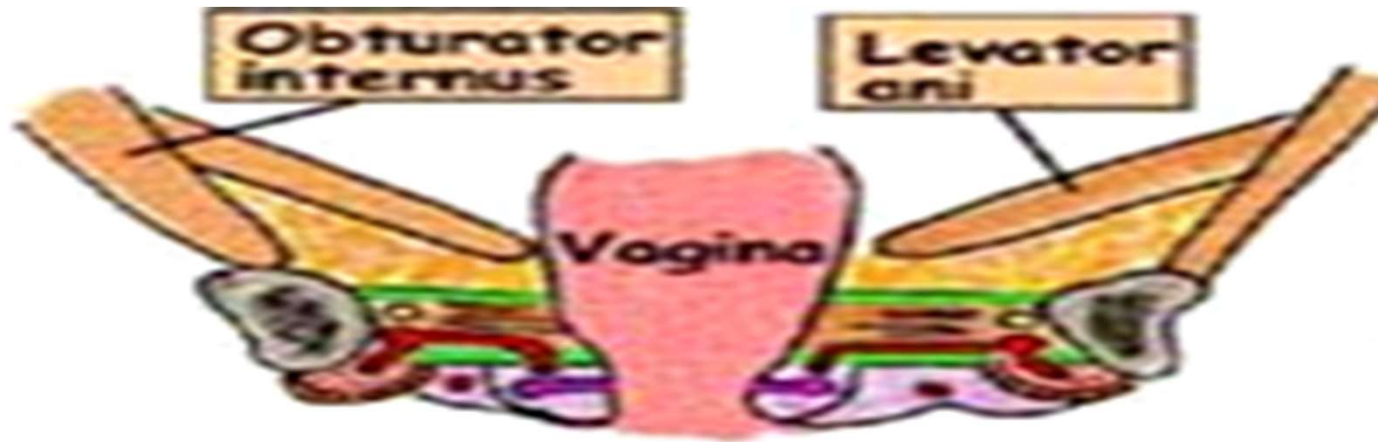




Deep perineal pouch in male



Deep perineal pouch in female



Coronal section
through urogenital
diaphragm at level
of vagina

Superficial Perineal Pouch:

Boundaries :

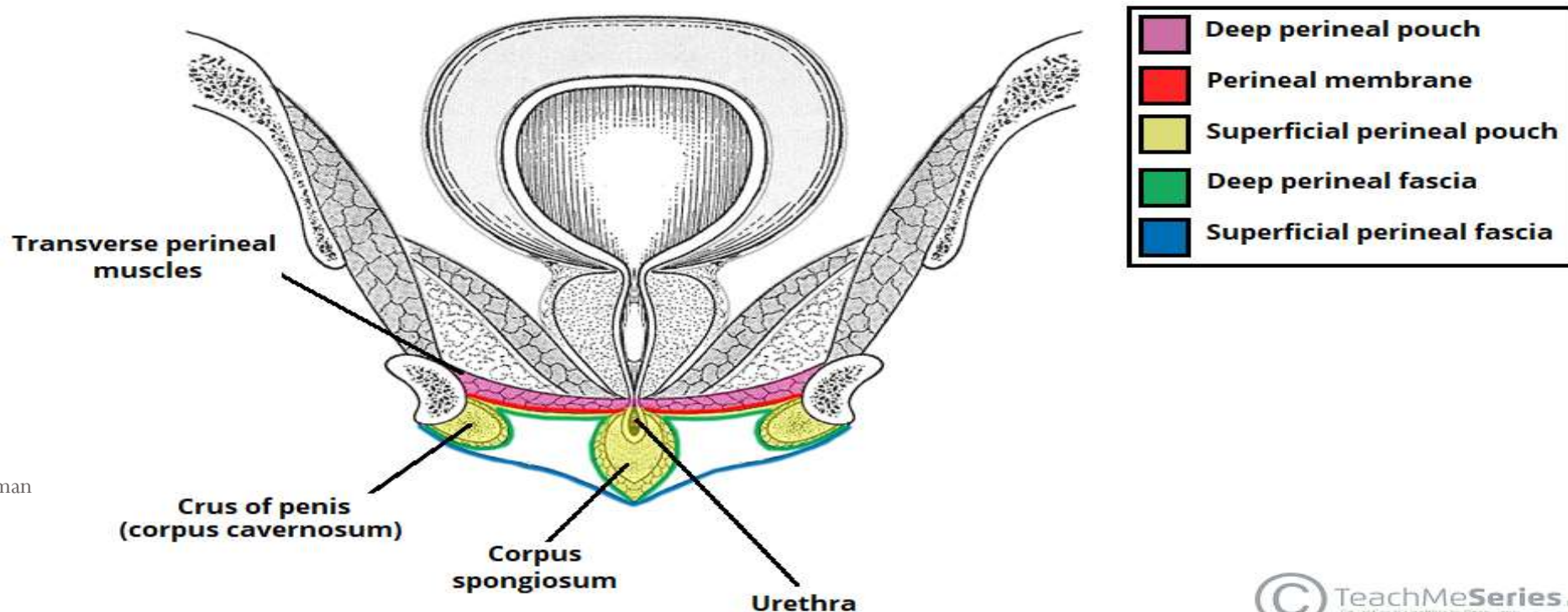
Floor : Membranous layer of the superficial fascia of the perineum (Colles fascia).

Roof : Perineal membrane.

On either side : both roof and floor are attached to the side of the pubic arch .

Posteriorly : The pouch is closed by union of the roof and floor.

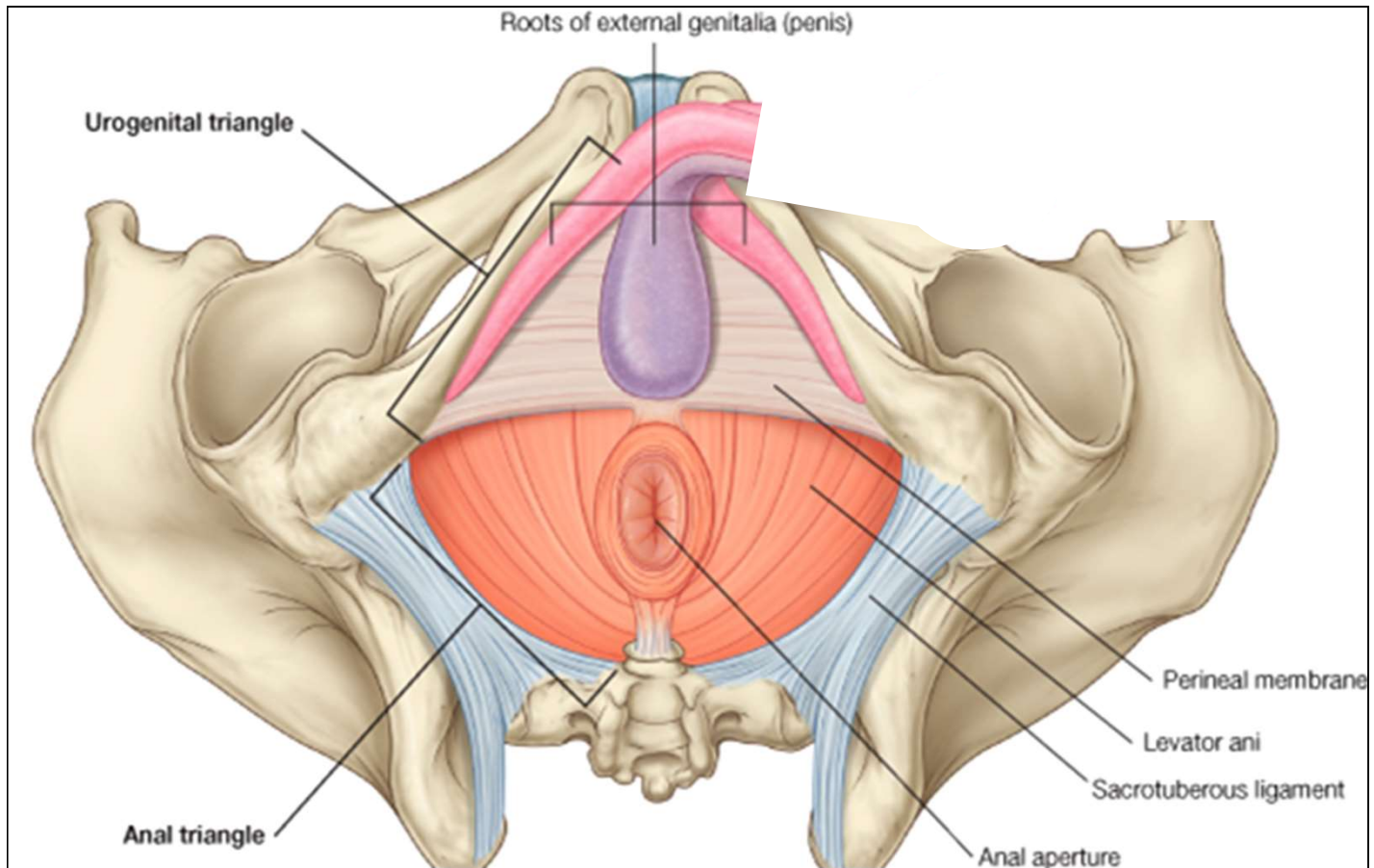
Anteriorly : The pouch is opened and continuous with the interval between the membranous layer of anterior abdominal wall and the external oblique aponeurosis



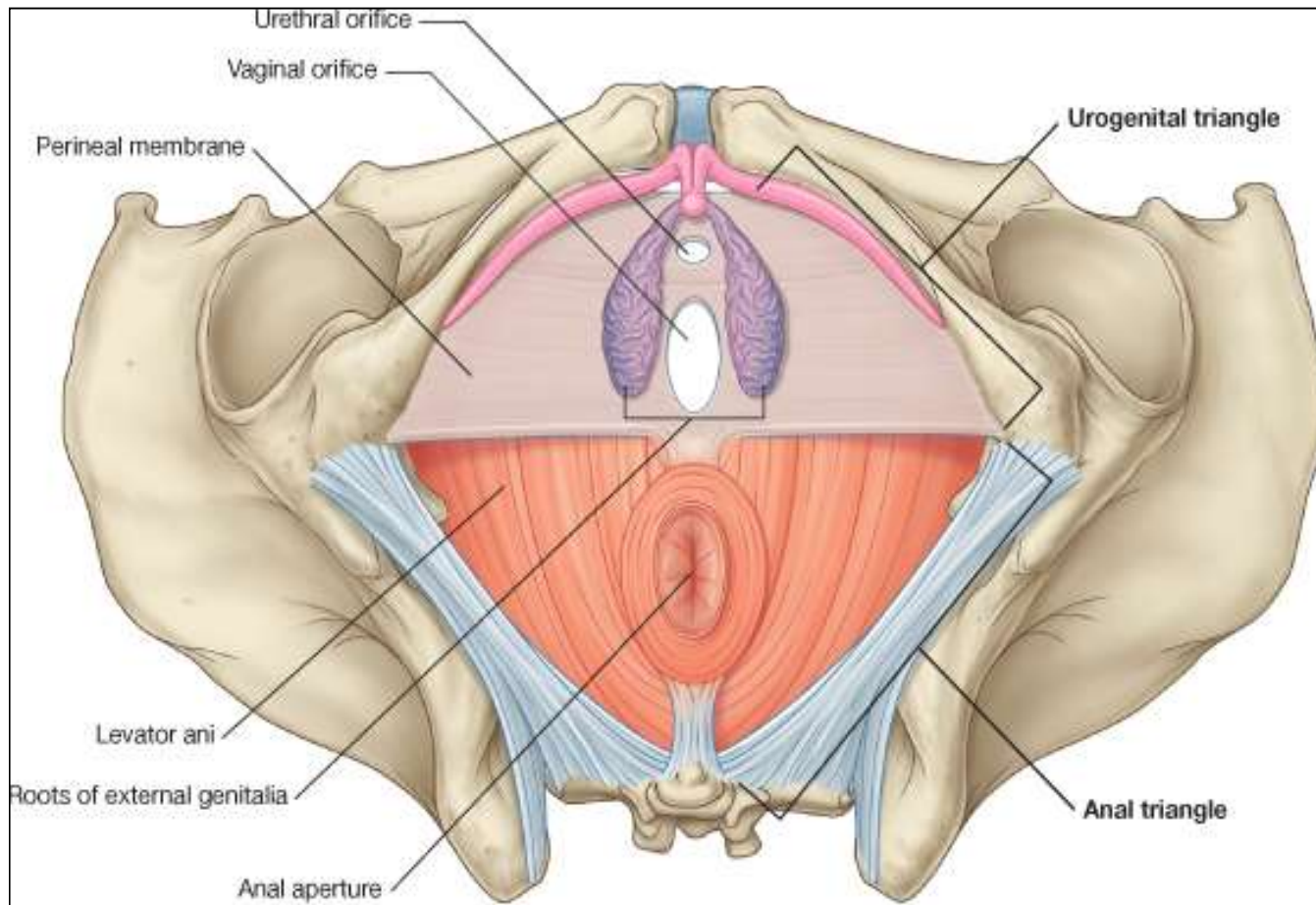
Contents of Superficial Perineal Pouch

	Male	Female
Urogenital Structures	<ul style="list-style-type: none"> • Root of penis (2 crura + Bulb) • Penile urethra in corpus spongiosum (bulb of penis) 	<ul style="list-style-type: none"> • Root of clitoris (2 crura) • Two bulbs of vestibule • Greater vestibular glands.
Muscles	<ul style="list-style-type: none"> • Two ischiocavernosus muscles cover the 2 crura • Bulbospongiosus muscle covers bulb of penis. • Two superficial transverse perineal muscles. 	<ul style="list-style-type: none"> • Two ischiocavernosus • Bulbospongiosus muscle • Two superficial transverse perineal muscles.
Vessels	<ul style="list-style-type: none"> • Dorsal A. of penis. • Deep A. of penis. • Two scrotal arteries 	<ul style="list-style-type: none"> • Dorsal A. of clitoris. • Deep A. of clitoris. • Two labial arteries.
Nerves	<ul style="list-style-type: none"> • Dorsal N. of penis. • Two scrotal nerves 	<ul style="list-style-type: none"> • Dorsal N. of clitoris. • Two labial nerves

Superficial perineal pouch in male

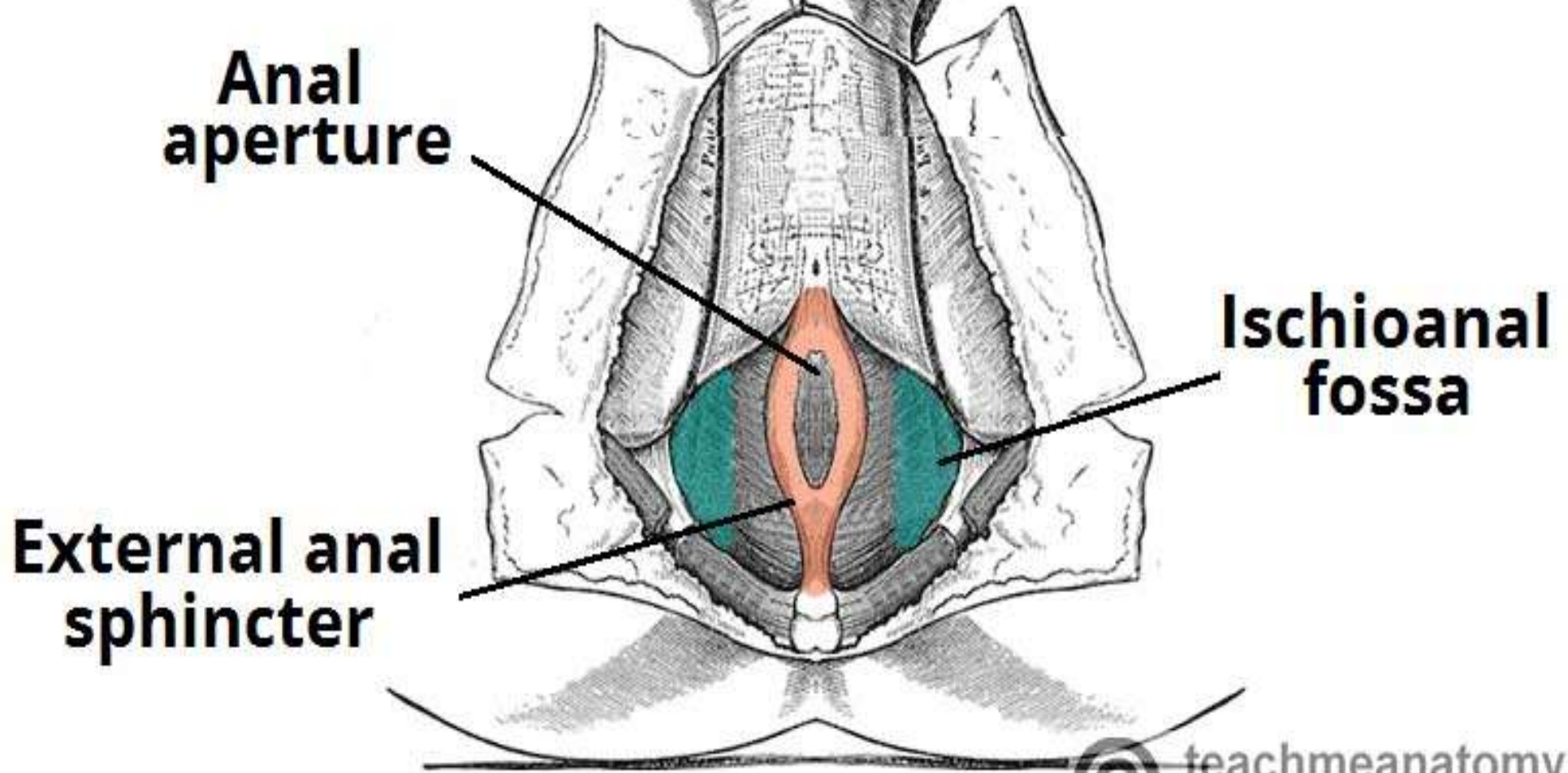


Superficial perineal pouch in female



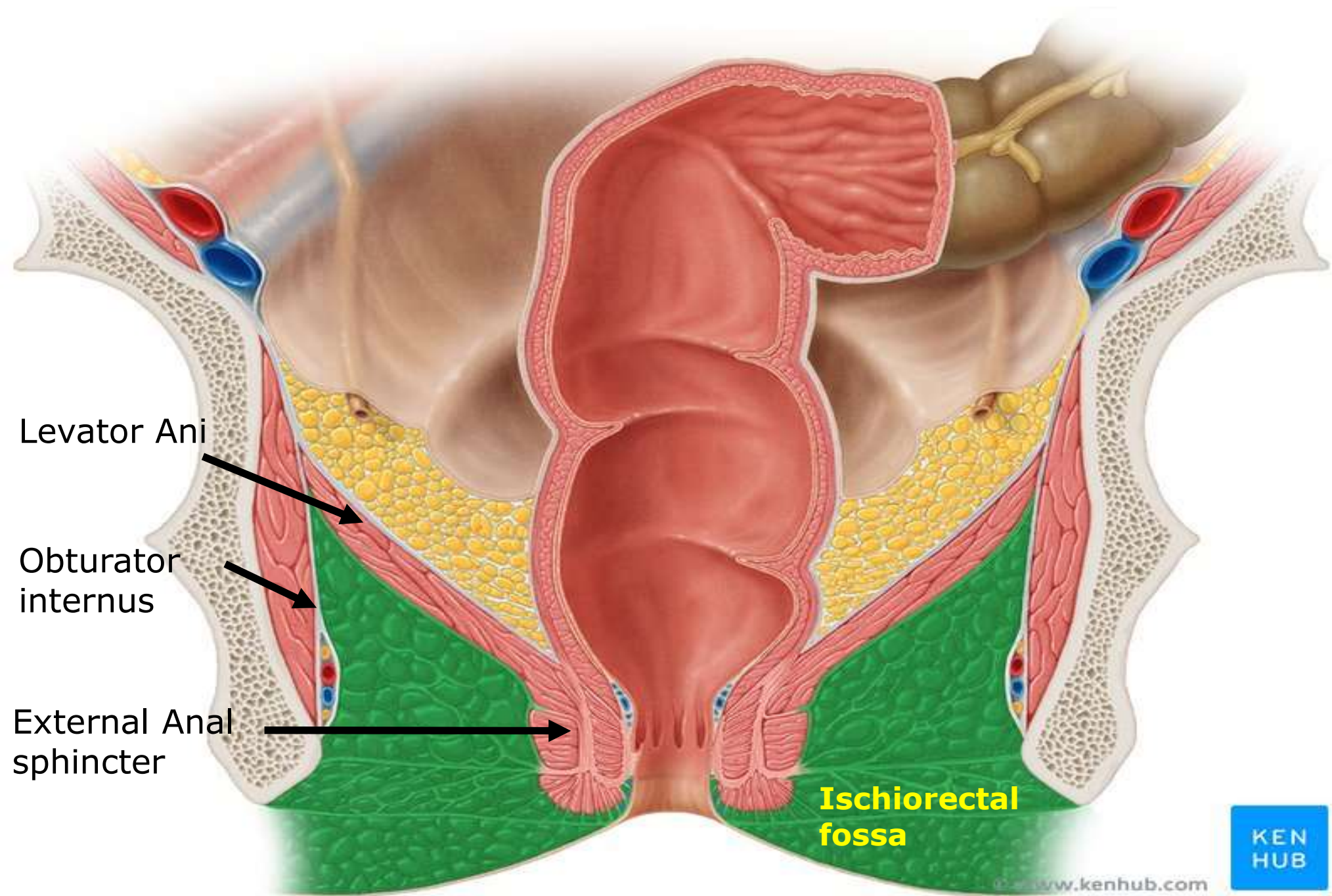
Ischioanal fossa

Location : It is wedge shaped space on either side of the anal canal



Boundaries : It has

- 1. Apex :** it is the origin of levator ani from the lateral pelvic wall (White line)
- 2. Base :** skin on either side of the anal orifice (skin of the base is supplied by inferior rectal N.).
- 3. Anteriorly :** the posterior border of the perineal membrane
- 4. Posteriorly :** sacrotuberous ligament covered by lower border of gluteus maximus muscle.
- 5. Lateral wall :** is vertical formed by :
 - Lower part of obturator internus muscle and lower part of obturator fascia splitting to form pudendal canal.
 - Medial surface of ischial tuberosity.
- 6. Medial wall :** formed by :
 - Levator ani muscle (lower surface).
 - External anal sphincter.



Levator Ani



Obturator internus



External Anal sphincter



Ischioanal fossa



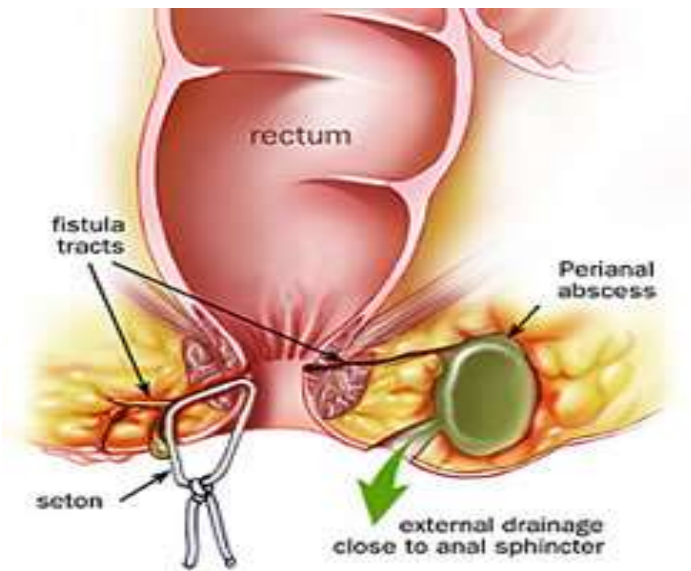
Contents of Ischiorectal fossa :

1. Pudendal nerve.
2. Internal pudendal vessels.
3. Inferior rectal nerve.
4. Inferior rectal vessels.
5. Posterior scrotal nerves.
6. Posterior scrotal vessels.
7. Perforating cutaneous N. (S2, S3) .
8. Pad of Fat : It is rich in fibroelastic fibres and has two functions :
 - It acts as a cushion support for rectum and anal canal.
 - It allows distention of the rectum and anal canal during defaecation,
Then compress them after termination of the act.

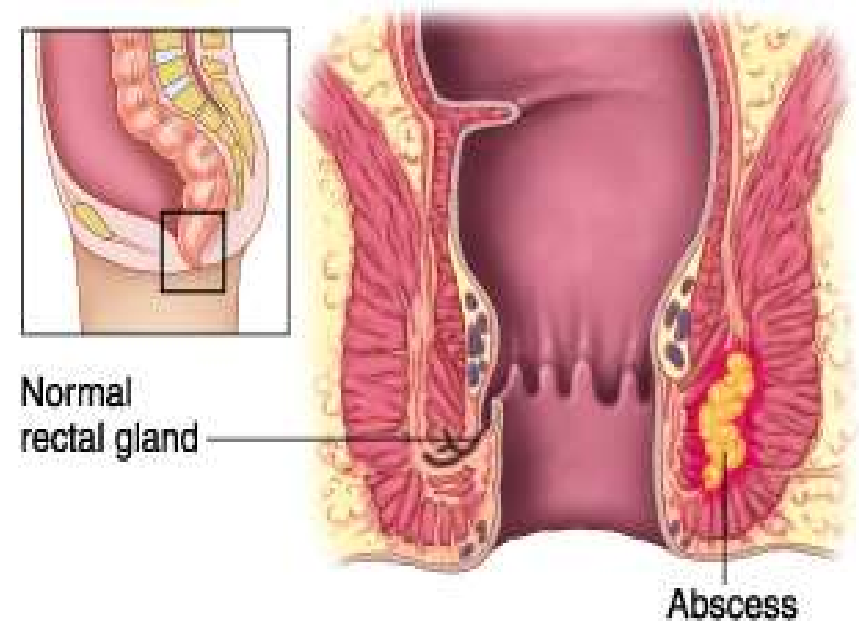
Applied Anatomy:

Infections in the ischiorectal pad of fat is common and lead to abscess formation.

The abscess may rupture medially into the anal canal or downwards into the skin at the fossa. This may leads to anal fistula



Anal Fistula



Dr. Ahmed Salman

Thank
you