


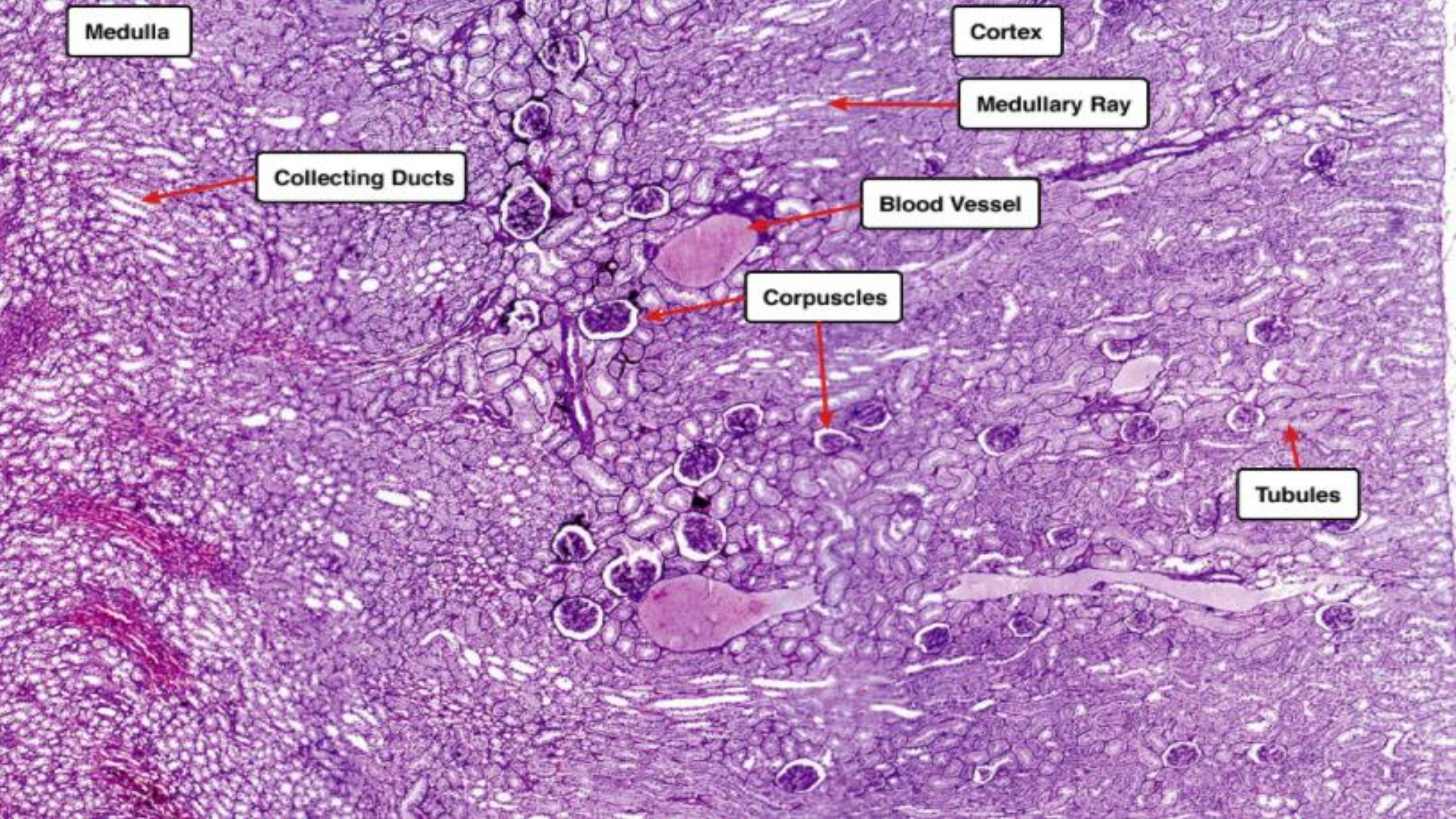


Practical Histology

UGS

Urinary system





Medulla

Cortex

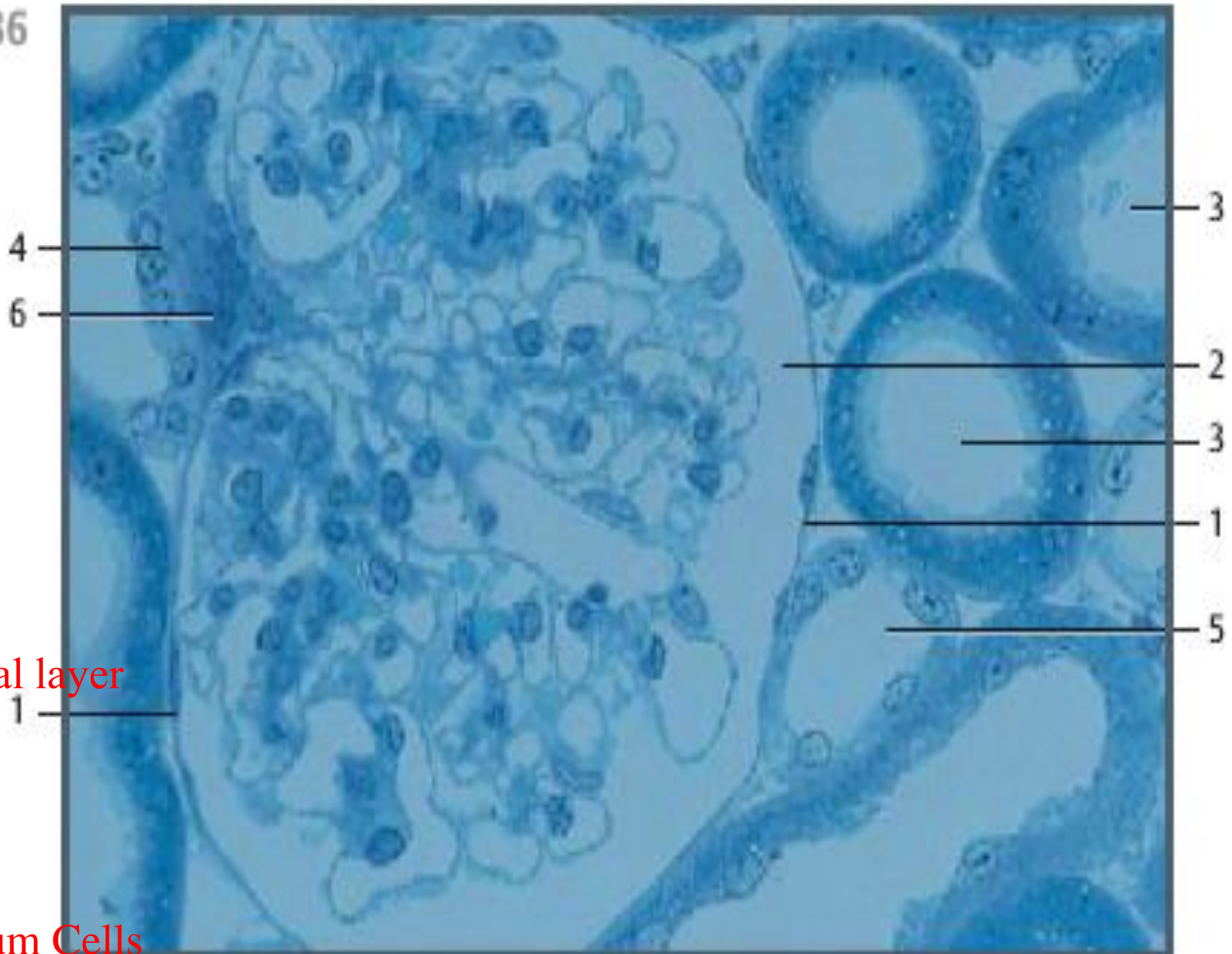
Medullary Ray

Collecting Ducts

Blood Vessel

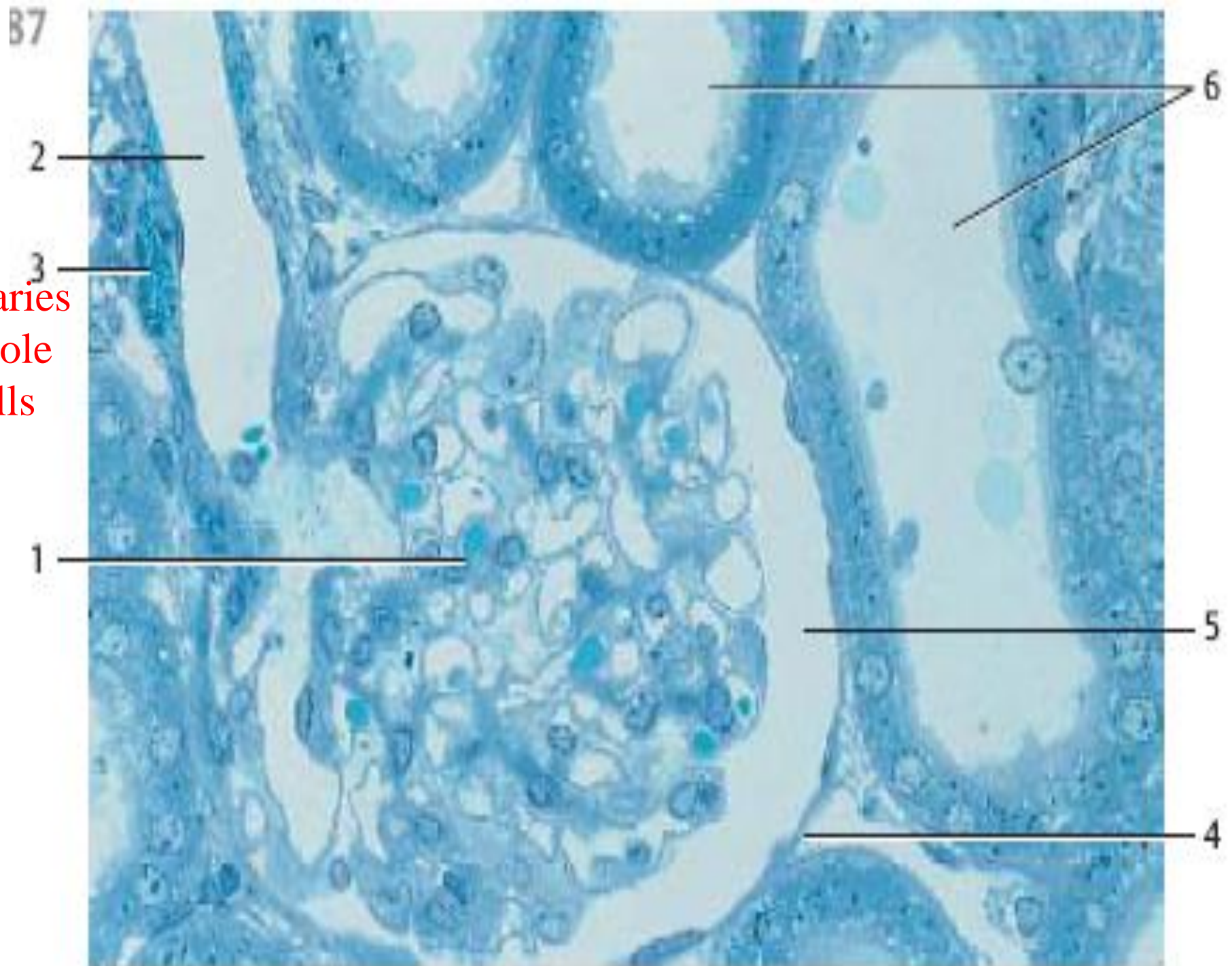
Corpuscles

Tubules

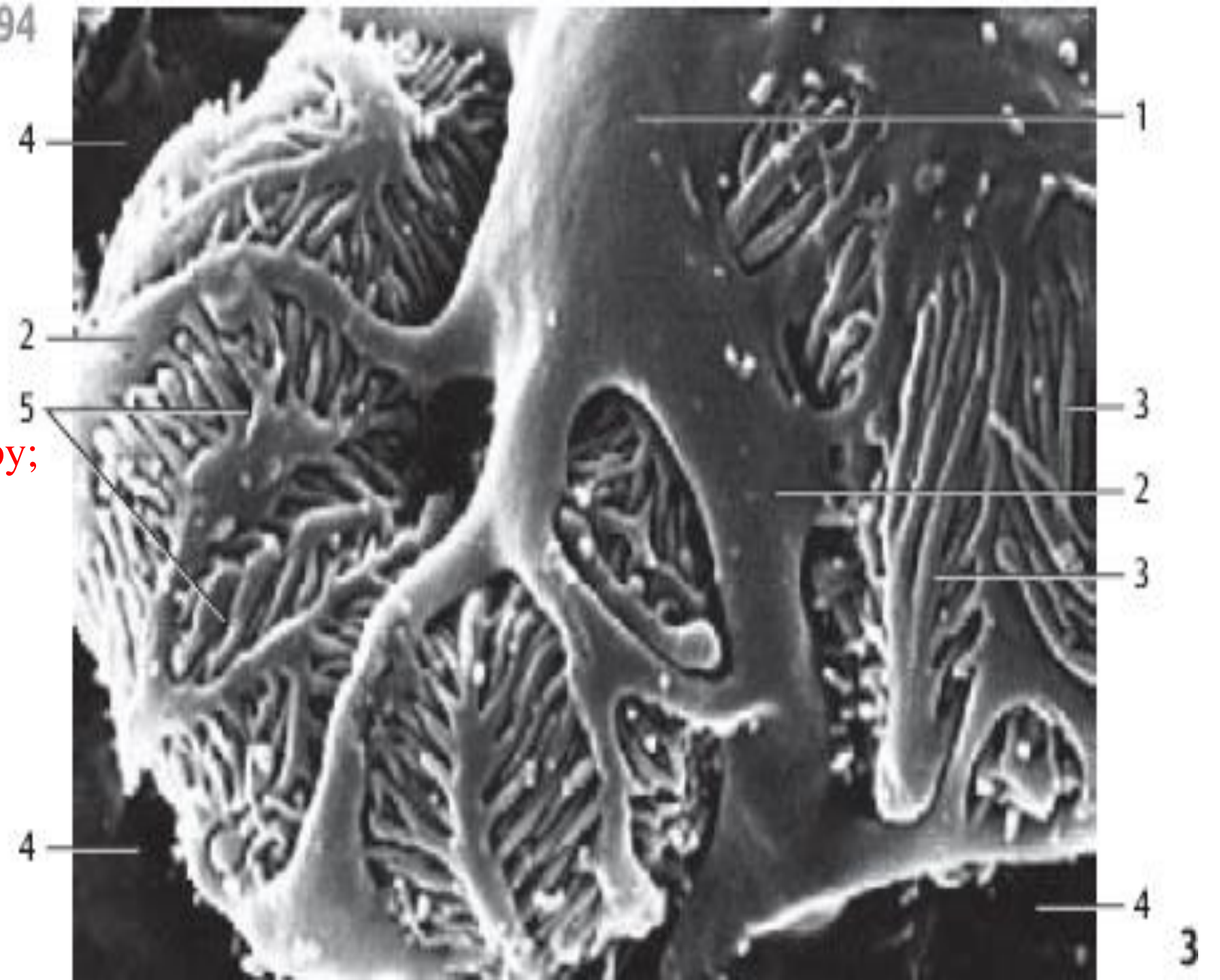


1. Bowman's capsule, parietal layer
2. Bowman's space
3. Proximal tubule
4. Macula densa
5. Distal tubule
6. Extraglomerular mesangium Cells

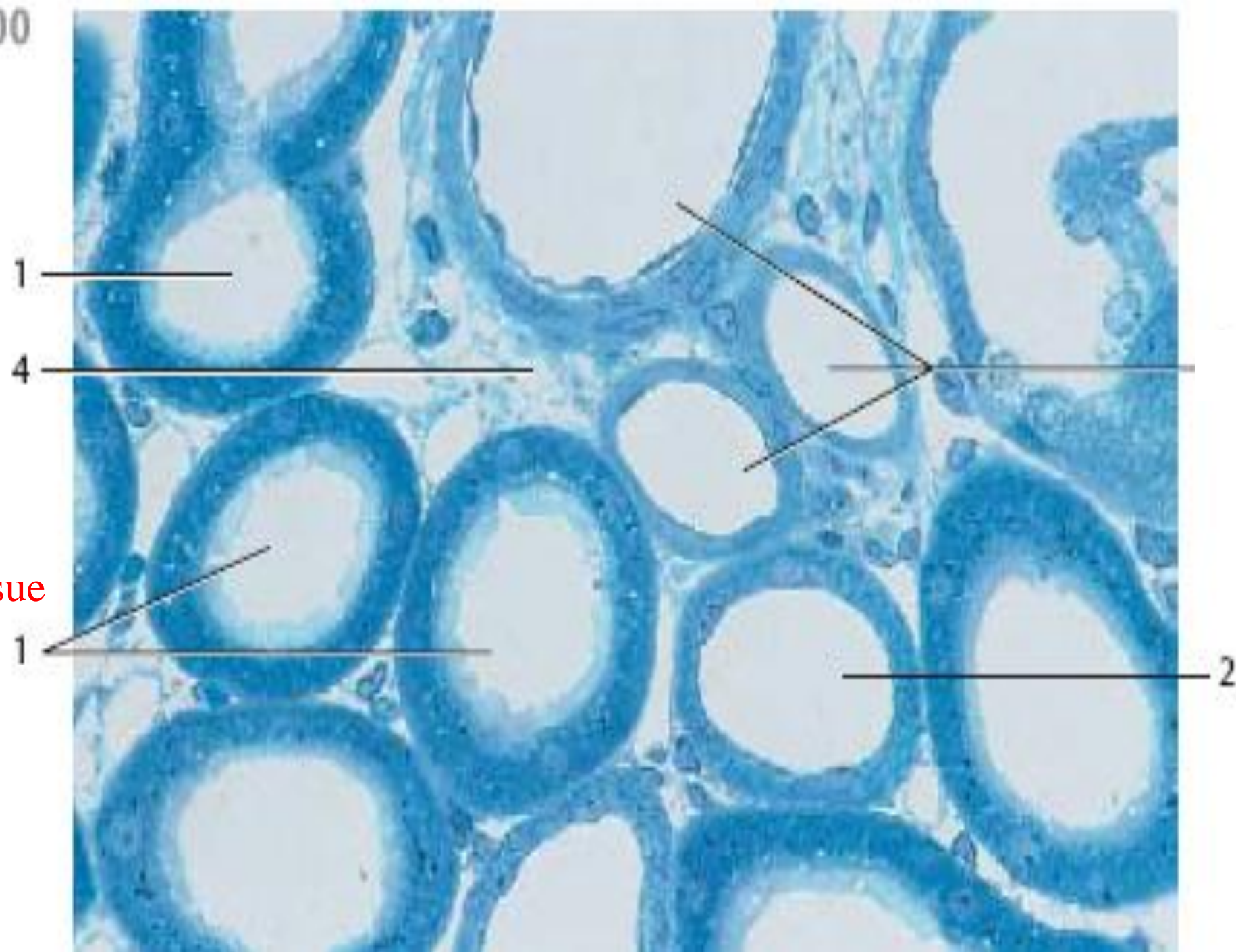
1. Glomerulus, coiled capillaries
- 2 .Afferent glomerular arteriole
- 3 . Juxta-glomerular (JG) cells
- 4 .Bowman's capsule, parietal lamina (lining)
- 5.Bowman's space
- 6.Proximal tubule



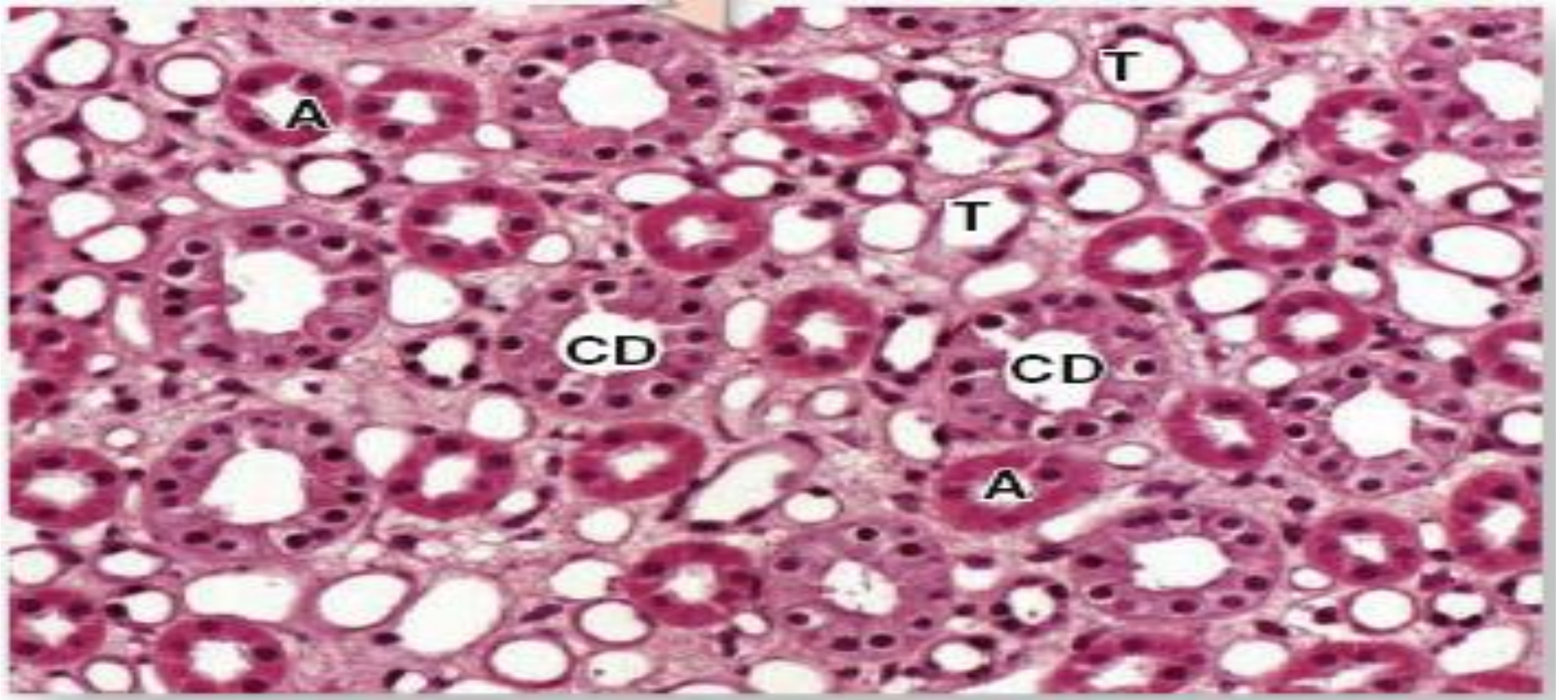
- 1. Podocyte, cell body
 - 2. Primary pedicles
 - 3. Secondary pedicles (foot processes)
 - 4. Bowman's space
 - 5. Filtration slits
- Scanning electron microscopy;
magnification: $\times 7850$



500

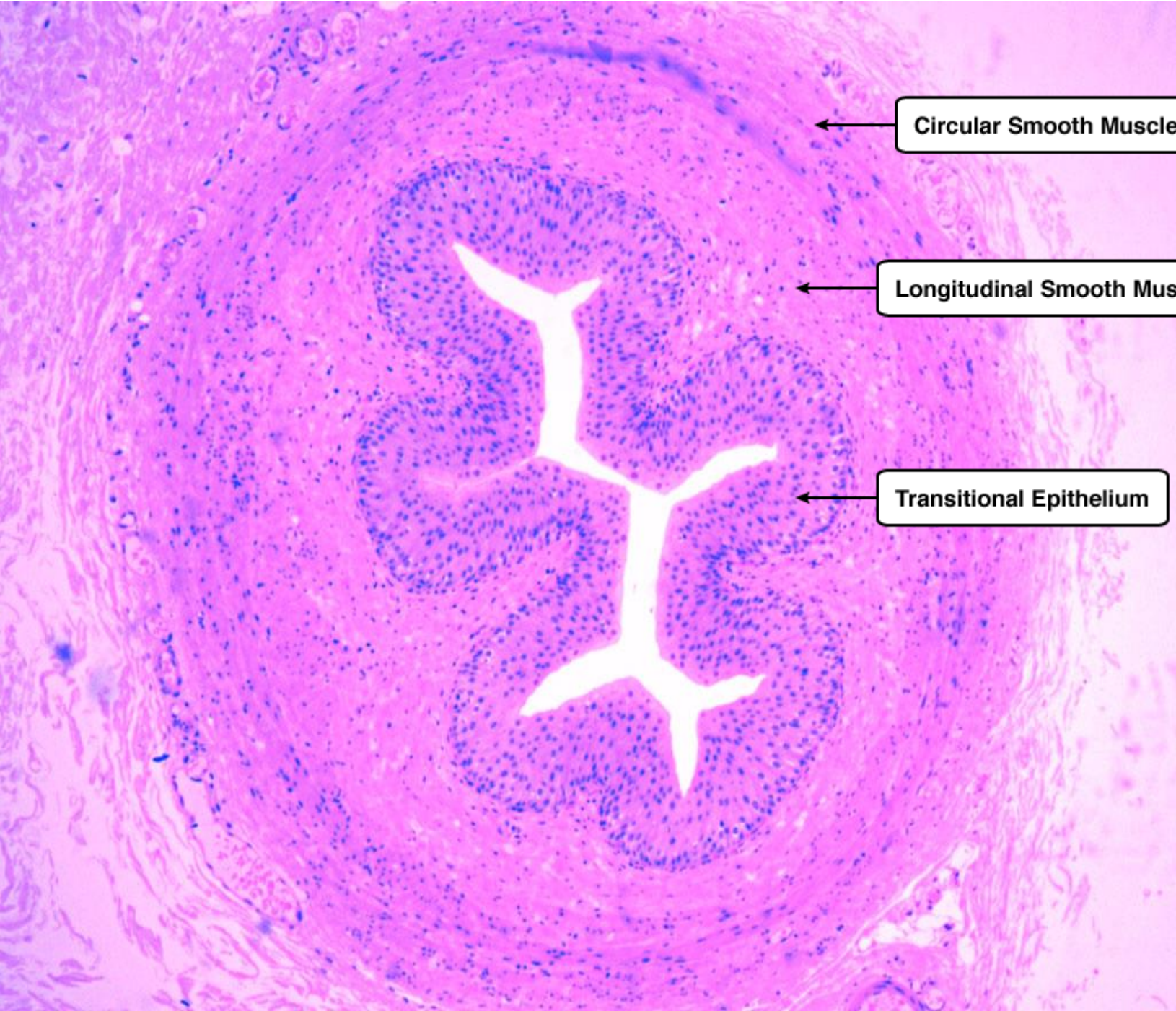


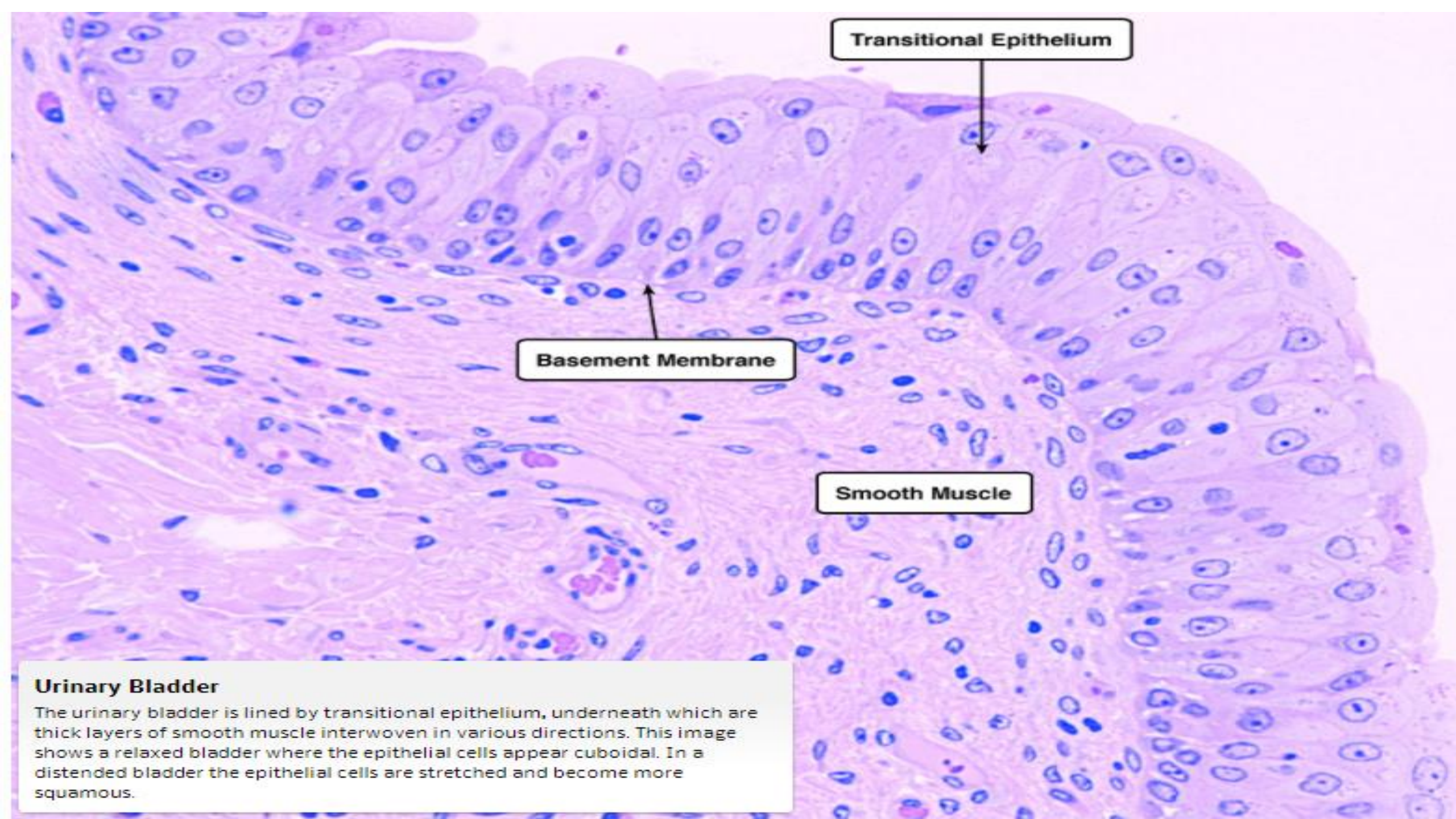
- 1. Proximal tubules
- 2. Distal tubules
- 4. Interstitial connective tissue



A cross section through a medullary renal pyramid shows the simple squamous epithelium of the thin descending and ascending limbs of loops of Henle (**T**) and its thick ascending limbs (**A**), as well as the pale columnar cells of collecting ducts (**CD**).

Ureter



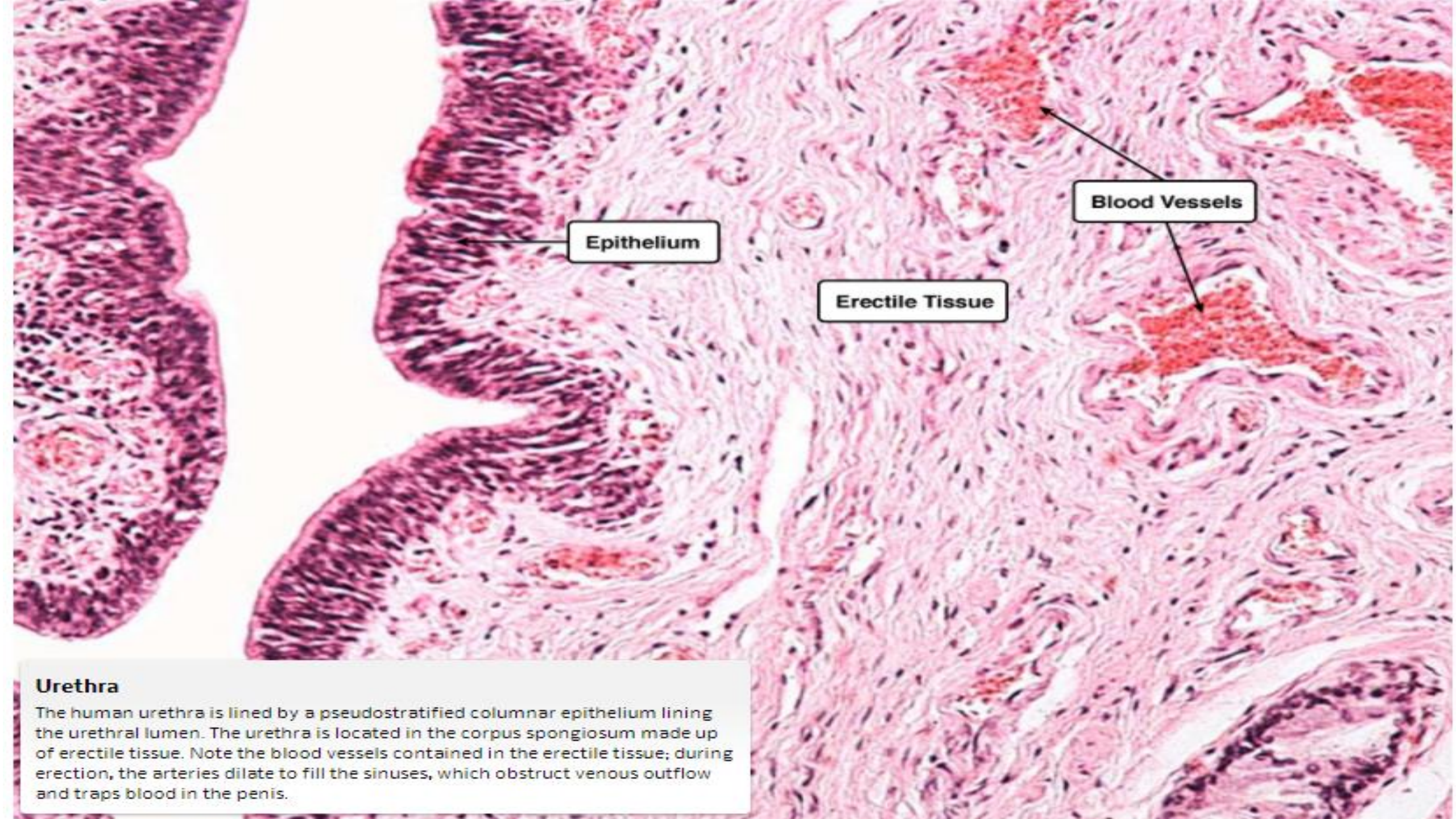


Transitional Epithelium

Basement Membrane

Smooth Muscle

Urinary Bladder
The urinary bladder is lined by transitional epithelium, underneath which are thick layers of smooth muscle interwoven in various directions. This image shows a relaxed bladder where the epithelial cells appear cuboidal. In a distended bladder the epithelial cells are stretched and become more squamous.



Epithelium


Erectile Tissue

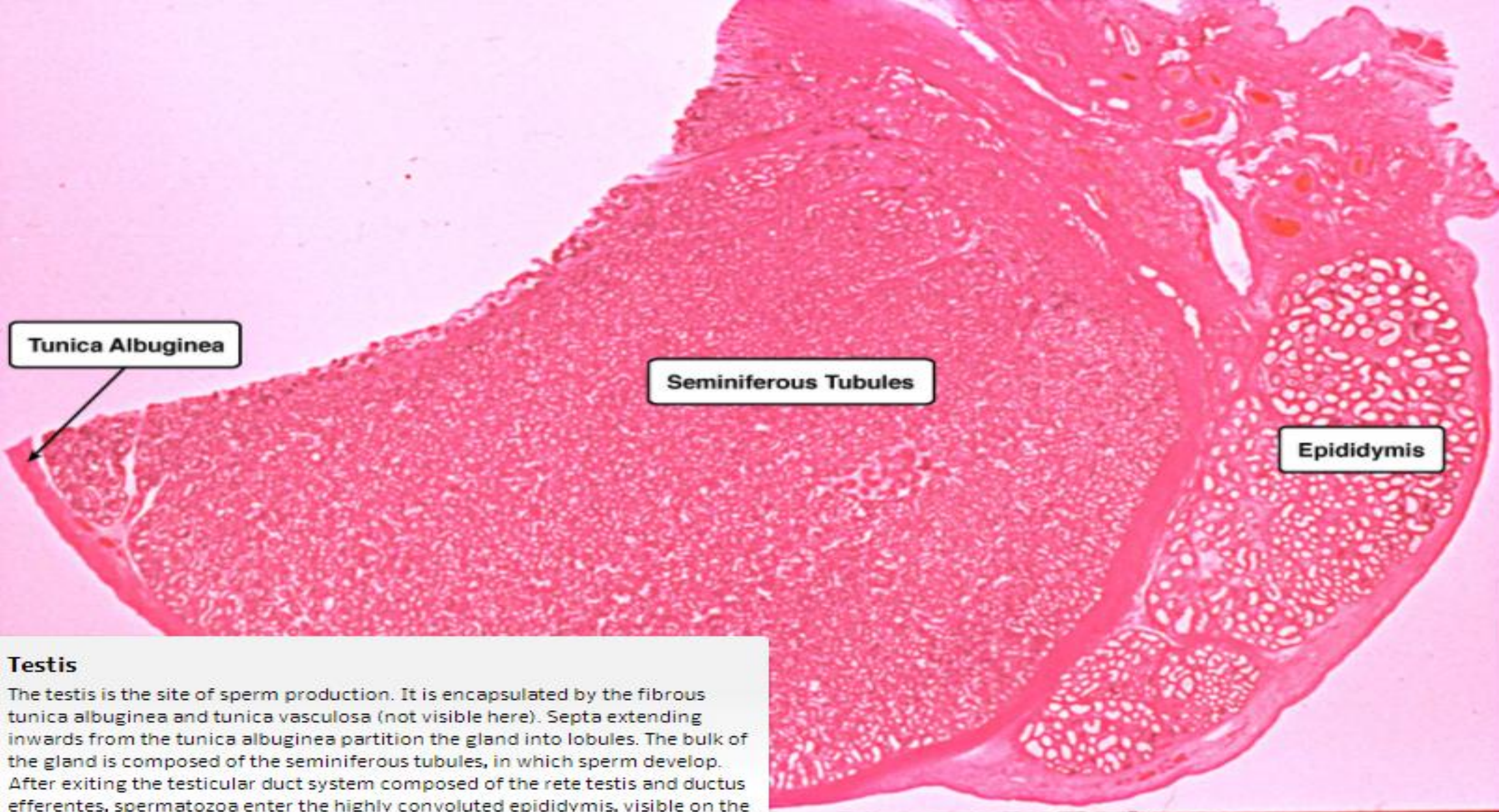
Blood Vessels

Urethra

The human urethra is lined by a pseudostratified columnar epithelium lining the urethral lumen. The urethra is located in the corpus spongiosum made up of erectile tissue. Note the blood vessels contained in the erectile tissue; during erection, the arteries dilate to fill the sinuses, which obstruct venous outflow and traps blood in the penis.

Male reproductive system





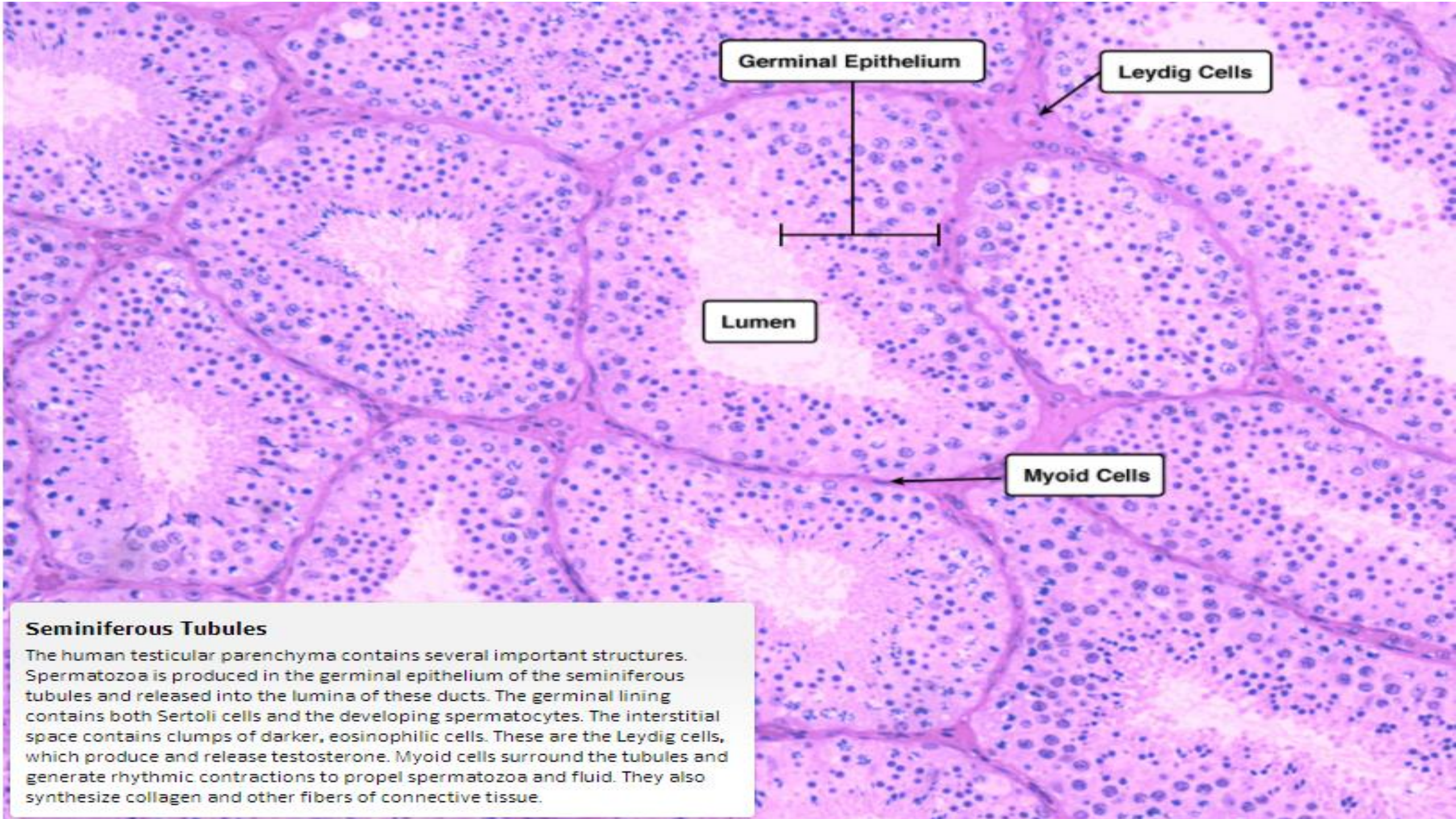
Tunica Albuginea

Seminiferous Tubules

Epididymis

Testis

The testis is the site of sperm production. It is encapsulated by the fibrous tunica albuginea and tunica vasculosa (not visible here). Septa extending inwards from the tunica albuginea partition the gland into lobules. The bulk of the gland is composed of the seminiferous tubules, in which sperm develop. After exiting the testicular duct system composed of the rete testis and ductus efferentes, spermatozoa enter the highly convoluted epididymis, visible on the dorsal aspect of the testis here.



Germinal Epithelium

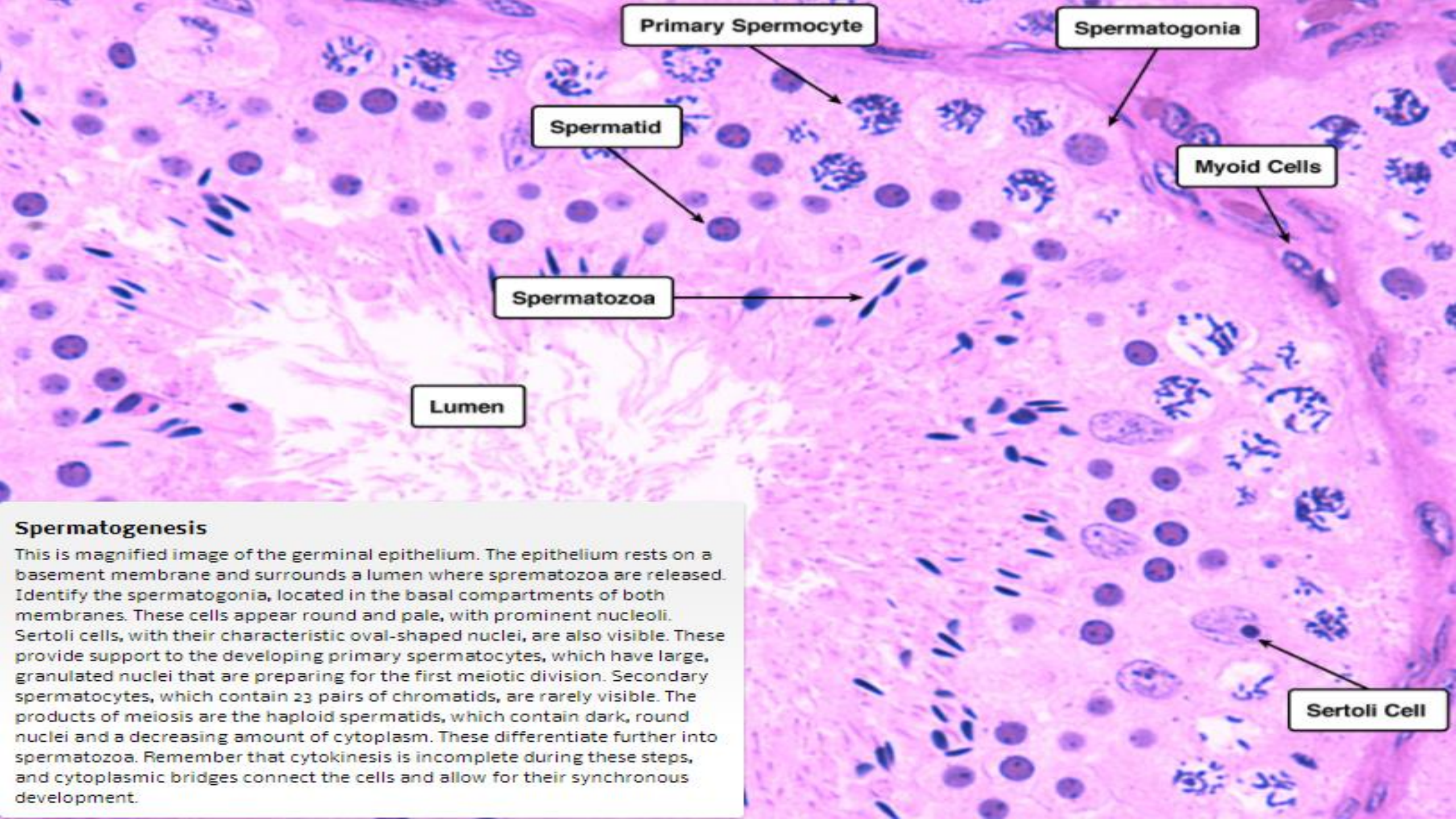
Leydig Cells

Lumen

Myoid Cells

Seminiferous Tubules

The human testicular parenchyma contains several important structures. Spermatozoa is produced in the germinal epithelium of the seminiferous tubules and released into the lumina of these ducts. The germinal lining contains both Sertoli cells and the developing spermatocytes. The interstitial space contains clumps of darker, eosinophilic cells. These are the Leydig cells, which produce and release testosterone. Myoid cells surround the tubules and generate rhythmic contractions to propel spermatozoa and fluid. They also synthesize collagen and other fibers of connective tissue.



Primary Spermocyte

Spermatogonia

Spermatid

Myoid Cells

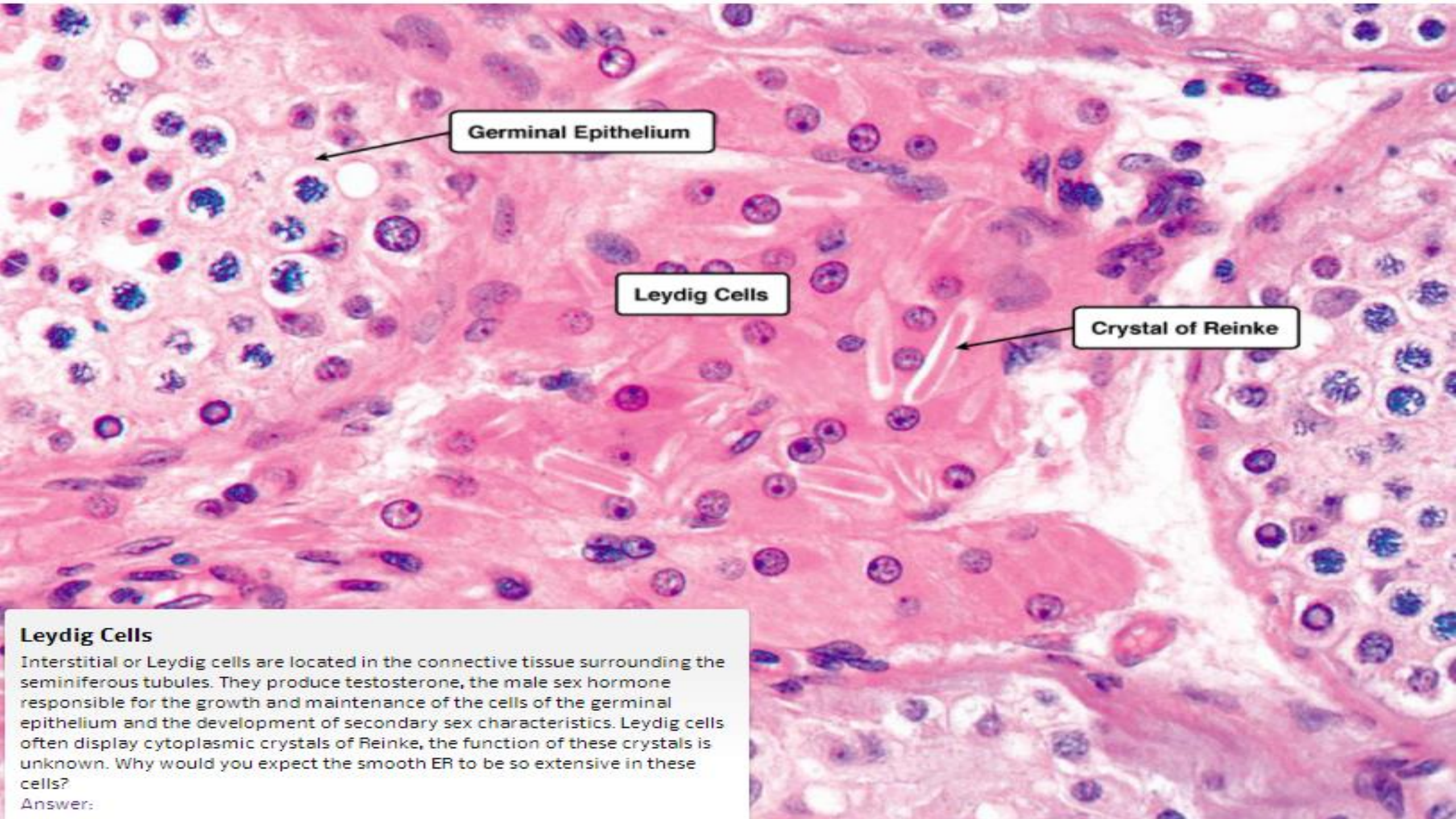
Spermatozoa

Lumen

Sertoli Cell

Spermatogenesis

This is magnified image of the germinal epithelium. The epithelium rests on a basement membrane and surrounds a lumen where spermatozoa are released. Identify the spermatogonia, located in the basal compartments of both membranes. These cells appear round and pale, with prominent nucleoli. Sertoli cells, with their characteristic oval-shaped nuclei, are also visible. These provide support to the developing primary spermatocytes, which have large, granulated nuclei that are preparing for the first meiotic division. Secondary spermatocytes, which contain 23 pairs of chromatids, are rarely visible. The products of meiosis are the haploid spermatids, which contain dark, round nuclei and a decreasing amount of cytoplasm. These differentiate further into spermatozoa. Remember that cytokinesis is incomplete during these steps, and cytoplasmic bridges connect the cells and allow for their synchronous development.



Germinal Epithelium

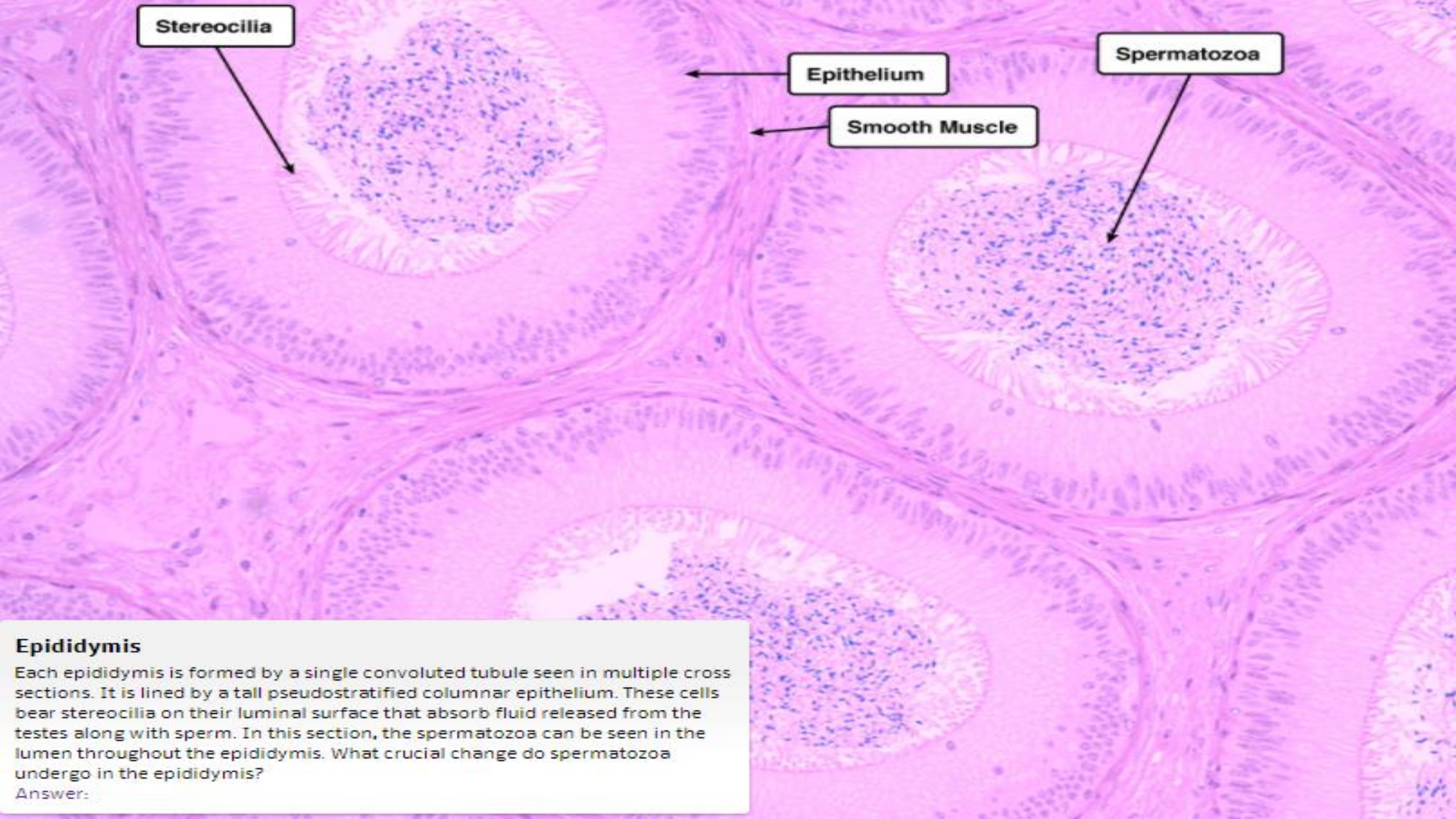
Leydig Cells

Crystal of Reinke

Leydig Cells

Interstitial or Leydig cells are located in the connective tissue surrounding the seminiferous tubules. They produce testosterone, the male sex hormone responsible for the growth and maintenance of the cells of the germinal epithelium and the development of secondary sex characteristics. Leydig cells often display cytoplasmic crystals of Reinke, the function of these crystals is unknown. Why would you expect the smooth ER to be so extensive in these cells?

Answer:



Stereocilia

Epithelium

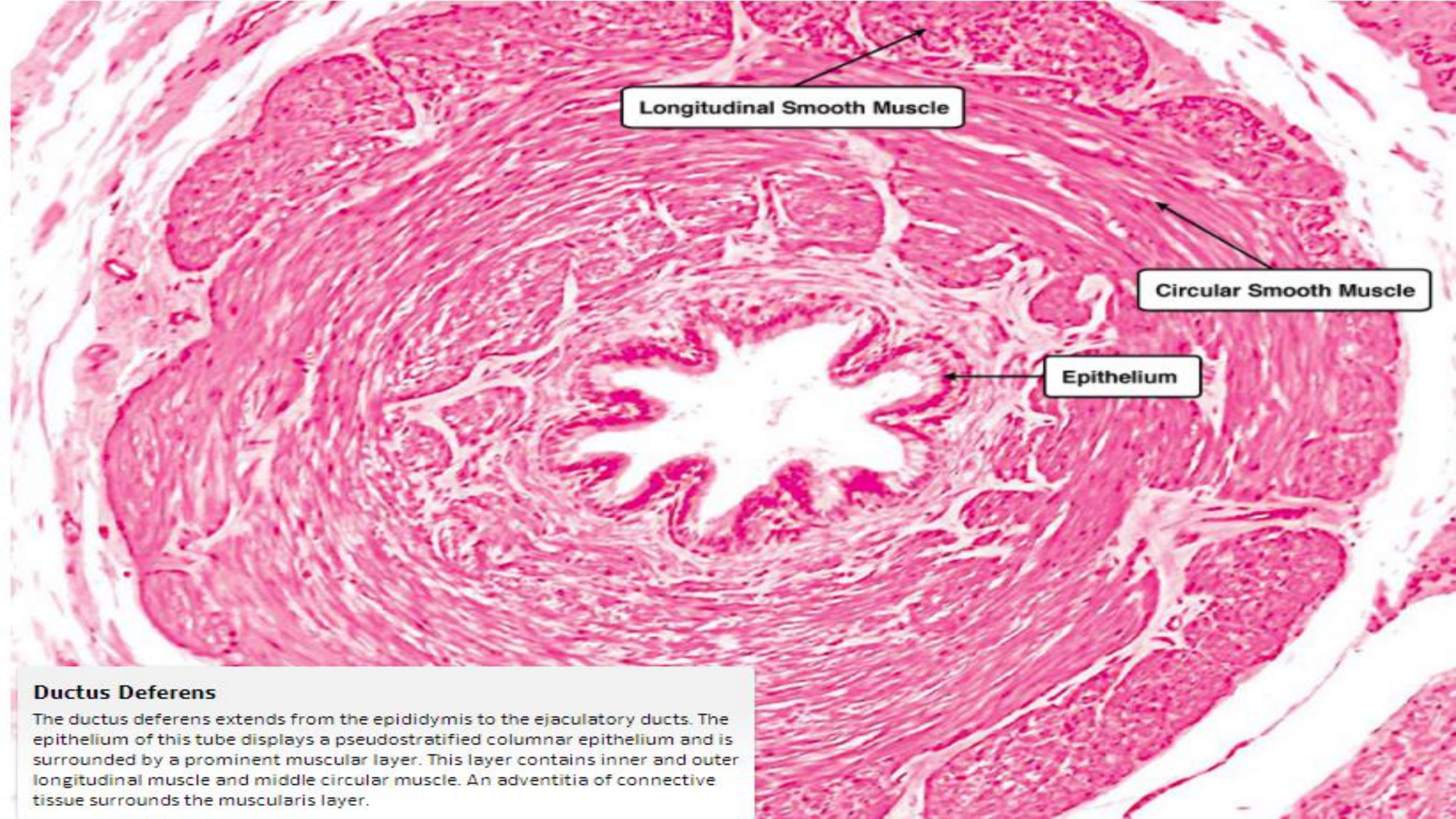Spermatozoa

Smooth Muscle

Epididymis

Each epididymis is formed by a single convoluted tubule seen in multiple cross sections. It is lined by a tall pseudostratified columnar epithelium. These cells bear stereocilia on their luminal surface that absorb fluid released from the testes along with sperm. In this section, the spermatozoa can be seen in the lumen throughout the epididymis. What crucial change do spermatozoa undergo in the epididymis?

Answer:



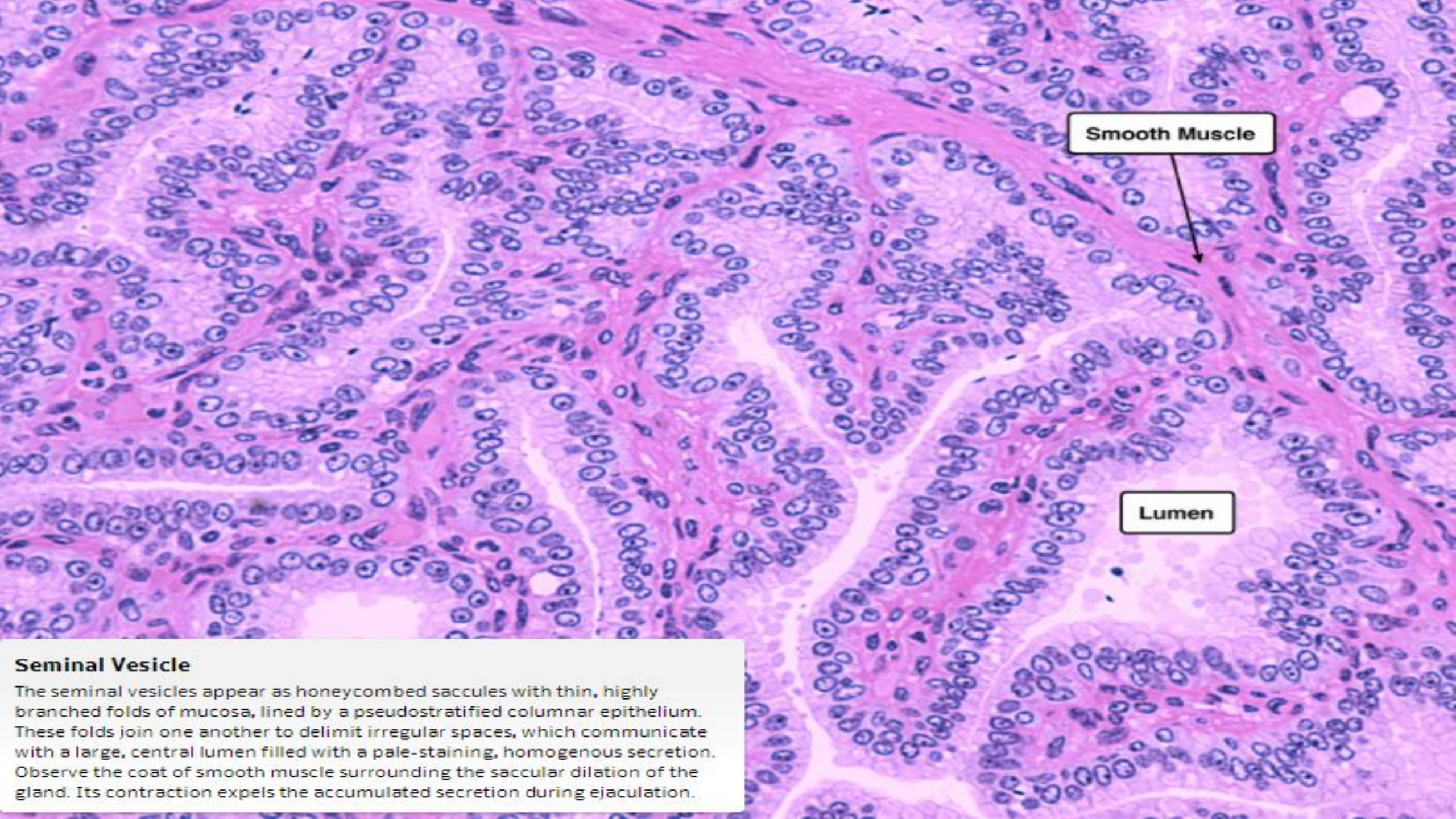
Longitudinal Smooth Muscle

Circular Smooth Muscle

Epithelium

Ductus Deferens

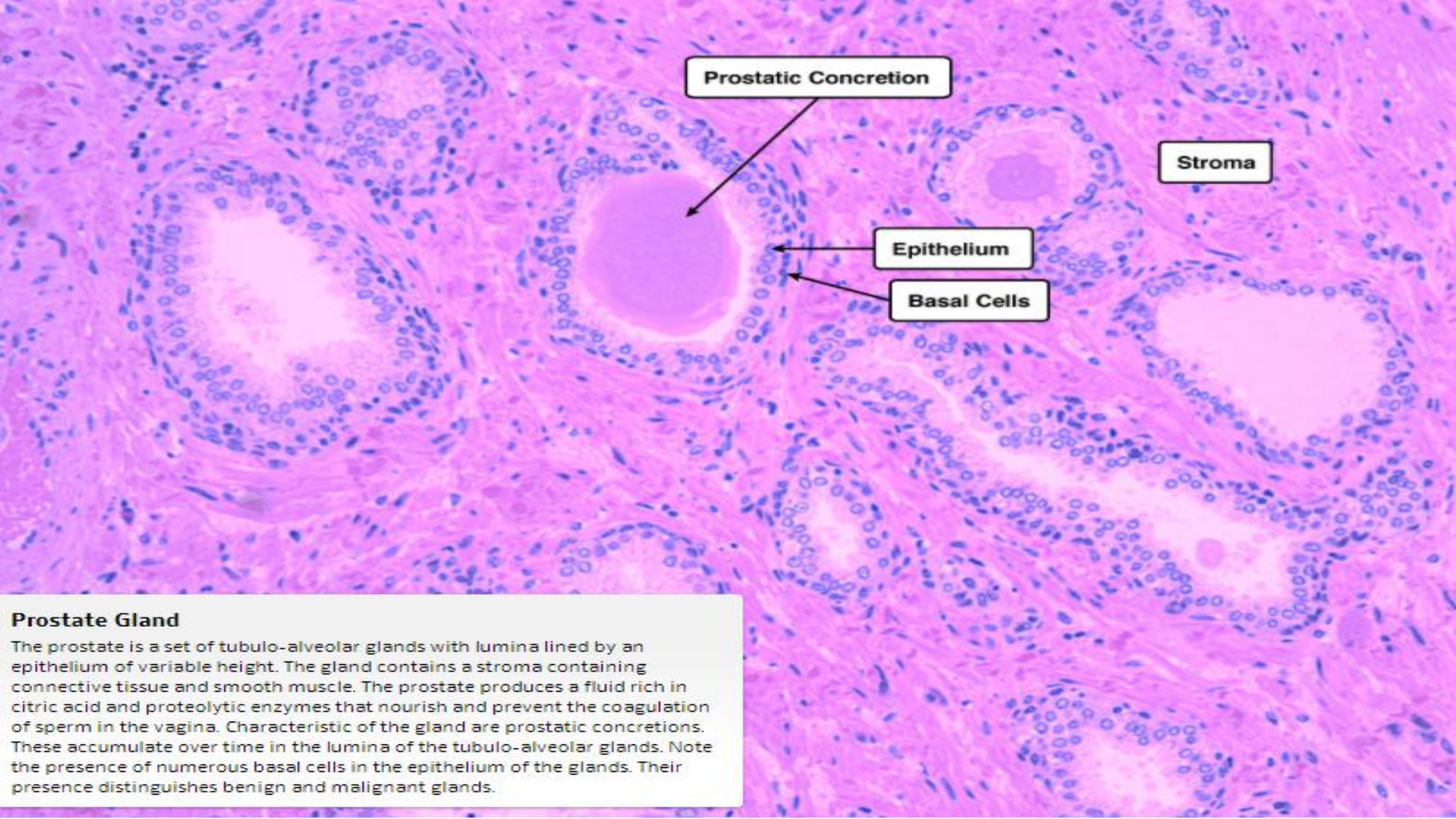
The ductus deferens extends from the epididymis to the ejaculatory ducts. The epithelium of this tube displays a pseudostratified columnar epithelium and is surrounded by a prominent muscular layer. This layer contains inner and outer longitudinal muscle and middle circular muscle. An adventitia of connective tissue surrounds the muscularis layer.



Smooth Muscle

Lumen

Seminal Vesicle
The seminal vesicles appear as honeycombed saccules with thin, highly branched folds of mucosa, lined by a pseudostratified columnar epithelium. These folds join one another to delimit irregular spaces, which communicate with a large, central lumen filled with a pale-staining, homogenous secretion. Observe the coat of smooth muscle surrounding the saccular dilation of the gland. Its contraction expels the accumulated secretion during ejaculation.



Prostatic Concretion

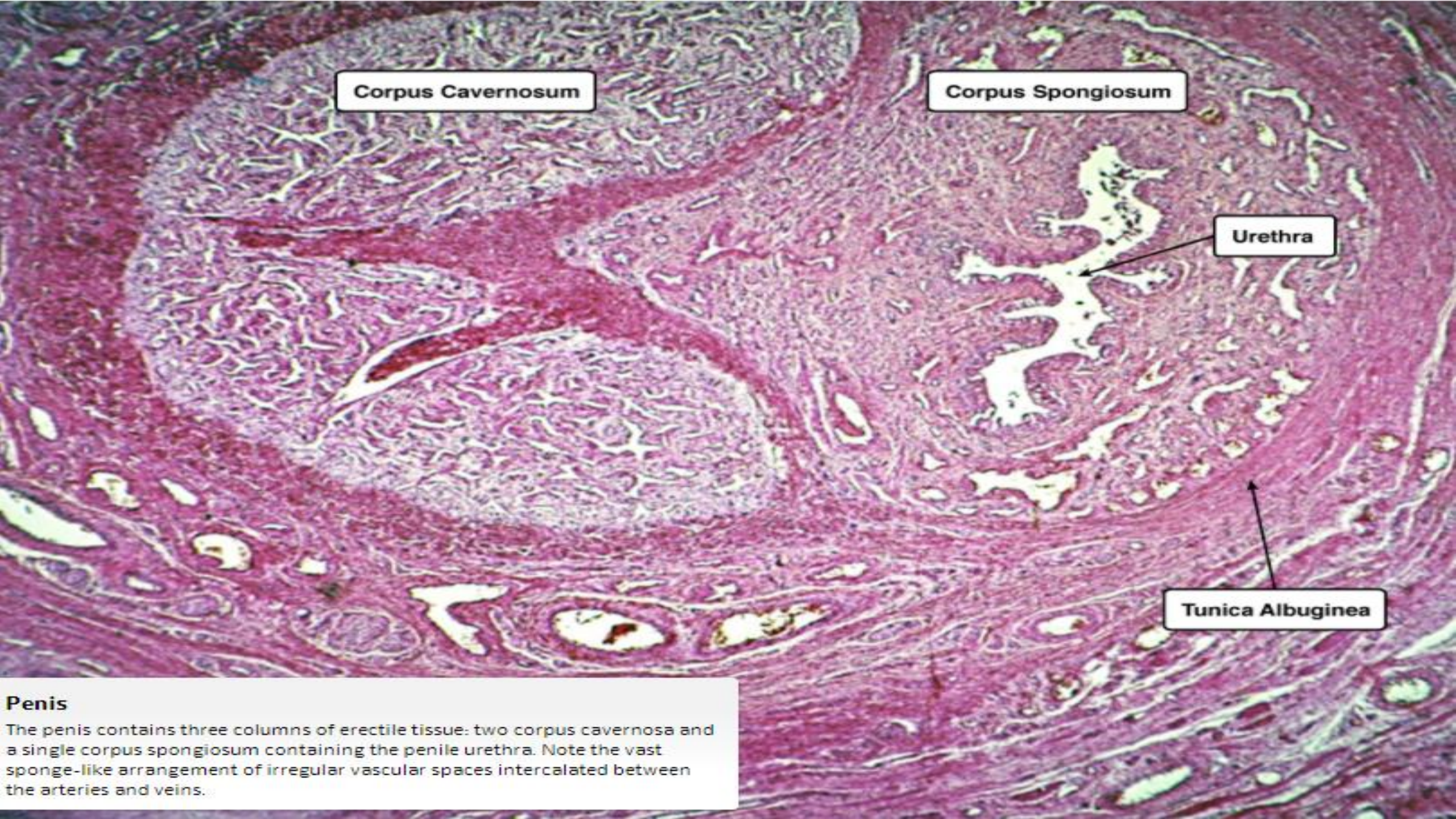
Stroma

Epithelium

Basal Cells

Prostate Gland

The prostate is a set of tubulo-alveolar glands with lumina lined by an epithelium of variable height. The gland contains a stroma containing connective tissue and smooth muscle. The prostate produces a fluid rich in citric acid and proteolytic enzymes that nourish and prevent the coagulation of sperm in the vagina. Characteristic of the gland are prostatic concretions. These accumulate over time in the lumina of the tubulo-alveolar glands. Note the presence of numerous basal cells in the epithelium of the glands. Their presence distinguishes benign and malignant glands.



Corpus Cavernosum


Corpus Spongiosum

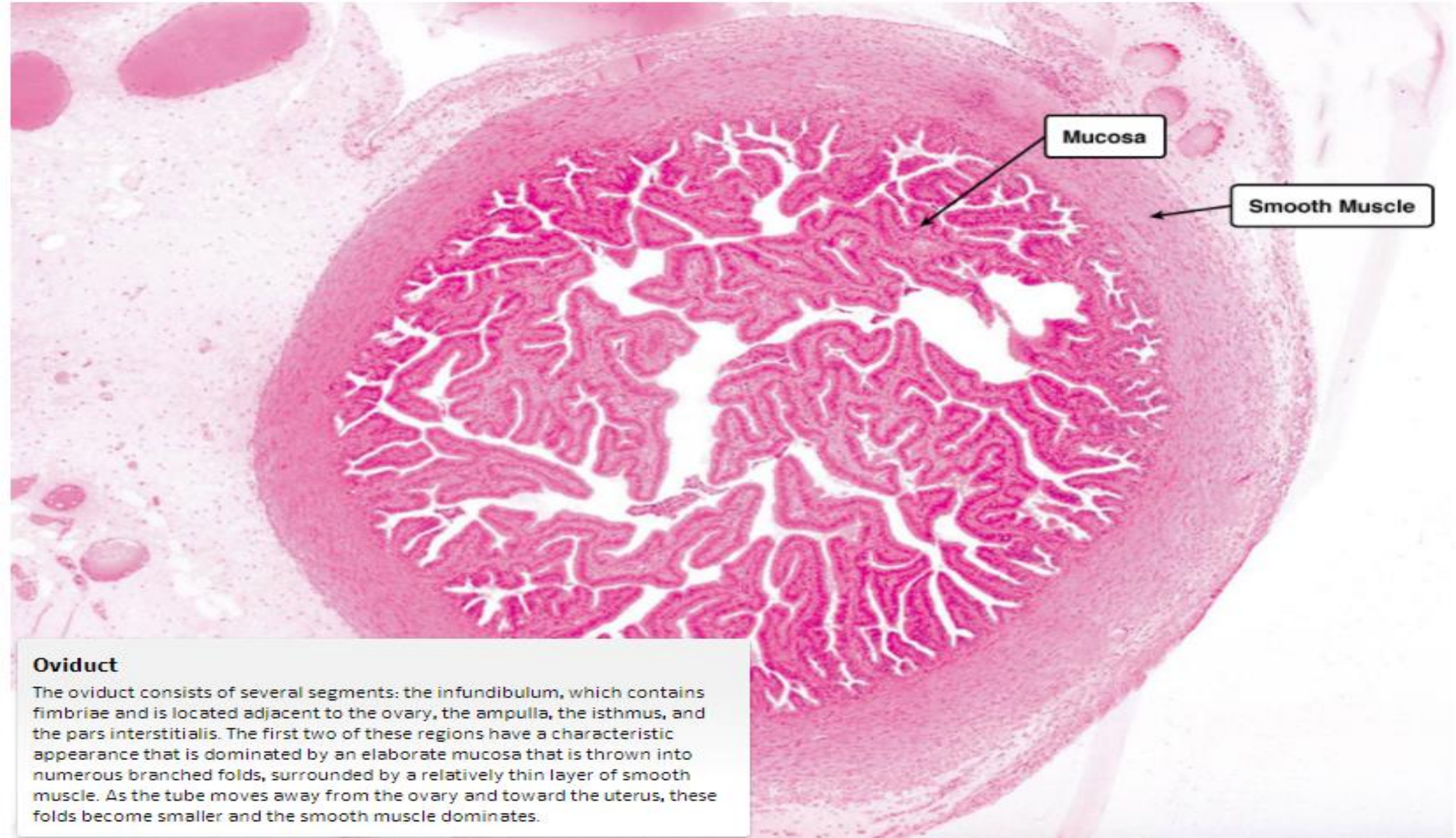
Urethra

Tunica Albuginea

Penis
The penis contains three columns of erectile tissue: two corpus cavernosa and a single corpus spongiosum containing the penile urethra. Note the vast sponge-like arrangement of irregular vascular spaces intercalated between the arteries and veins.

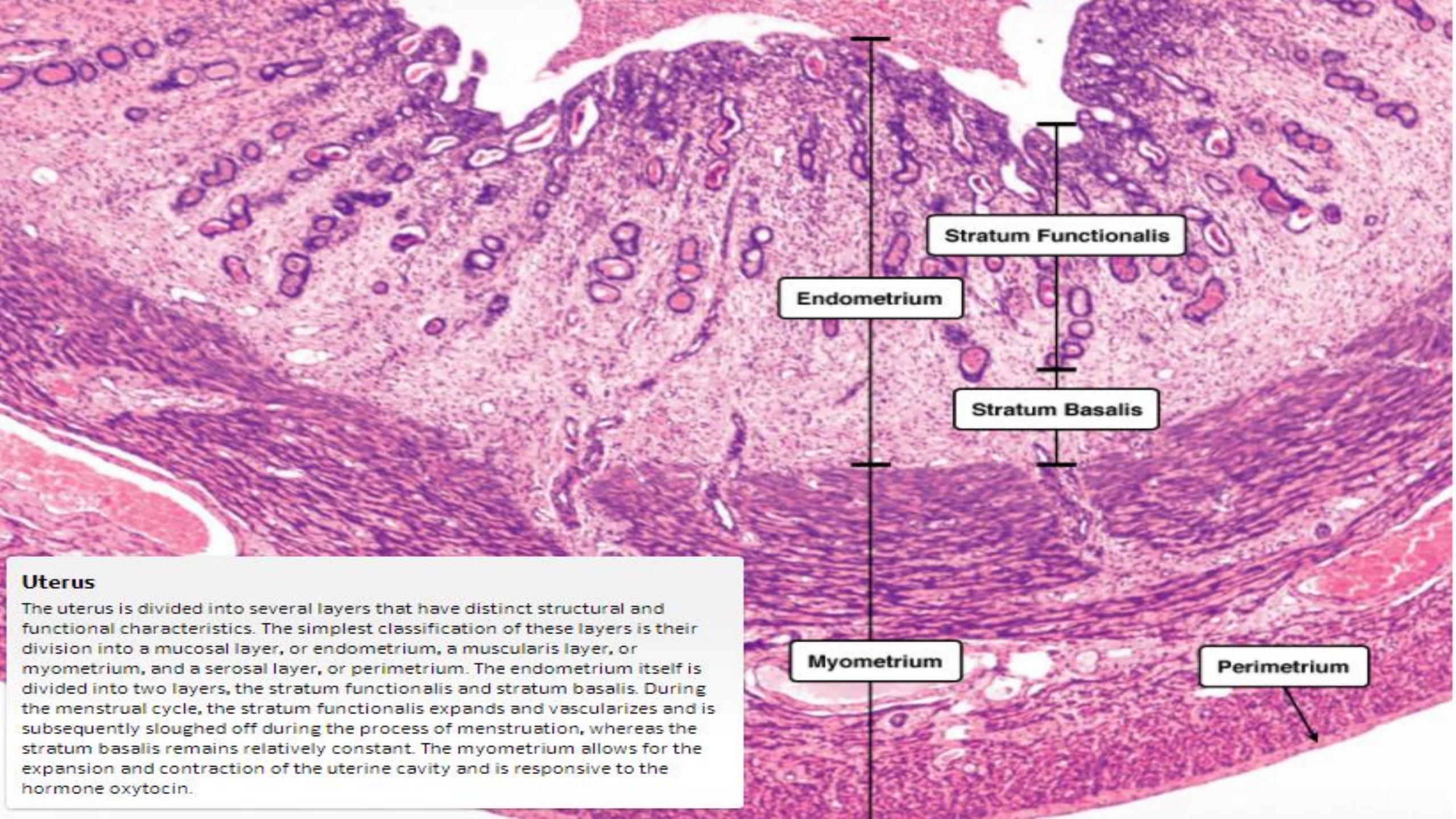
Female reproductive system





Oviduct

The oviduct consists of several segments: the infundibulum, which contains fimbriæ and is located adjacent to the ovary, the ampulla, the isthmus, and the pars interstitialis. The first two of these regions have a characteristic appearance that is dominated by an elaborate mucosa that is thrown into numerous branched folds, surrounded by a relatively thin layer of smooth muscle. As the tube moves away from the ovary and toward the uterus, these folds become smaller and the smooth muscle dominates.



Stratum Functionalis

Endometrium

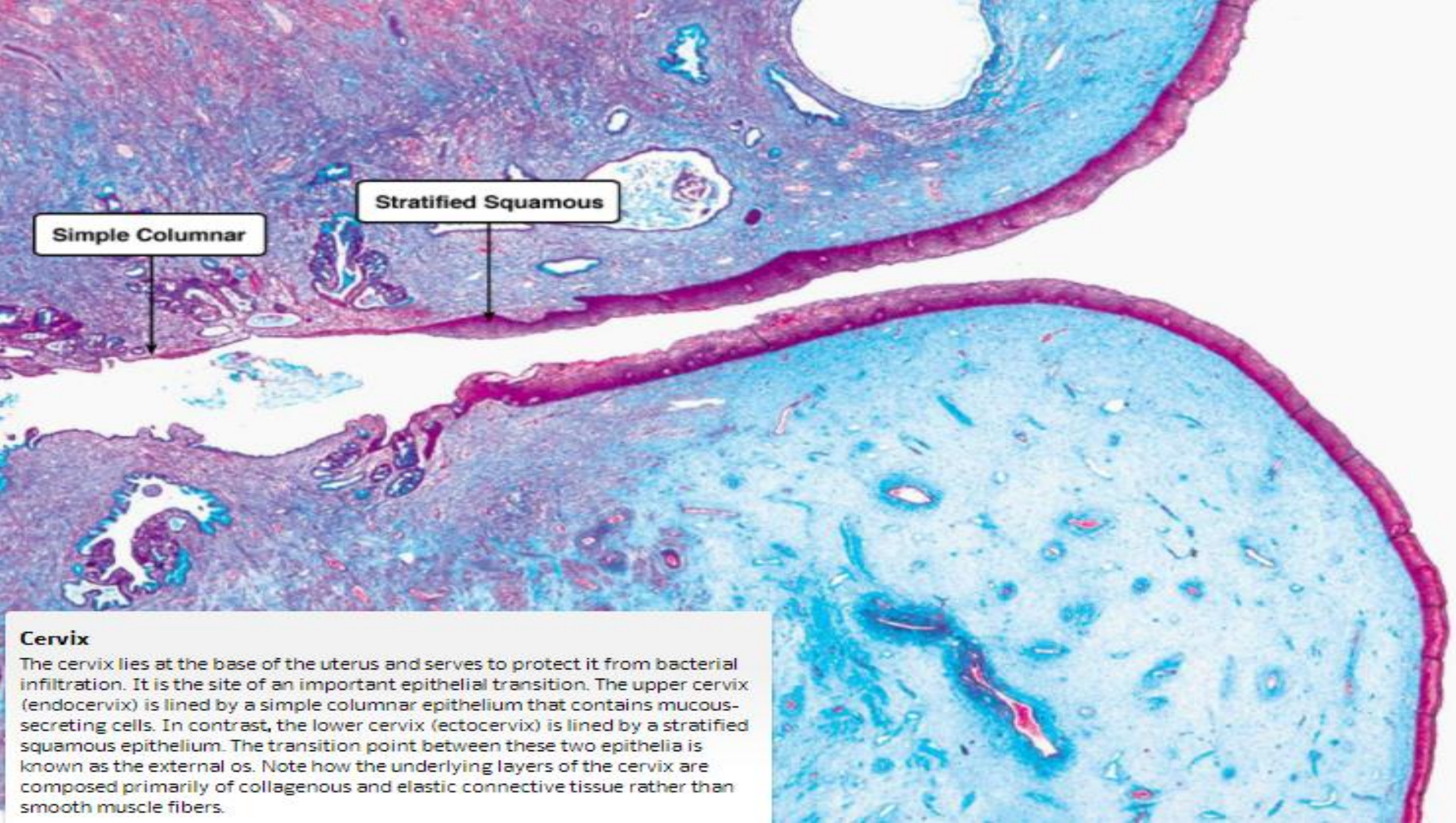
Stratum Basalis

Myometrium

Perimetrium

Uterus

The uterus is divided into several layers that have distinct structural and functional characteristics. The simplest classification of these layers is their division into a mucosal layer, or endometrium, a muscular layer, or myometrium, and a serosal layer, or perimetrium. The endometrium itself is divided into two layers, the stratum functionalis and stratum basalis. During the menstrual cycle, the stratum functionalis expands and vascularizes and is subsequently sloughed off during the process of menstruation, whereas the stratum basalis remains relatively constant. The myometrium allows for the expansion and contraction of the uterine cavity and is responsive to the hormone oxytocin.

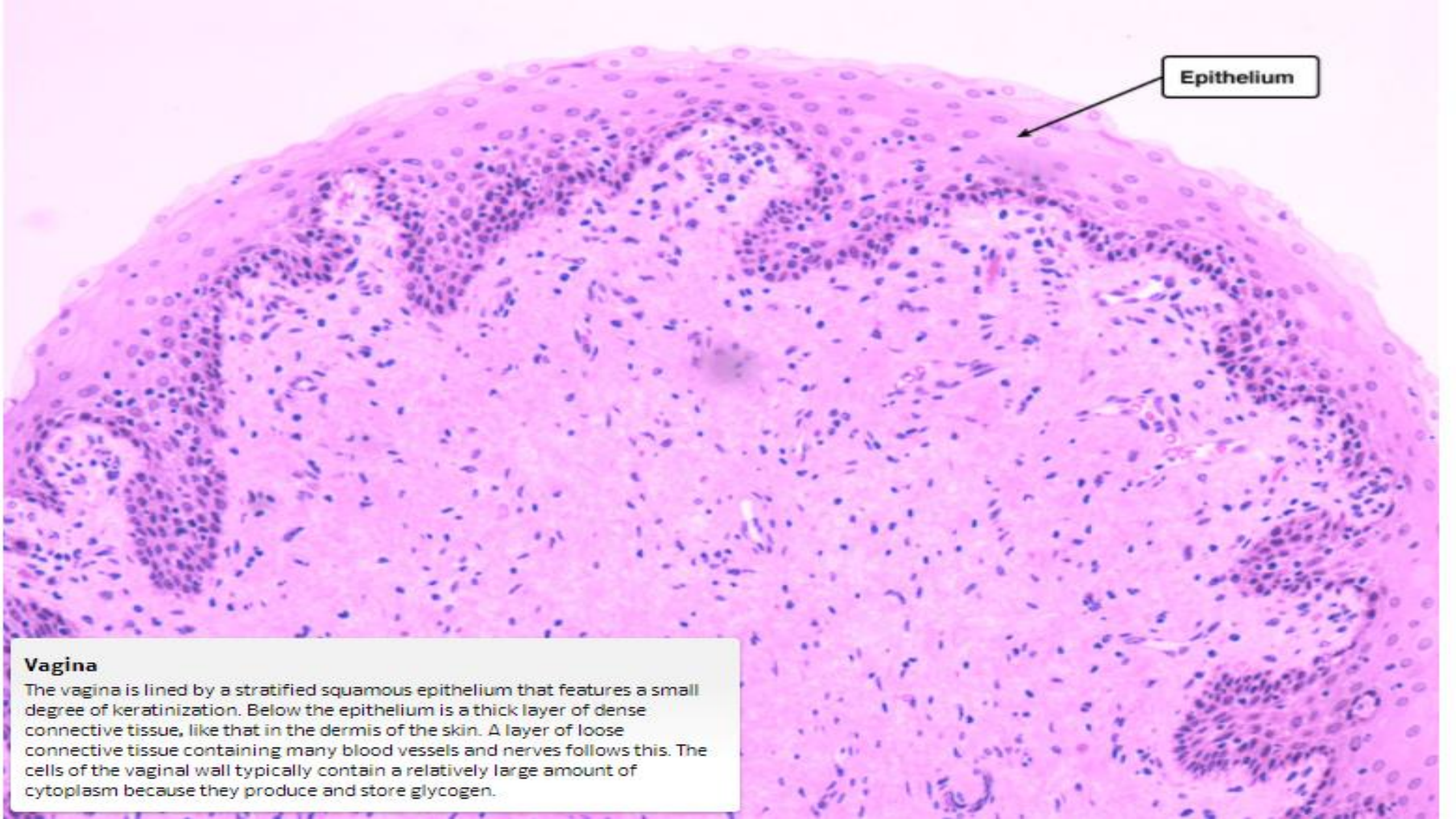


Simple Columnar

Stratified Squamous

Cervix

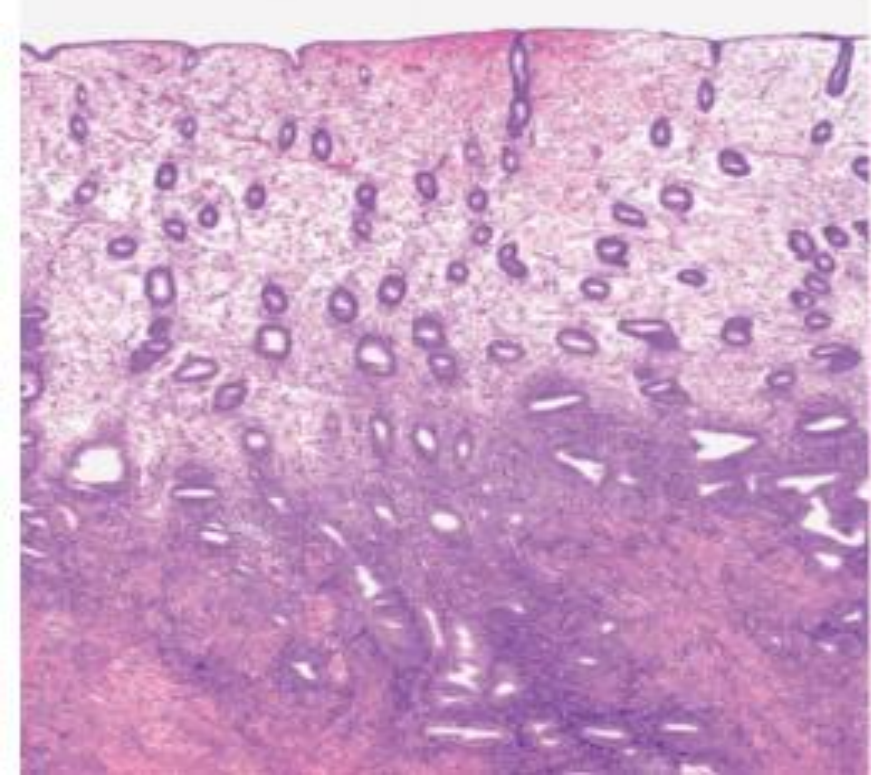
The cervix lies at the base of the uterus and serves to protect it from bacterial infiltration. It is the site of an important epithelial transition. The upper cervix (endocervix) is lined by a simple columnar epithelium that contains mucous-secreting cells. In contrast, the lower cervix (ectocervix) is lined by a stratified squamous epithelium. The transition point between these two epithelia is known as the external os. Note how the underlying layers of the cervix are composed primarily of collagenous and elastic connective tissue rather than smooth muscle fibers.



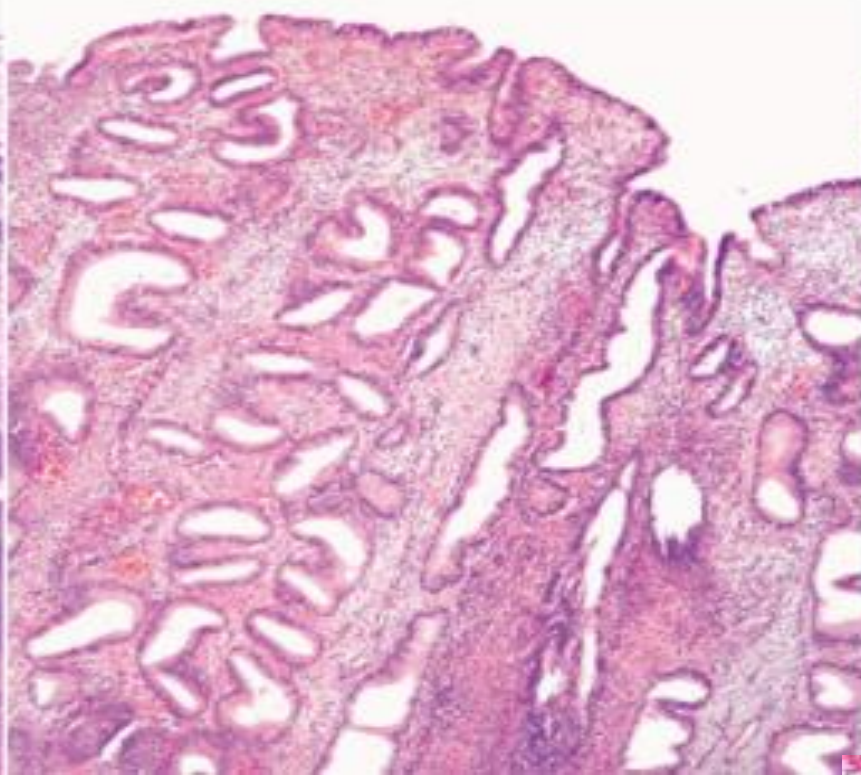
Epithelium

Vagina

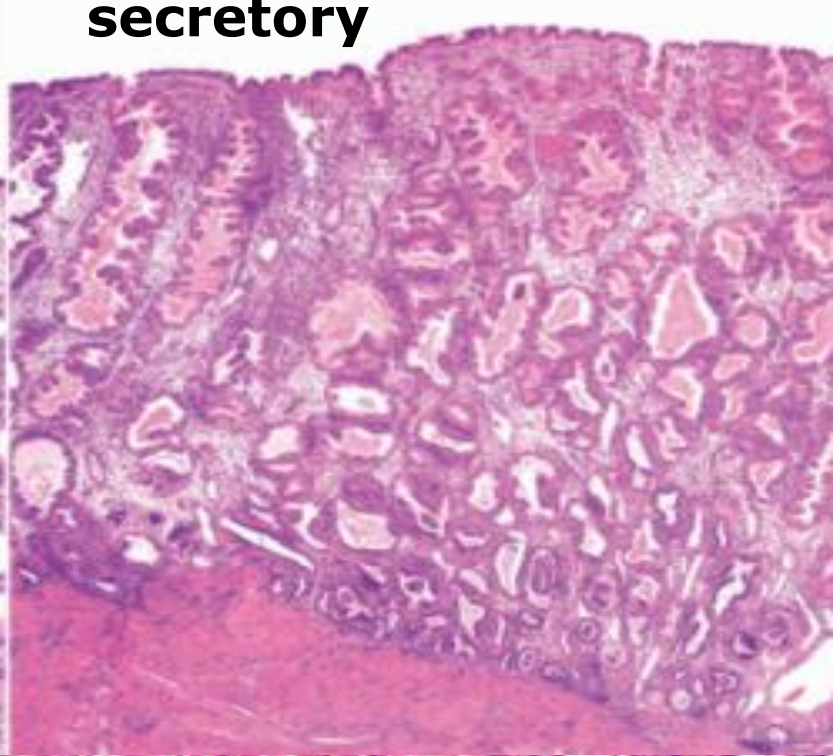
The vagina is lined by a stratified squamous epithelium that features a small degree of keratinization. Below the epithelium is a thick layer of dense connective tissue, like that in the dermis of the skin. A layer of loose connective tissue containing many blood vessels and nerves follows this. The cells of the vaginal wall typically contain a relatively large amount of cytoplasm because they produce and store glycogen.



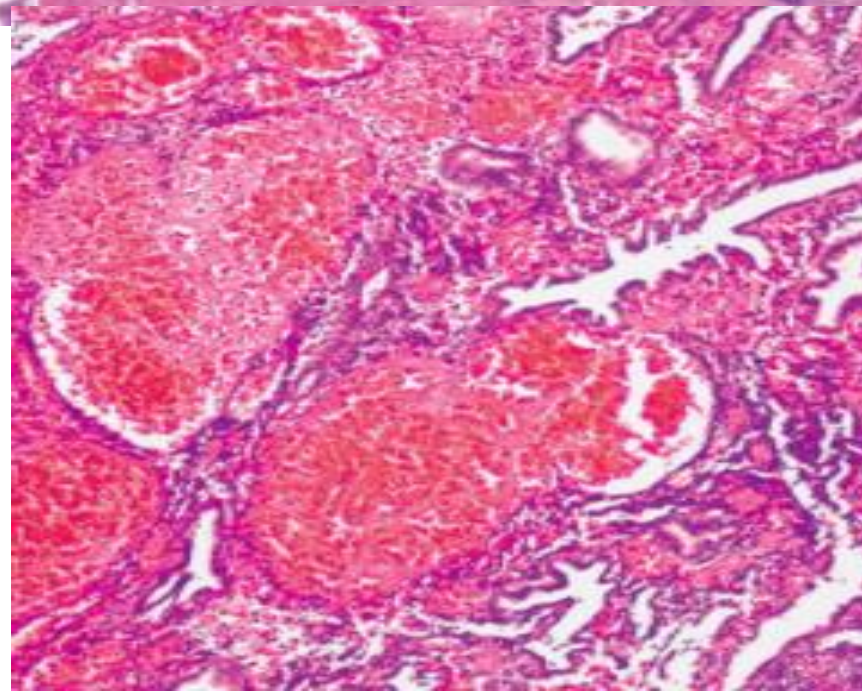
Early proliferative



Late proliferative

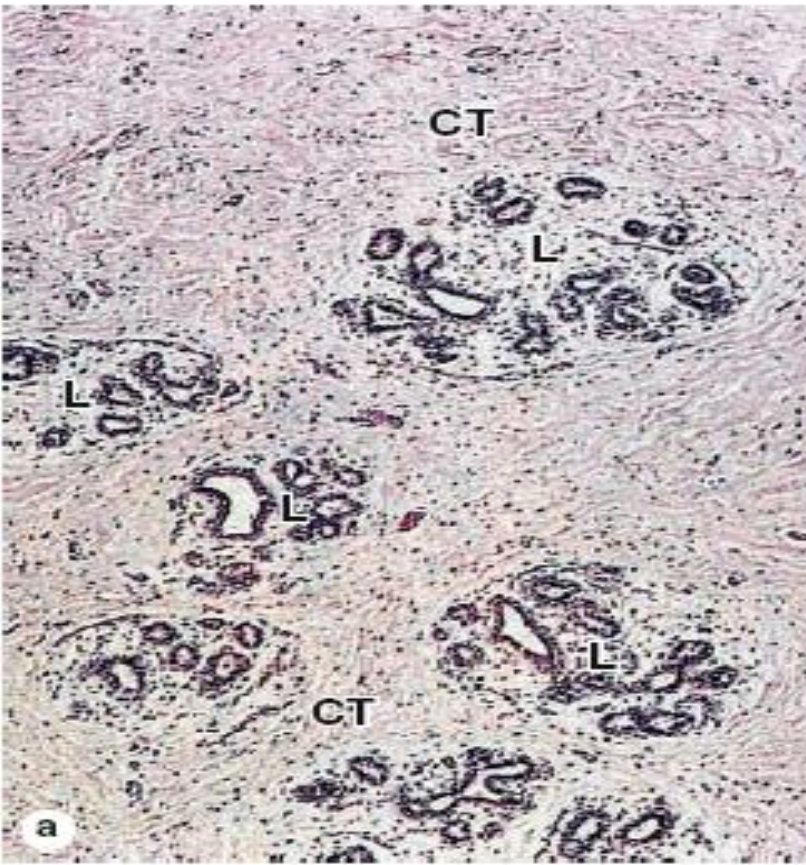


secretory

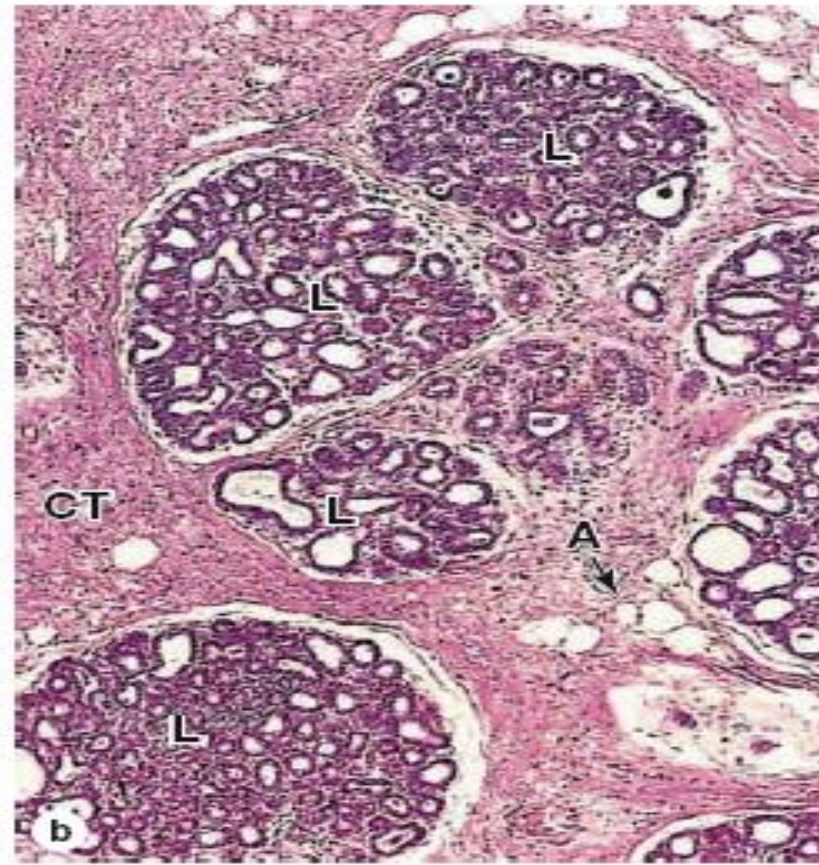


Menstrual

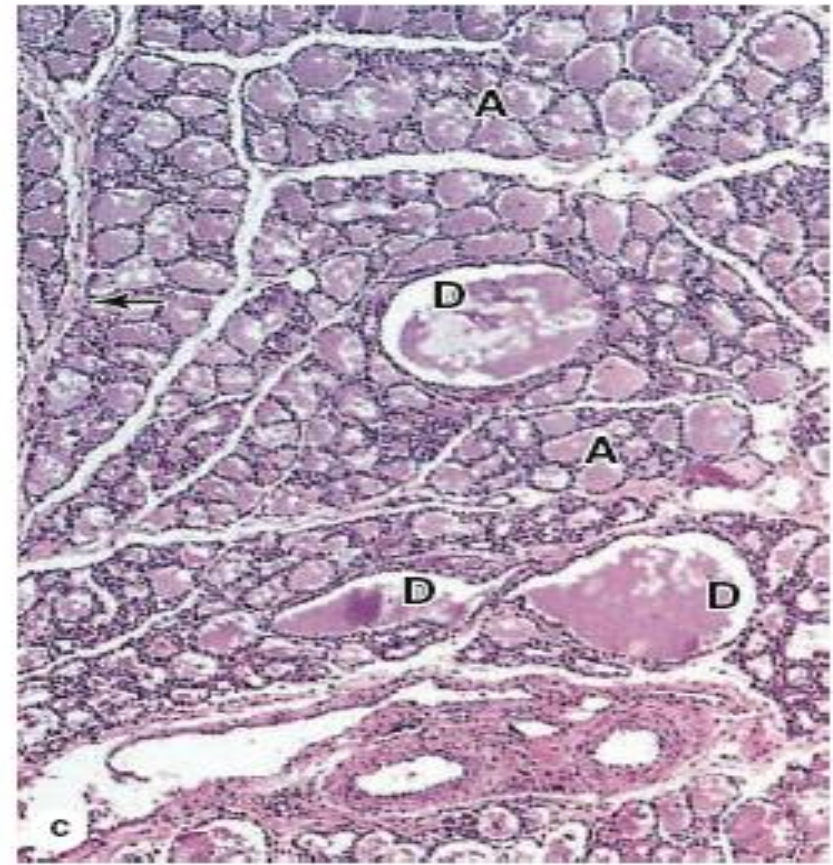
FIGURE 22-26 Alveolar development in the breast during pregnancy.



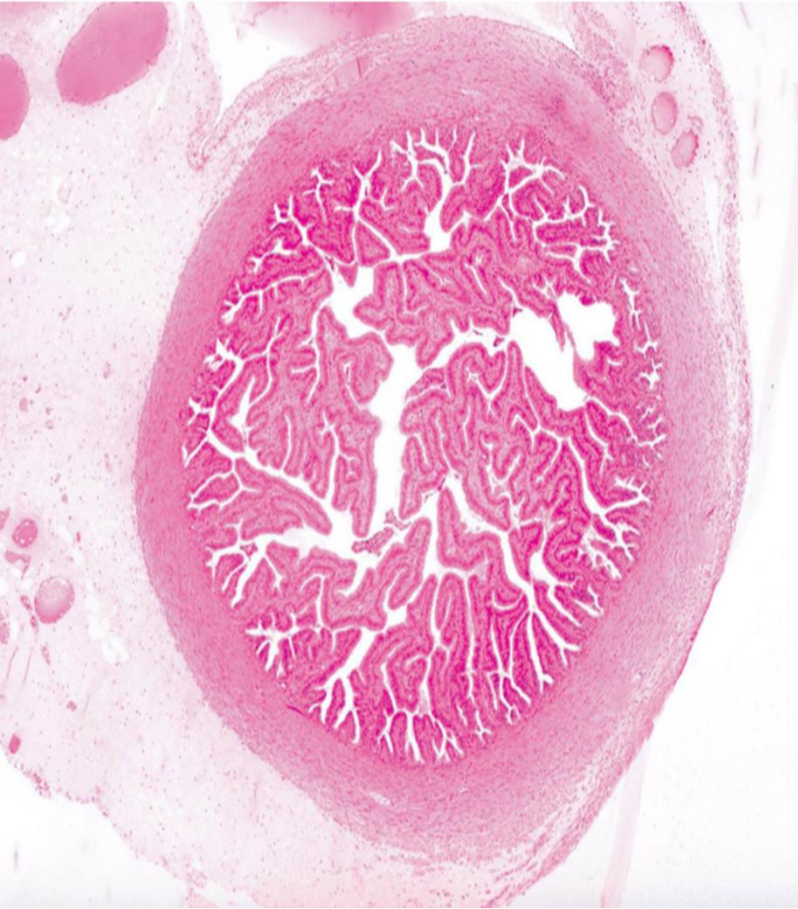(a) The mammary glands of adult, non-pregnant women are inactive, with small ducts and few lobules



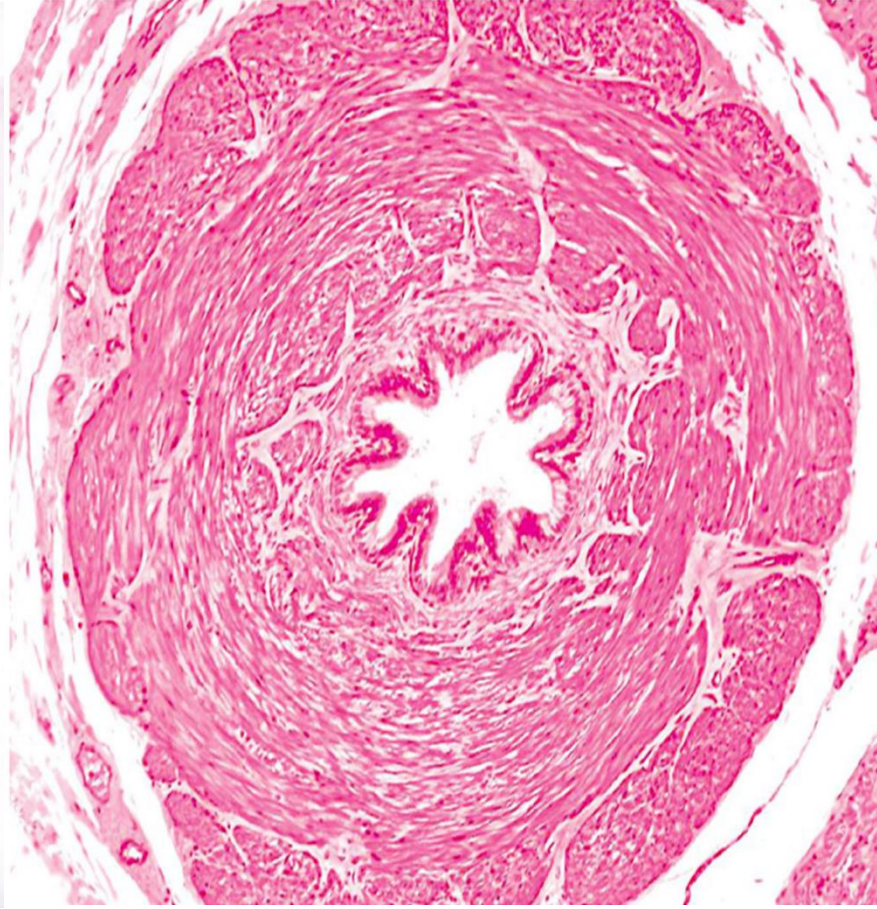
(b) During pregnancy,



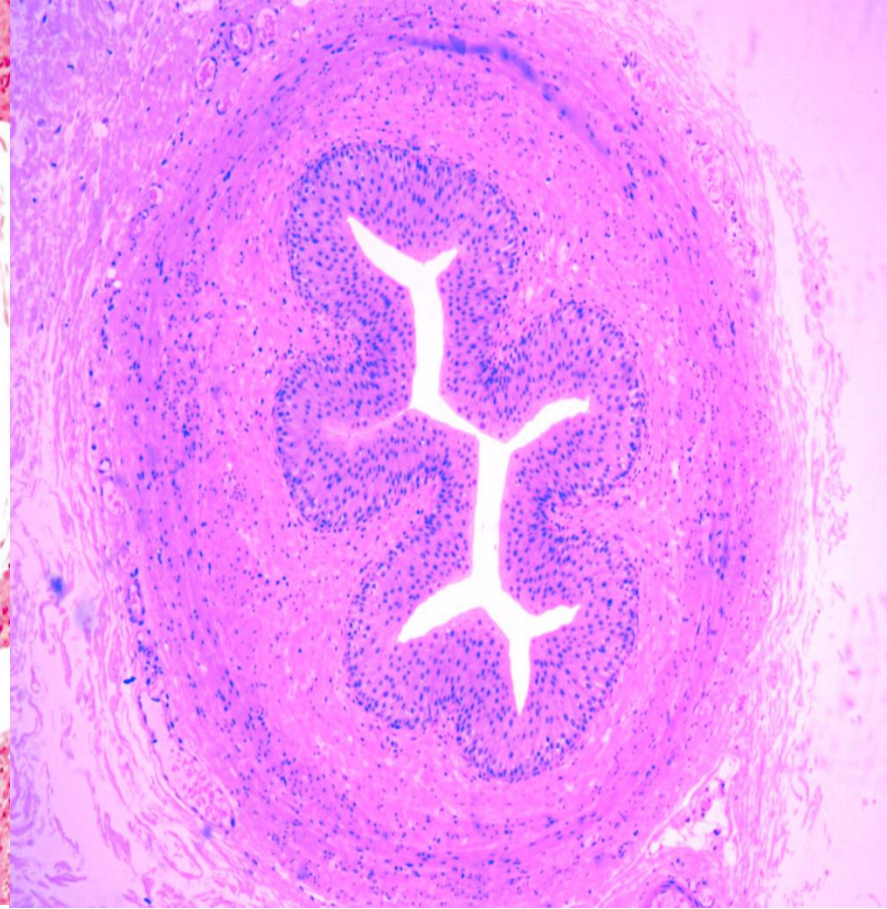
(c) During lactation, the lobules are greatly enlarged and the lumens of both the numerous glandular alveoli (A) and the excretory ducts (D) are filled with milk.



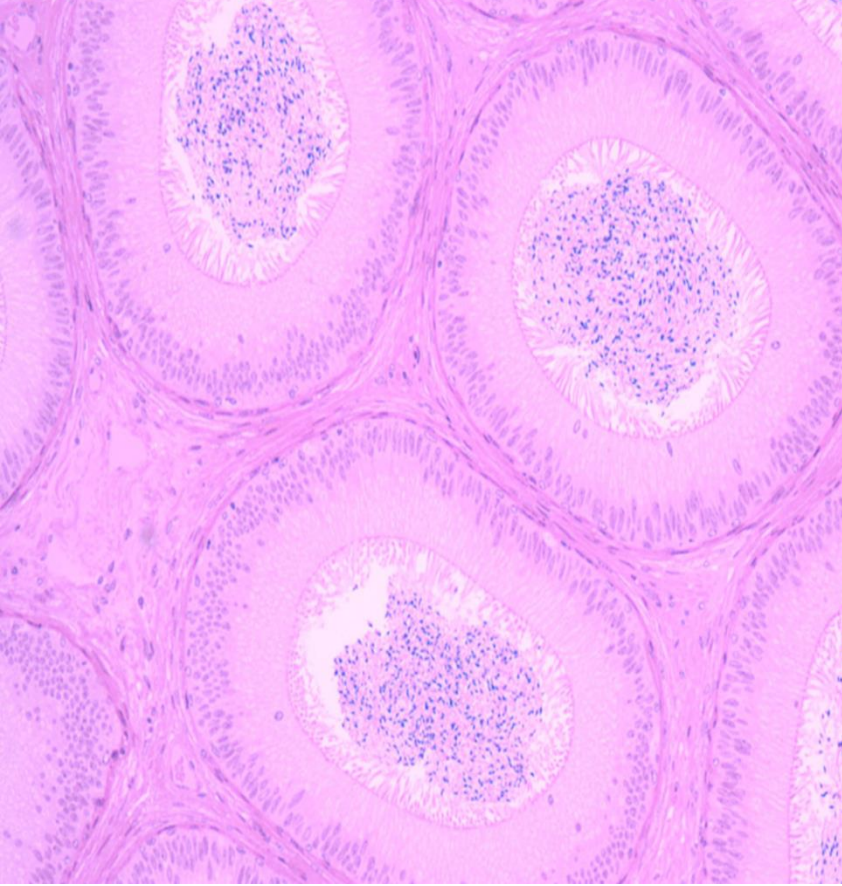
Uterine Tube



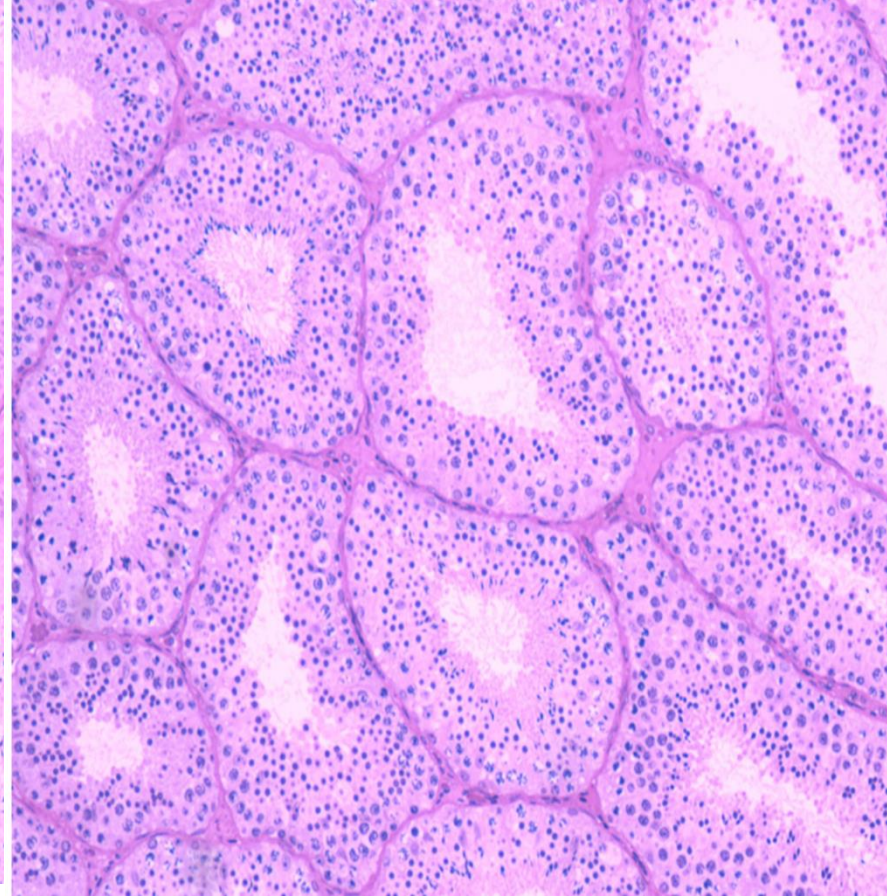
Vas Deference



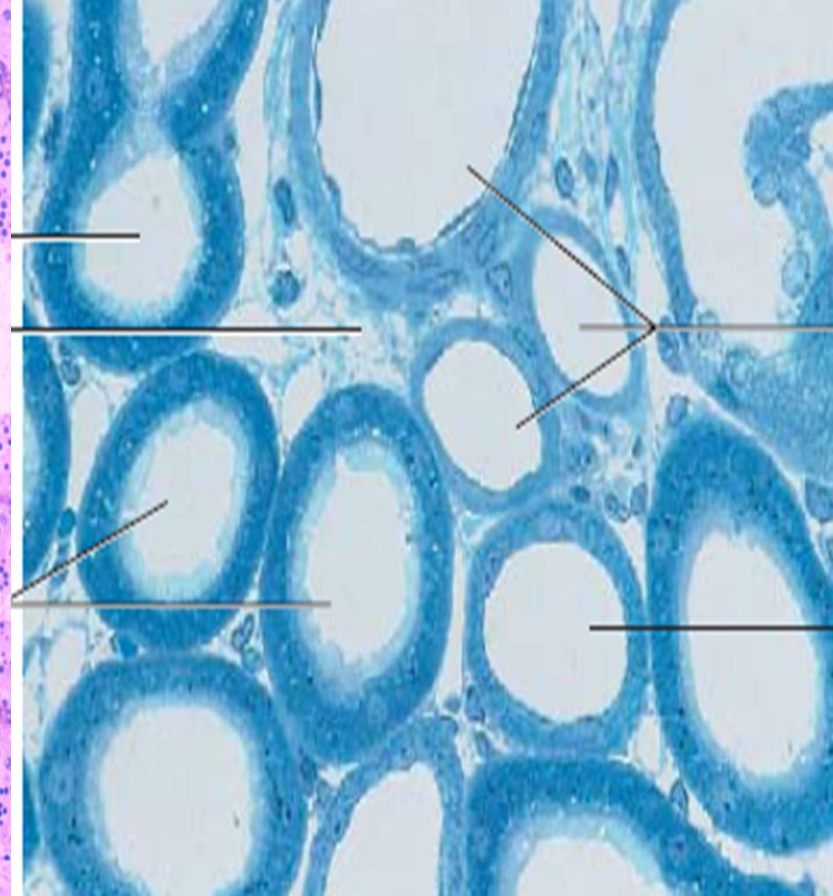
Ureter



Epididymis



Testis



Kidney

THANK YOU