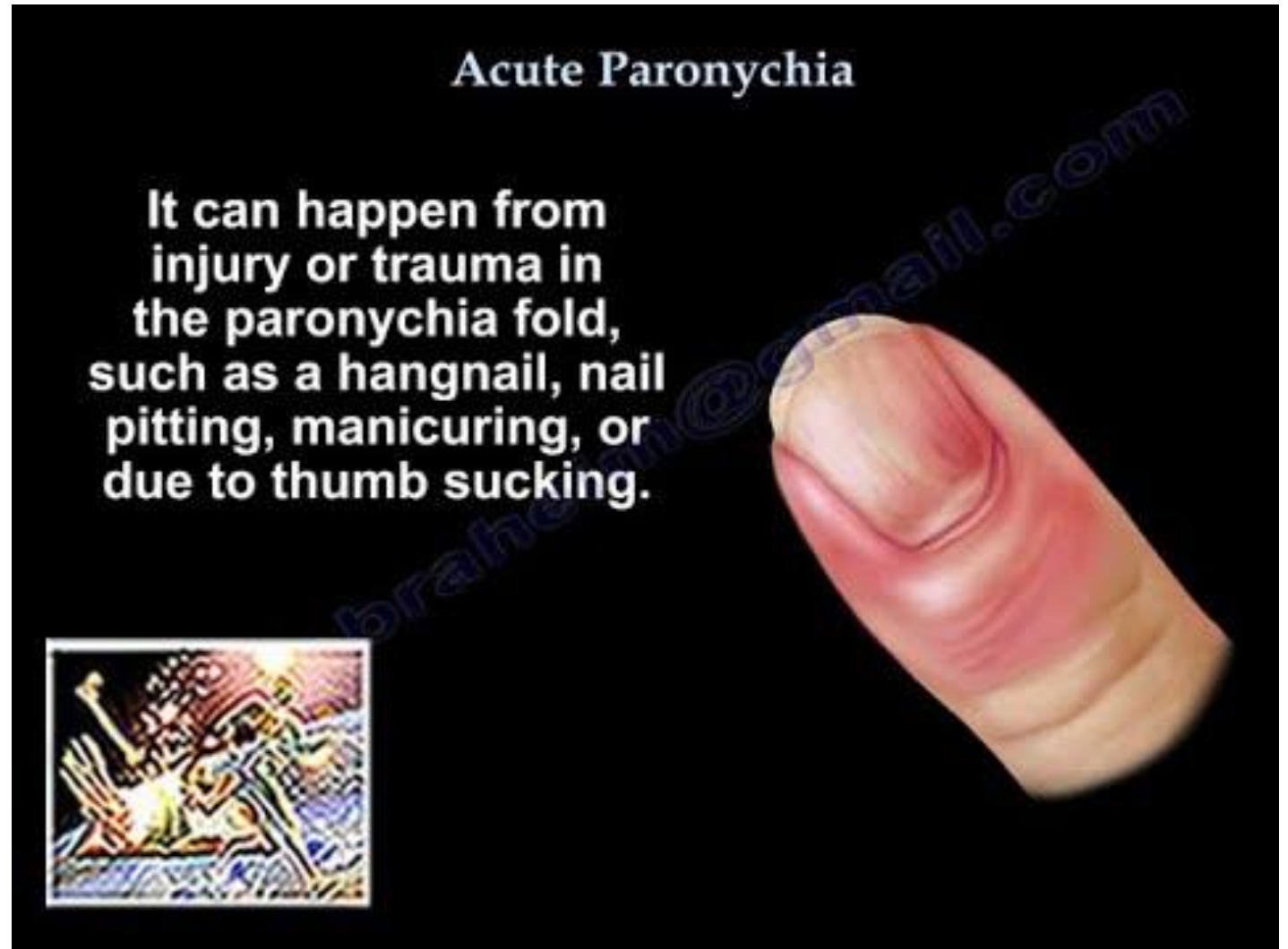


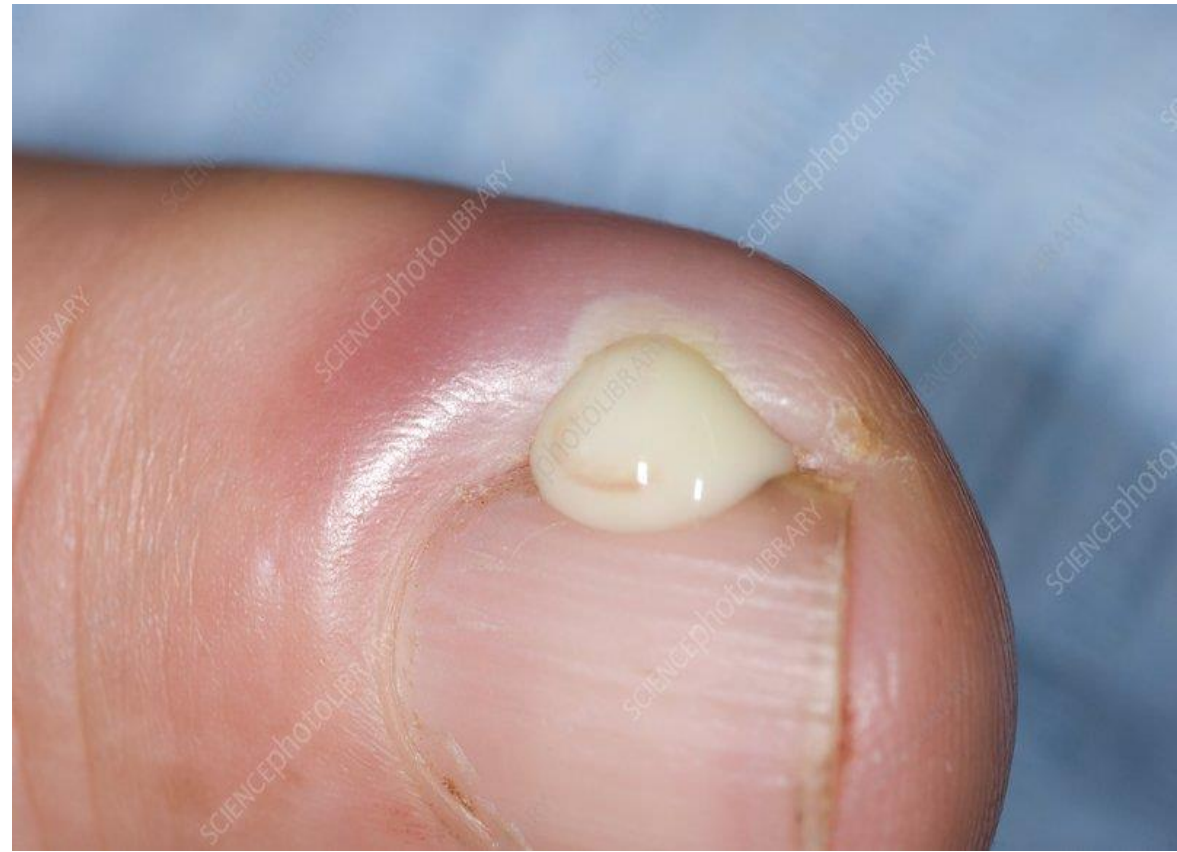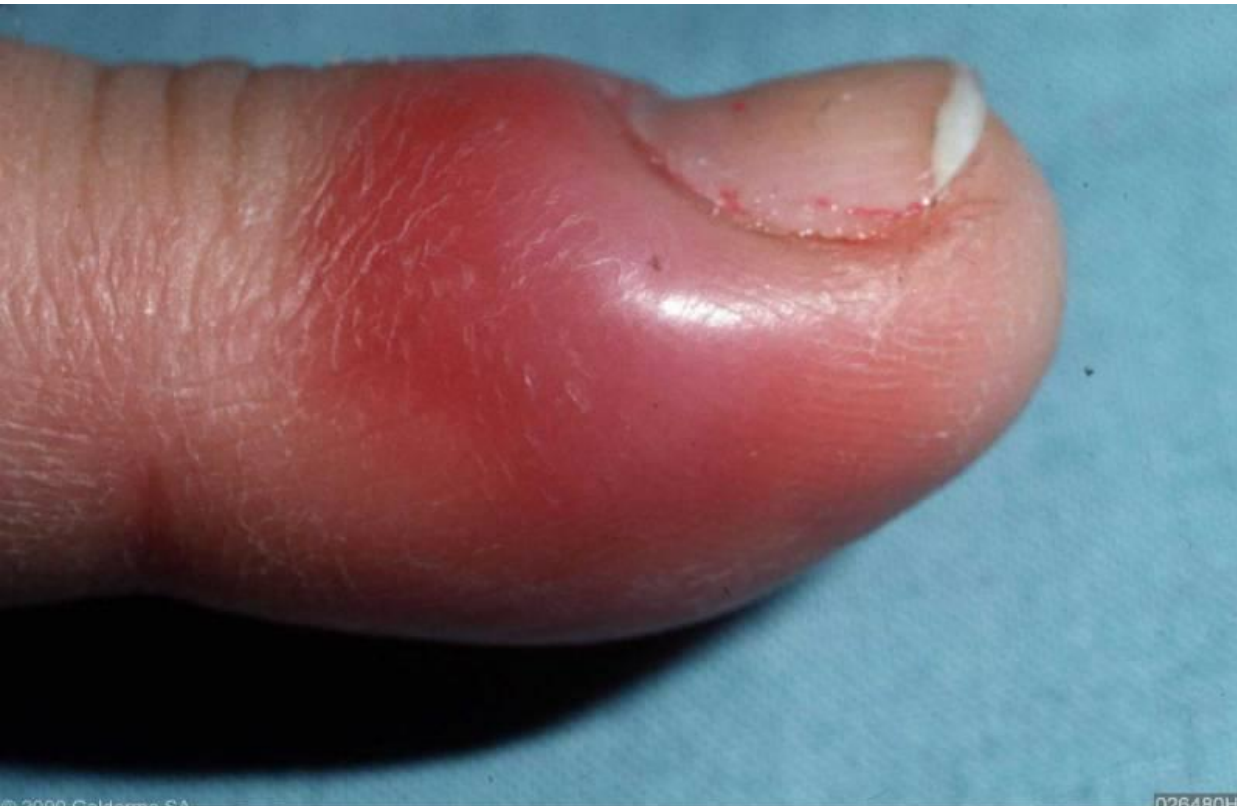Common hand conditions

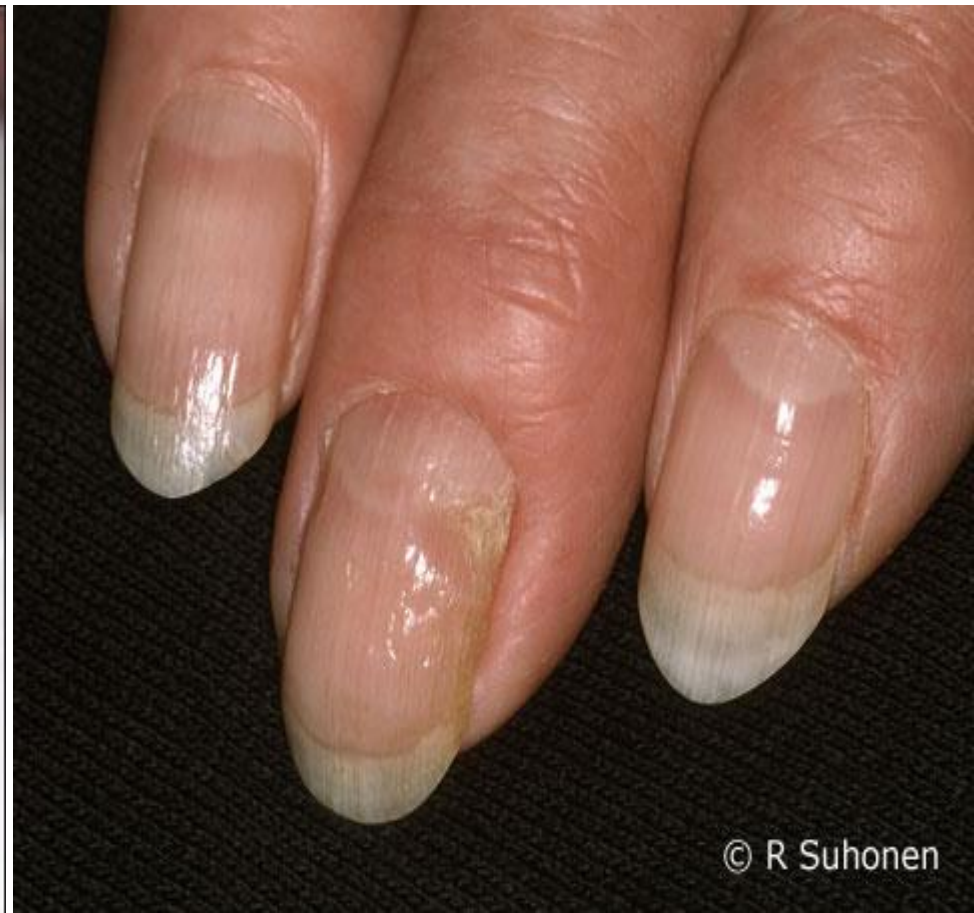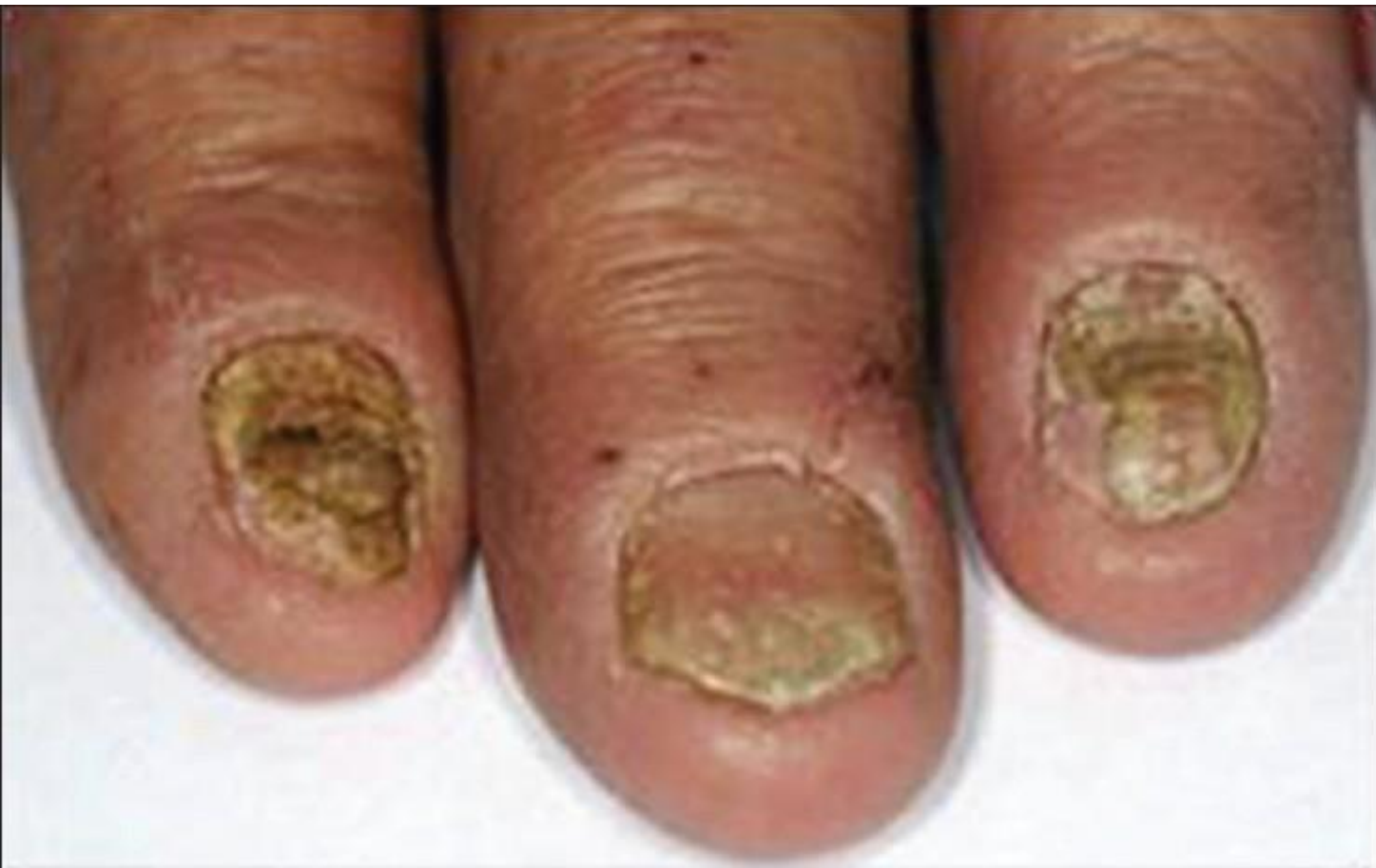- Paronychia

Refer to the following link:

<https://www.health.harvard.edu/a-to-z/paronychia-a-to-z>

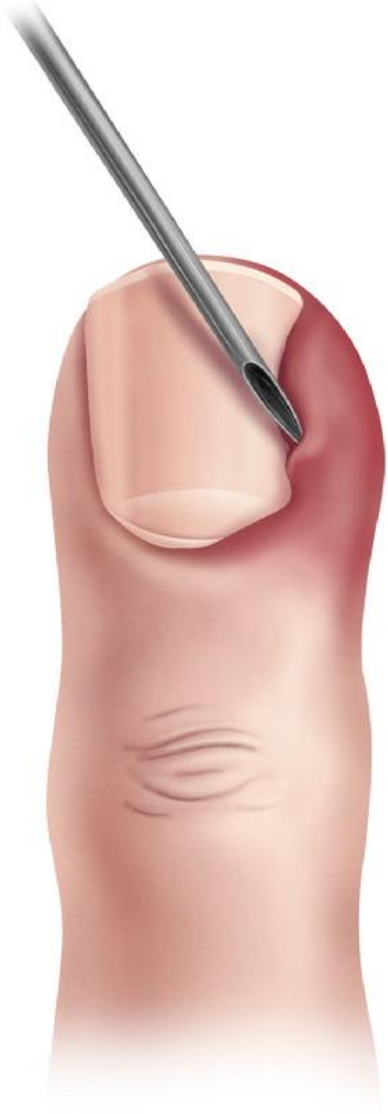




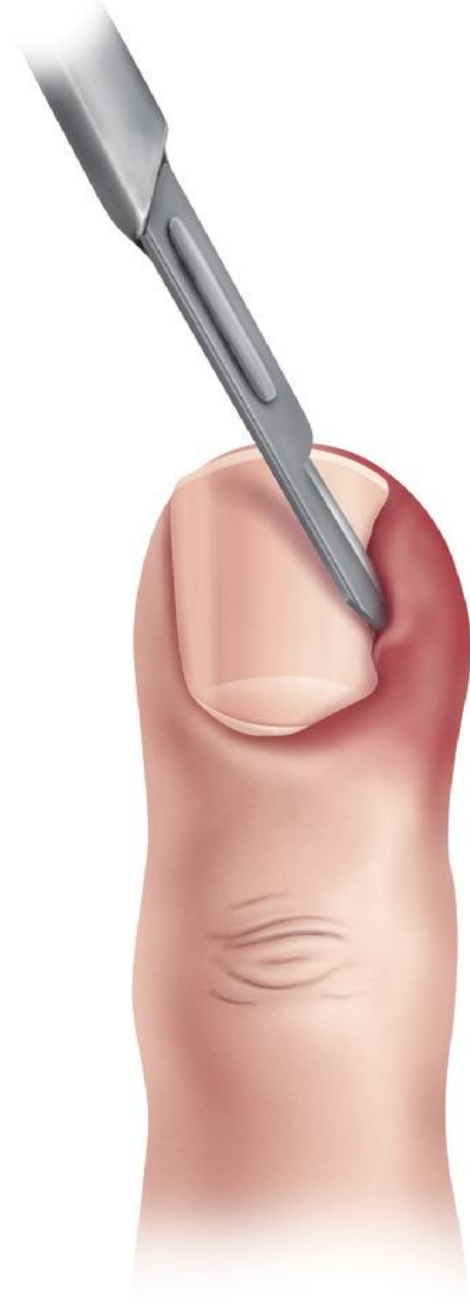
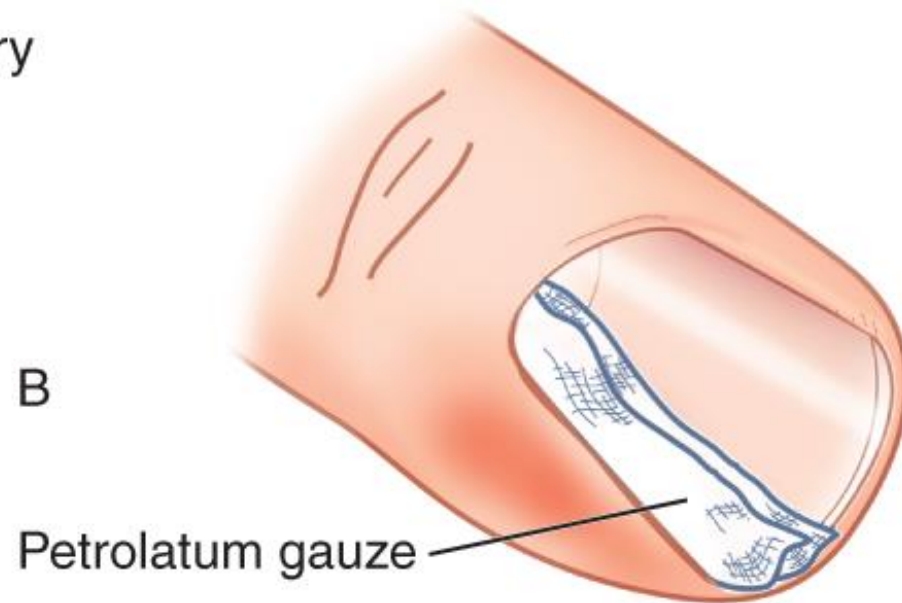
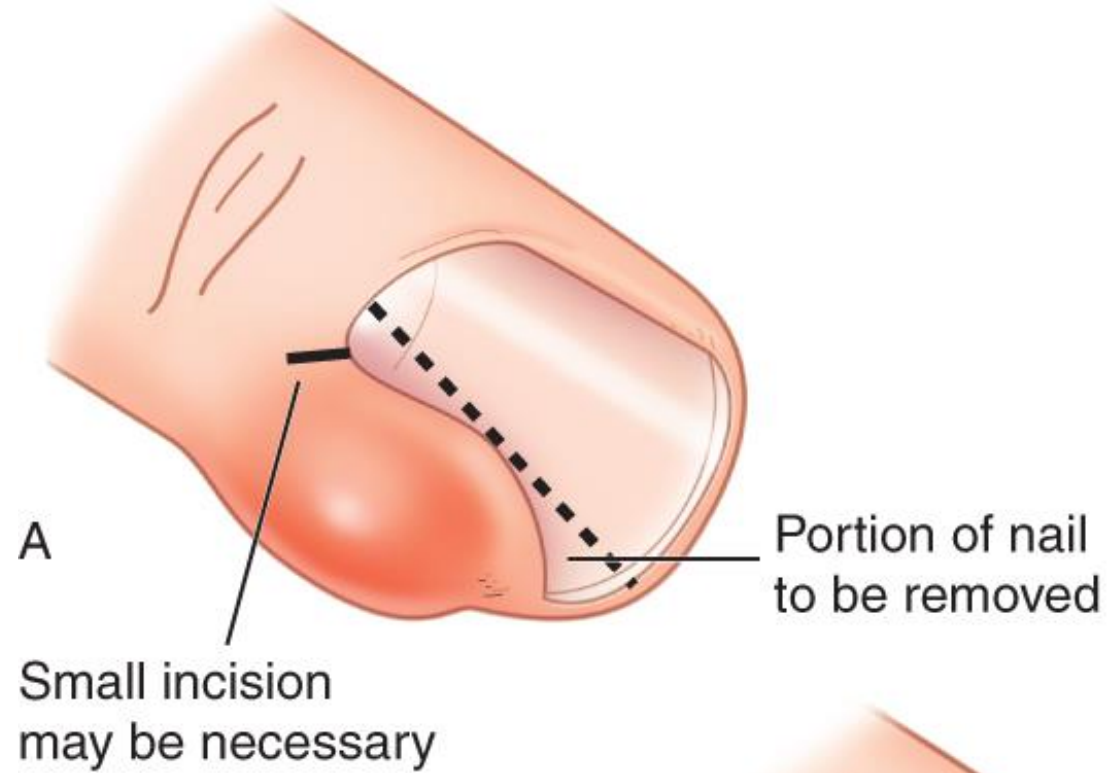
© R Suhonen

A



B

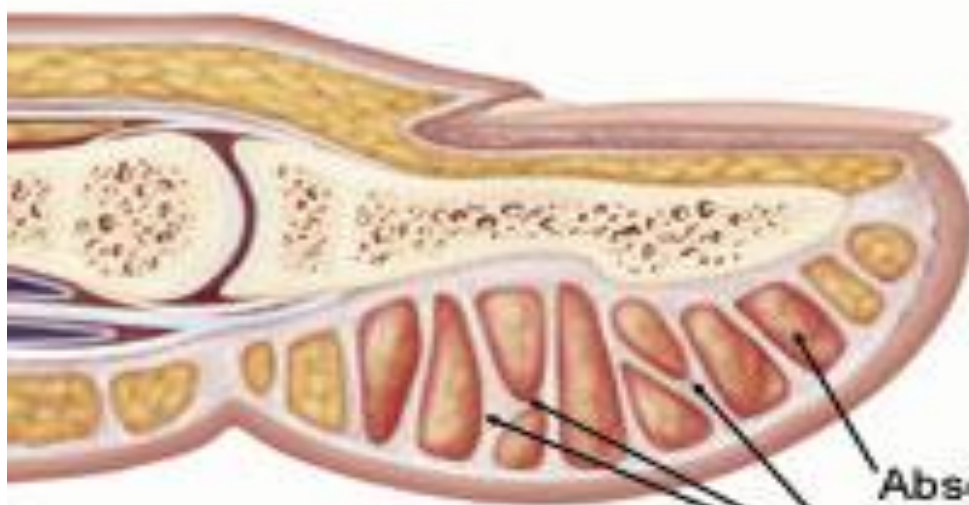
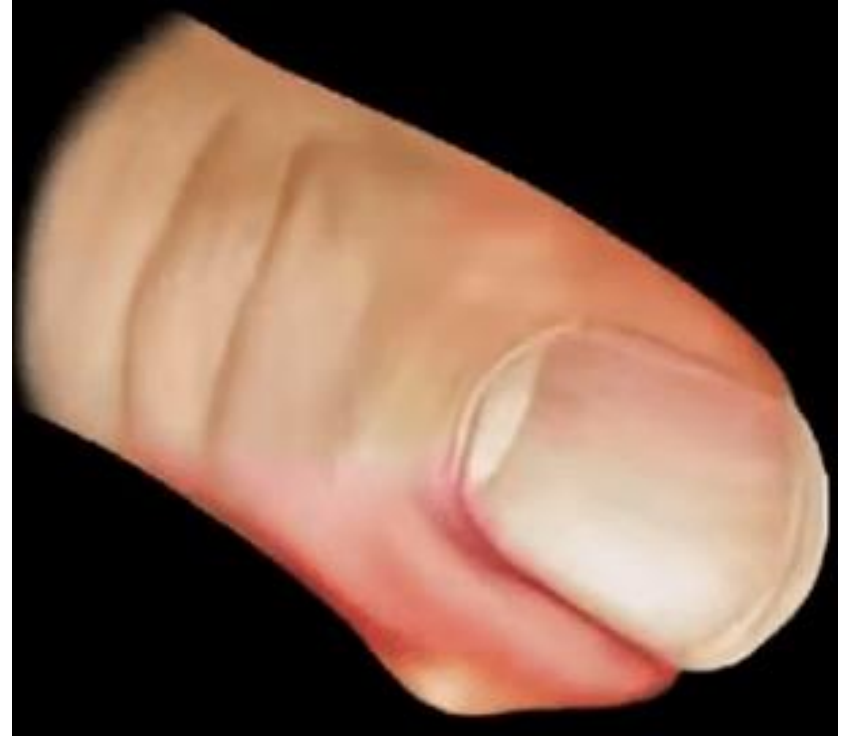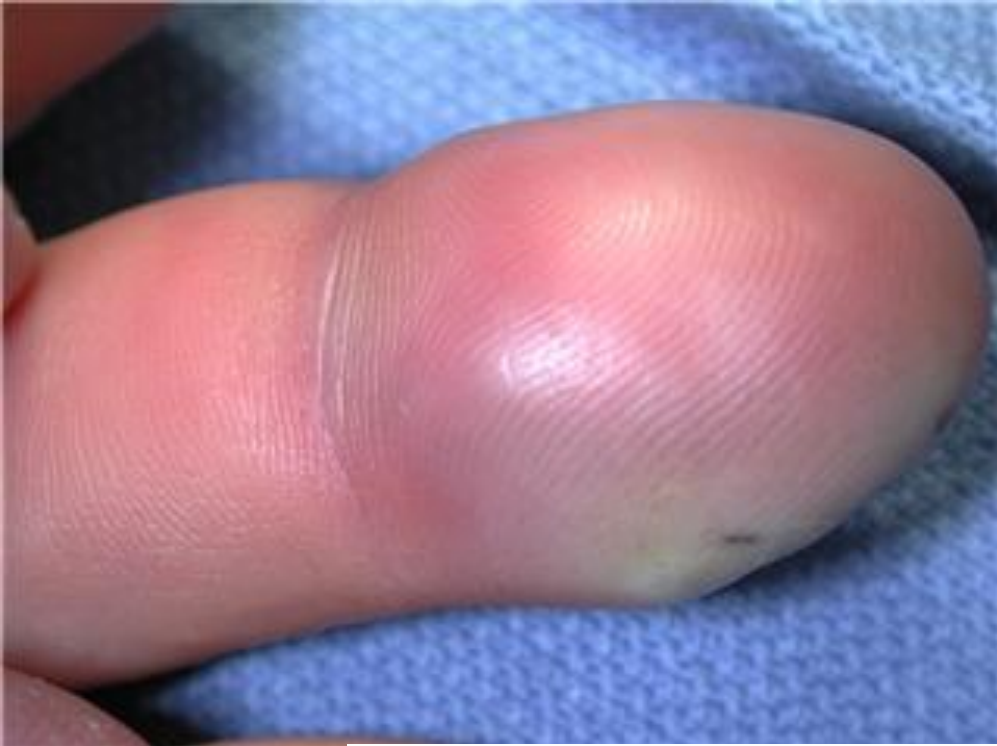




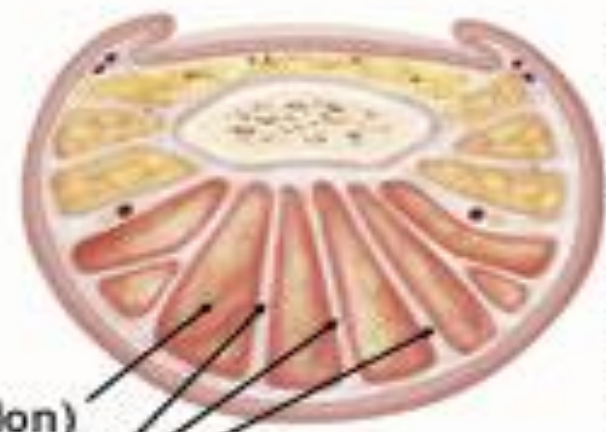
Common hand conditions

- Felon (Pulp abscess)

[https://www.health.harvard.edu/a to z/felon-a-to-z](https://www.health.harvard.edu/a_to_z/felon-a-to-z)

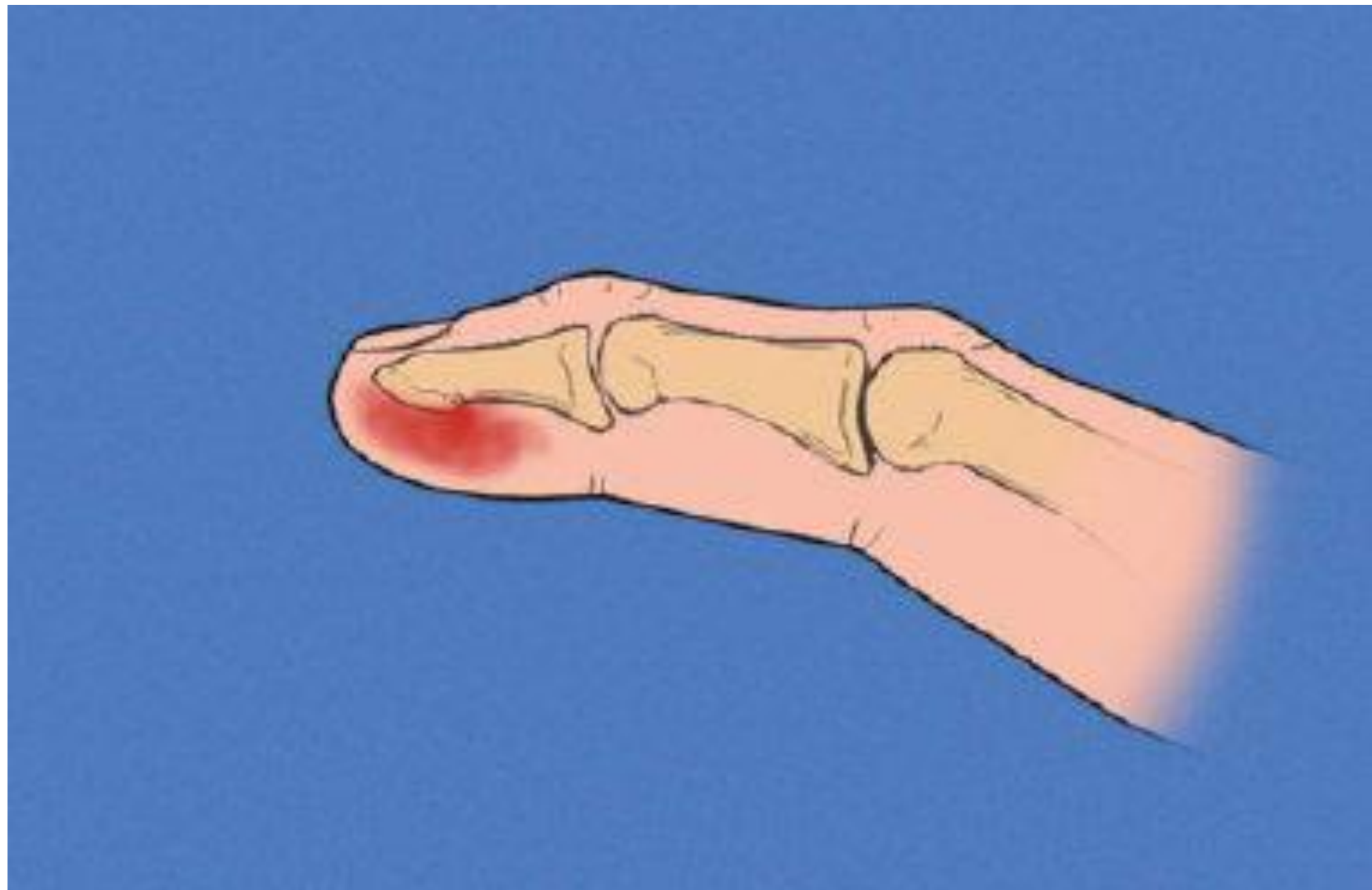

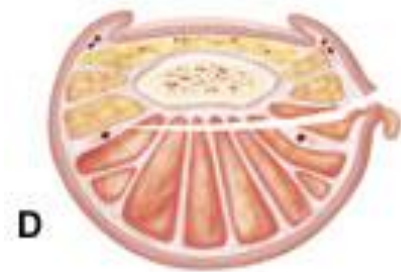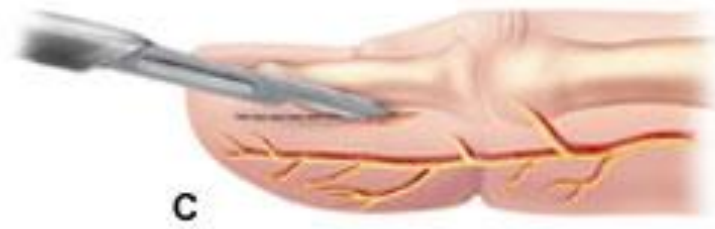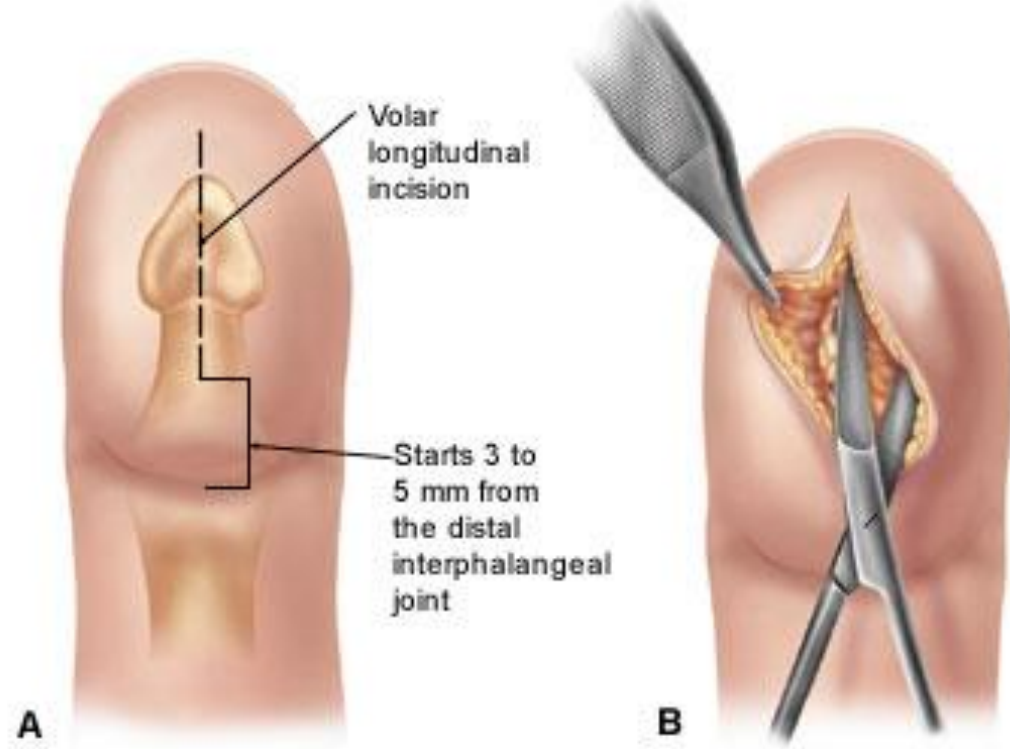
Cross section



Abscess (felon)

Fibrous septa



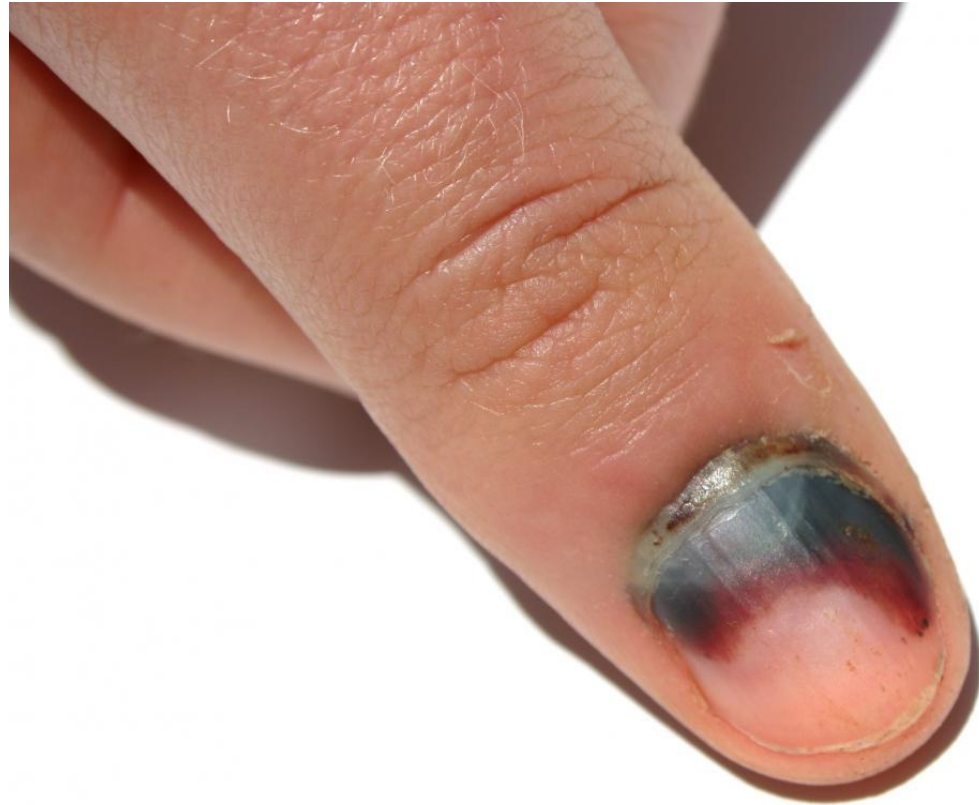

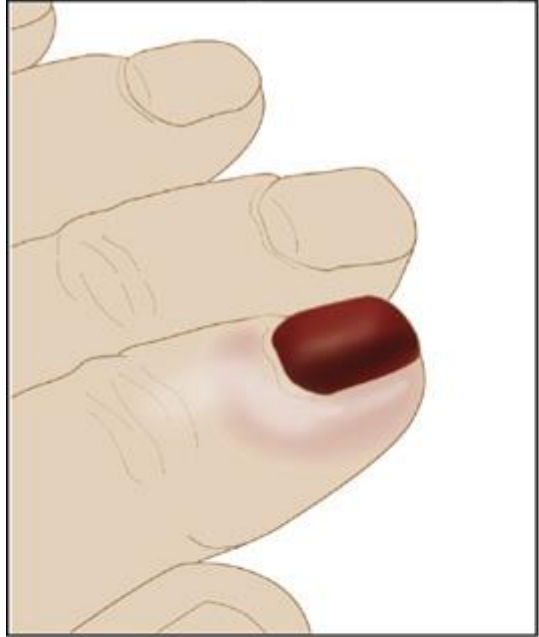
Common hand conditions

- Subungual hematoma

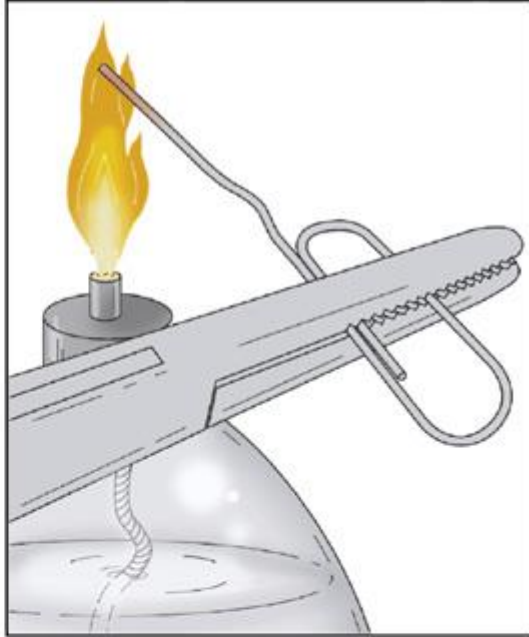
Please refer to the following link:

https://www.emedicinehealth.com/subungual_hematoma_bleeding_under_nail/article_em.htm#subungual_hematoma_facts

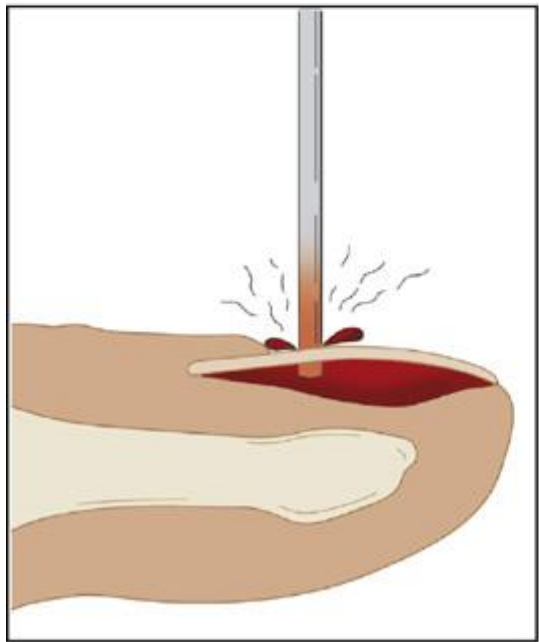




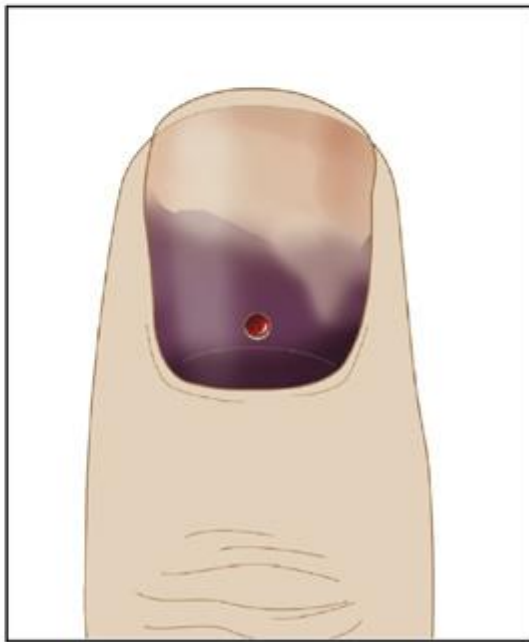
A



B



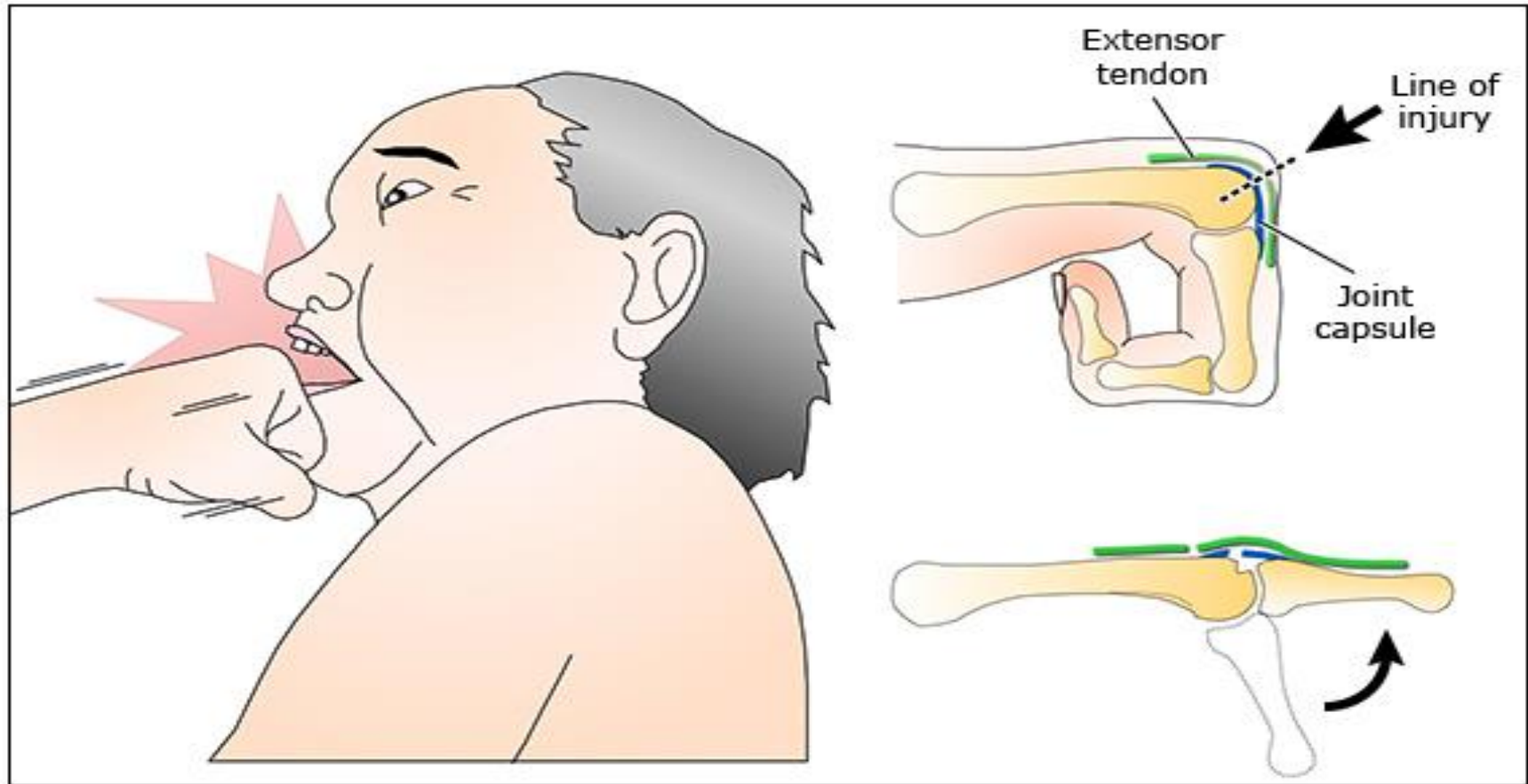
C

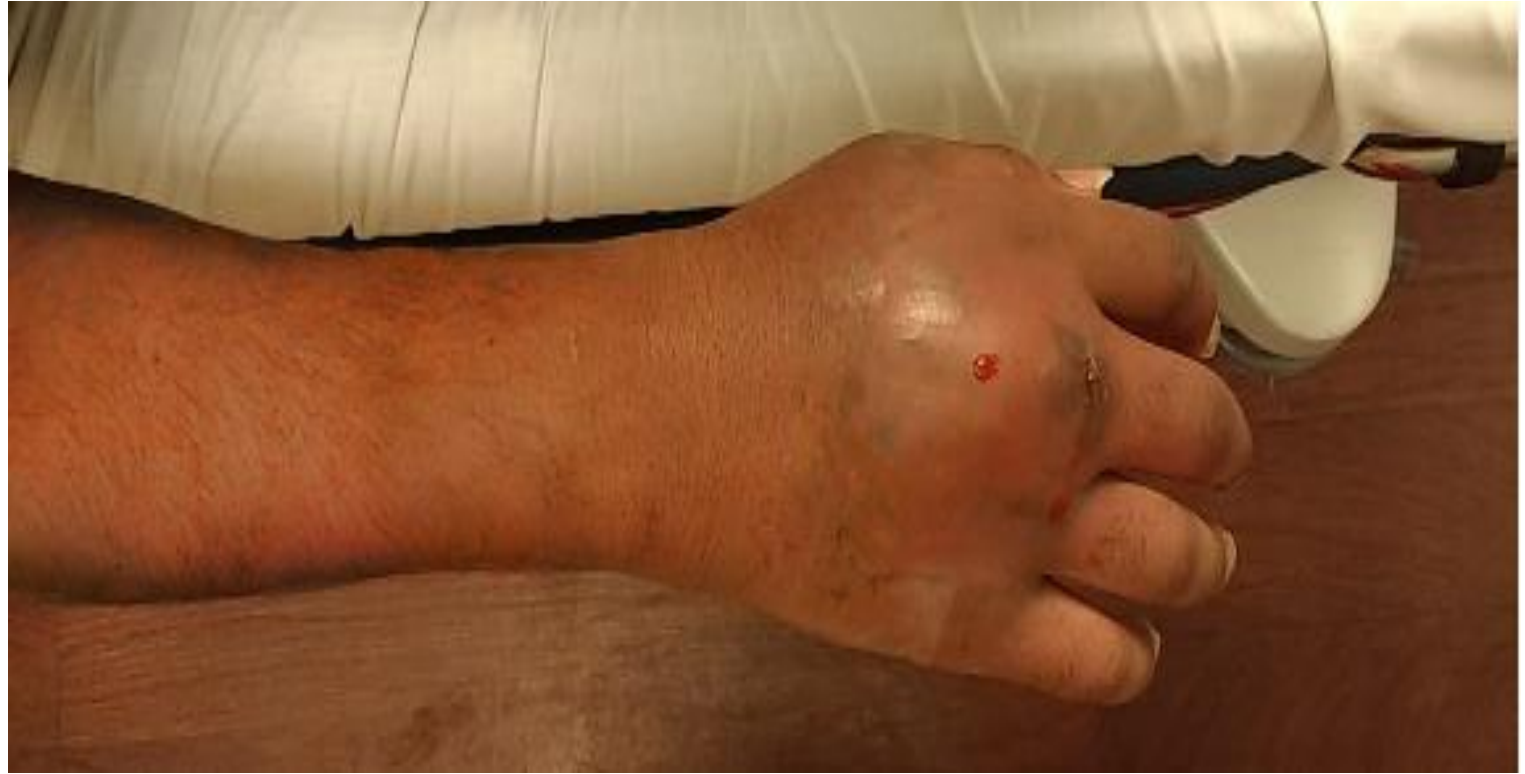
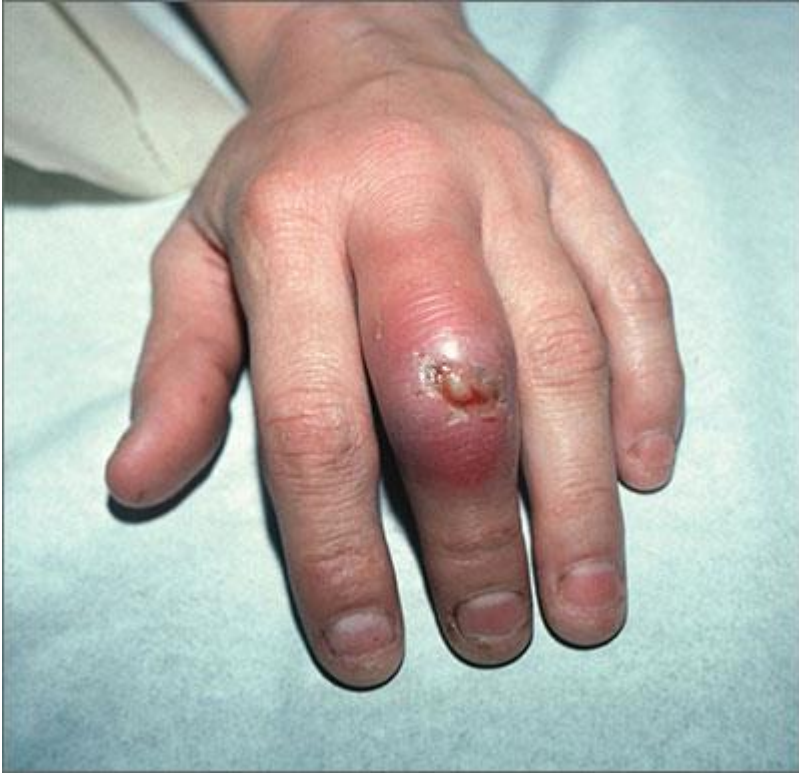
D

Common hand conditions

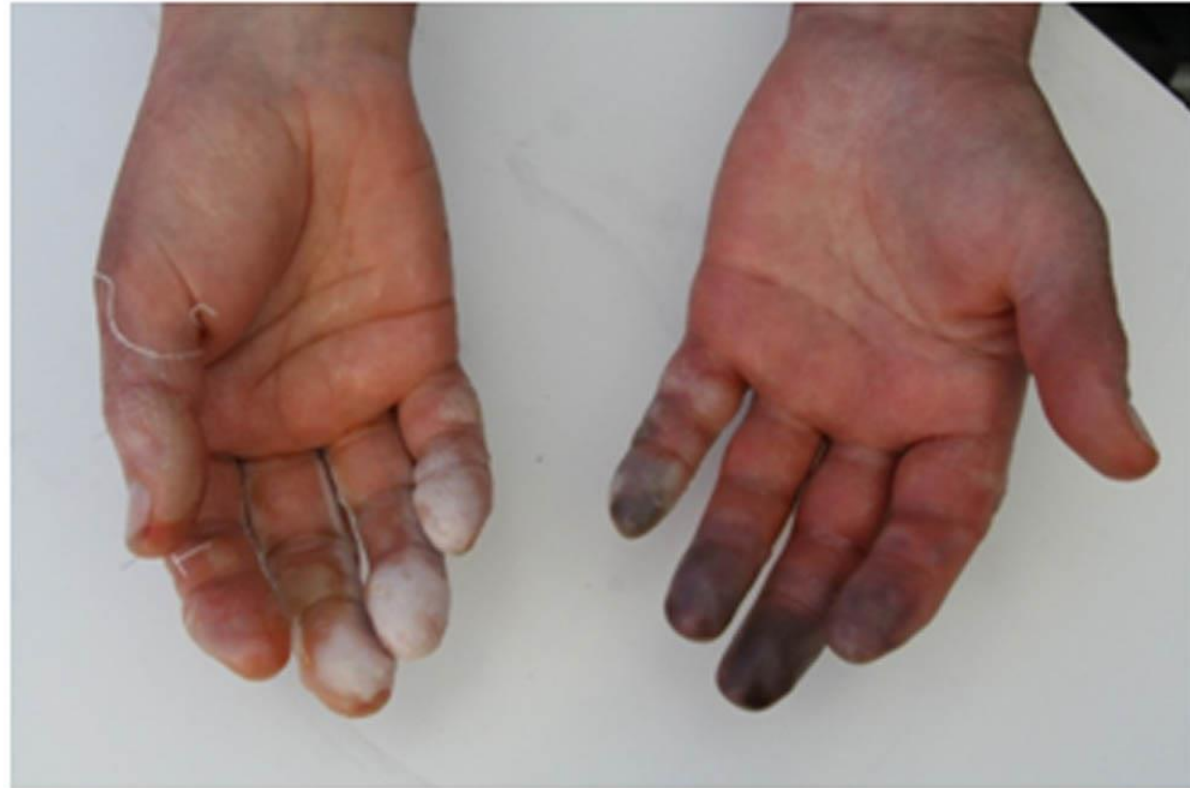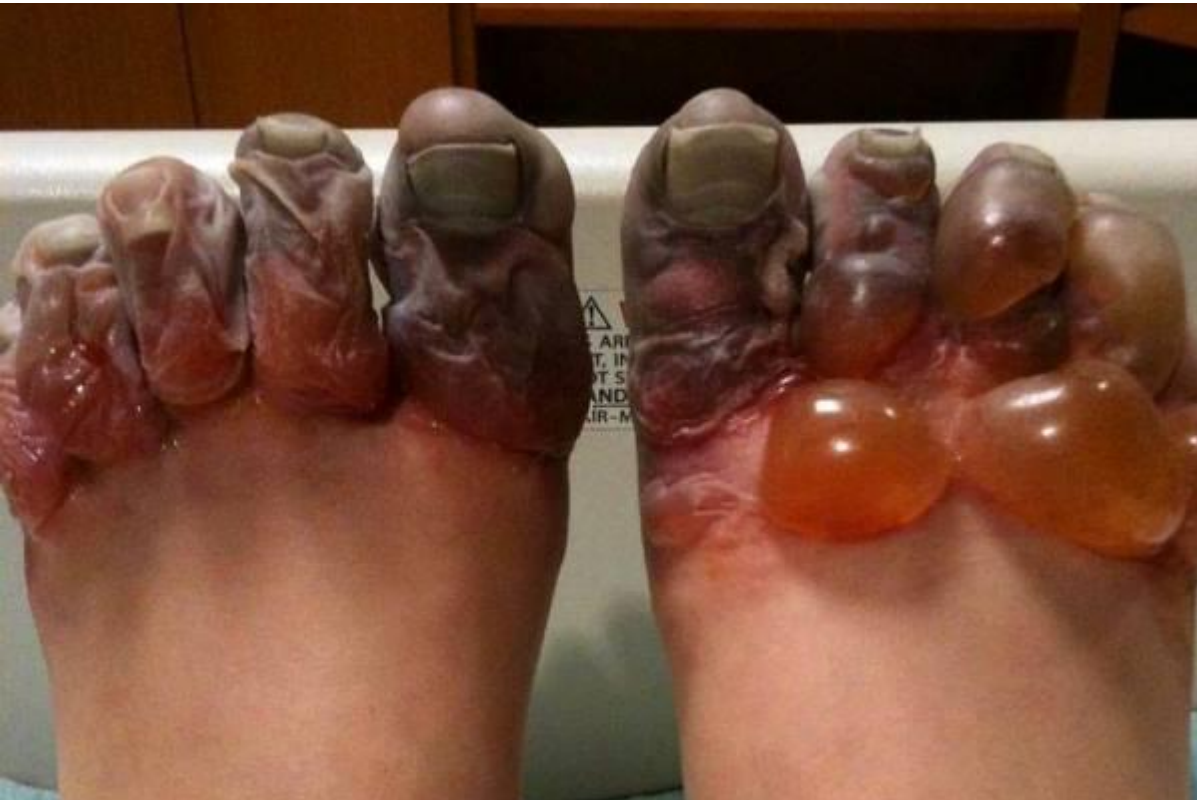- Human fight bite (fist injury)

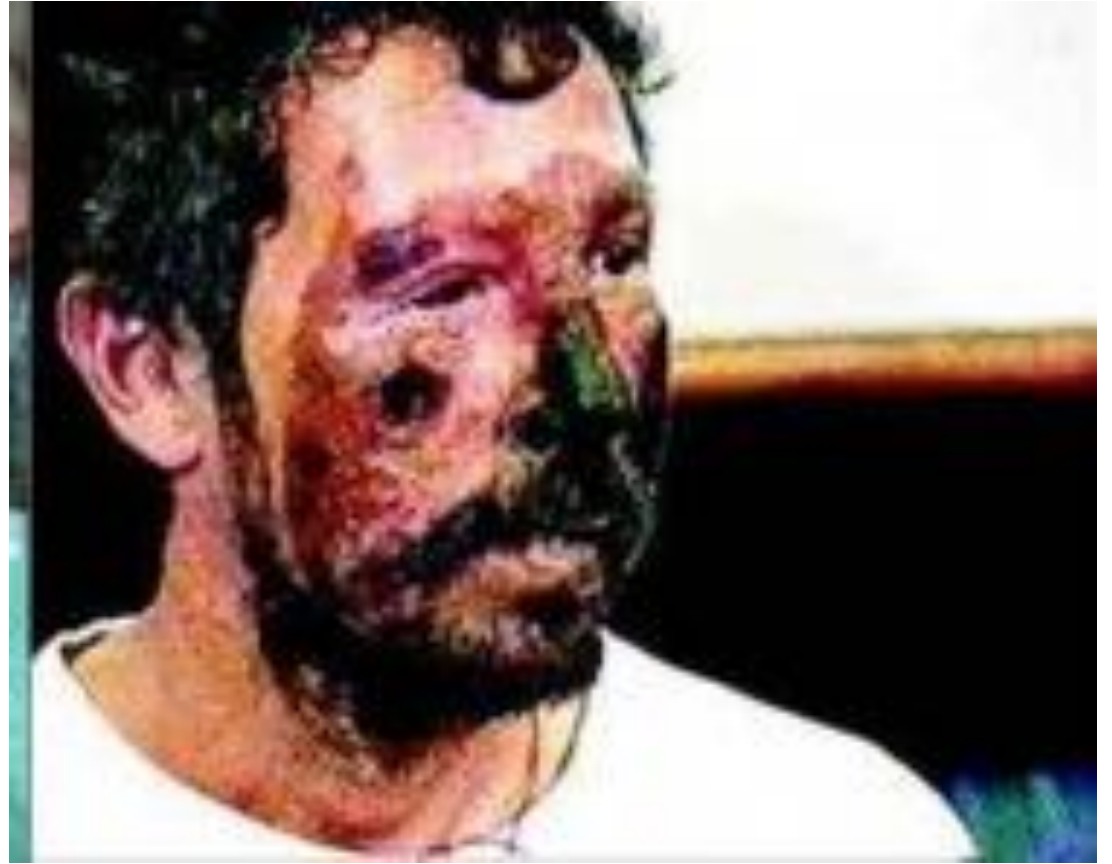
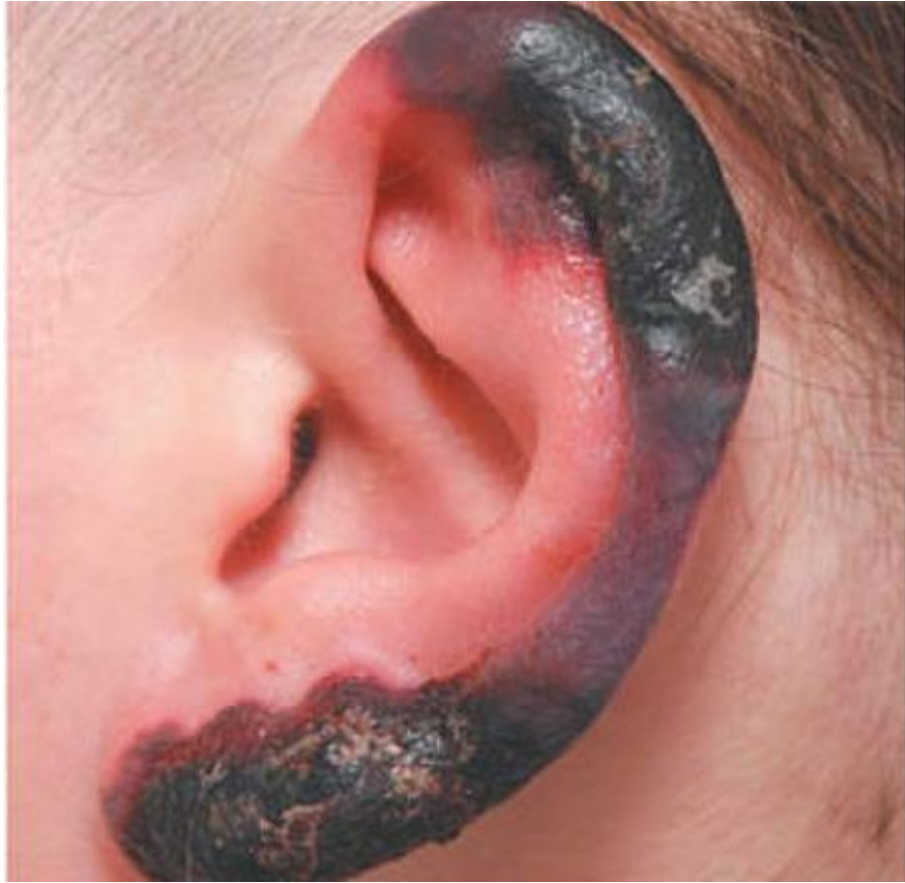


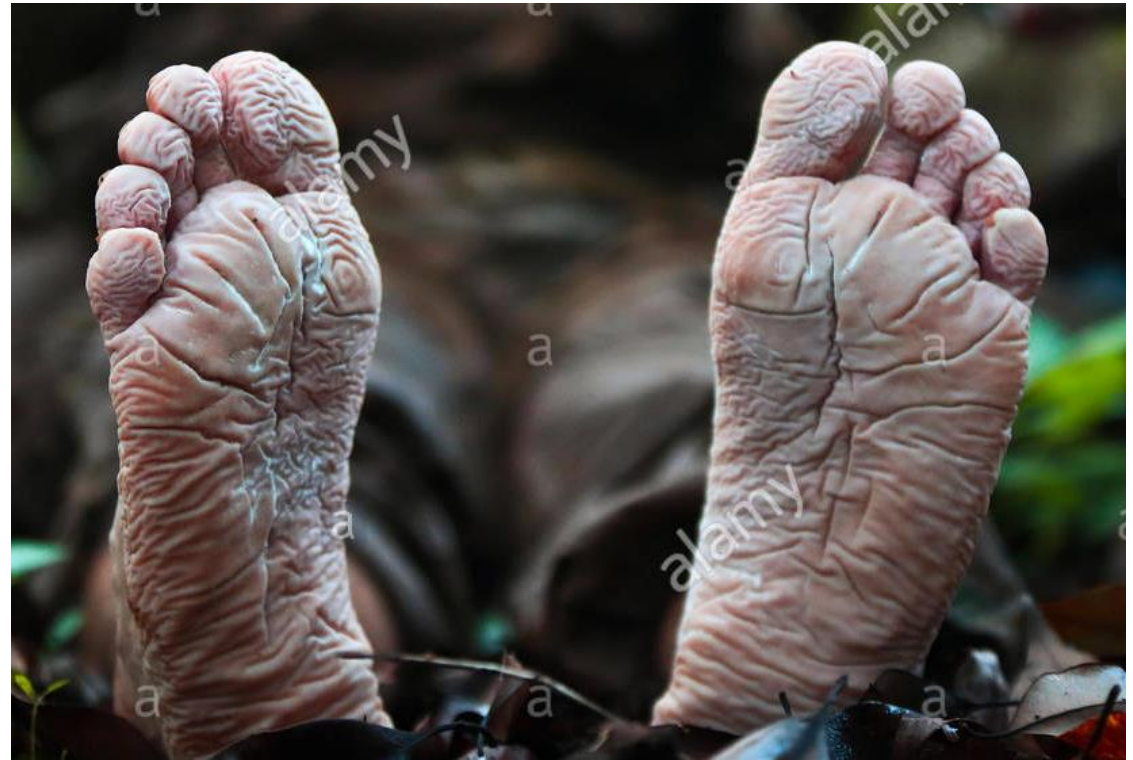Please refer to the following link:
<https://epmonthly.com/article/fite-bite/>

Frostbite





Trench foot



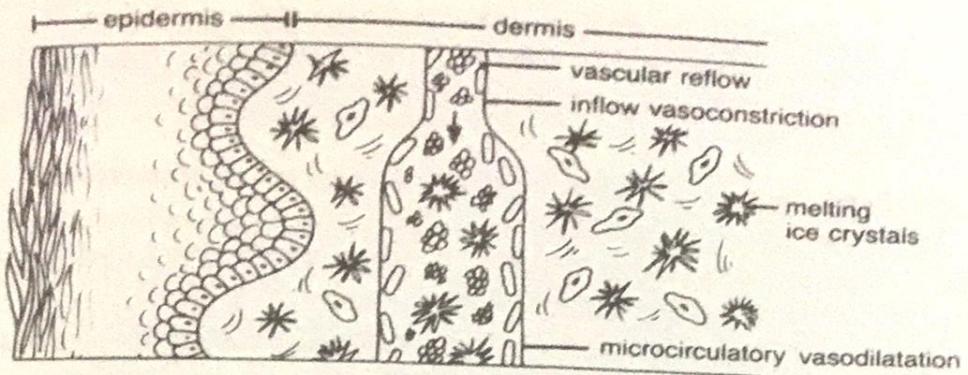
Please refer to this link:

<https://medlineplus.gov/frostbite.html>

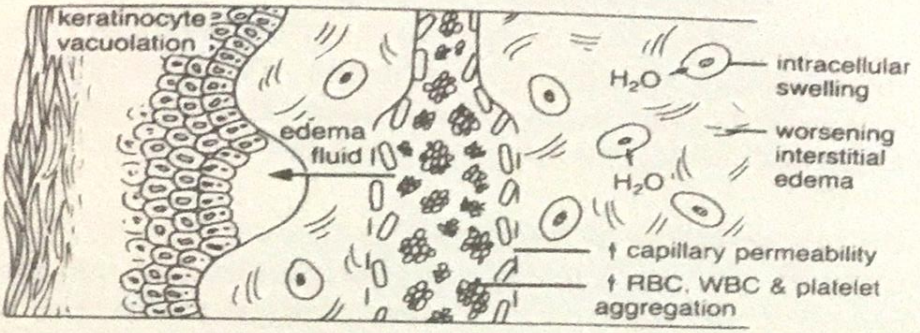
<https://www.healthline.com/health/trench-foot#qa>

- Predisposing risk factors
- Classification
- Pathophysiology

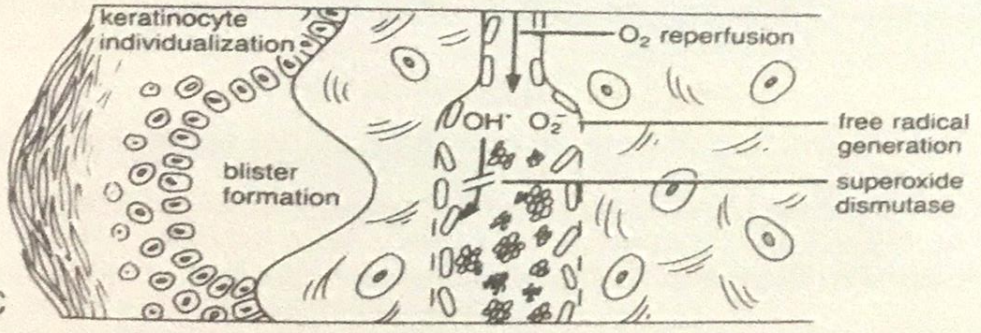
AMBIENT TEMP
TO -2°C



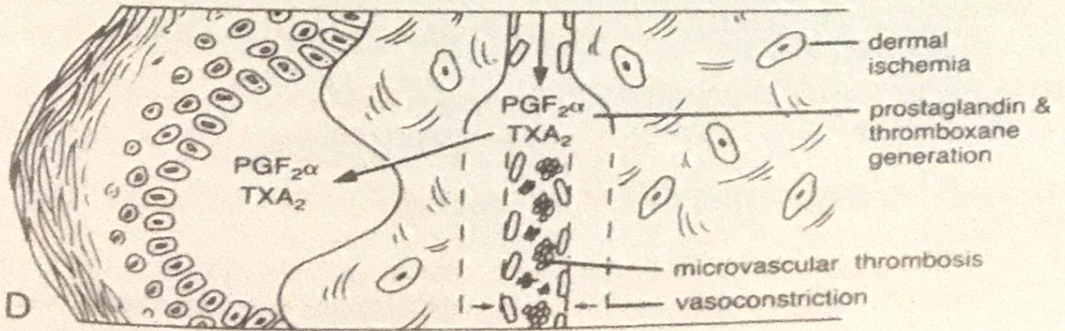
-2°C
 H_2O BATH TEMP



REWARMING
COMPLETE



POST-
REWARMING



- Treatment

- ❖ Re-warming

- ❖ Analgesia

- ❖ Massaging X

- ❖ Antibiotics X

- ❖ Steroids X

- ❖ Debridement

- ❖ Elevation

- ❖ Topical thromboxane inhibitor

- ❖ Systematic antiprostaglandin agent

- ❖ T.T

- ❖ Dressing

- ❖ Amputation

- ❖ Adjuvant therapy: alpha blocker, free radical scavengers, thrombolytics

- ❖ Late sequelae.