

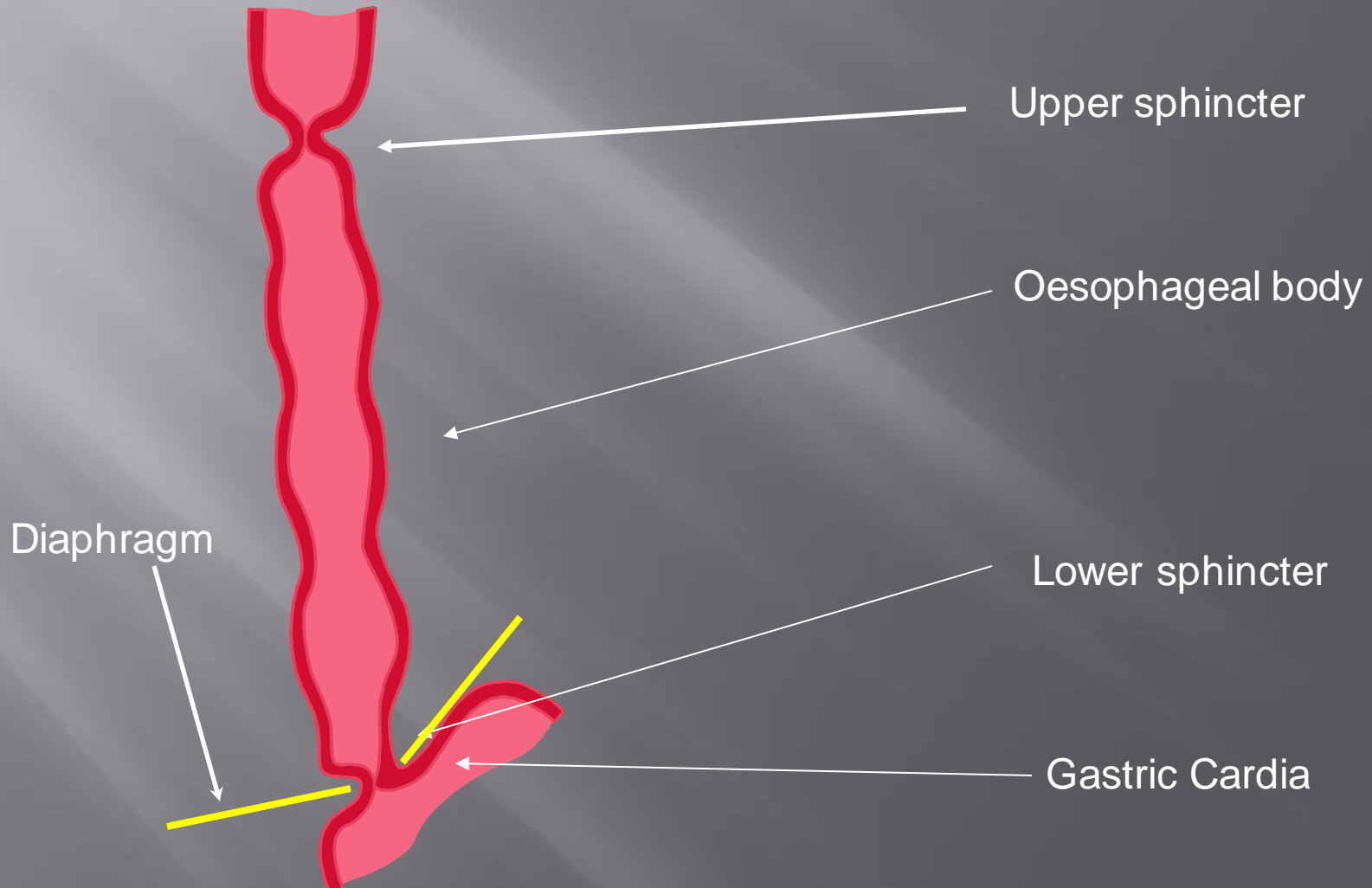
ESOPHAGEAL DISORDERS

Awni Taleb Abu sneineh

MBBS.MD.FRACP

Gastroenterologist and hepatologist

Anatomy



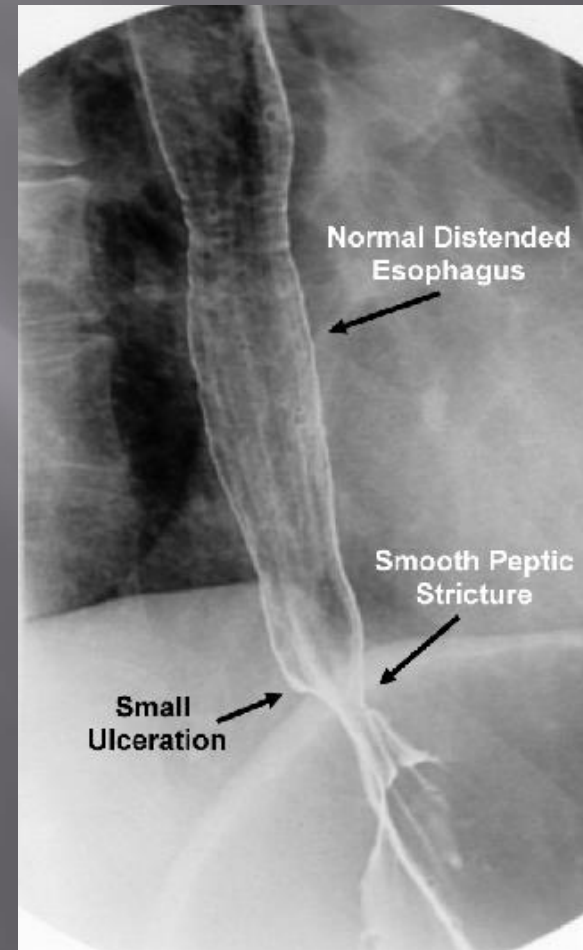
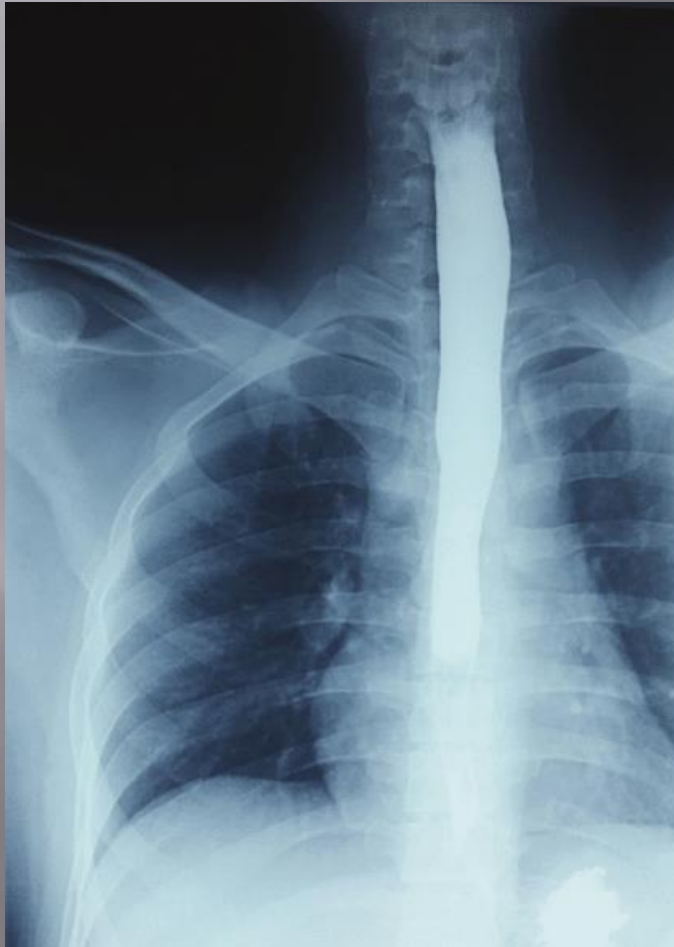
Symptoms of esophageal disorders

- ▣ Dysphagia
- ▣ Odynophagia
- ▣ Non cardiac chest pain
- ▣ Heartburn
- ▣ Regurgitation

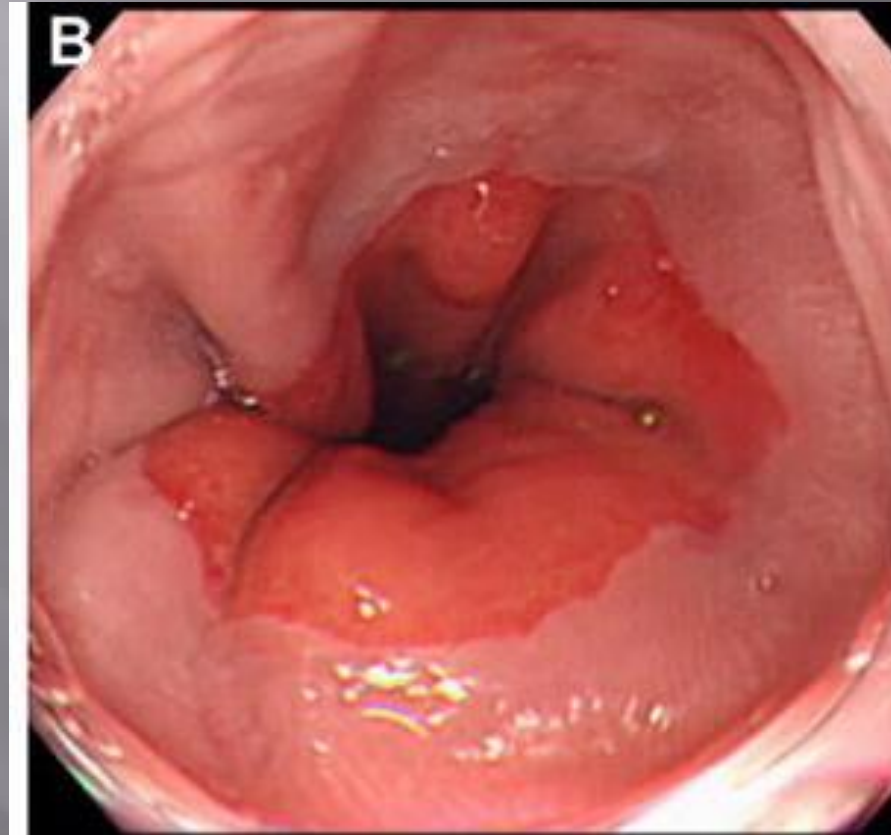
Diagnostic Tools

- ▣ Barium Swallow
- ▣ Endoscopy
- ▣ Esophageal manometry
- ▣ 24 hr esophageal pH monitoring
- ▣ Impedence

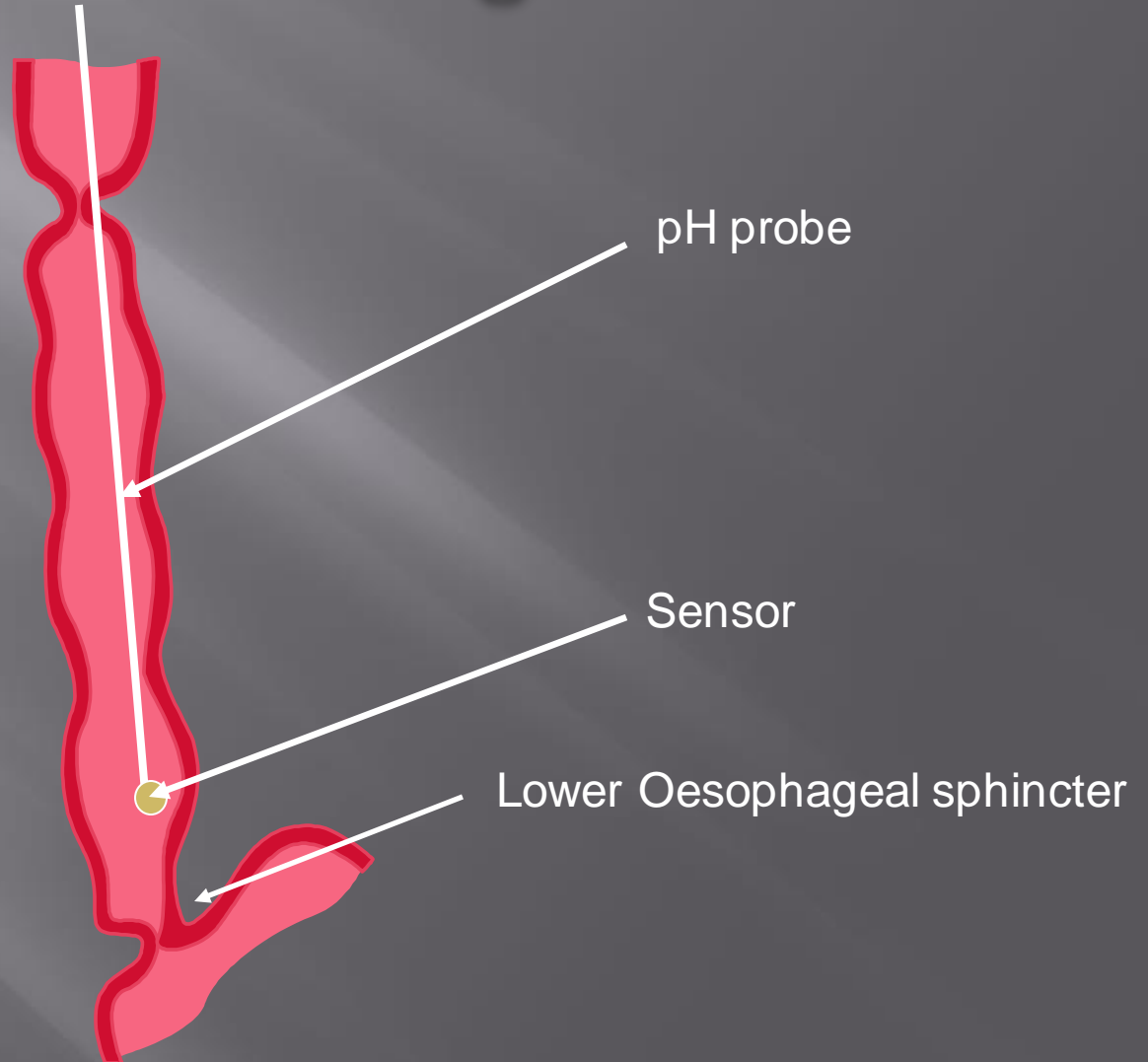
Barium Swallow



Endoscopy



24 hrs esophageal PH monitoring



Gastro-esophageal Reflux disease

GERD

- ▣ The flow back of the gastric content into the esophagus at a rate more than the physiological one .
- ▣ Physiologic reflux episodes typically occur postprandially, are short-lived, asymptomatic, and rarely occur during sleep.
- ▣ High prevalence in the general population.
- ▣ There is failure of anti-reflux mechanism.

GERD pathophysiology

- ▣ Reflects an imbalance between injurious and defensive factors.
- ❖ GEJ incompetence:
 - Transient LES relaxations (TLESRs)
 - A hypotensive LES [fat, chocolate, caffeine, alcohol, smoking, and several drugs (eg, anticholinergics, nitrates, calcium channel blockers, tricyclic antidepressants, opioids, diazepam)]
 - Anatomic disruption of the GEJ, often associated with a hiatal hernia or increased intra-abdominal pressure.

GERD pathophysiology

- ❖ Characteristics of the refluxate
- ❖ Impaired esophageal acid clearance (impaired motility, diminished salivation).
- ❖ Impaired defense against epithelial injury
- ❖ Esophageal hypersensitivity

Clinical Features

- ▣ Regurgitation.
- ▣ Heart burn.
- ▣ Chest pain.
- ▣ Dysphagia
- ▣ Nausea
- ▣ Hoarseness, cough, wheezes

Complications

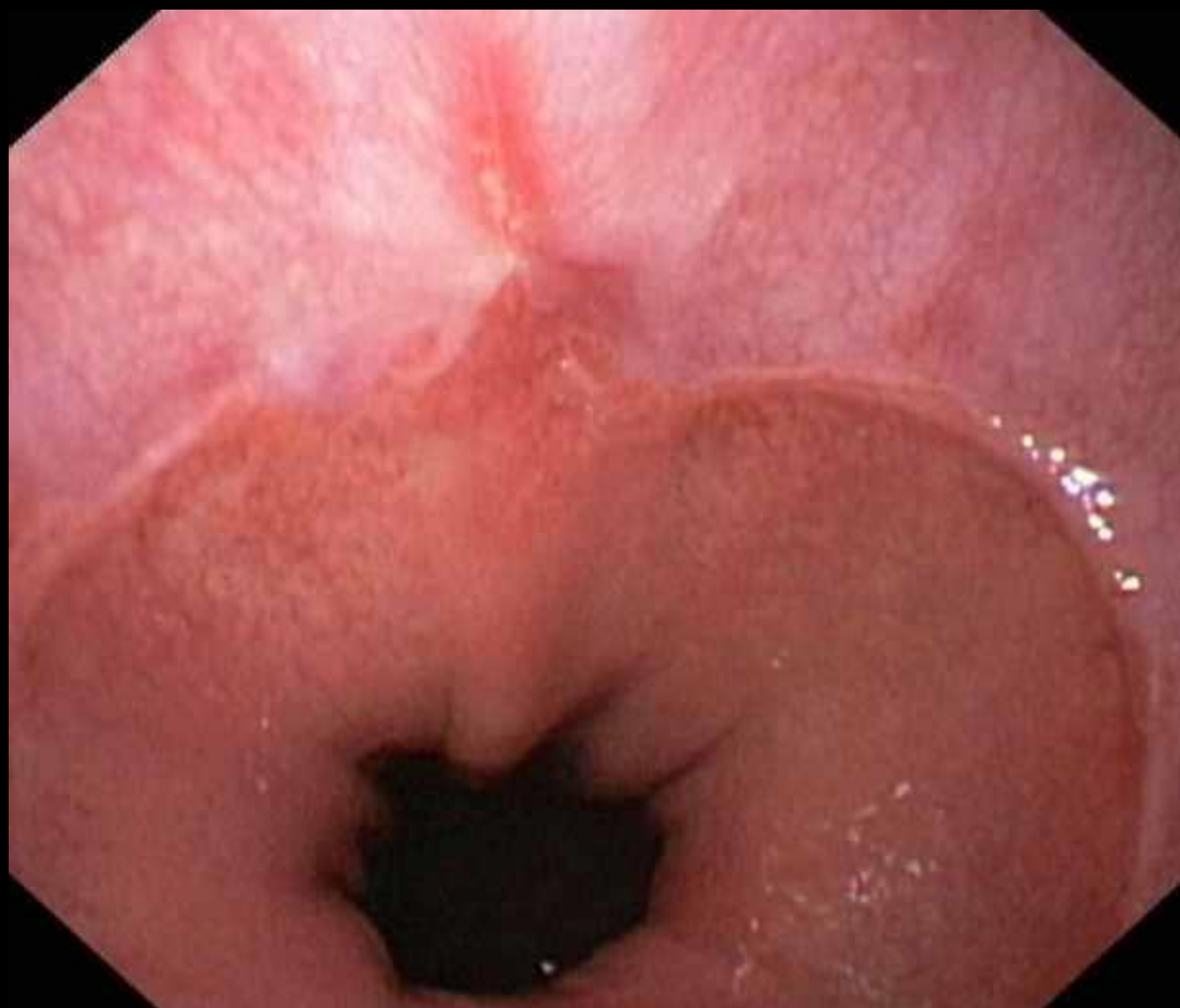
- ▣ Esophageal stricture
- ▣ Barrett's esophagus
- ▣ Esophageal adenocarcinoma
- ▣ Chronic laryngitis
- ▣ Exacerbation of asthma

Diagnosis

- ▣ Barium Swallow.
- ▣ Endoscopy.
- ▣ **24 hrs PH monitoring.**
- ▣ Laryngoscopy.
- ▣ High resolution Manometry & Impedence.

Treatment

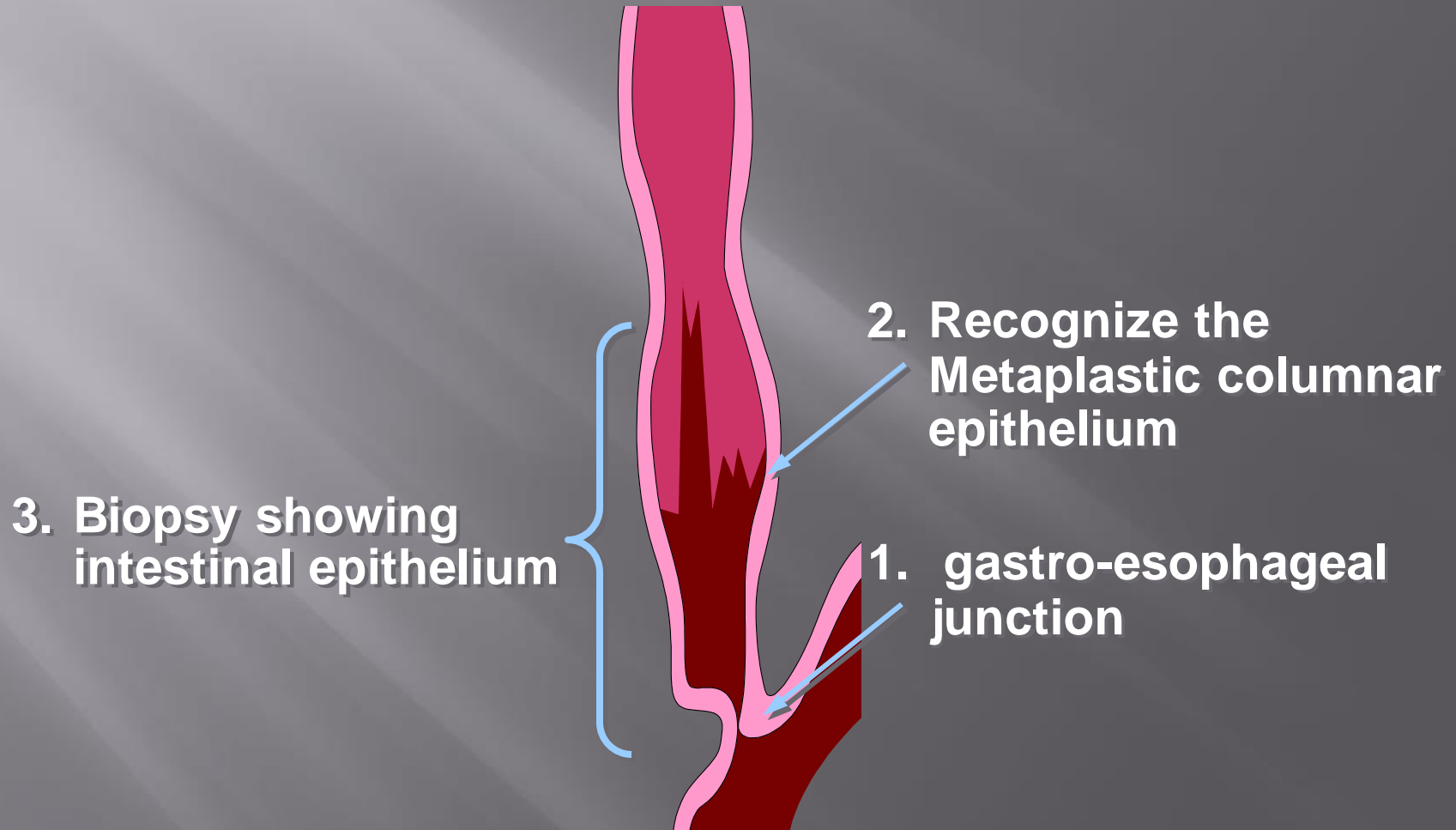
- ▣ Life style modification
- ▣ H2 receptors blockers
- ▣ PPI.
- ▣ Fundoplication.



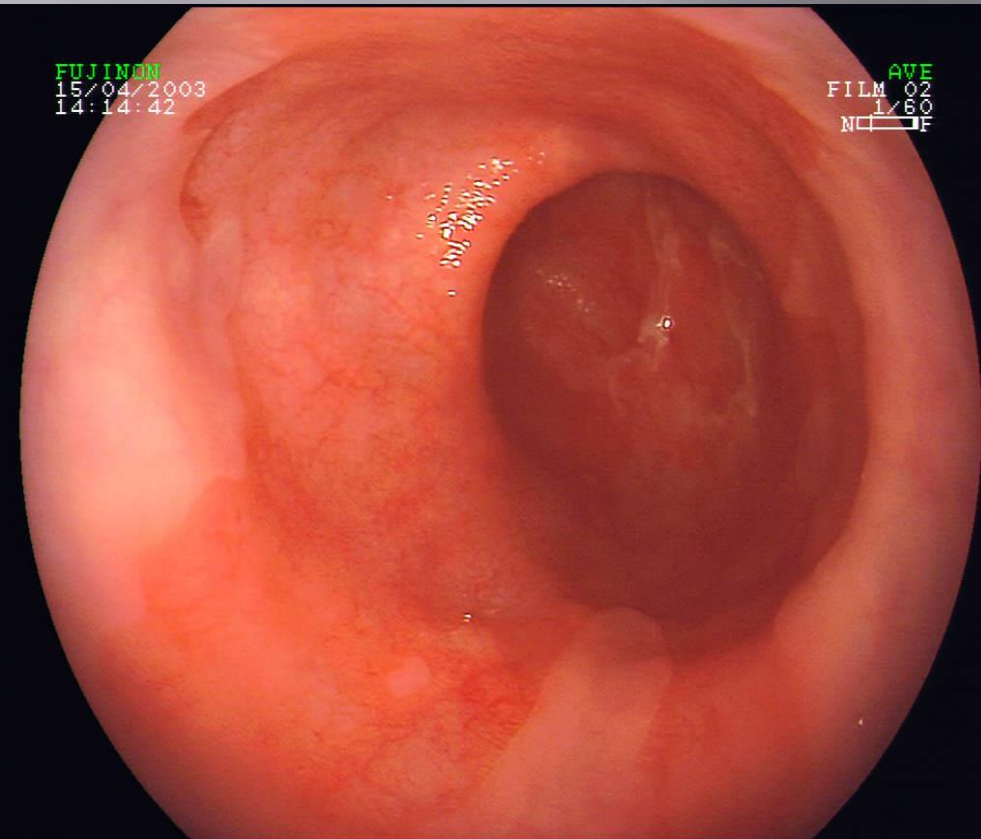
Barrett's esophagus

- ▣ As a result of chronic GERD
- ▣ Metaplastic columnar epithelium replaces the stratified squamous epithelium in the distal esophagus.
- ▣ There is increased risk of adenocarcinoma which is >30-fold above that of the general population (annual cancer incidence 0.1-3%).

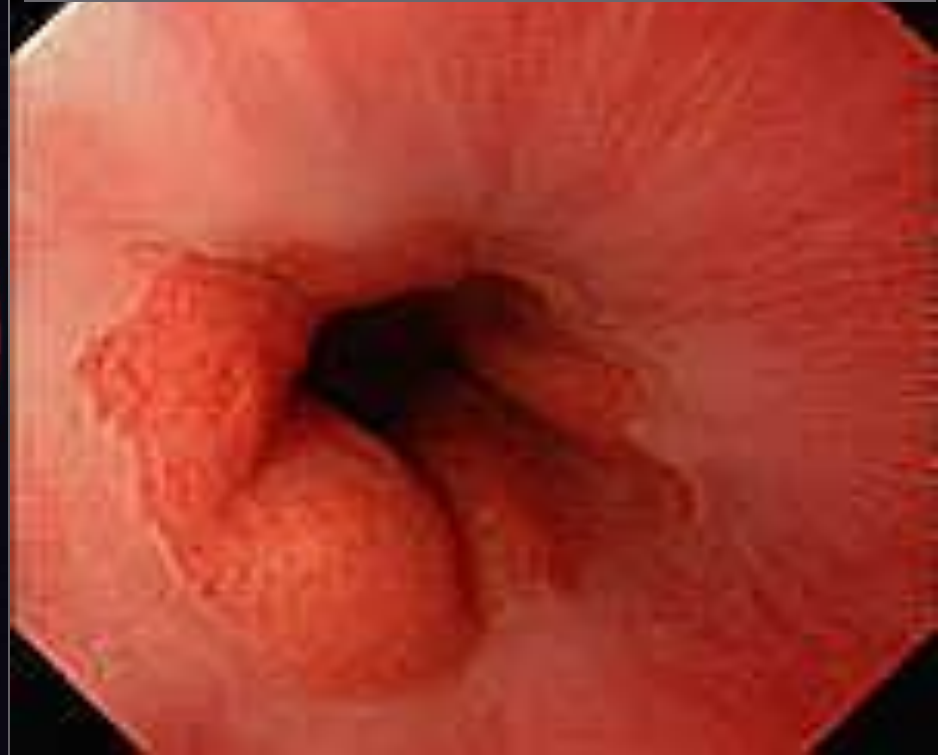Diagnosis



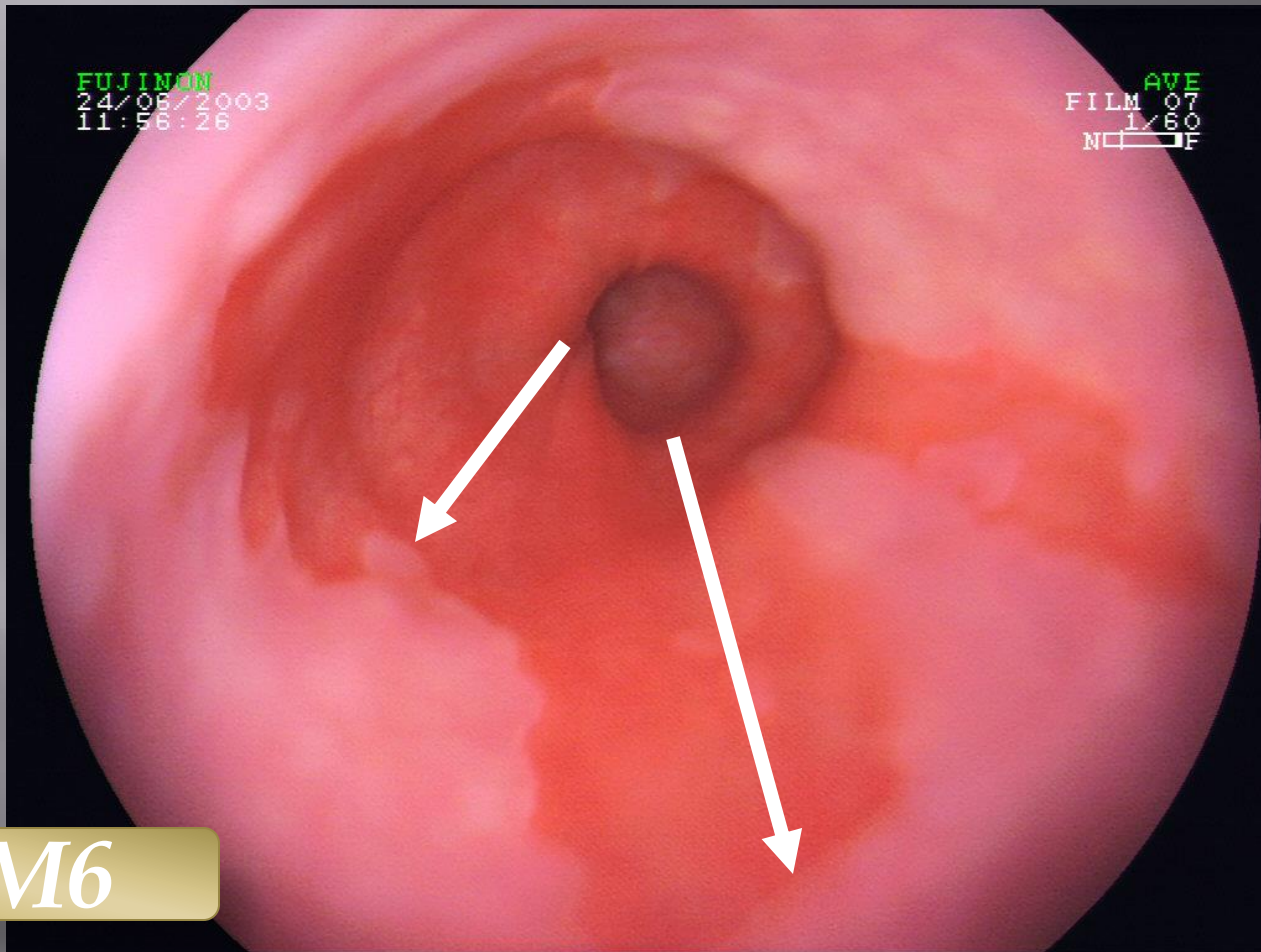
Gastro-Esophageal Junction and Barrett's Esophagus



Normal Gastro-esophageal Junction



Prague Classification



C3M6

Treatment

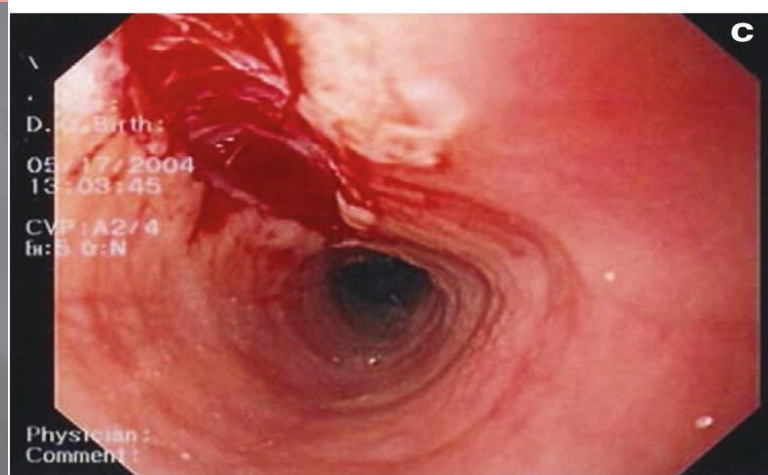
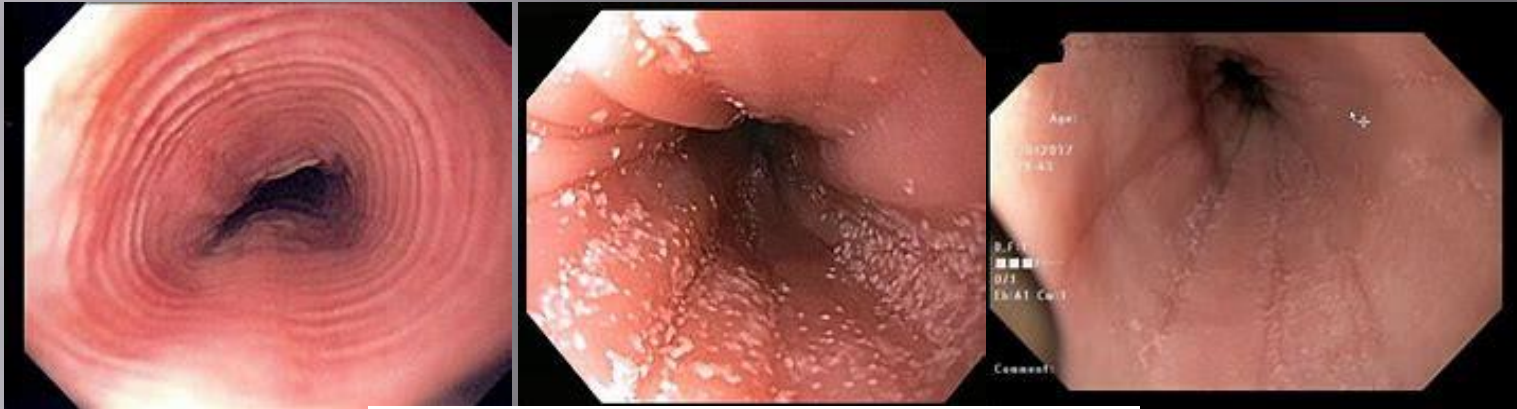- ▣ Treat GERD
- ▣ Surveillance for dysplasia
- ▣ Endoscopic therapy for dysplasia (ablation, resection)
- ▣ Surgery-esophagectomy

Eosinophilic Esophagitis

EoE

- ▣ A chronic, immune/antigen-mediated, esophageal disease characterized clinically by symptoms related to esophageal dysfunction and histologically by eosinophil-predominant inflammation(>15 /HPF).
- ▣ Symptoms: dysphagia, food impaction, refractory heartburn, feeding difficulties and abdominal pain.
- ▣ Strongly associated with allergic conditions

Eosinophilic Esophagitis EoE



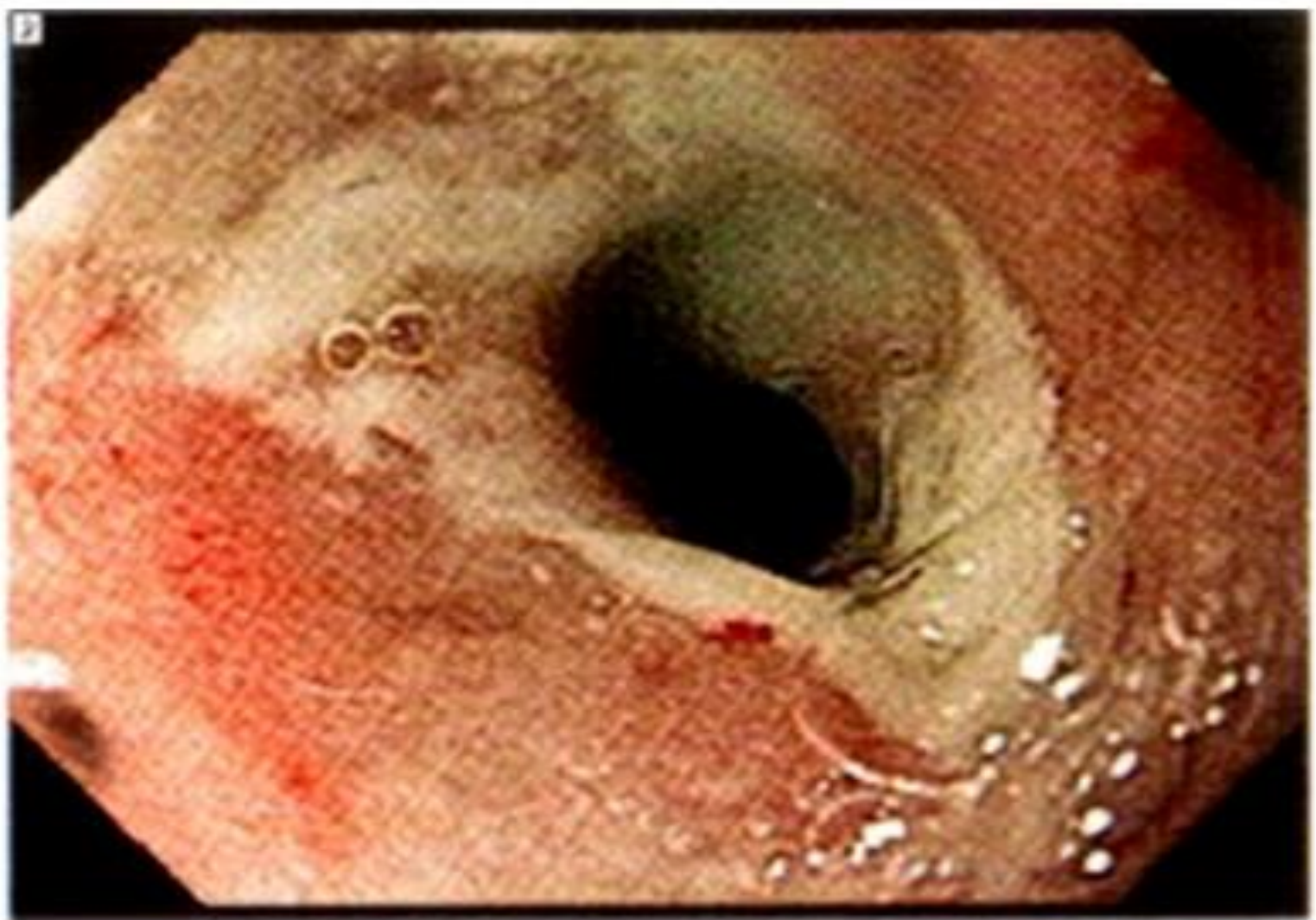
Eosinophilic Esophagitis

EoE

- ▣ Treatment:
 - PPI
 - Topical glucocorticoid
 - Dietary therapy
 - Endoscopic dilatation

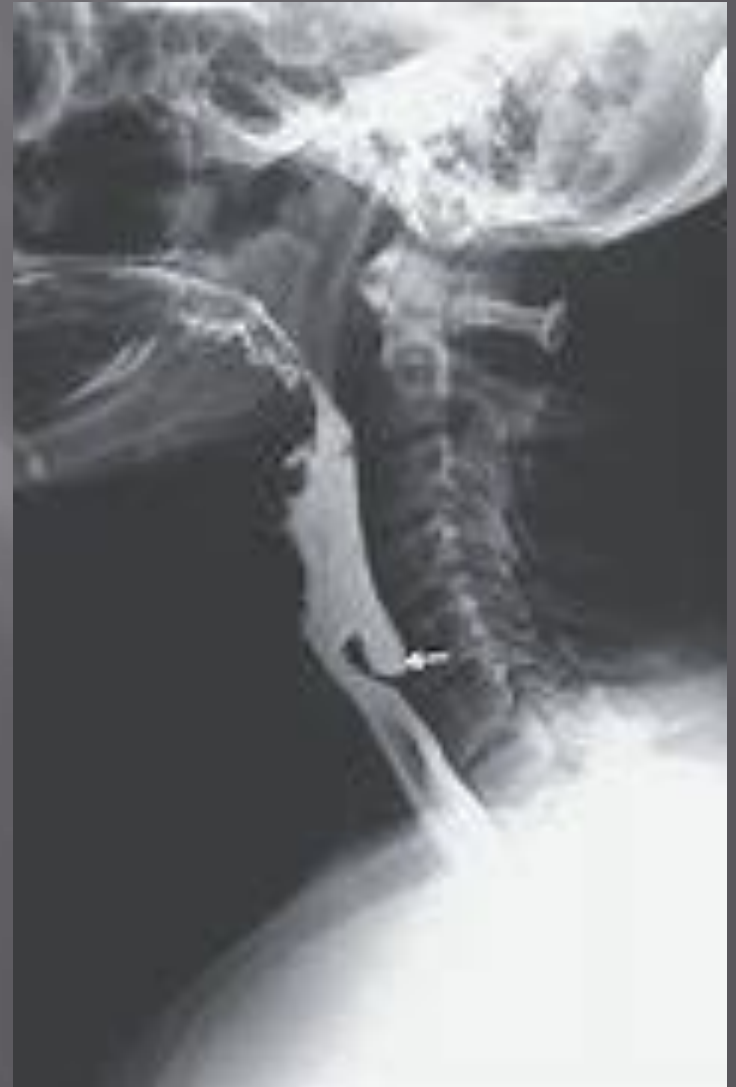Corrosive esophagitis

- ▣ Caused by ingestion of strong alkali or acid.
- ▣ May cause severe ulceration and end up in fibrosis and stricture formation.



Zenker's Diverticulum

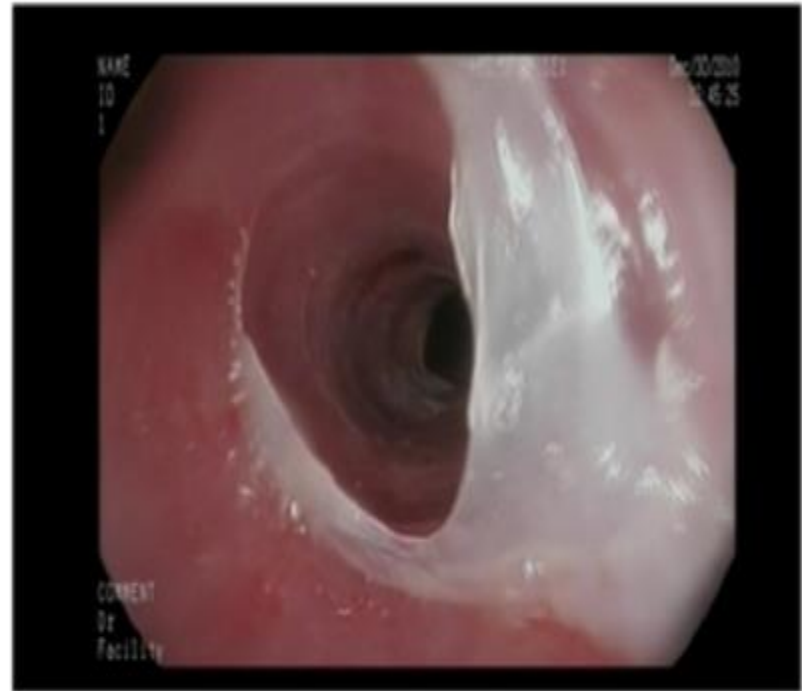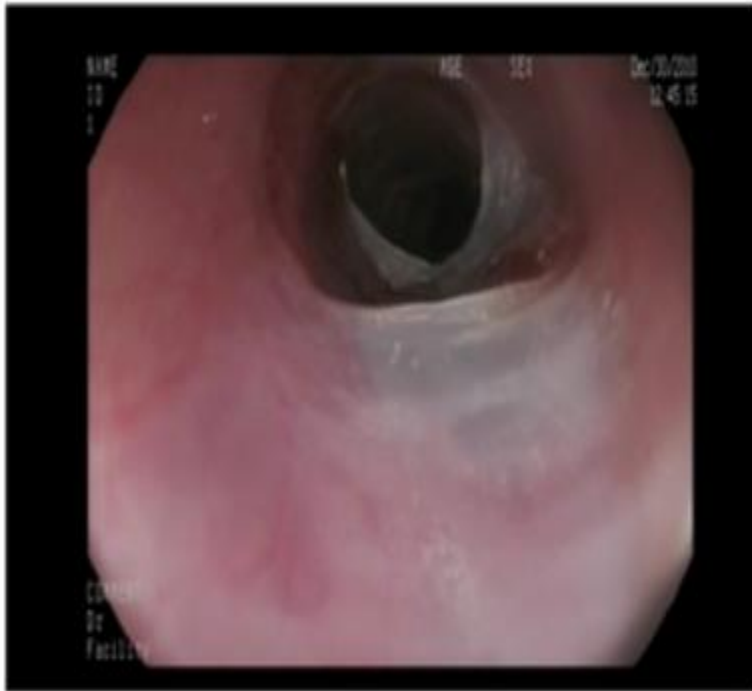- ▣ Occurs in the posterior hypopharyngeal wall.
- ▣ A false diverticulum
- ▣ Dysphagia, halitosis and food regurgitation.
- ▣ Treatment by cricopharyngeal myotomy+ diverticulectomy



Esophageal Webs

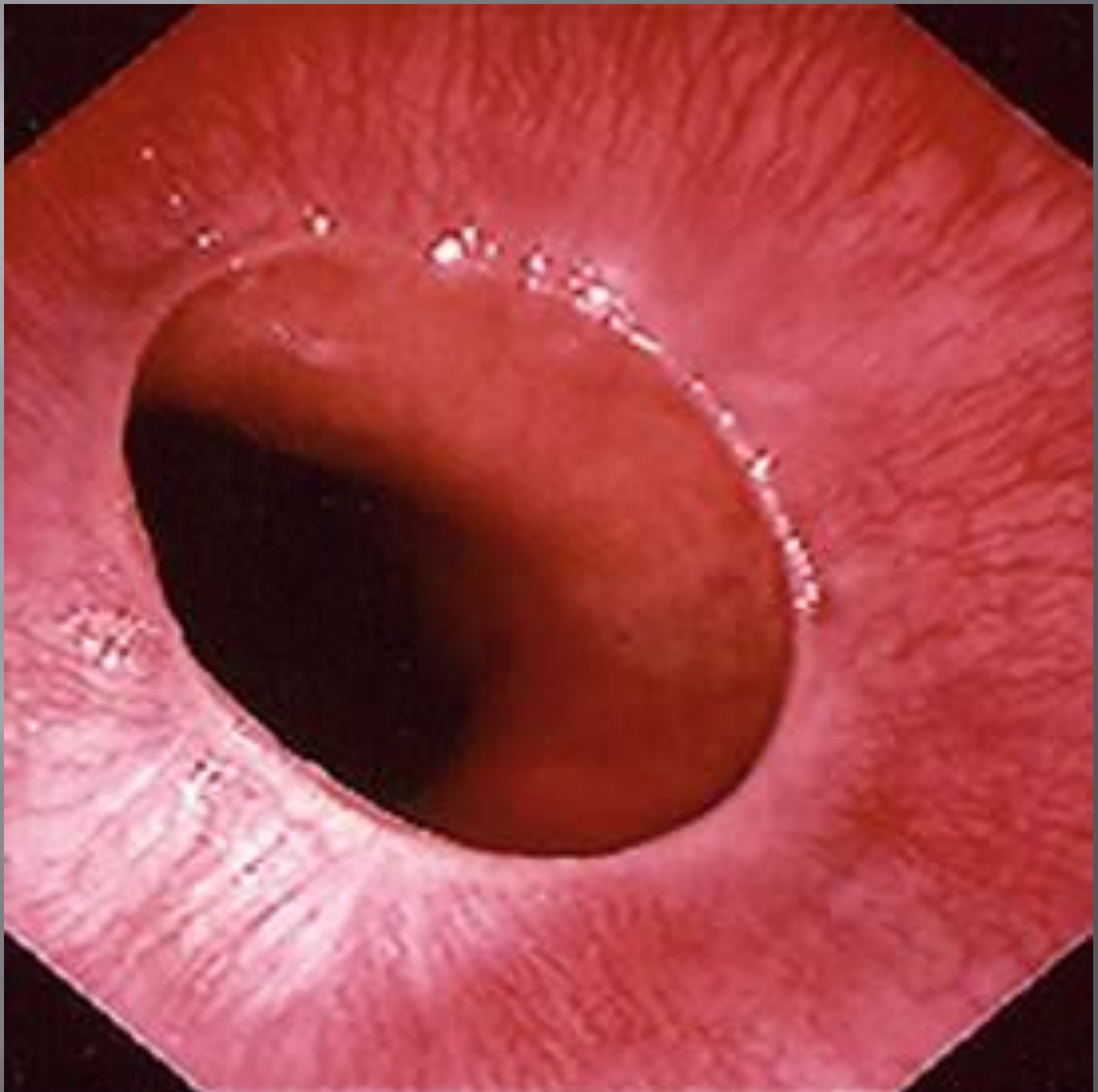- ▣ Congenital or inflammatory constrictions usually in the hypopharynx .
- ▣ May cause dysphagia.
- ▣ May be associated with iron deficiency anemia (Plummer-Vinson syndrome)
- ▣ Treatment by dilatation.

Esophageal Webs



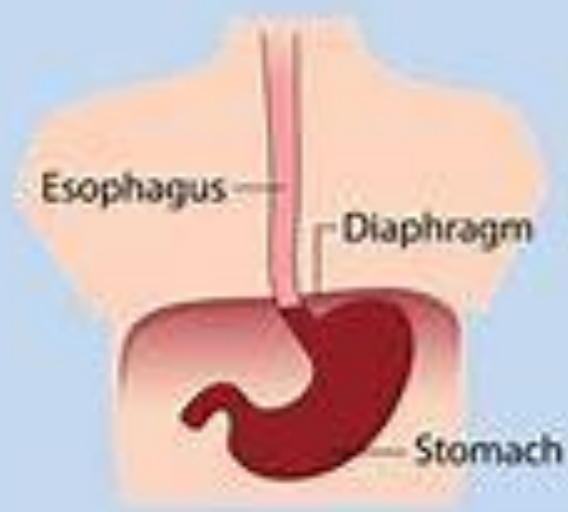Schatzki Ring

- ▣ Thin constriction at the Squamo-columinar junction.
- ▣ Common cause for dysphagia and underlies food bolus obstruction.
- ▣ Treated by dilatation.

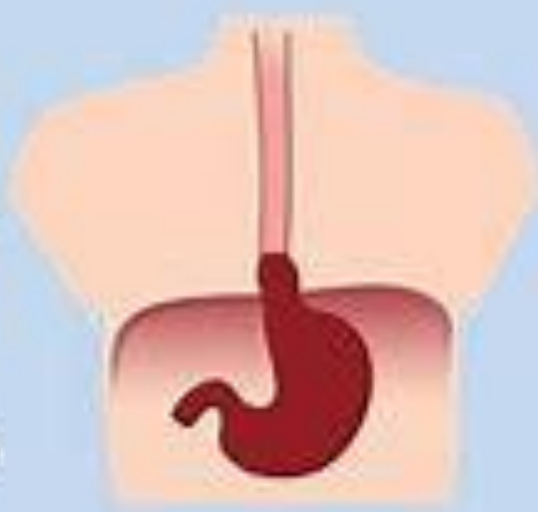

Hiatus Hernia

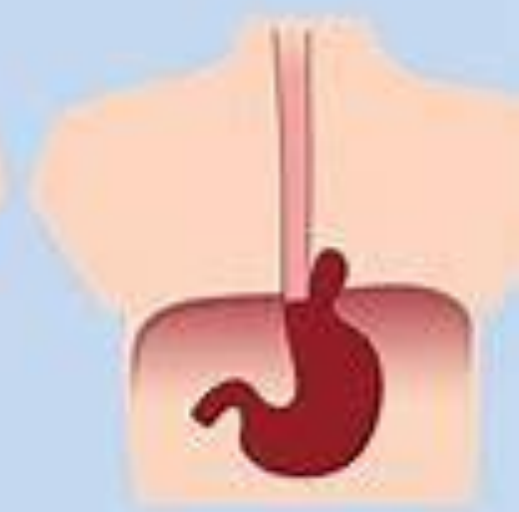- ▣ Sliding : the GE junction and part of the fundus lie in the thoracic cavity.
 - May contribute to GERD
- ▣ Para-esophageal hernia: part of the stomach is herniated beside the GE junction which is normally located.
 - May incarcerate, ulcerate or cause dysphagia.



Normal



Sliding hiatus hernia

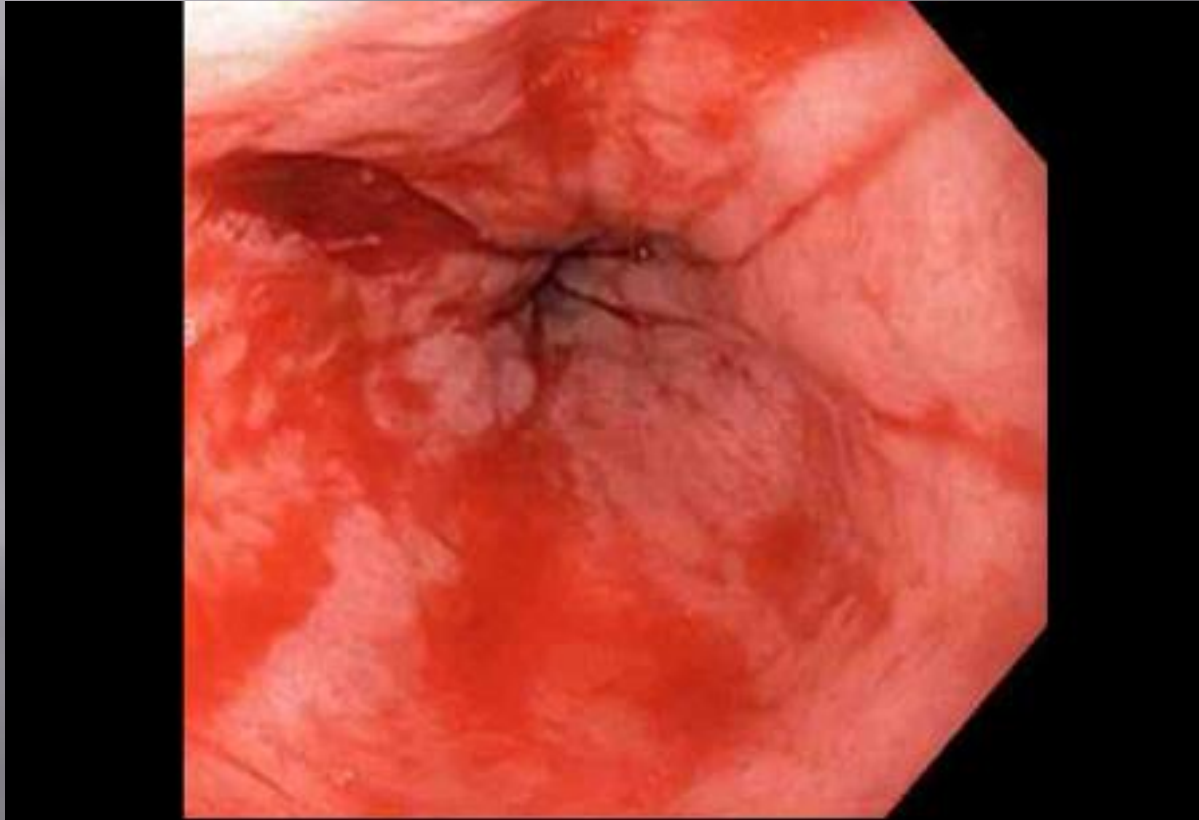


*Paraesophageal
hiatus hernia*

Mallory-Weiss Syndrome

- ▣ Usually preceded by vomiting and retching.
- ▣ Tear at the gastro-esophageal junction.
- ▣ Patients presents with upper GI bleeding
- ▣ Most cases resolves spontaneously.

Mallory Weiss syndrome



Esophageal motility disorders

Achalasia

- ▣ There is failure of relaxation of the lower esophageal sphincter.
- ▣ There is non peristaltic contractions in the body of the esophagus.
- ▣ It results from progressive degeneration of inhibitory ganglion cells (neurons) in the myenteric plexus in the esophageal wall.

Achalasia

- ▣ Psuedoachalasia or secondary causes of achalasia include:

- Gastric carcinoma**

- Amyloidosis

- Sarcoidosis

- Chagas disease

- Eosinophilic esophagitis

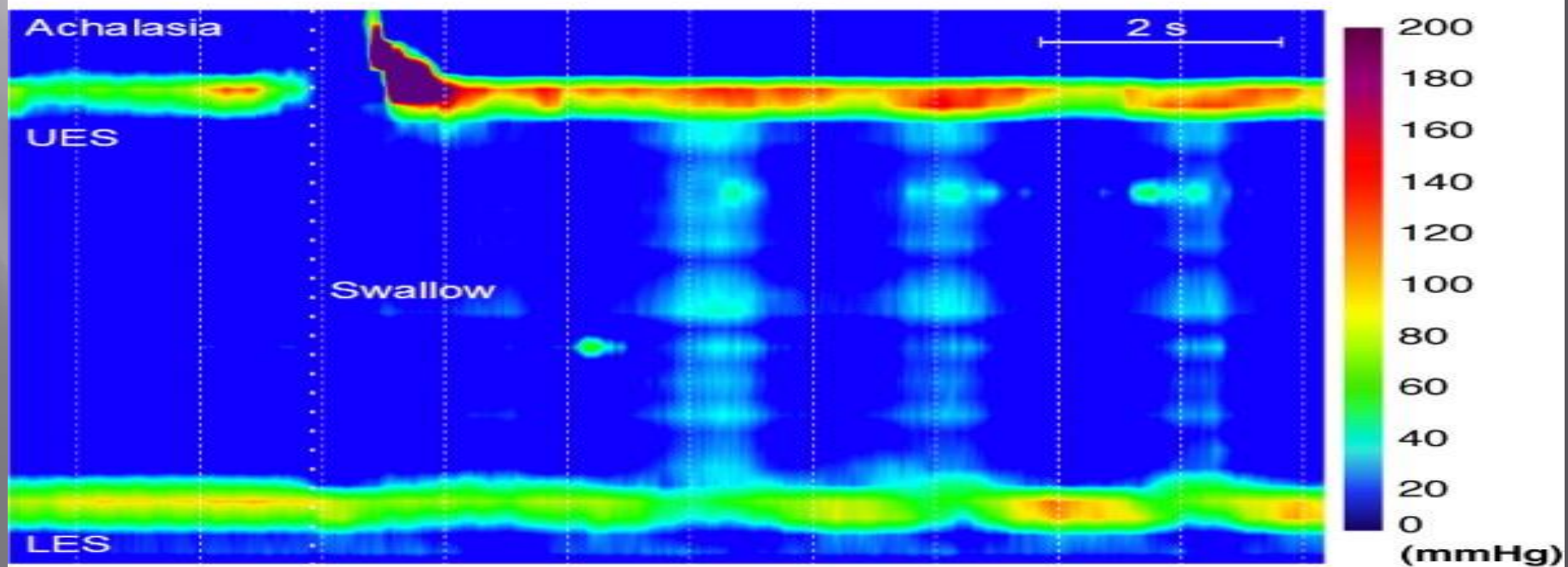
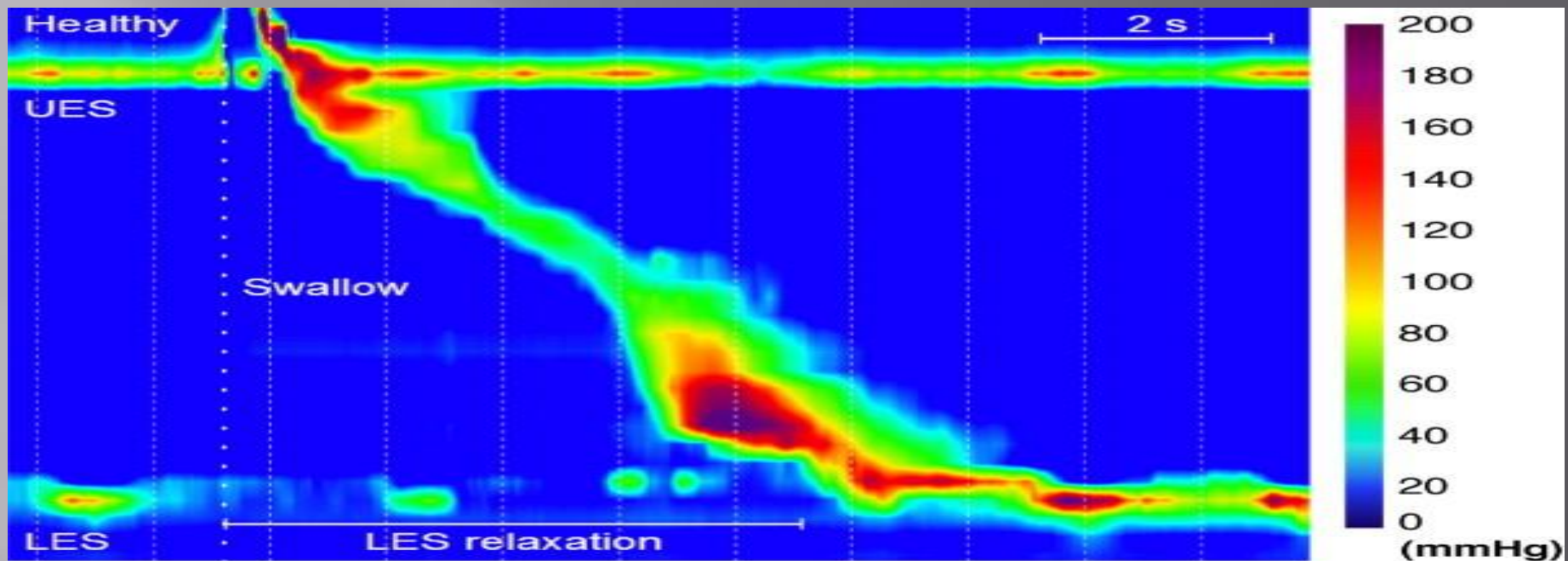
- Neurofibromatosis

Clinical Features

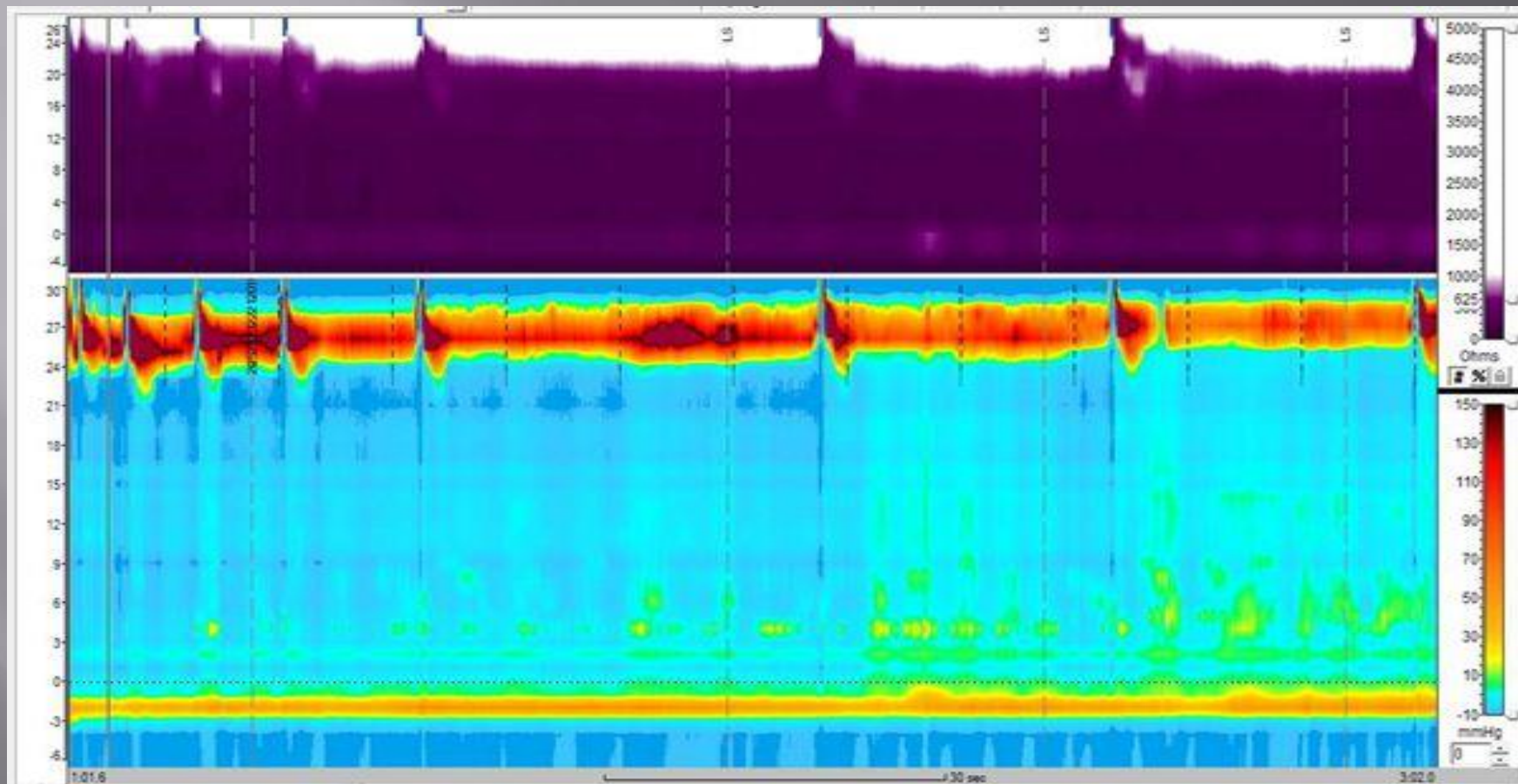
- ▣ Dysphagia.
- ▣ Chest pain.
- ▣ Regurgitation.
- ▣ Difficulty in belching.

Diagnosis

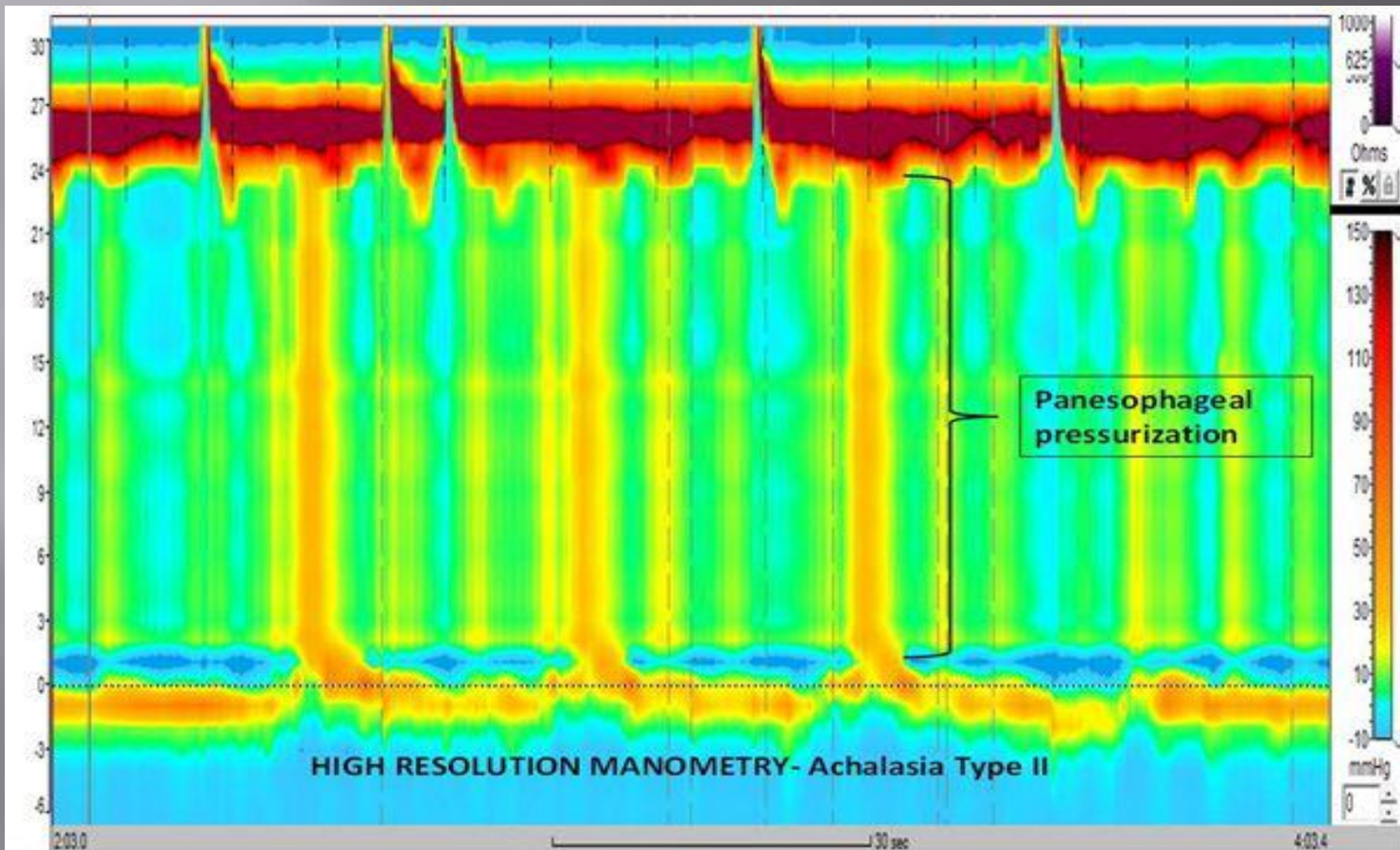
- ▣ Symptoms and signs.
- ▣ CXR: Absence of gastric bubble
 - Air fluid level
 - Widening of mediastinum
- ▣ Barium swallow:
 - Dilated esophagus
 - Bird-beak narrowing in the lower end
 - Absent peristalsis



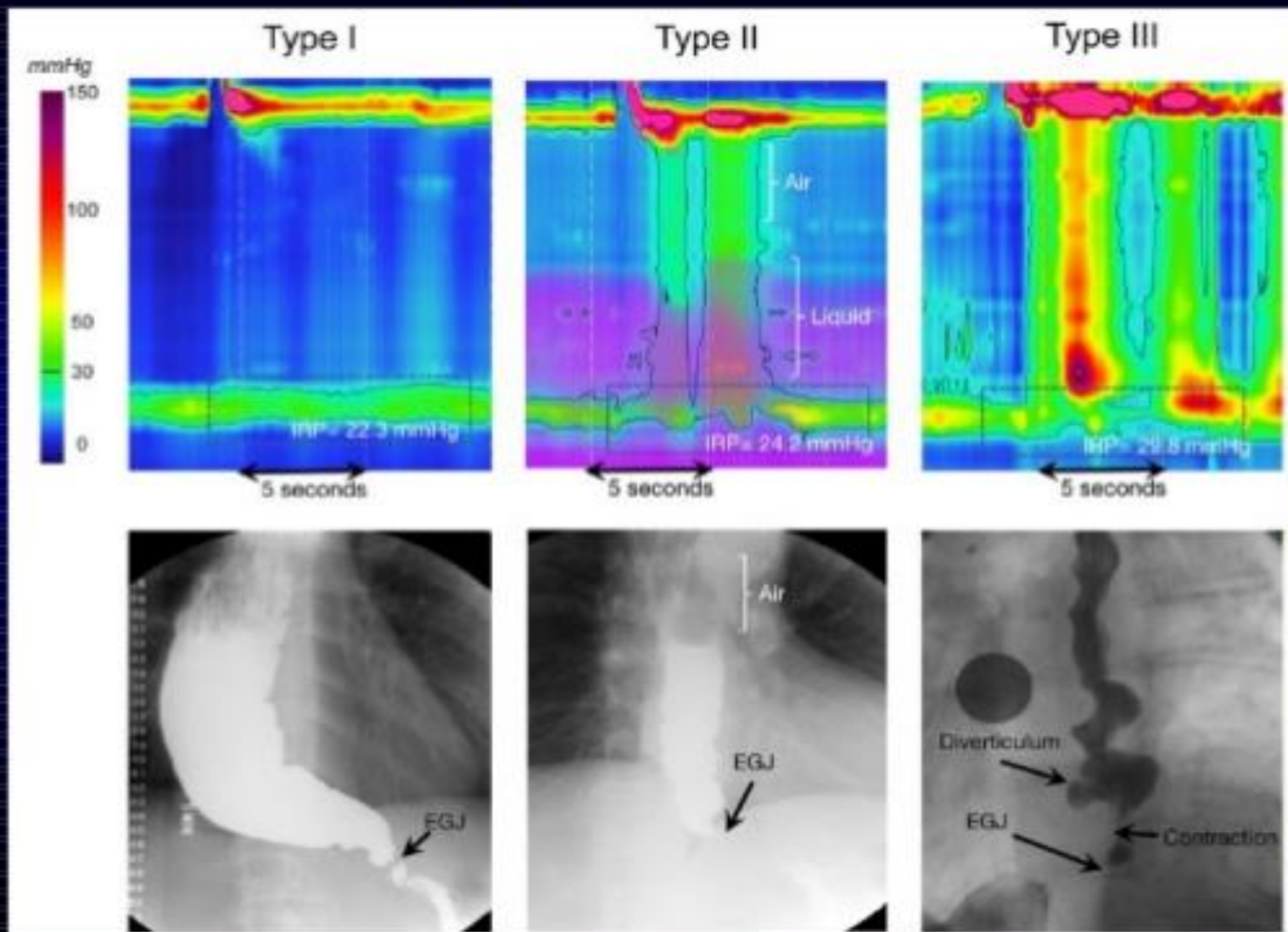
Achalasia Type I

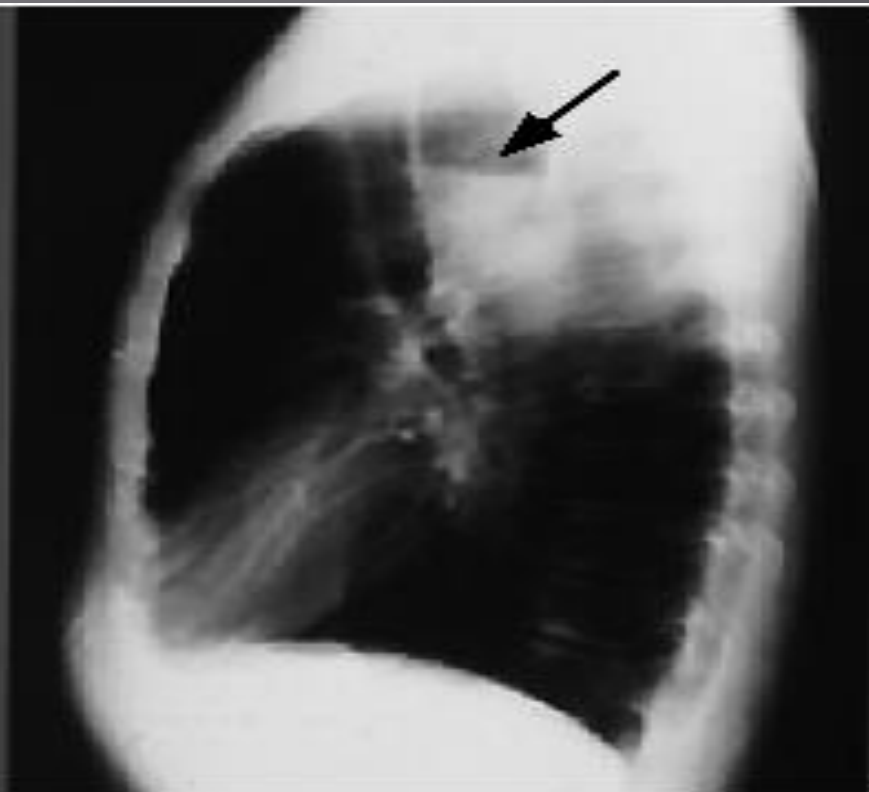
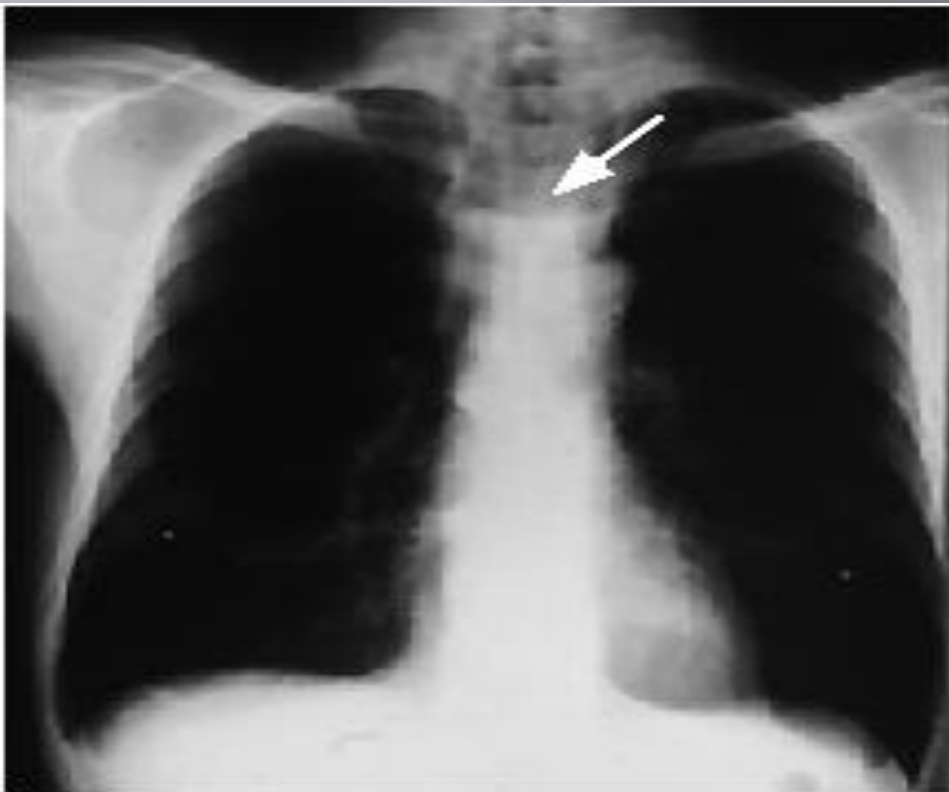
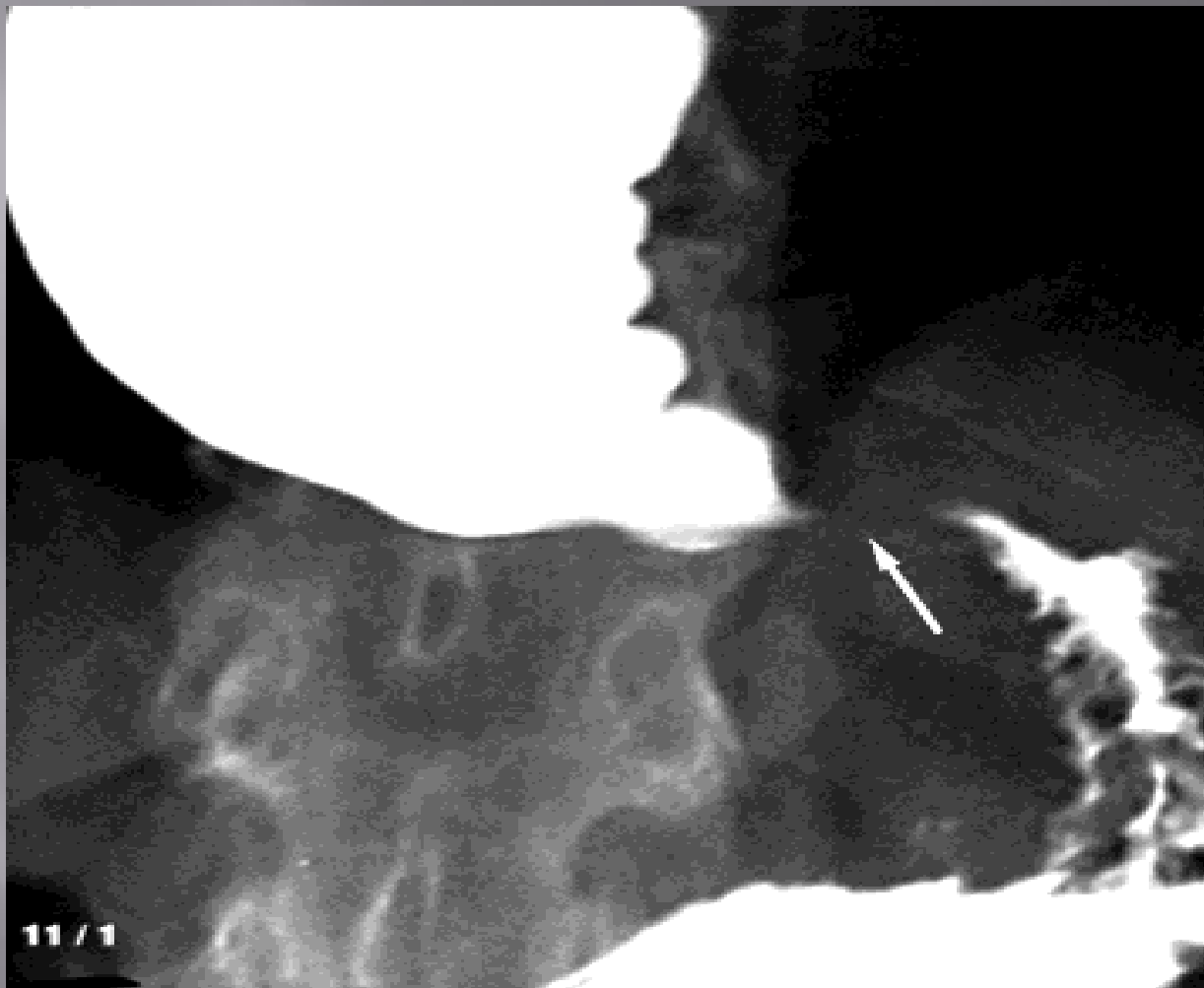Achalasia Type II



Chicago Classification







Achalasia Barium swallow in a 62 year old man demonstrates a dilated barium-filled esophagus with a region of persistent narrowing (arrow) at the GE junction, producing the so-called birds beak appearance. Achalasia was confirmed with manometry and the patient underwent successful dilation of the esophagus. Courtesy of Jonathan Kruskal, MD.

Diagnosis

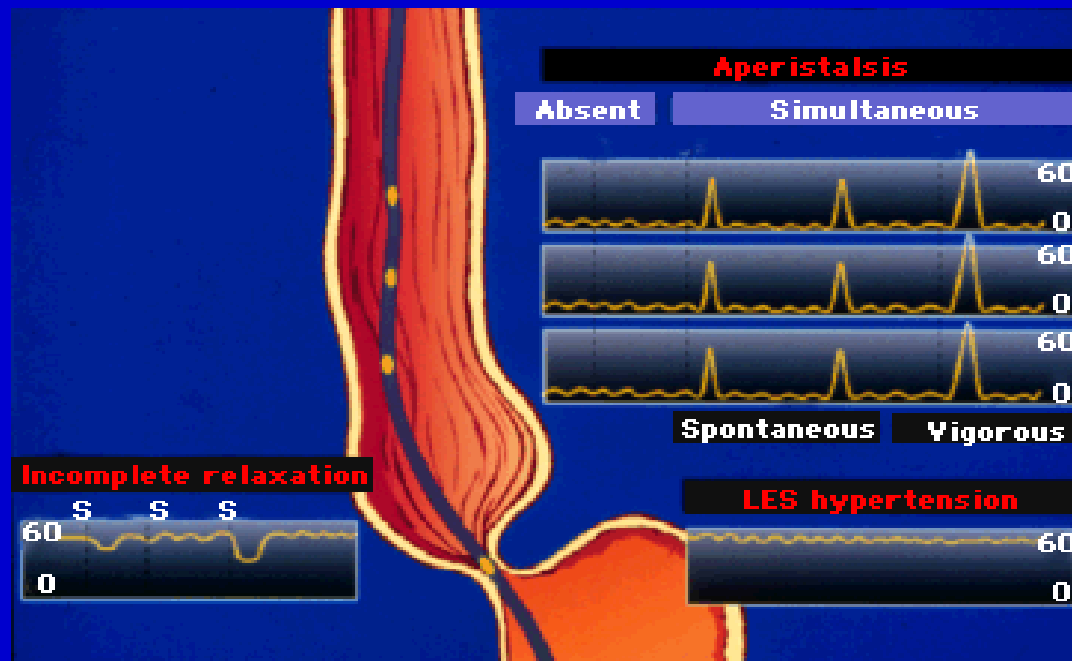
- ▣ Manometry:

- Failure of relaxation of the LES during swallowing.

- Normal or elevated resting LES pressure

- Aperistalsis in the body of esophagus

- Simultaneous esophageal body contractions with amplitudes >40 mmHg



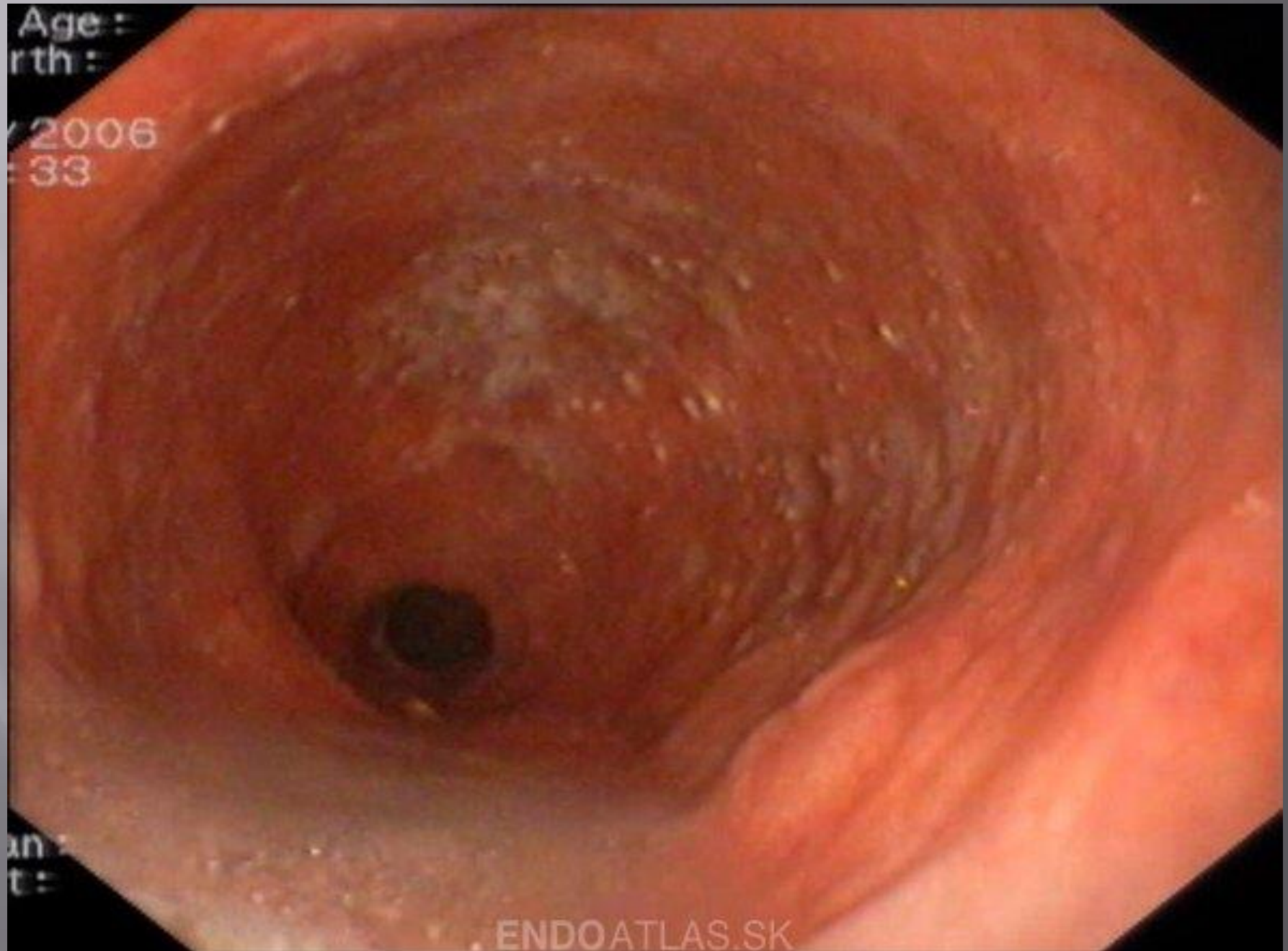Manometric features of achalasia There are three characteristic manometric features of achalasia: elevated resting lower esophageal sphincter (LES) pressure (above 45 mmHg); incomplete LES relaxation after a swallow (S); aperistalsis in the smooth muscle portion of the body of the esophagus. Swallows may elicit no esophageal contraction or may be followed by simultaneous contractions. The esophagus may also contract spontaneously in a simultaneous fashion. In some cases, the simultaneous esophageal contractions have amplitudes >60 mmHg, a condition known as "vigorous" achalasia. Reprinted, courtesy of the Clinical Teaching Project of the American Gastroenterological Association®. This slide cannot be downloaded but may be purchased as part of a set from the AGA through Milner-Fenwick, Inc. at 1-800-432-8433.

Endoscopy

- ▣ Dilated lumen contains food and fluid
- ▣ Narrow sphincter with resistance to the passage of the endoscope.
- ▣ Important to exclude secondary causes.

Age :
rth :
2006
33

an :
t :



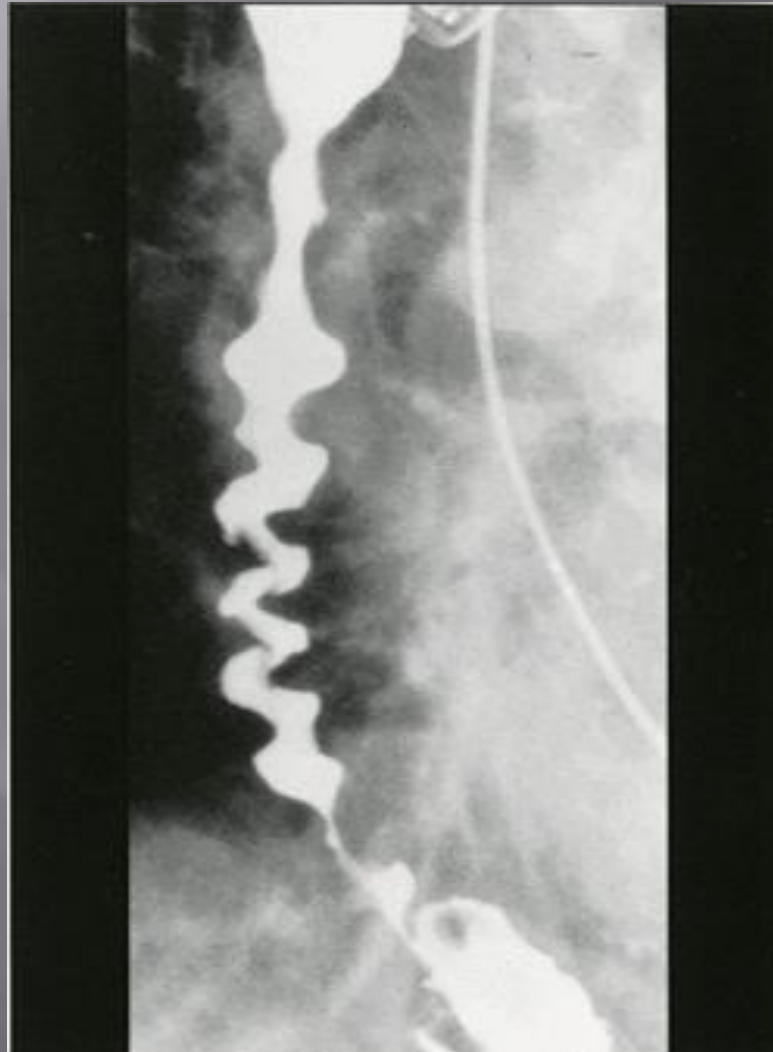
Treatment

- ▣ Aim is to decrease LES pressure to allow food to pass down.
- ▣ Mechanical disruption of the muscle fibers of the LES :
 - Endoscopic balloon dilatation.
 - Peroral endoscopic myotomy (POEM)
 - Hellers extramucosal myotomy.
- ▣ Pharmacological reduction in LES pressure
 - Botulinum toxin injection
 - Oral nitrates and calcium channel blockers

Distal esophageal spasm

- ▣ Dysphagia, chest pain, heartburn
- ▣ Due to impaired inhibitory innervation. May also be induced by acid exposure.
- ▣ Premature, simultaneous and rapidly propagated contractions in the distal esophagus >20% of swallows on manometry
- ▣ "rosary bead" or "corkscrew" appearance of the esophagus on barium esophagram
- ▣ Treatment with PPI, peppermint oil, Ca-channel blocker

Distal esophageal spasm

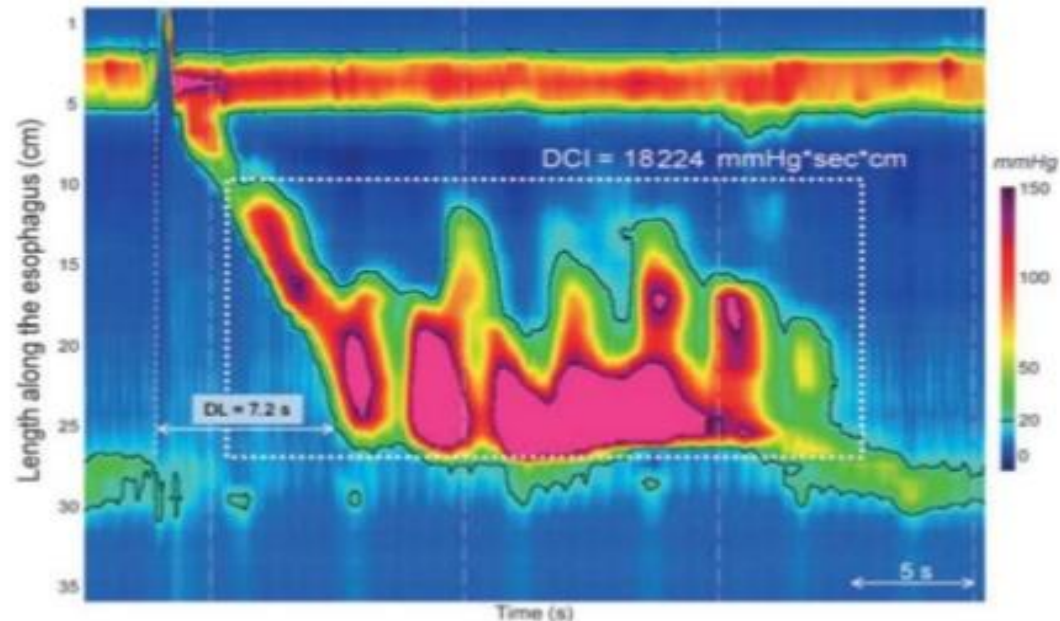


Jackhammer esophagus

- ▣ May be due to excessive excitation, smooth muscle hypertrophy and/or smooth muscle response to excitatory nerves
- ▣ Dysphagia, chest pain, heartburn
- ▣ Barium esophagram shows normal sequential peristalsis
- ▣ Characterized by high pressure but normally sequential contractions in the smooth muscle esophagus
- ▣ Treatment with PPI, peppermint oil, Ca-channel blocker

Jackhammer esophagus

Hypercontractile esophagus (jackhammer) restricted to the esophagus



At least two swallows with a $DCI \geq 8000$ mmHg.s.cm

The End