

Adrenal Glands

Ayman Mismar
Associate Prof. of Endocrine Surgery
The University of Jordan

edited by: INSAF AYAD

Anatomy

Adrenal Gland

Anatomy was first described in 1563.

Is located above (or attached to) the upper pole of the kidney.

Is pyramidal in structure and weighs ~ 4 g.

Consists of the adrenal cortex and adrenal medulla

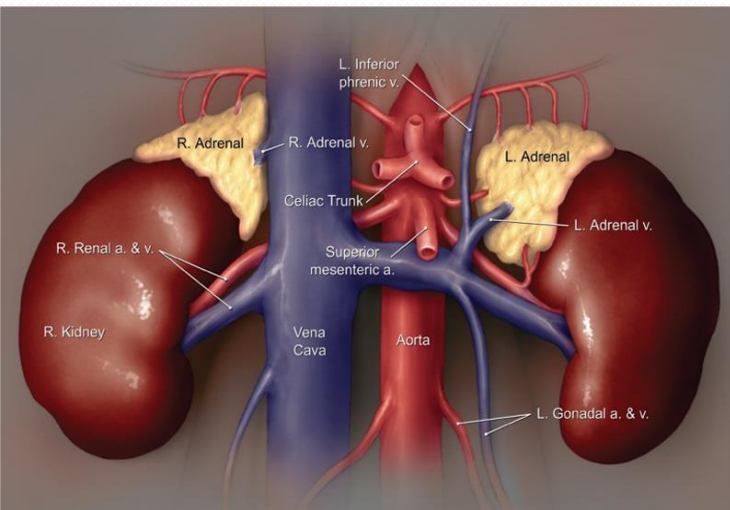
Activities are regulation of fluid volume and stress response

Adrenal Gland

- Blood supply
 - Arterial - receives 7cc/gram minute
- arterial sources of flow:
 1. Inferior phrenic artery
 2. Aorta
 3. Renal artery
- Venous – single main vein most important surgical structure

- right → post IVC
- left → renal vein

(its injury causes 25% of venous blood to go to peritoneal cavity, has 25% of return)

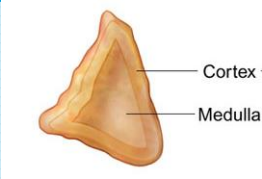



Adrenal Gland

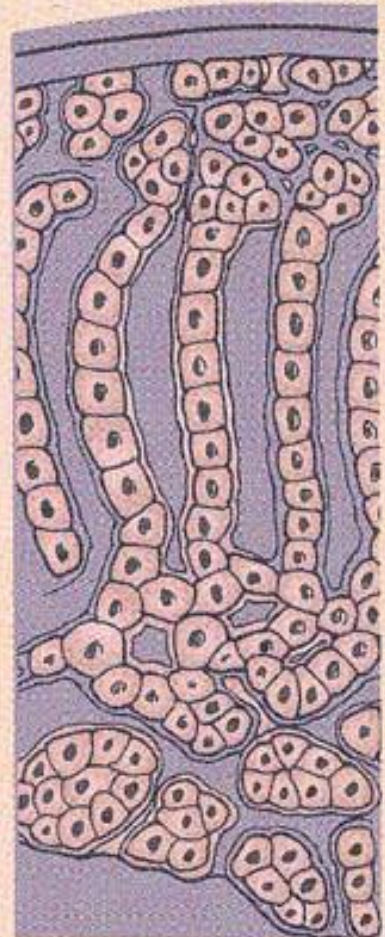
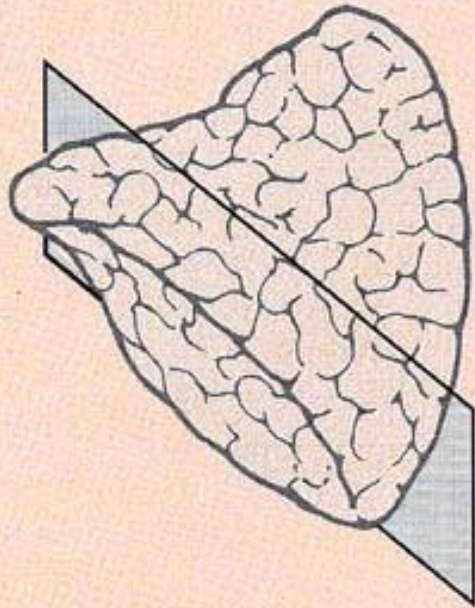
both regulate Stress (Cortex \rightarrow Chronically, medulla \rightarrow acutely)

- Cortex - mesoderm
 secretes cholesterol hormones (aldosterone, glucocorticosteroids, sex), regulated by ant. pituitary
- Medulla - neuroectoderm
 secretes amino acid hormones (epinephrine), regulated by Symp. N
- Renal agenesis, found in normal anatomic position
- Size- 5 x 3 x 1 x 5 cm
- Retroperitoneal structure, contained in its own sub-compartment w/in Gerota's fascia

Comparison between Rt. & Lt. Suprarenals

Right Suprarenal	Left Suprarenal
	
Triangular (pyramidal)	Crescentic (semilunar)
Does NOT reach the hilum of the right kidney	Reaches the hilum of the left kidney
The hilum is directed upwards	The hilum is directed downwards
Its vein is short and drains to the IVC	Its vein is long and drains to the left renal vein.

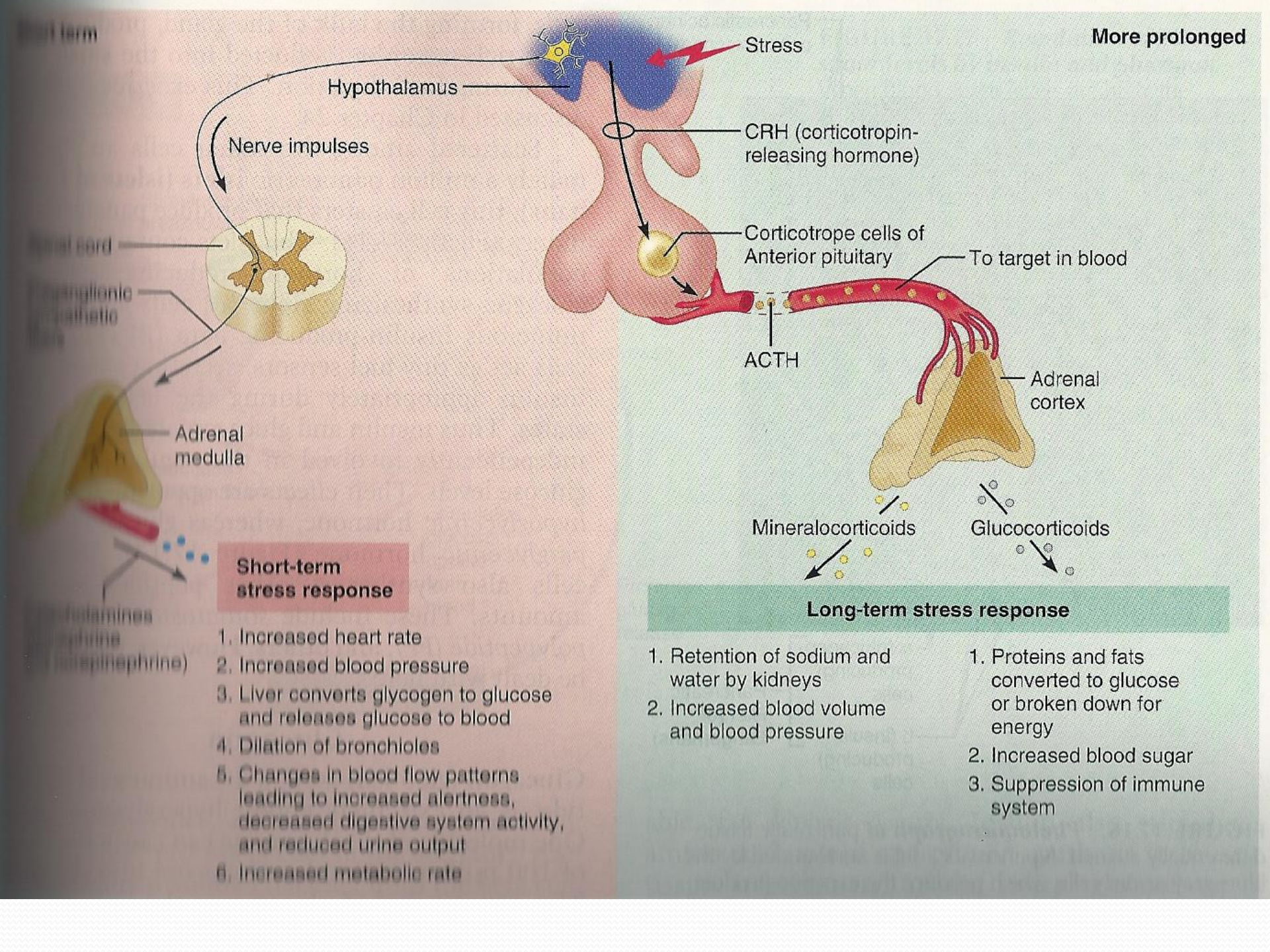
Cross section through adrenal gland



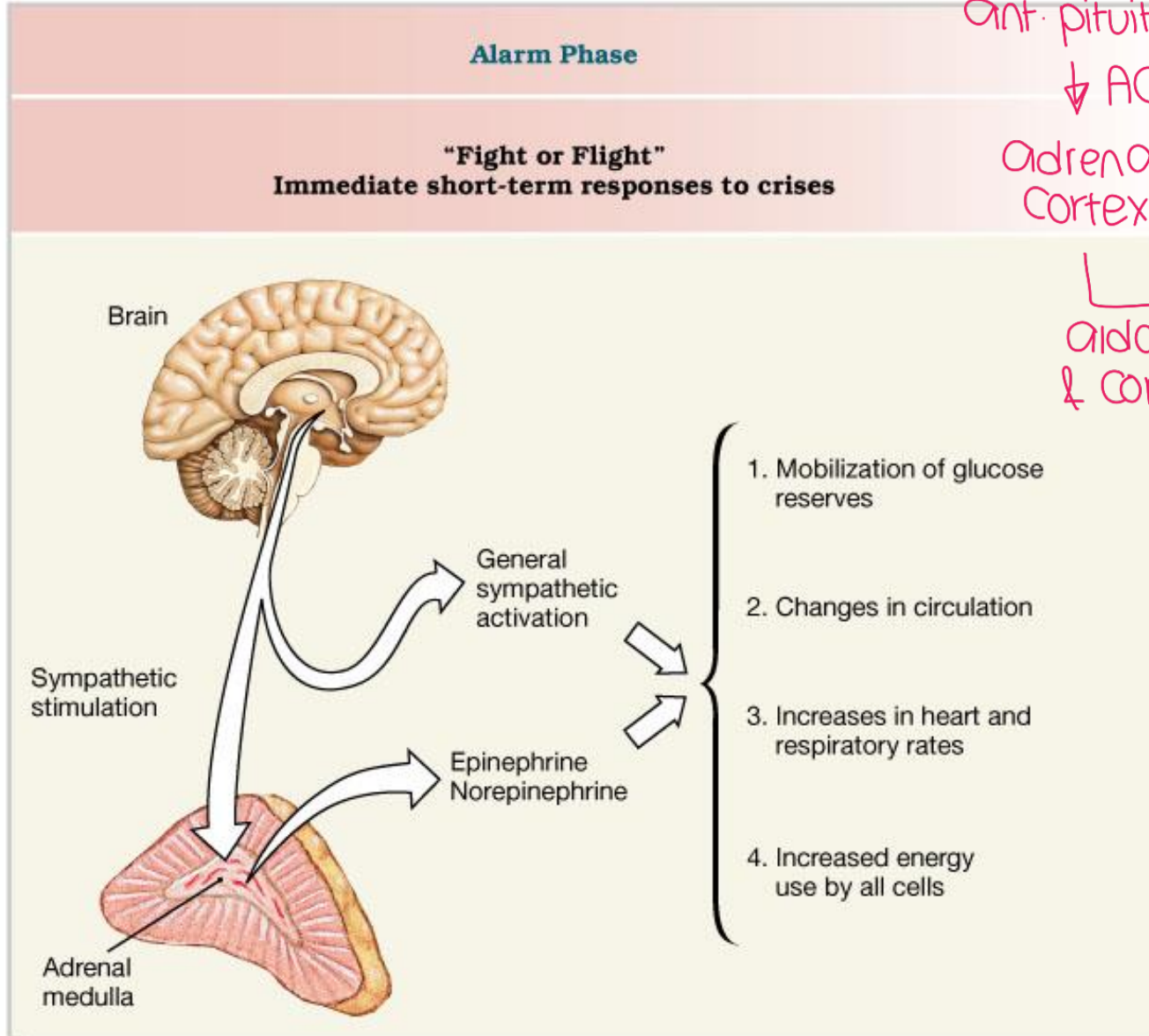
Zones	Main secretory product
Capsule	
Glomerulosa	Aldosterone <i>(maintain IV volume)</i>
Fasciculata	Cortisol
Reticularis	Androgens
Medulla	Epinephrine Norepinephrine

(if a child has androgen secreting tumor \rightarrow $\begin{matrix} \text{♂} \\ \text{precaucious puberty} \end{matrix}$ $\begin{matrix} \text{♀} \\ \text{ambiguous genitalia} \end{matrix}$)

Physiology



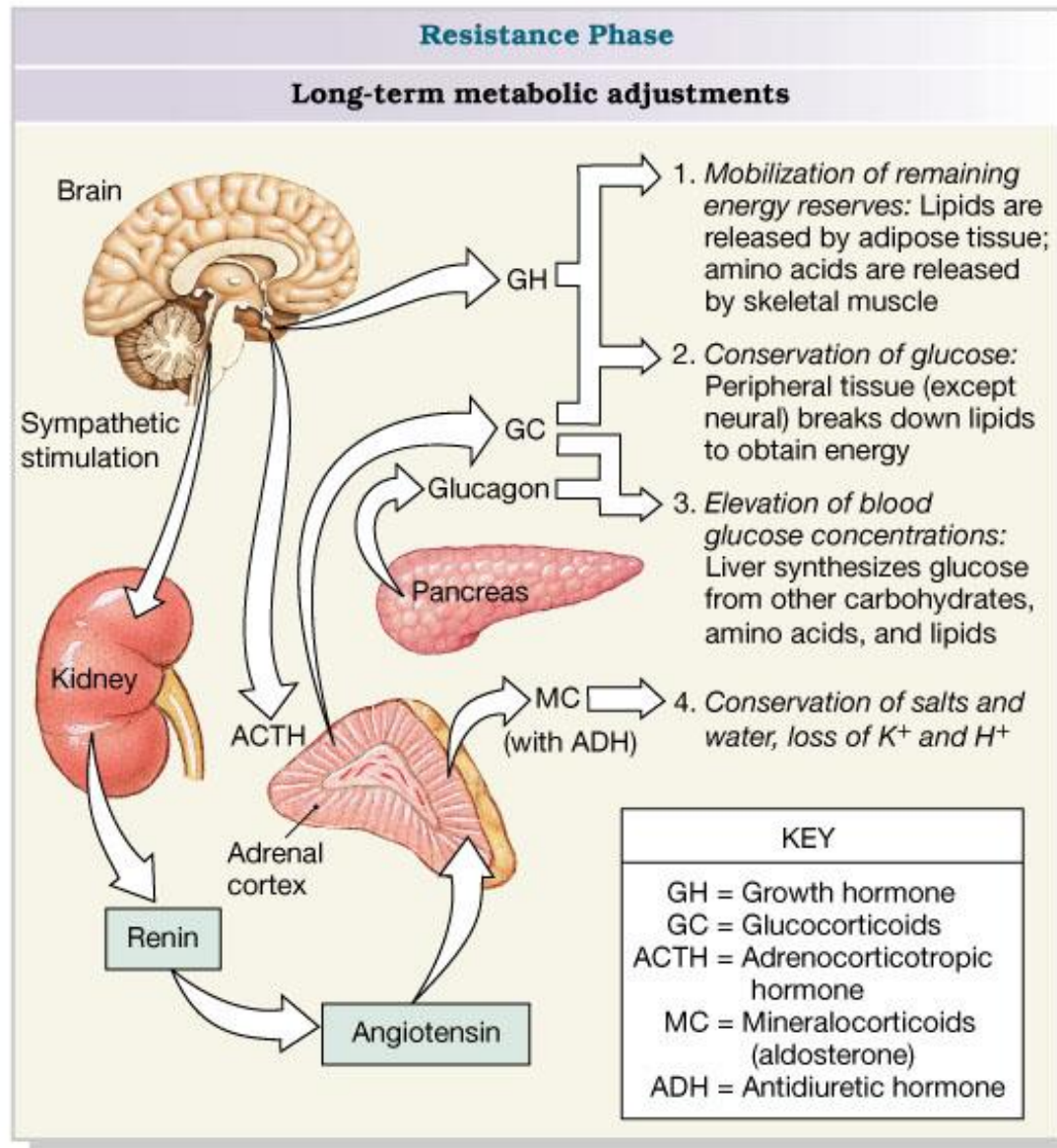
The General Adaptation Syndrome



hypothalamus \leftarrow \ominus
 \downarrow CRH
ant. pituitary \leftarrow \ominus
 \downarrow ACTH
Adrenal Cortex
aldosterone & cortisol

\uparrow cortisone (cushing or ectopic) \rightarrow suppressing other adrenal gland

The General Adaptation Syndrome



Disorders of the adrenal gland

most deadly cancers:

- ① adrenal cortical carcinoma
- ② anaplastic carcinoma
- ③ gall bladder tumor
- ④ colangiocarcinoma
- ⑤ pancreatic tumors.

Disorders of Adrenal glands:

↳ retroperitoneal
(its in a big space so presentation
is usually not cuz of mass effect)

- **A- Abnormal anatomy:** (diffuse or localized swelling)
↳ maybe adrenal cortical carcinoma
most adrenal tumors are benign & don't get large enough to do mass effect
- **B- Abnormal physiology:** (hyper or hypo secretion of hormones)

25% of >45 yo. ♀ have benign adrenal tumor (mostly adenoma)

Neoplasms arising from cortex and metastases

- Adenoma
- Carcinoma
- Myelolipoma *myeloid tissue + fat tissue (only in adrenals)*
- Metastatic carcinoma *(from GI, breast, prostate)*

Cortical Adenoma

- Solitary nodule
- Usually encapsulated by rim of connective tissue
- **Usually small:** <50 gm, < 5cm diameter
(on the average, much smaller than cortical carcinomas)
- Yellow color (majority, because of lipid-laden cells)
- Black color (minority, due to excess lipofuscin pigment)
- Cured by surgical excision

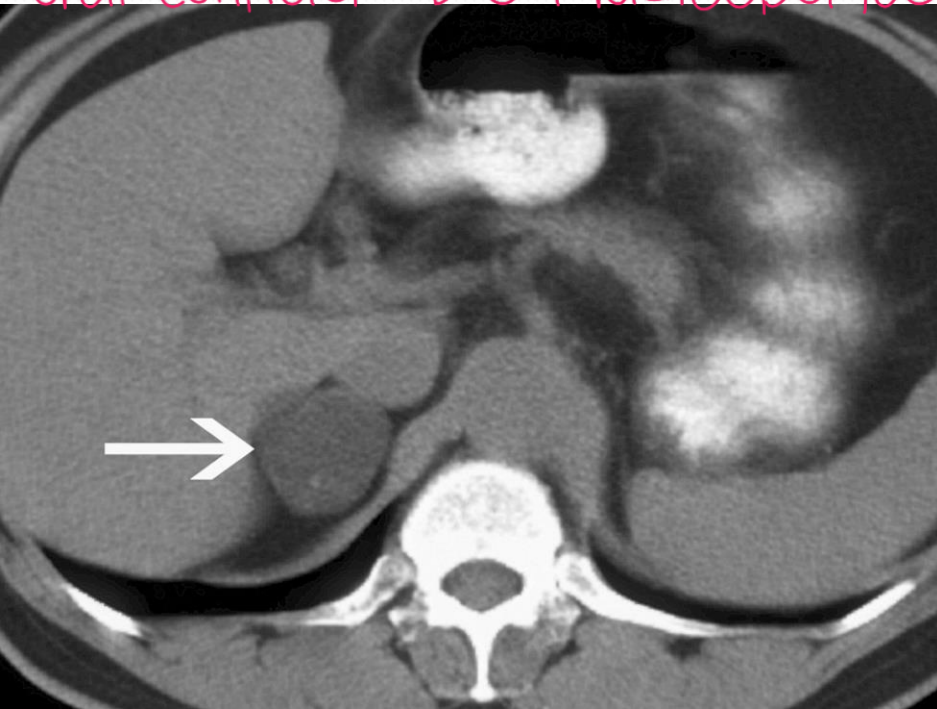- Endocrine function is *unpredictable*; 3 syndromes are
 - no hyperfunction (“silent”)
 - hypercortisolism
 - hyperaldosteronism

CT Adenoma Characteristics

- Sharp margins
- Smooth, homogenous, lipid rich
- Most <10 Hu on noncontrast images
- Washout >50% @ 15 min → Adenoma

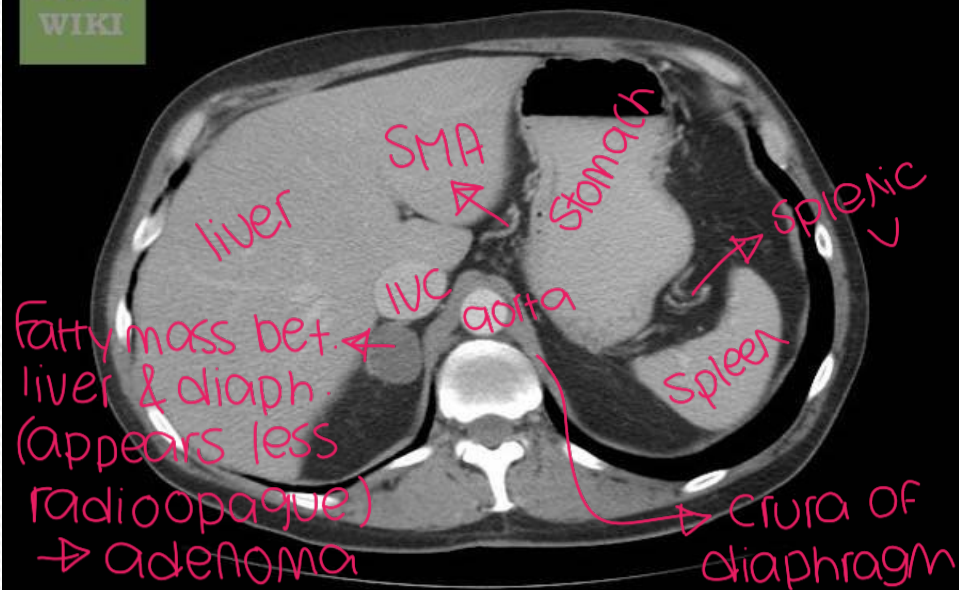
↓ density

oral contrast → GIT radioopaque



IV Contrast → vessels are radioopaque

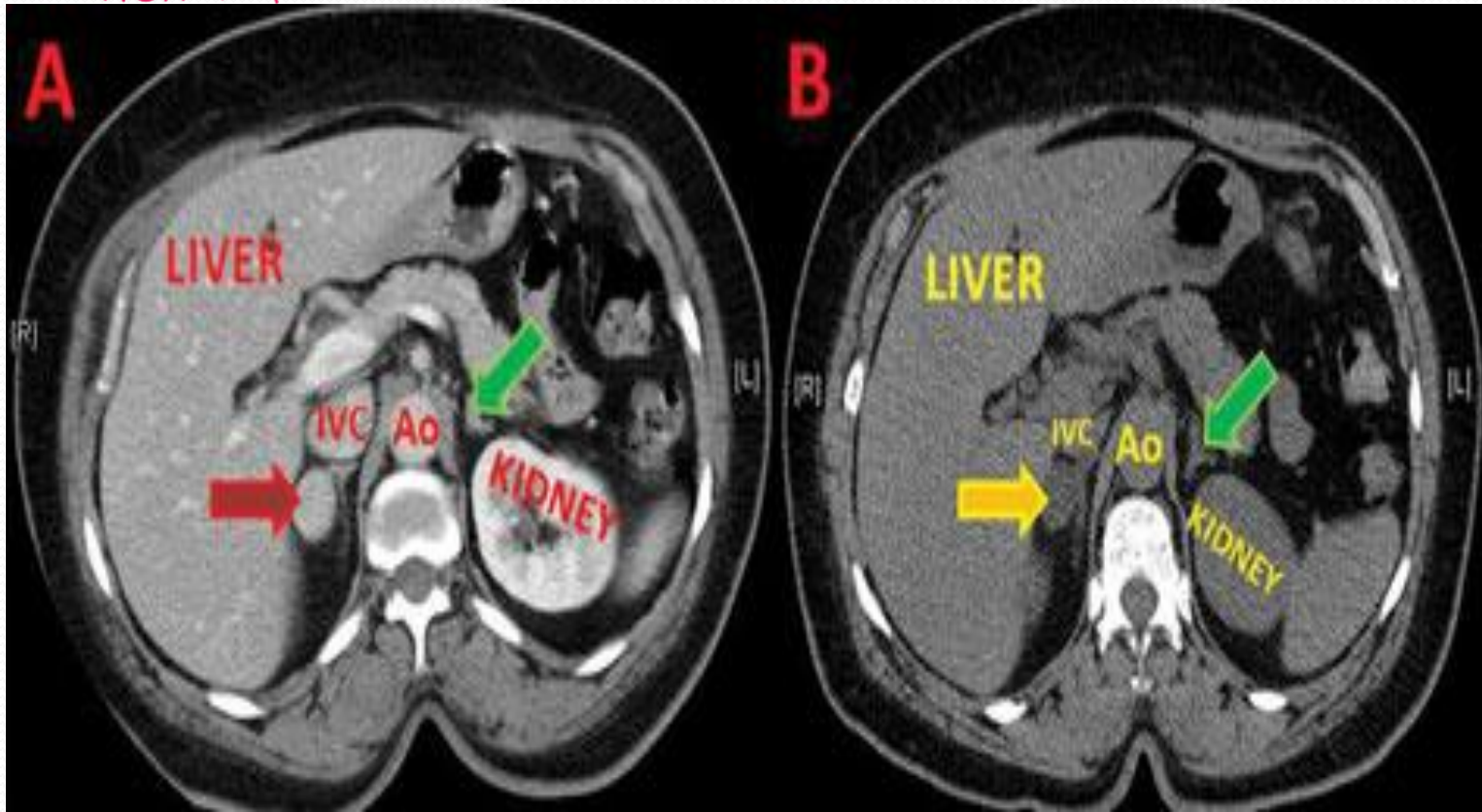
RADS
WIKI



this mass is from lat. limb of rt adrenal gland

Arterial phase

Venous Phase



wash out happened quickly (quick change in density)

- Secreting tumors:

→ Na⁺ & fluid retention

Cortical

- 1- Hyperaldosteronism (Conn`s syndrome) glomerulosa
- 2- Hypercortisolism (Cushing syndrome) fasciculata
- 3- Hyperandrogenism (Precocious puberty) reticularis
- 4- Pheochromocytoma medulla

2° hyperaldo → normal response of ↓ renal A pressure (due to hypotension or renal A stenosis), depends on juxtaglomerular apparatus of kidneys which secretes renin to stimulate

Primary Hyperaldosteronism adrenals through RAS

adrenal problem independent of juxtaglomerular apparatus (↓ renin, ↑ Aldo)

(Conn's syndrome)

1. **Solitary adrenal adenomas (80-90%)**
→ aldosterone medical treatment (spironolactone)
2. **Bilateral adrenal hyperplasia (10-20%)**
3. **Adrenal Carcinoma (rare)** ↳ have hyper
4. **Unilateral Adrenal Hyperplasia (very rare)**

blood test: bilat. venous sampling of adrenal veins to see if both glands secrete similar amounts of aldosterone (to know is it solitary or bilat.)

Clinical features of Conn's syndrome

- **Often asymptomatic**
- **Frontal headache**
- **Muscle weakness to flaccid paralysis
decreased muscle strength (because of low
potassium level)**
- **Polyuria and Polydipsia**
- **Hypertension**

→ MC sign: HTN ± headache

Investigation of Conn's syndrome

A. *Serum Electrolytes*

1. **Serum Potassium decreased** → weakness
2. **Serum Sodium increased (Mild)**
3. **Metabolic Alkalosis**

B. *Increased serum level of aldosterone*

C. *Greatly decreased serum level of renin*

D. *Sodium loading test*

Saline loading test:

give 2L saline → Aldo decreased → responsive / not Conn's

↘ Aldosterone Not affected → probably Conn's

Localization

- Ultrasound. → limitation: doesn't pass bone or gas
- CT Scan. (the best)
- MRI
- Angiographic Blood Sampling. (veins)
to localize it (rt or lt)

bilat. adrenal removal → pt can't cope w/ stress →
↓ aldosterone, ↓ cortisol, ↓ adrenaline → Addisonian Crisis
(so we usually don't do bilat. removal for Conn's)

Treatment of Conn's syndrome

A. Adrenal Adenoma

Surgical excision (unilateral adrenalectomy)

B. Adrenal Hyperplasia

Spironolactone (Aldactone)

pheochromocytoma needs bilat. removal & management

Cushing's syndrome

(↑ cortisol)

Endogenous :

ACTH dependent 85% ^{2° to}

- Cushing's disease (pituitary)
- Ectopic ACTH syndrome (small cell lung carcinoma)
- Ectopic CRH syndrome (bronchial carcinoid tumours)

↳ ⊕ pituitary to secrete ACTH

ACTH independent 15%

- Common: Adrenal adenoma, adrenal carcinoma
- Less common: Micronodular hyperplasia, macronodular hyperplasia

Exogenous

- **Glucocorticoid treatment**

Pseudo-Cushing's syndrome

- **Major depressive disorder**
- **Alcoholism**
- **Obesity**

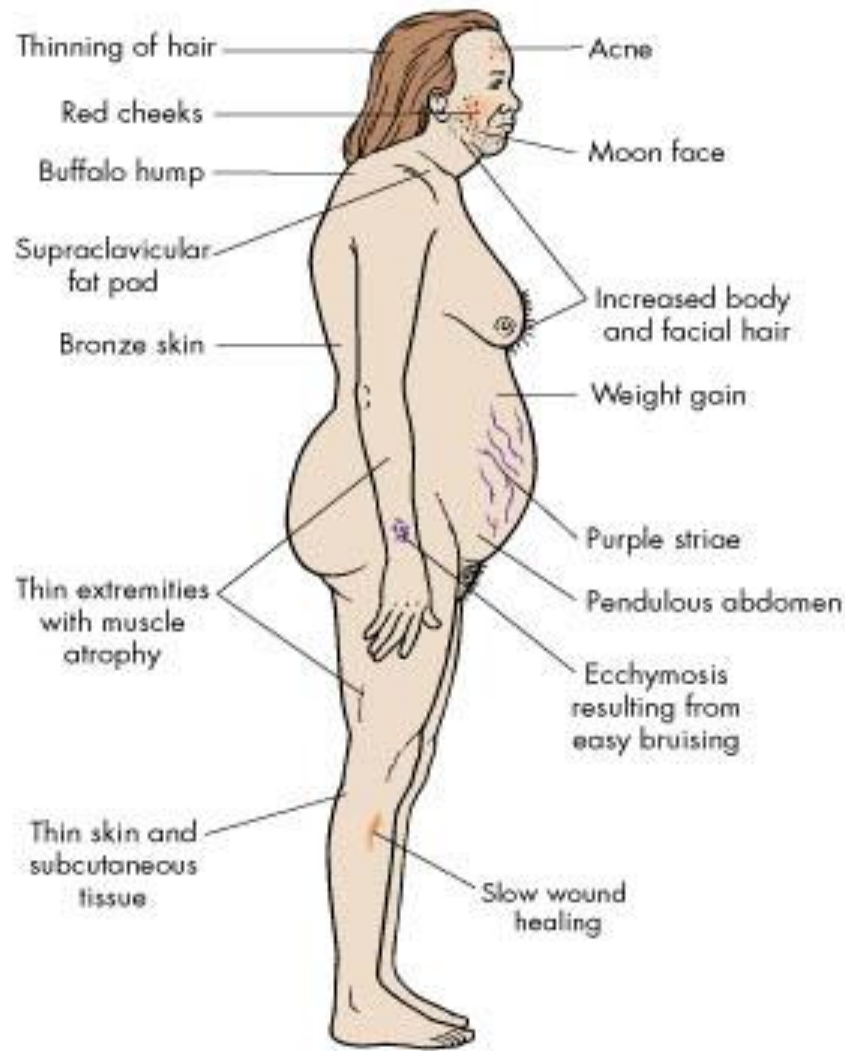


Figure 47-9 Common characteristics of Cushing's syndrome.

Copyright © 2000 by Mosby, Inc.

Investigation of Cushing's syndrome

Screening tests

- **Urinary free cortisol** → cuz of diurnal variation
The measurement of 24 hour excretion of cortisol in urine integrates the variations in plasma free cortisol concentrations seen during the entire day; three consecutive 24 hour urine specimens.
- There is a false negative rate of 5.6%, with false positives of 1% in normal people and 5% in obese individuals.

- **Dexamethasone suppression tests**

In normal subjects, administration of a supraphysiological dose of glucocorticoid results in suppression of ACTH and hence of cortisol secretion (cortisol <50 nmol/l). This is the basis of dexamethasone suppression tests, of which there are several types.

↳ Give dexamethazone in the morning → Normally cortisol will be suppressed

Treatment of Cushing's syndrome

- **Transsphenoidal surgery** (pituitary resection)
- **Pituitary radio-therapy**
- **Bilateral or unilateral adrenalectomy**
- **Medical therapy** (Mitotane + Chemo → suppress metastatic cortisol secreting tumor)

Pheochromocytoma Rule's of 10 %

- Bilateral
- Familial (non-sporadic)
- Pediatric
- Malignant
- Normotensive
- Extra-adrenal
- Multiple
- *Childhood presentation breaks the rules- 25%
bilateral, multiple, extra-adrenal

pt may have fixed or
impulsive secretion

Pheo

* OSCE

- Triad: **headache, tachycardia, diaphoresis**
- Other symptoms: Pallor, flushing, palpitations, abd/chest pain, weakness, N/V, psychosis
- Small tumors more likely symptomatic

Pheo- The Diagnosis

- Plasma free metanephrines : most sensitive test seen 99% of patients
→ epinephrine metabolite
↳ but ↓ Specificity
- 24 h urinary catecholamines (2x normal is diagnostic)
- VMA → Vanillyl mandelic acid
- Clonidine suppression test (0.3mg oral, test 3 hrs later)
>50% reduction catecholamines NO pheo
→ antihypertensive → ⊖ catecholamine (responsive) → Not pheo
↳ catecholamine not affected → Possibly pheo

Pre-op Management

→ α & β blockers
→ fluids

- Early alpha blockade
- Goal to control hypertension- phenoxybenzamine
- Do NOT use β -blocker before alpha (this causes bradycardia & \downarrow CO. with no big effect on adrenals → risk of acute HF)
- IV hydration
- Prevent cardiac arrhythmias

intra op or post op. → give adrenaline after gland removal till adaptation

Adrenal Cortical Carcinoma

- Mean age 50 years
- **Larger:** typically > 100 gm; mean weight 900 grams (BIG!)
- Gross clues for malignancy (some apparent by imaging)
 - Large size, hemorrhage, necrosis, invasion of adrenal vein
- **Absolute criteria for malignancy:** invasion & metastasis
- 5 year survival: 20-30%; most tumor-related deaths occur within first two years after diagnosis

adrenal incidentaloma → adrenal mass discovered by
incidence on a CT for sth. else.

4. The adrenal “Incidentaloma”

- **Definition:** “an adrenal mass, generally more than 1 cm. diameter, that is discovered accidentally during a radiologic examination performed for indications other than an evaluation for adrenal disease.” *

Nature of Incidentally Found Adrenal Masses

- Review of 2,005 incidentally-discovered adrenal masses:
 - Nonfunctioning adenoma 82%
 - Functioning: Cushing's 5%
 - Pheo 5%
 - Aldosteronoma (conn's) 1%
 - Malignancy: Metastasis 3%
 - ACC 4%
- Young WF, et al. Endocrinol Clin N Am. 2000

Incidental Adrenal Mass Management

- Hormonally active → surgical removal
- > 5 cm → removal (with a scalpel)
- < 3 cm observe
- Surveillance Recommendations:

Old: CT at 6 months then Annual endocrine eval for 4 years

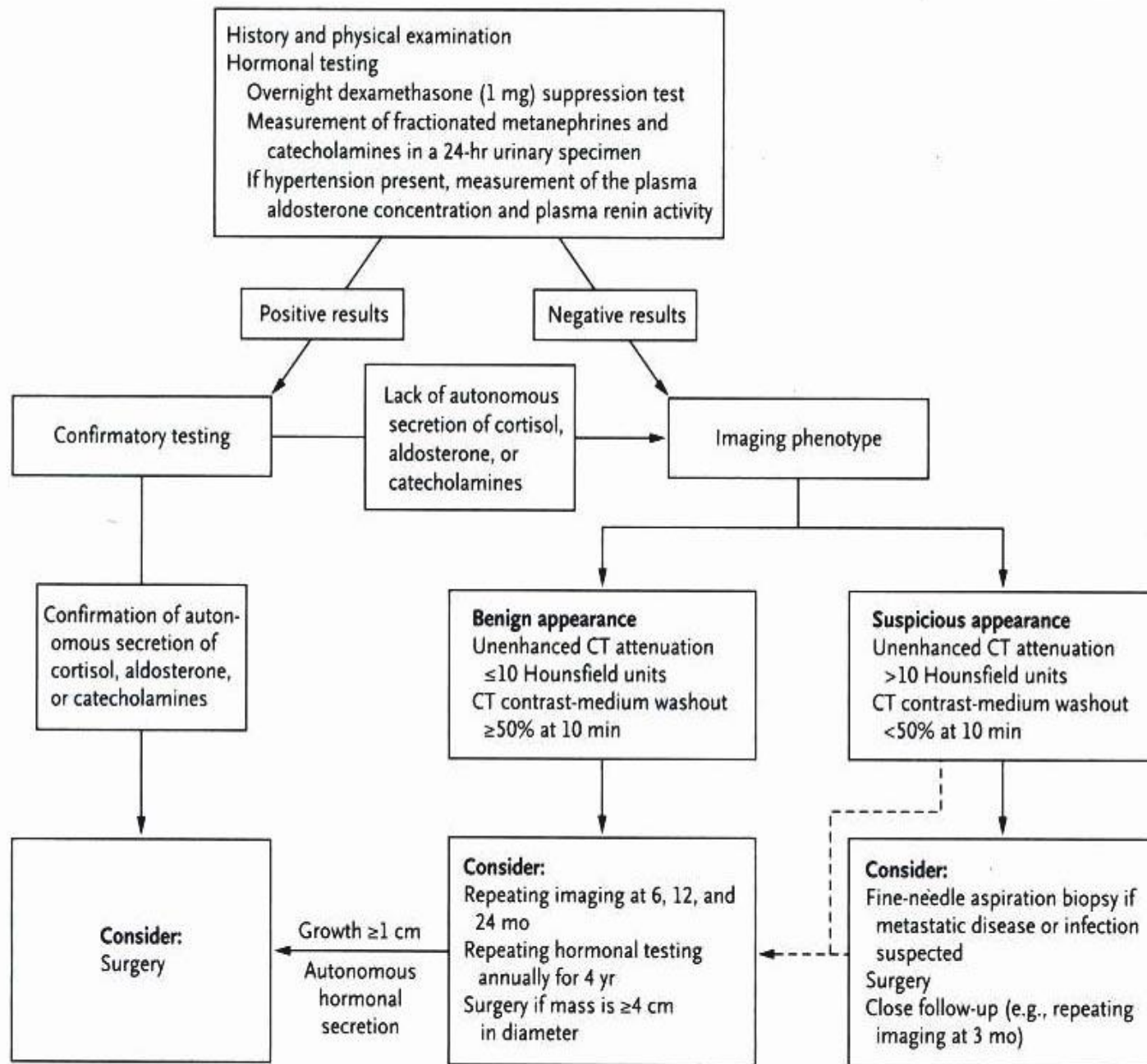
New: If mass stable on scans @ 3m and 1 yr then no further workup

indications of Surgery:

- ① hormonally active
 - ② > 5 cm
-

Observe Only:

- ① < 3 cm
- ② fat rich



Young, WF;
New England
Journal of
Medicine,
356:601-610,
2007, fig. 1

Figure 1. Algorithm for the Evaluation of Patients with an Adrenal Incidentaloma.

Surgical approach

Surgical Management of Adrenal Neoplasms

- Before the era of laparoscopic procedures, conventional open adrenalectomy was the only surgical approach to adrenal neoplasms
- Since the introduction of laparoscopic adrenalectomy by *Gagner* et al. in 1992, the majority of benign adrenal lesions have been removed by various laparoscopic techniques.

Indications

- The choice of approach will depend on size, location, possibility of malignancy, and surgeon experience with the different techniques.
- The open approach to adrenalectomy is considered the gold standard for masses suspected of being adrenal carcinoma

Indications

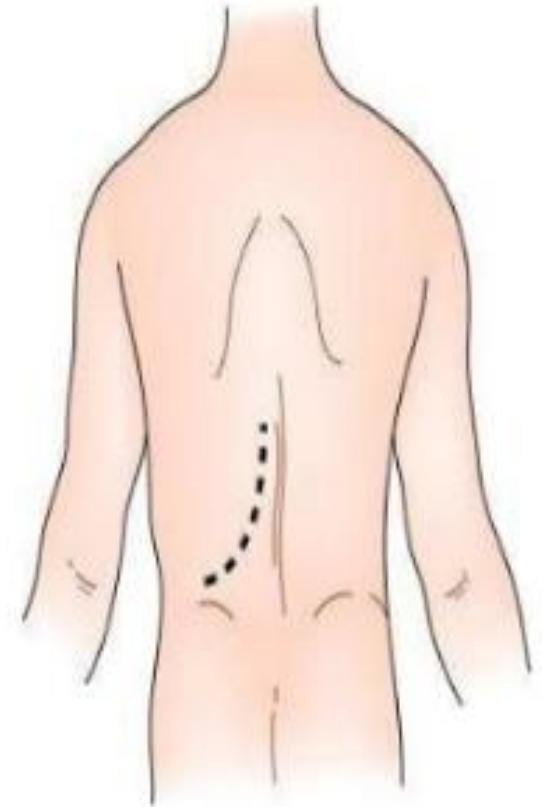
- Conn syndrome
- Cushing syndrome
- pheochromocytoma
- large myelolipoma
- metastatic tumors
- adrenocortical carcinoma
- neuroblastoma

Conventional Open Methods

- The flank or posterior
- The anterior or transabdominal
- The transthoracic or thoracoabdominal

- The standard approach has the patient in the prone position with arms extended over the head
- The incision is made over the 11th or 12th rib, with or without a “hockey stick” extension cephalad

POSTERIOR APPROACH (Retroperitoneal)



Posterior Approach

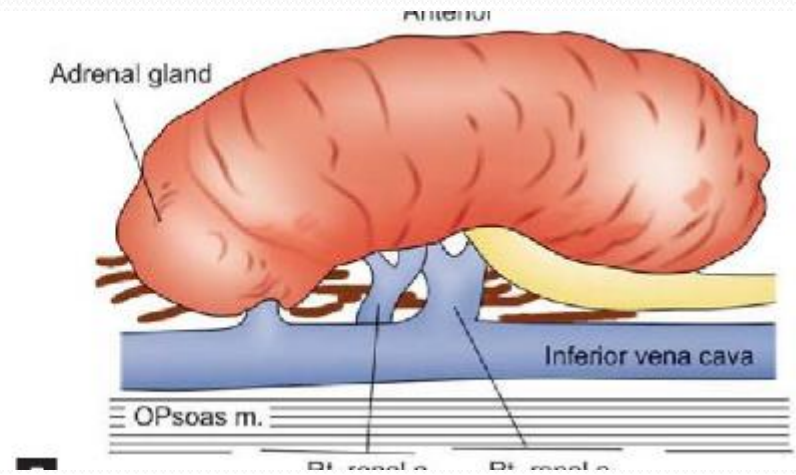
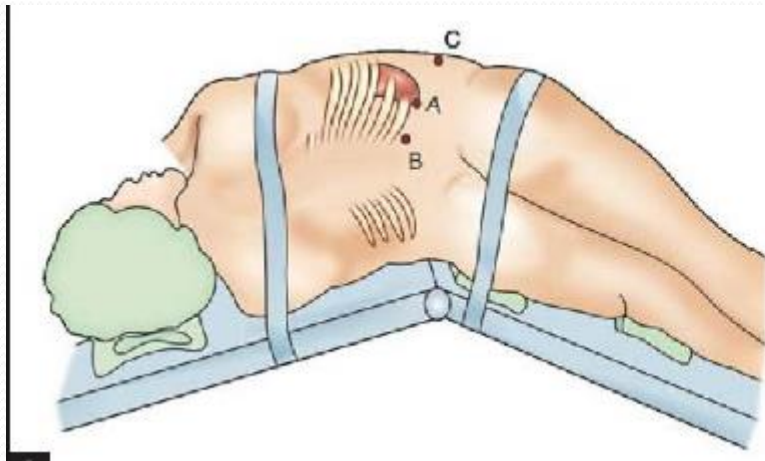
- Also referred to as the lumbodorsal approach
- The advantage of this approach is allowing the surgeon to both remain in an extraperitoneal dissection plane and offers access to both adrenal glands
- The incision is made through the bed of the twelfth rib

Posterior Approach

Disadvantages :

- Since exposure with this approach is limited, it should only be used to remove tumors up to 5 cm in size
- Intra-abdominal exploration for other pathology or metastases is impossible
- Two separate incisions are required for bilateral adrenalectomy

Flank Approach



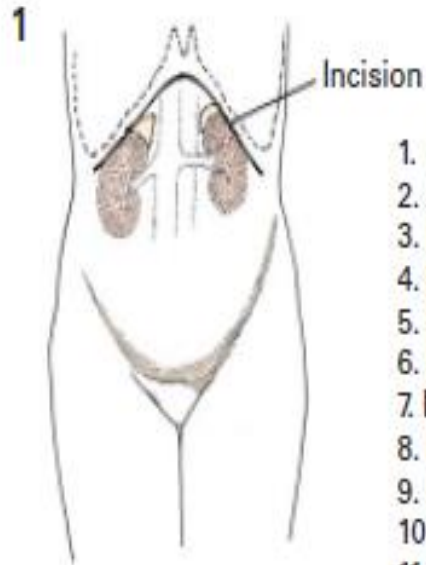
Flank Approach

- Incision is made over the 11th rib and carried down through the muscle and fascial layers over the 11th rib
- The rib is mobilized posteriorly taking care to avoid injuring the neurovascular bundle
- The rib is then resected and entry is made into the retroperitoneal space through the lumbodorsal fascia.

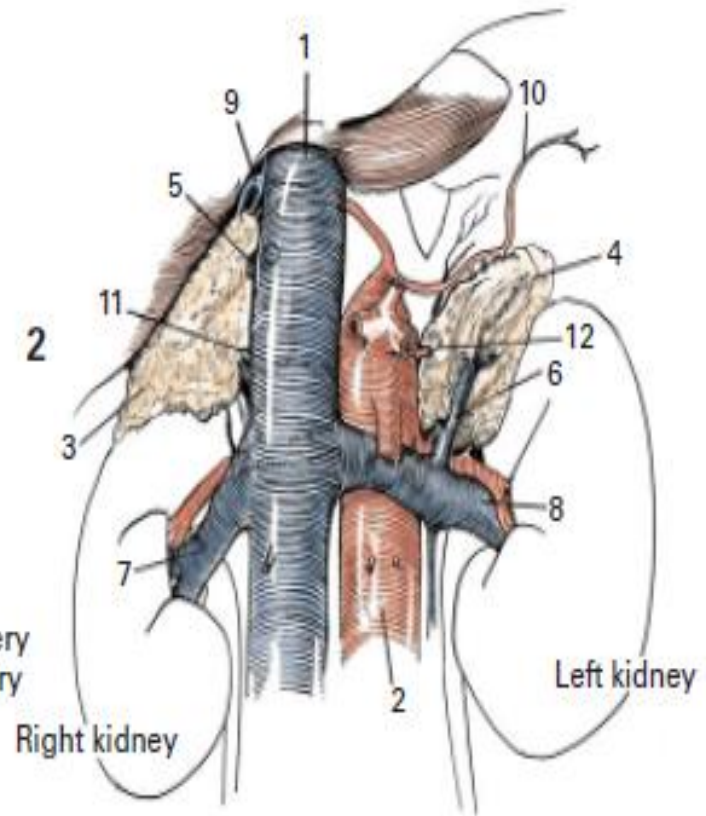
Flank Approach

- This approach offers excellent exposure in obese patients
- there is a risk of injury to the pleural reflection at the level of the 11th rib in the midaxillary line and inadvertent entry into the pleural cavity or lung injury.

Anterior Subcostal Approach



1. Inferior vena cava
2. Aorta
3. Right adrenal gland
4. Left adrenal gland
5. Right adrenal vein
6. Left adrenal vein
7. Right renal vein
8. Left renal vein
9. Right inferior phrenic artery
10. Left inferior phrenic artery
11. Right adrenal artery
12. Left adrenal artery



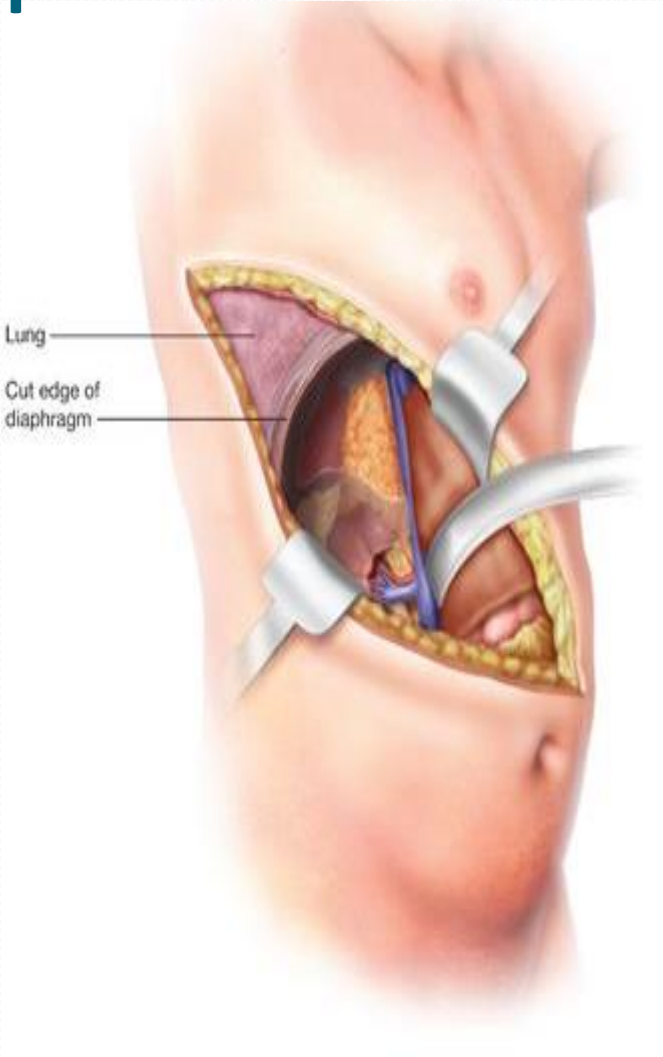
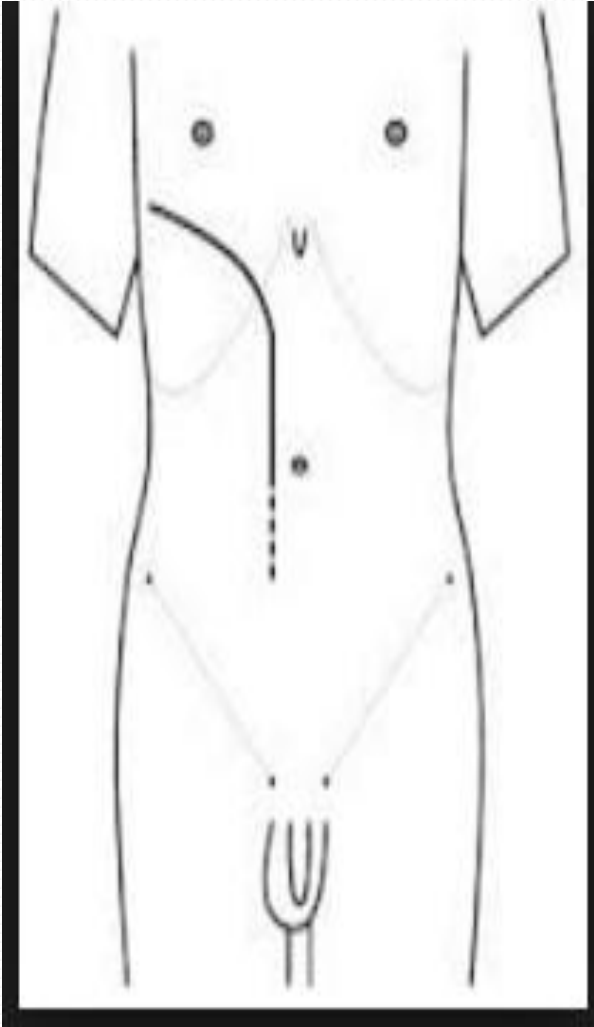
Anterior Subcostal Approach

- The subcostal approach is initiated with the patient supine and the incision is made two fingerbreadths below the costal margin.
- The adrenal is identified by its characteristic yellowish color, lobulated appearance, and clearly definable blunt lateral edge.
- The vascular attachments are usually on or near the medial and superior edges of the gland rather than on its broad surfaces.

Anterior Subcostal Approach

- This approach offers the advantage of being well known to all surgeons and allows for bilateral exploration.
- However, it carries a higher rate of ileus, and may be difficult with obese patients

Thoracoabdominal Approach



Thoracoabdominal Approach

- The incision is then made through the 8th or 9th intercostal space through the muscle layers and carried medially through the costal cartilage
- The incision is carried through the anterior and posterior rectus sheaths and the pleura is entered and the lung packed out of the field
- Care is taken during division of the diaphragm to not be too central as the phrenic nerve can be damaged with careless division

Thoracoabdominal Approach

- This approach offers excellent exposure to the retroperitoneum and the great vessels.
- However, it has the highest morbidity of all the approaches with risk of prolonged ileus, pulmonary complications, and necessary chest tube
- Most authors reserve this approach for large tumors and adrenal carcinoma

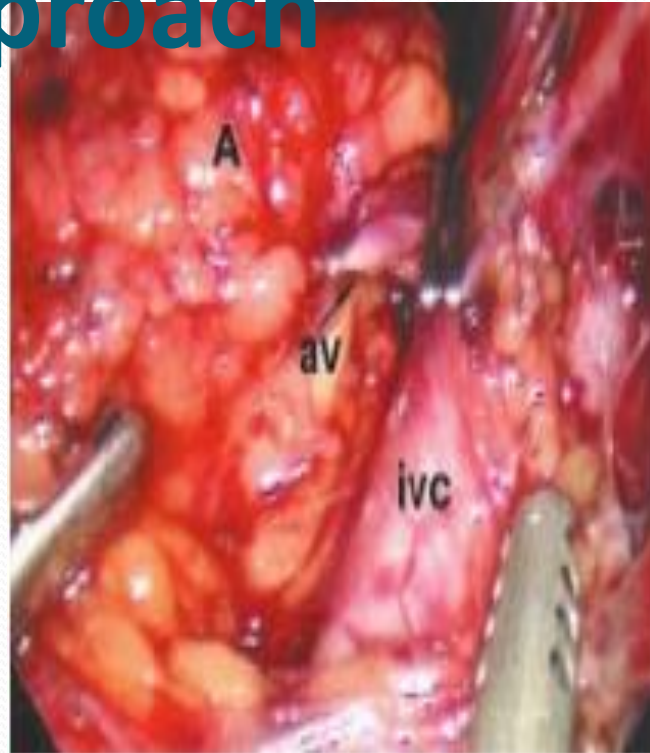
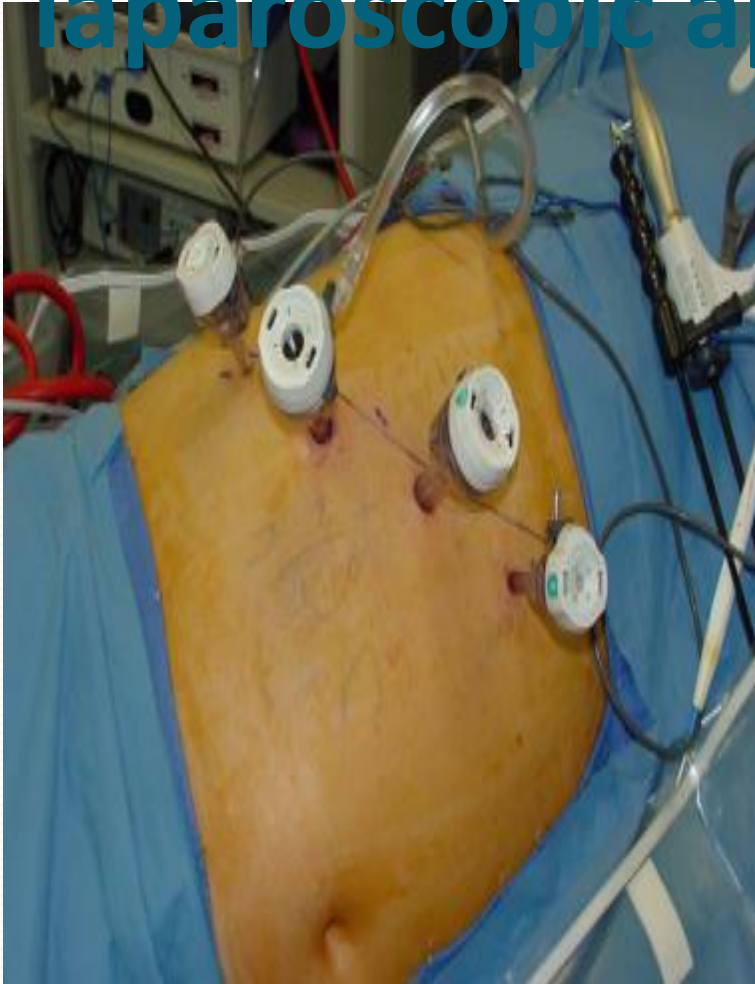
Laparoscopic approaches

- Lateral transperitoneal (flank)
- Anterior
- Posterior retroperitoneal

The lateral transperitoneal laparoscopic approach

- Four trocars are inserted in the flank area, one under the subcostal area at the anterior axillary line and three under the twelfth rib along a line lateral to the first one
- This method allows one to inspect much of the abdominal cavity and provides wider exposure for removing relatively larger glands than can be removed with the retroperitoneal approach.

The lateral transperitoneal laparoscopic approach



The Anterior Laparoscopic Approach

- four to five trocars are inserted, one above the umbilicus and two subcostally, one at the anterior axillary line and another at the midclavicular line.
- The advantages and disadvantages of the anterior approach are similar to the lateral transperitoneal or flank approach
- more dissection and retraction is required which may lead to more bleeding and other injuries

The posterior or retroperitoneal laparoscopic approach

- The patient is placed in a semi-jackknife prone position.
- A balloon trocar is inserted 2.5 cm lateral to the twelfth rib into the retroperitoneum to create a working space.
- Three more trocars are introduced into the created retroperitoneal space under direct vision

The posterior or retroperitoneal laparoscopic approach

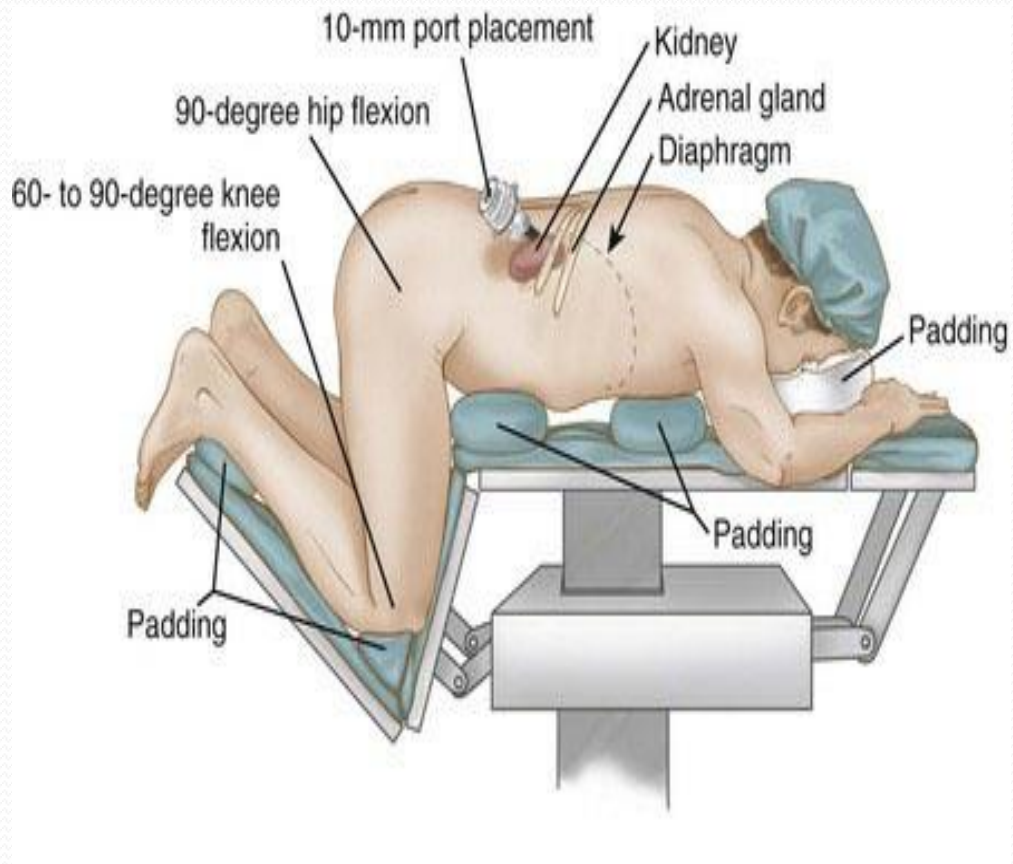
Advantages

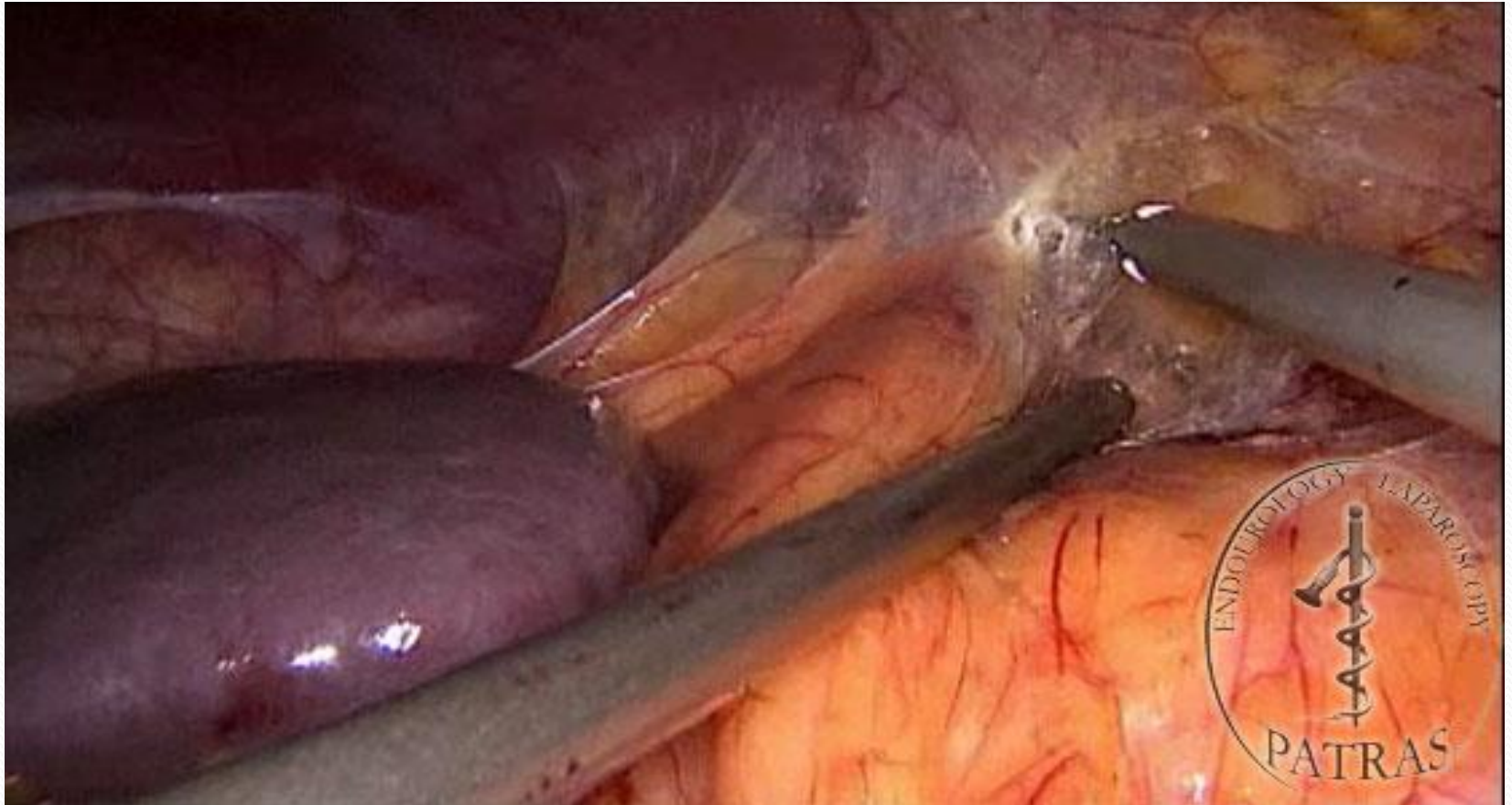
- the retroperitoneal approach allows one to perform a bilateral adrenalectomy without repositioning the patient
- It also avoids adhesions from previous operations and other abdominal conditions that might interfere with the operation

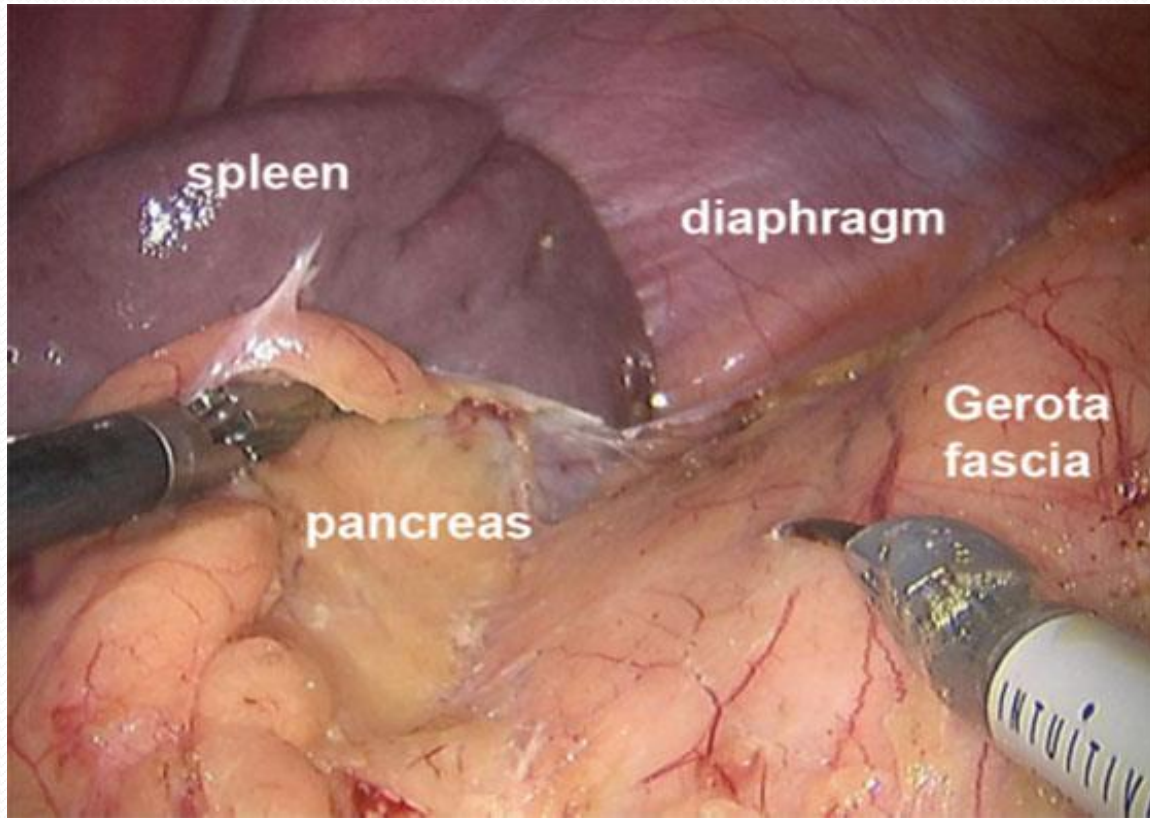
The posterior or retroperitoneal laparoscopic approach

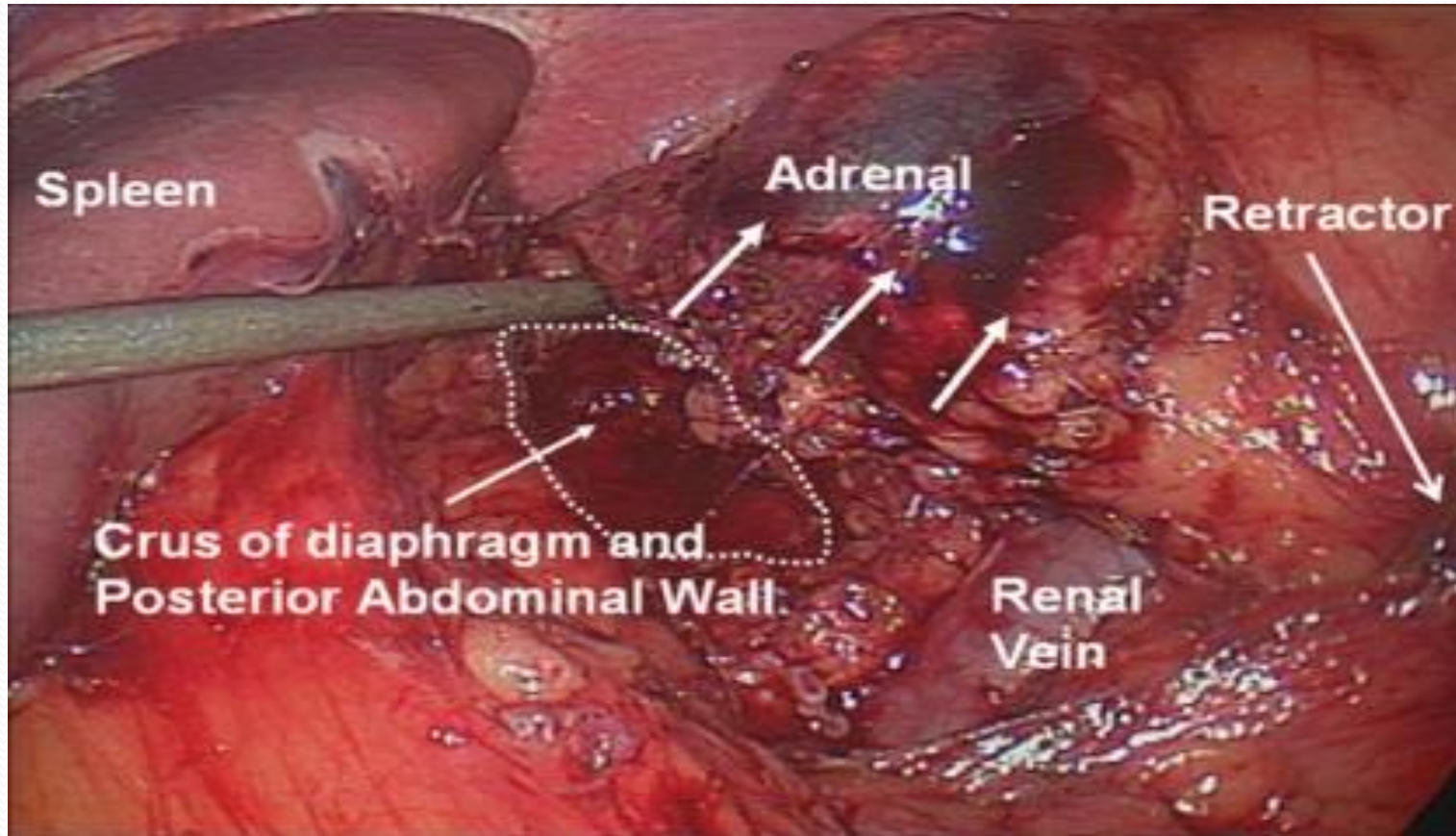
Disadvantages

- However, the retroperitoneal approach precludes intra-abdominal exploration.
- Due to its limited working space, large tumors cannot be removed (up to 5 cm).











Thank You