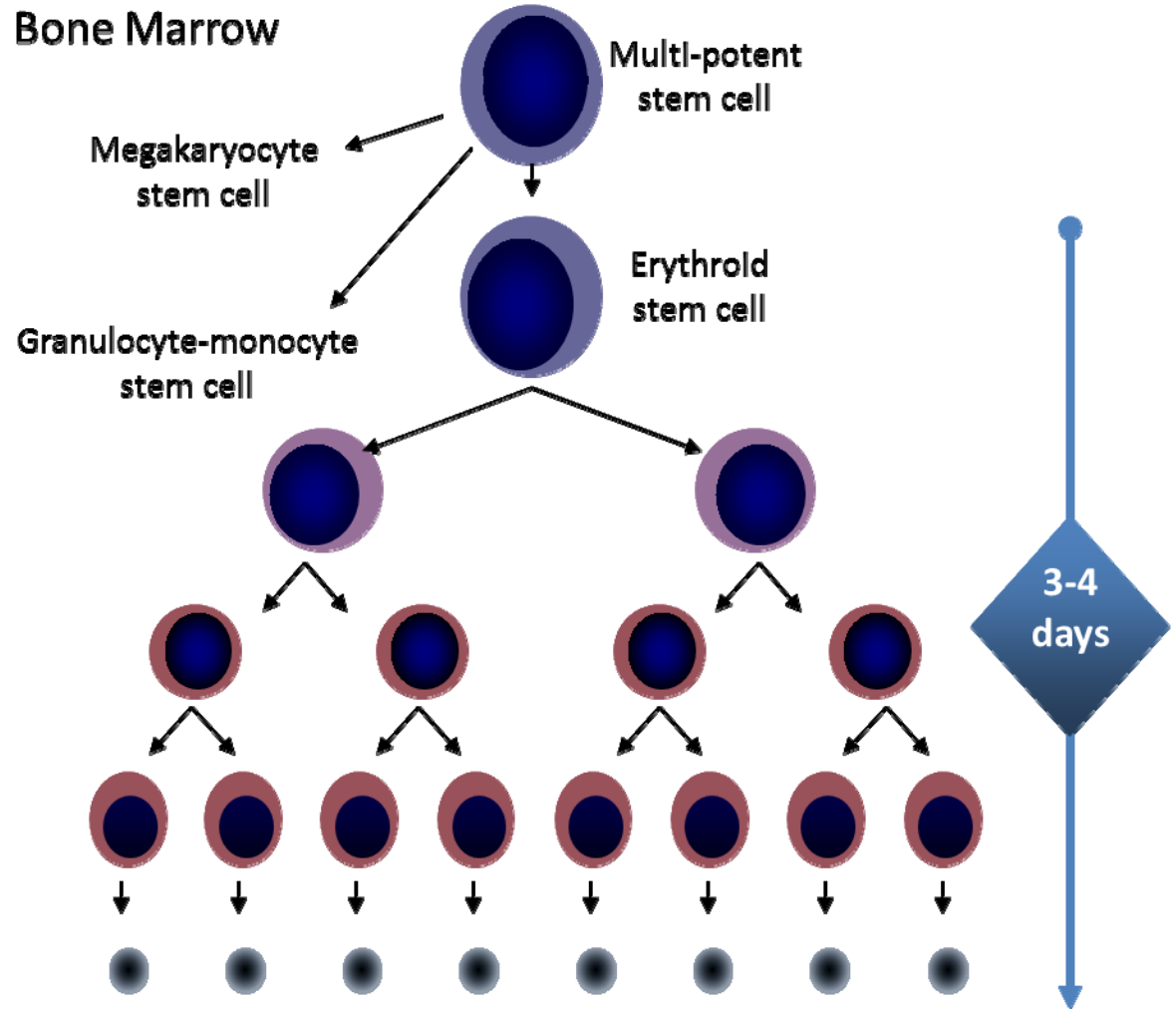
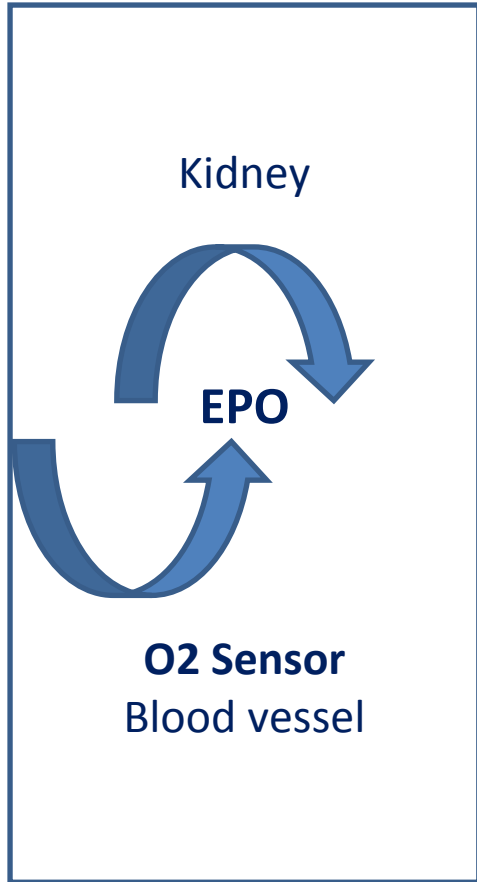




Approach to Anemia

Laith AL-Showbaki, MD



Definition:

Anemia is operationally defined as a reduction in one or more of the major RBC measurements:

**Hemoglobin concentration,
Hematocrit,
RBC count**

These are all concentration measures

The cut-off value defining anemia has been determined by convention as the value at -2 SD from the mean or the 2.5th percentile of the normal distribution of a healthy iron-replete population.

WHO's Hemoglobin thresholds used to define anemia in adults (g/dl)

Women, non-pregnant (>15yrs) 12.

Women, pregnant 11.

Men (>15yrs) 13.

Severity of Anemia/g/dl/WHO Classification

	Mild	Moderate	Severe
Non-pregnant women (15 yrs and above)	11-11.9	8-10.9	< 8
Pregnant women	10-10.9	7-9.9	<7
Men (15 yrs and above)	11-12.9	8-10.9	<8

Anemia

- Understanding anemia
 - Disease - to be treated on its own merits
 - Condition - a secondary manifestation of another disease
- Causes
 - Decreased production
 - Blood loss
 - Hemolysis

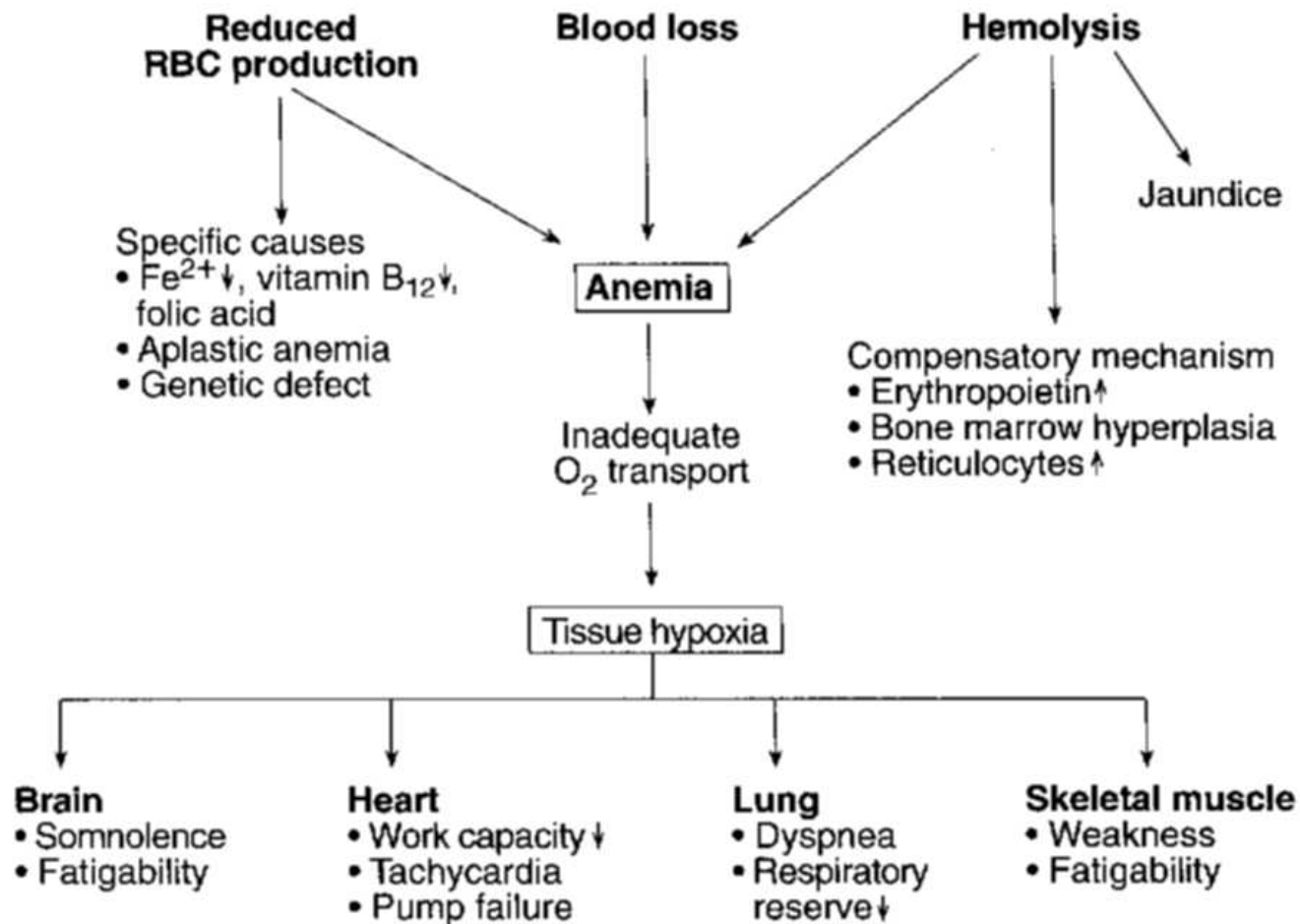
Factors that influence symptomatology and severity of symptoms

- Acute or chronic
- Cardiovascular status
- Additional symptoms related to cause
- Additional symptoms related to type of anemia
- Any intravascular hemolysis

Clinical Evaluation of Anemia: History

- **Proper History; including history of bleeding and systemic illness**
- **Dietary History**
- **Past History**
- **Family History**
- **Drug history**
- **Travel History**

PATHOLOGY, SYMPTOMS, AND SIGNS OF ANEMIA



The “Anemia Syndrome” due to **tissue hypoxia**

1- Dizziness

2- Fatigue

3- Shortness of breath especially on exertion

4- Headaches

5- Chest pain/ palpitations

6-? Heart Failure

Clinical evaluation of anemia: **Physical Examination**

- **Look for signs of anemia**
- **Look for signs suggestive of type**
- **Examine for splenomegaly/Hepatomegaly**
- **Look for signs suggestive of cause**
- **Examine for signs of systemic disease**

Anemia Classification: Two main approaches

1- Biologic or kinetic approach

- Determined by reticulocyte count

2- Morphology.

- Determined by MCV

Acute vs. chronic

- Signs and symptoms

Laboratory Evaluation of Anemia

- Complete blood count including HB, RBC, MCV, RDW
- Reticulocyte count
- Peripheral smear
- Other specialized tests

Morphological Classification of Anemia

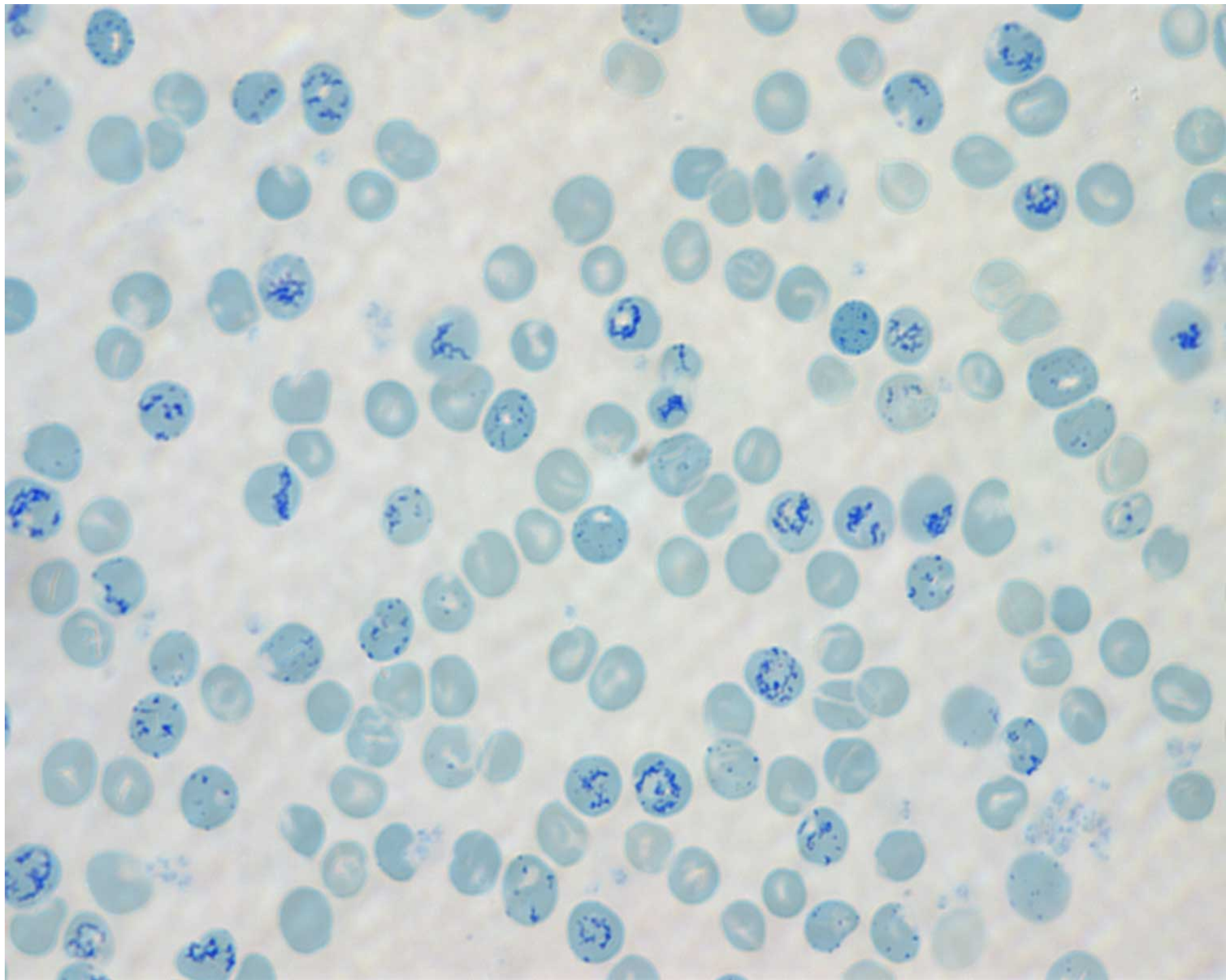
A- Normocytic/normochromic (normal MCV &MCH): acute blood loss, Hemolysis, ACD, BM failure

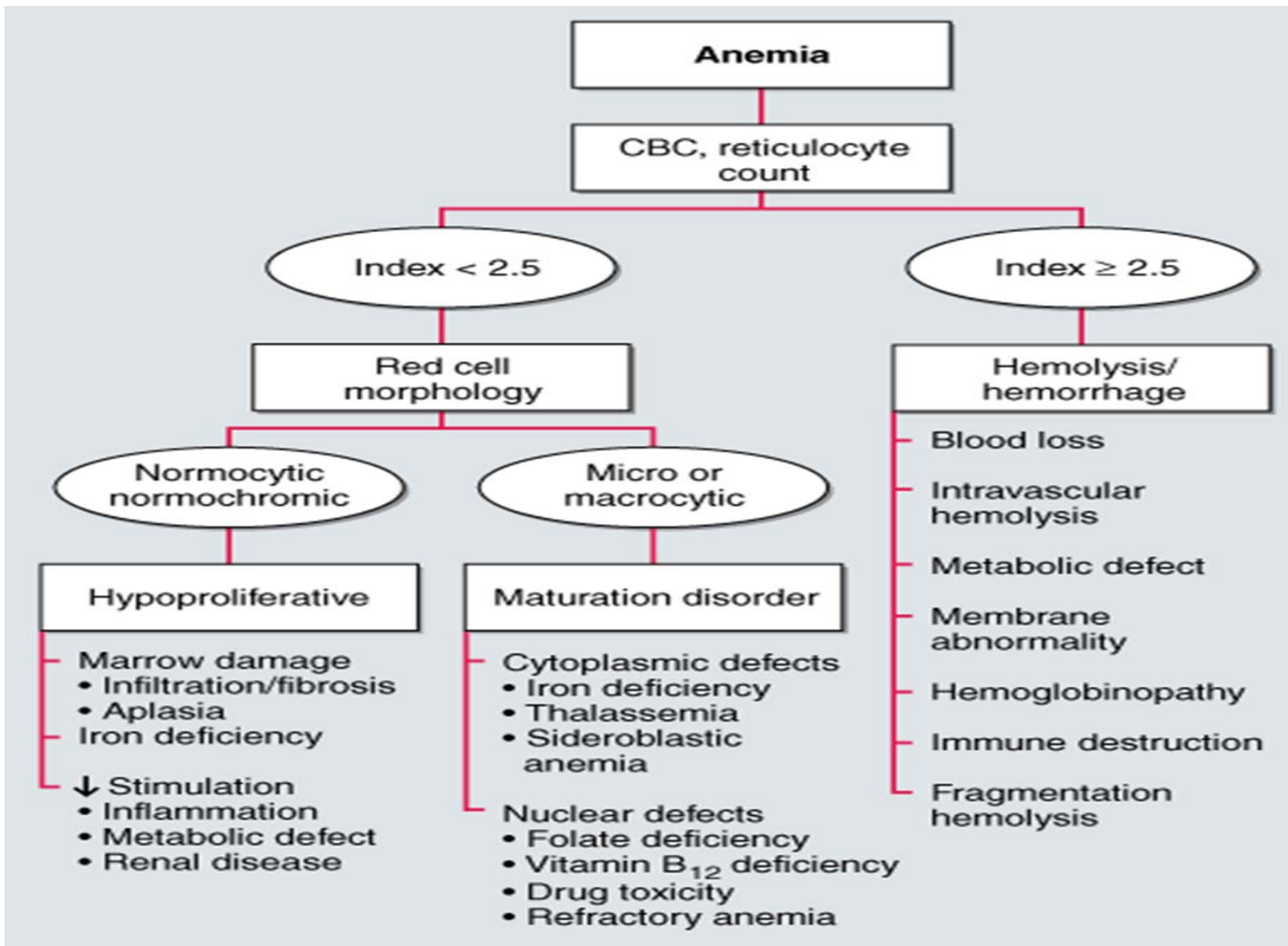
B- Microcytic/hypochromic (MCV<78, MCH <26): IDA, Thalassemia

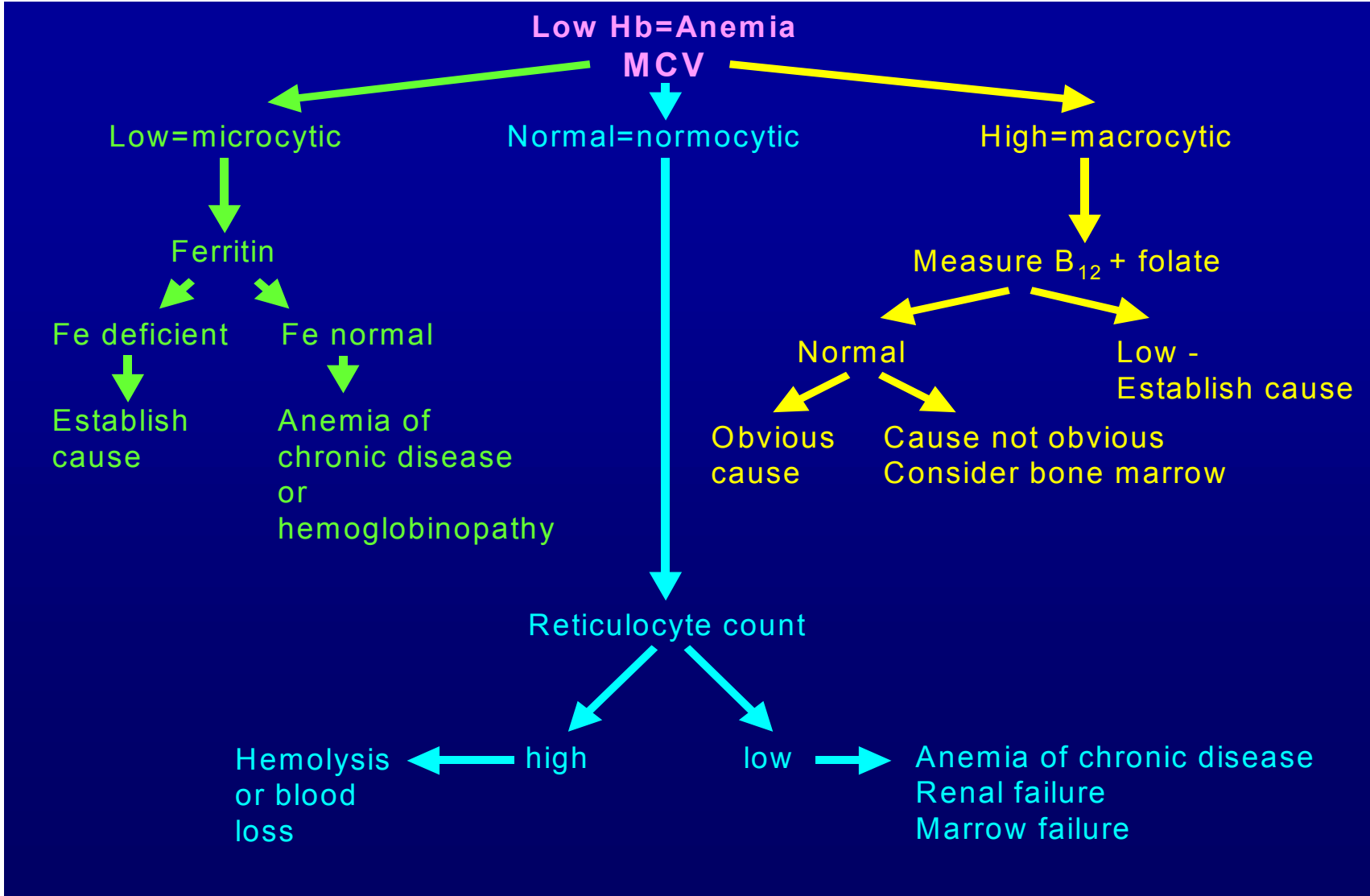
C- Macrocytic (MCV>98): megaloblastic anemias.MDS.

The reticulocyte count

- **Corrected retic.** = Patients retic.(**3%**) x (Patients Hct(30)/45) : $3(\%) \times 30/45 = 2\%$
- **Retics index (RPI)** = corrected retic. count/Maturation time
(Maturation time = 1 for Hct=45%, 1.5 for 35%, 2 for 25%, and 2.5 for 15%.) example above: $2/1.75 = \mathbf{1.14}$
- Absolute reticulocyte count = retics % x RBC number.
Example: $1.1\% \times 4.96 \times 10^6 = 55,000/\mu\text{l}$
 $12.2\% \times 2.05 \times 10^6 = 250,000/\mu\text{l}$







Microcytic Hypochromic Anemia: Diagnosis

- Mild (MCV $>$ 70 fl)
 - Iron deficiency
 - Thalassemia
 - Lead toxicity
 - Sideroblastic anemia
 - Anemia of chronic disease
- Severe (MCV $<$ 70 fl)
 - Iron deficiency
 - Thalassemia

Evolution of Iron Deficiency Anemia

- **Depletion of body Iron stores only but No anemia**
- **Iron Deficiency with anemia**
- **Ferritin: The Best Marker for Iron Deficiency in “adults”**

TRANSPORT PROTEINS/Fe

- ❑ DMT1 (Divalent Metal Transporter 1)
(Tranports from lumen into the enterocytes)

- ❑ FERROPORTIN1
(Transports from enterocytes to circulation)

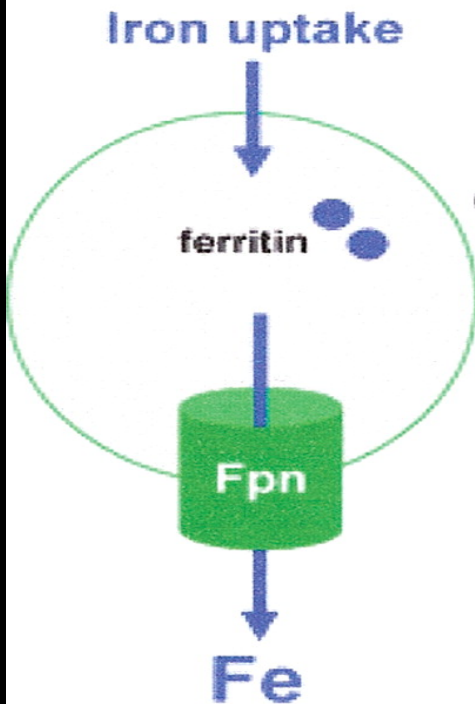
What is HEPICIDIN??

- HEPICIDIN is the key regulator of iron in our body.
- Is a peptide hormone.
- Its molecular weight is 25 Kda.
- Highly folded structure.
- Present in inactive form; prohepcidin(60aa) and its active form is hepcidin(25aa).

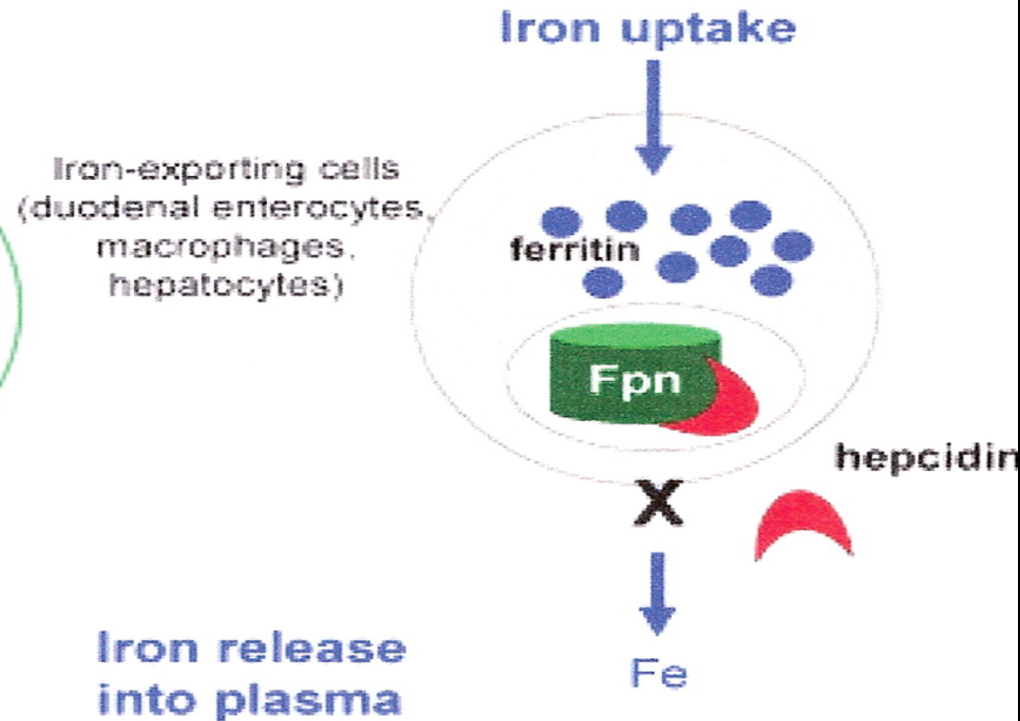
Mechanism of action of hepcidin

- ❑ The major mechanism of hepcidin is THE REGULATION OF TRANSMEMBRANE IRON TRANSPORT.
- ❑ It binds to FERROPORTIN ,forms hepcidin-ferroportin complex ,which is degraded in the lysosomes and iron is locked inside the cells(mainly enterocytes,hepatocytes and macrophages).

Low hepcidin



High hepcidin



Hepcidin Regulation

So when hepcidin levels are low, iron exporting cells have abundant ferroportin and thus releases iron into plasma. When hepcidin concentration increases it binds to ferroportin and thus iron is retained in the cells.

Hepcidin/Ferroportin

- ❖ Hypoxia/Anemia leads to decrease in hepcidin
- ❖ Inflammation leads to increase in hepcidin

Ferroportin

- ❑ The only cellular iron exporter in vertebrates.
- ❑ Present in enterocytes, macrophages, placenta and the hepatocytes.

Mechanism of action of hepcidin

- ❑ The major mechanism of hepcidin is THE REGULATION OF TRANSMEMBRANE IRON TRANSPORT.
- ❑ It binds to FERROPORTIN ,forms hepcidin-ferroportin complex ,which is degraded in the lysosomes and iron is locked inside the cells(mainly enterocytes,hepatocytes and macrophages).

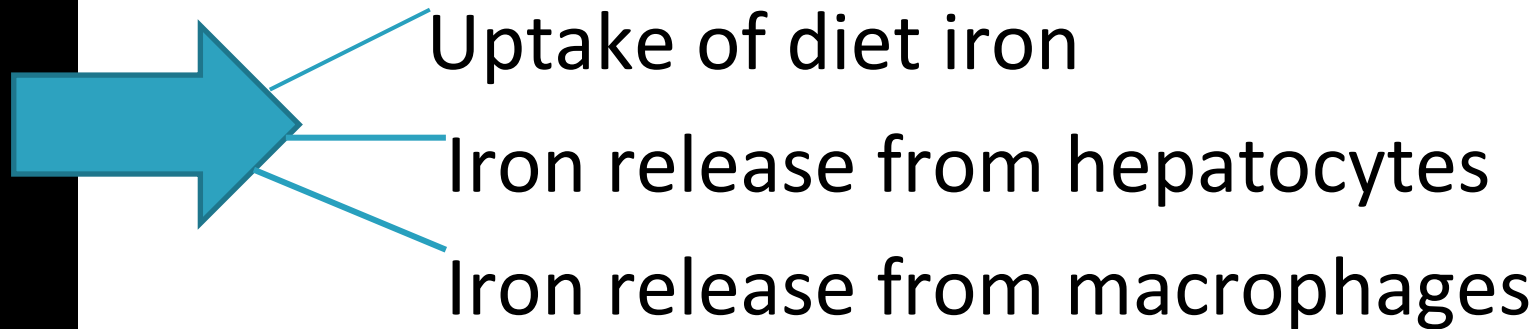
- Hepcidin lowers iron absorption in the intestine ,lowers iron releasing from hepatocytes and macrophages



Serum iron is decreased

Regulation of Hepcidin synthesis by anemia and hypoxia

• Oxygen ↓ → Hepcidin ↓



Regulation of Hepcidin synthesis by inflammation

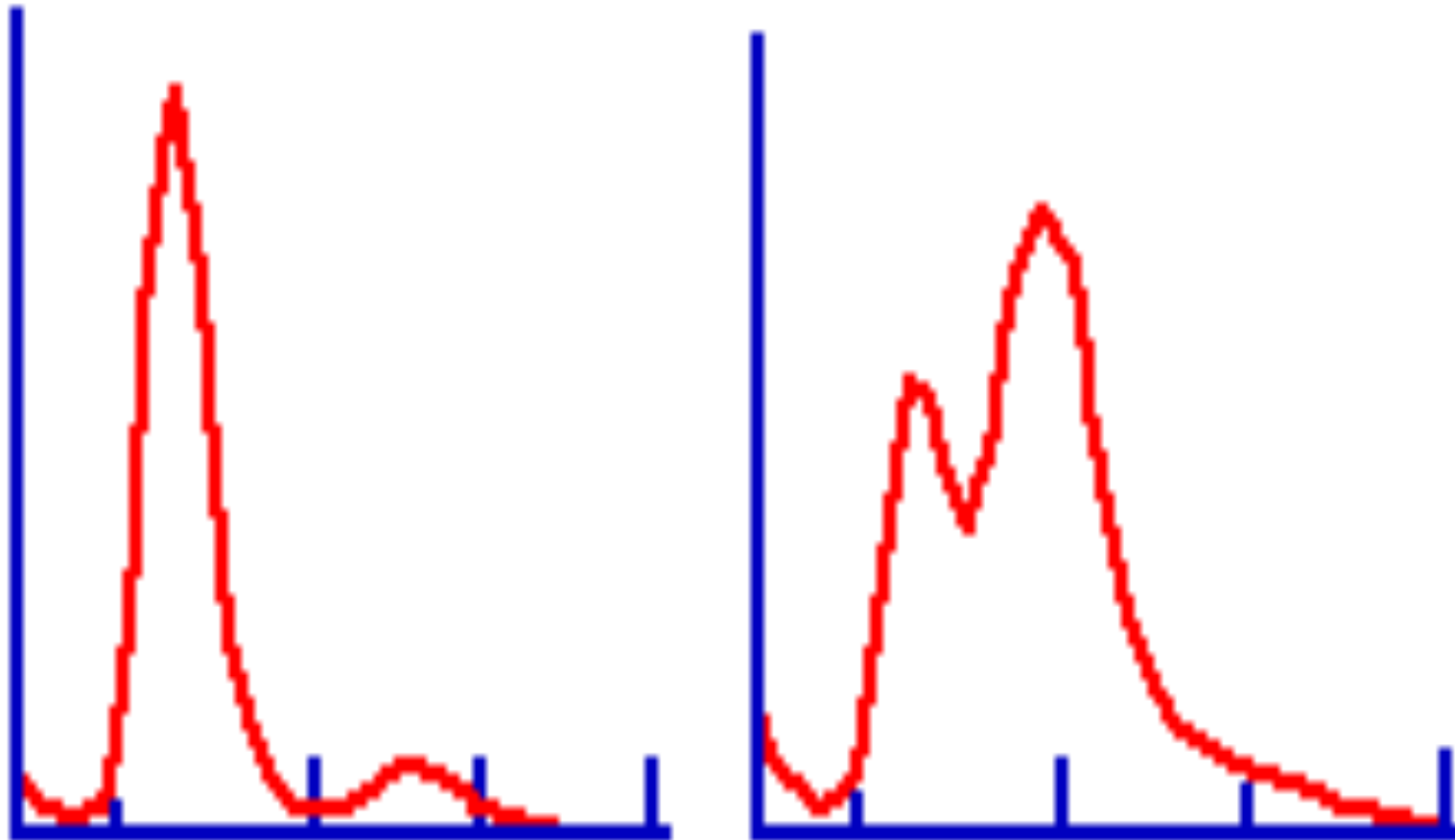
❖ Interleukin-6 ↑ → Hepcidin ↑

→ iron ↓ → anemia of chronic disease.

Disease States

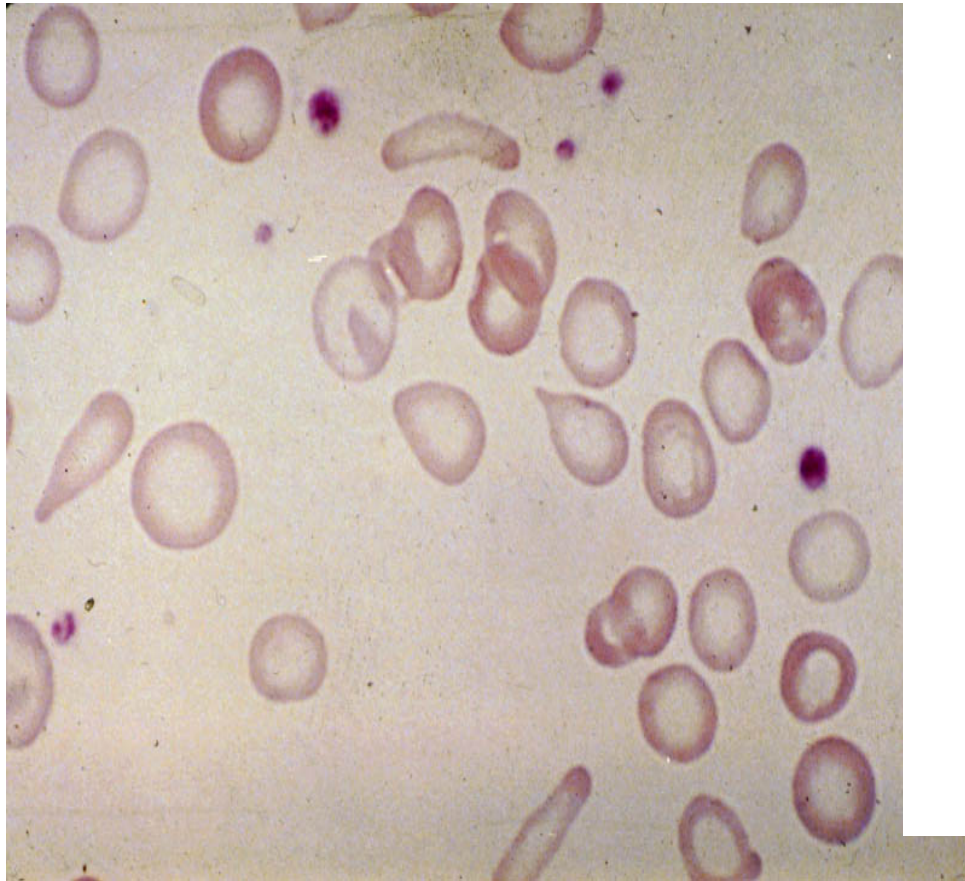
- ❖ Hepcidin deficiency, physiological = Haemochromatosis
- ❖ Hepcidin excess – anaemia of chronic disease

RDW: Normal + Abnormal

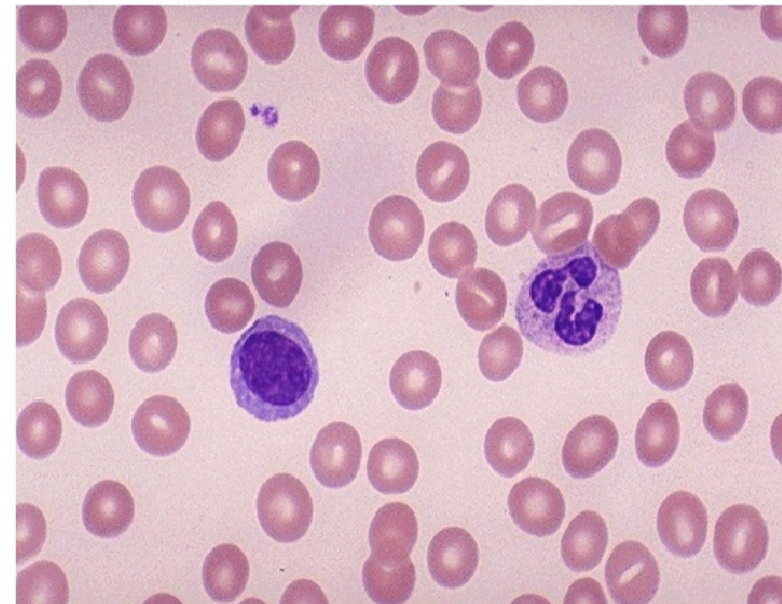

divide the standard deviation of the RBC volume by the MCV
and multiply by 100

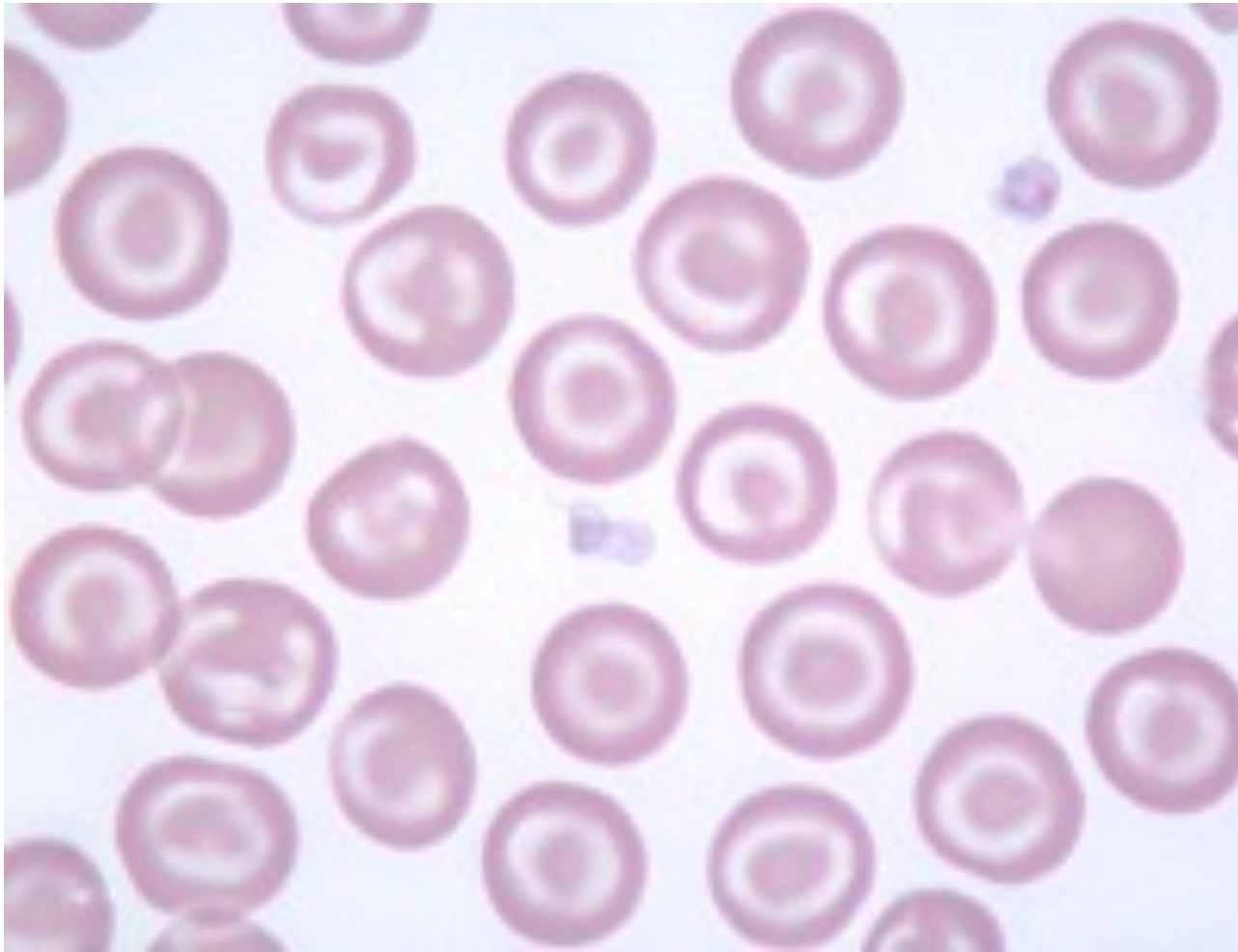
Severe Hypochromia & Anisocytosis, Poikilocytosis: Iron Deficiency Anemia



Normal Smear



Hypochromia with target cells but without Anisocytosis: Thalassemia Trait



Major Categories of the cause of IDA

- 1- Nutritional: poor or absent red meat consumption
- 2- Blood loss: GI/GU/: benign or malignant lesions. Hemosiderinuria
- 3- Malabsorption: Gluten enteropathy
- 4- Repeated pregnancies

Case one

24 yr old female complains of

Dizziness, Fatigue, Shortness of breath especially on exertion and Headaches for the last 4 months. She has been losing scalp hair.

She does not eat red meat and has reported heavy menstrual bleeding.

Her physical exam is shown

Lab and Xray test are shown

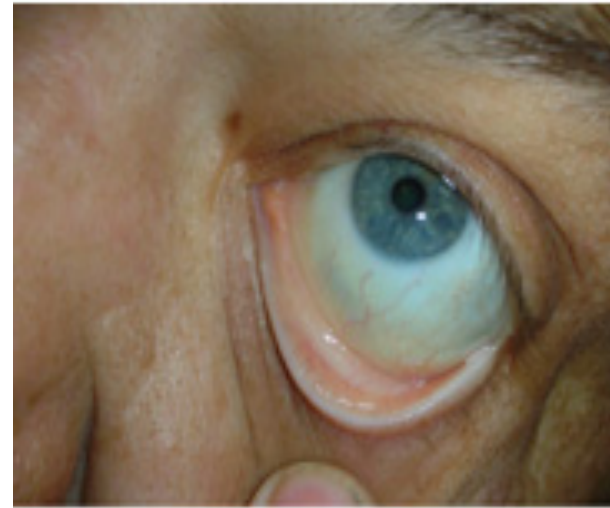
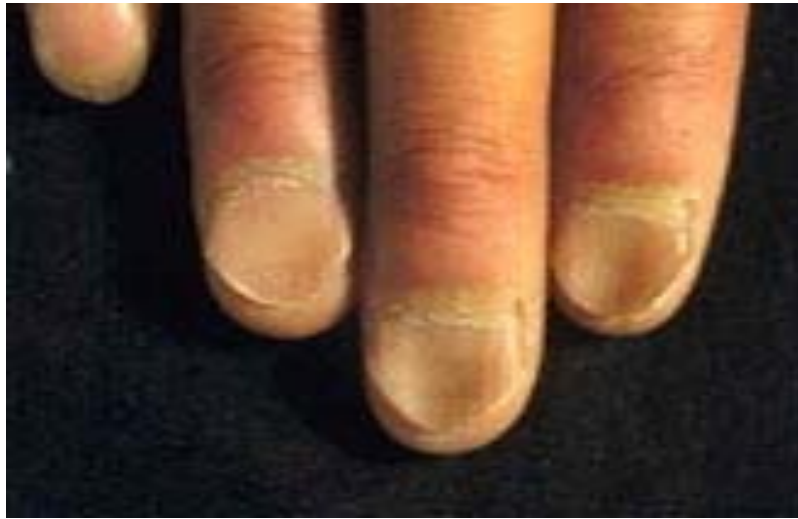Likely Diagnosis

Case Onecontinuation

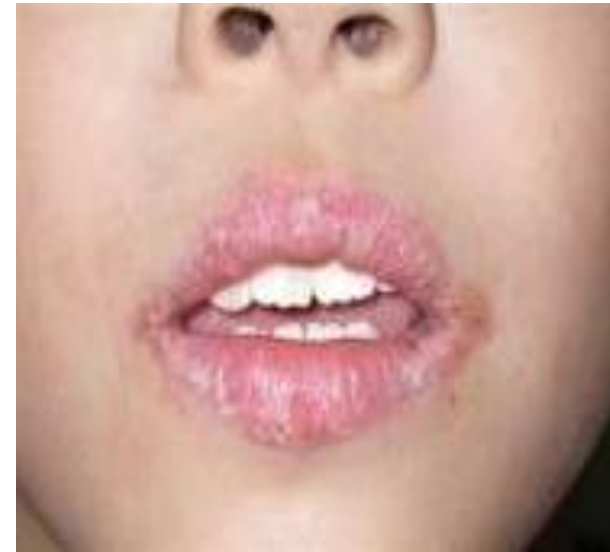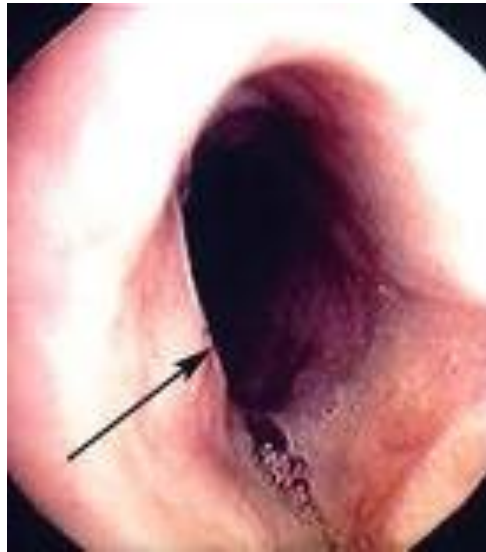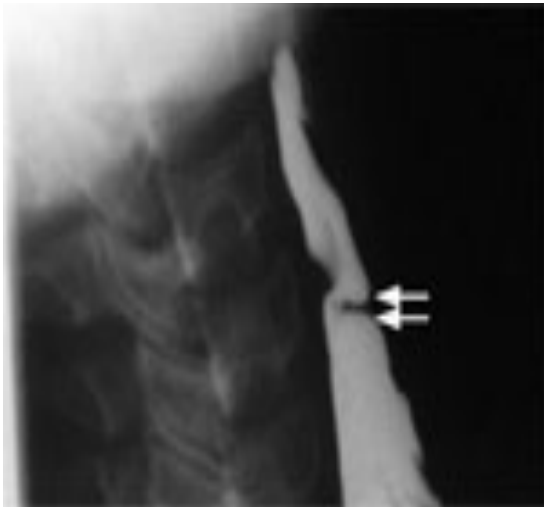
Lab: Hb 8, MCV 72, RDW 19, MCH 20pg. WBC
8000/Normal dif.Plts 380000

Bld Film: microcytic, hypchromic, anisocytosis,
poikilocytosis, Retics (corrected) 0.8%

Serum Ferritin 2



A



Hb Electrophoresis?? Serum B12,
Folate??

S Fe, TIBC??, BM ??? GI
endoscopy??, Investigate for
bleeding disorder: VWD?, celiac
disease?

Gyne consultation

GI consultation

Treatment/ Follow up of Case 1

1- Oral Iron: Fe gluconate, sulphate

2- educate

3- IV Fe?? Fe sucrose/carboxymaltose or new Fe dextran

Follow up: check CBC every month :
expected Hb rise $\pm 1\text{g}/ 10$ days. Check
Ferritin at 3 months. Follow other
investigations and consultations

Differential Diagnosis of Microcytic Anaemia

- Thalassaemia syndromes
- Certain haemoglobinopathies (Hb C)
- True (classical) iron deficiency secondary to blood loss, iron-poor diet, increased iron needs, *Helicobacter pylori* infection or gastric pathology
- Anaemia of chronic inflammatory diseases
- Certain forms of sideroblastic anaemia
- Genetic forms of iron deficiency anaemia

Case one B

60 yr old male complains of :Dizziness, Fatigue, Shortness of breath especially on exertion and Headaches for the last 2 months. He has constipation and weight loss 5 kg over 2 months.

Lab: Hb 8, MCV 72, RDW 19, MCH 20pg. WBC 8000/Normal dif.Plts 380000

Bld Film: microcytic, hypchromic, anisocytosis, poikilocytosis, Retics (corrected) 0.8%

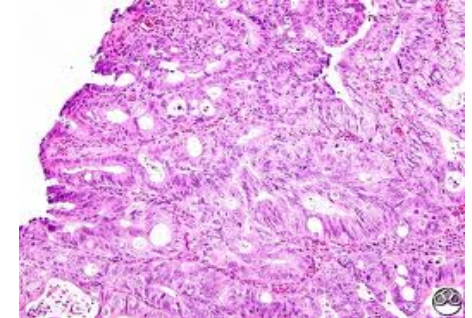
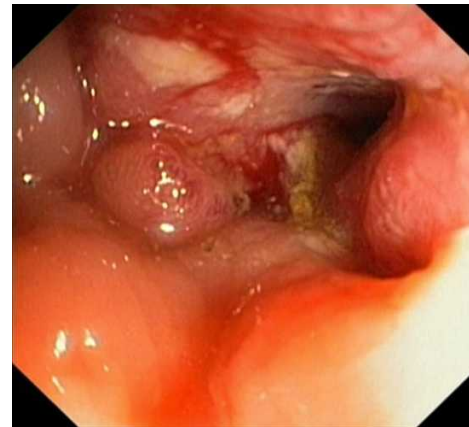
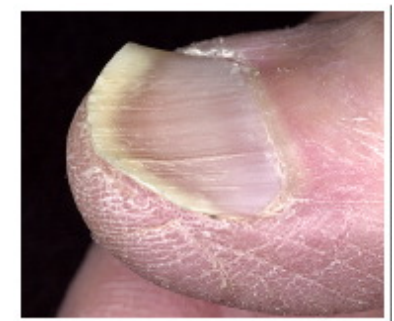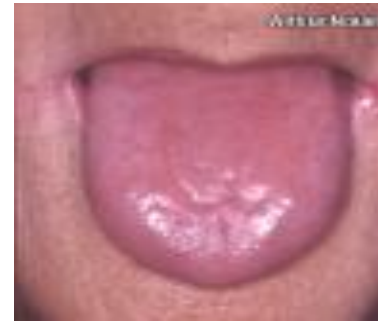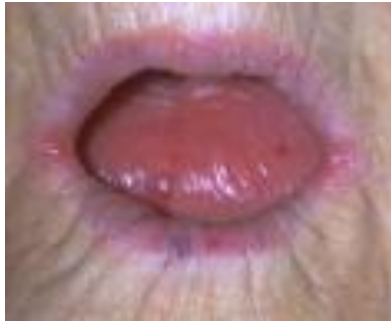Serum Ferritin 2. FOB x 3 positive in 2.

Case One B

Findings:

**Diagnosis: Colon
adenocarcinoma
Mod. dif.**

**Always Look for a
cause for IDA.
Anemia must have a
full identification**



Anemia is **not a final diagnosis**

IRON DEFICIENCY ANEMIA **IS NOT A DIAGNOSIS**
PER SAY.

ALWAYS PUT A LABEL TO IT:

**IDA DUE TO UPPER GI BLEEDING DUE TO
GASTRIC CANCER**