

Respiratory imaging

Asma S Albitoosh,MD

Jordan university hospital

CXR interpretation

Identification

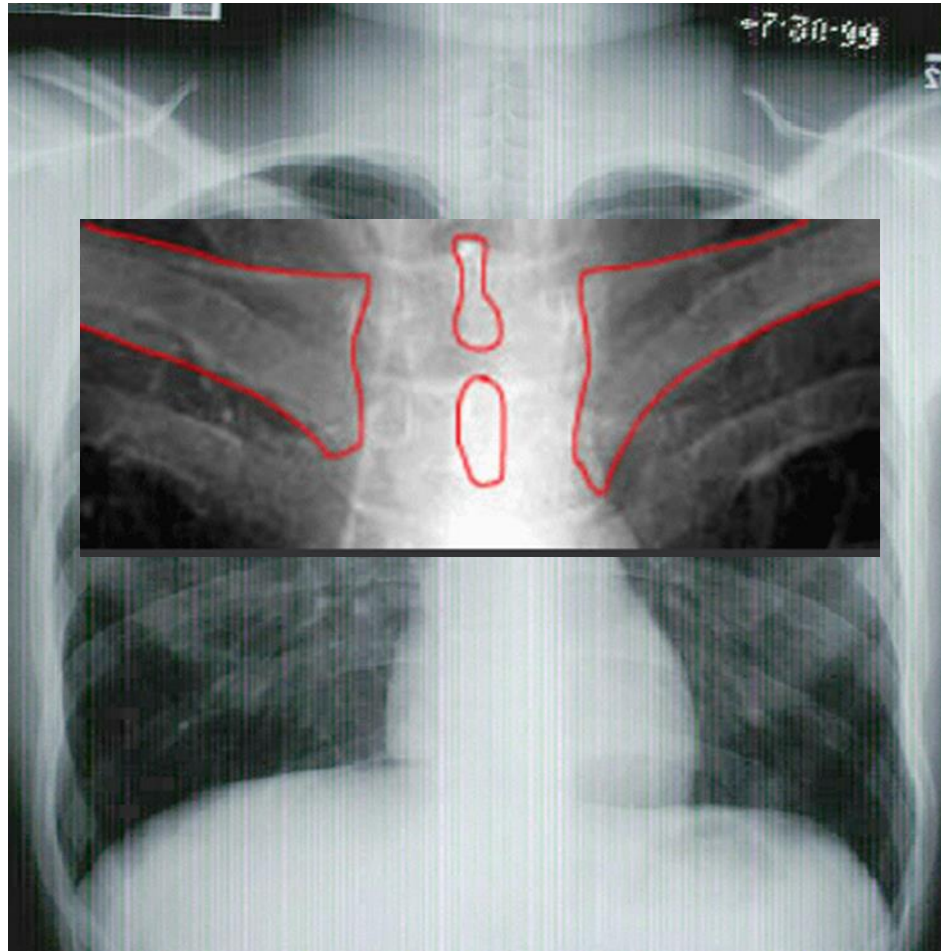
Correct patient

Correct date & time

Technique: RIPE(rotation. inspiration.
Projection, exposure)

Abnormal finding

Rotation and inspiration

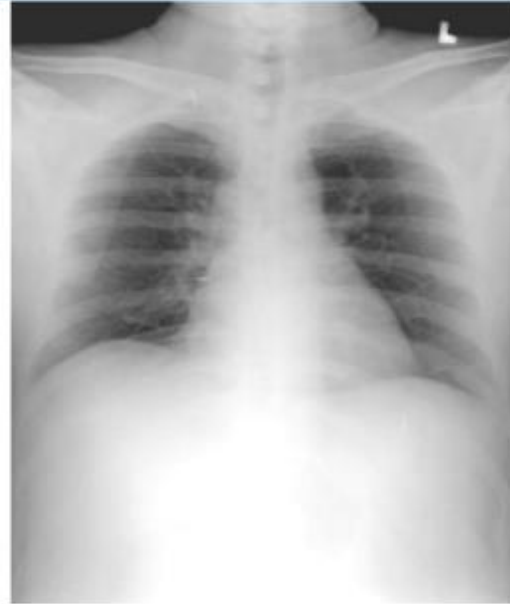
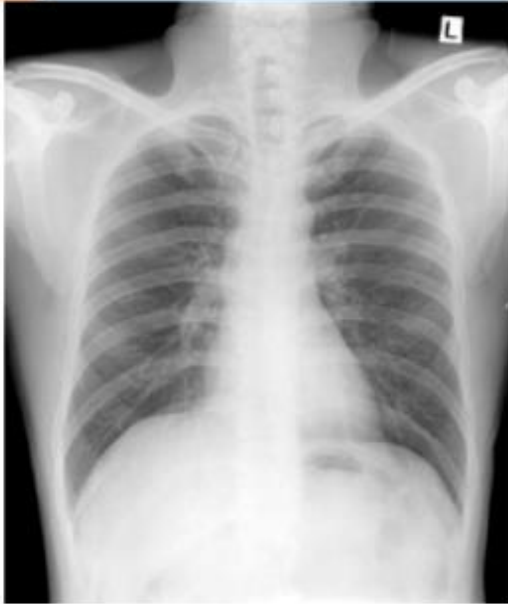
Projection

PA

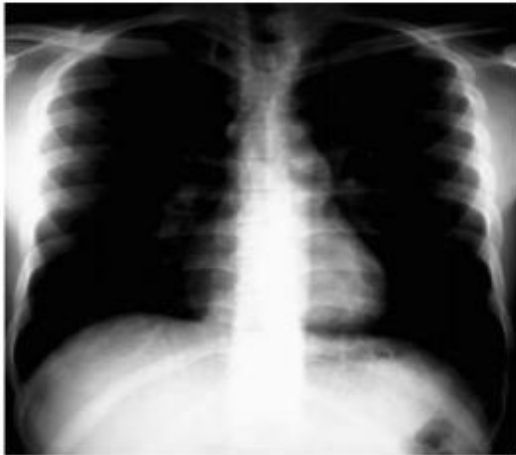VS

AP

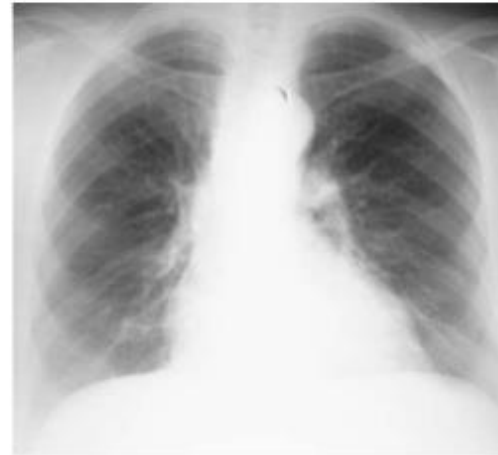

Exposure=Penetration

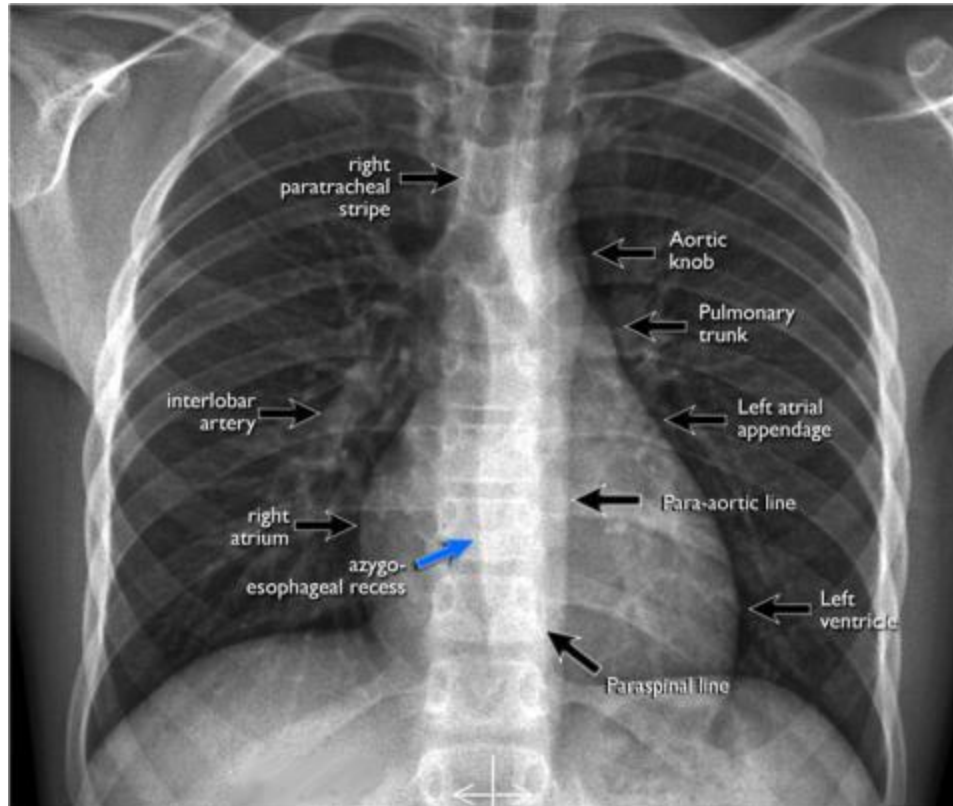
Over penetrated



Under penetrated



Normal anatomy



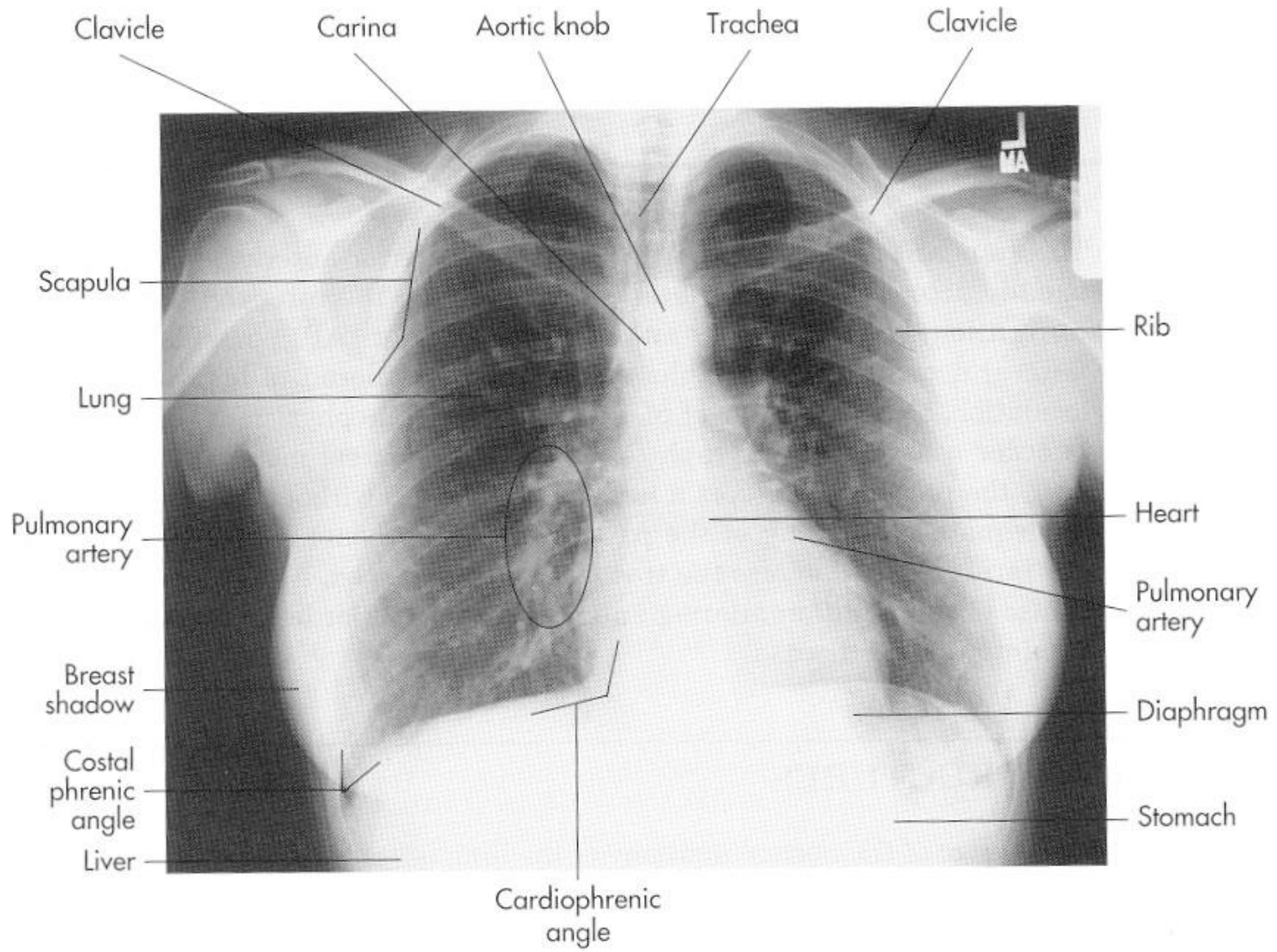
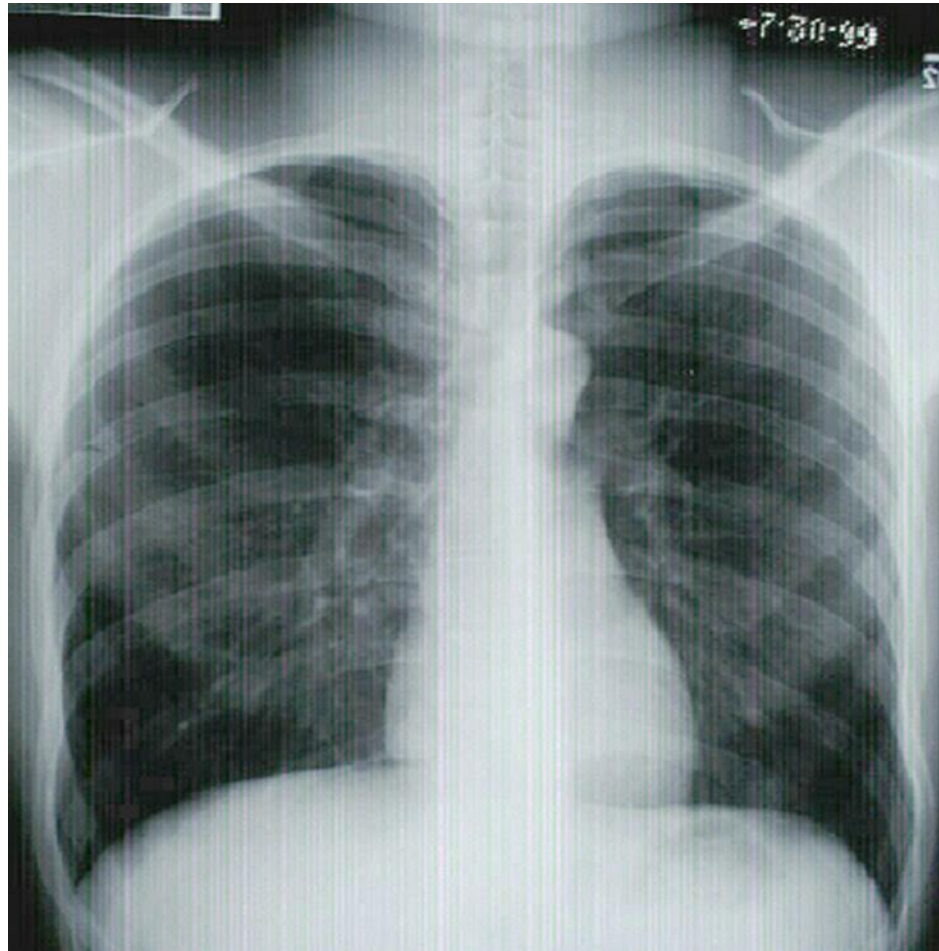
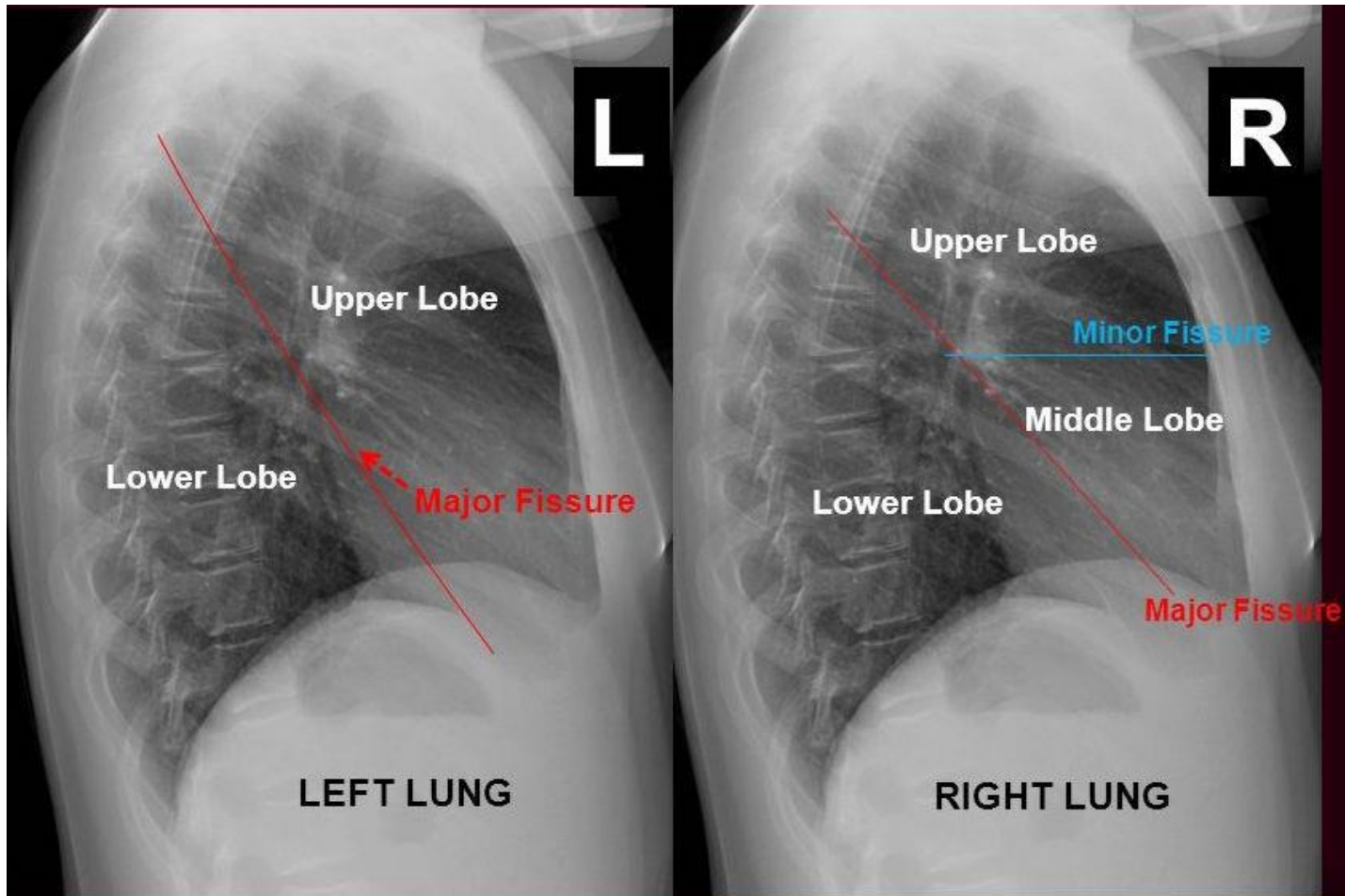


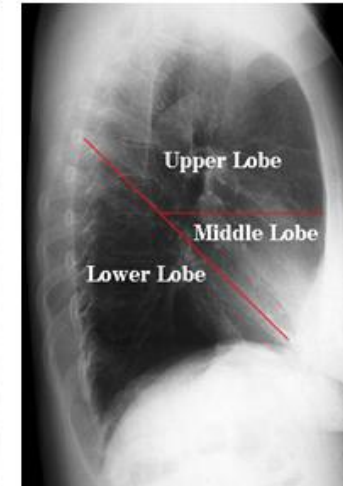
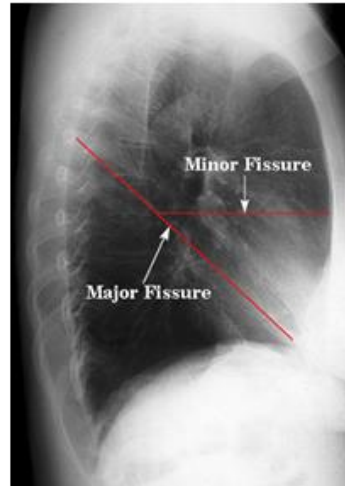
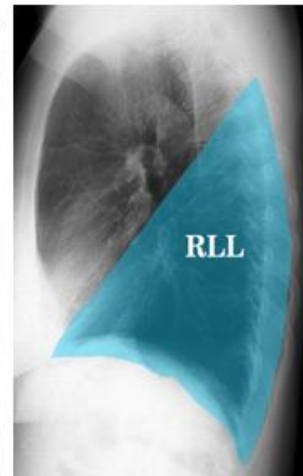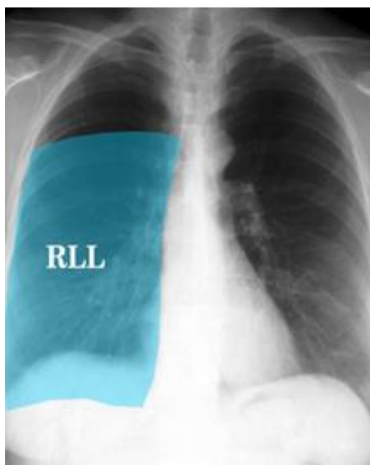
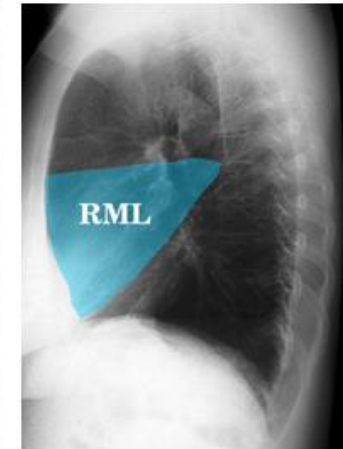
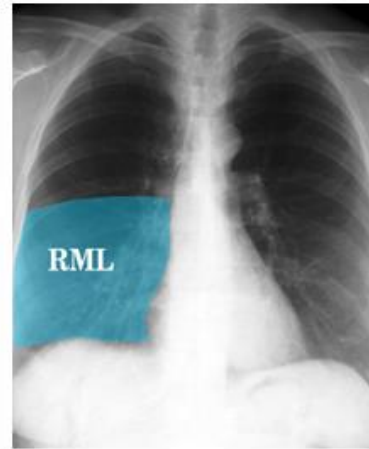
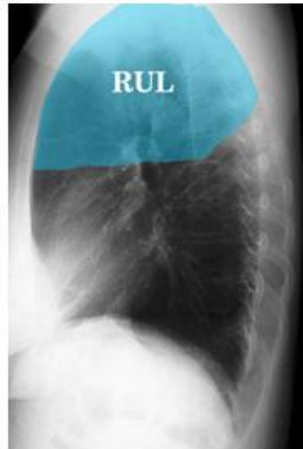
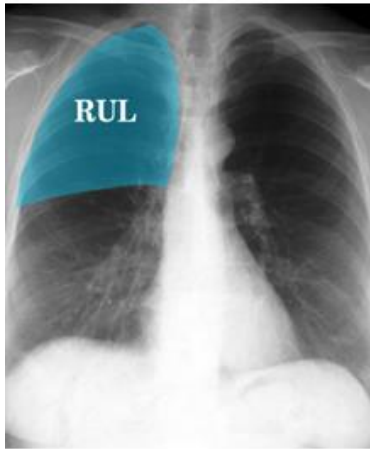
Fig. 3-1 Normal position of anatomical structures on a posterior or anterior chest radiograph.

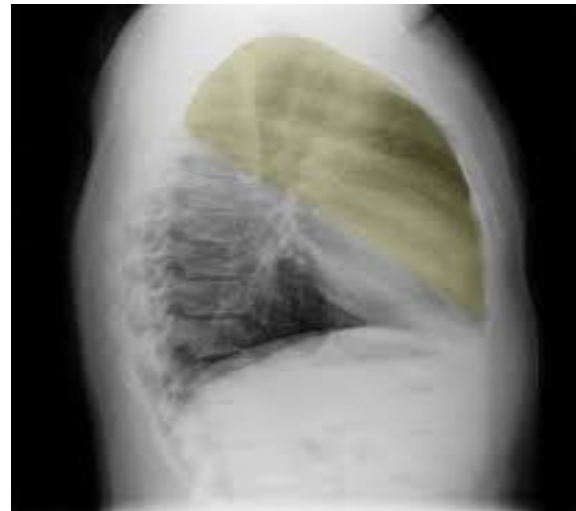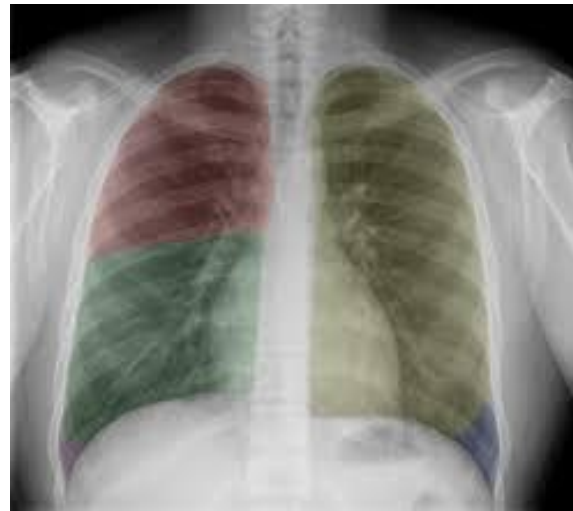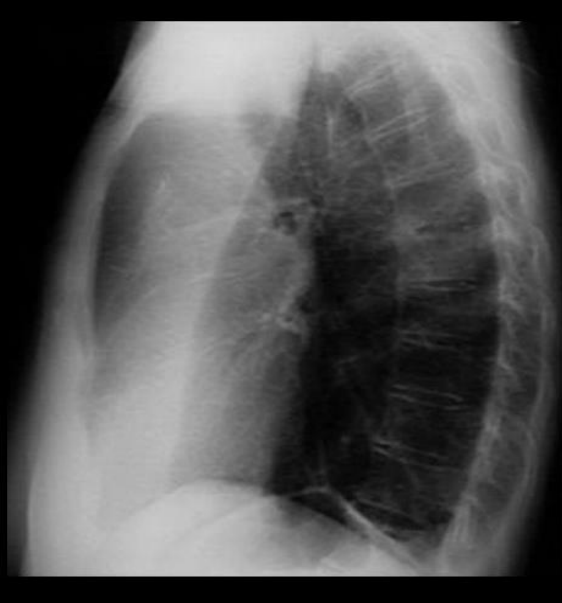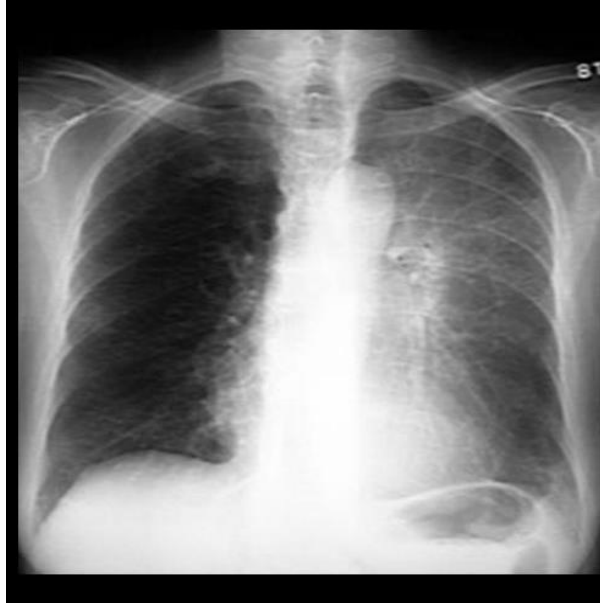Zones or lobes?



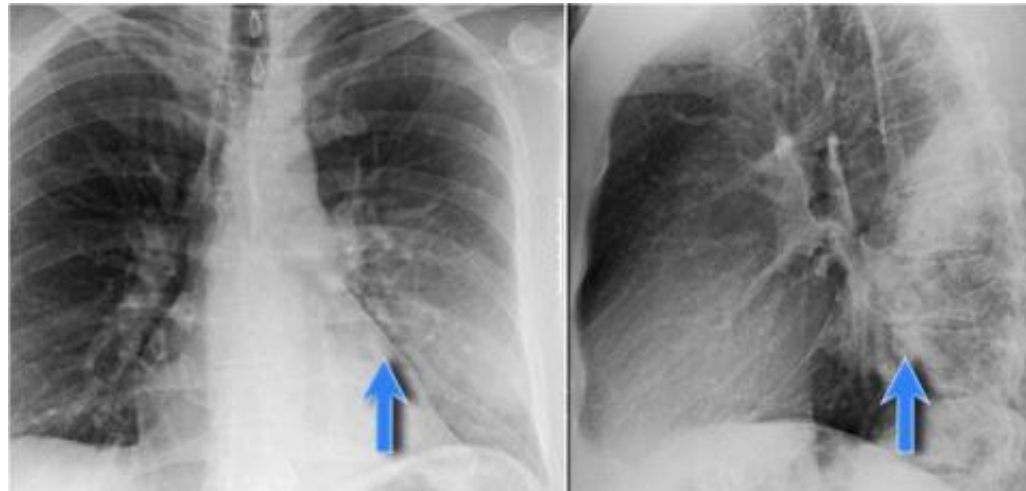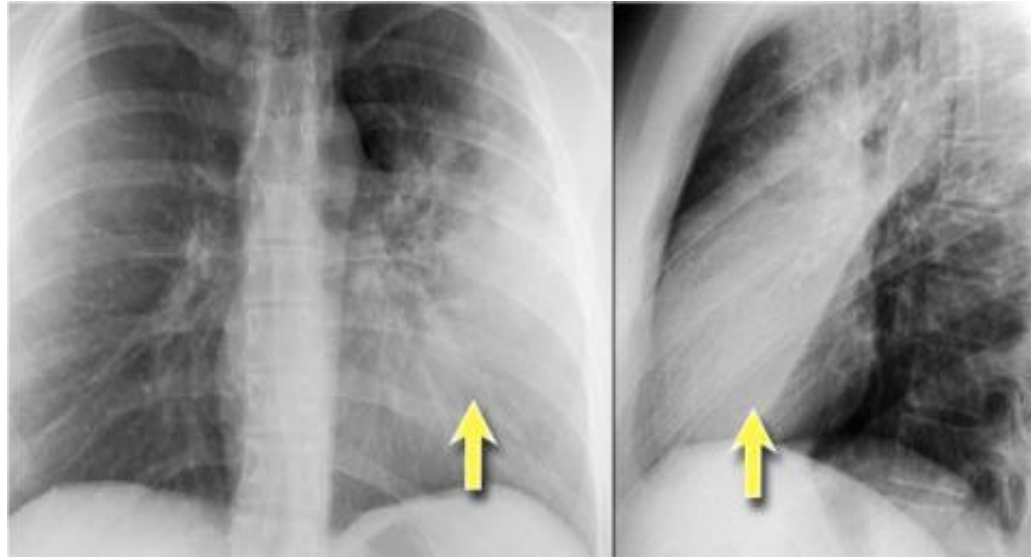
Lateral CXR







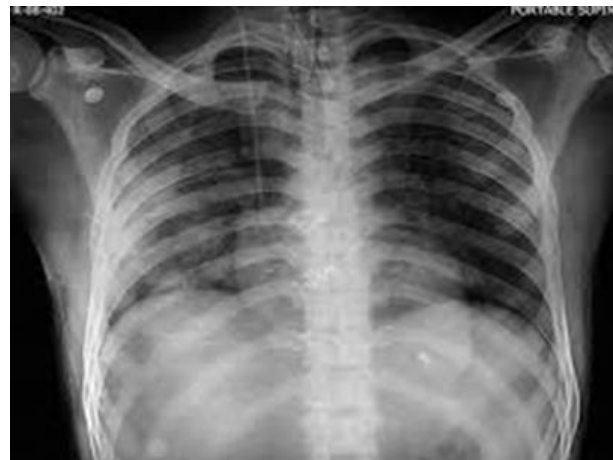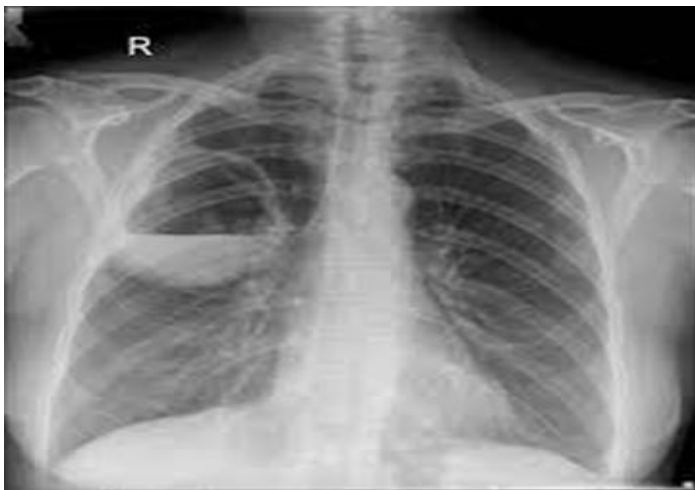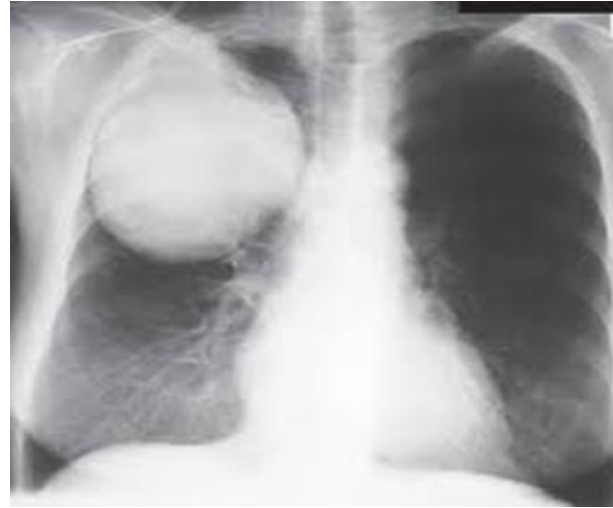
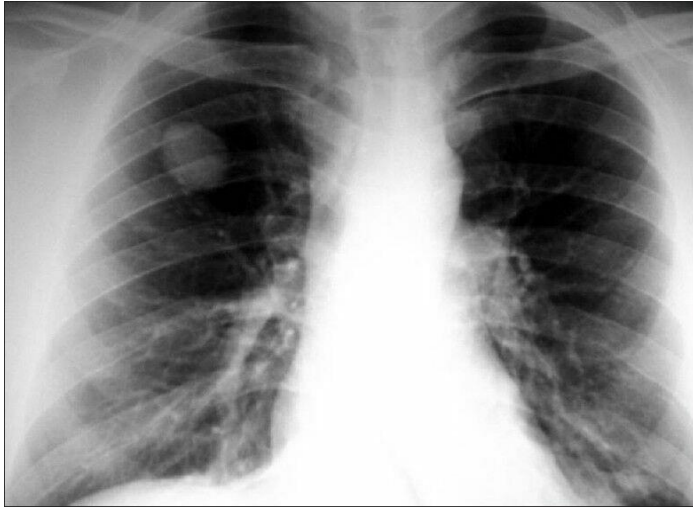
A silhouette sign



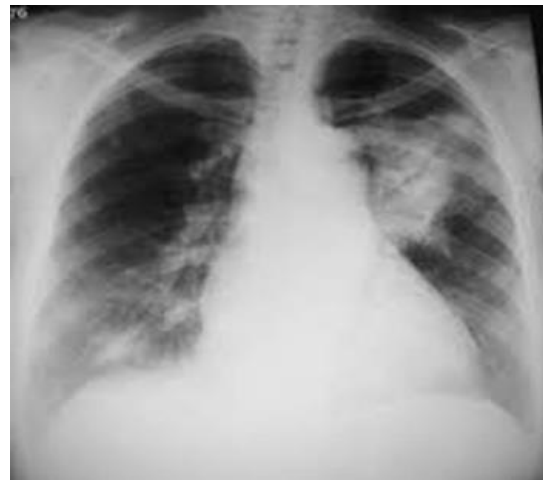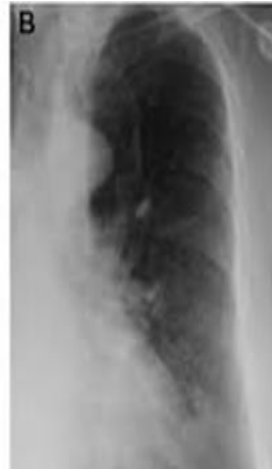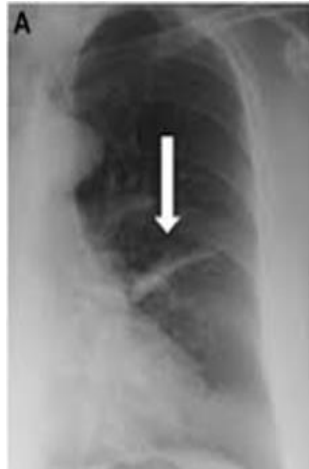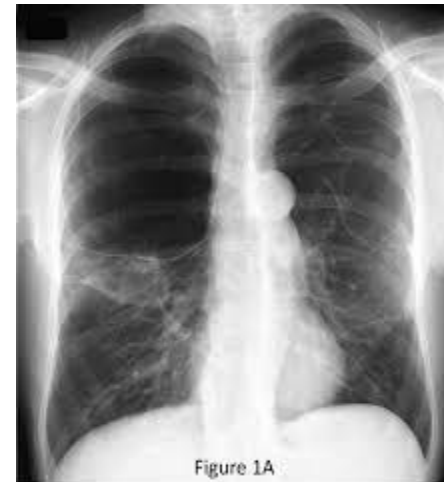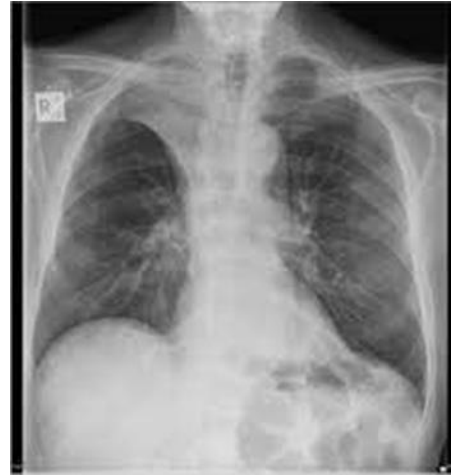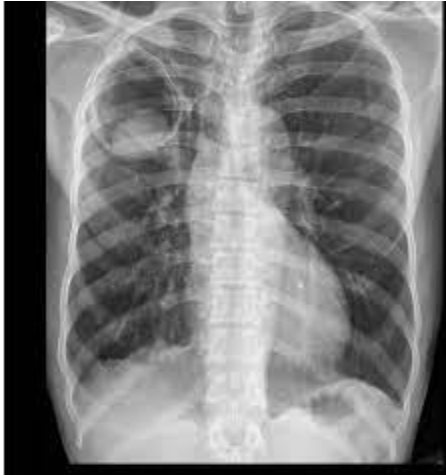ABCDE

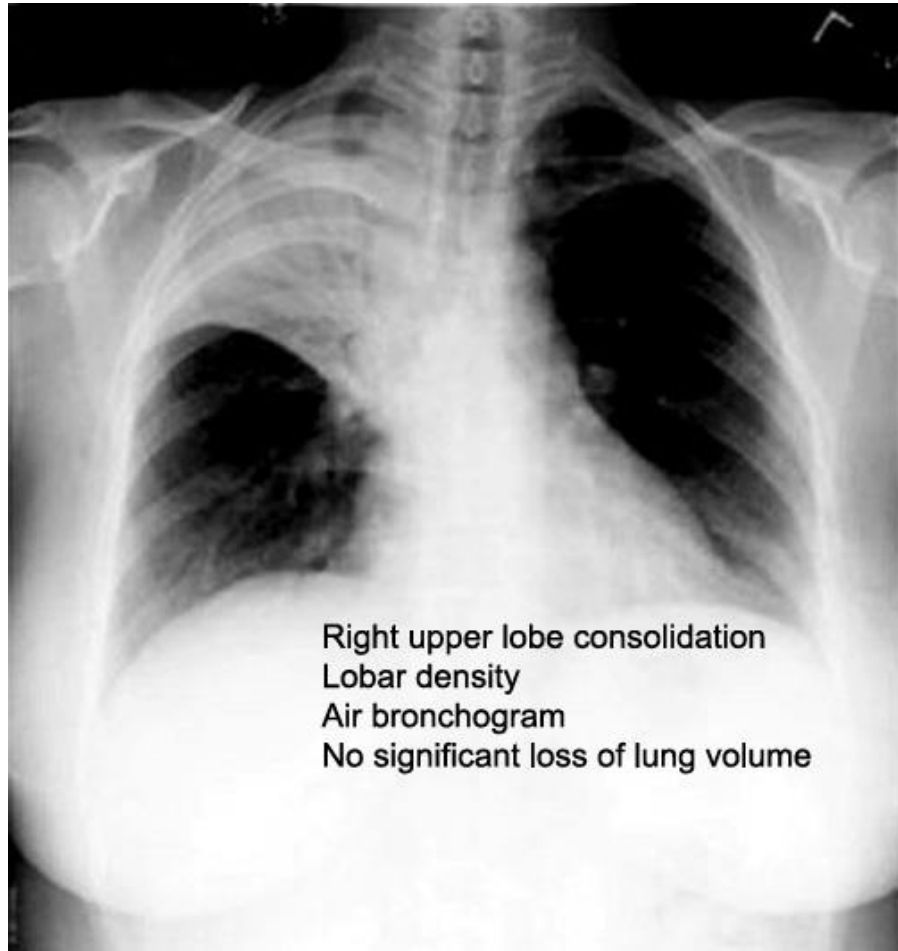
- Airway.
- Breathing.
- Cardiac, hila and mediastinum.
- Diaphragm.
- Everything else .

Focal lung lesions



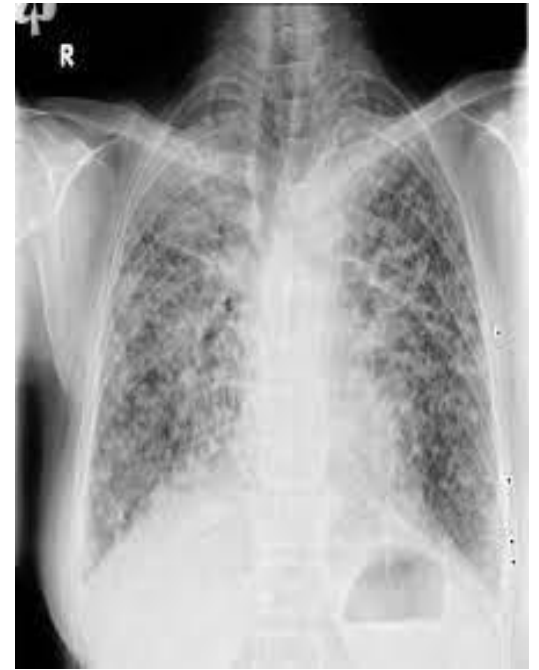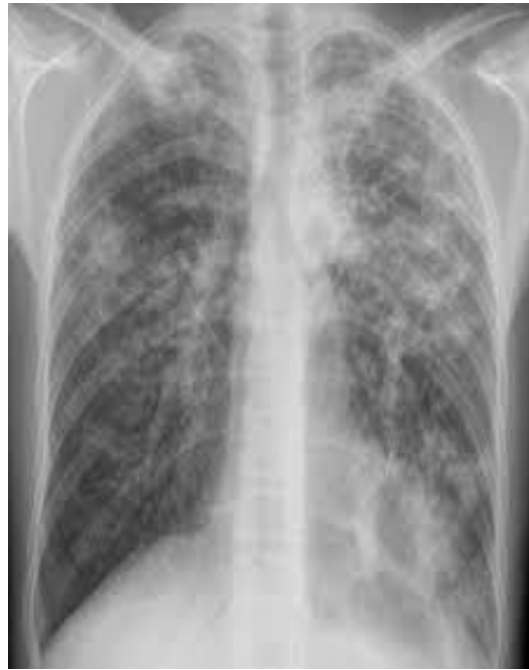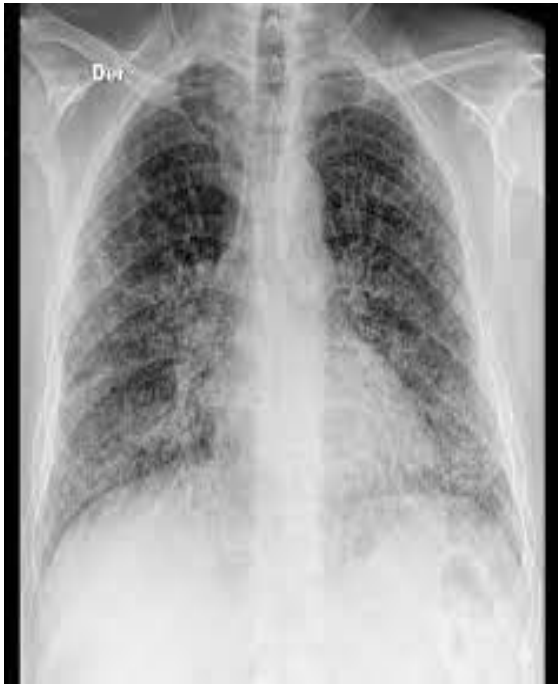Focal lung lesions. Cont'd



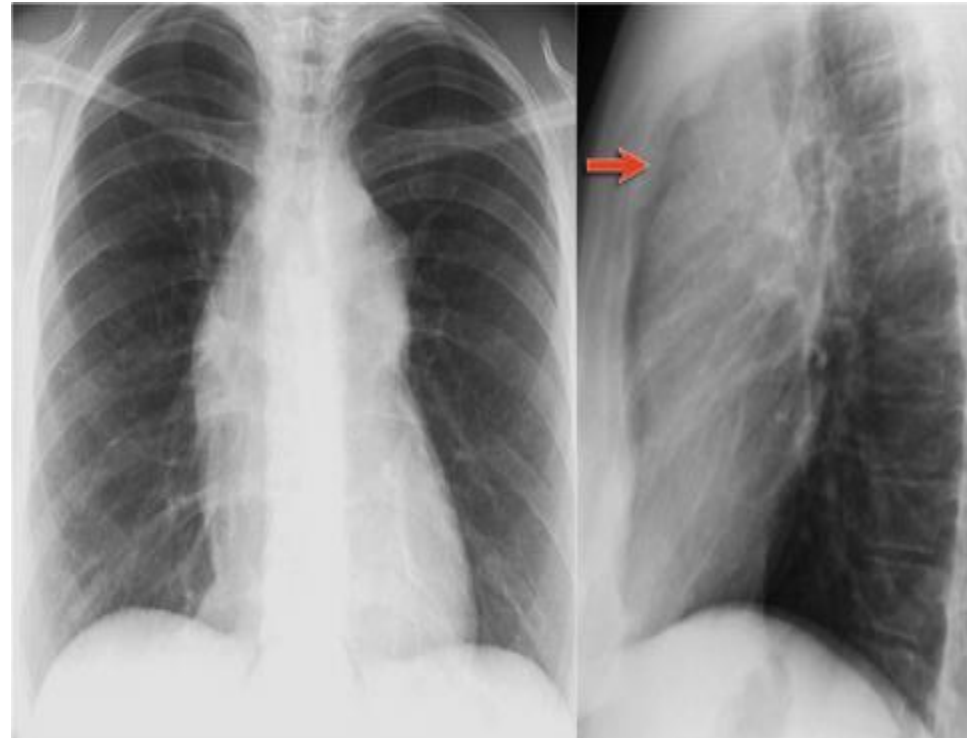
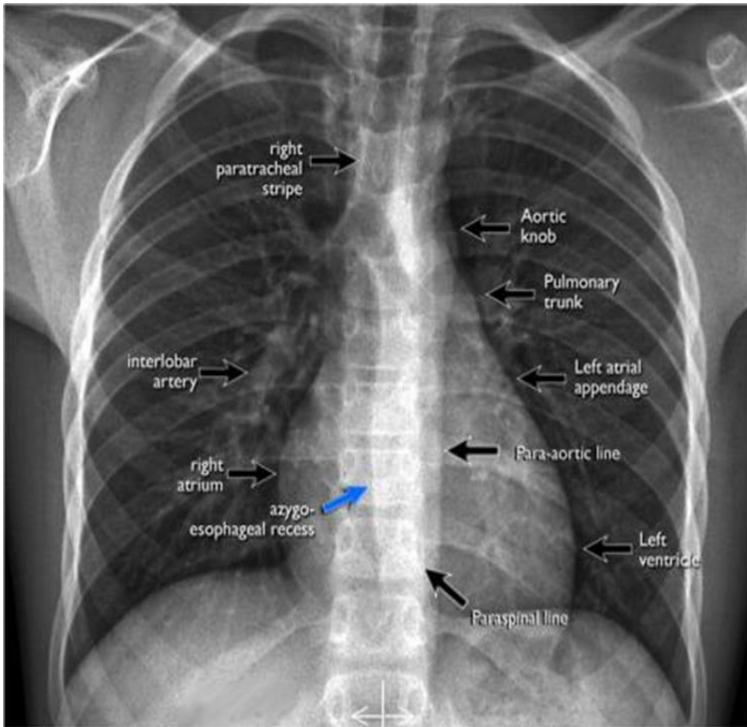


Right upper lobe consolidation
Lobar density
Air bronchogram
No significant loss of lung volume

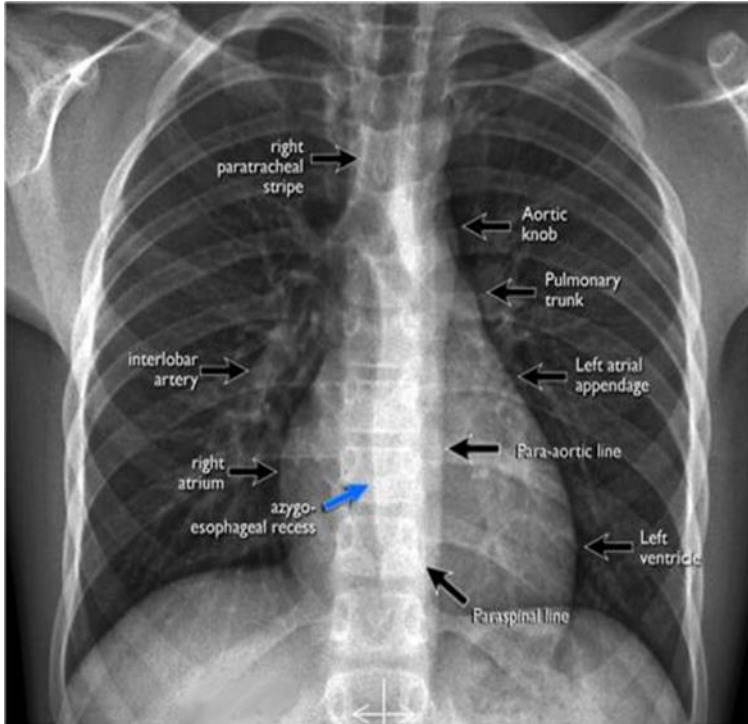
Diffuse lung lesions



Mediastinum

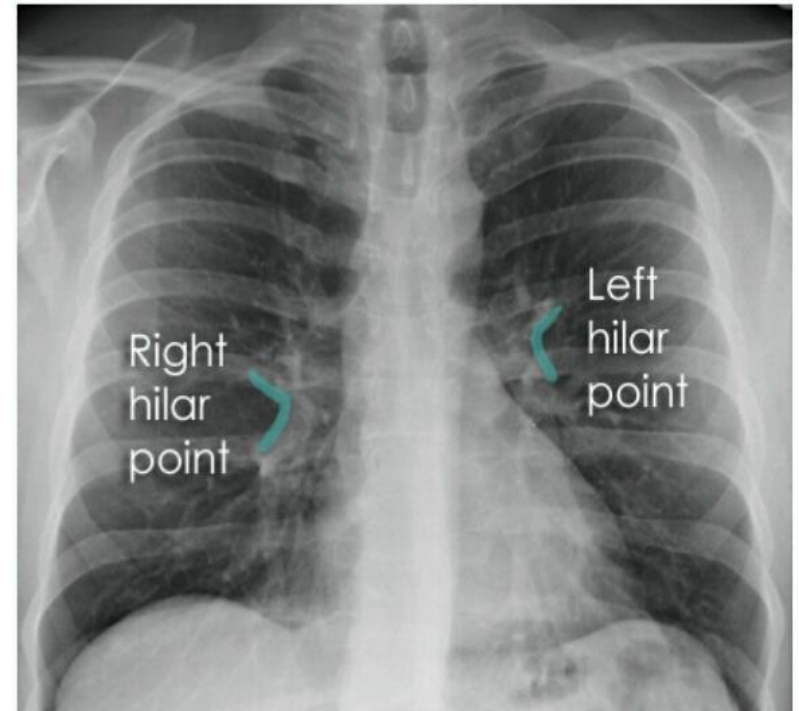


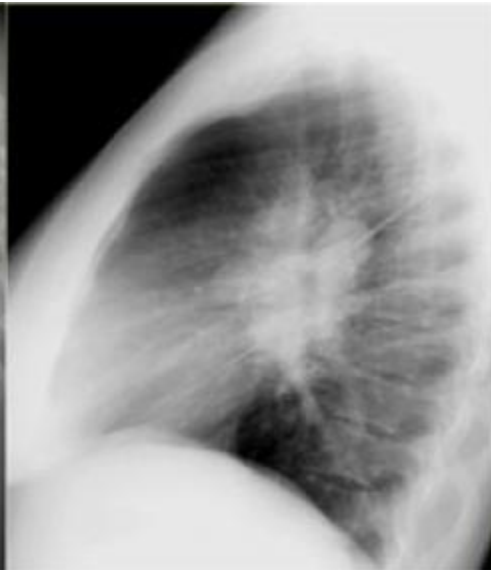
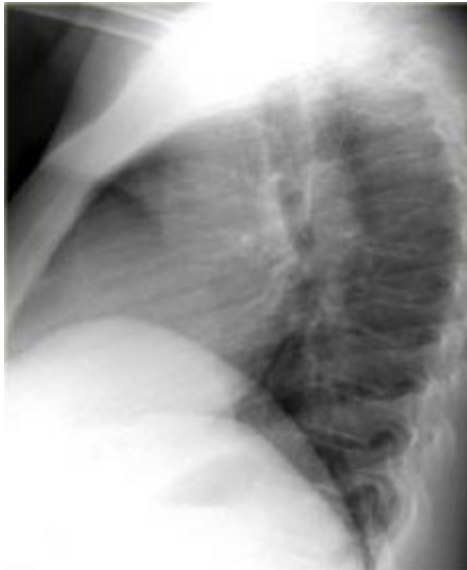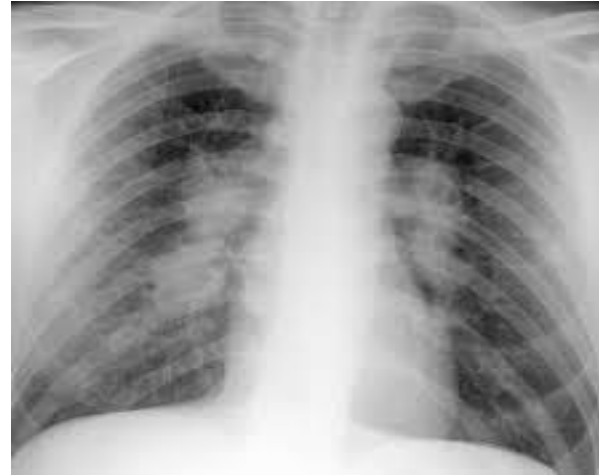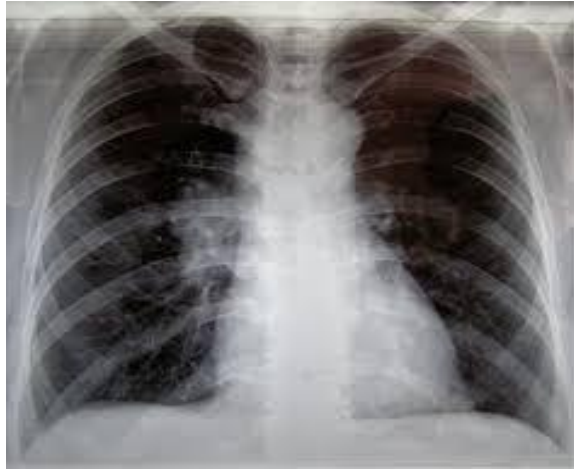
Hilum

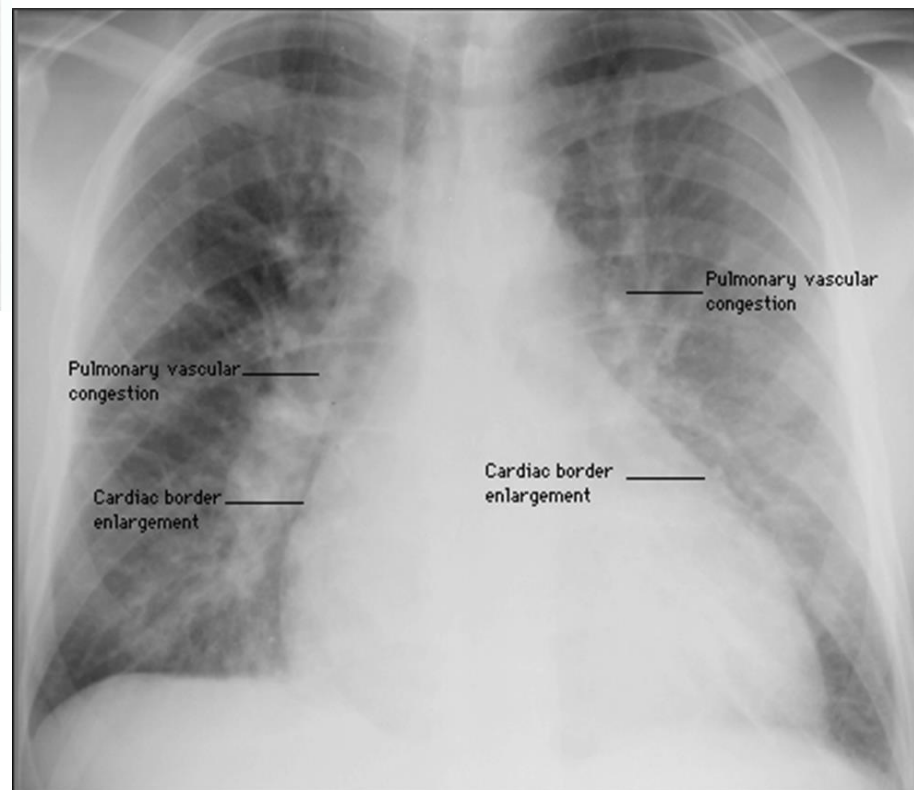
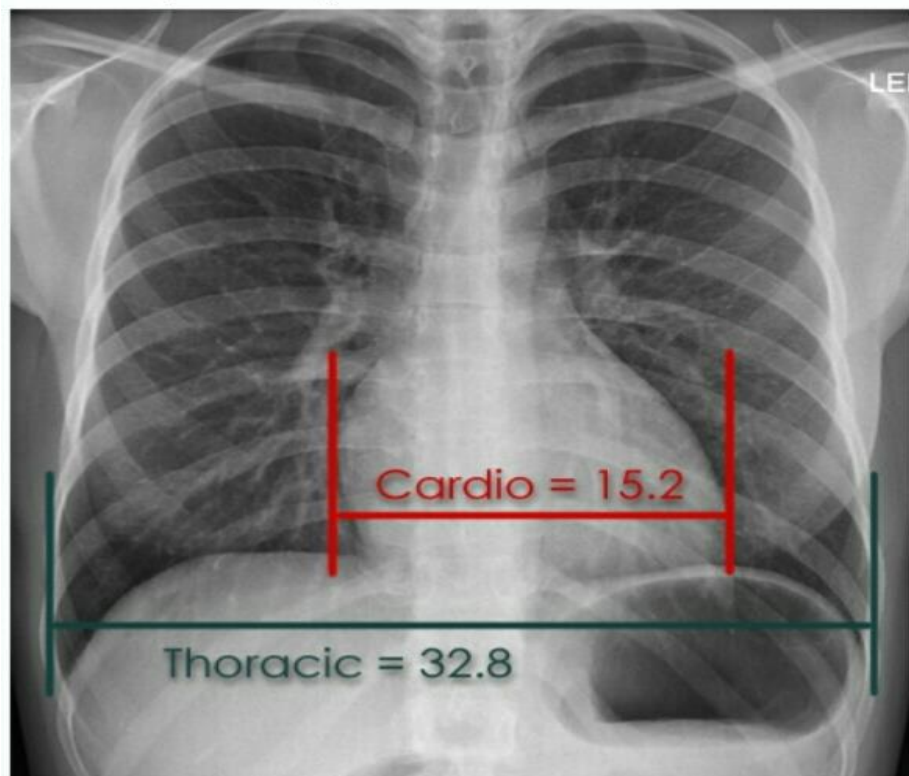


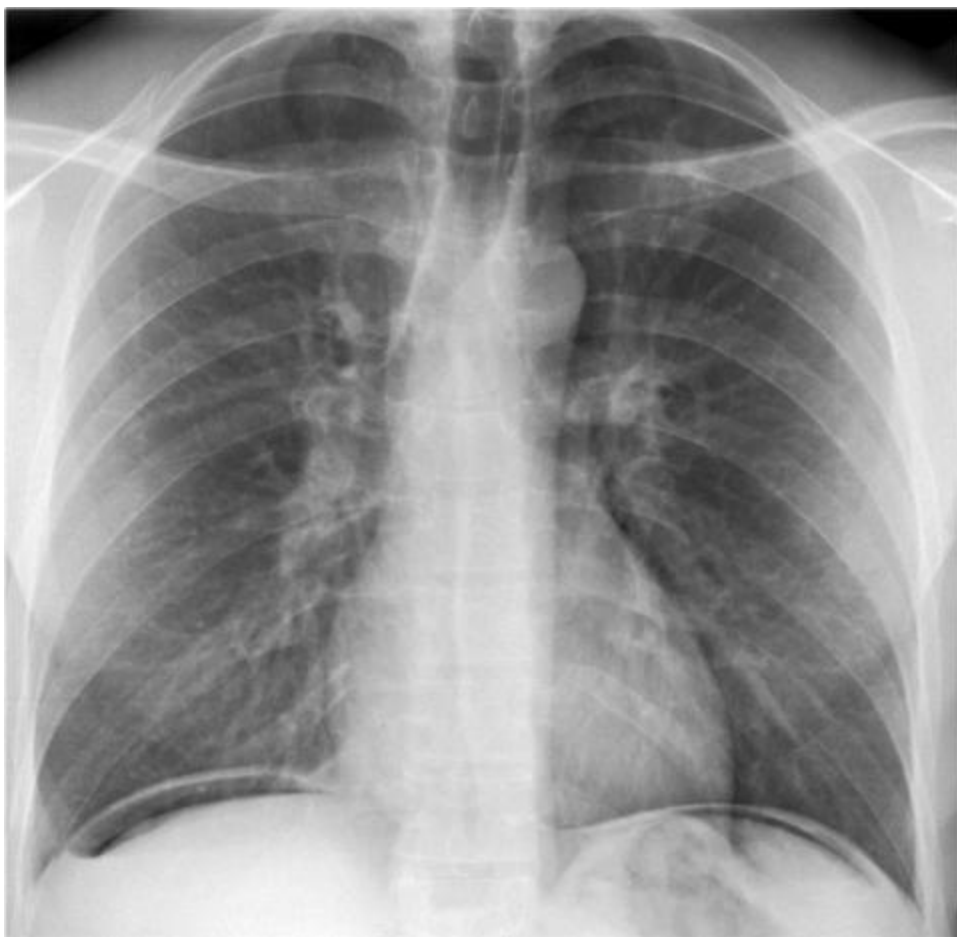Normal hilar position

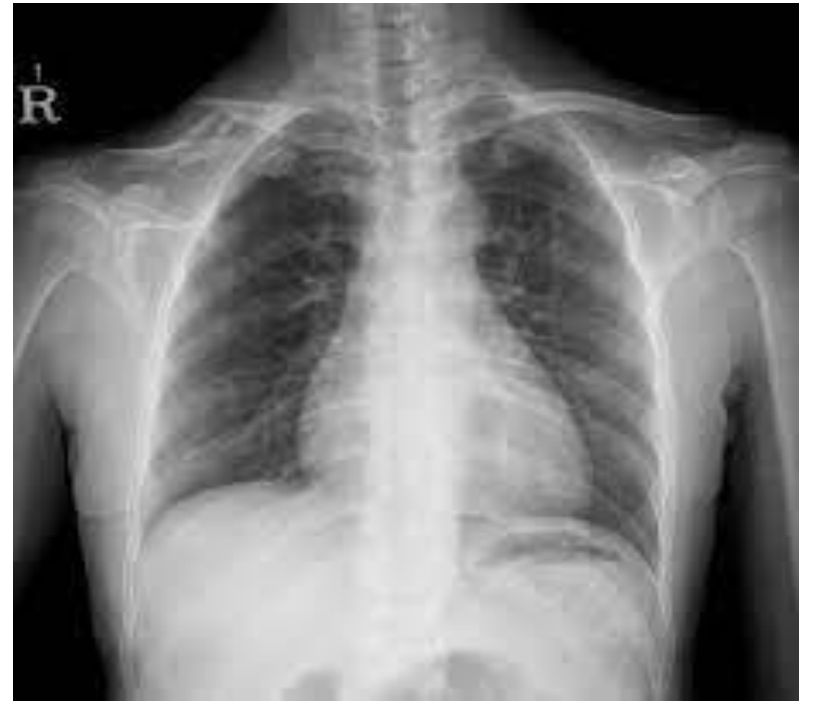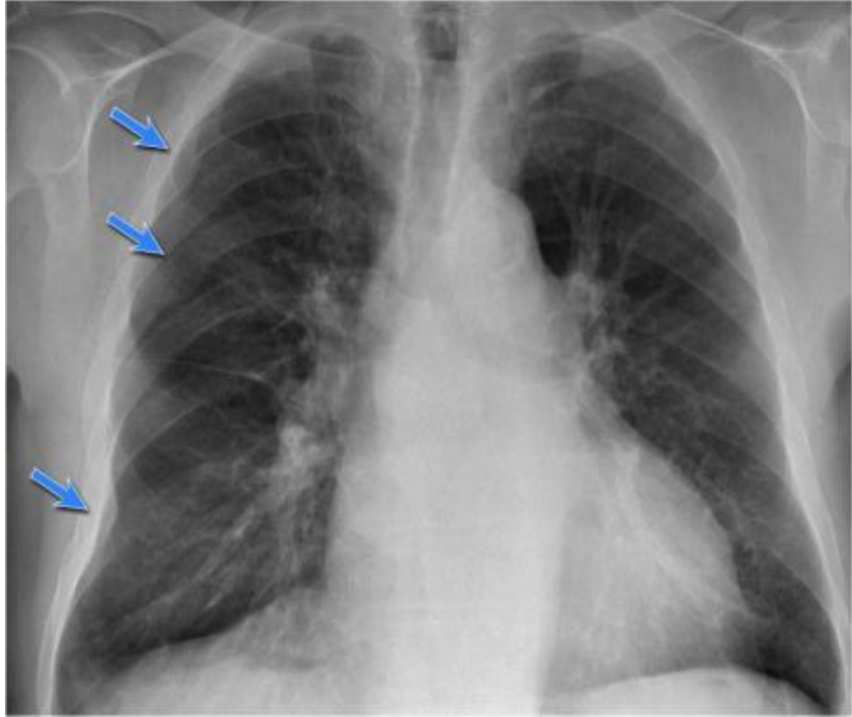
Hover over image to show findings





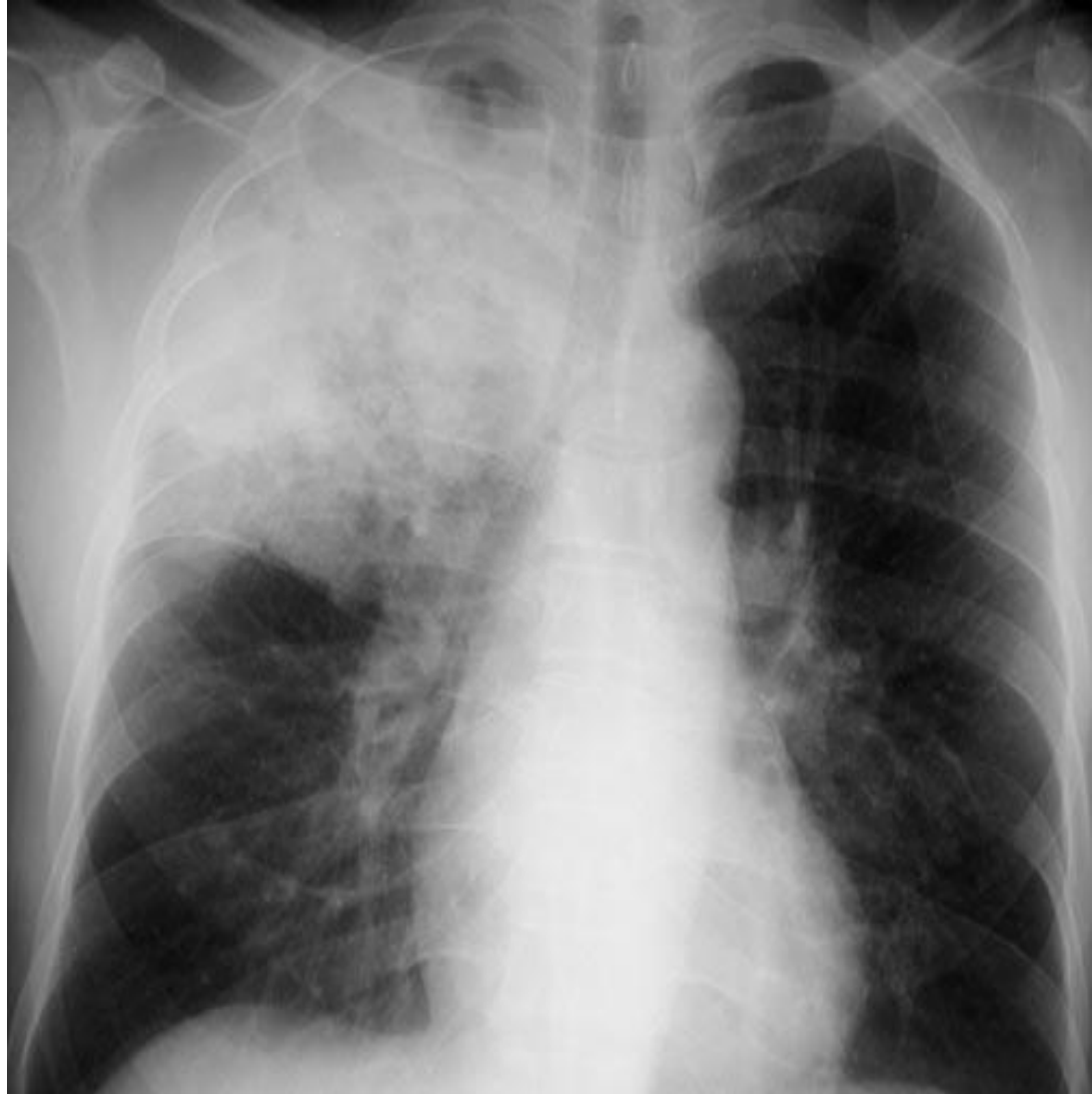

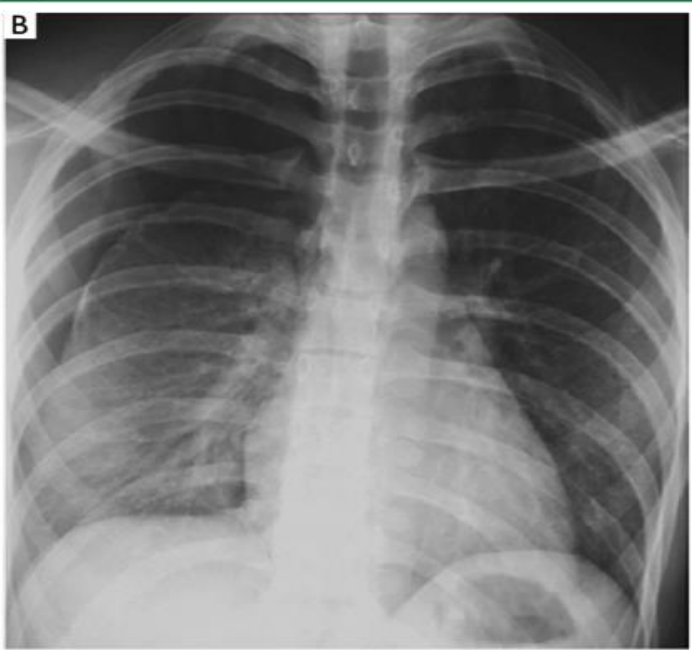
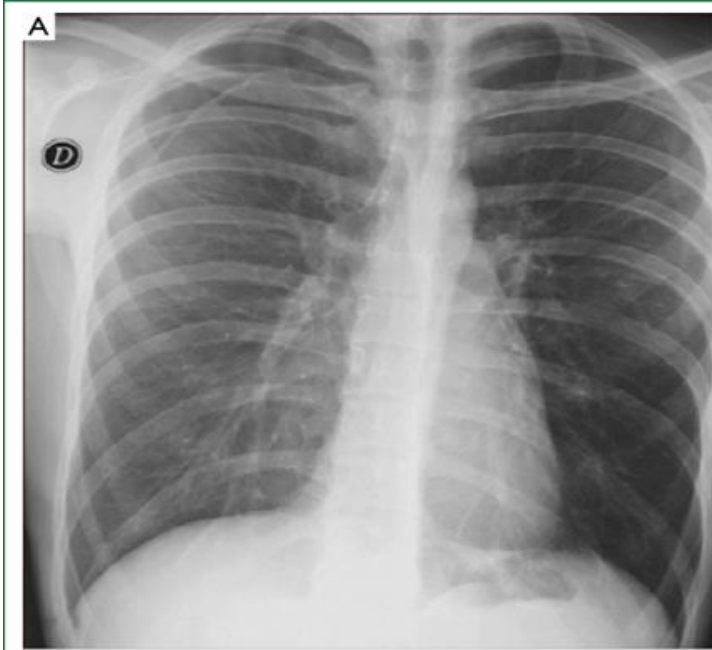

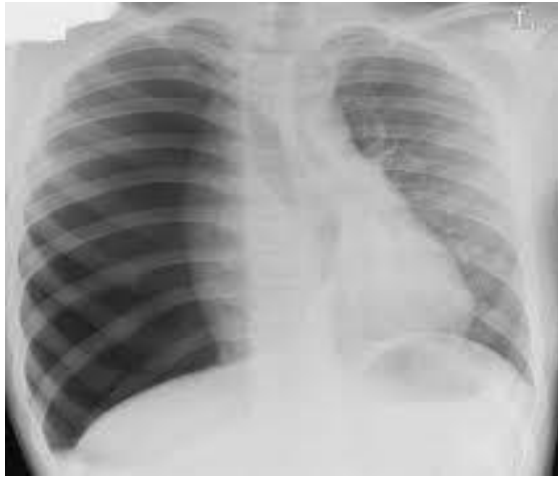
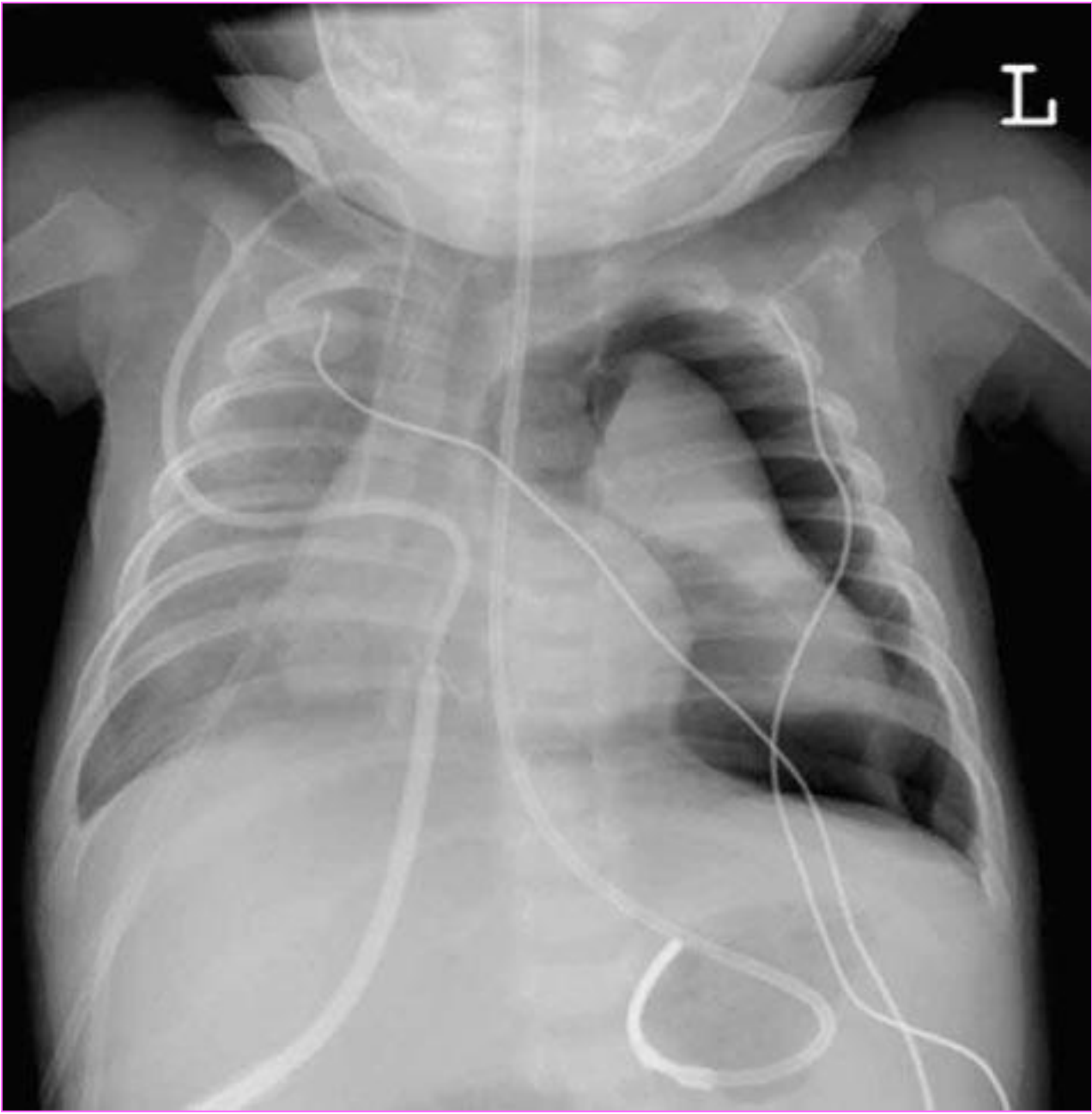


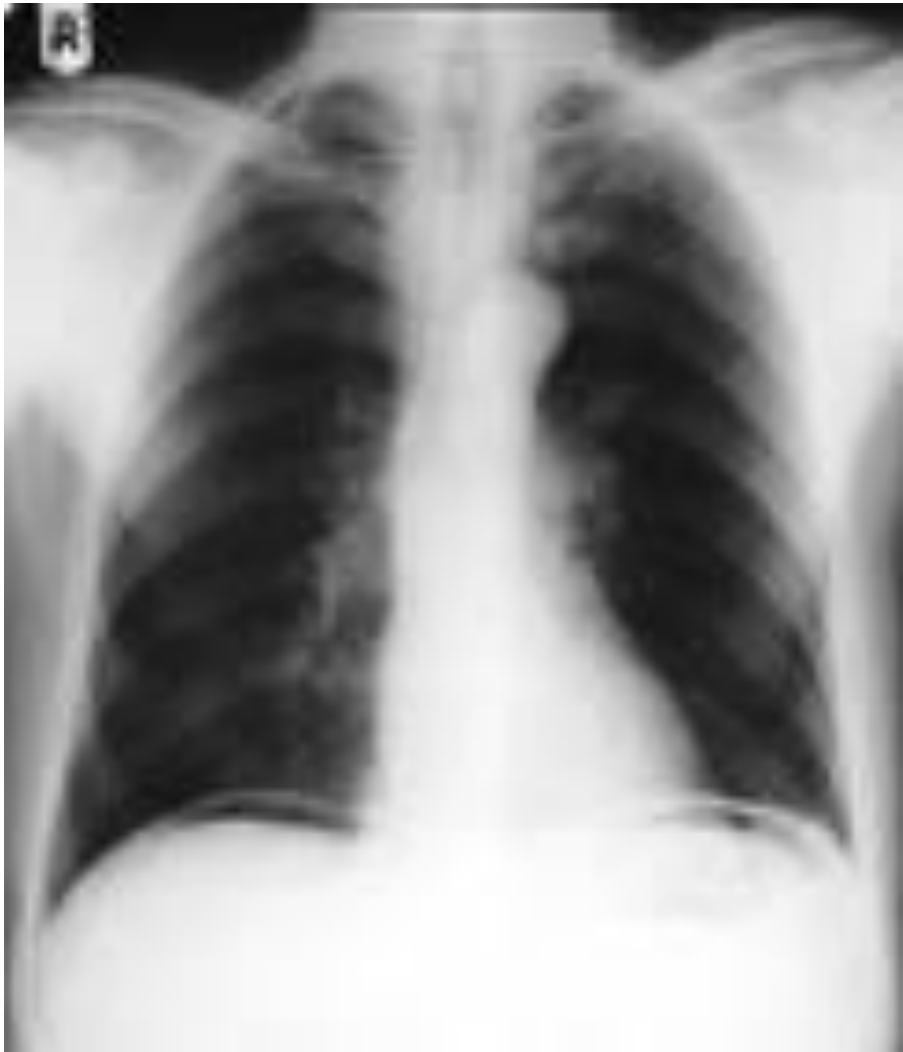Exercise

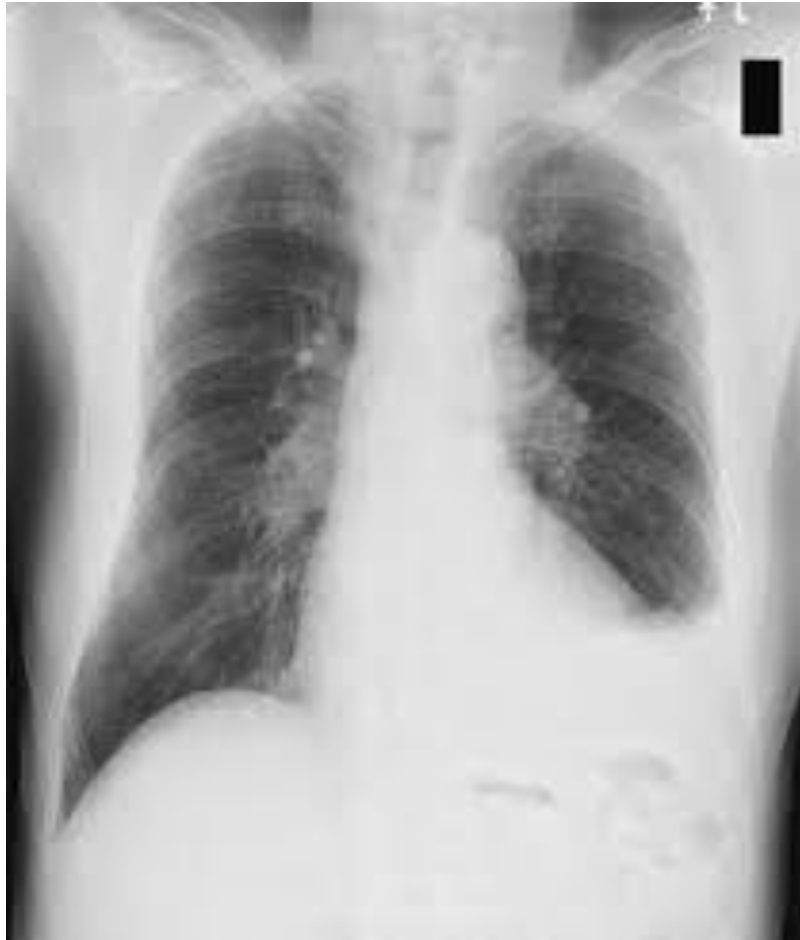


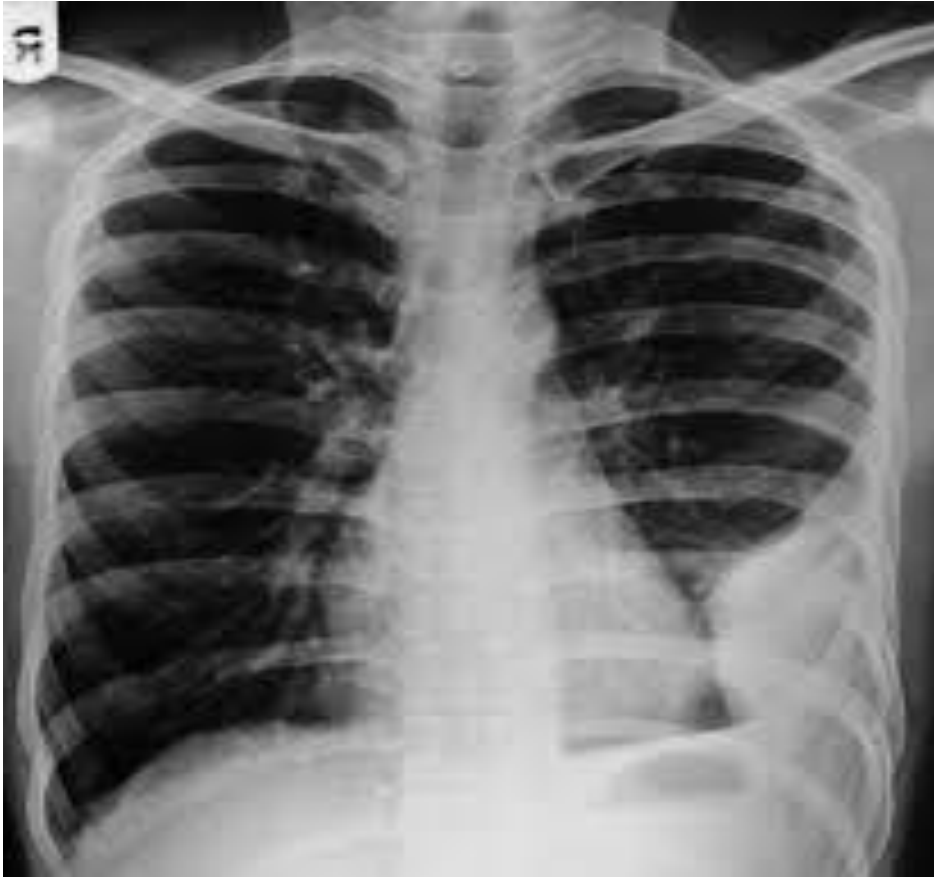
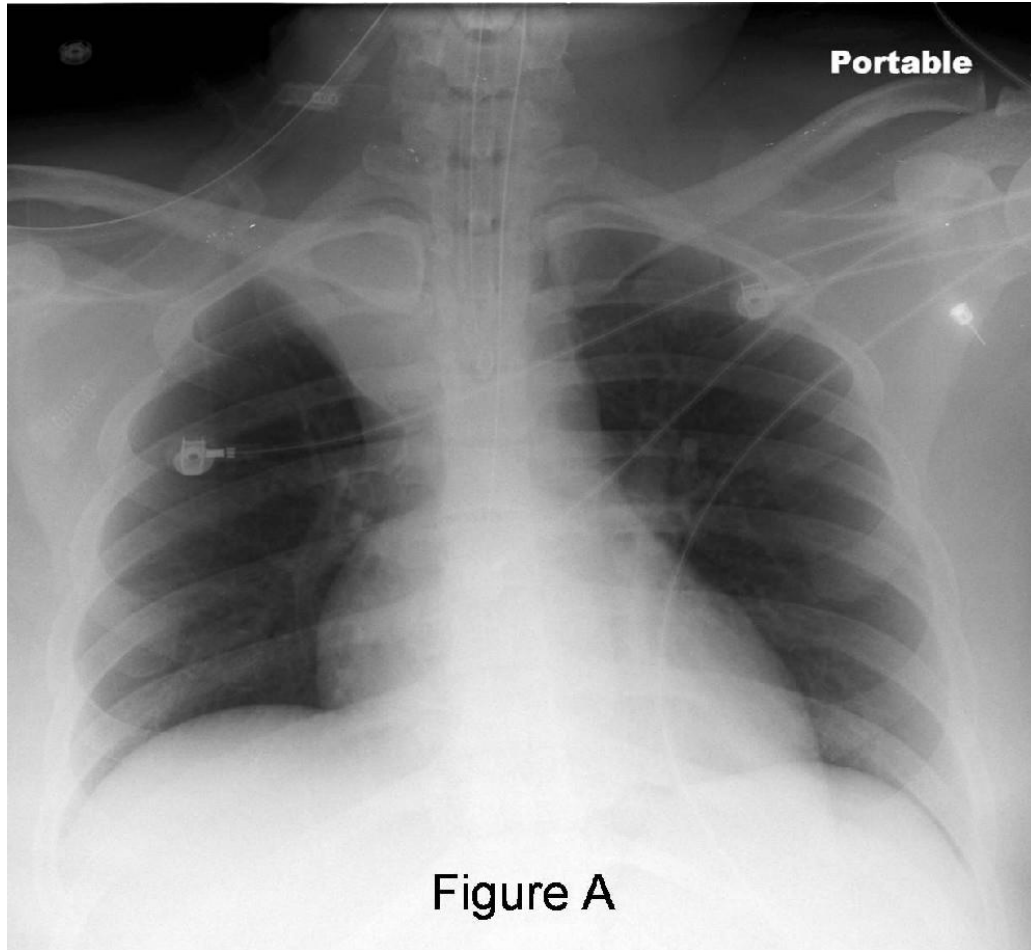


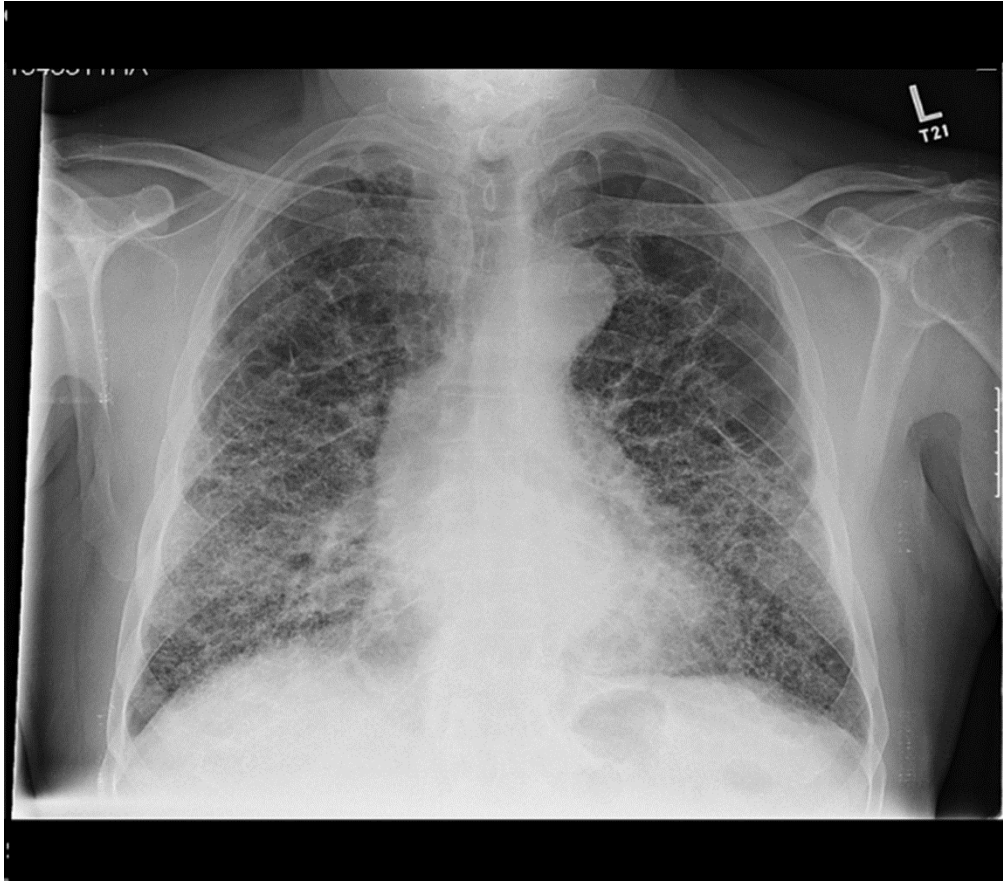










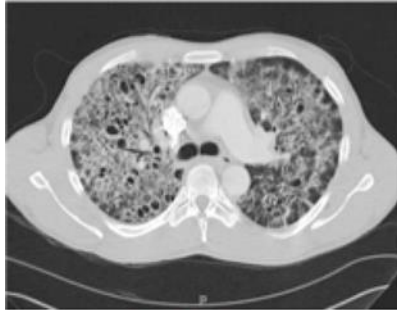

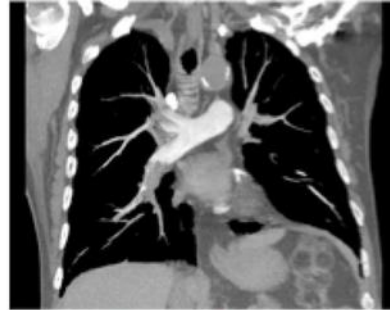Chest CT interpretation

Terms...

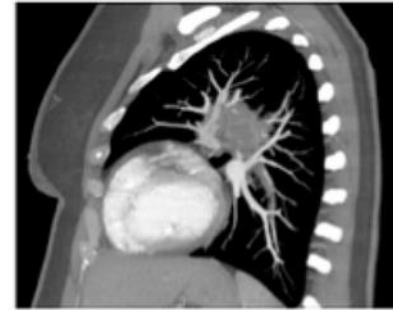
axial, coronal, sagittal



Axial view
Top to bottom



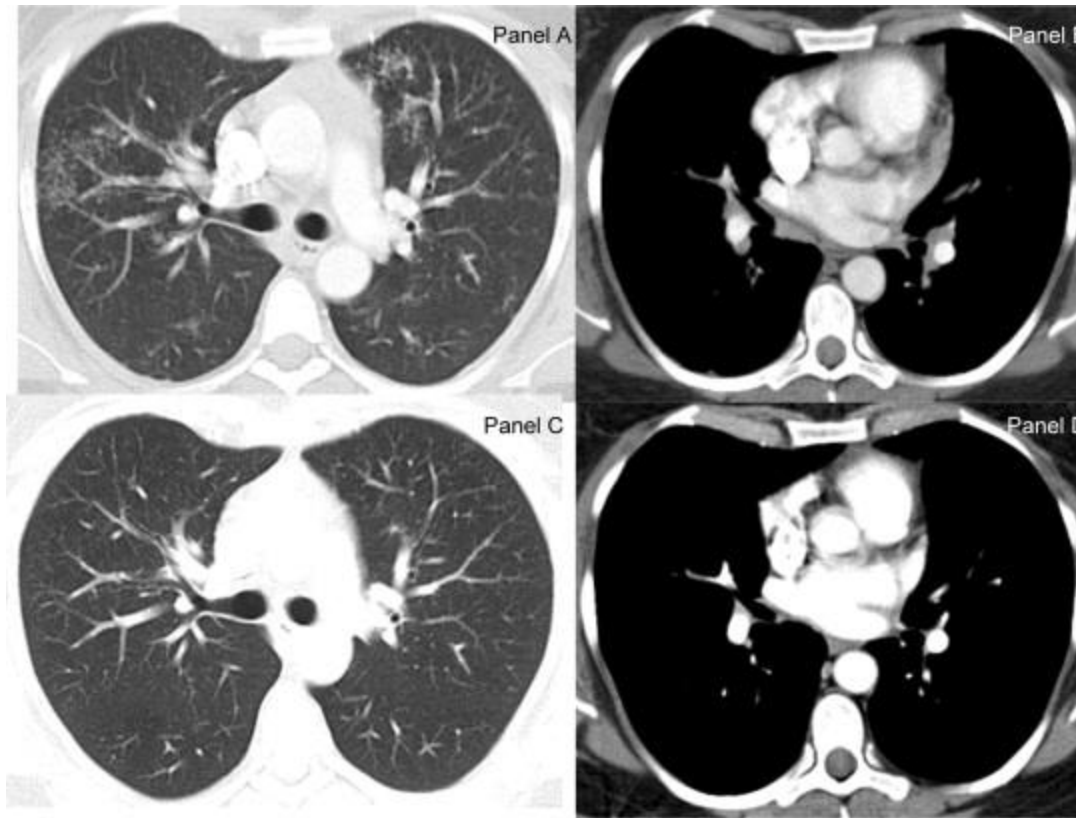
Coronal view
Front to back



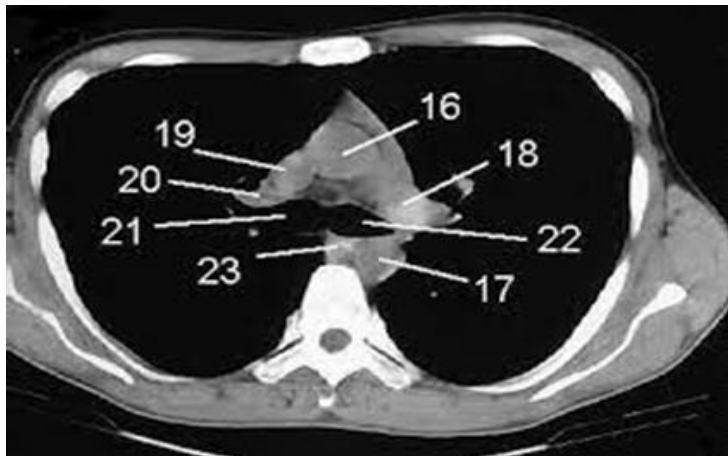
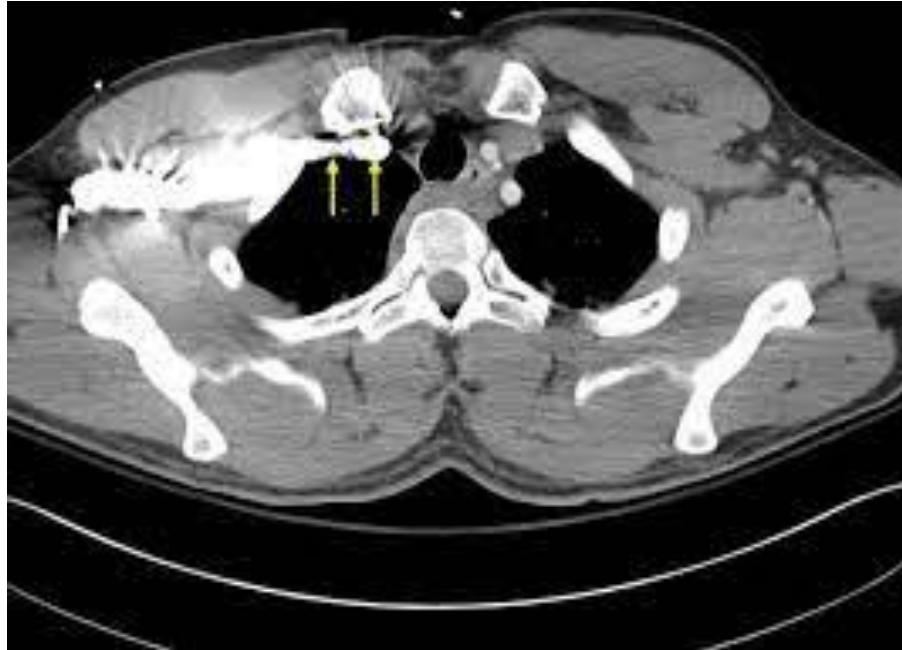Sagittal view
Side to side

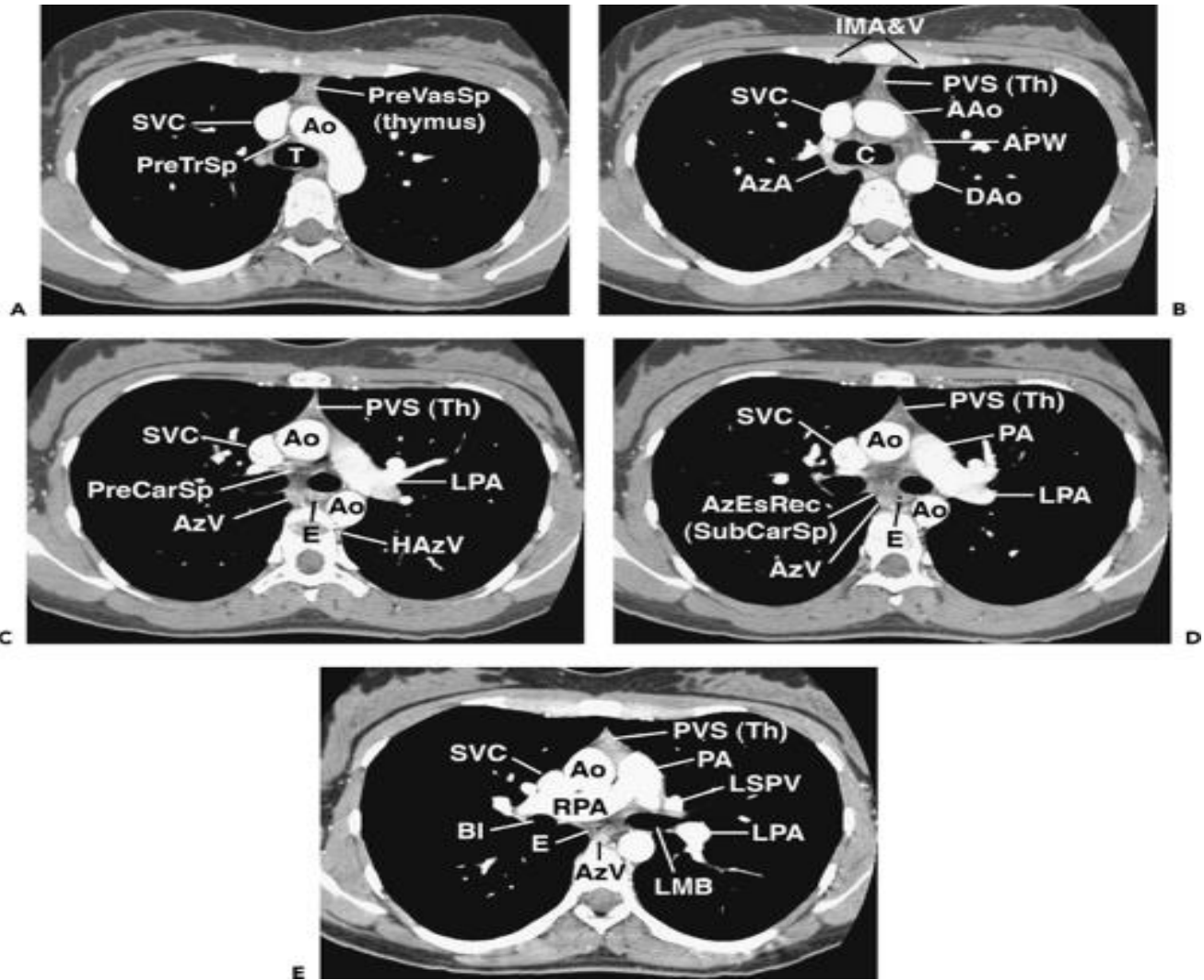
Terms ...

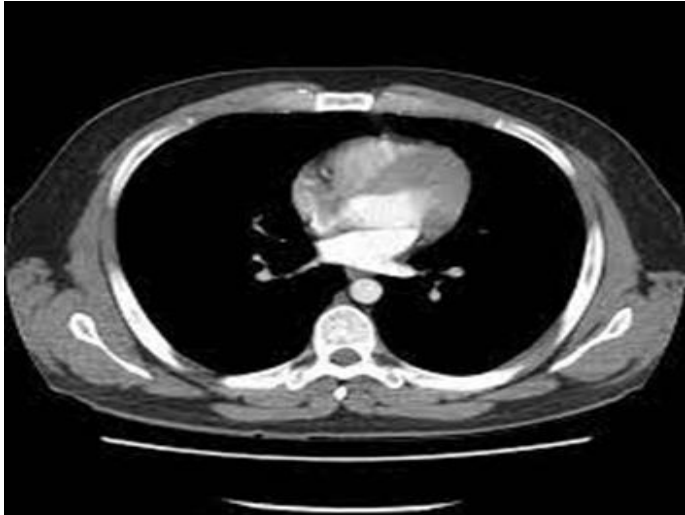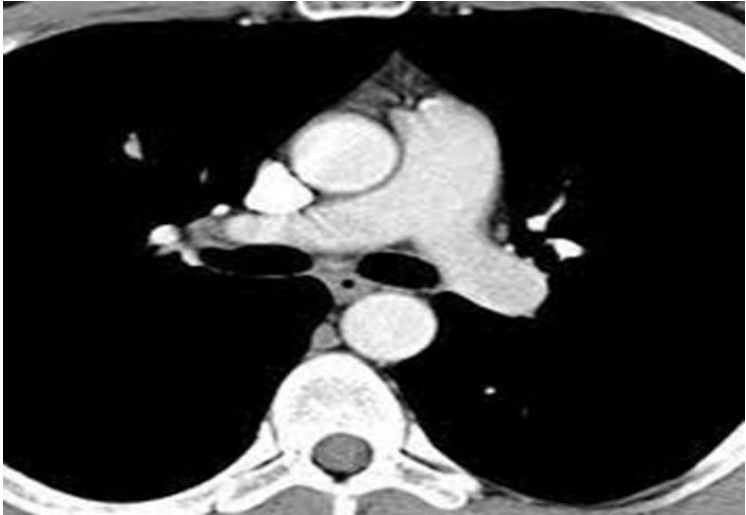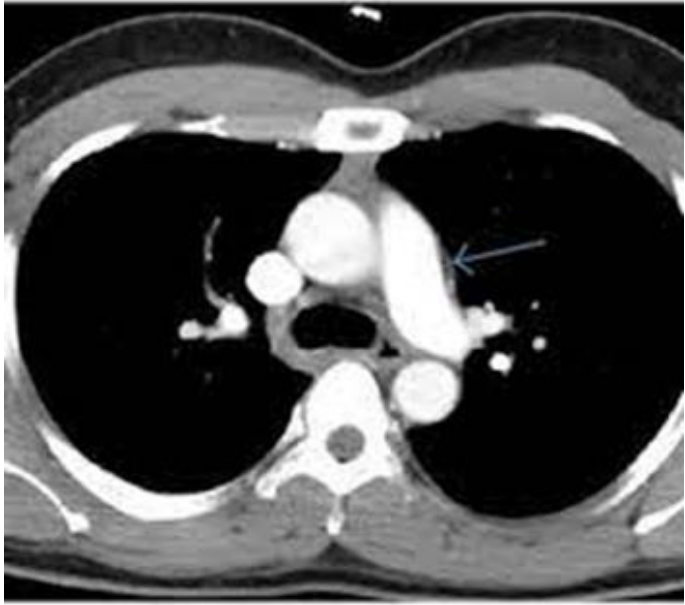
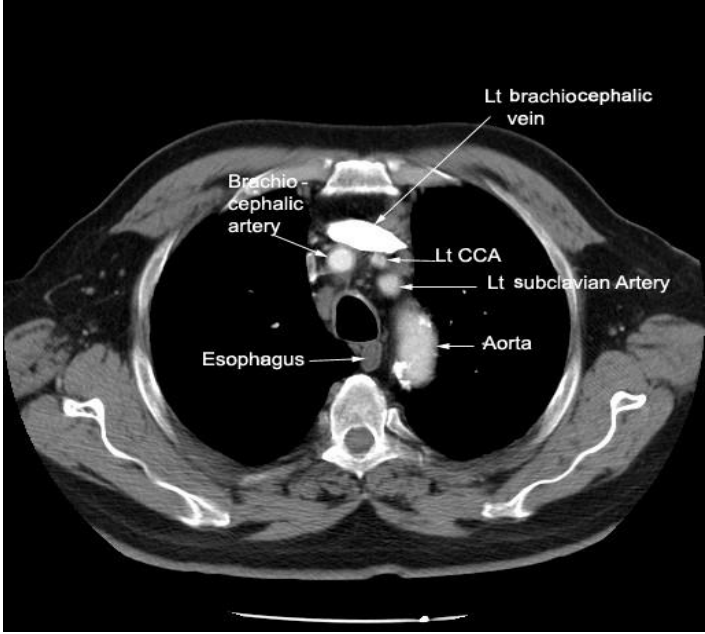
Mediastinal and lung window



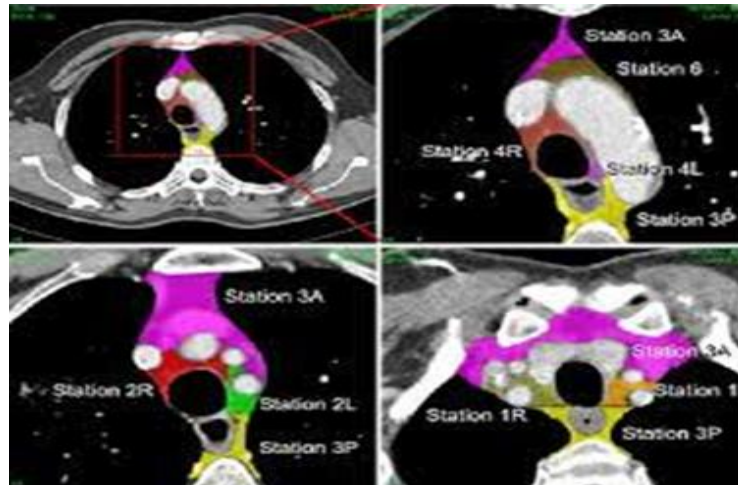
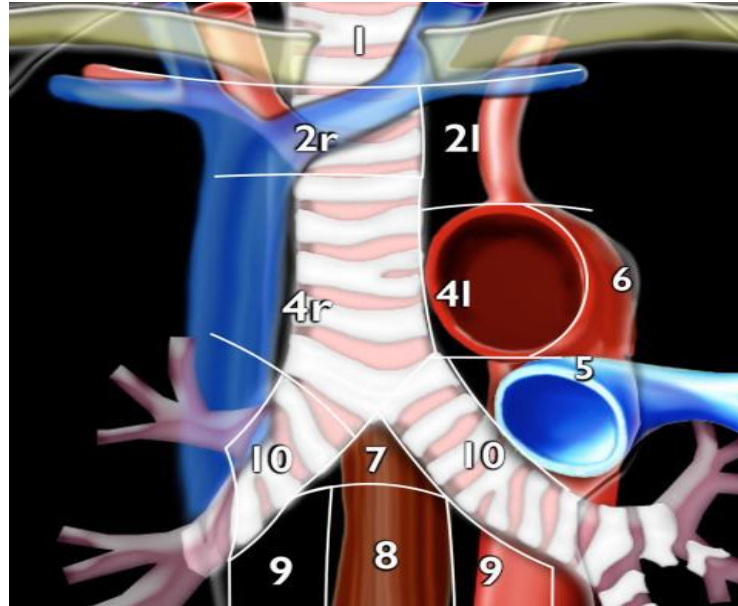
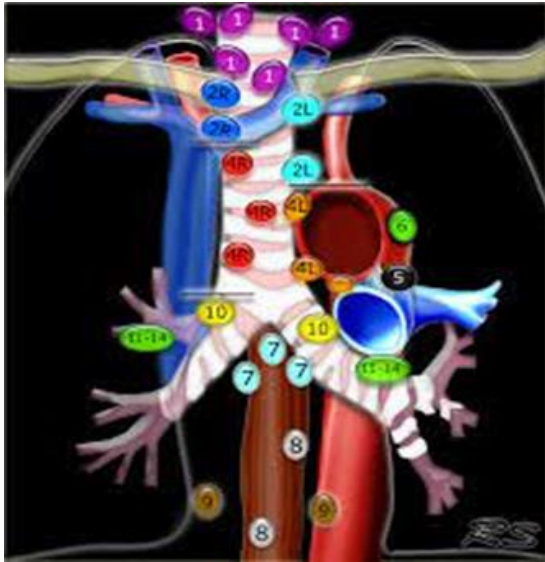
Ct chest with contrast

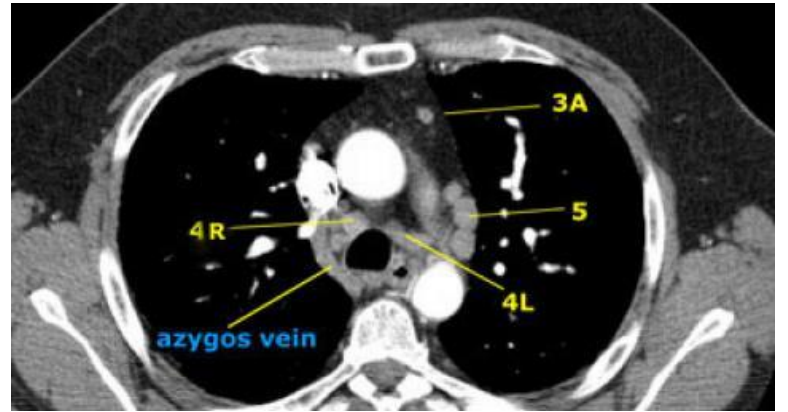
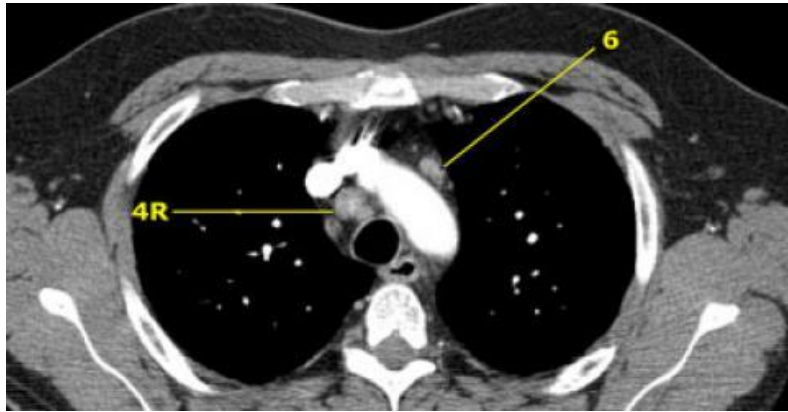
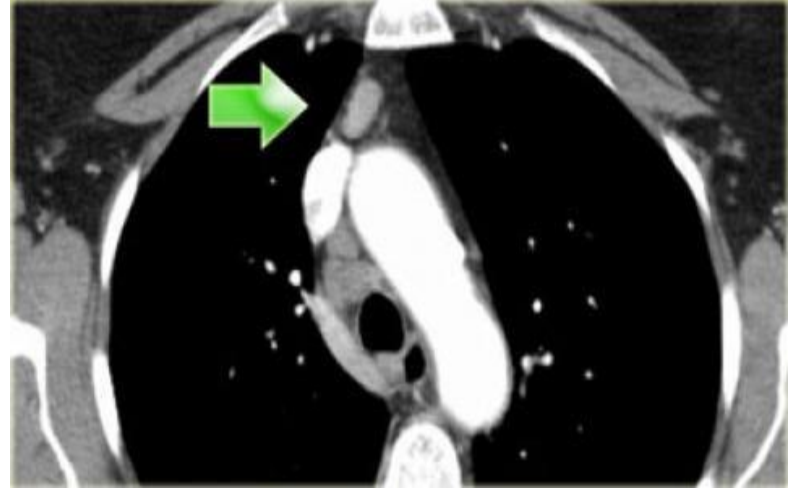
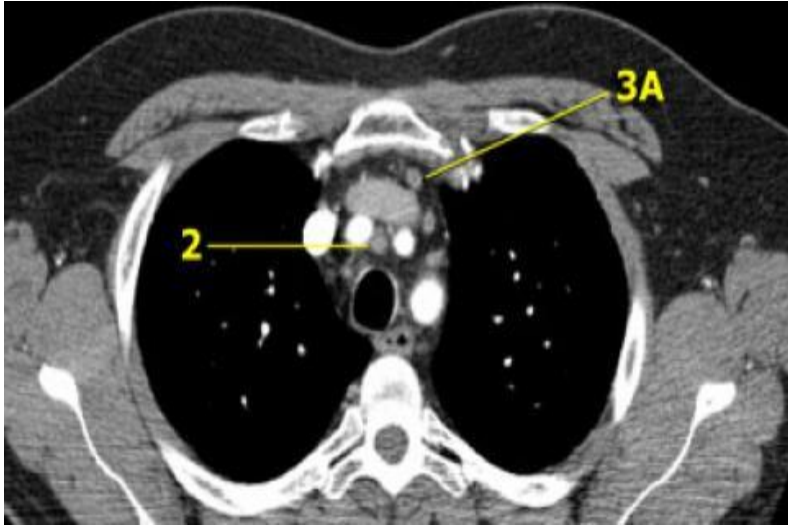


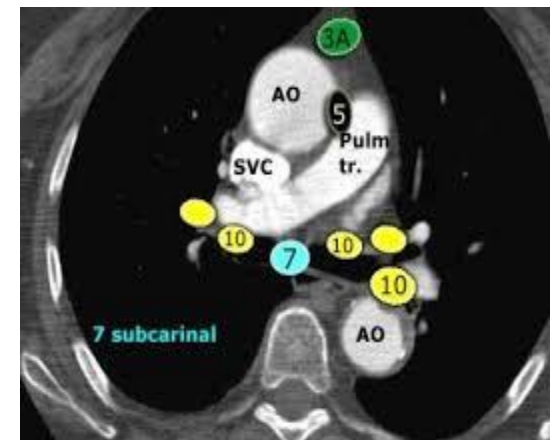
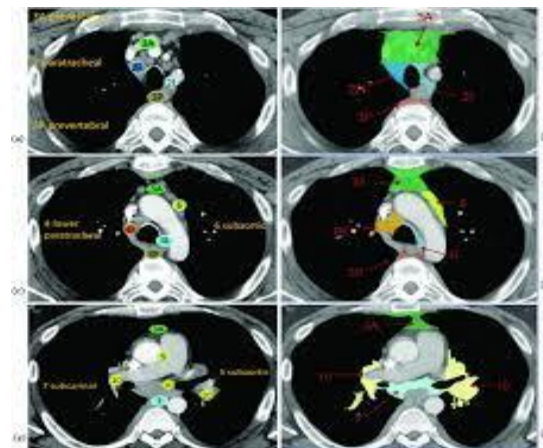
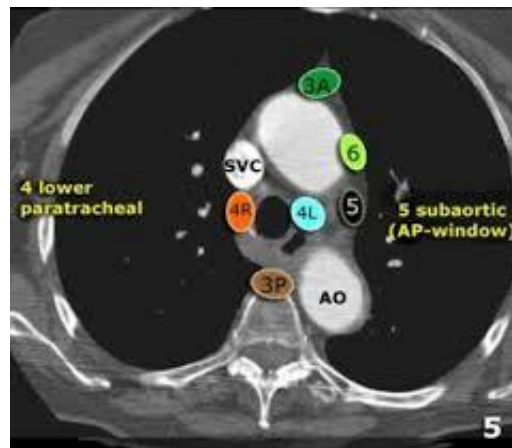
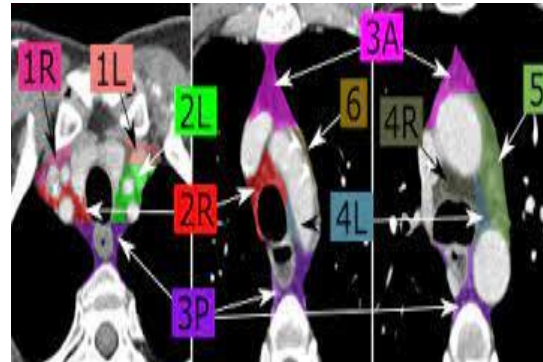
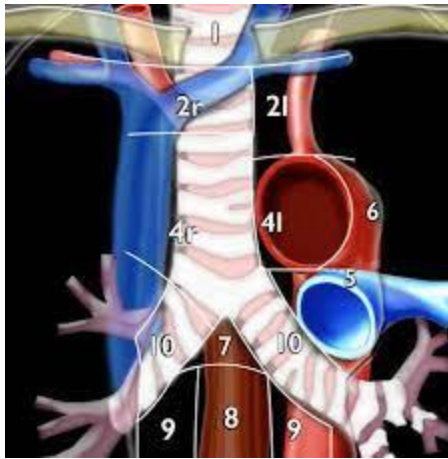


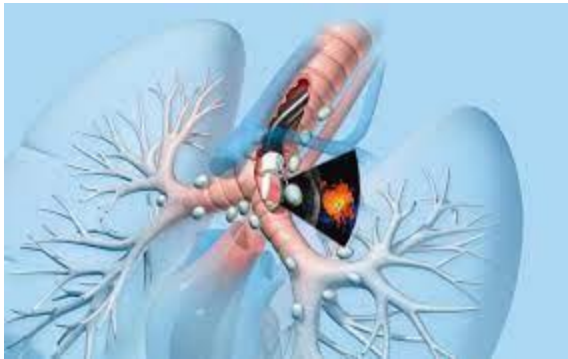

IASLC lymph node map.

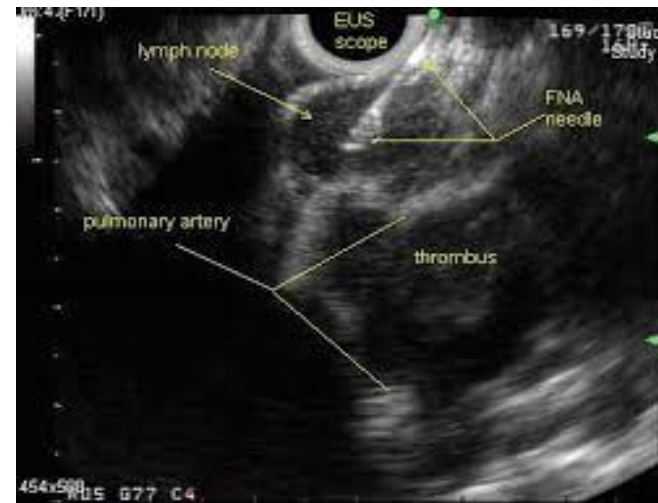
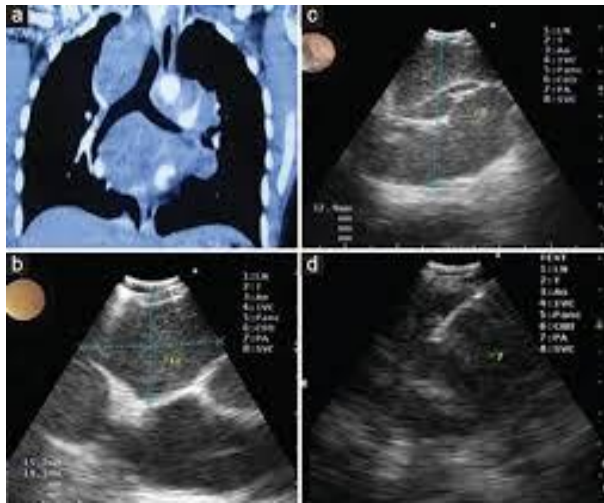


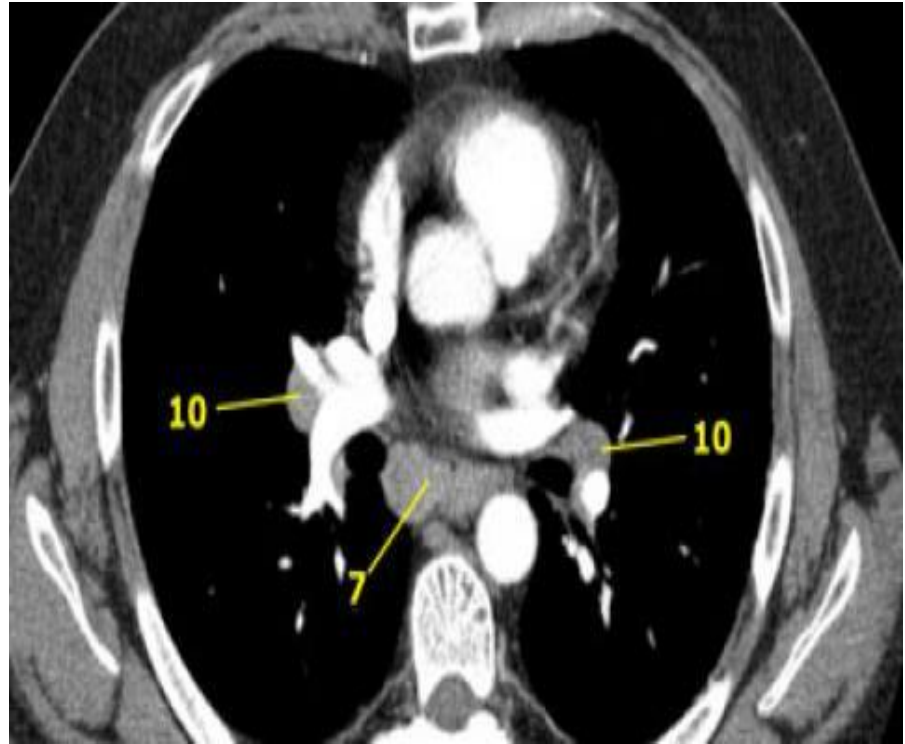
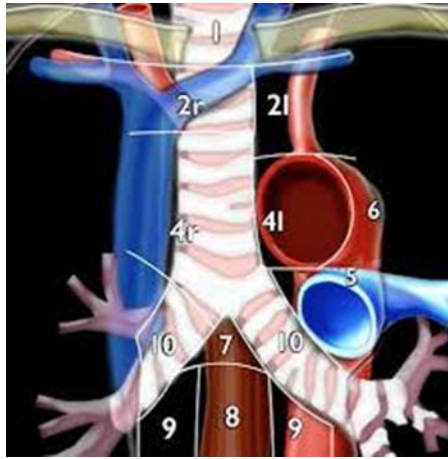


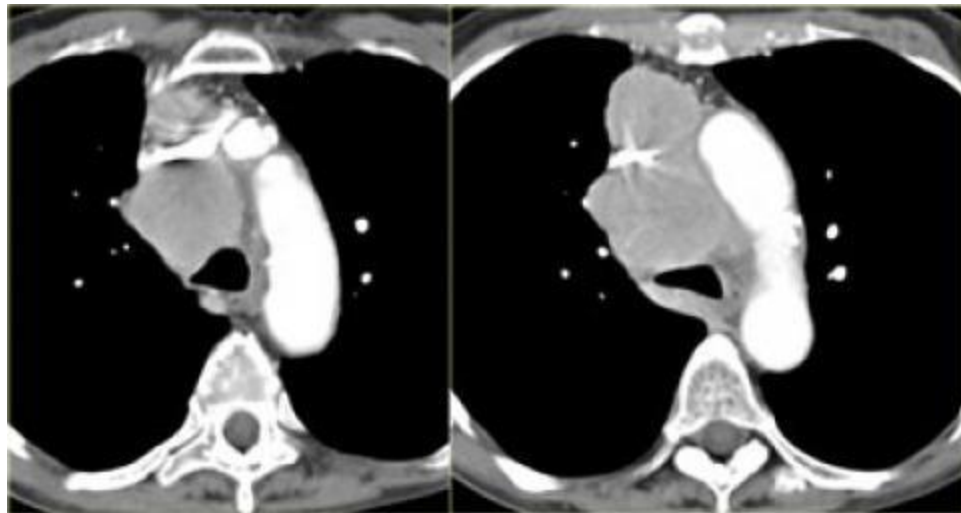
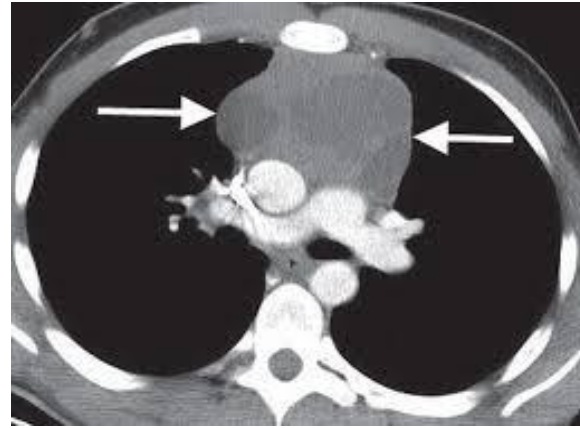
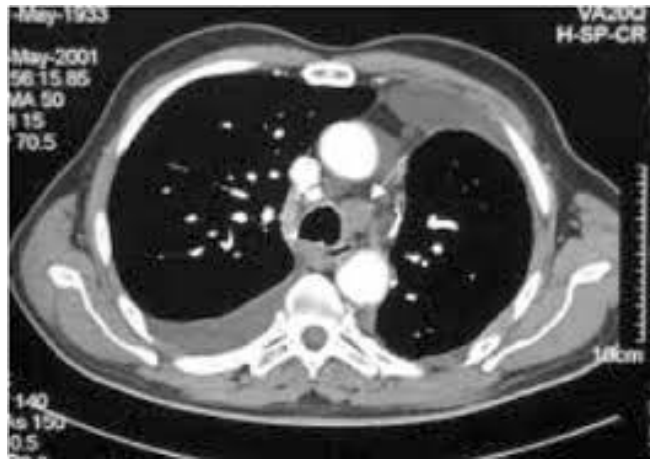


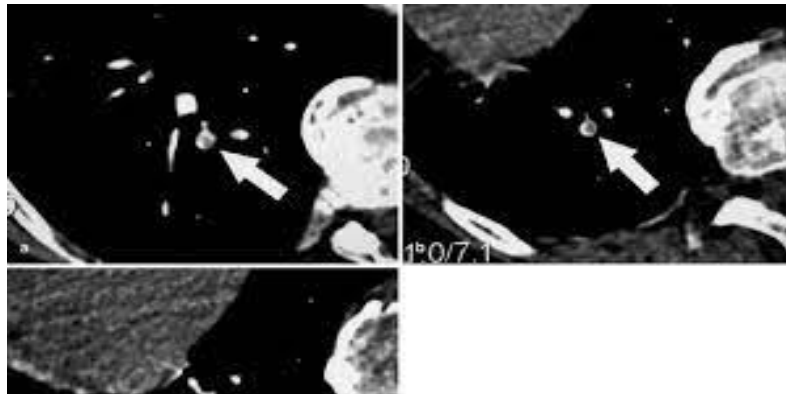
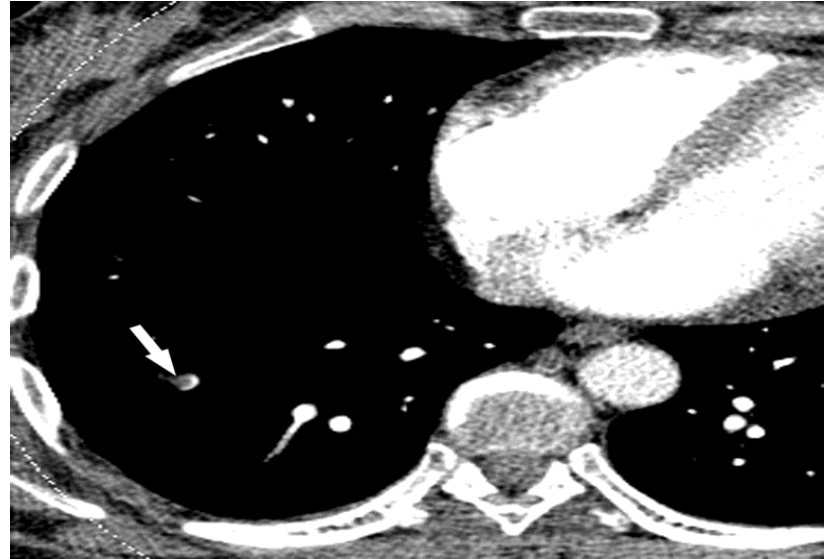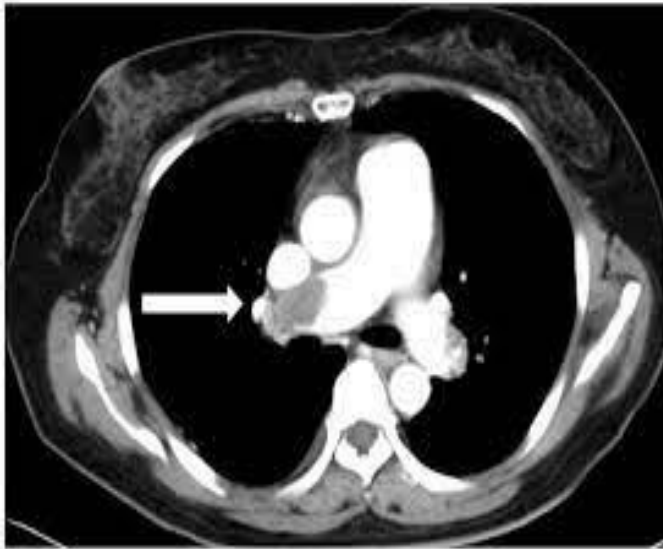


EBUS





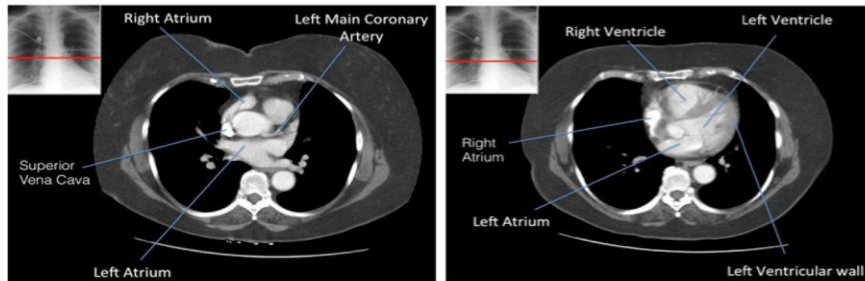




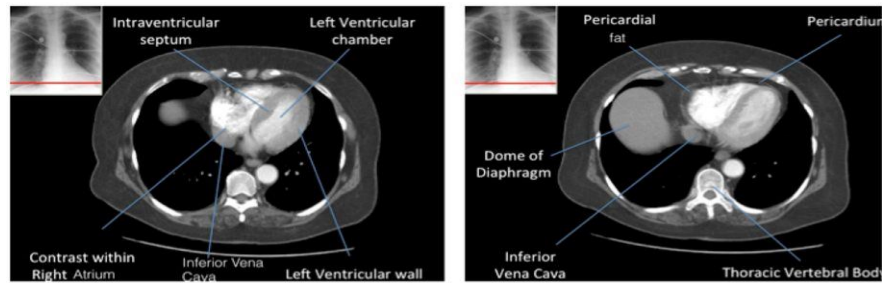
Atria Region

Located within this region are the

- *Atria*
- *Coronary Arteries*
- *The superficial aspects of the Ventricles*



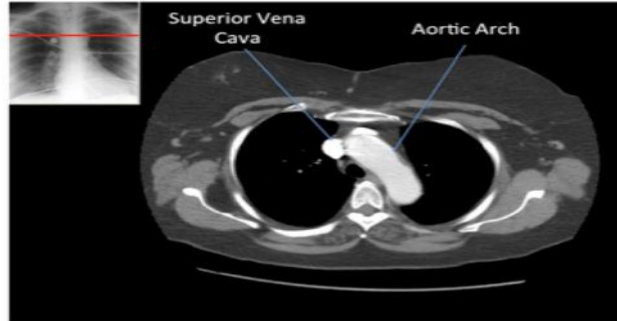
Ventricular Region



Located within this region are the

- *Ventricles*
- *Interventricular Septum*
- *Pericardium*
- *Pericardial Sac*
- *Dome of Diaphragm*

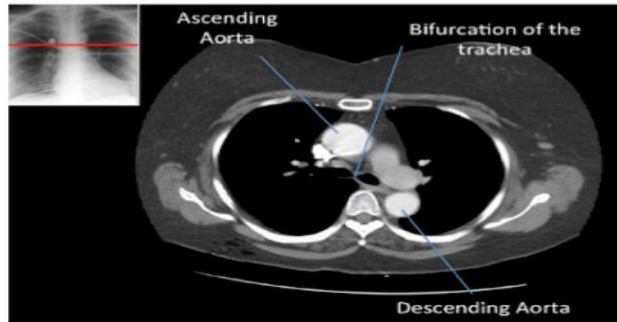
Aortic Arch Region



Located within this region are:

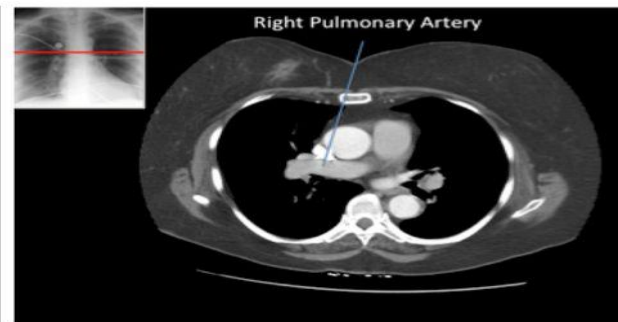
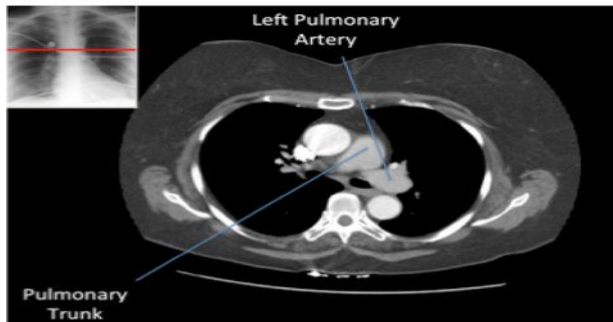
- *Superior Vena Cava*
- *Aortic Arch*

Carina and Pulmonary Vessel Region

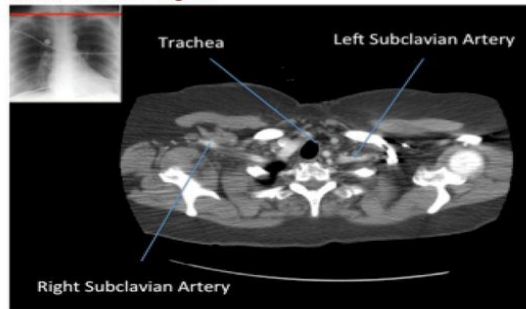


Located within this region are the:

- *Ascending and Descending Aorta*
- *Bifurcation of the trachea*
- *Aortic Arch*
- *Pulmonary Arteries*
- *Pulmonary Trunk*

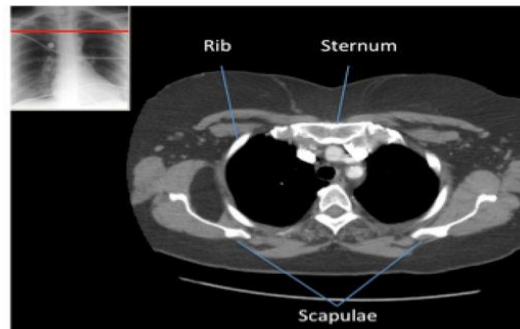
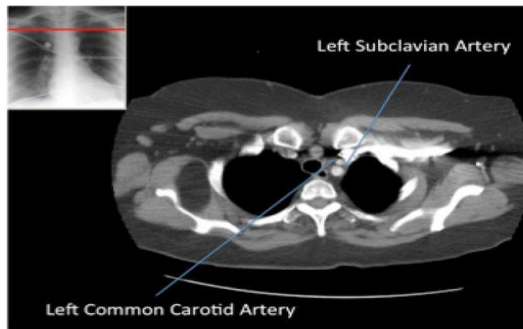
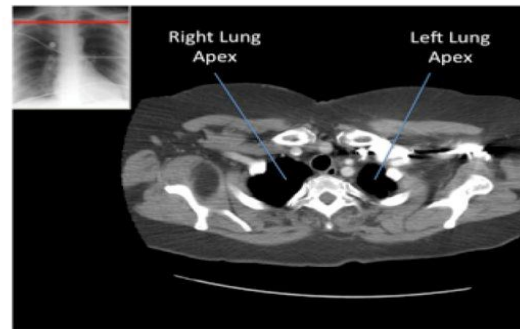
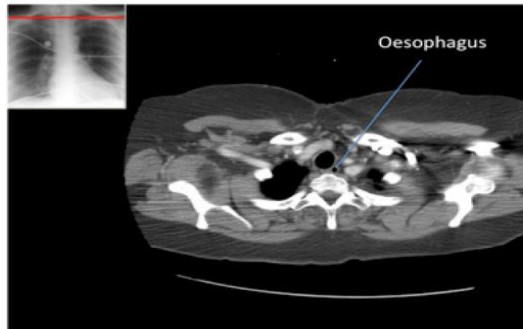


Great Vessels Region



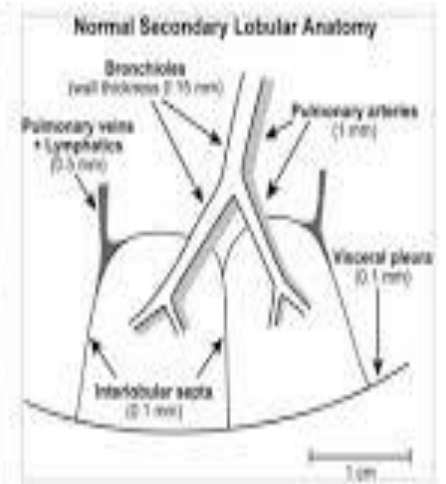
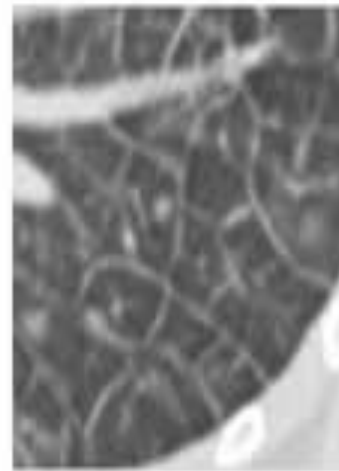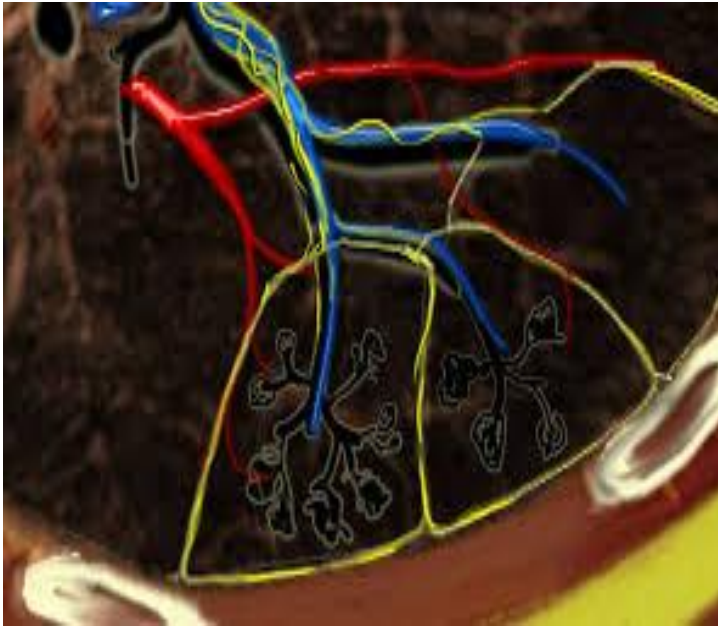
Located within this region are the:

- trachea
- oesophagus
- subclavian vessels
- carotid vessels
- lung apices
- Boney structures



HRCT chest

Secondary pulmonary lobule



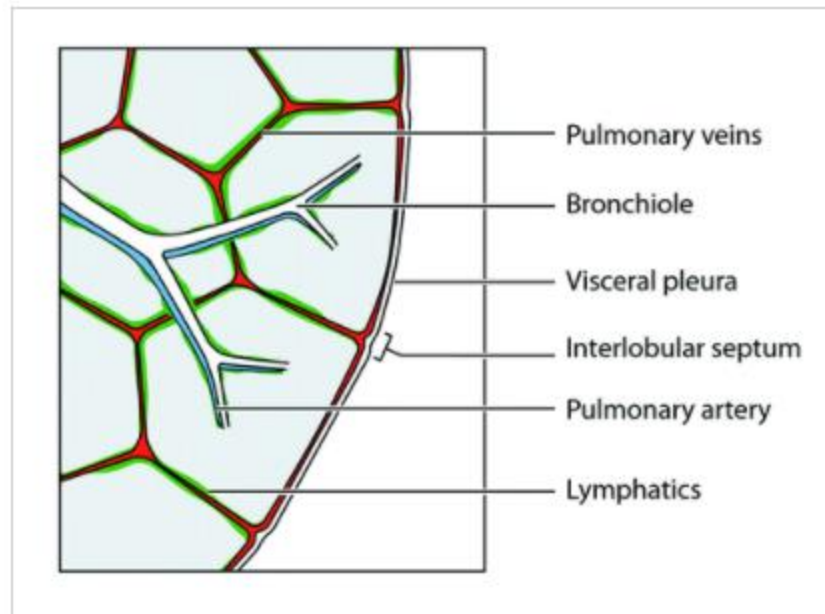
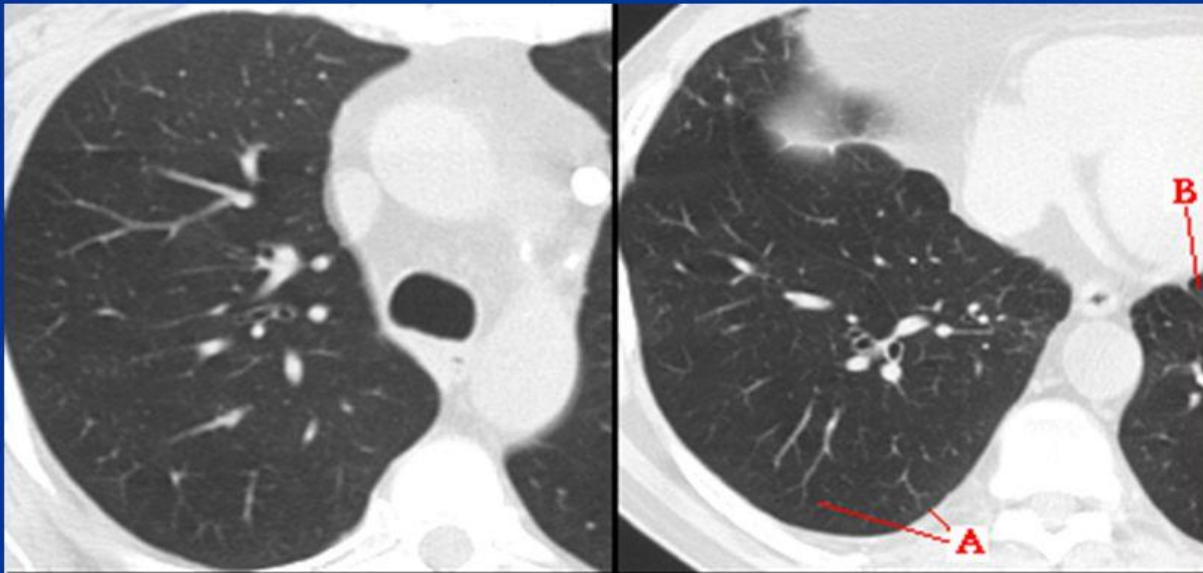


Fig. 1. —Line drawing of a secondary pulmonary lobule. Borders of lobule are interlobular septa. At center of each lobule is a bronchiole and a pulmonary artery (*blue*). Pulmonary vein (*red*) run in interlobular septa. Lymphatics (*green*) are found in interlobular septa and in central or axial interstitium that surrounds bronchovascular bundles.

Normal HRCT

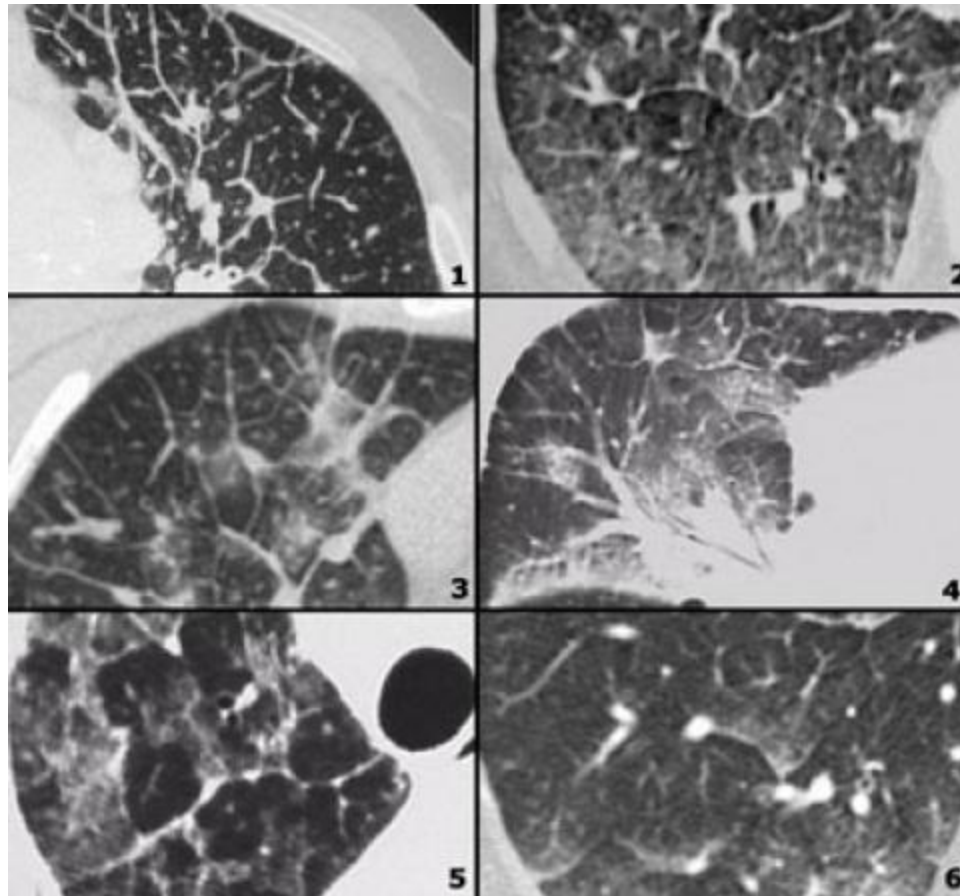


Normal upper (left) and lower (right) HRCT scans obtained in the prone position. The center of a pulmonary lobule is defined by the presence of a distal pulmonary artery (A). The faint outline of a distal interlobular septum is noted in the lower lobes (B). A subpleural clear space is normally present in the nondependent lung.

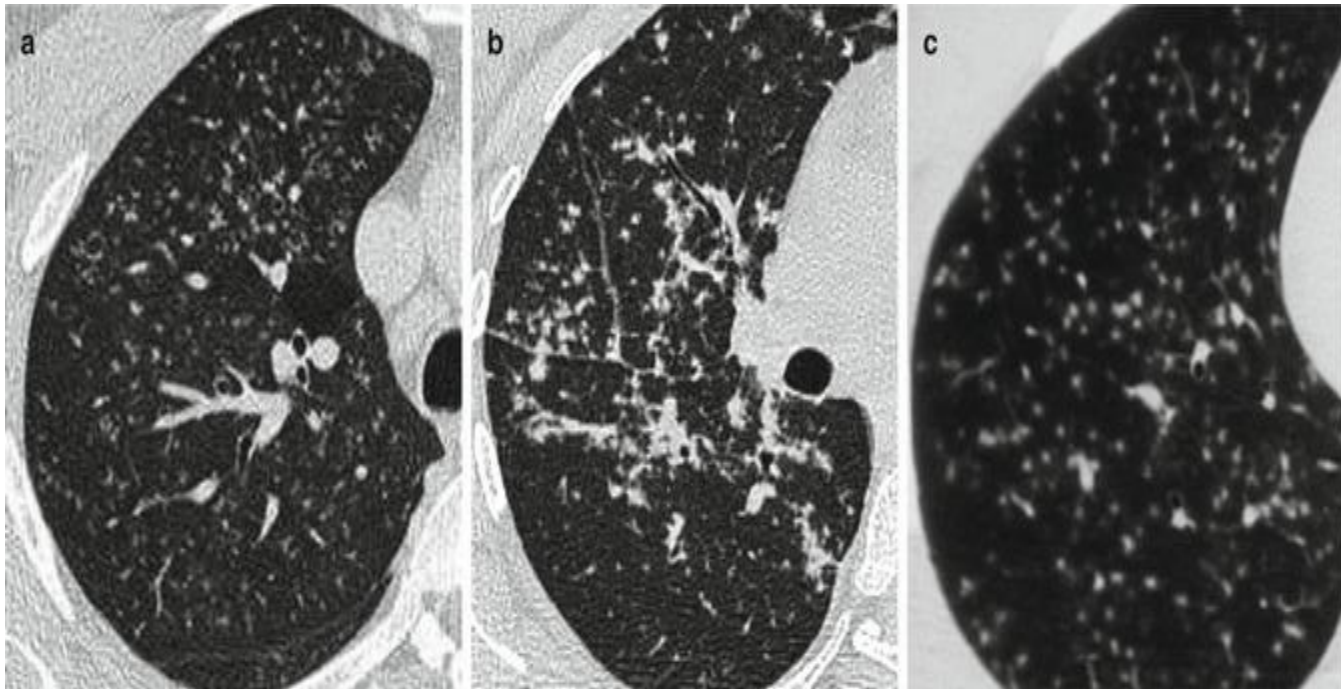
HRCT-Patterns

- Nodular pattern.
- Reticular pattern .
- Increased density (Consolidation, GGO).
- Decreased density (cystic pattern)

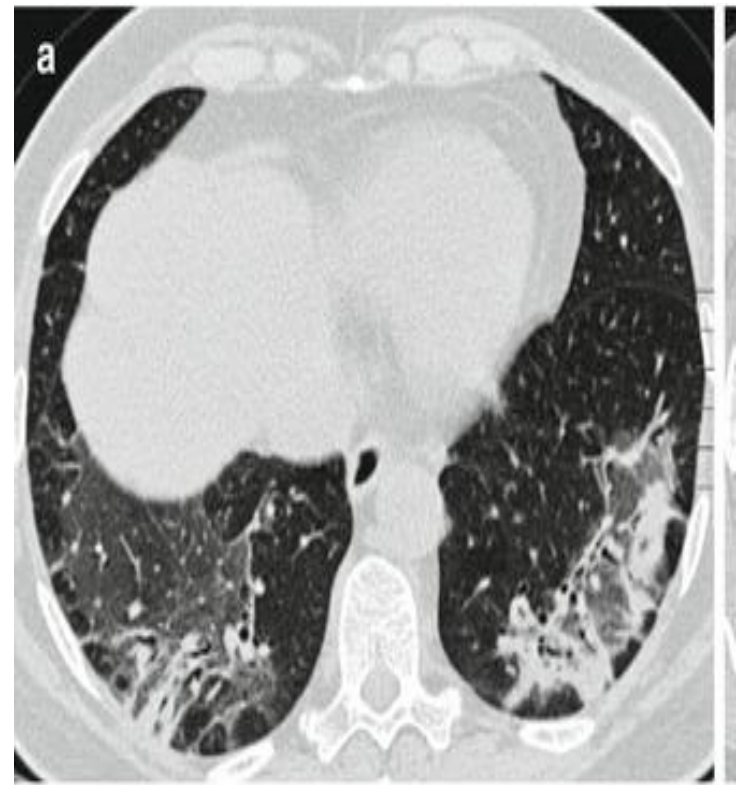
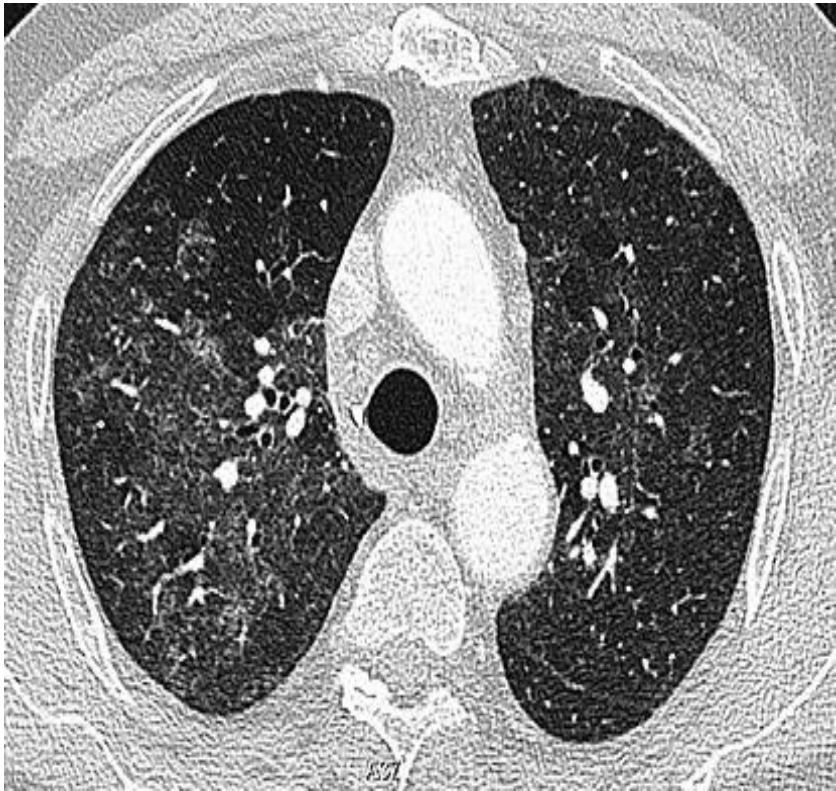Reticular pattern



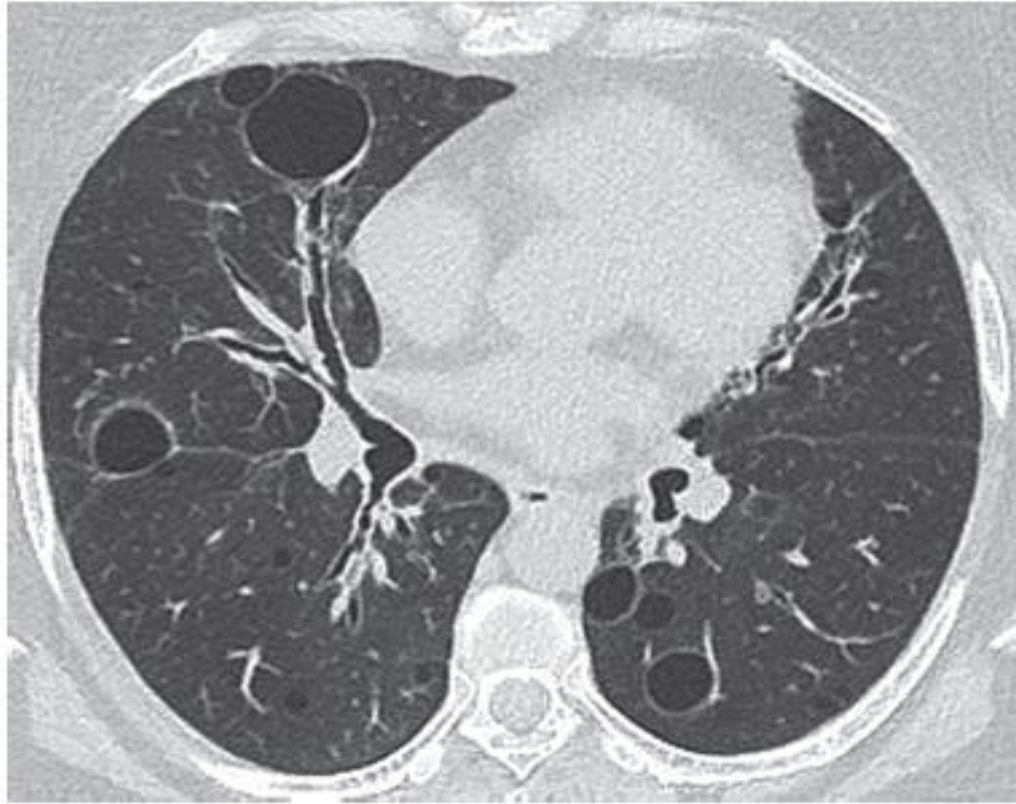Nodular pattern



Ground glass opacity, Consolidation /Increased density



Cystic pattern / decreased density



Mosaic attenuation

- is a descriptive term used in describing a patchwork of regions of differing pulmonary attenuation on CT imaging.

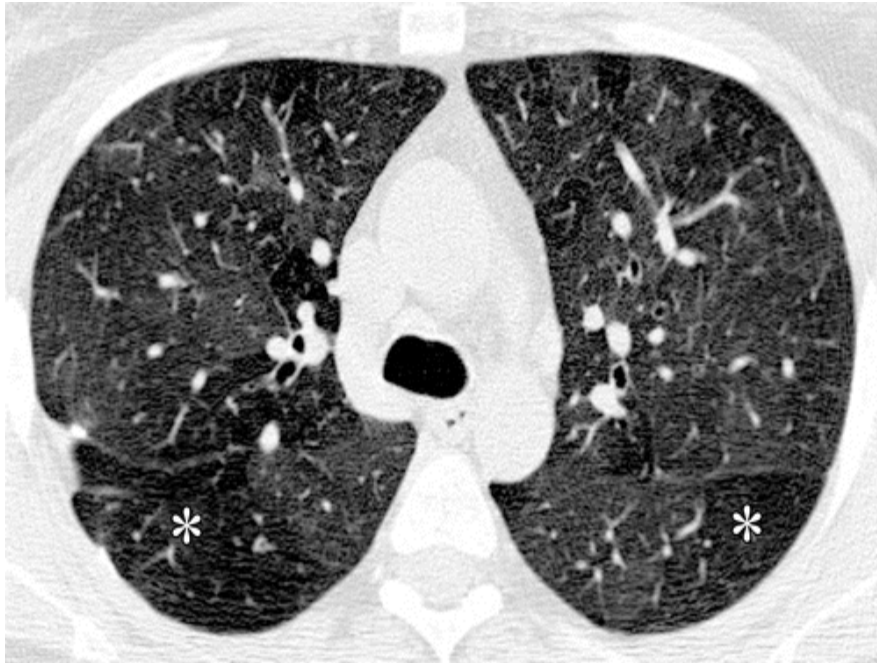
- Causes:

Obstructive small airways disease: air-trapping in lung areas with obstructive small airways disease, and reduced perfusion in these pathological areas secondary to vasoconstriction

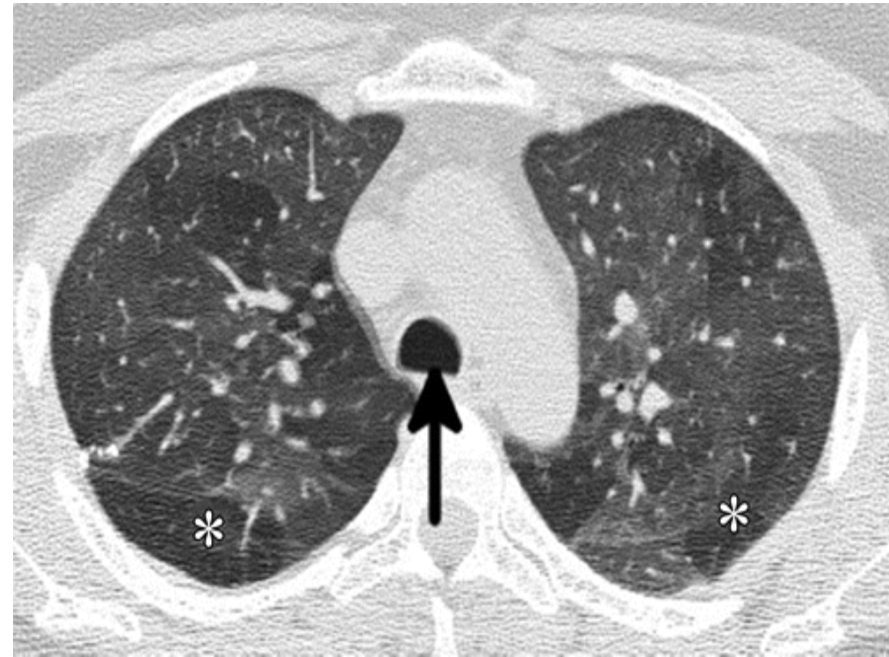
Occlusive vascular disease: low attenuation regions are abnormal and reflect relative oligemia

Mosaic attenuation

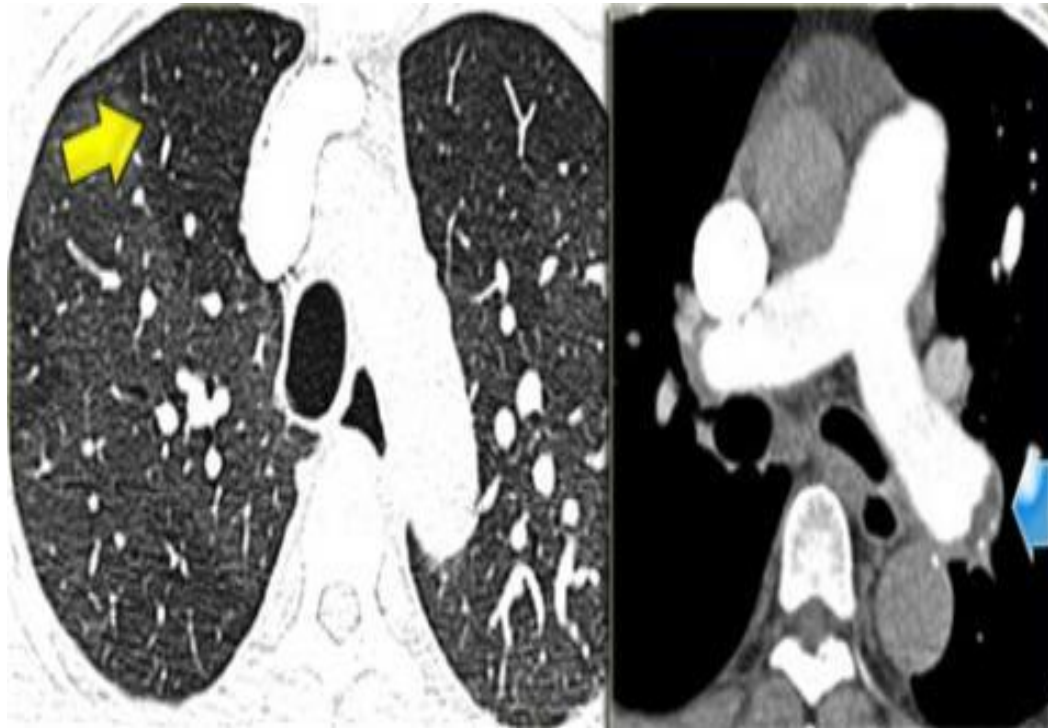
Inspiration

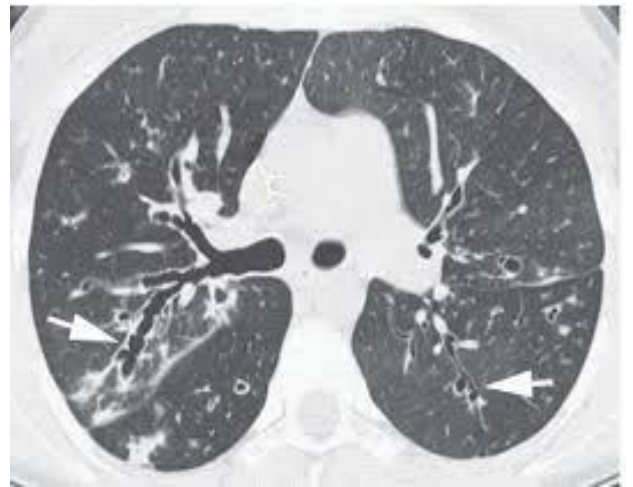
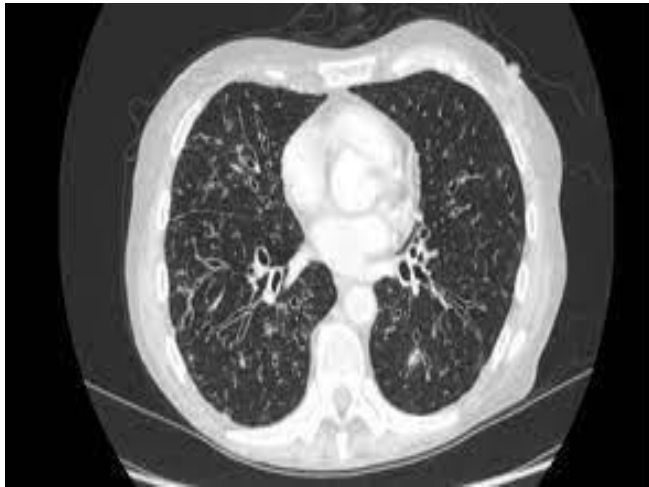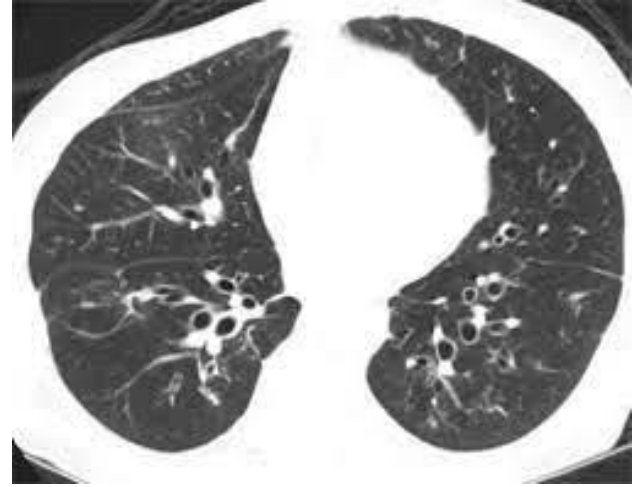
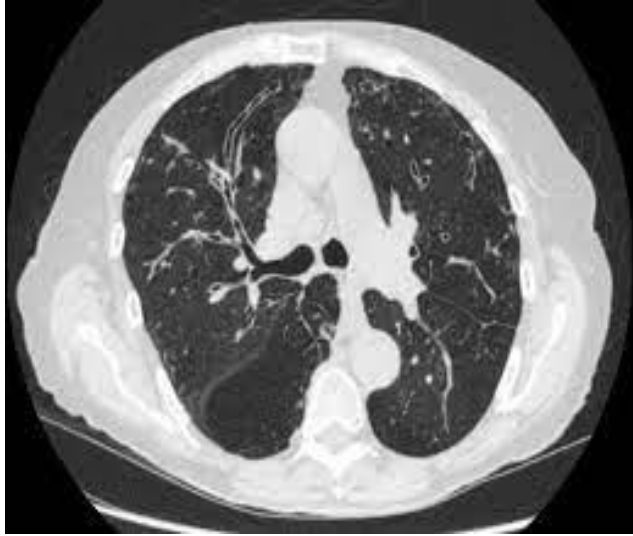


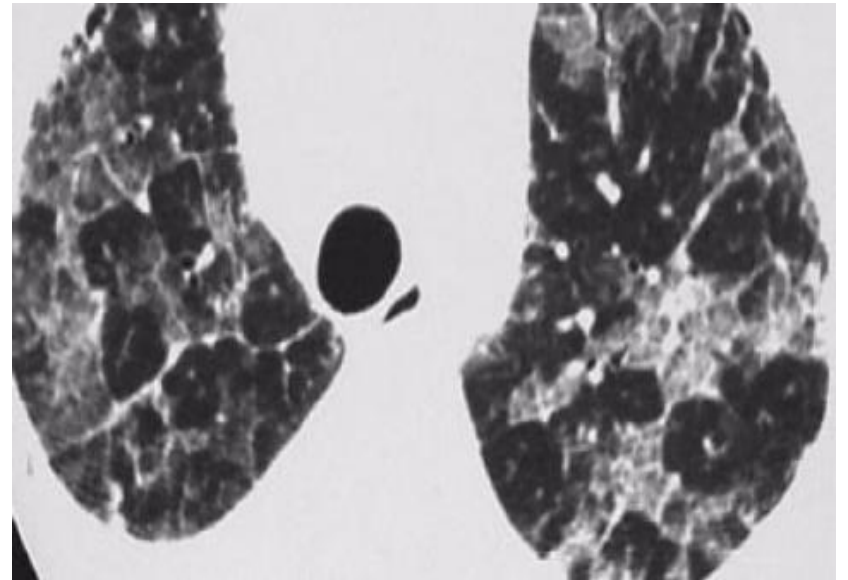
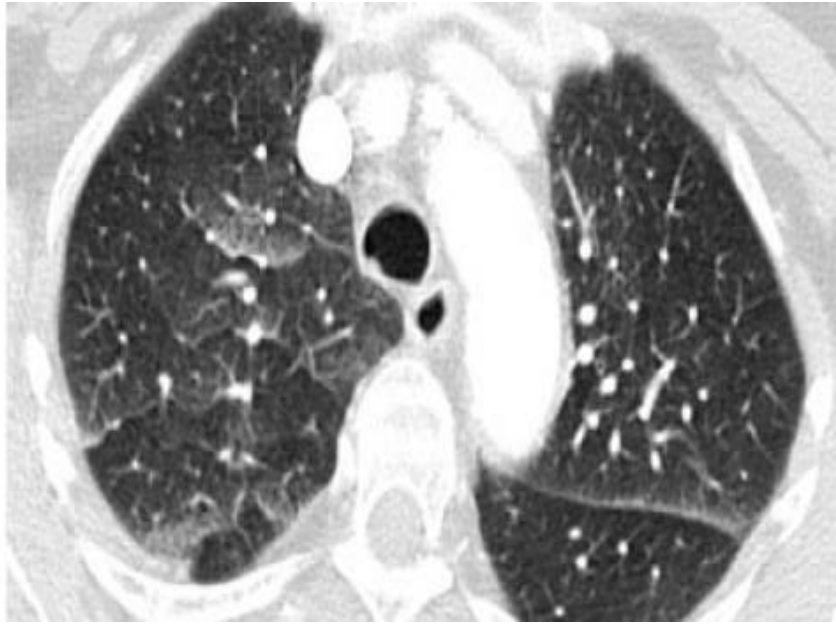
Expiration

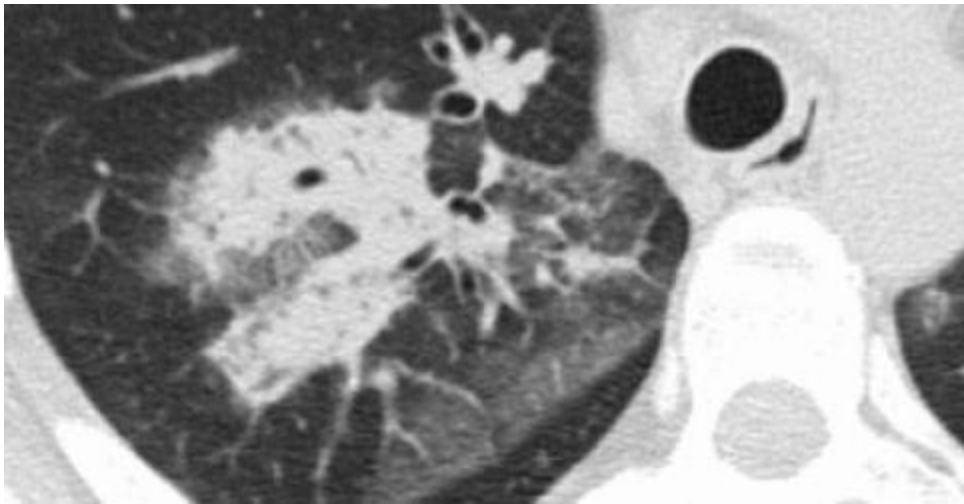


Mosaic attenuation

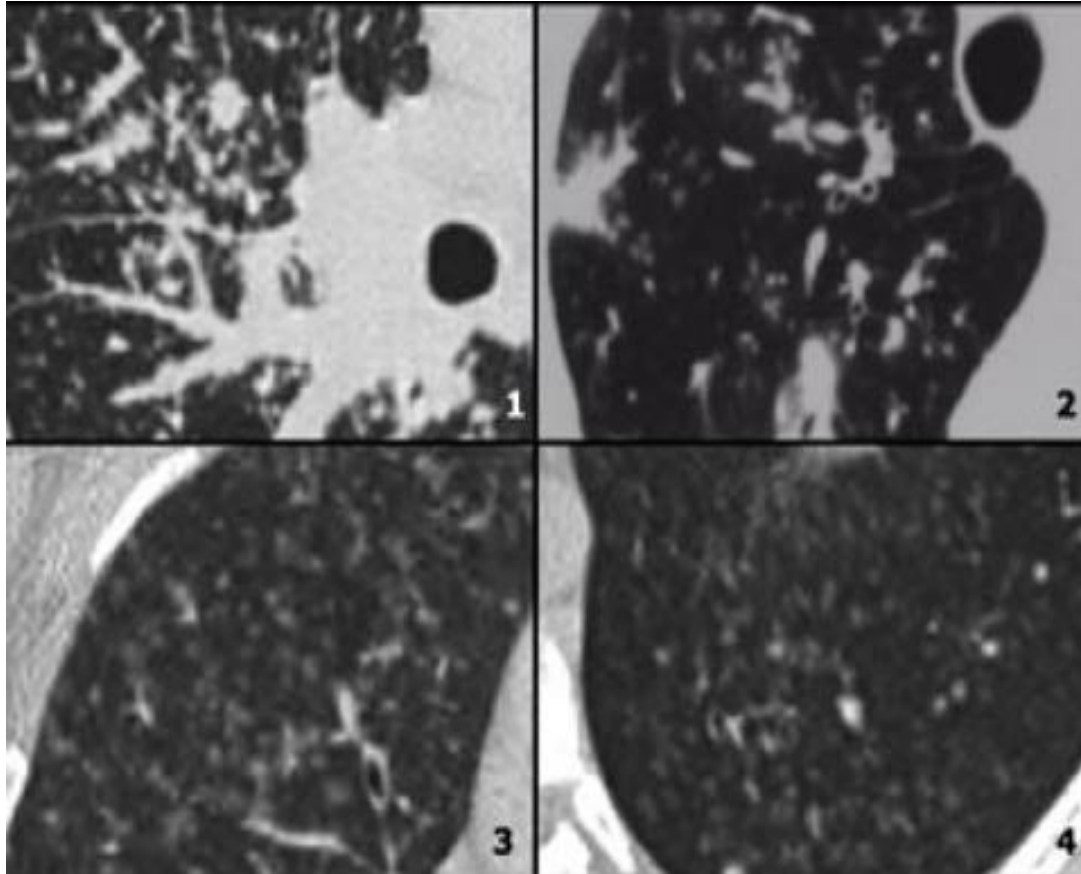




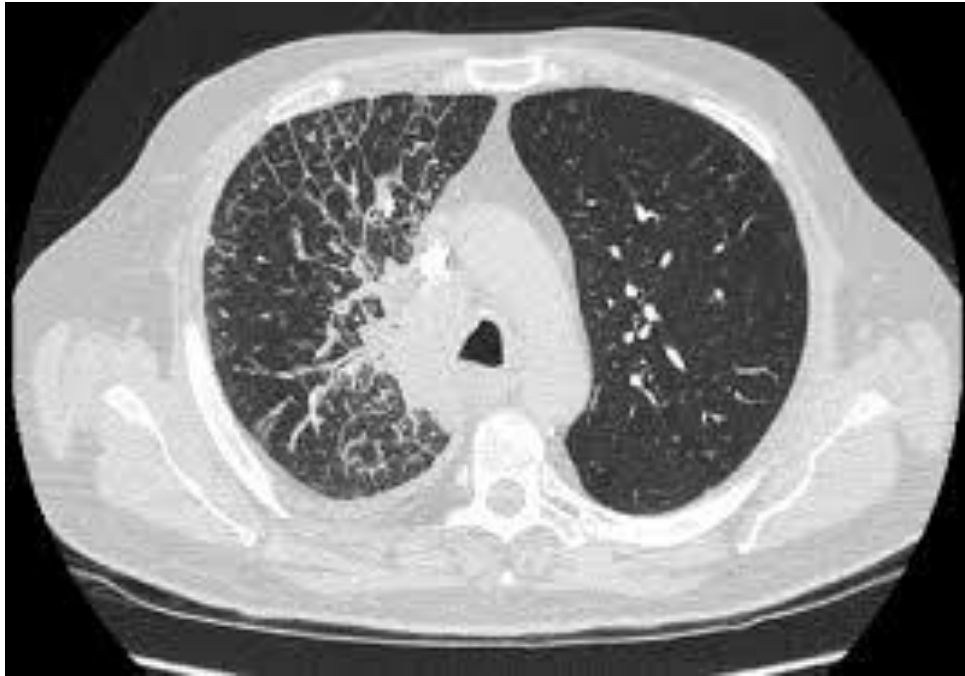



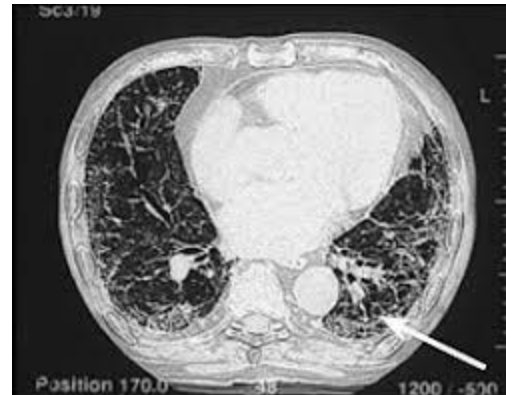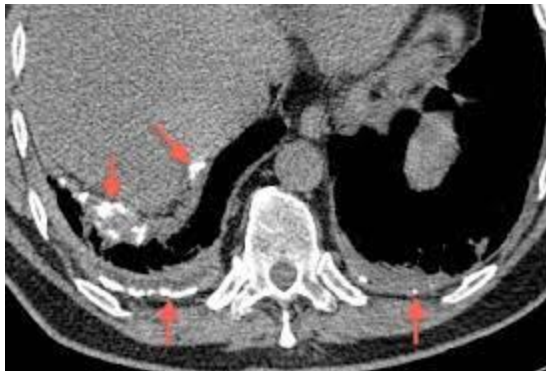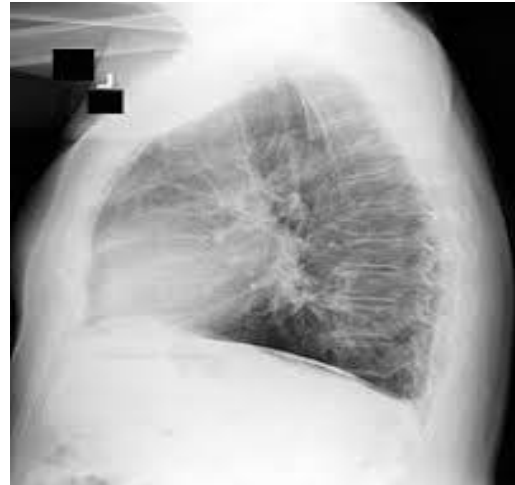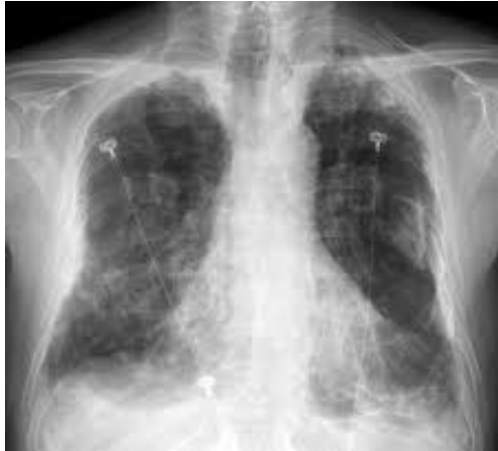2 tree in bud



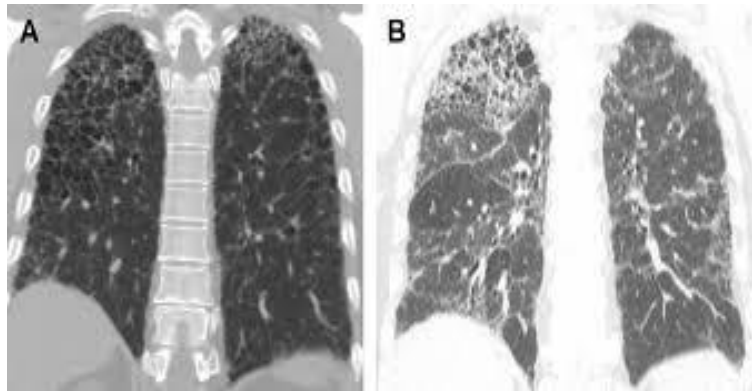
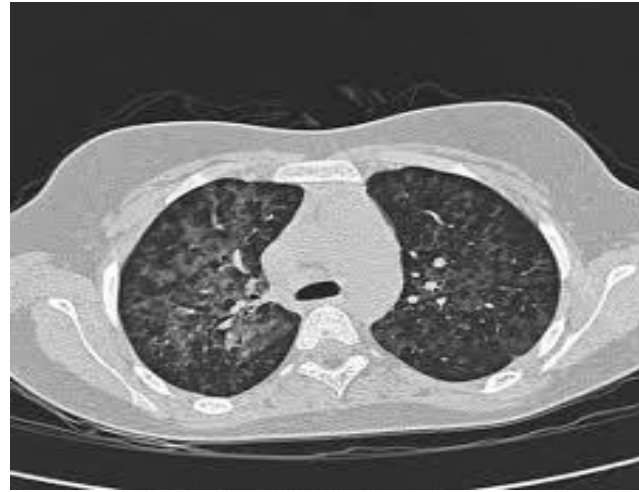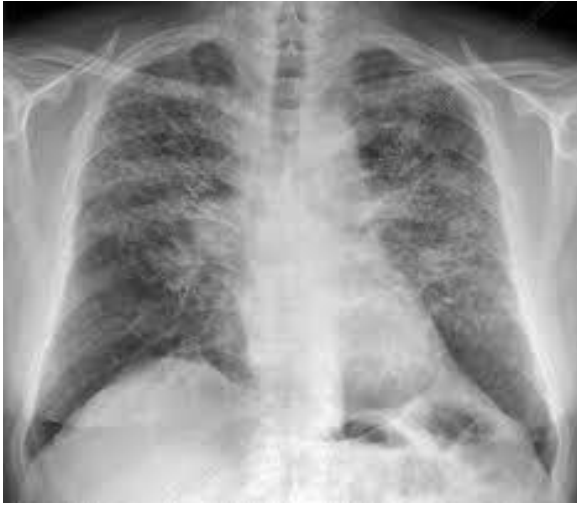Lymphangitis carcinomatosa



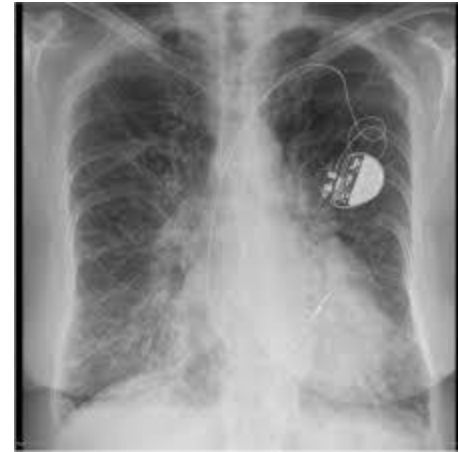
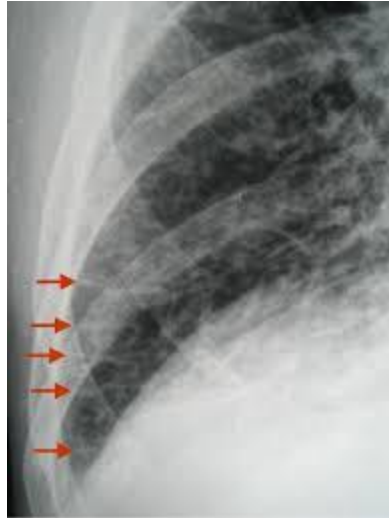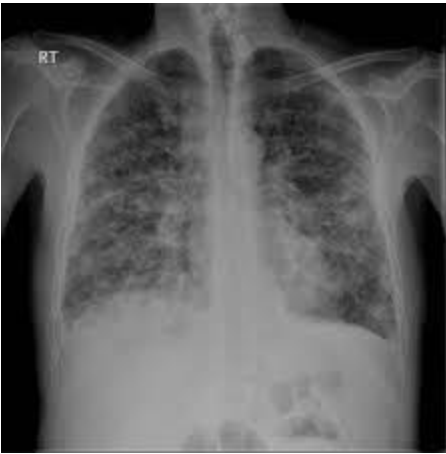Asbestosis



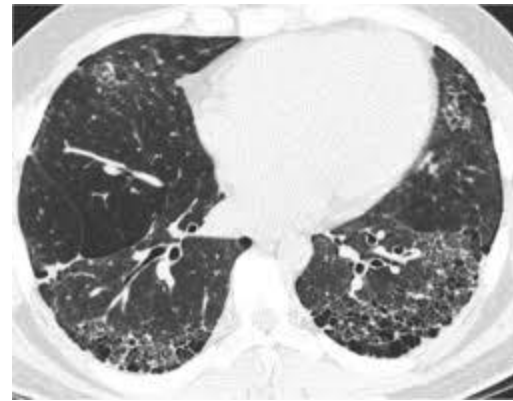
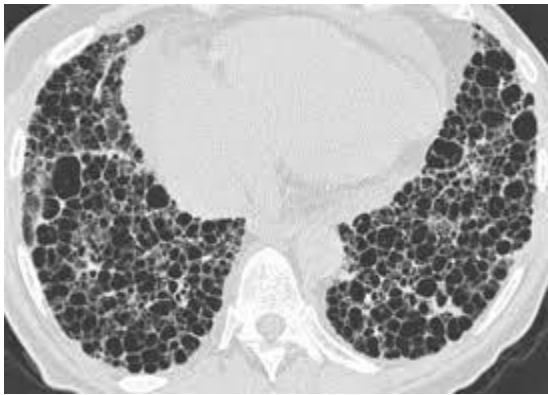
Hypersensitivity pneumonitis



Congestive heart failure

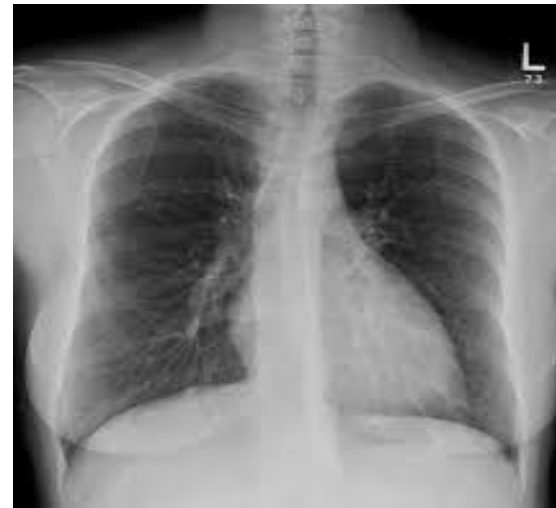
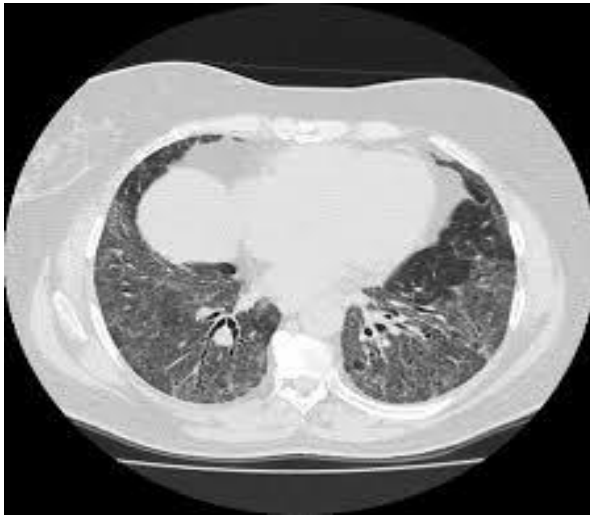
Honeycombing IPF

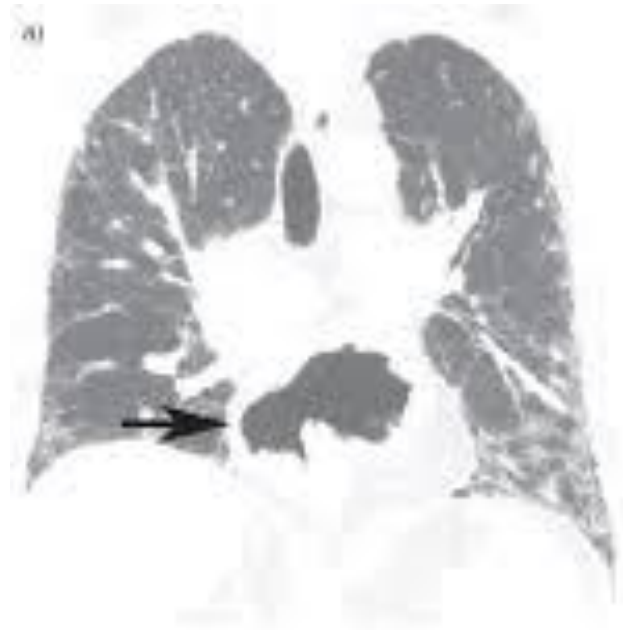

NSIP(nonspecific interstitial pneumonia)

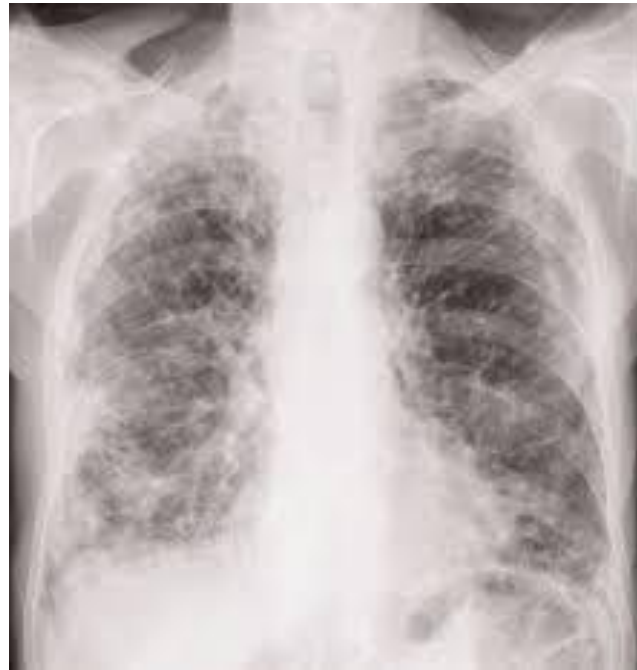GGO



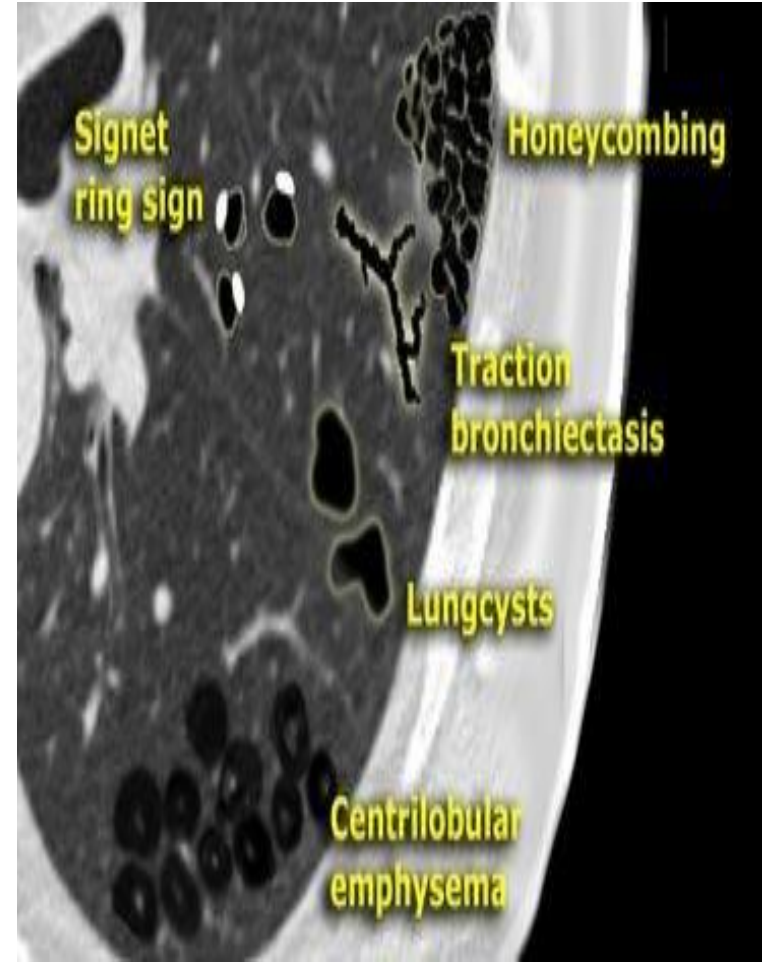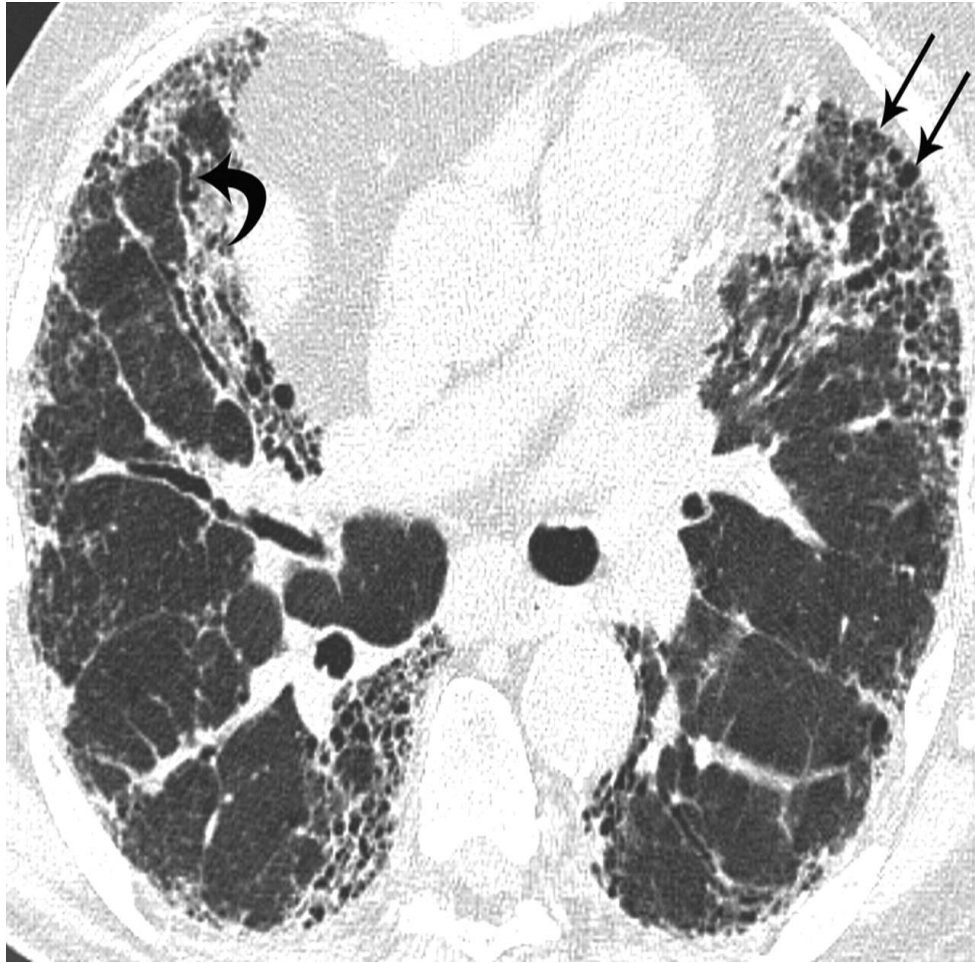
Diagnosis ?

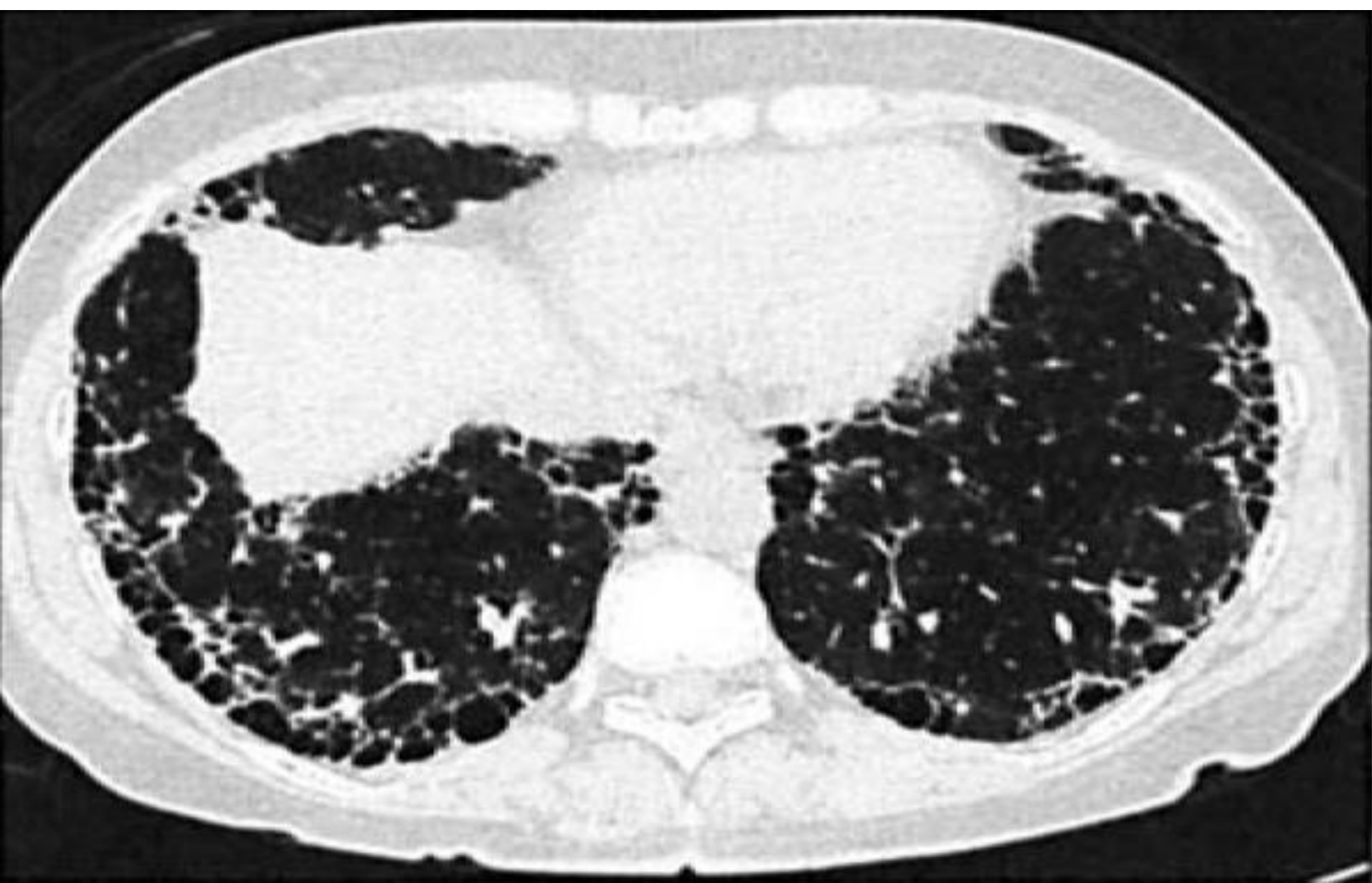


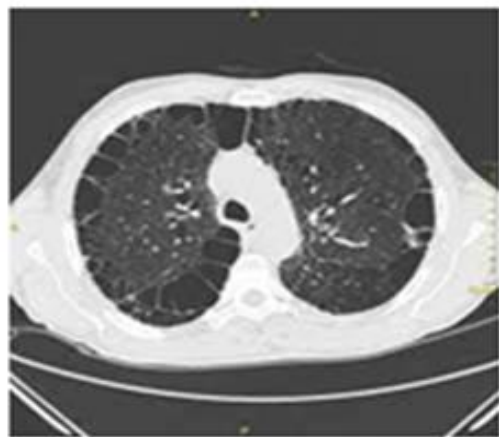
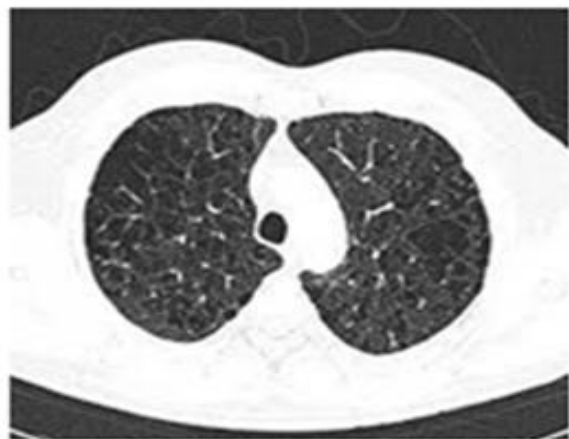Drug induced Radiation induced

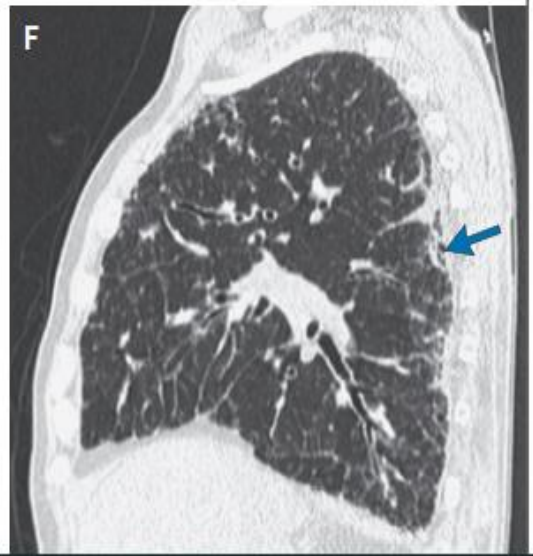
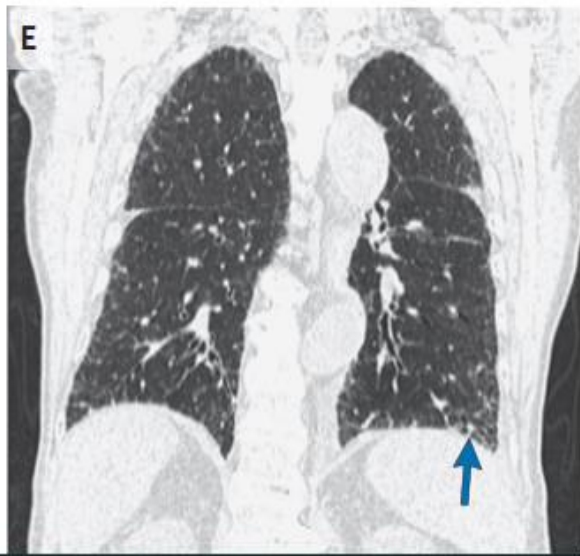
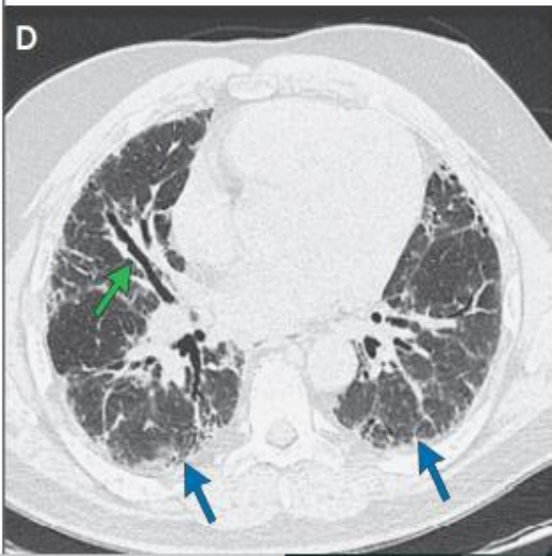
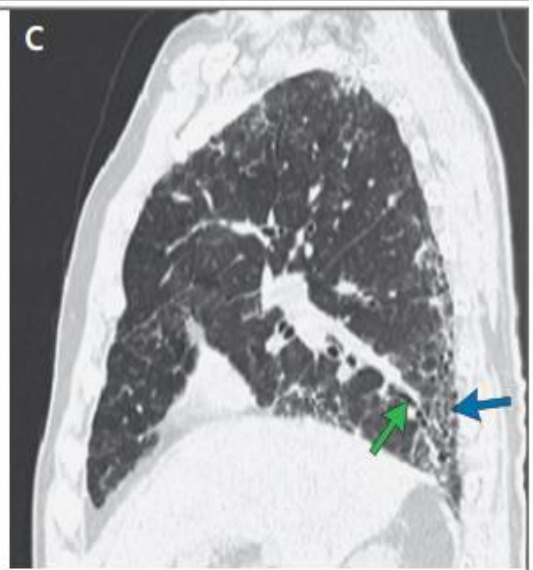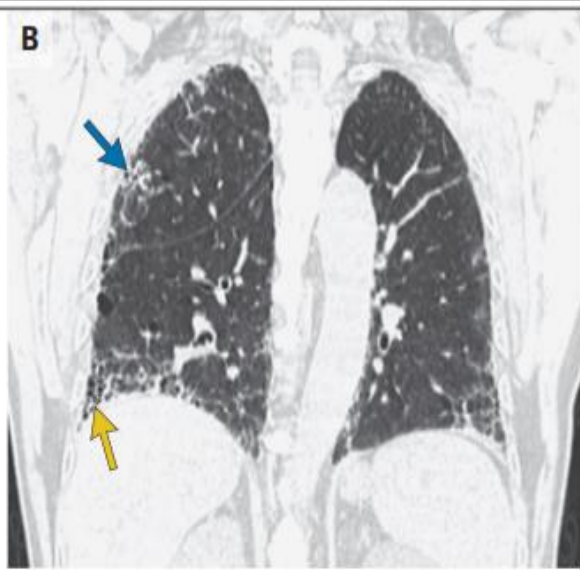
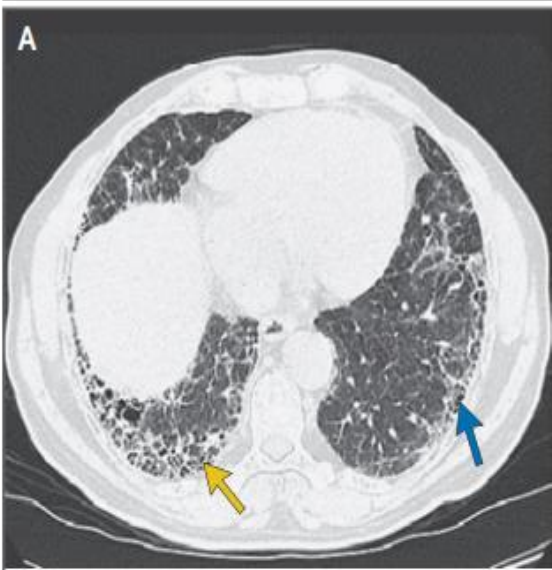


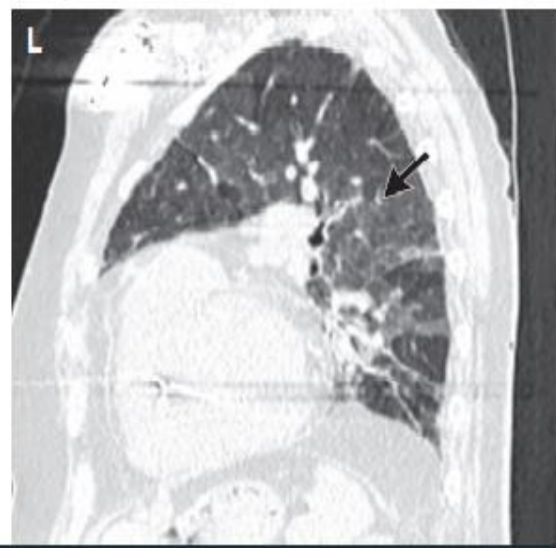
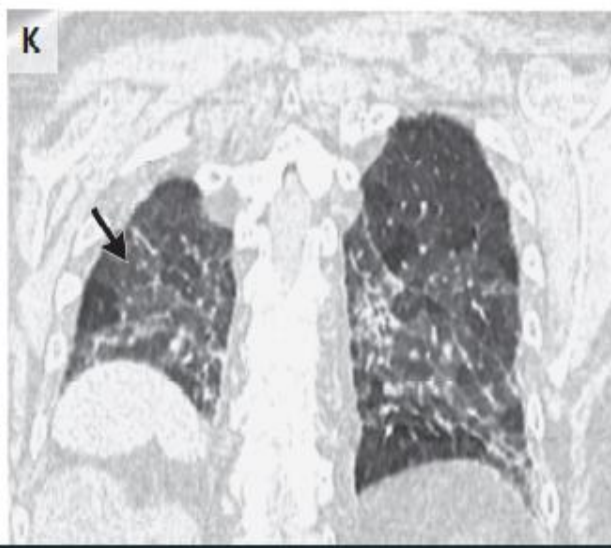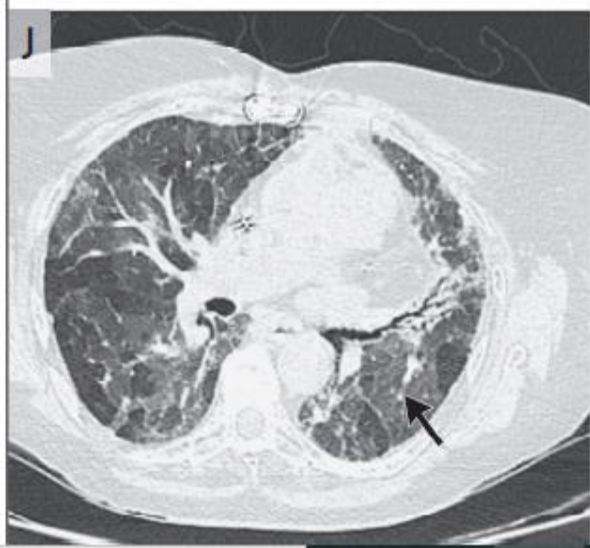
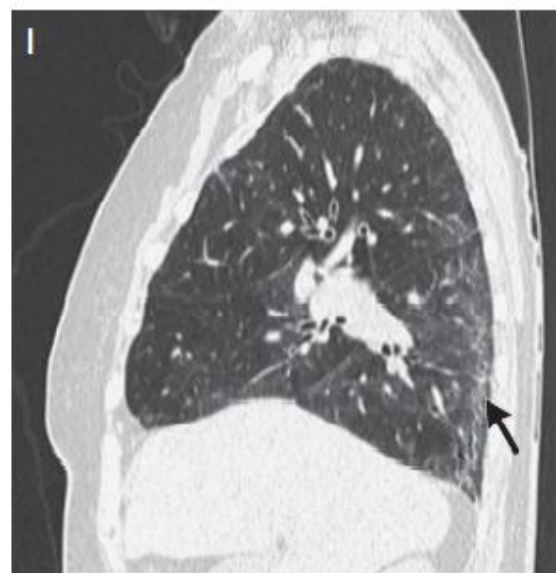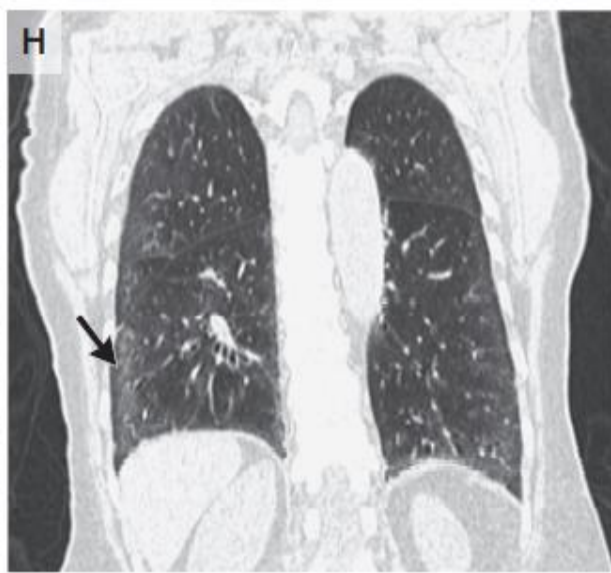
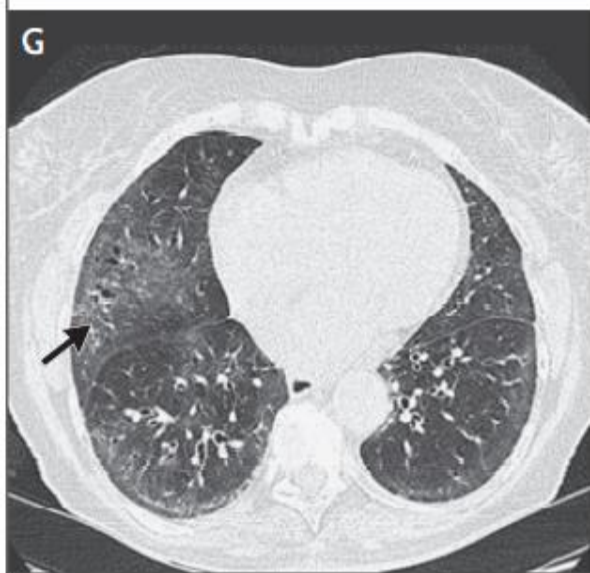
HRCT OF IPF

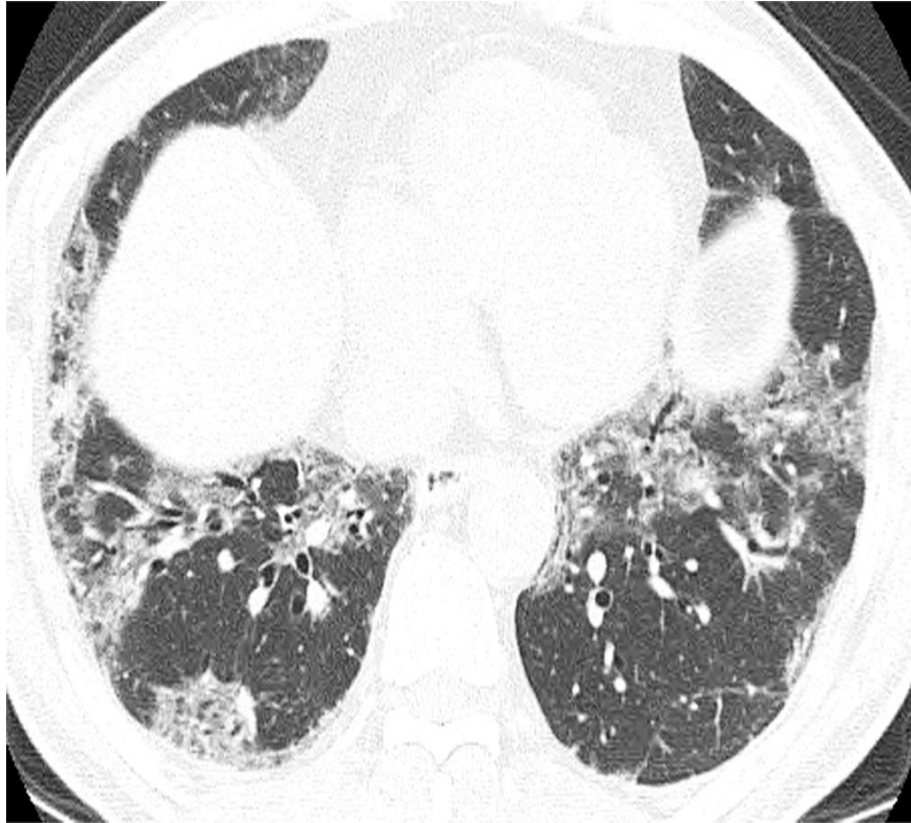


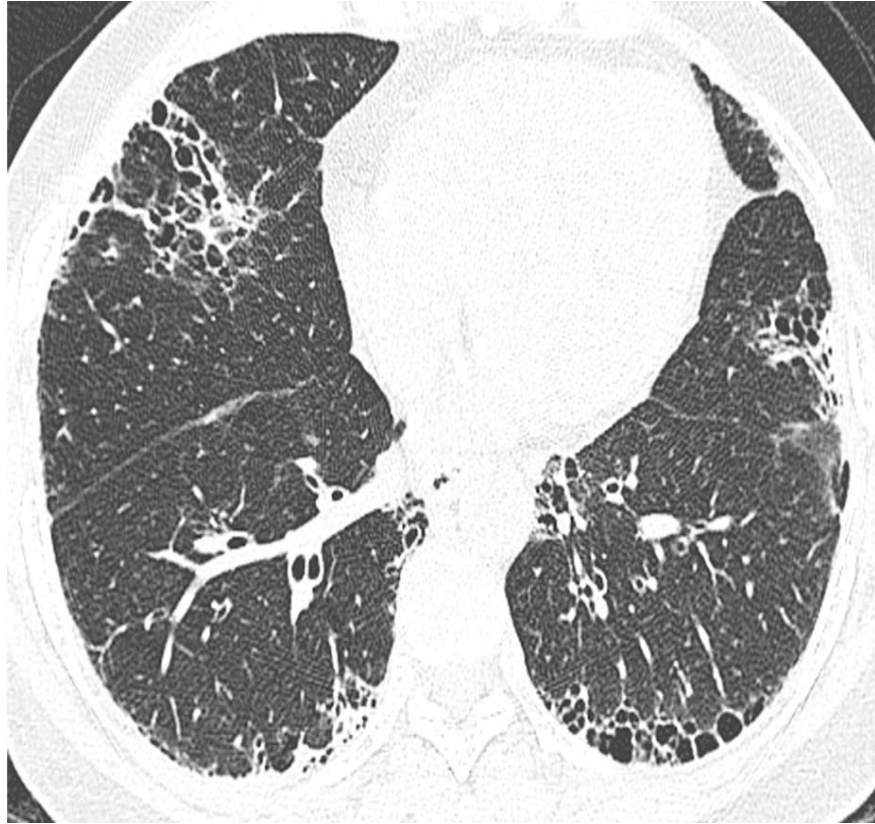


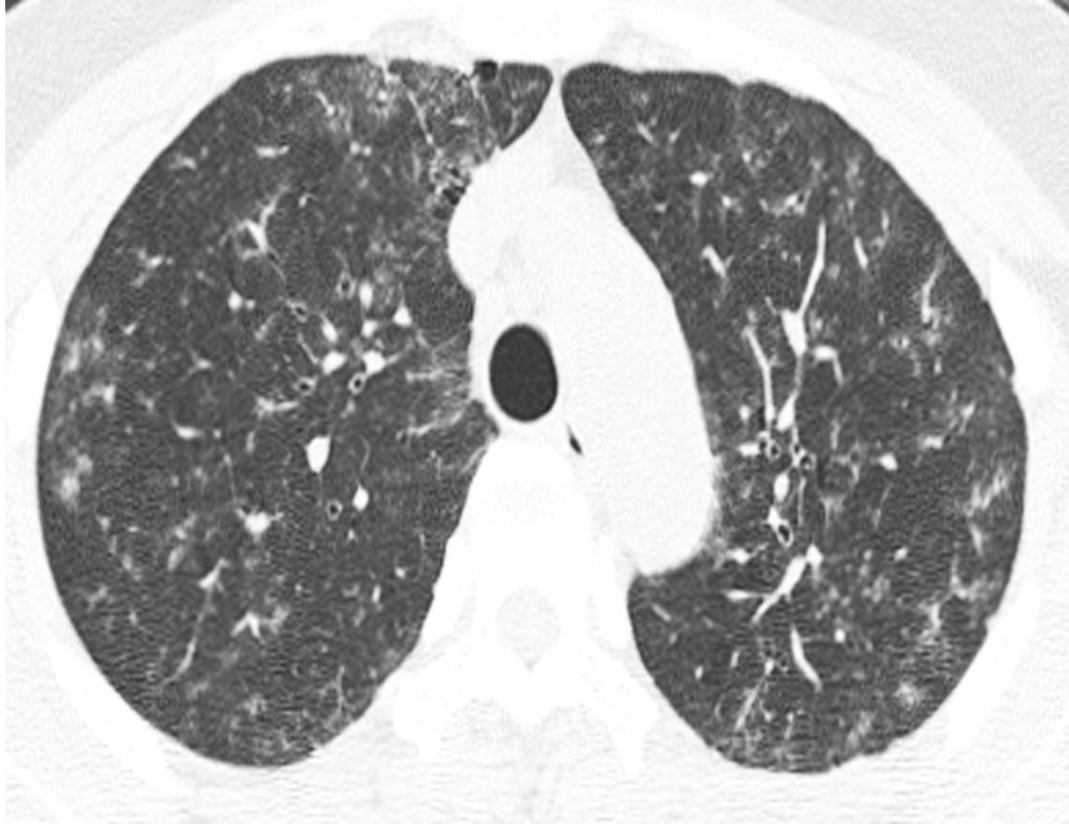

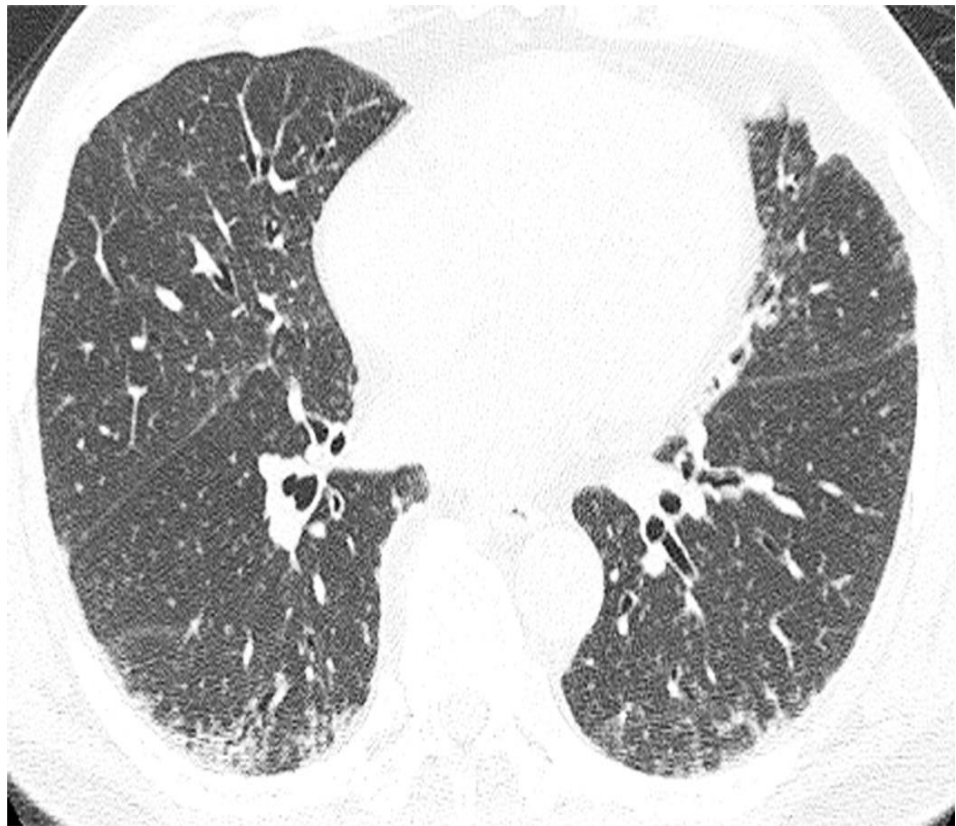












High resolution computed tomography patterns and UIP diagnosis

UIP	Probable UIP	Indeterminate for UIP	Alternative diagnosis
<ul style="list-style-type: none"> ■ Subpleural and basal predominant; distribution is often heterogeneous* ■ Honeycombing with or without peripheral traction bronchiectasis or bronchiolectasis† 	<ul style="list-style-type: none"> ■ Subpleural and basal predominant; distribution is often heterogeneous ■ Reticular pattern with peripheral traction bronchiectasis or bronchiolectasis ■ May have mild GGO 	<ul style="list-style-type: none"> ■ Subpleural and basal predominant ■ Subtle reticulation; may have mild GGO or distortion ("early UIP pattern") ■ CT features and/or distribution of lung fibrosis that do not suggest any specific etiology ("truly indeterminate for UIP") 	<ul style="list-style-type: none"> ■ Findings suggestive of another diagnosis, including: <ul style="list-style-type: none"> ● CT features: <ul style="list-style-type: none"> ○ Cysts ○ Marked mosaic attenuation ○ Predominant GGO ○ Profuse micronodules ○ Centrilobular nodules ○ Nodules ○ Consolidation ● Predominant distribution: <ul style="list-style-type: none"> ○ Peribronchovascular ○ Perilymphatic ○ Upper or mid-lung ● Other: <ul style="list-style-type: none"> ○ Pleural plaques (consider asbestosis) ○ Dilated esophagus (consider CTD) ○ Distal clavicular erosions (consider RA) ○ Extensive lymph node enlargement (consider other etiologies) ○ Pleural effusions, pleural thickening (consider CTD/drugs)

UIP: usual interstitial pneumonia; GGO: ground-glass opacities; CT: computed tomography; CTD: connective tissue disease; RA: rheumatoid arthritis.

* Variants of distribution: occasionally diffuse, may be asymmetrical.

† Superimposed CT features: mild GGO, reticular pattern, pulmonary ossification.

Reprinted with permission of the American Thoracic Society. Copyright © 2019 American Thoracic Society. Raghu G, Remy-Jardin M, Myers JL, et al. Diagnosis of Idiopathic Pulmonary Fibrosis. An Official ATS/ERS/JRS/ALAT Clinical Practice Guideline. *Am J Respir Crit Care Med* 2018; 198:e44-e68. The American Journal of Respiratory and Critical Care Medicine is an official journal of the American Thoracic Society.

Thank you