

Surgical Aspect Of The Spleen

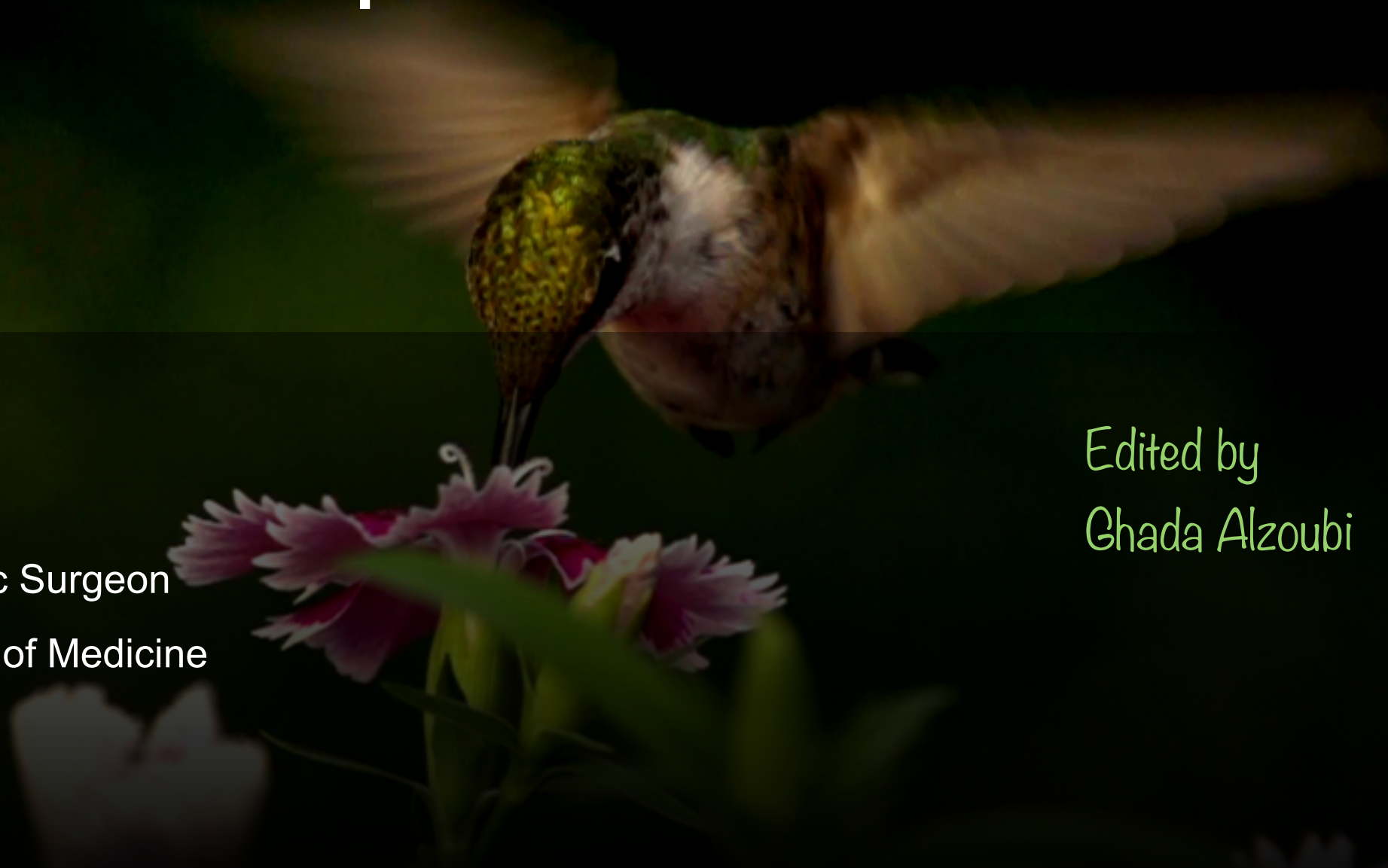Khaled Daradka

Hepatobiliary and Pancreatic Surgeon

Assistant Professor/ Faculty of Medicine

University of Jordan

Edited by
Ghada Alzoubi



Properties of the Normal Spleen

The spleen (largest lymphopoietic organ) is located posterolaterally in the left upper quadrant of the abdomen

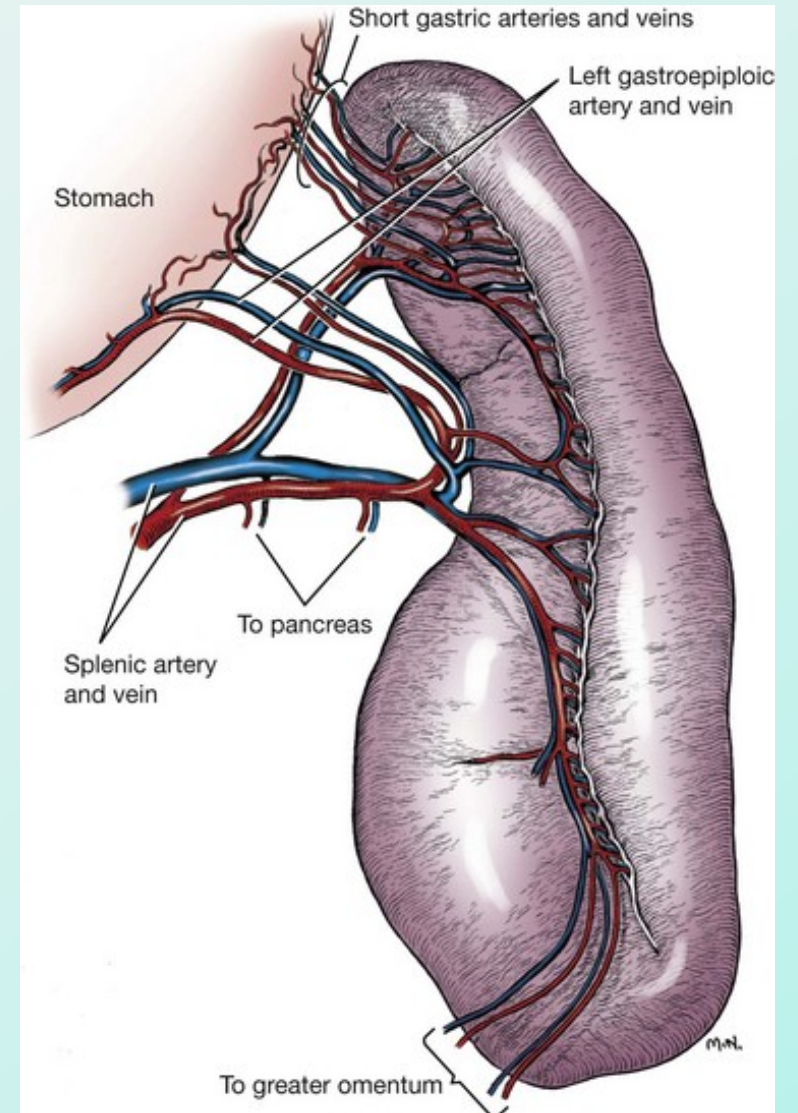
Through 9th to 11th rib

Fragile sponge-like organ

Thicker splenic capsules in children

The splenic artery, from the celiac artery

Three to seven segments, each with its own intraparenchymal **terminal vascular supply**



1, 3, 5, 7, 9, 11

The size of the spleen correlates with a person's height, weight, and sex rule of the odd numbers

1
3
5
كوب
عكس
الارتفاع

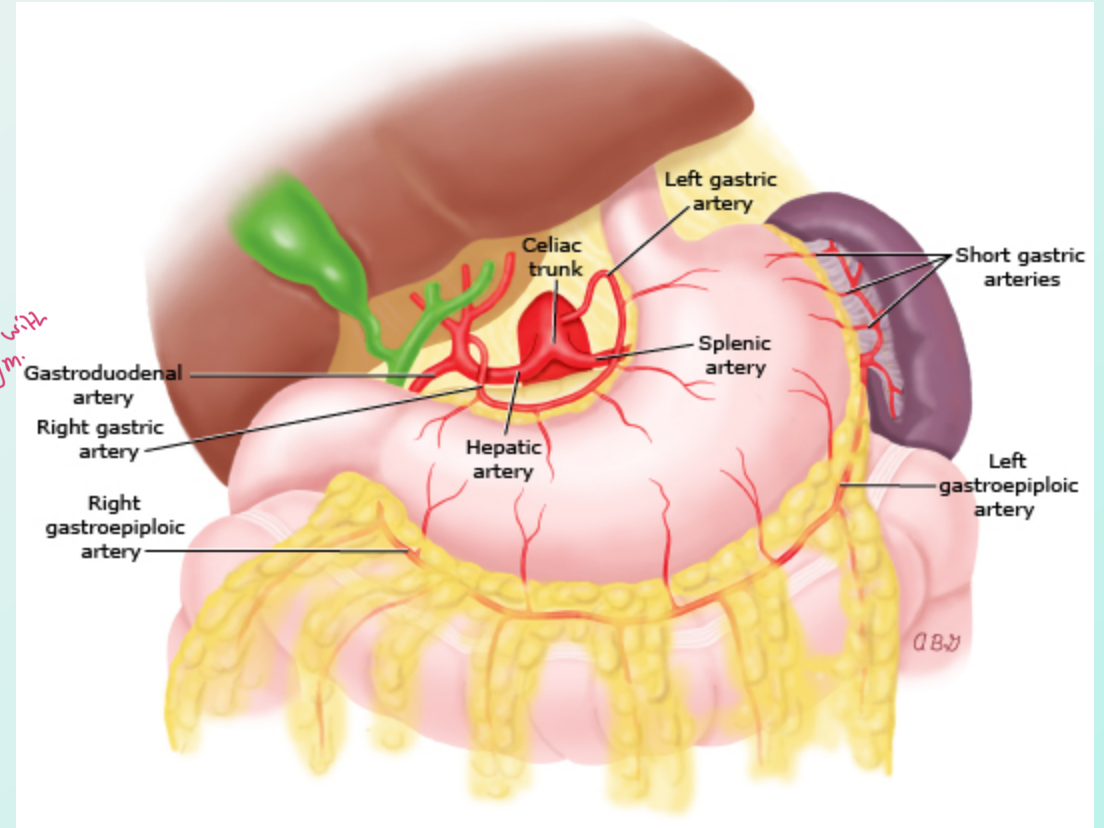
7 - 11

9th Rib } location
11th Rib }

The spleen is attached to surrounding structures via four main ligaments.. the gastrosplenic and splenorenal, splenophrenic and spleno-colic ligaments

→ Association with Diaphragm

Involved in the antibody response against infection, most importantly for opsonization of encapsulated bacteria



Indications for Elective (nontraumatic) Splenectomy

- Broadly include:
 - Conditions with significant hemolysis or thrombocytopenia that depends on splenic function and/or autoantibody production
 - Malignant or infectious disorders predominantly localized to the spleen
 - Removal en bloc with other organs for cancer surgery
 - Rare complications of other disorders in which there is massive splenomegaly and/or hypersplenism with cytopenias

Elective Splenectomy

Not very important

Possibly indicated

Cancer surgery*

Felty syndrome

Hereditary spherocytosis

Immune thrombocytopenia (ITP)

Pyruvate kinase (PK) deficiency

Splenic abscess

Splenic marginal zone lymphoma

Splenic vein thrombosis with bleeding gastric varices

Splenomegaly (massive or symptomatic)

Transfusion-dependent thalassemia

Warm autoimmune hemolytic anemia (AIHA)

Rarely indicated

ABO or HLA desensitization for kidney transplant

Chronic lymphocytic leukemia (CLL)

Hairy cell leukemia

Primary myelofibrosis

Splenic infarction

Splenic sequestration crisis in sickle cell disease

Thrombotic thrombocytopenic purpura (TTP)

Preoperative Considerations

Vaccinations

Splenectomy increases the risk for serious, including life-threatening, infections, especially with encapsulated organisms such as *Streptococcus pneumoniae*, *Haemophilus influenzae*, and *Neisseria meningitidis*.

A good immune response to most vaccines occurs within two weeks, Still ideal timing is 10 to 12 weeks

Annual influenza vaccination can reduce mortality from secondary bacterial infection

Optimizing haemoglobin and platelet count

VTE prophylaxis

Splenectomy carries a higher postoperative VTE risk than other types of major abdominal surgery ~10%

venous thromboembolism

Surgical approach

- **Open versus laparoscopic procedure**

- Settings in which an open procedure may be preferred include the following:

1. **Massive splenomegaly** *we can't put trocha + distend the Abdomen*

2. **Local expertise / lack of support or equipment for laparoscopy**

3. **Ability to search more thoroughly for an accessory spleen** *hilum of spleen, greater omentum, lesser omentum*

Splenectomy may be less effective therapeutically if the accessory spleen is not removed at the time of splenectomy, leading to recurrence of the underlying condition for which splenectomy was performed.

4. **Cancer surgery or adhesion of the spleen to adjacent organs requiring laparotomy**

** Traumatic splenectomy
Accessary spleen
* Pathological splenectomy
we need Exploration
to Remove it, to Avoid
Recurrence
↳ In case of
hematological Disease*

*ولين يكون
موجود*



most common Affected Organ in Blunt trauma → Spleen.

most common Affected Organ in penetrating trauma → Small intestine

Background of splenic trauma

- The spleen and liver are the most commonly injured intra-abdominal organs following blunt trauma.
- Most commonly occurs following motor vehicle collisions.
- Also result from falls, sport-related activities, or assault
- ✓ Penetrating splenic trauma is less common
- Iatrogenic traumatic injuries can result from surgical or endoscopic manipulation of the colon, stomach, pancreas, kidney, or with exposure and reconstruction of the proximal abdominal aorta.
- **Kehr's sign** is pain referred to the left shoulder that worsens with inspiration and is due to irritation of the phrenic nerve from blood adjacent to the left hemidiaphragm

Diagnostic evaluation

FAST Exam → Ultra Sound Examination

- Hypoechoic rim around the spleen

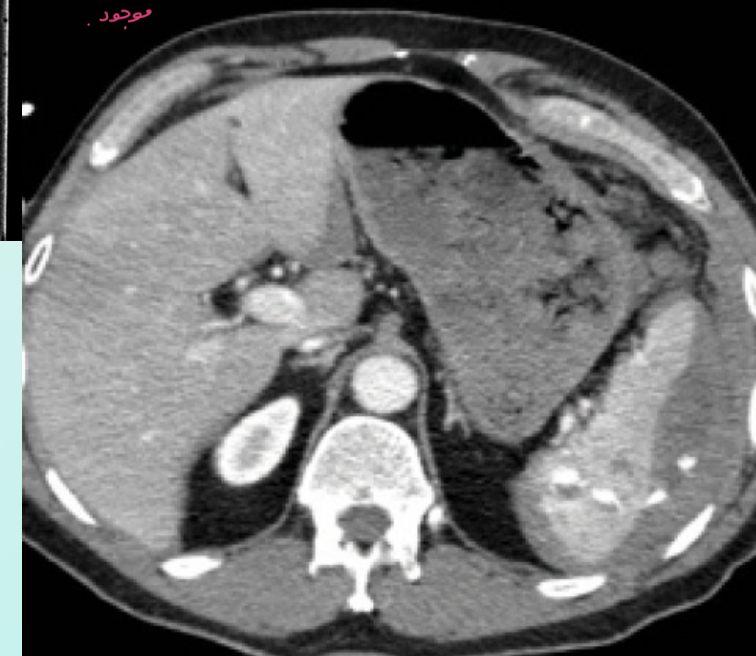
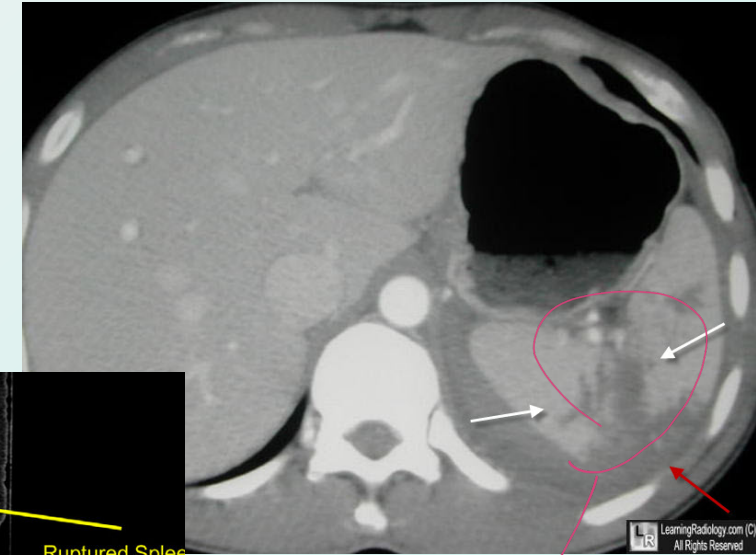
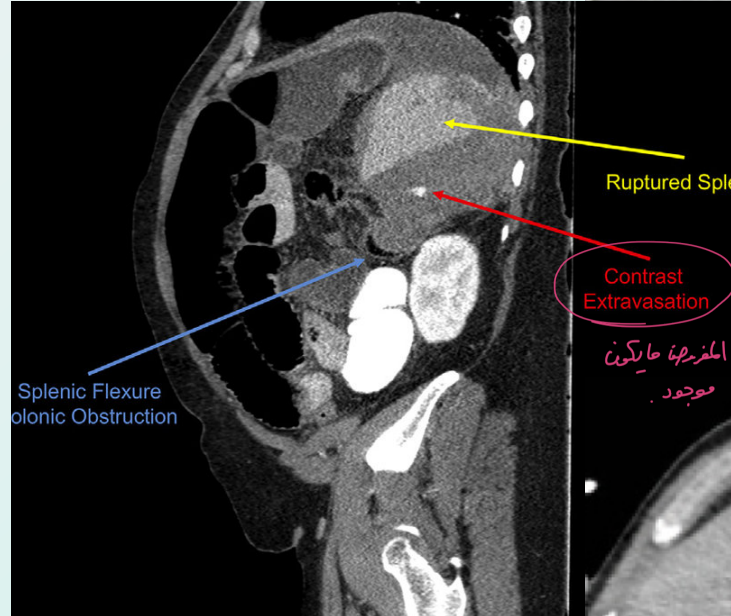
CT scan → if the Pt. hemodynamically stable.

→ getting stable After Resuscitation.

- Hemoperitoneum – Localized fluid collections around the spleen
- Hypodensity – Hypodense regions represent areas of parenchymal disruption, intraparenchymal hematoma, or subcapsular hematoma.

● Contrast blush or extravasation – represent traumatic disruption or pseudoaneurysm of the splenic vasculature.

- Active extravasation of contrast implies ongoing bleeding and the need for urgent intervention

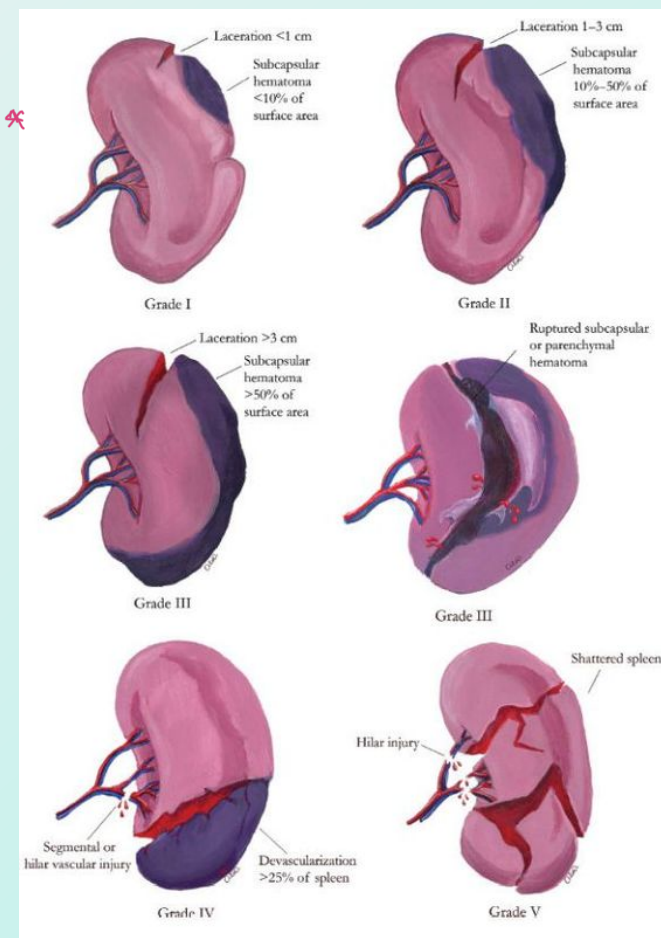


American Association For The Surgery Of Trauma Organ Injury Scale

ليلا خلاص
المسؤولية
ممن حفظ حسب
ميديوها ت لانه

I	Hematoma Laceration	Subcapsular, <10% surface area Capsular tear, <1 cm parenchymal depth
II	Hematoma Laceration	Subcapsular, 10% to 50% surface area Intraparenchymal, <5 cm in diameter Capsular tear, 1 cm to 3 cm parenchymal depth that does not involve a trabecular vessel
III	Hematoma Laceration	Subcapsular, >50% surface area or expanding: ruptured subcapsular or parenchymal hematoma: intraparenchymal hematoma >5 cm or expanding 3 cm parenchymal depth or involving trabecular vessels
IV	Laceration	Laceration involving segmental or hilar vessels producing major devascularization (>25% of spleen)
V	Laceration Vascular	Completely shattered spleen Hilar vascular injury with devascularizes spleen

كل ما زاد ال grade
كل ما زادت الخطوبة

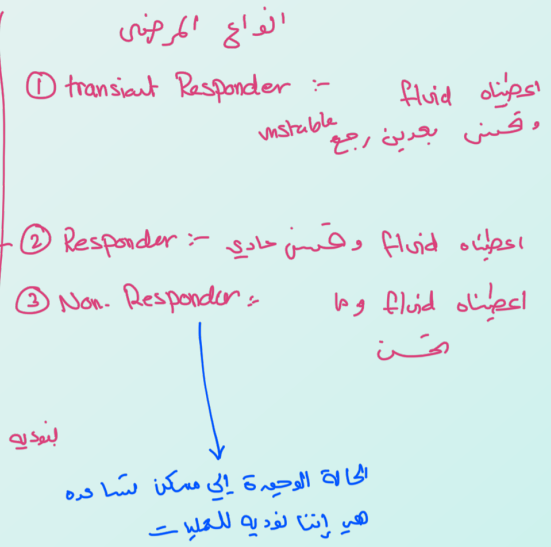


Adapted from American Association for the Surgery of Trauma organ injury scale for spleen.

Case → 26 yrs old healthy male has an car Accident and he put previously seat Belt, but ضرب بالسيدخ

- ↳ has → 1. Lt. lower Rib fracture
- 2. Abcd. pain
- 3. on Examination → Tachy then get stable After Resuscitation
- 4. on CT → splenic injury grade 4 → Next Step ??

Management Approach



Non-operative management

- NOM consists of close observation and monitoring, supplemented with splenic artery embolization if necessary

معلومة مهمة ← Any attempt to salvage the spleen (to preserve functional spleen) is abandoned in the face of ongoing hemorrhage or other life-threatening injuries

* Never try to preserve spleen And losing the pt him self
 * إذا بقدر احافظو على كبريتا، وال spleen يكون اشبه كويب ليس ما احافظو عليه على حساب حياة المرئض
 * كان كان في Risk راجح

- Emergent and urgent splenectomy remains a life-saving measure for many patients

General indications

- ② -continom Hemodynamic stability and absence of other abdominal organ injuries requiring surgery (peritonitis), **irrespective of injury grade**
- ③ An environment that provides capability for intensive monitoring, an immediately available OR and immediate access to blood and blood product

indication for surgery → ① pt. hemodynamically unstable and No other way to stop bleeding Except intra-operatively.
 → ② stable but there are signs of peritonitis / Air under diaphragm [perforated viscus]

Doctor Khaled said → The most common affected organ in Blunt trauma is Solid organ → 1. spleen
 → 2. liver

بالسنة مرة
 دمرة
 spleen

* Liver act in Agood way in trauma situations → لا يفرغ إلى ينيج اد
 mortality is very high ← يمكن إيقاف النزيف ← بـ مجاله في نزيف و ماوقف مس ←
 coagulation factors

* on the other hands → Bleeding in spleen will never ever stop by it self like liver
 Except in case if the capsule of spleen still intact → يمكن تكتف الة قش
 thick capsule ← في حالها عند الة قش

Splenic Artery Embolization

→ the idea of it → Block splenic Artery to stop Bleeding.

two types :-

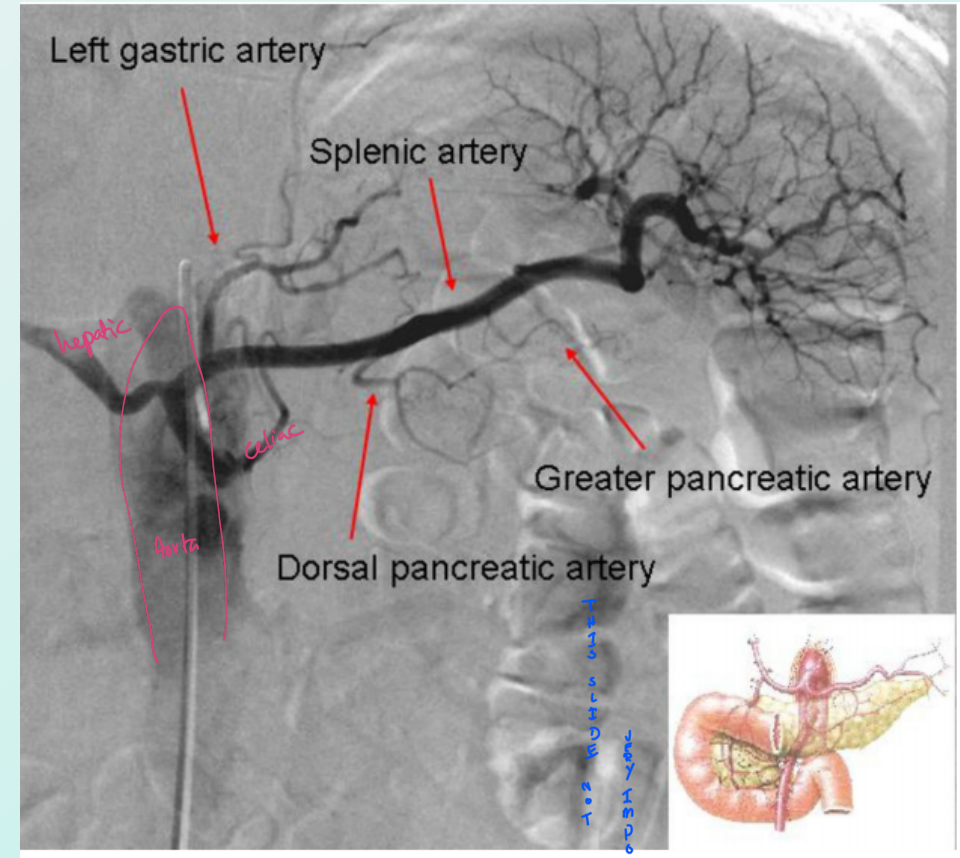
Distal (selective) Embolization

- Vascular injury such as contrast extravasation (blush), pseudoaneurysms
- As close as possible to the site of bleeding in order to limit parenchymal infarction

Proximal Embolization

→ behind the blood supply of the pancreas

- Lowers distal systolic arterial pressure by 40 mm Hg on average, enhancing the healing process
- Preventive embolization seems to have potential in High-grade trauma (Splenoctomy decreased by 16% to 18%) Patients who have high-risk prognosis factors



Short gastric → قبل ال Short gastric
 Antecy → Embolization قبل ال Short gastric

* كمال على proximal → مع ميزية عنبر ال Risk لجموت لا spleen ← بـ الفكرة منها إنا فاضل على متناقله
 Collateral from Short gastric Antecy ← another blood supply → Anotomically
 ↳ = preserved the Spleen.

Note

THIS IS THE MAIN TASK

Risk Factors For Failure Of NOM

- Age → increasing Age
- Grade of injury and the quantity of hemoperitonium (مقدار الدم في البطن)
- Concomitant solid organ injury → another solid organ injury
- Vascular abnormality.. Contrast blushes.. Pseudoaneurysms... A-V fistula...
- **None** has been shown to consistently predict success or failure of nonoperative management
- **Timing:**
- An observation period of five days identifies at least 95 percent of patients who would require some form of intervention
- The failure rate of NOM is around 10-15%

grade +1 → Days of observation.

Pros and Cons of NOM

• Advantages

- Preservation of functional spleen
- Overwhelming post-splenectomy infection
- Surgical risks and potential complications
- Shorter hospitalisation period and a concomitant reduction in costs

• Disadvantages

- Risk of delayed splenic rupture/ re-bleeding
- Increased risk of missed injuries (hollow viscus)
- Transfusion related complications
- SAE Risks if used:
 - Splenic infarction
 - Splenic/subdiaphragmatic abscess
 - Inadvertent embolization of other organs (eg, pancreas) or lower extremities
 - Allergic reaction to contrast
 - Contrast-induced renal insufficiency

Operative management

Positive FAST means that the bleeding coming from the abdomen

- Indicated for the hemodynamically unstable trauma patient who has a positive focused assessment with sonography in trauma (FAST exam) or diagnostic peritoneal aspiration/lavage (DPA/DPL) to control life-threatening hemorrhage, which may be due to an injured spleen OR those who failed NOM

“Unstable” patient:

- Blood pressure < 90 mmHg and heart rate > 120 bpm
- Evidence of skin vasoconstriction (cool, clammy, decreased capillary refill)
- Altered level of consciousness and/or shortness of breath
- Transient responder patients are to be considered as unstable patients.

Associated intra-abdominal injuries (**peritonitis**) are indications for surgery

Splenectomy vs Salvage

- The small future risk of overwhelming postsplenectomy sepsis needs to be balanced against the more significant risk of recurrent hemorrhage
-
- Splenectomy is the safest option, given that most patients who require damage-control surgery are on the brink of physiological collapse; are hypothermic, acidotic, coagulopathic; and will likely only poorly tolerate recurrent hemorrhage
-
- The shift toward nonoperative management with angiographic embolization has decreased the number of patients who would be ideal candidates for operative splenic salvage techniques
-

Splenorrhaphy

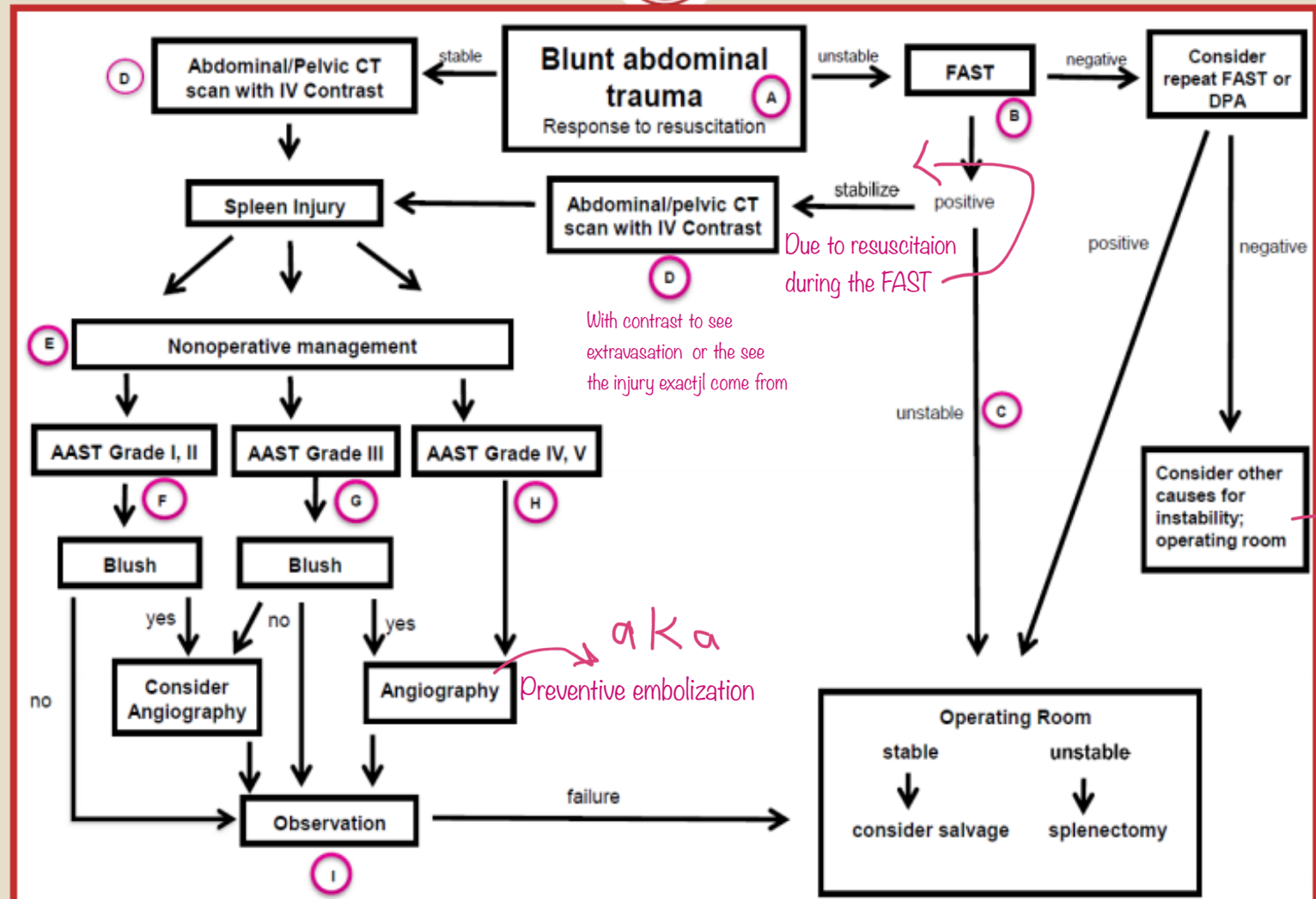
- Splenorrhaphy refers to the suture repair of the spleen with or without splenic wrapping.
- Hemostasis can be achieved with topical hemostatic agents, electrocautery, or argon beam coagulation *Tools that used to preserved hemostasis state*
-

Partial splenectomy

Partial splenectomy is a form of splenic salvage and refers to the removal of a portion of the spleen based upon its segmental blood supply

Western Trauma Association - Algorithms

Adult Splenic Injury - 2015



Due to resuscitation during the FAST

With contrast to see extravasation or the see the injury exactjl come from

aka Preventive embolization

We dose not consider it for lapratomy , because of the bleeding is not from the abdomen

Surgical Outcomes And Complications

- The mortality rate for patients undergoing surgery for **isolated** splenic injury is dependent on the grade of injury, as well as the presence or absence of shock.
- Mortality can be as high as 22 percent for grade V injury
- **Postoperative bleeding**
- **Perioperative infection**
 - Pulmonary complications are the most common postoperative infection
 - Intra-abdominal abscess
- **Gastric perforation** Uncommon but can result from necrosis of the gastric wall
- **Pancreatic fistula**

Vascular thrombosis

- Portal, mesenteric, and splenic veins appear to be affected more often. DVT and PE are still a risk

Thrombocytosis

- Usually peaking between 7 and 20 days postoperatively, and then falling to normal levels over weeks to months, but sometimes over years

Splenosis

- Iatrogenic rupture of the spleen during splenectomy can cause subsequent implantation of splenic tissue within the peritoneal cavity, also referred to as splenosis
- This generally does not require any intervention, but it could cause abdominal pain, partial return of splenic function, or other complications

Risk for malignancy

Postsplenectomy sepsis Overwhelming post-splenectomy infections (**OPSI**)

- Fever in a patient with impaired splenic function is a warning sign for possible sepsis and should be treated as a medical emergency
- Postsplenectomy sepsis is a fulminant and rapidly fatal illness due to encapsulated pathogens
- The incidence of postsplenectomy sepsis associated with splenic injury appears to be lower than that for splenectomy performed for other indications.
- **Immunizations**
- Immunisation against encapsulated organisms.
- Following splenorrhaphy or partial splenectomy, the need to immunize is unclear

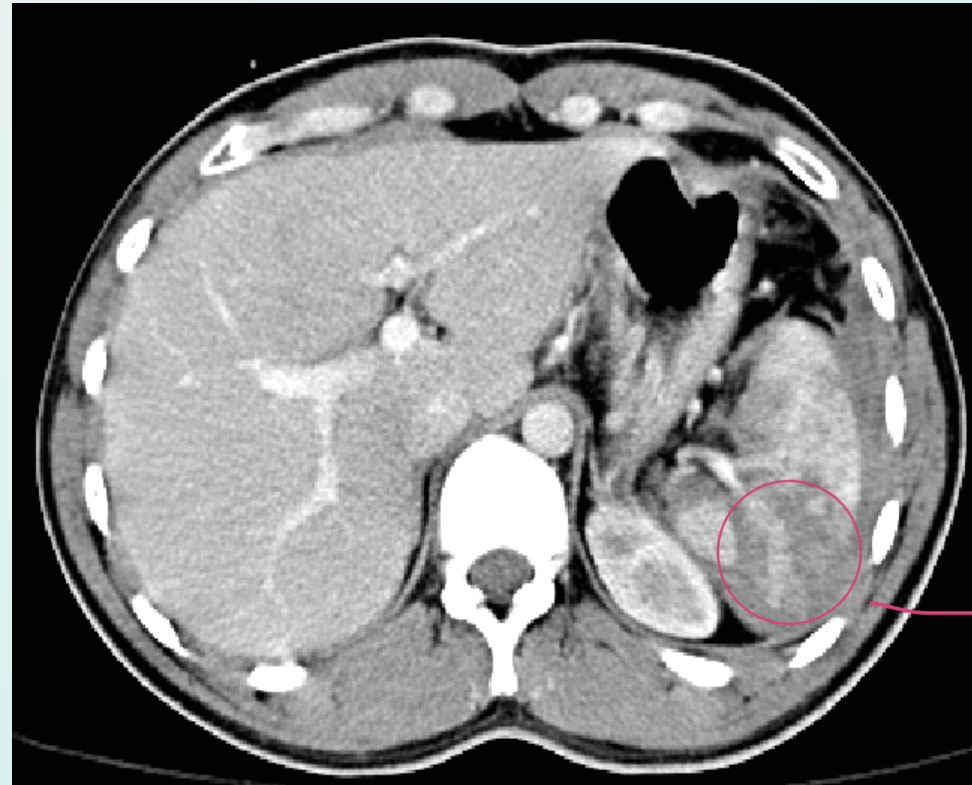
Long Life Prophylactic Antibiotics

- Recommendations for prophylactic antibiotics vary
 - A common recommendation for children <5 years of age is for antibiotic prophylaxis for at least two years following splenectomy
 - For children and adults with concurrent immunocompromising conditions, daily antibiotics until at least age 18 or for life.
 - For children or adults with history of sepsis or other severe infections caused by encapsulated organisms. lifelong prophylaxis.
 - For adults, at least one year following splenectomy
- The disadvantages of long-term antibiotic use are not insignificant
 - These include the potential for hypersensitivity reactions, alteration of the microbiome, the emergence of drug-resistant pathogens, difficulty with adherence and incomplete protection

Clinical Scenario

- 65 yr old male pt, RTA *Road traffic accident*
- On admission GCS 14/15
- B/P 85/50 HR 130 *Unstable pt.*
- After Fluids resuscitation B/P120/70 HR 88
- Responder pt.* Examination: left upper quadrant tenderness without peritoneal signs.
- Underwent CT scan..

NOM



No contrast here

الاشياء التي ممكن تؤدي لفشل ال NOM
العمر و إنه بال CT ثلاث ارباع ال spleen رايح

THANK YOU