

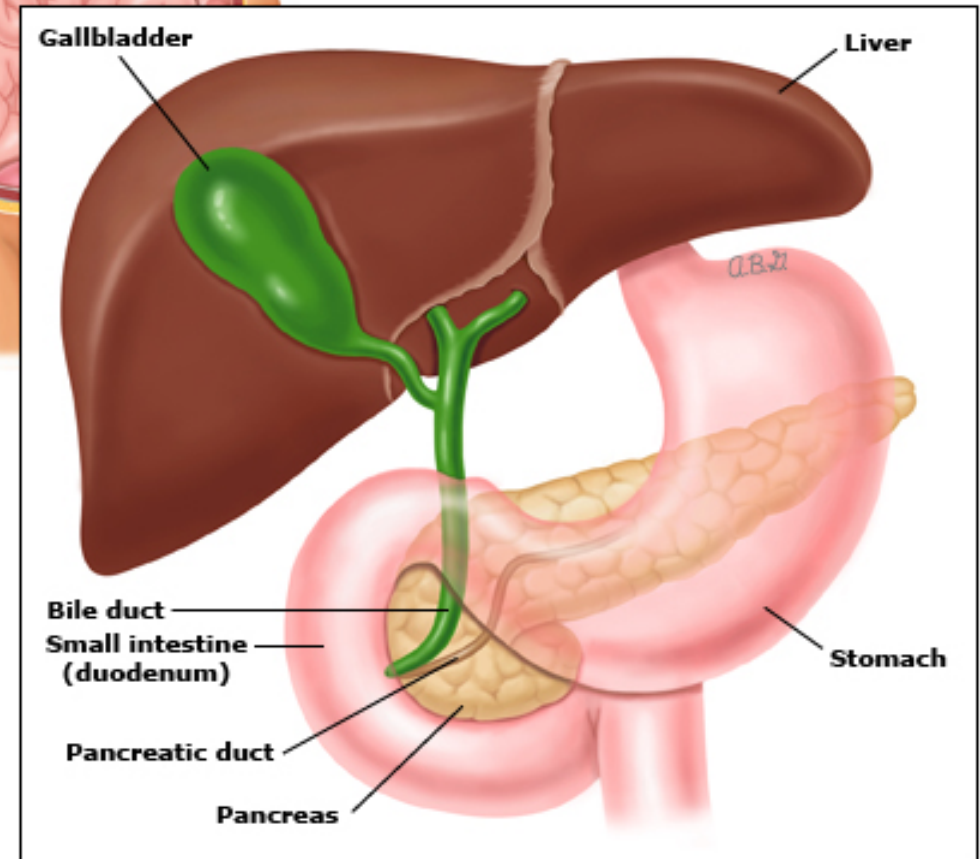
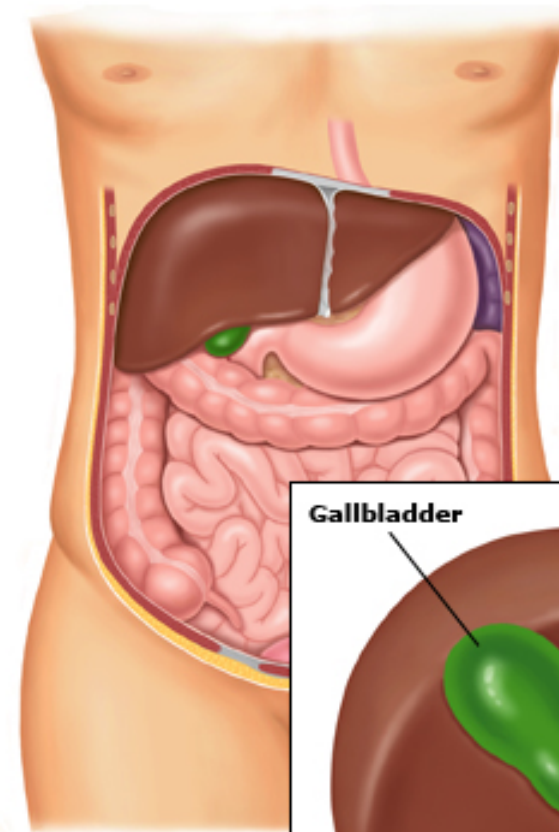
# Pancreatic Cancer

Khaled Daradka MD

Assistant Professor/ School of Medicine

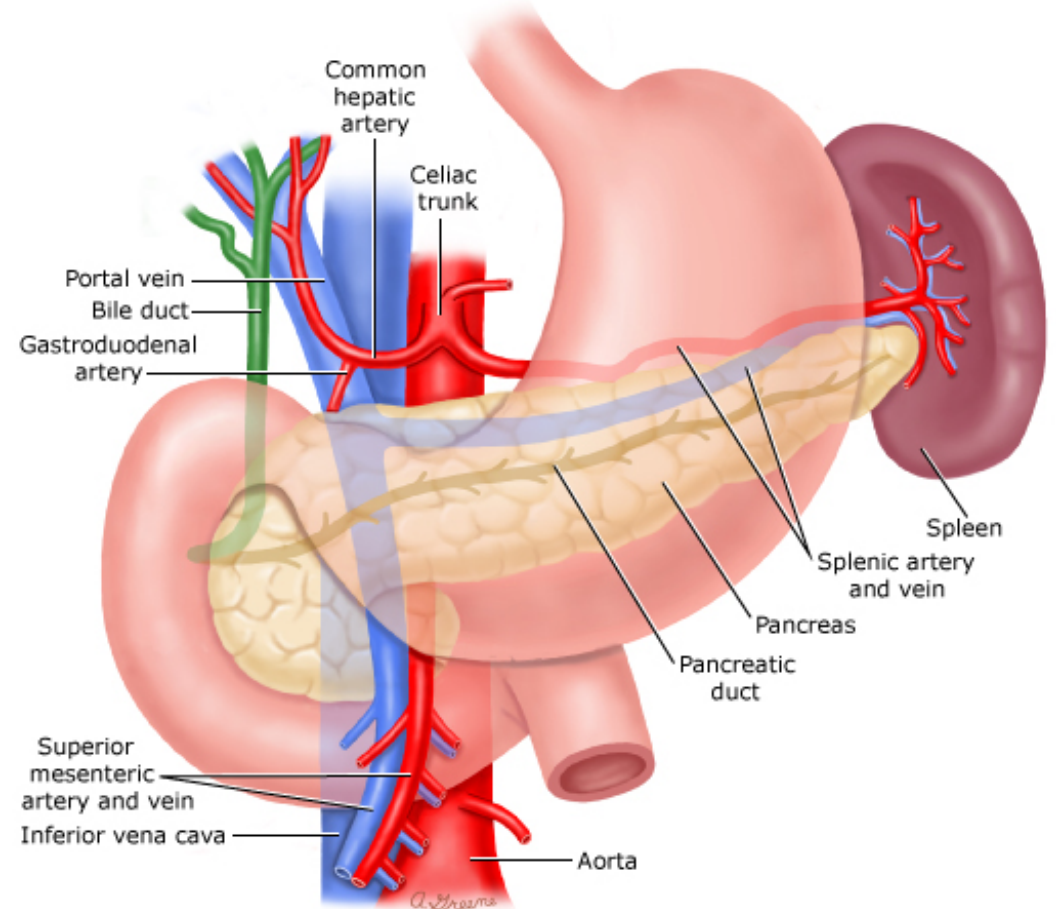
HPB & General Surgery Consultant

The University of Jordan



# Introduction

- The pancreas gives rise to several malignant and benign neoplasms
- More than 95% of malignant neoplasms of the pancreas arise from the exocrine elements.
- The commonly used term "pancreatic cancer" usually refers to a ductal adenocarcinoma of the pancreas (including its subtypes), which represents approximately 85 to 90% of all pancreatic neoplasms.
- Neoplasms arising from the endocrine pancreas (pancreatic neuroendocrine [islet cell] tumors) comprise no more than 5%.



# Epidemiology

- Worldwide, pancreatic cancer is the seventh leading cause of cancer deaths.
- Affects more Western/industrialized parts of the world.
- The disease is rare before the age of 45, Incidence rises sharply thereafter.
- Cases peaked at age 65 to 69 for men and at 75 to 79 for women
- The incidence is greater in males (1.3:1)
- 62% involving the head of the gland, 10% body, 6% tail, and the remainder not determined

# Risk Factors

- High fasting plasma glucose
- High body mass index (BMI)
- Lack of physical activity
- **Environmental risk factors**
  - **tobacco use**, diet, alcohol consumption, and high caloric intake
- Pancreatic cysts
- Nonhereditary chronic pancreatitis
- **Hereditary risk factors**
  - Two broad categories: defined **genetic predisposition** syndromes and familial pancreatic cancer
  - 5 to 10 percent of individuals with pancreatic cancer have a family history

**Inherited  
cancer  
syndromes  
associated with  
increased risk  
of pancreatic  
cancer**

Hereditary breast/ovarian cancer	<i>BRCA2, BRCA1</i>
	<i>PALB2</i>
Familial atypical multiple mole melanoma syndrome	<i>CDKN2A</i>
Peutz-Jeghers syndrome	<i>STK 11</i>
Hereditary nonpolyposis colon cancer (Lynch syndrome)	DNA mismatch repair genes
Hereditary pancreatitis	<i>PRSS1, SPINK1</i>
Ataxia telangiectasia	<i>ATM</i>
Li-Fraumeni syndrome	<i>P53</i>
Familial adenomatous polyposis	<i>APC</i>

# Classification

1. **Benign** — serous cystadenoma.
2. **Premalignant lesions**
3. **Malignant**
  - Ductal adenocarcinoma and its subtypes
  - IPMN with an associated invasive carcinoma
  - MCN with an associated invasive carcinoma
  - Solid pseudopapillary neoplasm
  - Acinar cell carcinoma
  - Pancreatoblastoma
  - Serous cystadenocarcinoma

# Pathology

The more inclusive term "exocrine pancreatic neoplasms" includes all tumors that are related to the pancreatic ductal and acinar cells and their stem cells (including pancreatoblastoma).

Several subtypes of ductal adenocarcinoma, most have a similar poor long-term prognosis, with the exception of colloid carcinomas, which have a better prognosis, and adenosquamous cancers, which have a worse prognosis.

In general, all are treated similarly.

# Clinical Presentation

The initial presentation of pancreatic cancer varies according to tumor location. Approximately 60 to 70% are localized to the head of the pancreas.

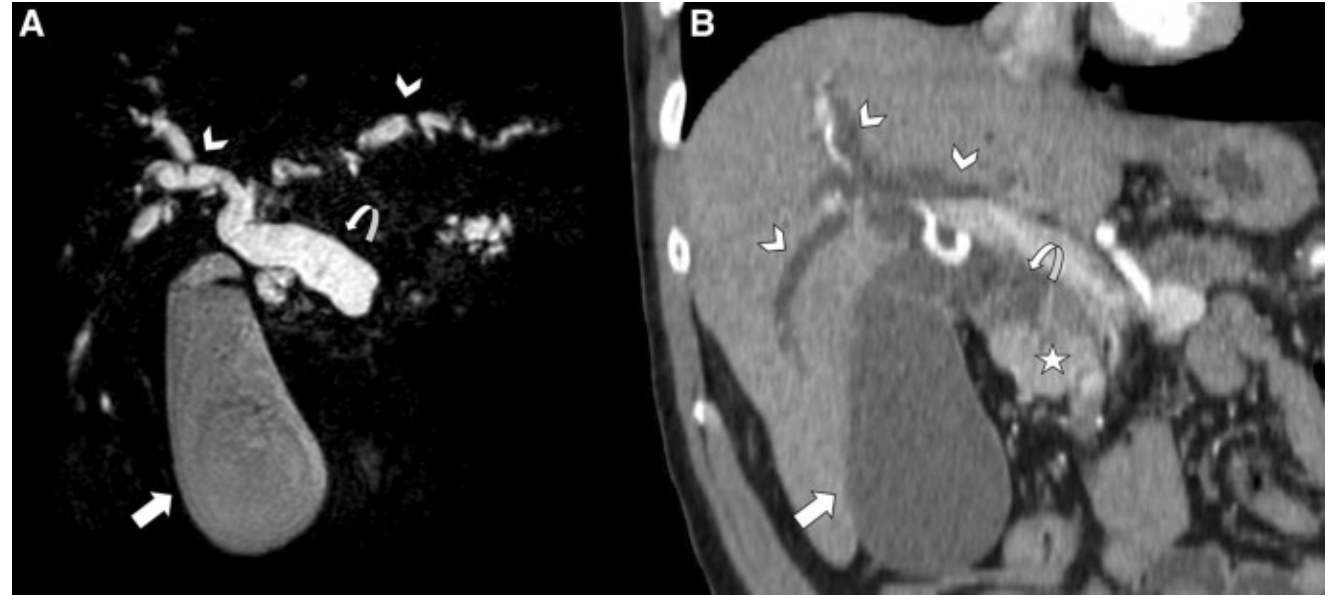
The most common presenting symptoms are **pain, jaundice, and weight loss.**

Asthenia	Weight loss
Anorexia	Abdominal pain
Dark urine	Jaundice
Nausea	Back pain
Diarrheal	Vomiting
Steatorrhea	Thrombophlebitis

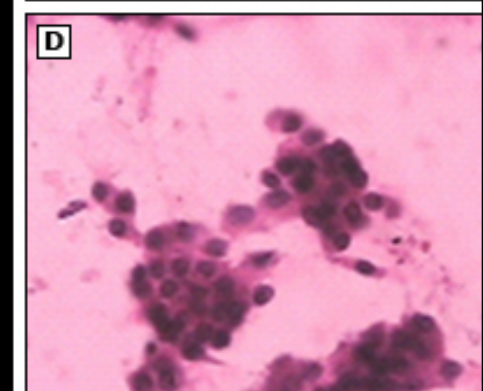
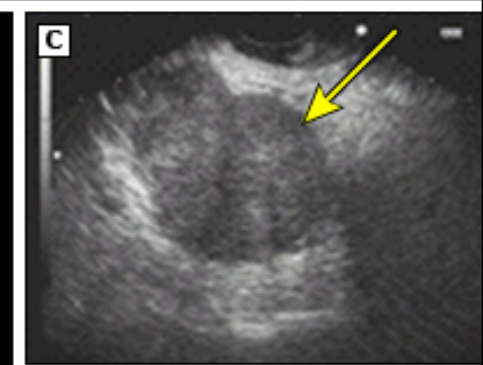
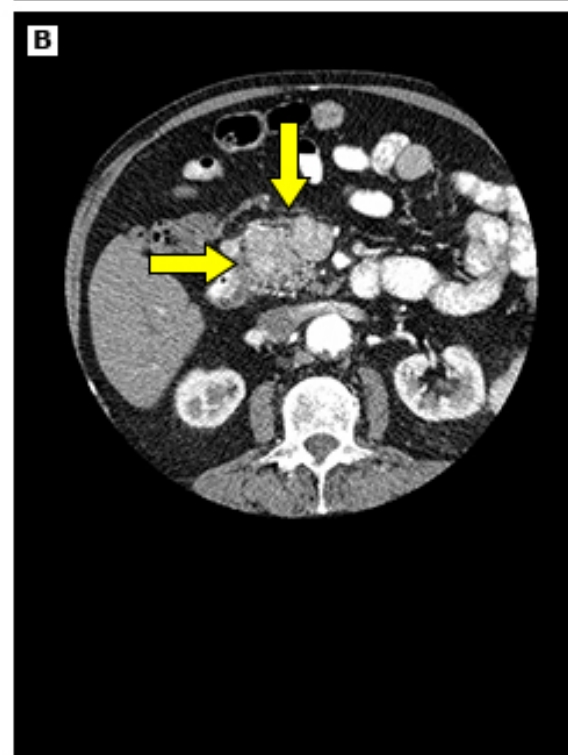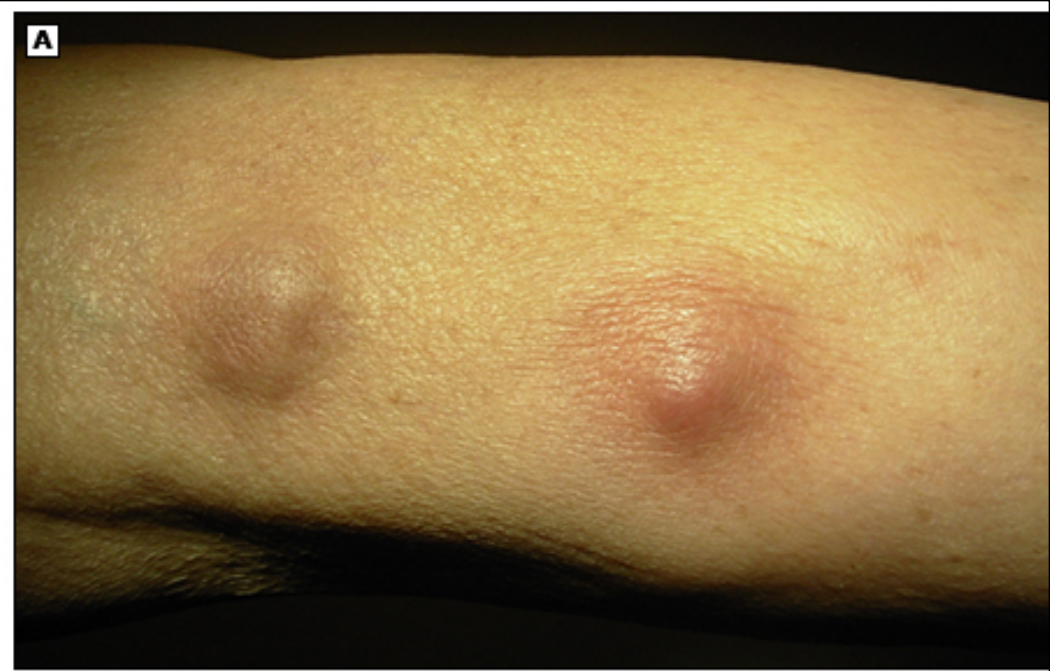


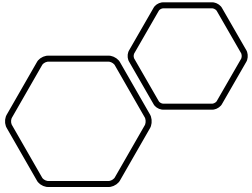
The most frequent signs:

- Jaundice
- Hepatomegaly
- Right upper quadrant mass
- Cachexia
- Courvoisier's sign (nontender but palpable distended gallbladder at the right costal margin)
- Epigastric mass
- Ascites



- Unexplained superficial thrombophlebitis, which may be migratory (classic Trousseau's syndrome), is sometimes present and reflects the hypercoagulable state that frequently accompanies pancreatic cancer.
- Rarely, erythematous subcutaneous areas of nodular fat necrosis, typically located on the legs (pancreatic panniculitis).

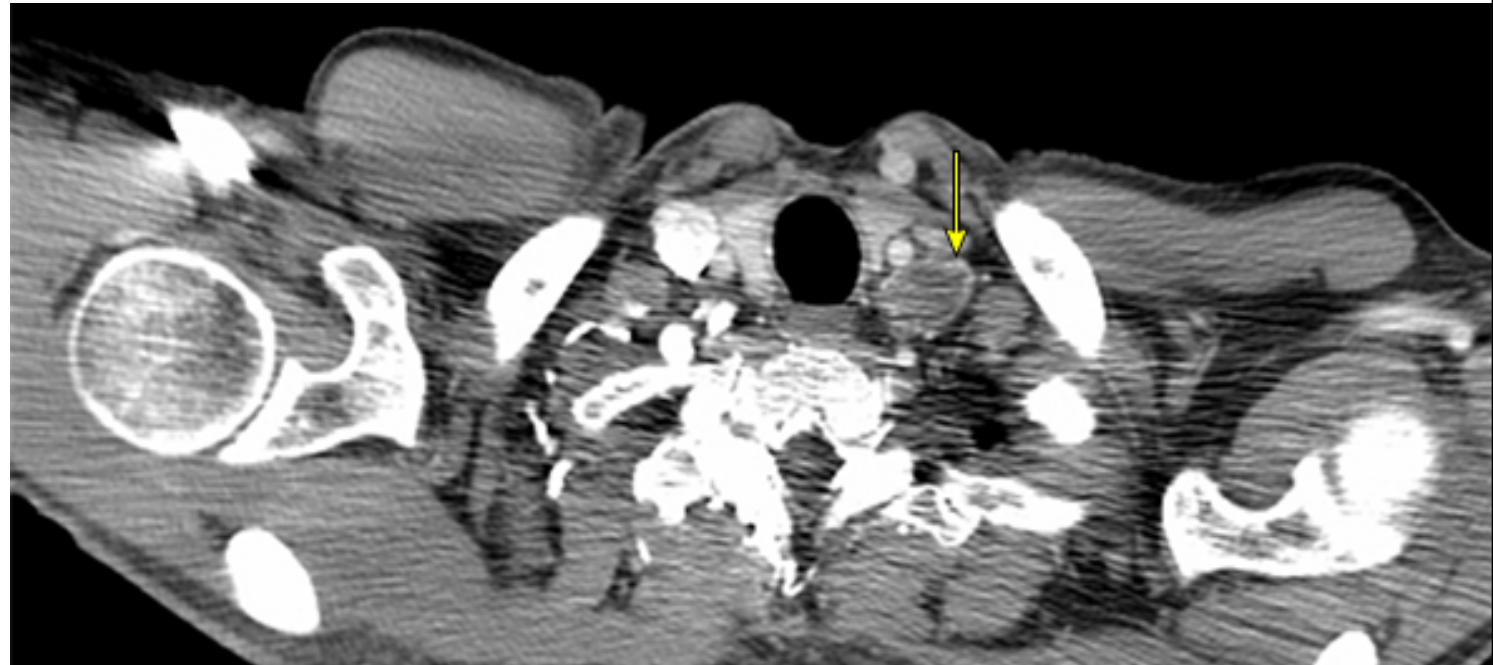
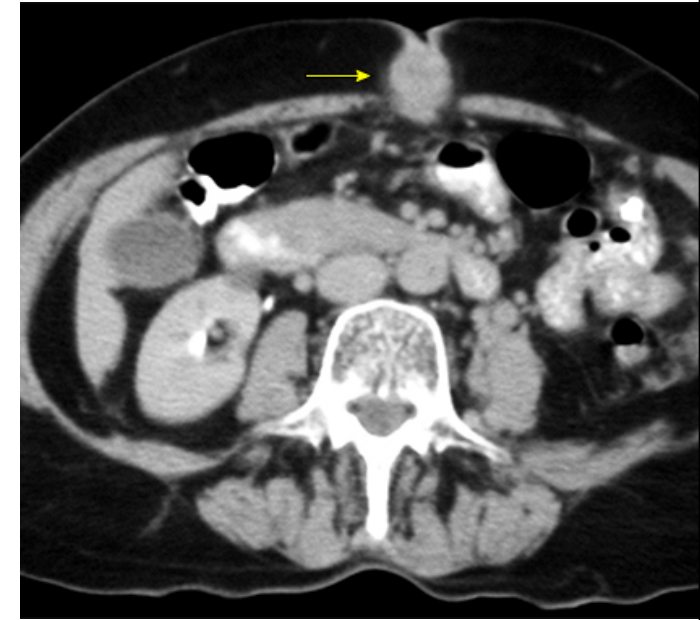
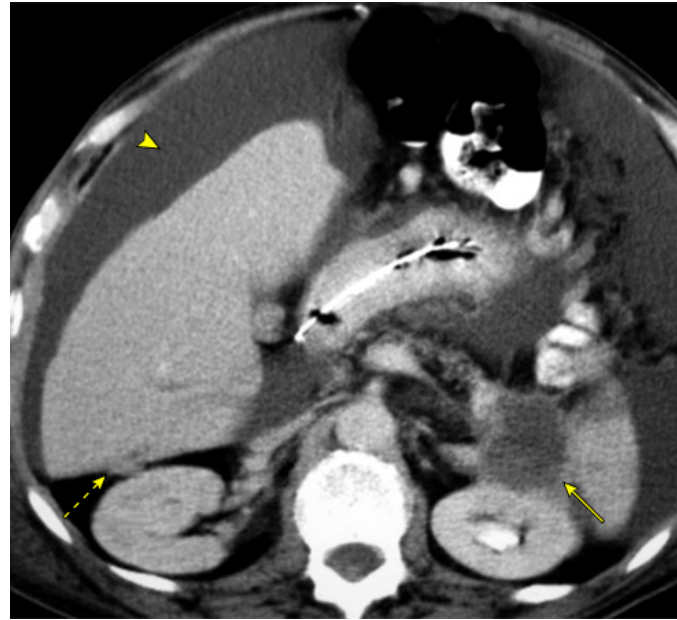




Metastatic disease most commonly affects the liver, peritoneum, lungs, and less frequently, bone.

Signs of advanced, incurable disease:

- An abdominal mass.
- Liver metastases.
- Ascites.
- Left supraclavicular lymphadenopathy (Virchow's node).
- A palpable periumbilical mass (Sister Mary Joseph's node)



# Differential Diagnosis

The signs and symptoms associated with pancreatic cancer are often nonspecific, so the differential diagnosis is large.

Three of the more common findings leading to suspicion for pancreatic cancer are jaundice, epigastric pain, and weight loss.

The positive predictive value of these symptoms for the diagnosis of pancreatic cancer is low, with the possible exception of jaundice in an older patient.

# Conjugated Hyperbilirubinemia

Intrahepatic cholestasis	Extrahepatic cholestasis (biliary obstruction)
Viral hepatitis/ Chronic hepatitis/ End-stage liver disease	Choledocholithiasis
Alcohol-associated hepatitis/ Non-alcohol-associated steatohepatitis	Intrinsic and extrinsic tumors (eg, cholangiocarcinoma, pancreatic cancer)
Primary biliary cholangitis/ Following organ transplantation	Primary sclerosing cholangitis
Drugs and toxins (eg, alkylated steroids, chlorpromazine, herbal medications [eg, Jamaican bush tea], arsenic)	AIDS cholangiopathy
Sepsis and hypoperfusion states/ Total parenteral nutrition	Acute and chronic pancreatitis
Infiltrative diseases (eg, amyloidosis, lymphoma, sarcoidosis)	Strictures after invasive procedures
Pregnancy	Certain parasitic infections (eg, <i>Ascaris lumbricoides</i> , liver flukes)
Postoperative cholestasis	<b>Defect of sinusoidal reuptake of conjugated bilirubin..</b> Rotor syndrome
Hepatic crisis in sickle cell disease	<b>Defect of canalicular organic anion transport</b> Dublin- Johnson syndrome

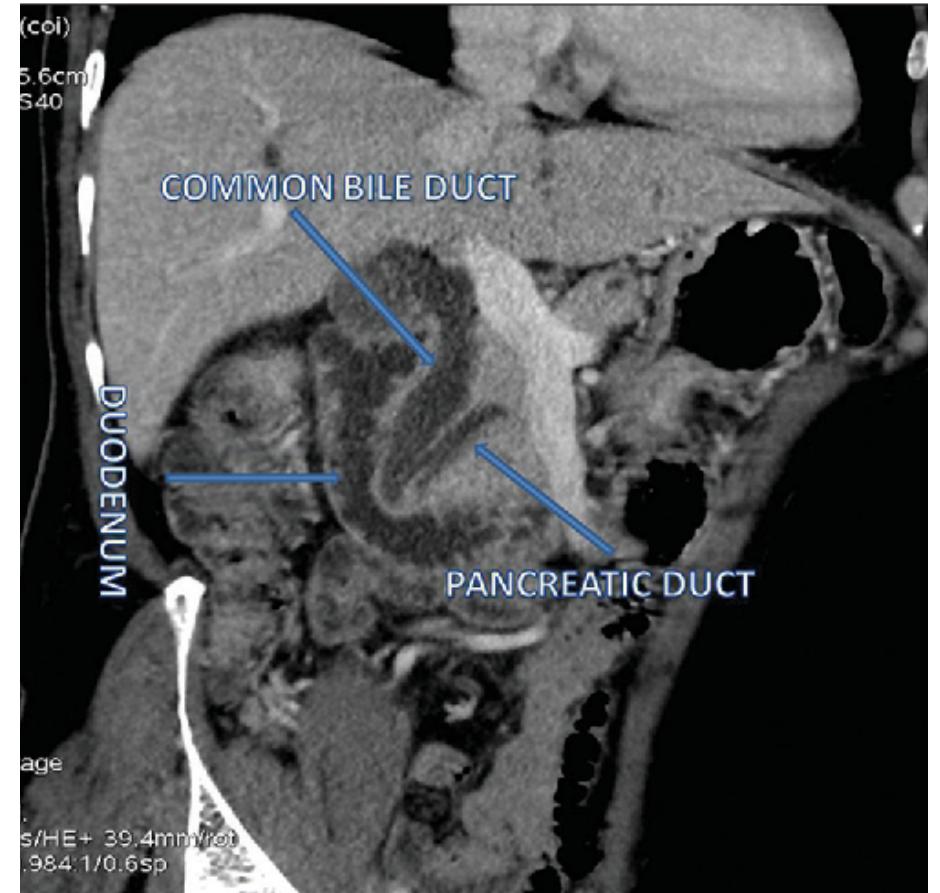
# Diagnostic Approach

## ❖ Initial testing

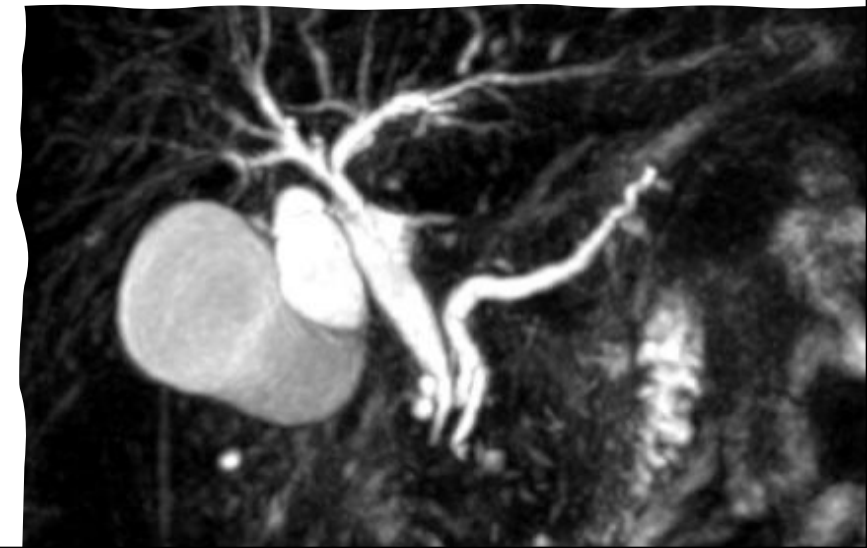
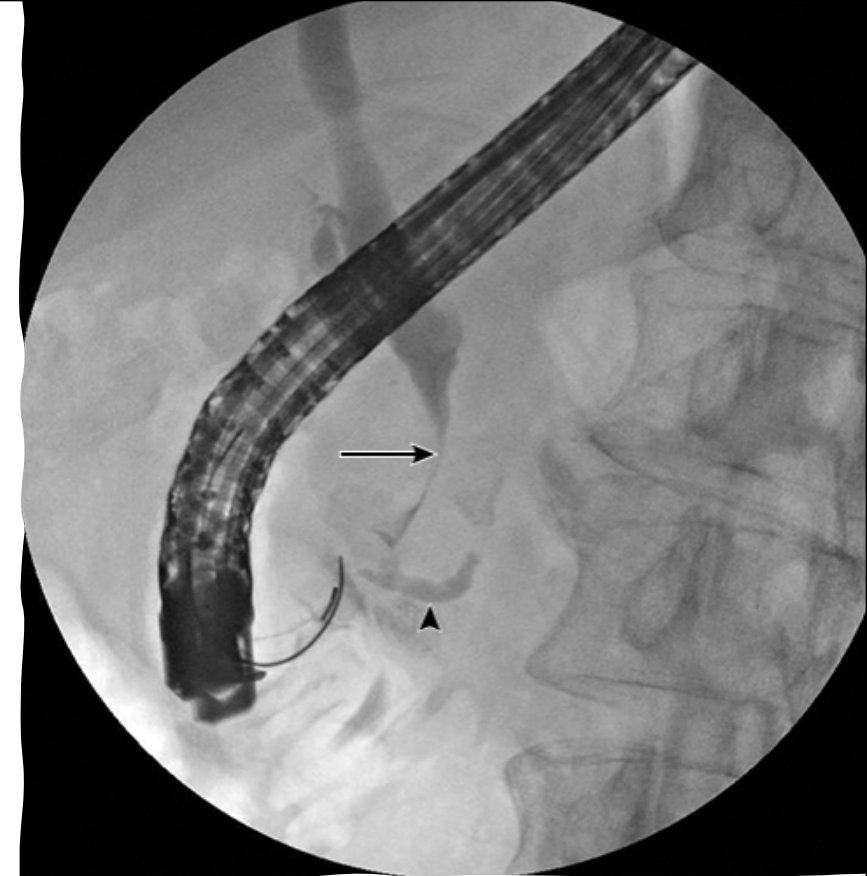
- Routine laboratory tests are often abnormal but are not specific for pancreatic cancer. Common abnormalities include an elevated serum bilirubin and alkaline phosphatase levels, and the presence of mild anemia.
- Abdominal imaging (Transabdominal ultrasound/ Abdominal CT)

## ❖ Subsequent testing if initial imaging is positive

- a CT with "pancreatic protocol"
- Tumor markers (CA19.9)



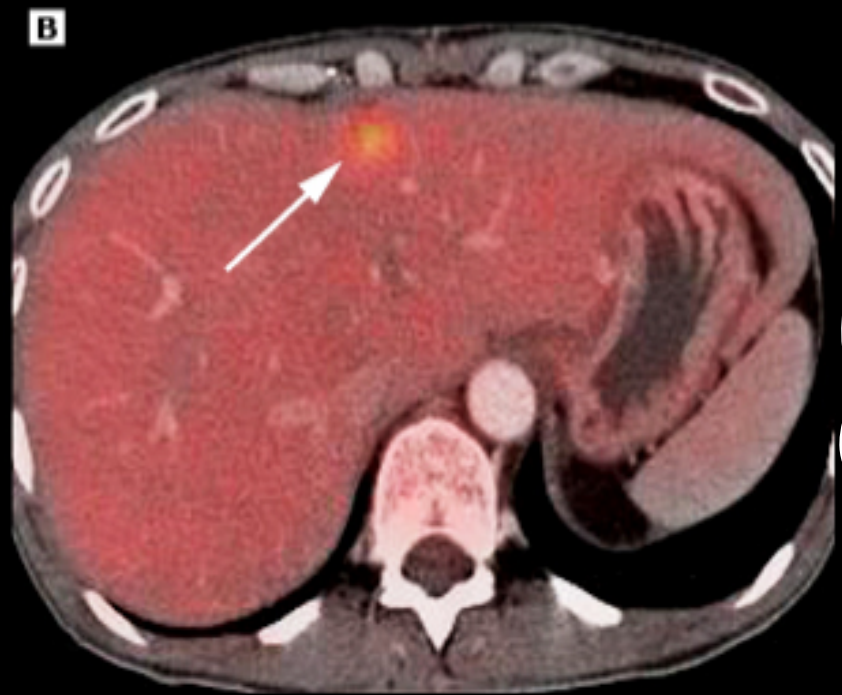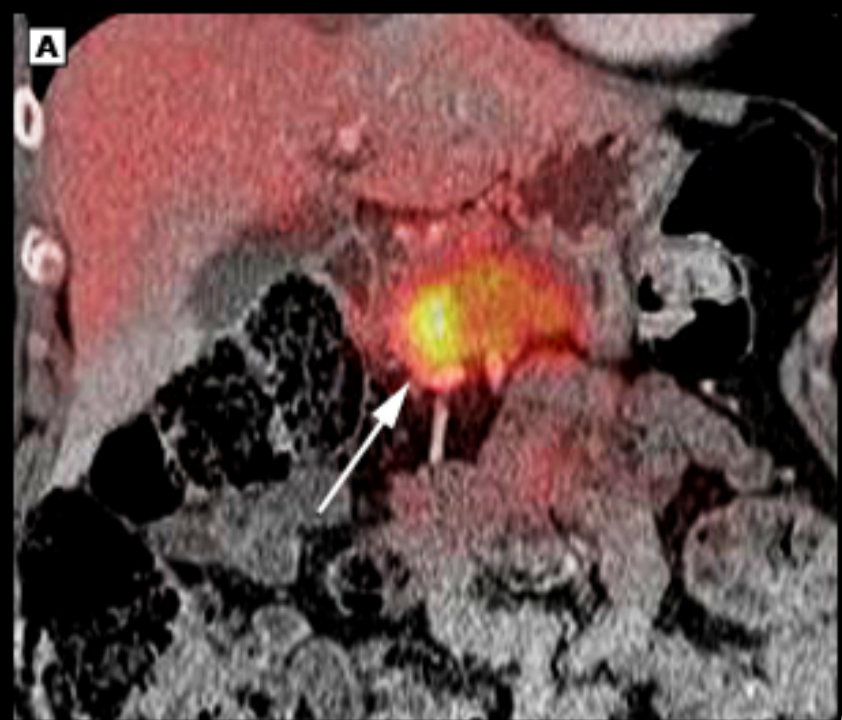- 
- **Endoscopic retrograde cholangiopancreatography**
  - ERCP provides an opportunity to collect tissue samples (forceps biopsy, brush cytology) for histologic diagnosis.
  - **Magnetic resonance cholangiopancreatography**
  - Dilation of both the pancreatic duct and the common bile duct, commonly referred to as the "**double duct sign**"



# Endoscopic Ultrasound

- An endoscopic ultrasound (EUS)-guided biopsy may be recommended if a diagnosis of chronic or autoimmune pancreatitis is suspected
  - ✓ Based on history (eg, extreme young age, history of alcohol use disorder, history of other autoimmune diseases)
  - ✓ Or based on other imaging (eg, multifocal biliary strictures (suggestive of autoimmune pancreatitis) or diffuse pancreatic ductal changes (suggestive of chronic pancreatitis)).
- Endoscopic ultrasound (EUS)-guided or percutaneous biopsies, though this is not always required in patients who appear to have potentially resectable disease and who have typical imaging findings.



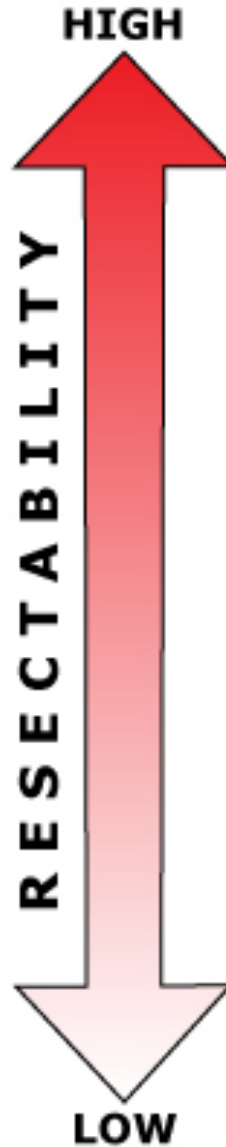


# Assessing Resectability

---

- Complete surgical resection is the only potentially curative modality of treatment for pancreatic cancer.
- In general, pancreatic cancers are categorized on a continuum from resectable to unresectable according to the involvement of adjacent structures and the presence of distant metastases
- Unfortunately, only 15 to 20 percent of patients are candidates for pancreatectomy

# Continuum of resectability for pancreatic adenocarcinoma

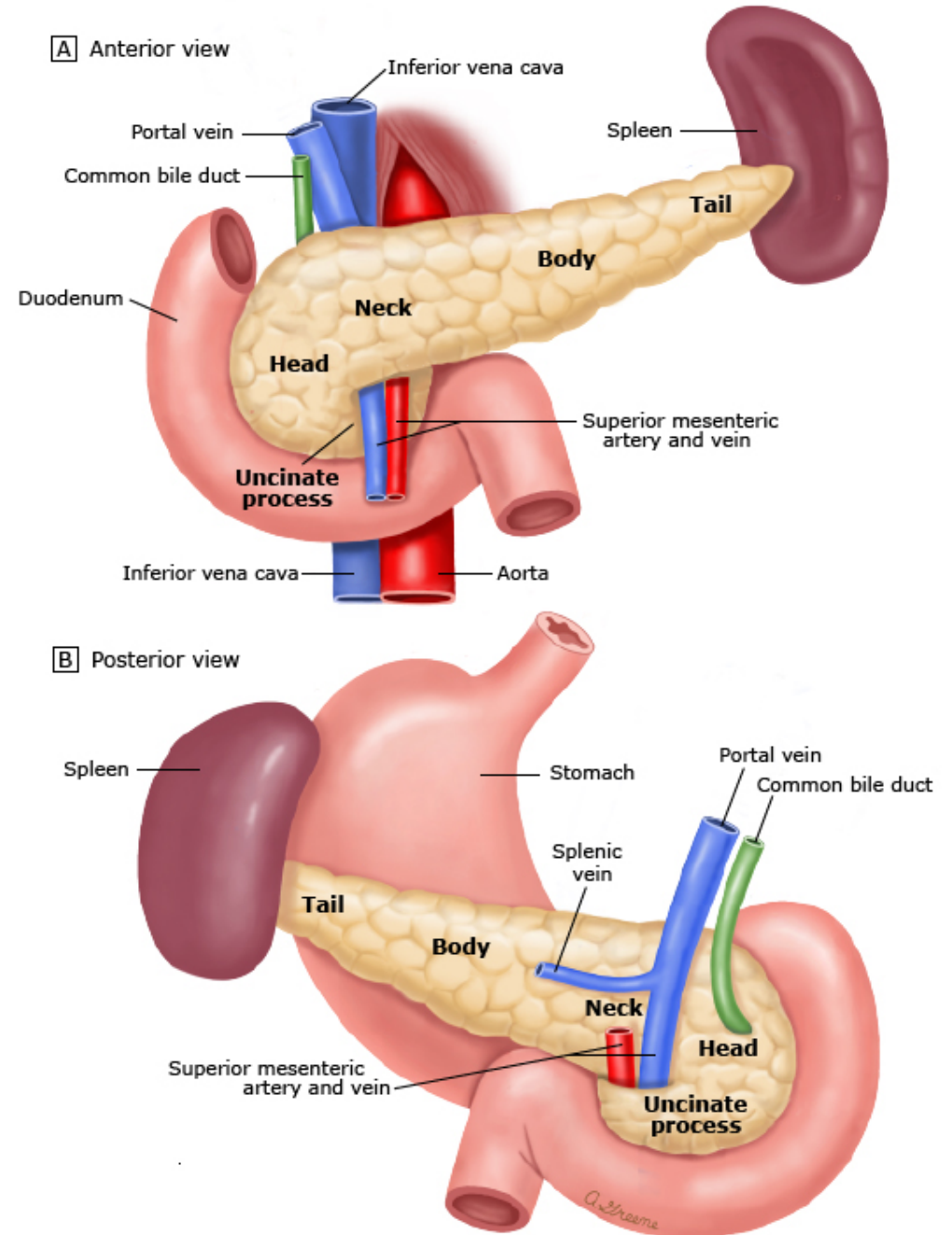


- No distant metastases
- No arterial or venous involvement
- Attachment to other organs (eg, spleen)
- Venous involvement (SMV or portal) less than 180 degrees, as long as there is suitable vessel proximal and distal to the areas of involvement for reconstruction
- Gastroduodenal artery encasement up to the common hepatic artery with other short segment encasement or abutment of the hepatic artery, but without extension to celiac trunk
- Tumor abutment of the SMA less than one-half the circumference of the vessel wall.
- Greater than 180 degree encasement or occlusion/thrombus of SMA, unreconstructable SMV or SMV-portal vein confluence occlusion
- Direct involvement of the inferior vena cava, aorta, celiac trunk or hepatic artery, as defined by absence of a fat plane between low density tumor and these structures on CT or EUS.
- Metastases to lymph nodes beyond the peripancreatic tissues
- Distant metastases

# Preoperative Considerations

---

- Staging Laparoscopy
- Role Of Preoperative Biliary Drainage
- Role Of Neoadjuvant Chemotherapy



# Surgical Management

- **Tumors in the head of the pancreas**

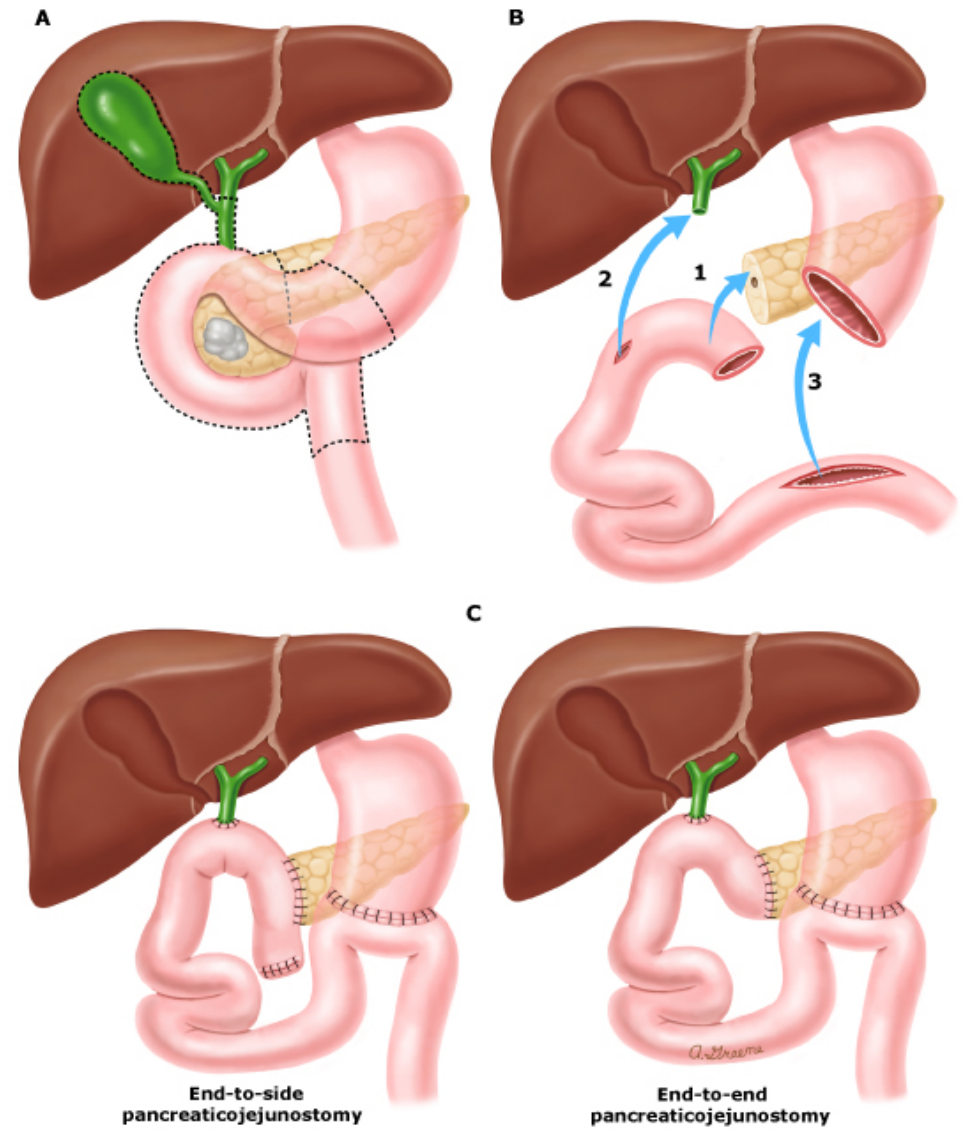
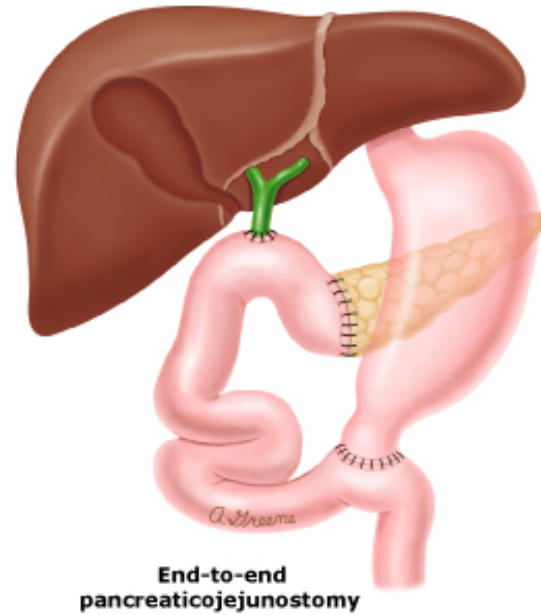
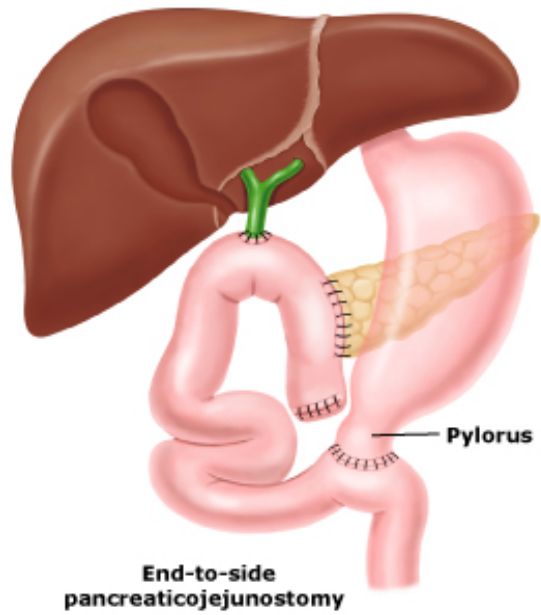
Pancreaticoduodenectomy (Whipple procedure)

- **Tumors in the body or tail**

Distal subtotal pancreatectomy, usually combined with splenectomy.

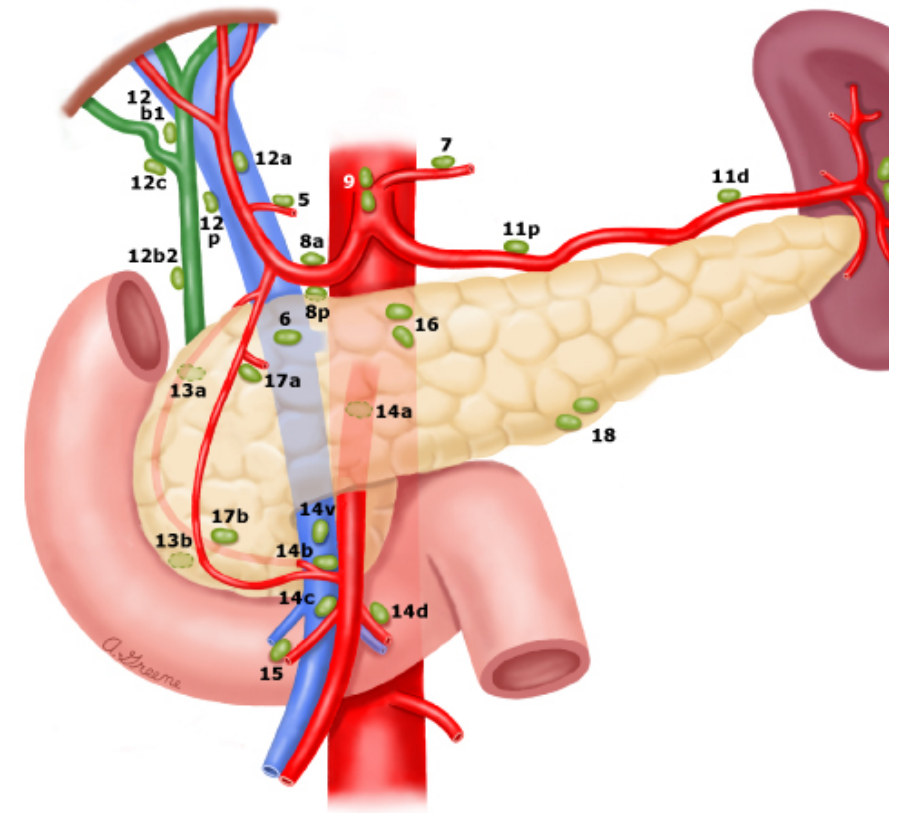
- **Tumors involving the entire gland**

Total pancreatectomy, however, the metabolic consequences of total pancreatectomy, include permanent exocrine insufficiency and brittle diabetes

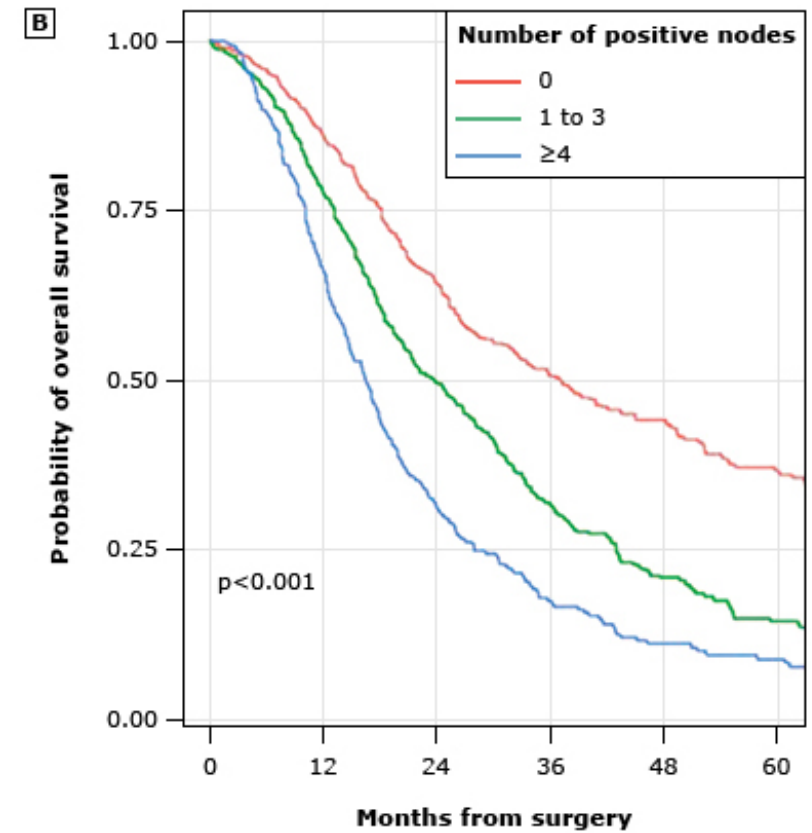
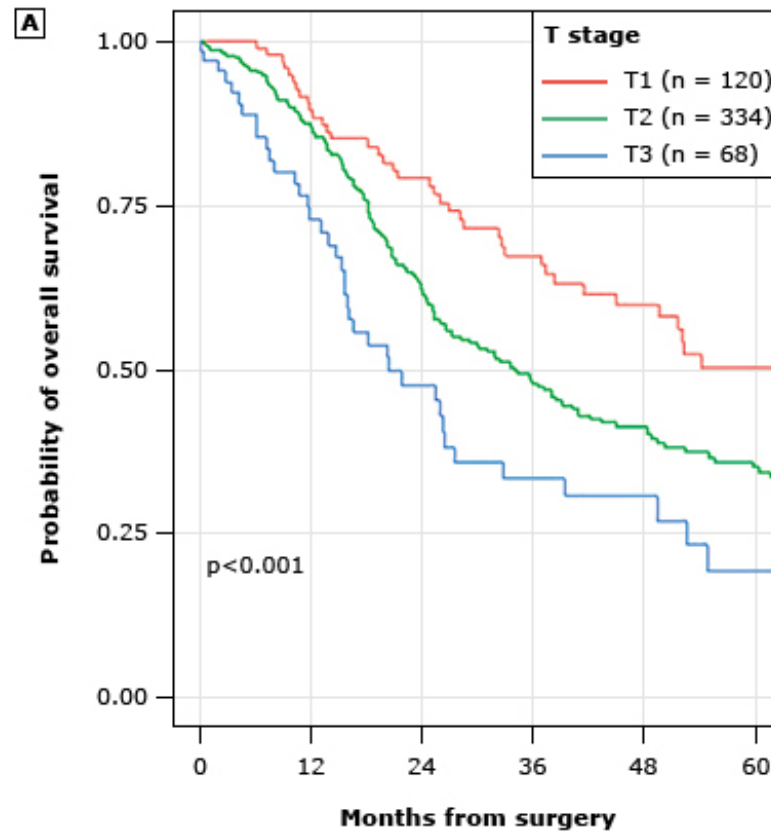


# Prognosis and Prognostic Factors

- The most important prognostic factor for completely resected patients is nodal status.
- Tumor stage is the most important prognostic factor (TNM) classification
- The status of the surgical margins (involved or uninvolved)
- Tumor differentiation
- The presence or absence of lymphatic invasion
- Both preoperative and postoperative serum CA 19-9 levels,
- Cigarette smoking



# Outcomes of pancreaticoduodenectomy



- Cancer of the exocrine pancreas is a highly lethal malignancy.
- Surgical resection is the only potentially curative treatment.
- Unfortunately, only 15 to 20% of patients are candidates for pancreatectomy.
- Furthermore, prognosis is poor, even after a complete resection.
- The five-year overall survival for stage ia pancreatic cancer nearly doubled from 45% to 84%.
- These trends were attributed to improved early diagnosis and detection.

