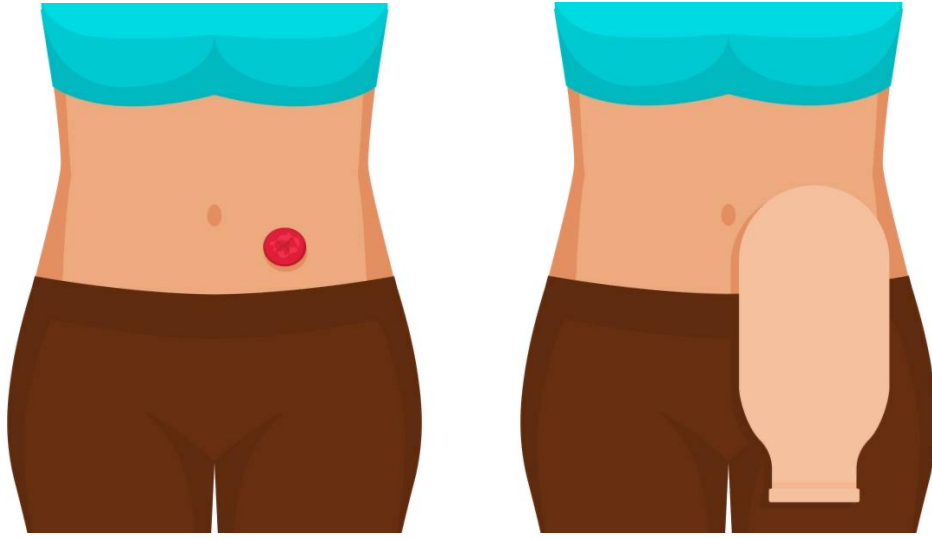


Surgical terms + Stomas



By: Rahaf Melhem

Edited by 8 Dana Almanzalji ❤️

اذكرونا بدعوة طيبة ...
وإذا في أي خطأ خبروني حتى أعدل.

- To make an open in the body \Rightarrow **-otomy**

↳ ex: opening in the vein \rightarrow Phlebotomy

Cut through the pyloric muscle alone \rightarrow Pyloromyotomy (not all the pyloric wall)

Pulorotomy \rightarrow to open all through the pyloric wall (from serosa to the lumen)

myotomy \rightarrow to open the muscle alone.

- To remove anything in the body \Rightarrow **-ectomy**

- To fix things together by over suturing under tension \Rightarrow **-orrhaphy** (ex: herniorrhaphy)

↳ if we didn't add a mesh

- If we **add any foreign devices/materials** in any surgery \Rightarrow **-plasty**

ex: stent angioplasty, knee replacement arthroplasty, hernioplasty

↳ if we add a mesh

- Any **change in the configuration** or the shape of the tissue \Rightarrow **-Plasty**

ex: pyloroplasty, abdominoplasty, U-Y plasty, Y-V Plasty
Z-plasty, Z plasty (on contracted scars)

- To fold something (size of \approx \approx) without removal of anything (tissues or part of the organ itself) \Rightarrow **-plication**

↳ ex: fundoplication, diaphragmplication (in diaphragm eventration)
Plication of recti (in divarication of recti)

- Anything that moves pathologically, and its movement will harm the organ itself, need to be fixed \Rightarrow **-pexy**.

↳ ex: orchidopexy in 3 cases: ① undescended testies ② testicular torsion.
③ retractile testicle (in most cases need only conservative Tx and no need for surgery until it is symptomatic "cause pain", not getting larger, not descending down after puberty).

↳ ex: rectopexy, gastropexy (in gastric volvulus),
spleenopexy (in splenic infarction due to splenic torsion).

- To aspirate \Rightarrow ?

- If we insert a scope in any cavity in the body \Rightarrow Cavitoscopy

\hookrightarrow ex: laparoscopy, ductoscopy (in the ducts of submandibular gland), bronchoscopy, EGD (upper endoscopy), Colonoscopy, Cysto-urethroscopy, urethroscopy, hysteroscopy, otoscopy, fundoscopy, laryngoscopy, thoracoscopy (inside the pleural cavity, through the chest wall), mediastinoscopy, arthroscopy, retroperitoneoscopy, interoscopy.

\hookrightarrow x-ray for ex.

- filming a cavity in the body after injecting it with a contrast \Rightarrow - ography (cavitography)

\hookrightarrow ex: esophagography (contrast/barium swallow), colonography (contrast enema "trans anal"),
 \hookrightarrow retrograde contrast

angiography, hysterosalpingography, ERCP (endoscopic retrograde cholangiopancreatography),

PTC (percutaneous transhepatic cholangiography),

MRCP (magnetic resonance cholangiopancreatography),

IOC (Intraoperative cholangiography),

Intravenous urography, MCUG (micturating

Cystourethrography) \rightarrow we inject a contrast in the bladder through the urethra to see if the contrast goes to the ureters or not, and after that we ask the pt to micturate to see the contrast comes out transurethral \rightarrow why we do it? \rightarrow to see if there is a reflux between the bladder and the ureters (vesicouretral reflux), to see the anatomy of the urinary bladder and the urethra

* Stoma : any opening in the body

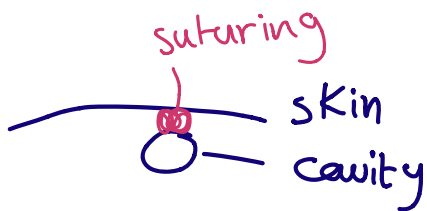
* ostomy : surgically opened stoma

* Fistula : Pathologic opening stoma in the body

cavity + skin → cavitocutanoostomy = cavitostomy
cavity + cavity → cavito cavitoostomy

ex: duodojejinoostomy, gastrojejunoostomy
vesicocolostomy, choledchojejunoostomy
tracheostomy, esophagostomy,
thoracostomy tube (chest tube),
hepaticoduodenostomy

bypass procedure by doing anastomosis
between the proximal duodenum
and the distal duodenum ⇒
duodenoduodenostomy

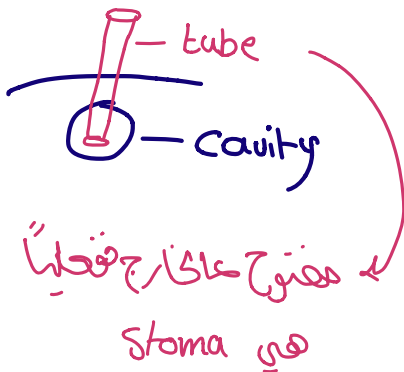


⇒ ostomy



لستيرها لاريم عايه

Temporary




⇒ ostomy tube

⇒ Tubest لستيرها بيني ال

↳ No direct anastomosis between
Skin & cavity (ex.: Tracheal)

* Tracheostomy tube

: لان مؤقت



indication : Pt with intubation for 2 weeks

Prolonged intubation

* Thoracostomy tube \equiv Chest tube

* Gastrostomy tube \rightarrow for feeding

* Choledo duodostomy (Common Bile + duodenom)

* Duodeno jejunostomy

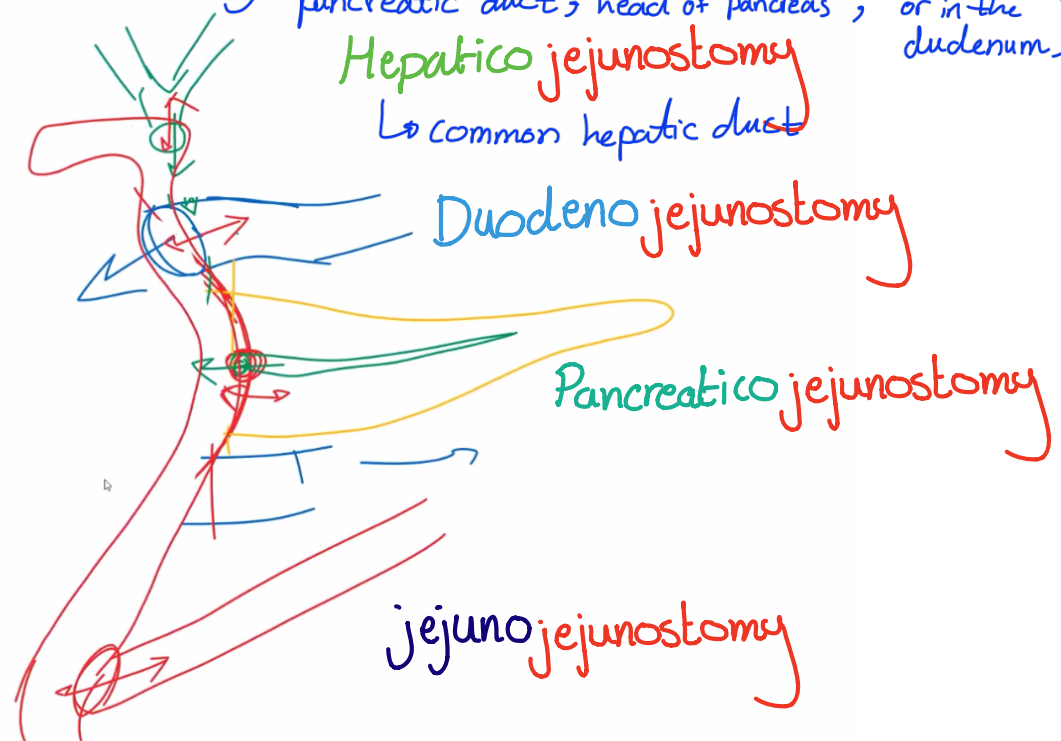
* jejunostomy tube \checkmark \rightarrow for feeding

jejunostomy X \rightarrow skin \rightarrow skin


* Gastrojejunostomy \rightarrow bariatric surgery

* Whipples procedure :

\rightarrow in cases of periampullary tumors (distal biliary duct, distal pancreatic duct, head of pancreas, or in the duodenum)



* Ureterostomy



* Vesicostomy (Urinary Bladder)

* **Cholecystomy tube** :

⇒ to drain the bile in Gall bladder

Pt can't go for cholecystectomy so I put this tube for him to drain the GB, if the pt is unstable, critically ill (not fit for surgery under GA),

~~hemodynamically unstable~~ ⇒ we need to relieve his symptoms by ↓ the pressure in the gallbladder by inserting a percutaneous tube to the gallbladder which is **cholecystomy tube**.

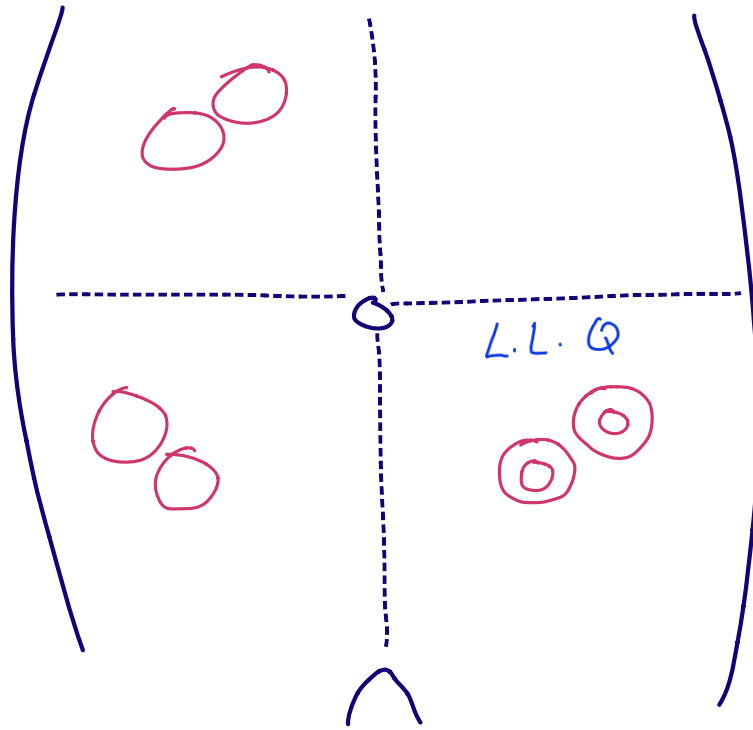
* Renal pelvis = pyelo ⇒ pyelostomy tube من الكلى إلى خارج الجسم

* Cutaneous appendico-vesicostomy or appendicovesicostomy (Mitrofanoff procedure) ⇒ a procedure to create a new tube on a child's belly (through the umbilicus) to help him to urinate by using a catheter.

Stomas

Colostomy:
Transverse

Ileostomy



Colostomy:
Sigmoid
Descending

* in Peds → anywhere could be ileo / Colo stomy

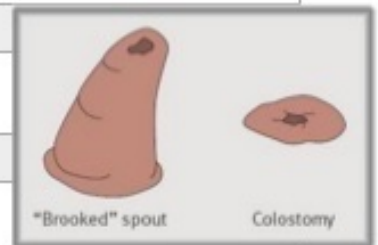
* Differences :

Colostomy vs ileostomy

+ operative note +

X-ray
with contrast

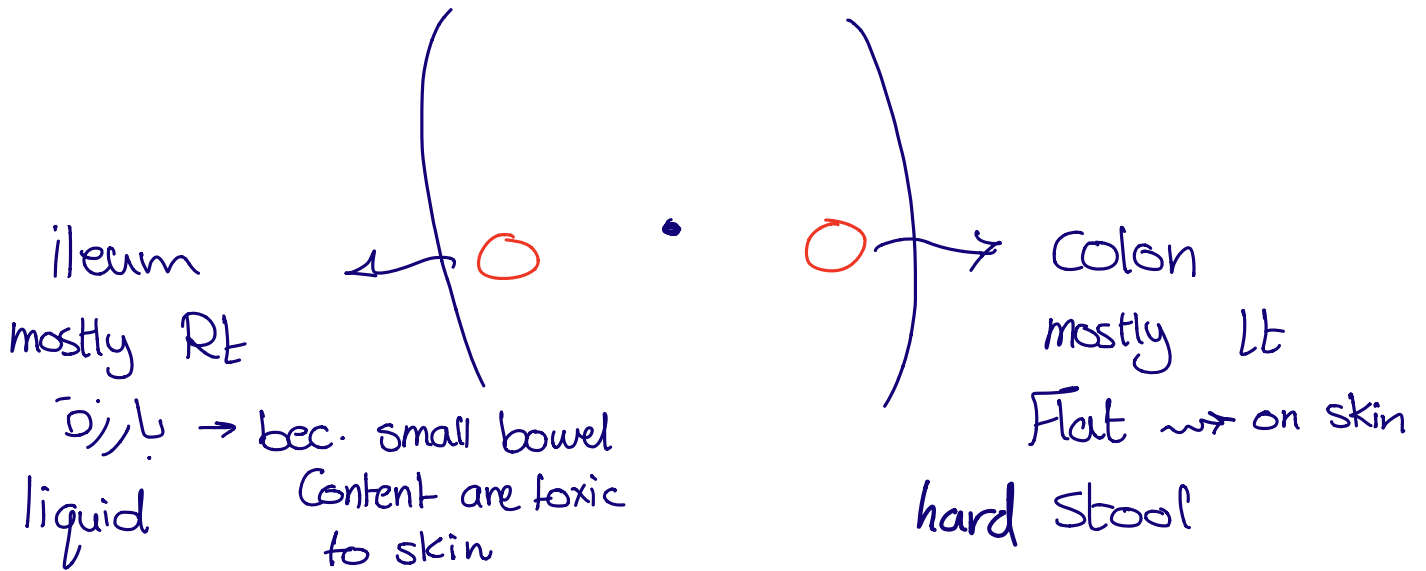
	Ileostomy	Colostomy
	Sprout + (elevated)	No sprout / flush
Site	Usually in RIF	Temporary colostomy - transvers or right upper quadrant End colostomy - usually in LIF
Effluent	Liquid contain some amount of enzymes (alkali and proteolytic enzymes) → excoriation of skin + (Autodigestion) <i>irritation of the skin</i>	Solid, hard stools compared to ileostomy
	Watery liquid stools	Hard stools
Oddor	Oddor +	Oddor is more
Frequency of discharge	Higher	Lower
	Circular folds on the ileum +	no
	More likely to develop fluid and electrolyte problems (irritation of skin)	



Stomas \rightsquigarrow any hollow organ : colon
 Small Bowel
 Urinary Bladder


RT

Lt

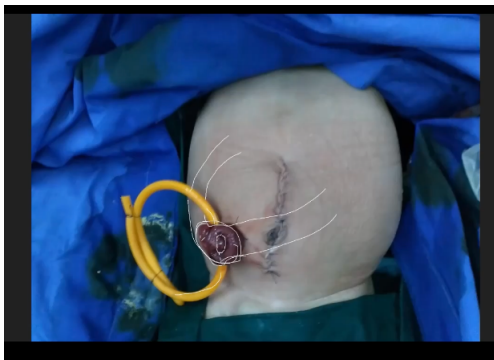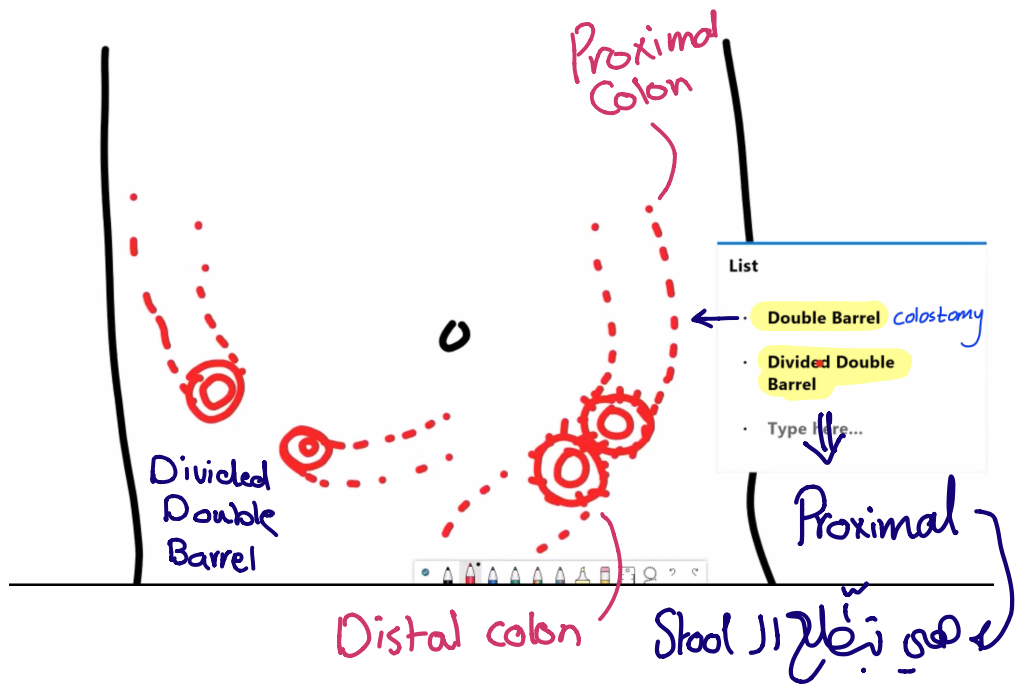


End \rightarrow nothing after it

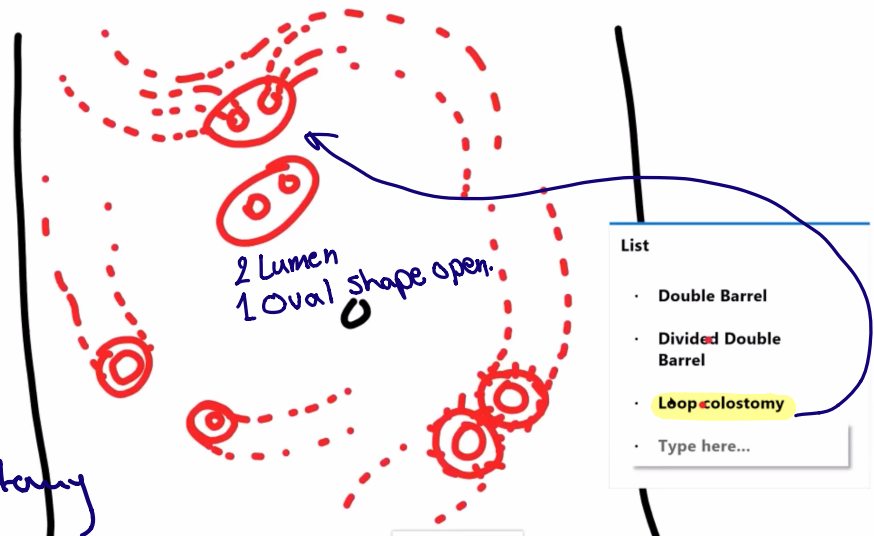
Double \rightarrow small bowel + colon
 colon + colon
 small b + small b



Types :



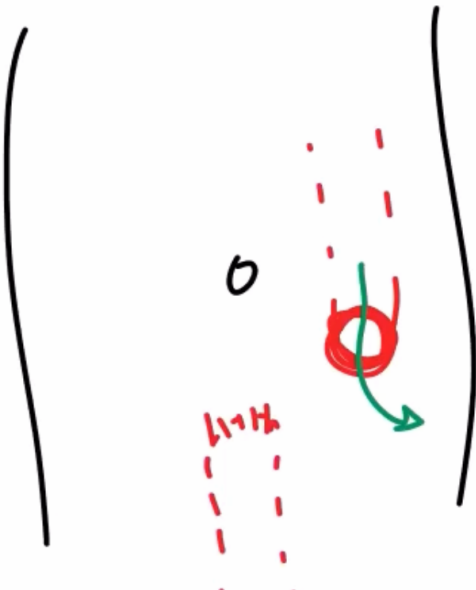Tube between the skin & Colon ⇒ ~~X~~ Loop colostomy



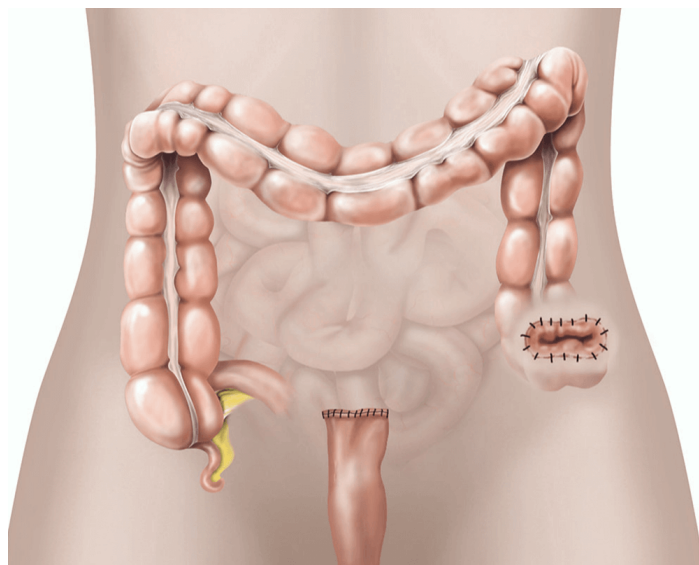
End Colostomy

- * The proximal part → stoma
- * The Distal → keep inside with Stitches → Temporary
- + Rectum → Permanent Removal

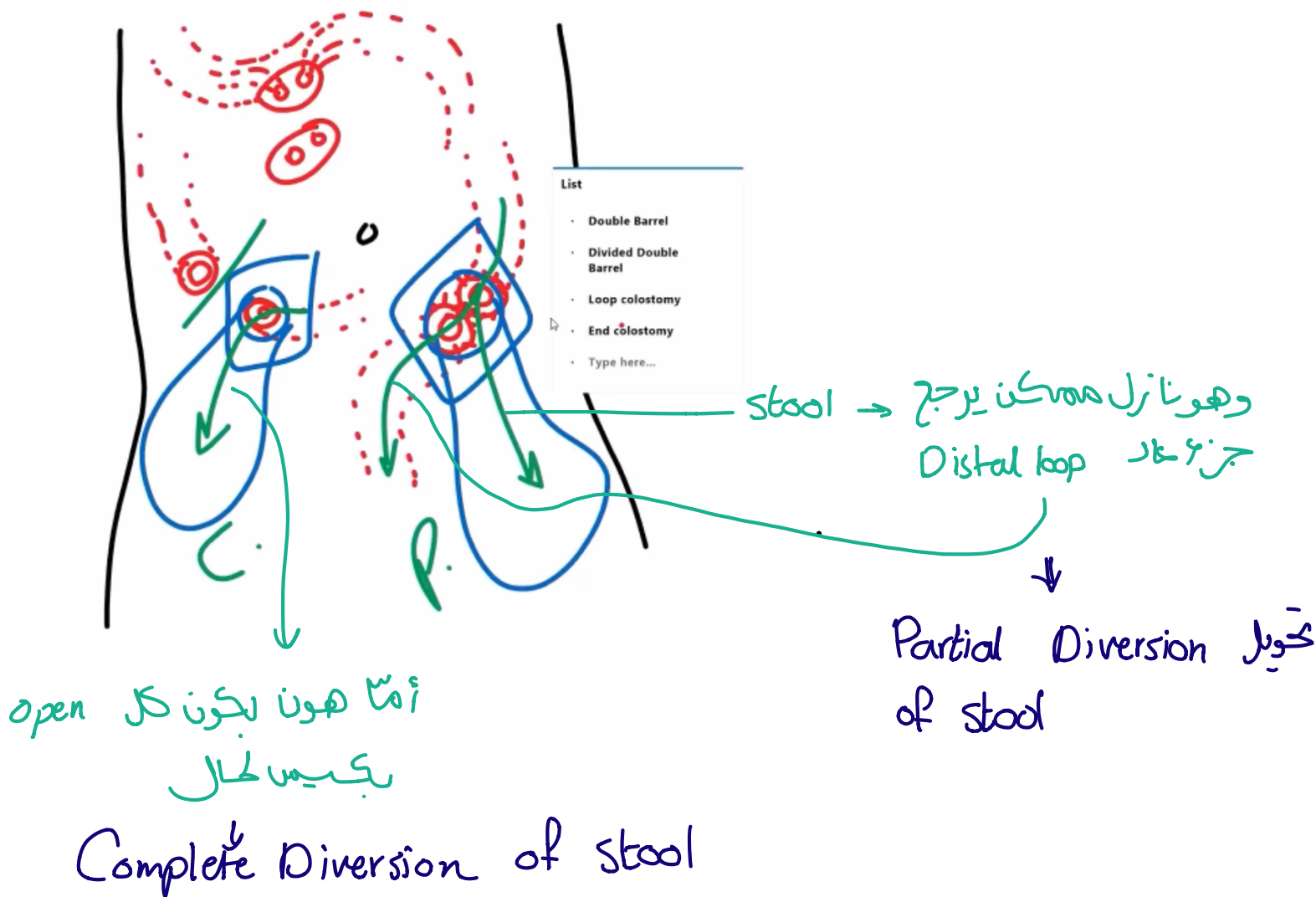
* Hartmann's procedure :



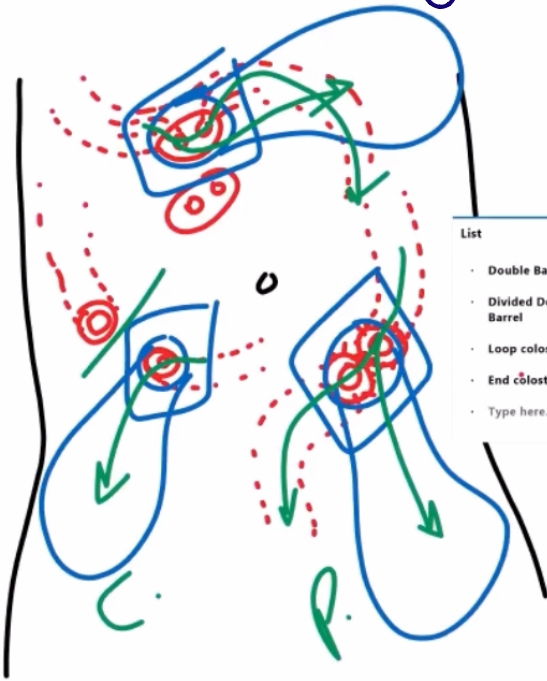A **proctosigmoidectomy**, **Hartmann's operation** or **Hartmann's procedure** is the **surgical resection** of the **rectosigmoid colon** with **closure of the anorectal stump** and formation of an **end colostomy**. It was used to treat **colon cancer** or **inflammation** (**proctosigmoiditis**, **proctitis**, **diverticulitis**, etc.).



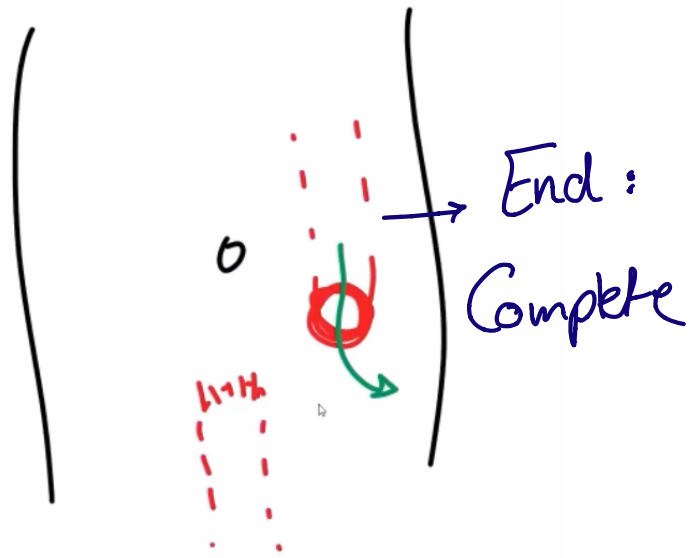
تفریق بین Divided Double Barrel & Double Barrel



Loop colostomy → Partial Diversion



- List
- Double Barrel
 - Divided Double Barrel
 - Loop colostomy
 - End colostomy
 - Type here...

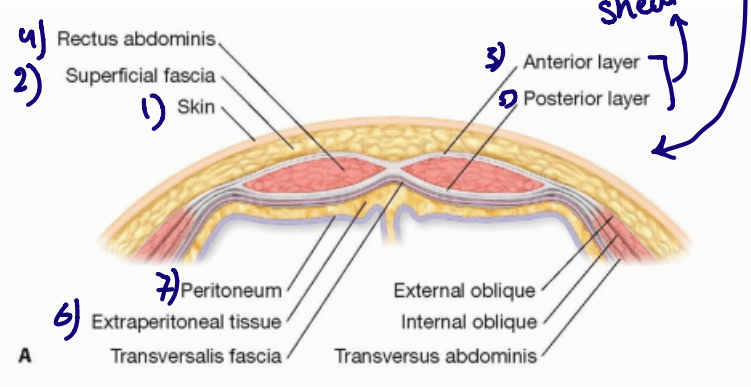
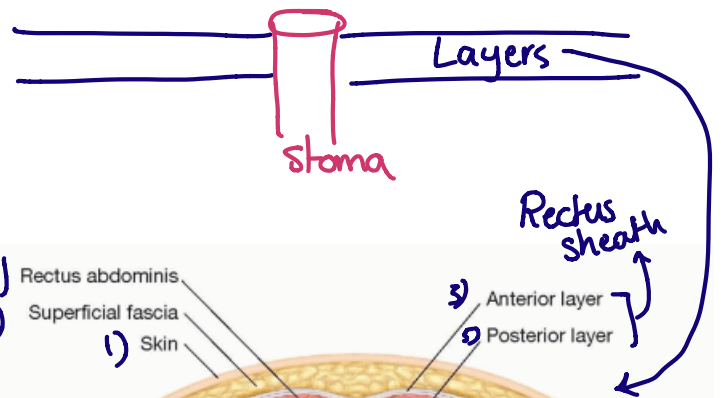


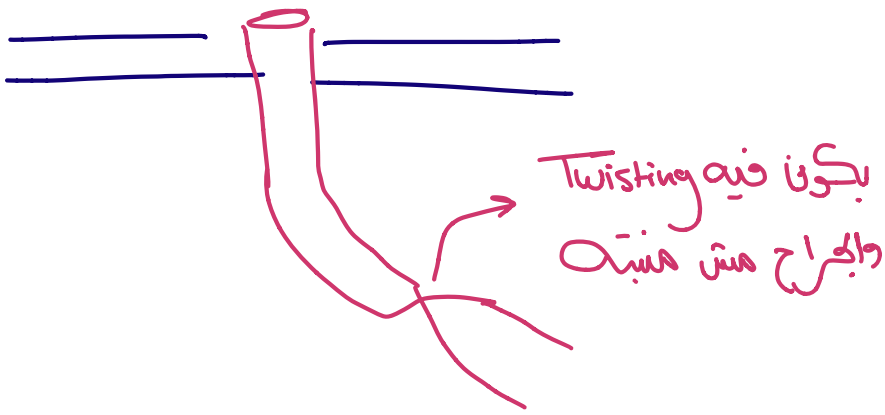
Complications :

Infection } General
Bleeding }

① Obstruction
due to : * tight fascia
or * Twisting

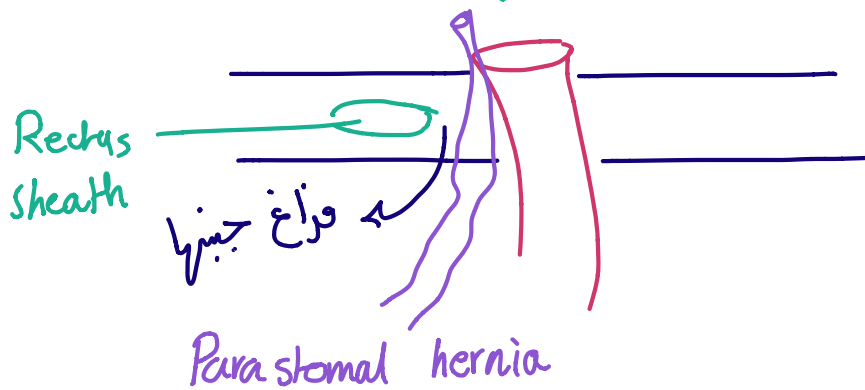
The toughest layer :
Rectus sheath would
tight & obstruct the
lumen of stoma





② Dermatitis (irritation of skin)

③ Parastomal hernia → hernia of adjacent loop



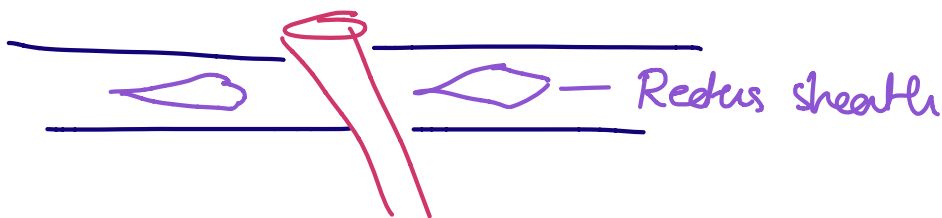
④ Dehydration

⑤ Electrolyte Embalance

} exit of many fluids + elect.
through the stoma

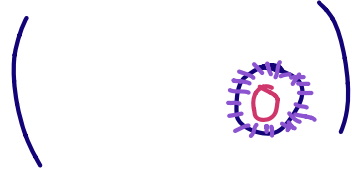⑥ Colostomy ischemia

→ Deep
→ Superficial



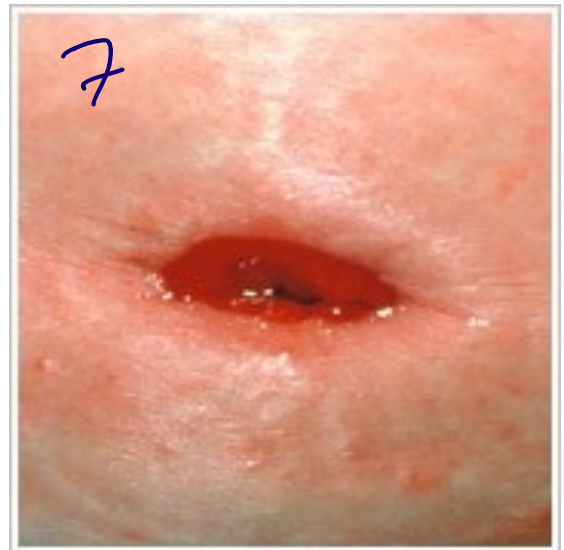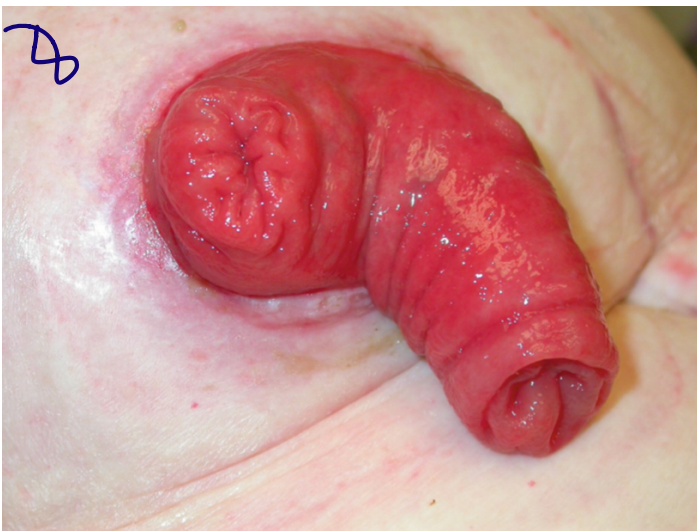
* The loop is out & around it is its own mesentery with its blood supply → Tight Rectus fascia would lead to ischemia ⇒ Deep

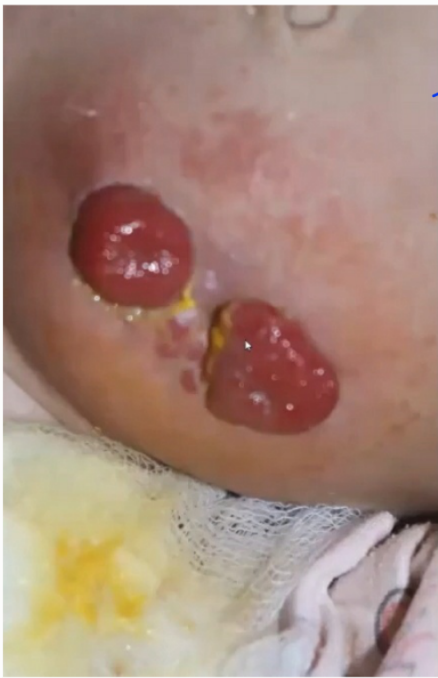* When a surgeon is موسوس & جتن the stoma with stitches it would cause ischemia to skin \Rightarrow Superficial



- ⑦ Retraction \rightarrow
- ⑧ Prolapse \rightarrow

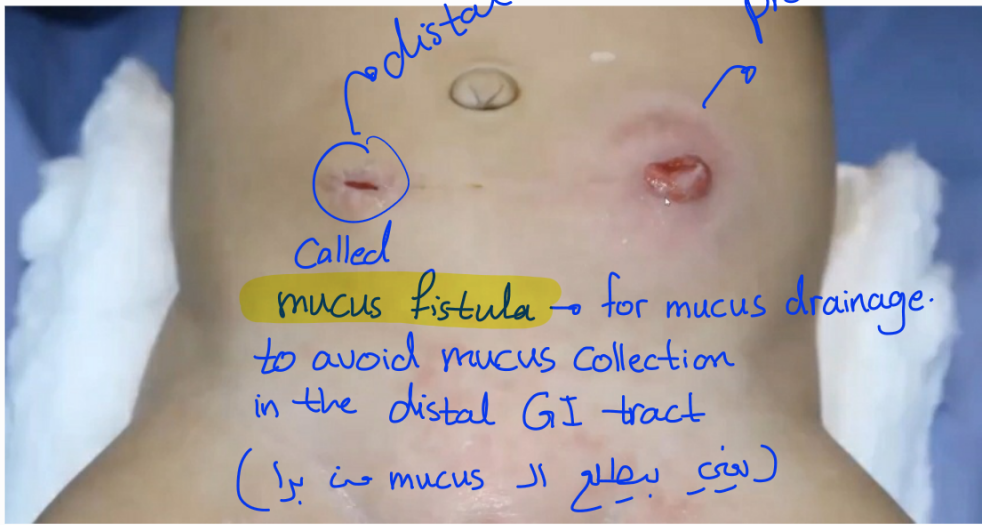
ostomy \leftarrow تدخل لبره
لها قالب لبره



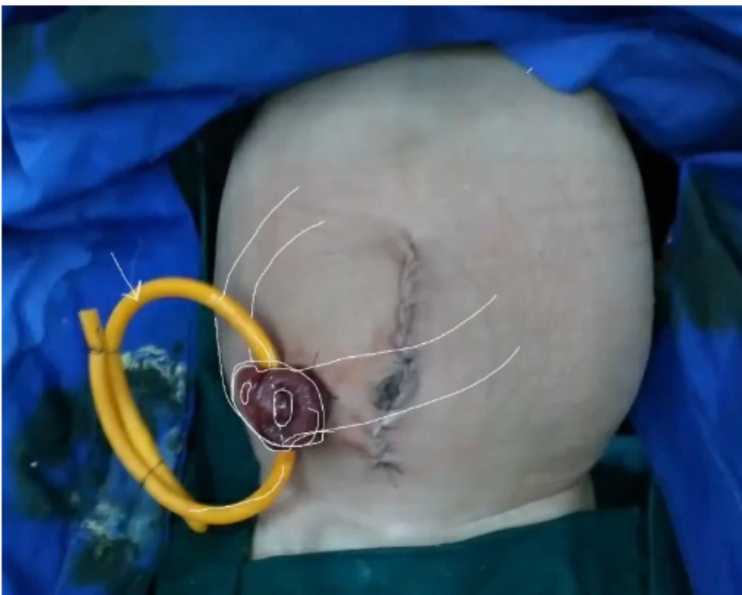

* Devided double barrel colostomy or iliostomy (pediatric)

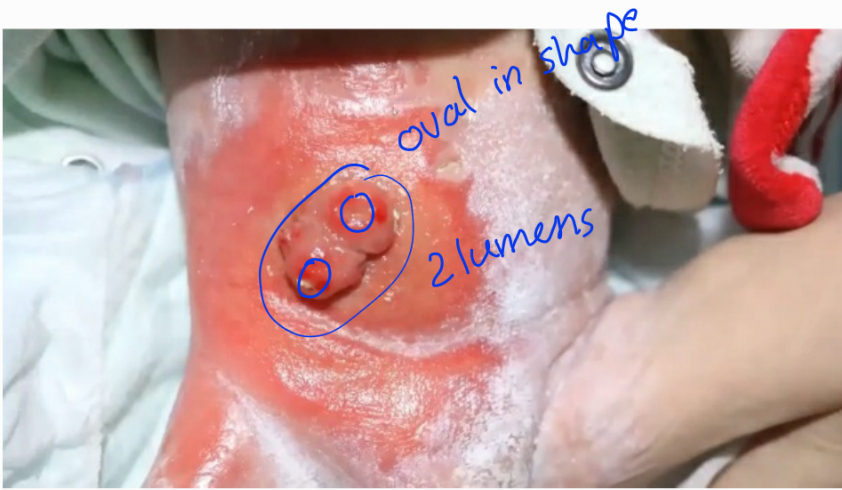* Complication : dermatitis present here.



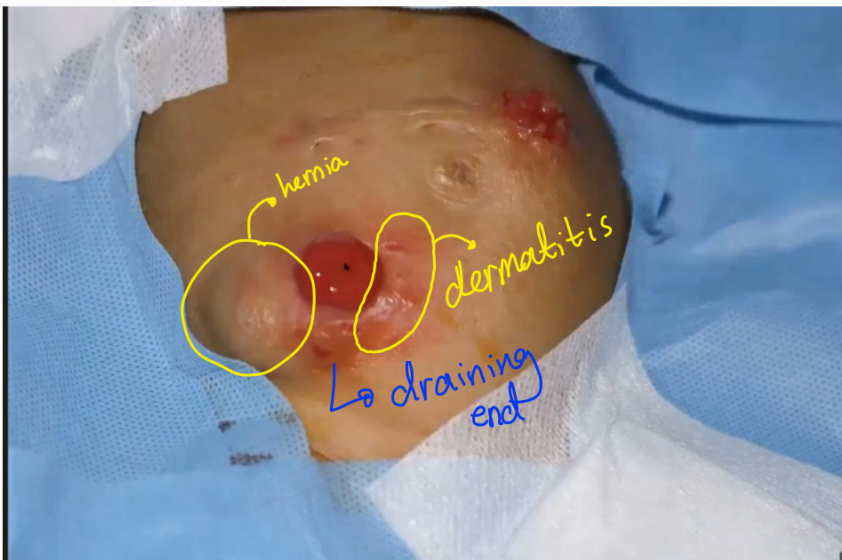* Devided double barrel (complete diversion of stool).



* Loop colostomy
 (partial diversion of stool).



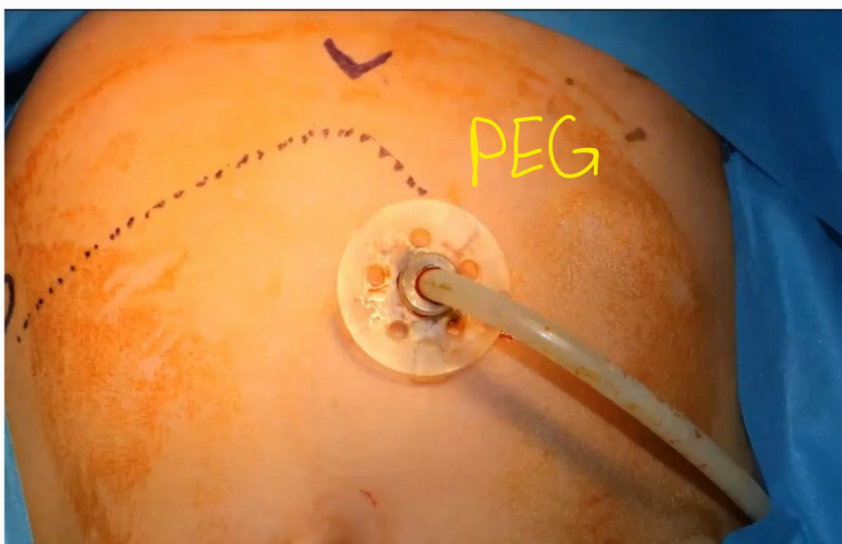- * Loop colostomy
- * Very severe dermatitis.



- * Complications present here & (diagnosis) &
 - parastomal hernia.
 - dermatitis

- * (findings) &
 - bulge / swelling adjacent to the colostomy opening.
 - red, erythematous and shiny ulcerating lesions around the colostomy opening.

* Devided boube barrel



- * Gastrostomy tube
 - ↳ indicated in & poor feeding (directly into the stomach)
 - ↳ percutaneous endoscopic gastrostomy tube insertion (PEG tube) or surgery gastrostomy tube.