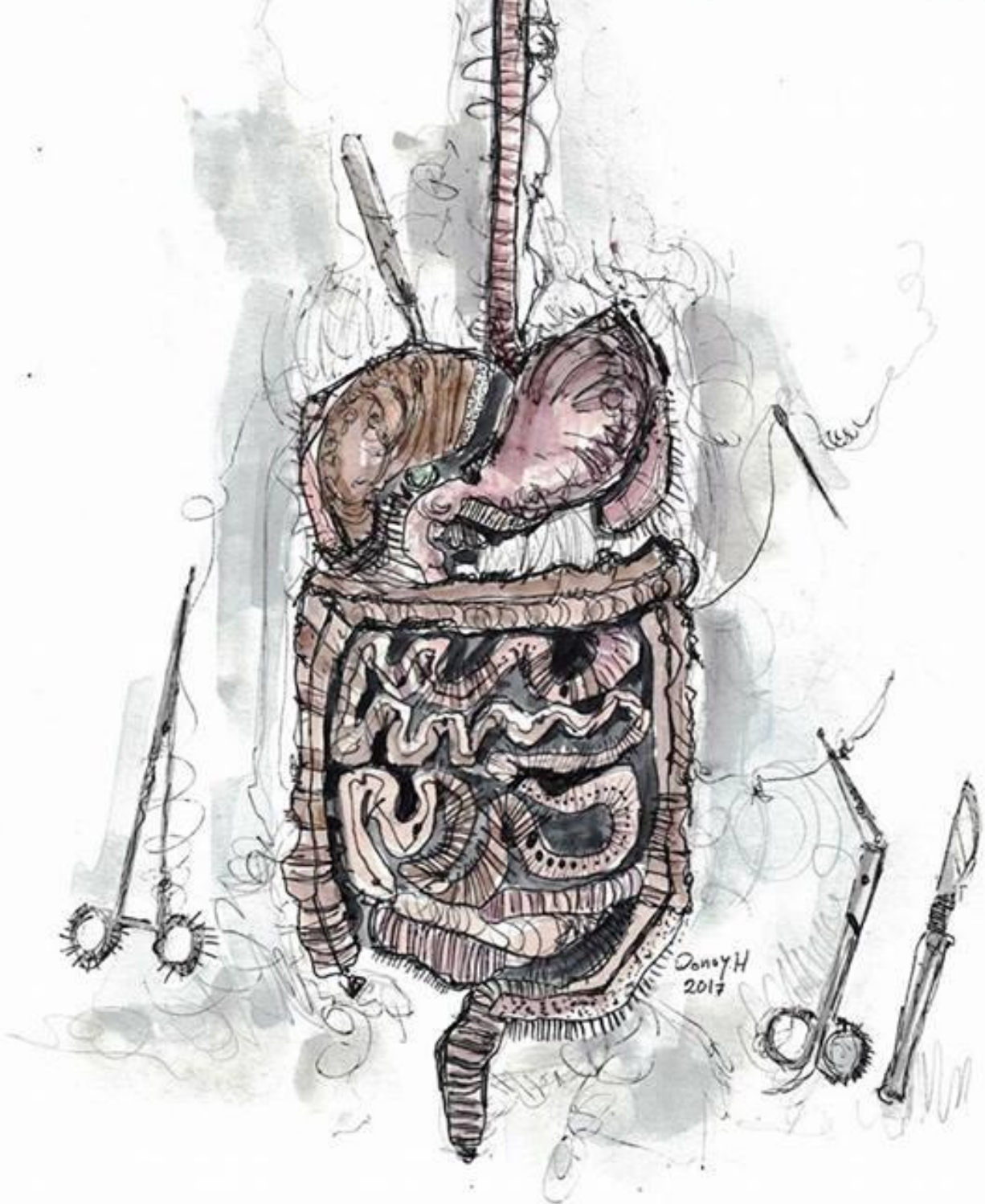


# GI Surgery



**Editors:**

Alma Jarkas

Mohammad Daas

Mohammad Karajeh

Mohammad Qussay Al-sabbagh

Nada Hajjaj

Russole Emad

Yousef Al-As3d

**Designed by:**

Mohammad qussay al-Sabbagh

Yousef Al-As3d

**Cover photo is done by:**

Donay Habbak

**What's new in this edition?**

- Some new figures and charts:  
*Helping you understanding diagnostic work ups in the ward!*
- Summary & past papers at the end of each chapter:  
*Prepare for the final exam in the most effective way!*
- Bookmarks and Hyperlinks in the Pdf version  
*yes, it's a real E-book!*

**Edited by:** Mohammad Qussay Al-sabbagh & Nada Hajjaj

## TABLE OF CONTENTS

<b><u>CHAPTER 1 (ESOPHAGUS &amp; STOMACH)</u></b> .....	3
<u>ESOPHAGUS</u> .....	4
<u>STOMACH</u> .....	29
<b><u>CHAPTER 2 (PANCREAS &amp; SPLEEN)</u></b> .....	59
<u>PANCREAS</u> .....	60
<u>SPLEEN</u> .....	97
<b><u>CHAPTER 3 (LIVER &amp; BILIARY TREE)</u></b> .....	111
<u>LIVER</u> .....	112
<u>BILIARY TREE</u> .....	146
<b><u>CHAPTER 4 (ACUTE ABDOMEN, APPENDIX &amp; SMALL INTESTINE)</u></b> .....	179
<u>ACUTE ABDOMEN</u> .....	180
<u>APPENDIX</u> .....	185
<u>SMALL INTESTINE</u> .....	191
<b><u>CHAPTER 5 (COLON, RECTUM &amp; ANUS)</u></b> .....	211
<u>COLON</u> .....	212
<u>RECTUM &amp; ANUS</u> .....	239



## Surgery-Gastrointestinal Dossier editing:

### Page 214

1. left colic artery → Supplies the distal 1/3 of the transverse colon and descending colon.

SMV drains the cecum and ascending colon . (Corrected)

### Page 221

Low risk table:

-Anal fissure does not cause bleeding, since it is an ischemic area.

Another paragraph:

-Rt sided colon cancer :occult blood is more common than hematochezia.

-Lt sided colon cancer predicted to have hematochezia .

-Hematochezia is the most common symptom of rectal cancer.

### Page 223

Additional important notes:

CEA: tumor marker, increased level of CEA indicates presence of colon CA (Not specific but it is an indication) , CEA Level should be decrease after surgery ( remove of CA).

### Page 224

( to clarify)

1st option to treat colon CA is surgery.

1st step to treat rectal lesions is RTX ( radiotherapy).



**Page 240**

Anus :

Anatomical anal canal length + dentate line above anal verge distance? The correct length it's about 1-1.5 cm not 3 cm as mentioned in dossier.

**Page 245**

Risk factors of hemorrhoids : portal hypertension has nothing to do with hemorrhoids ( correction )

# Esophagus & Stomach

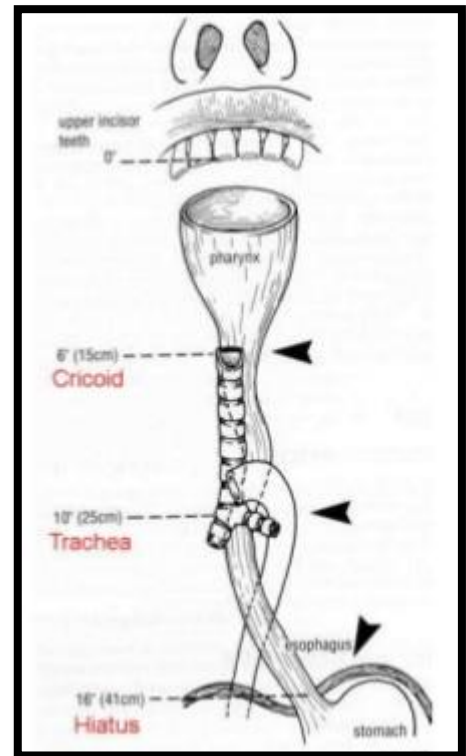
- Written by Mohammad Qussay Al-sabbagh
- Corrected by: Mohammad karajeh & Nada Hajjaj

- Esophagus : 4
  - Introduction: 4
  - Diseases of the esophagus : 7
  - GERD : 20
  - Summary and past papers: 25
- Stomach: 29
  - Introduction : 29
  - PUD : 32
  - Gastric CA: 39
  - GIST: 44
  - GI lymphoma: 45
  - Bariatric surgery: 48
  - Gastric syndromes: 53
  - Summary and past papers: 55

# Esophagus

✦ **Anatomy:** The esophagus is a 25 cm- long muscular tube (40 cm from the mouth) that begins at the pharynx (lower border of C6) and ends at the opening of the stomach (cardia) The muscle type varies along the esophagus:

1. Upper 1/3 → skeletal muscle.
  2. Middle 1/3 → mixed (skeletal + smooth)
  3. Lower 1/3 → smooth muscle.
- There are 3 areas of Narrowing:
1. At the beginning of the esophagus (caused by the cricopharyngeus muscle). (C6)
  2. Where the left main bronchus and aorta cross. (T4)
  3. At the hiatus of diaphragm.
- It has 2 sphincters:
1. Upper esophageal sphincter (UES): anatomical sphincter, caused by actual thickening of the muscular wall, its main function is swallowing.
  2. Lower esophageal sphincter (LES): functional sphincter, so it's an area of high pressure, its main function is prevention of reflux.
- Blood supply:
1. Upper 1/3 → inferior thyroid + anterior intercostal arteries.
  2. Middle 1/3 → esophageal arteries + bronchial arteries.
  3. Lower 1/3 → left gastric + left inferior phrenic arteries.



**#Note\_1:** the vagus nerve runs with the esophagus

**#Note\_2:** the esophagus is at risk of perforation due to absence of serosa.

**#Note\_3:** All GIT has serosa except esophagus and rectum.

⚡ **Histology:** lining epithelium of the esophagus is stratified squamous epithelium.

⚡ **Physiology:** esophagus is a connection canal through which the food pass, it transfers food by peristalsis.

➤ Types of peristalsis:

1. **Primary:** esophageal peristalsis accompanying swallowing.
2. **Secondary:** initiated by the esophageal musculature without the pharyngeal phase to clean the esophagus of any substance left behind Primary peristalsis.

➤ Phases of swallowing:

1. **Oral phase** :1 sec. / voluntary
2. **Pharyngeal phase:** <1 Sec. / involuntary
3. **Esophageal phase:** 8-20 sec. / involuntary

➤ Anti-reflux mechanism:

1. Lower esophageal sphincter (LES)
2. Crura of diaphragm.
3. Cardiac angle (angle of His)
4. Peristaltic movement.
5. Saliva

⚡ **Main signs and symptoms:** In esophageal disorders, we rely on History and investigations. Physical examination has low value here.

1. **Dysphagia:** the most important symptom, it means difficulty of swallowing, and almost all esophageal problems present with anatomical/functional dysphagia.
2. **Odynophagia:** may indicate esophageal problem as well.
3. **Wight loss:** as a consequence of Dysphagia and odynophagia.
4. **Regurgitation of** food or gastric content.
5. **Pain:**
  - A. **Heartburn:** a burning sensation in the central chest or upper central abdomen. The pain often rises in the chest and may radiate to the neck, throat, or angle of the jaw.
  - B. **Atypical chest pain:** may mimic MI.

**Main Investigations:**

- A. **Barium swallow:** a special type of X-ray, that uses barium sulfate to visualize upper GI, it's the first test (best initial) test performed in workup of dysphagia.



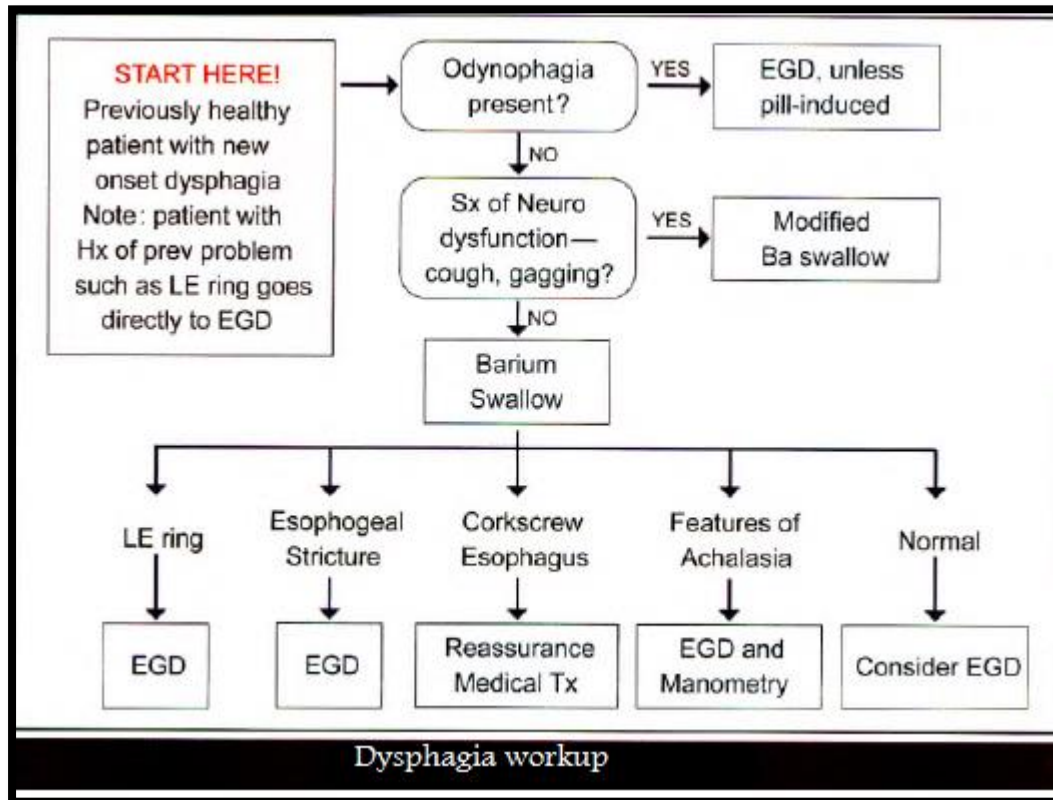
B. Upper endoscopy: follow Barium swallow (if needed).

**#Note\_1:** Barium swallow is done before Upper endoscopy, as endoscopy carries the risk of perforation in case of diverticular diseases or obstruction. Moreover, Barium swallow could be diagnostic or it may give a big hint to direct other investigations.

**#Note\_2:** Barium swallow and Upper endoscopy look for structural problems, while other investigations look for functional problems

C. Esophageal manometry: (dysphagia with -ve barium swallow and upper endoscopy → go for Manometry).

D. 24 hour esophageal monitoring



# Achalasia

## INTRODUCTION

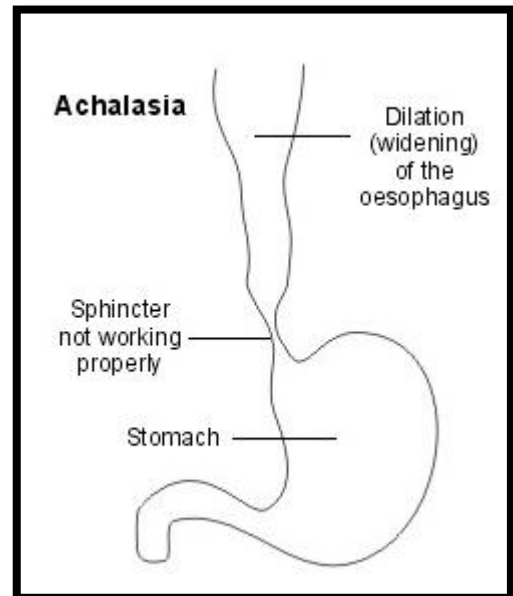
☿ **Definition:** a failure of smooth muscle fibers to relax, which can cause a sphincter to remain closed and fail to open when needed.

## ETIOLOGY

☿ Of unknown etiology.

☿ pseudoachalasia/secondary achalasia:

1. Esophageal CA.
2. Lymphoma
3. Chagas disease (trypanosoma cruzi infection).
4. Eosinophilic esophagitis
5. Neurodegenerative diseases.



## PATHOPHYSIOLOGY

☿ Loss of intraluminal neurons → inc. LES tone (failure of relaxation) → Dilation of the Distal esophagus.

☿ No esophageal peristalsis.

☿ inc. LES pressure

☿ LES does not relax with swallowing.

## CLINICAL FEATURES

☿ **Signs and Symptoms:**

- 1- **Dysphagia**
  - For solids and liquids.
  - Progressive (become worse overtime)
  - Longstanding, not associated with smoking and alcoholism, occur in younger group than CA (Vs CA).

## 2- Regurgitation of food

- especially at night.
- No reflux or difficulty in retching.
- Without bad smell

### ⚡ Complications:

- Aspiration pneumonia.
- Weight loss.
- Esophageal carcinoma



## DIAGNOSIS

### ⚡ Imaging:

1. **Barium swallow:** (best initial test) → bird's beak appearance (narrow LES + dilated esophagus)
2. **Upper endoscopy+ biopsy:** to confirm diagnosis + rule out CA
3. **Esophageal manometry:** (the definitive diagnosis) → absence of peristalsis+ non relaxing LES.



## TREATMENT

### ⚡ pneumodilatation: (BEST initial therapy)

- 3-4 diameter balloon is inflated in the LES → produce higher pressure.
- Effective in 85% of patients.
- 5% risk of perforation.

### ⚡ Botox (botulinum toxin injection)

- Effective in 65% of patients.
- Requires repeating therapy within 6-12 months.

### ⚡ Surgical myotomy.

- "Heller" myotomy.
- Excision of circular muscle layer of LES.
- High risk of GERD

### ⚡ Medical treatment (CCB and nitrates) is not that effective.

# Diffuse esophageal spasm

## INTRODUCTION

⚡ **Diffuse esophageal spasm (DES):** Idiopathic abnormality in neuromuscular activity of the esophagus, resulting in non-peristaltic contractions with high amplitudes causing pain and dysphagia.

- **Nut-Cracker:** Similar to DES but it's peristaltic contractions.
- DES and Nut-cracker are the same disease, the only difference is manometry.
- Think about DES as Irritable bowel syndrome of the esophagus.

## ? ETIOLOGY

⚡ Idiopathic.

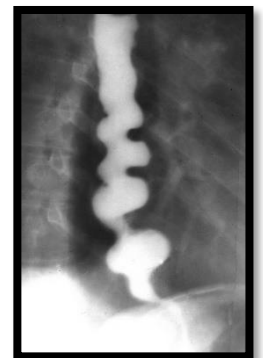## CLINICAL FEATURES

1. **Dysphagia:**
  - For both solids and liquids.
  - Intermittent.
2. **Atypical chest pain.**
  - May mimic MI.
  - Intermittent.
  - Not associated with swallowing (not odynophagia)
  - Not related with exercise.
  - Inc. With cold liquids.

## 💡 DIAGNOSIS

⚡ **Imaging :**

- 1- **ECG** to rule out MI.
- 2- **Barium swallow :**
  - Corkscrew appearance (see picture).
  - Could be normal.



- 3- **Manometry** (most accurate test):
  - High intensity, intermittent, disorganized contractions.

## TREATMENT

- 1- CCB (Diltiazem /Nifedipine)+nitrates → 1<sup>st</sup> line
- 2- Isosorbide or sildenafil → 2<sup>nd</sup> line
- 3- Botox injection → 3<sup>rd</sup> line

## Lower esophageal ring (Schatzki ring)

## INTRODUCTION

⚡ **Definition:** Lower esophageal ring, usually at the squamo-columnar junction.

## ETIOLOGY

⚡ almost always associated with esophageal hiatal hernia.

## CLINICAL FEATURES

- 1- Dysphagia:
  - Intermittent and not progressive.
  - For solids only, especially meat and fibers.
  - Not associated with pain.

## DIAGNOSIS

⚡ **Imaging:**

- 1- Barium swallow (the ring should be >13 mm to cause symptoms)
- 2- endoscopy

## TREATMENT

- ⚡ **esophageal dilatation**, using bougie or balloon dilators.
- The patients are placed on PPI after dilatation.

# Esophageal Webs



## INTRODUCTION

✦ **Esophageal webs:** Thin protrusion of esophagus mucosa, most often in the upper esophagus (hypopharynx).



## ETIOLOGY

✦ **Plummer-vinson syndrome**, due to iron deficiency anemia (IDA), it's characterized by:

- Esophageal webs
- Beefy-red tongue
- Koilonychia.
- Pica.



## CLINICAL FEATURES

✦ **Signs and Symptoms:**

1. **Dysphagia:**

- Intermittent and not progressive.
- For solids only.
- Not associated with pain.

✦ **Complications:** slightly increased risk for esophageal CA.



## DIAGNOSIS

✦ **Imaging:**

- 1- Barium swallow.
- 2- endoscopy



## TREATMENT

✦ **Treat IDA**

✦ **or treat it like esophageal rings, by dilatation.**

# Esophageal stricture



## INTRODUCTION

**Definition:** Narrowing of the esophagus.



## ETIOLOGY

- Long history of incompletely treated reflux.
- Prolonged NG tube placement.
- Lye (bleaching agent) ingestion decades ago (alkali is worse than acids) → erosive esophagitis.



## PATHOPHYSIOLOGY

⚡ Prolonged/severe Esophageal irritation → erosion of the mucosa → fibrosis (stricture).



## CLINICAL FEATURES

⚡ **Signs and Symptoms:**

- 1- **Dysphagia:** (Vs CA)
  - Constant, slowly progressive.
  - For solids then liquids.



## DIAGNOSIS

⚡ Barium swallow.



## TREATMENT

⚡ **Dilation**

# Esophageal CA

## INTRODUCTION

### ◆ Epidemiology:

- 99% of esophageal neoplasms are malignant.
- It's endemic In China, western Africa, central America and Iran.
- It's relatively rare in Jordan.

### ◆ Types:

#### 1- Adenocarcinoma.

- The most common type in USA (& Jordan).
- Associated with Barret's esophagus.
- distal 1/3.

#### 2- Squamous cell CA. (SCC)

- Most common (90%) worldwide (and in endemic areas).
- Causes are environmental.
- Middle or upper thirds

## ? ETIOLOGY

### ◆ General risk factors:

- Male gender, age >50.
- Poor nutrition (low fruits and vegetables intake) .
- Hot beverages.
- Smoking and Alcohol (synergistic effect, especially in low incidence areas).
- History of Radiation to the mediastinum

### ◆ Risk factors of SCC:

- **In general, Irritation of the mucosa.**
- Smoking and Hot beverages.
- Underlying esophageal disease (Achalasia, strictures, esophageal webs).
- Prior gastrectomy.
- Zinc oxide.
- Nitrosamines.
- Tylosis.



⚡ Risk factors of adenocarcinoma:

- GERD → Barret's esophagus → **most important risk factor.**
- Obesity.
- Smoking, and alcoholism.
- H. pylori
- EGF (epidermal growth factor) polymorphism.

## PATHOPHYSIOLOGY

### 1- SCC:

- It occurs due to prolonged esophageal irritation, usually seen in upper or middle thirds.
- It grows as polypoid, white plaques, or scar like lesions, early stages could be missed by endoscopy. → biopsy any lesion seen in endoscopy.
- It invades the submucosa, and travels cranially and caudally.
- It invades regional lymph nodes (Cervical & mediastinal) early.
- The trachea and aorta could be invaded, leading to tracheoesophageal fistula and bleeding, respectively.
- 1/3 of cases shows metastasis to liver, bone and lungs

### 2- Adenocarcinoma:

- GERD → Barret's esophagus → dysplasia → CA
- It occurs in lower 1/3.
- In endoscopy, Lesions are similar to Barret's esophagus.
- Spread to lymphatics around the stomach, Porta hepatis, and celiac lymph nodes.

## CLINICAL FEATURES

⚡ Most patients are asymptomatic till the tumor is advanced.

### 1- Dysphagia.

- The earliest sign.
- Dysphagia does not usually develop until >60% of esophageal lumen is obstructed.
- Constant, rapidly progressive.
- For solids then liquids.
- **Associated with reflux**

- 2- **Loss of appetite** and Wight loss, weakness and retrosternal discomfort.
- 3- **Achalasia-like symptoms.**
- 4- **Hoarseness** and Horner syndrome.
- 5- Tracheoesophageal fistula and bleeding.



## DIAGNOSIS

### ⚡ Investigations:

- 1- **Barium study** → may show us changes in contour.
- 2- **Endoscopy** and multiple biopsies for any change seen in the mucosa of the esophagus.
- 3- Full metastasis work up (CT scan of abdomen and chest, endoscopic ultrasound, PET scan).

### ⚡ Staging (TNM):

#### 1- **Endoscopic ultrasound** for T staging:

- T1 → mucosa/submucosa
- T2 → Muscularis propria
- T3 → Adventitia
- T4 → invasion of surrounding structures
  - T4a → not adherent
  - T4b → adherent

#### 2- **CT, then PET scan for N staging:**

No → no lymphatic invasion    N1 → 1-2  
 N3 → 3-6    N4 → 3-6  
 N5 → more than 6

#### 3- **CT scan for lung and liver** for distant metastasis.

#### 4- Final staging (briefly):

- Stage 1 and 2 → no lymph node invasion.
- Stage 3 → lymph node involvement or wall invasion (T3)
- Stage 4 → distant metz.

### ⚡ Ddx

- |              |                     |
|--------------|---------------------|
| 1-Leiomyoma  | 2-Metz.             |
| 3-Lymphoma   | 4-Benign stricture. |
| 5-Achalasia. | 6-DES               |
| 7-GERD       |                     |



## TREATMENT

### ⚡ The only way to cure esophageal CA is surgery:

- Stage 1 and 2 → surgery.
- Stage 3 → neoadjuvant chemotherapy/radiotherapy to shrink the tumor → then surgery.
- Stage 4/or patients is unfit → chemotherapy/palliative surgery.

☯ In surgery, we remove the esophagus, and we put a conduit (stomach or colon):

- Stwert 1 → if the tumor above LES → we remove esophagus only
- Stwert 2 → invades LES → we remove the esophagus + parts of the stomach with -ve margins.
- Stwert 3 → below LES → we remove the stomach with -ve margins.
- It's indicated to remove regional lymph nodes as well.

☯ Palliative therapy:

- Stenting
- Palliative surgery.
- Laser therapy.
- Phototherapy.

## Scleroderma esophagus

### INTRODUCTION

☯ **Scleroderma** (AKA systemic sclerosis): is a group of autoimmune diseases that may result in changes to the skin, blood vessels, muscles, and internal organs.

☯ CREST syndrome (limited scleroderma) is one of its types, it stands for:

- 1- calcinosis.
- 2- Raynaud's phenomenon.
- 3- esophageal dysmotility.
- 4- Sclerodactyly.
- 5- Telangiectasia

☯ 85% of patients with scleroderma have esophageal disorders, so it's the most common Connective tissue disease affecting the esophagus.

### PATHOPHYSIOLOGY

☯ Atrophy of esophageal wall smooth muscles → absent/weak esophageal contractions + LES is wide open with no tone/pressure → reflux → fibrosis of the esophageal wall.

☯ dysphagia due to Scleroderma is a neuromuscular problem, so it's for solids only. However, it may become mechanical eventually as a result of fibrosis of the smooth muscles.



## CLINICAL FEATURES

### ⚡ Signs and Symptoms:

#### 1- Dysphagia:

- Progressive, painless and for solids only (could progress into liquids in late stages)

#### 2- Reflux



## DIAGNOSIS

⚡ The clinical picture is clear, so need for further investigations.

⚡ Barium swallow and endoscopy?



## TREATMENT

⚡ treat the reflux with PPI + follow up every 2-3 months.

# Zenker's Diverticulum



## INTRODUCTION

**Definition:** is a diverticulum (outpouching) of the mucosa of the pharynx, just above the cricopharyngeal muscle (i.e. above the upper sphincter of the esophagus). It is a pseudo diverticulum (not involving all layers of the esophageal wall).



## PATHOPHYSIOLOGY

⚡ The upper esophageal sphincter has two parts, Upper Oblique (thyropharngeus) and lower transverse (cricopharyngeus), between these muscles, there's a weak area.

⚡ If swallowing is Uncoordinated so that the cricopharyngeus does not relax, the weak unsupported area above these fibers bulges out.



## CLINICAL FEATURES

### ◆ Signs and Symptoms:

- 1- **Dysphagia:**
  - Transfer dysphagia (difficulty initiating the swallowing)
  - For solids Only.
- 2- Halitosis (bad smell)
- 3- Food reaggregation.
- 4- Posterior neck mass.



## DIAGNOSIS

◆ Barium swallow.

◆ ~~Endoscopy and NG tube are contraindicated (due to the risk of perforation)~~



## TREATMENT

◆ Surgical resection

## Other esophageal conditions

◆ These conditions are medical problems more than surgical, and usually don't present with dysphagia, we will mention them briefly:

### 1- Esophagitis

◆ **Definition:** It's a general term referring to either infection or inflammation of the esophagus, that results in a **painful swallowing (Odynophagia)**.

◆ We have 3 types:

- 1- Pill induced esophagitis.
- 2- Infective esophagitis.
- 3- Eosinophilic (allergic) esophagitis.

#### A. Pill-induced esophagitis:

◆ Inflammation due to direct effect of contact between the mucosa & pill, usually in patients who ingest pills without water.

⚡ Examples of pills: NSAIDs, KCL, Iron sulfate, Doxycycline, Bisphosphonates, Alendronate etc....

⚡ **Diagnosis** is based on history:

- **Odynophagia.**
- Pain ONLY with swallowing.
- History of taking pills with small amount or without water.

⚡ **Treatment:**

- swallowing pills in upright posture & drinking enough water.

## **B. Infective esophagitis**

⚡ **Definition:** Opportunistic infection usually occur in immunocompromised patients (patients with HIV, DM, or using steroids, Chemotherapy etc..)

⚡ It's caused by many organisms, but the most common are: Candida (may present with oral thrush), HSV and CMV.

⚡ **Diagnosis and treatment:**

- We give **Fluconazole** empirically:
  1. If improved → Continue treatment, until the offending agent is gone (or CD4 improved)
  2. If not improved → Do endoscopy with biopsy.

## **C. Eosinophilic (allergic) esophagitis**

⚡ **Definition:** Immune mediated chronic esophageal inflammation:

- More common in males (20-40 years old)
- Strong association with other allergies: Involves IL-5, associated with peripheral eosinophilia, IgE is high in 20% of patients.

⚡ **Diagnosed by Endoscopy with biopsy:**

- Classical finding of Scalloped off.
- Biopsy shows dense eosinophilic infiltration in the middle of esophagus.

⚡ **Treatment:**

- Topical corticosteroids: (topical viscous budesonide or fluticasone).
- PPI maybe helpful.

## 2-Mallory weiss tear syndrome

☼ Definition: Partial-thickness mucosal laceration at gastroesophageal junction due to severe vomiting, Usually found in alcoholics and bulimics.

☼ Symptoms:

1. Painful Hematemesis, preceded by vomiting and retching.
2. Not a cause of dysphagia

☼ Diagnosis:

1. History.
2. Direct visualization upper endoscopy.

☼ Treatment: No need, is it resolves spontaneously.

# Gastroesophageal Reflux (GERD)

## INTRODUCTION

☼ **Definition:** Gastroesophageal reflux disease (GERD), also known as acid reflux, is a long-term condition where stomach contents come back up into the esophagus resulting in either symptoms or complications

☼ **Epidemiology:** Very common disease.

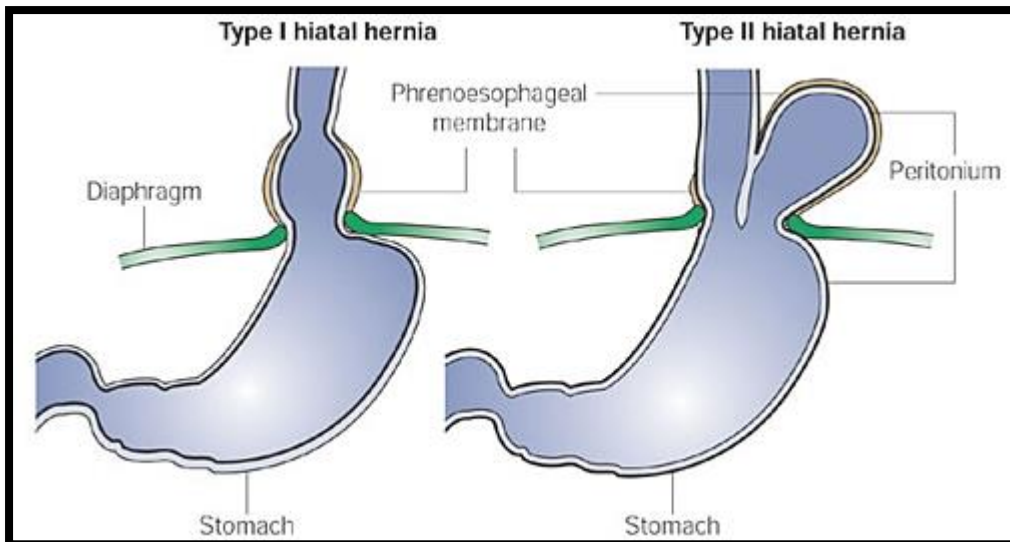
## PATHOPHYSIOLOGY

☼ Loss of anti-reflux mechanisms:

1. **Loss of LES tone &/or peristalsis;** due to smoking, alcohol, peppermint, Chocolate, CCB & nitrates. Or **hiatal hernia (see below).**
2. **Inc. Gastric volume;** due Diabetic gastroparesis or pyloric stenosis.
3. **Inc. Gastric pressure;** due to Ascites or pregnancy.

☼ **Hiatal hernia:**

- It is a type of hernia in which abdominal organs (typically the stomach) slip through the diaphragm into the middle compartment of the chest.
- It has two major subtypes, sliding (type I) and paraesophageal (Type II) :



### 1. Sliding hiatal hernia (Type I) :

- Both the stomach & GE junction herniate into the thorax via esophageal hiatus.
- It's the most common type of hiatal hernia. (>90% of cases)
- Mostly asymptomatic, but may present with GERD, esophagitis, dysphagia. And pulmonary problems.
- Diagnosed by UGI series, Manometry and endoscopy with biopsy.
- Treatment Is medical in 85% of cases, and surgical in 15% of cases.

### 2. Paraesophageal hiatal hernia (Type II):

- Herniation of all or part of the stomach through the esophageal hiatus into thorax without displacement of Gastroesophageal junction.
- It's rare (5% of cases)
- It causes mechanical obstruction → Dysphagia, stasis gastric ulcers & strangulation.
- However, most cases are asymptomatic (it's not associated with reflux, as the LES is normal)
- Complications: hemorrhage, obstruction, incarceration and strangulation.
- Treatment is surgical only.

3. Type III hiatal hernia → combined type I & II

4. Type IV hiatal hernia → Organ(colon/spleen) + stomach in chest cavity.





## CLINICAL FEATURES

### ⚡ Signs and Symptoms:

1. **Heartburn/** sore throat.
2. **Water brush.**
3. **Epigastric/substernal pain** (the most common cause of non-cardiac chest pain is GERD).
4. Bad, metal-like taste in mouth.
5. Cough, wheezing or hoarseness (it may exacerbate asthma).

### ⚡ Alarming signs:

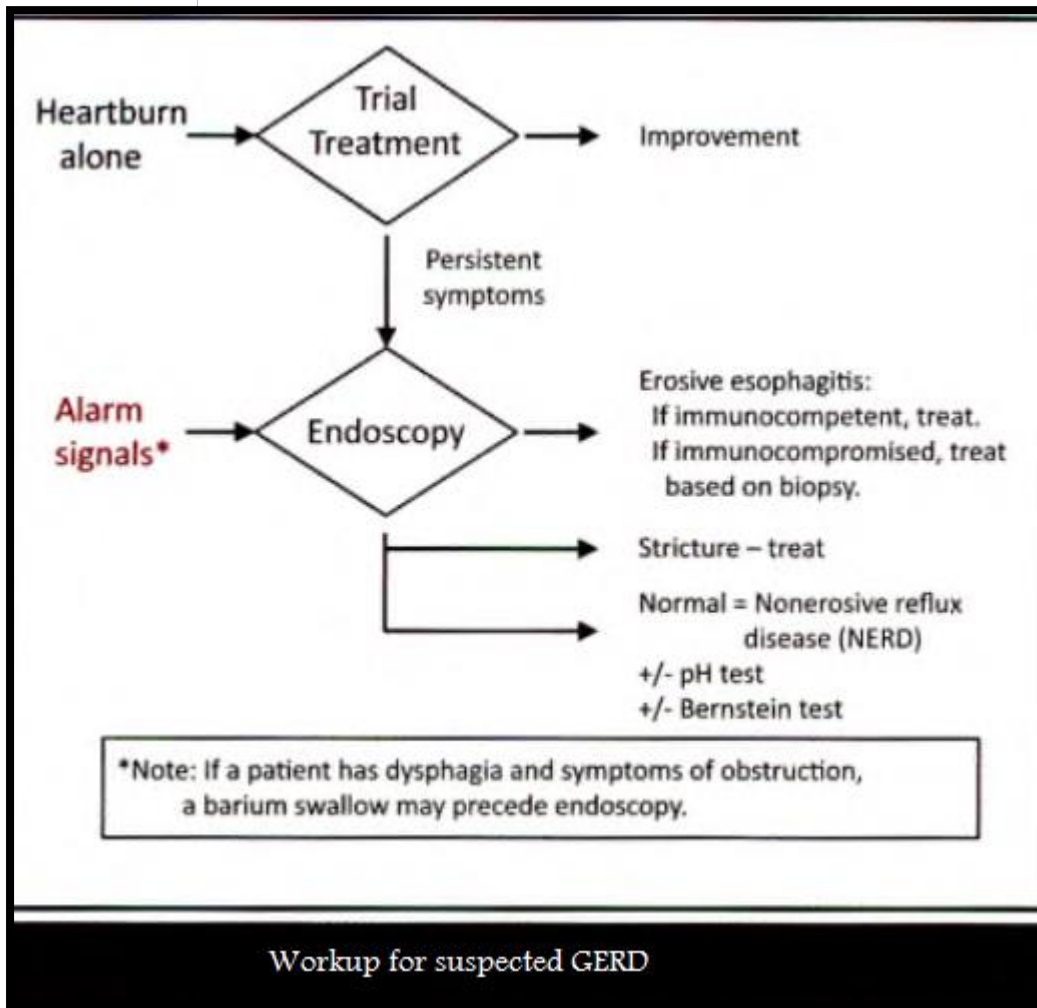
1. Nausea/emesis.
2. Dysphagia/odynophagia
3. Wight loss/ anorexia/ anemia/ blood in stool.
4. Abnormal physical exam.
5. Family history of peptic ulcer disease.
6. Failure to respond to PPI.
7. Long duration of symptoms.

### ⚡ Complications:

1. Exacerbation of asthma.
2. Esophageal ulcers
3. Strictures,
4. bleeding
5. **Barrett esophagus**
  - It's an intestinal metaplasia of lower esophageal mucosa (change from stratified squamous epithelium into simple columnar epithelium with goblet cells).
  - Risk factors are smoking and GERD, but many cases lack these risk factors.
  - Diagnosed by endoscopy.
  - Management is by PPI and **follow up:**
    - i. **No dysplasia** → 3-5 years
    - ii. **Low-grade dysplasia** → 6-12 months
    - iii. **High-grade dysplasia** → 3 months



## DIAGNOSIS



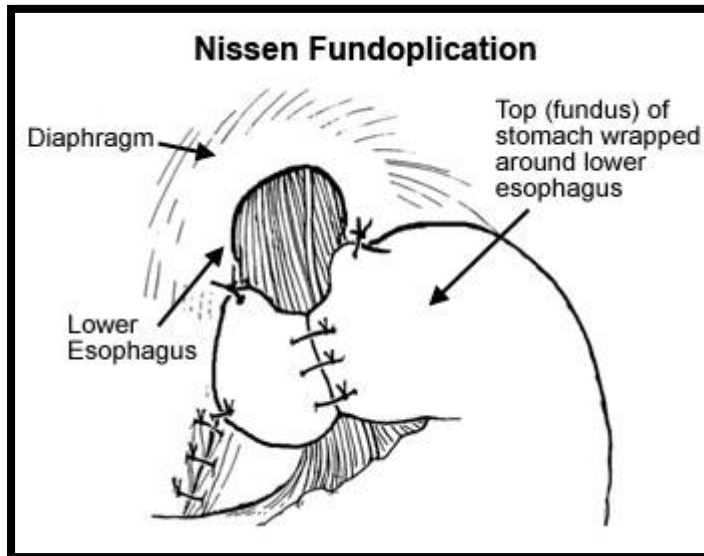
## TREATMENT

### Medical:

- Mild or intermediate:
  1. Life style modification. (raise head in bed, weight loss, small not fatty or sweet meals, eat at least 3 hours before sleep, stop smoking and alcohol drinking)
  2. Antacids
  3. H2 blockers.
- Moderate or progressive:
  1. Life style modification.
  2. PPI

## ☼Surgical:

- Indications for surgery:
  1. Failure of medical treatment.
  2. Respiratory problems.
  3. Severe esophageal injury
- Surgical options:
  1. **Lap Nissen**
    - It's 360 fundoplication – 2 cm Laparoscopically.



- It works through improving lower esophageal sphincter function; **Increasing LES tone, Elongates LES by 3 Cm, Returning LES into abdominal cavity.**
- Post-op complications:
  - i. Gas-bloating syndrome (Inability to vomit)
  - ii. Strictures
  - iii. Dysphagia.
  - iv. Spleen injury requiring splenectomy.
  - v. Esophageal perforation.
  - vi. Pneumothorax.
- 2. **Belsey Mark IV**: 240 to 270 fundoplication through thoracic approach.
- 3. **Hill**: Arcuate ligament repair (close large esophageal hiatus) + gastropexy (suture stomach to diaphragm).
- 4. **Toupet**: laparoscopic Incomplete Wrap (200)

# Summary & past papers

## Summary

☯ Dysphagia is the most important symptom in esophageal disorders, it means difficulty of swallowing, and almost all esophageal problems present with anatomical/functional dysphagia.

☯ Dysphagia could be due to motility/neuromuscular problems (Achalasia, DES and early scleroderma), Obstruction (Strictures, cancer, rings, webs and late scleroderma) or nervous (like in strokes and neurodegenerative disorders).

☯ Barium swallow, upper endoscopy, esophageal manometry and 24 hour esophageal monitoring are the main diagnostic workup used in diagnosing esophageal disorders; Barium swallow is the best initial test performed in workup of dysphagia.

☯ Achalasia is the failure of esophageal smooth muscle fibers to relax, which makes LES unable to relax with swallowing, leading to dilation of the Distal esophagus. It presents with dysphagia and regurgitation of food. Diagnostic workup is Barium swallow (best initial test), upper endoscopy and esophageal manometry (the definitive diagnosis). Pneumodilatation is the best initial therapy, other lines of treatment are Botox injection and surgical myotomy. CCB and nitrates are NOT effective.

☯ Esophageal cancer has two main types; Adenocarcinoma and squamous cell carcinoma. Adenocarcinoma is more common in Jordan, and is associated with GERD and Barrett esophagus, it originates from the lower 1/3 of the esophagus. Squamous cell carcinoma is more common worldwide, especially in endemic areas, it results from chronic irritation of the

esophageal wall (Smoking and Hot beverages, Achalasia, strictures, esophageal webs, Zinc oxide and Nitrosamines), it originates from the upper and middle 1/3 of the esophagus). Esophageal cancer presents with constant, rapidly progressive dysphagia, loss of appetite, weight loss, weakness and retrosternal discomfort. Initial diagnostic workup is: barium study, Endoscopy and biopsy. Once diagnosed, full staging and metastatic workup should be done (Endoscopic ultrasound, CT, PET scan, CT liver and CT lung). Prognosis is generally poor, early stages (1, 2) are treated surgically, stage 3 could be treated surgically only after shrinking the tumor by neoadjuvant therapy, late stages (4) are sent for the palliative care.

☯ Gastroesophageal reflux disease (GERD) is a long-term condition where stomach contents come back up into the esophagus resulting in either symptoms or complications. It results from loss of LES tone (like in hiatal hernia), increased gastric volume, or increased gastric pressure. It presents with heartburn, water brush, substernal pain, metal-like taste in mouth, Cough, wheezing or hoarseness. In the absence of alarming signs (Nausea, emesis, Dysphagia, odynophagia, weight loss, anorexia, anemia, blood in stool), the patient could be given a trial of PPI, if no improvement occurs, or if the patient had one of the alarming signs, upper GI endoscopy with biopsy is the best next step, if no pathology is detected, the next step is 24-hours pH monitoring to make sure that the patient is truly having GERD, not NERD. If reflux is demonstrated by 24-hours pH monitoring and there's no response to anti-reflux medications,

surgical management (fundoplication) is the last resort.

### Past papers

**1- best Initial investigation in a patient with GERD?**

- a) barium swallow
- b) EGD**
- c) Manometry

**2- True about Barrett esophagus:**

- a) it's an intestinal columnar metaplasia**

**3-A case of a male, having dysphagia for 6 months, started for solids, but now for solids and liquids, he has also significant weight loss, Dx?**

- a) Achalasia
- b) esophageal stricture.
- c) esophageal web
- d) Esophageal cancer**

**4- which of the following does not pass through the three openings of the diaphragm?**

- a) Left phrenic nerve**
- b) IVC
- c) Aorta
- d) left vagus nerve
- e) esophagus

**5- Wrong about GERD:**

- a) **90% will have esophagitis on endoscopy due to reflux (60% will show normal mucosa on endoscopy).**
- b) Not all types of reflux are diagnosed by PH monitoring
- c) Barium swallow can detect hiatal hernia

**6- Wrong about GERD:**

- a) not all esophageal hernias result in reflux.

**b) manometry is mandatory before surgery**

**7- The best diagnostic test for achalasia:**

- a) Manometry**
- b) EGD with biopsy
- c) 24 pH monitoring

**8- Another patient has difficulty in swallowing, what's the best diagnostic test?**

- a) Manometry
- b) EGD with biopsy**
- c) 24 pH monitoring Stomach

**9- The site of esophageal rupture in boerhaave syndrome is?**

- a) Proximal esophagus anteriorly
- b) Proximal esophagus posteriorly
- c) Distal esophagus anteriorly
- d) Distal esophagus posteriorly**

**10- In achalasia, the most sensitive test is:**

- a) Bird peak on Barium swallow
- b) Manometry showing failure of complete relaxation of LES with swallowing**
- c) Biopsy
- d) Aperistalsis of cervical esophagus

**11- one of the following can't be candidate for Fundoplication:**

- a) young patient
- b) patient with paraesophageal hernia (not sure)**
- c) patient with esophageal dysmotility
- d) patient with LES pressure 8mmHg
- e) patient with lateral sliding hernia

**12- regarding GERD, all of the following are true except:**

- a) triad of heartburn, regurgitation and dysphagia are the usual presentation.

- b) improvement on PPI is one of the diagnostic Criteria
- c) ambulatory PH MONITORING is used to assess
- d) GERD in patients with persistent symptoms
- e) **esophageal manometry is used to evaluate esophageal peristalsis before antireflux surgery (not sure)**
- f) Lap.Nissien fundoplication is indicated for patients with normal length esophagus

**13- Manometry can show all except:**

- a) length of intraabdominal esophagus
- b) length of LES
- c) pressure of the esophagus
- d) peristaltic contractions
- e) **degree of gastric reflux**

**14- True about esophagus:**

- a) starts at the upper limit of thyroid cartilage
- b) **starts at C6**
- c) 35 cm in length
- d) infra abdominal part is not covered with peritoneum
- e) pass the diaphragm at T8

**15-Wrong about zenker diverticulum:**

- a) **Barium is not diagnostic and endoscopy is Needed.**
- b) Almost all esophageal diverticula are acquired
- c) Epiphrenic diverticula associated with motility problems
- d) Herniation between superior constrictor and Sth

**16- regarding esophagus, all true except:**

- a) primary peristalsis propels food to the stomach, occurs in progressive way

- b) **2ry peristalsis is initiated voluntarily**
- c) 3ry peristalsis is simultaneous, non peristaltic contractions
- d) abdominal part of the esophagus is covered by peritoneum
- e) LES is not an anatomical structure and it is a zone of high pressure measuring 3-5 cm in length

**17- All of the following in regards to GERD are true except:**

- a) **vomiting undigested food is common**

**18- regarding esophageal cancer, all true except:**

- a) most patients in Jordan present with late stage 3B
- b) adenocarcinoma increased in incidence due to barrett's esophagus
- c) no matter the site, we always have to check the celiac LN
- d) **5 year survival rate has reached 60% in recent years**

**19-What structure passes with the aorta through the opening of the diaphragm:**

- a) IVC
- b) superior gastric vessels
- c) **Thoracic duct**
- d) Phrenic nerve
- e) Vagus nerve

**20-one is right about esophagus anatomy:**

- a) **It deviates anterior and to the left at diaphragm.**

**21- all of the following decrease reflux to esophagus except :**

- a) **Fundus distention**

**22- which of the following causes LES contraction:**

- a) Protein
- b) Fat
- c) Pepper
- d) fundal expansion**

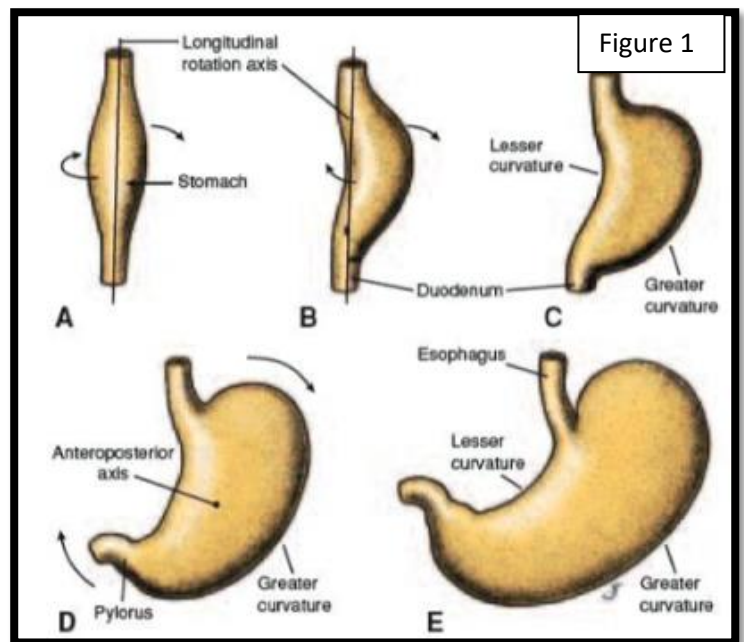
**23- Regarding esophageal cancer, which is wrong:**

- a) around 80% present with dysphagia
- b) dysphagia causes weight loss
- c) all Adult pts with dysphasia should undergo upper GI endoscopy to rule out malignancy
- d) Screening for esophageal cancer in Jordan is not cost effective**

# The stomach

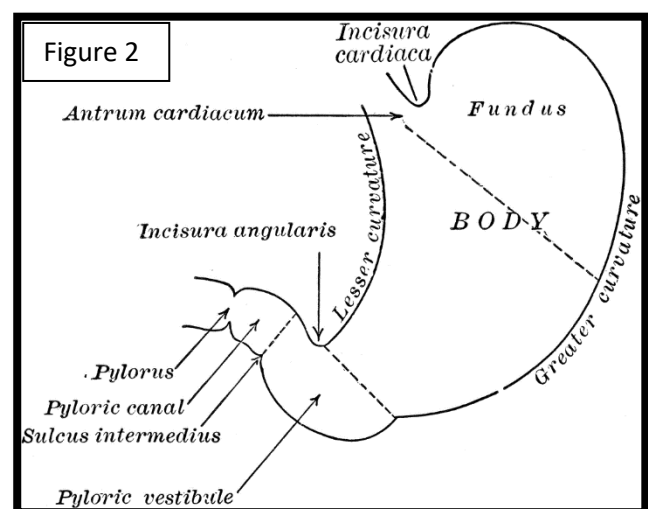
✦ **Embryology:** the stomach starts to grow as a part of the foregut, it grows like a cylinder, that has ventral and dorsal part. (figure 1)

- This cylinder is suspended to the body wall by the ventral embryonal mesentery and the dorsal embryonal mesentery.
- A fusiform dilation grows out of this tube, forming the stomach.
- The dorsal part grows more rapidly than the ventral part, forming the greater curvature.
- Meanwhile, the stomach rotates 90° clockwise, so the dorsal part becomes to the left, forming the greater curvature. and the ventral part becomes at the right side, forming the greater curvature.



✦ **Anatomy:** The stomach starts at the end of the LES, and ends at the pyloric sphincter: (figure 2)

- The main anatomical parts of the stomach are: the cardia, fundus, body, antrum, and pylorus.
- The left border of the stomach is called the greater curvature, and it's attached to the greater omentum. The right border of the stomach is called the lesser curvature and it's attached to the lesser omentum.





- The stomach and lesser omentum separate the abdomen into two sacks; the greater sac (most of the abdominal cavity, anterior to the stomach), and the lesser sac (behind the stomach).
- The only connection between these sacs is the foramen of Winslow.

⚡ **Blood supply:** All parts of the stomach are supplied by the branches of the celiac trunk. (figure 3)

- The celiac trunk gives 3 major arteries; left gastric, splenic and common hepatic.

- The **left gastric artery** supplies the lesser curvature (it gives also a branch to the esophagus).
- The splenic artery runs in a tortuous way behind the stomach, at the upper border of the pancreas, and before reaching the spleen, it gives one large artery, namely: the **left gastroepiploic artery**, to the greater curvature. Moreover, the spleen itself supplies the stomach from the terminal branches of the splenic artery with **the short gastric arteries** to the fundus of the stomach.

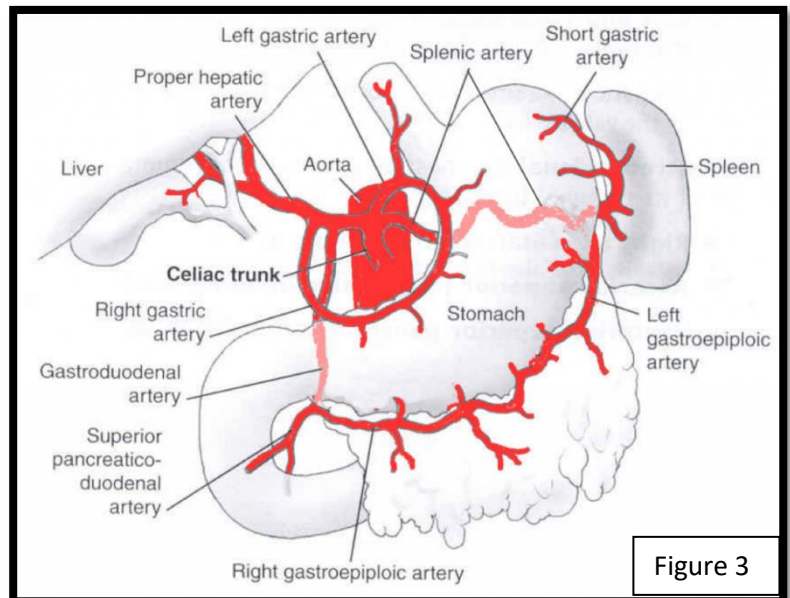


Figure 3

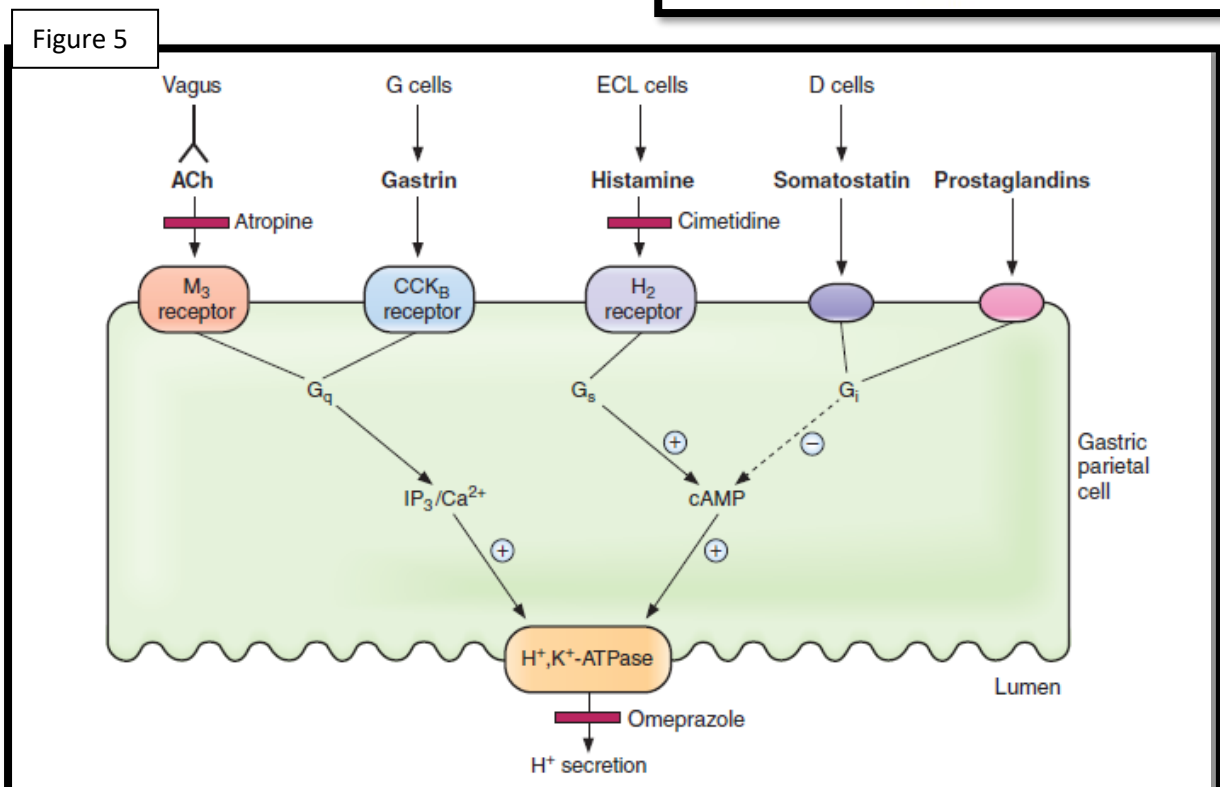
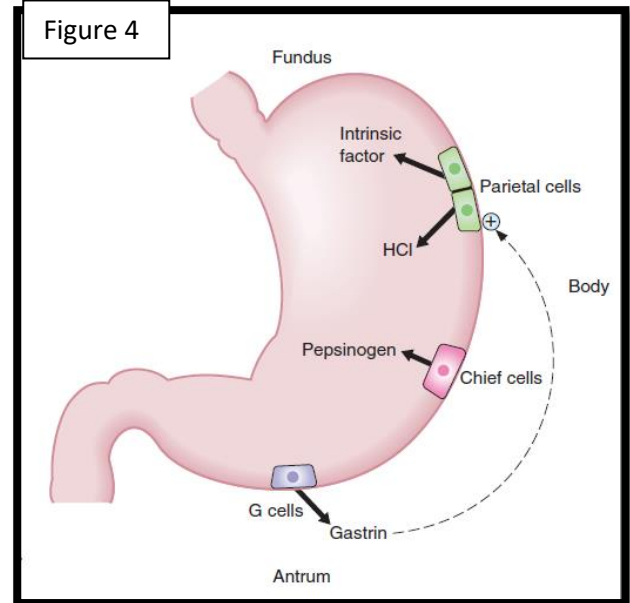
- The common hepatic artery gives two arteries before becoming the hepatic artery proper, these arteries are the **right gastric artery** (to the lesser curvature) and the gastroduodenal artery, respectively. The gastroduodenal artery descends posteromedial to the second part of the duodenum and terminates as **right gastroepiploic artery** (to the greater curvature) and the superior pancreaticoduodenal arteries.
- To sum up: blood supply to the greater curvature is from the right and left gastroepiploic arteries, and the blood supply to the lesser curvature is from the right and left gastric arteries.
- **Venous drainage** of the stomach:
  - Right and left gastric veins → Directly to the portal vein.
  - Left gastroepiploic vein → splenic vein.
  - Right gastroepiploic vein → SMV.

## ⚡ Innervation

- Anterior gastric wall → left vagus nerve.
- Posterior gastric wall → right vagus nerve.
- Gastroduodenal pain is sensed via sympathetic afferents from T5 to T10

⚡ **Physiology:** The major secretory cells of the stomach are Parietal cells, chief cells, mucus cells (found in the fundus, produces  $\text{HCO}_3^{2-}$  and mucus) and G-Cells (figure 4).

- Main factors that increase gastric acid secretion are gastrin, Acetylcholine and histamine.
- Somatostatin and prostaglandins decrease gastric acid secretion (figure 5).



### ⚡ Main signs and symptoms:

1. **Epigastric discomfort (dyspepsia):** Non-specific term that refers to recurrent upper abdominal pain or discomfort, it includes: epigastric fullness, burning, belching, bloating and heart burn.
  - It could be exacerbated or reduced by food, relieved by medications, or continuous.
2. Other serious or (ALARM Signs):
  - Anemia
  - Loss of weight
  - Anorexia
  - Recent onset of progressive symptoms.
  - Melena/Hematemesis.
  - Swallowing difficulty

### ⚡ Main Investigations:

1. **Flexible upper endoscopy (FUE):** is the 'gold standard' investigation of the upper gastrointestinal tract.
2. **Barium Contrast studied** could be used, but these studies are less sensitive than FUE.
3. **Endoscopic/ laparoscopic Ultrasound.**
4. **CT, MRI, PET scan and laparoscopy** → for assessment of gastric CA.

## Peptic ulcer disease

### INTRODUCTION

⚡ **Definition:** Peptic ulcer disease represents a spectrum of diseases characterized by ulceration of the stomach or proximal duodenum due to imbalance between acid secretion & mucosal defense mechanisms.

⚡ **Epidemiology:** It's a very common disease.

- But the incidence is decreasing due to: discovery and eradication of H. pylori, better medical treatment, improvement in the quality of life, more sanitation and more precautions in the use of NSAIDs and aspirin.

⚡ Classification:

- **Duodenal:** on the anterior wall (more common).
- **Gastric:** (less, common, has 5 categories):

**Type I** → lesser curvature (near incisura angularis), it's associated with decreased mucosal production.

**Type II** → lesser curvature + duodenal, it's associated with increased acid production.

**Type III** → Prepyloric, it's associated with increased acid production.

**Type IV** → proximal stomach/ cardia, it's associated with decreased mucosal production.

**Type V** → anywhere in the stomach, it's medication induced.

## ? ETIOLOGY

1. **Helicobacter pylori** (the most common cause)
  - It causes both duodenal ulcers (90%) and Gastric ulcers (70-80%)
  - The infection causes chronic antral gastritis, and ulceration.
  - If eradicated, it has A very low reoccurrence rate.
2. **NSAIDs** (2<sup>nd</sup> most common cause)
  - It causes both duodenal ulcers (8%) and Gastric ulcers (40%).
  - It occurs due to decreased PGs production, so it's dose dependent.
  - IF NSAIDs are discontinued, it doesn't reoccur.
3. **Acid hypersecretion**
  - Associated with duodenal ulcers.
  - EX: Zollinger Ellison syndrome
4. **Smoking**

## ⚡ PATHOPHYSIOLOGY

⚡ PUD occurs when there is loss of the protective mucous barrier (of mucus and  $\text{HCO}_3^-$ ) and/or excessive secretion of  $\text{H}^+$  and pepsin.

- Protective factors are mucus,  $\text{HCO}_3^-$ , prostaglandins (that increases mucous production) , mucosal blood flow, and growth factors.
- Damaging factors are  $\text{H}^+$ , pepsin, Helicobacter pylori (H. pylori), nonsteroidal anti-inflammatory drugs (NSAIDs), stress, smoking, and alcohol.



## CLINICAL FEATURES

### ◆ Signs and Symptoms:

- Usually asymptomatic.
- If symptomatic: it presents with **burning/Gnawing intermittent epigastric discomfort** that either relieved by food (duodenal ulcer) or exacerbated by food (peptic ulcer).
- It may present also with nausea, vomiting, Weight loss, upper GI bleeding or the complications.
- **ALARM** Symptoms may indicate malignancy.

### ◆ Complications:

- Bleeding.
- Perforation.
- Obstruction.



## DIAGNOSIS

### ◆ History

◆ **Investigations:** **Flexible upper endoscopy** to confirm the diagnoses, once the diagnosis is confirmed, we have to look for the cause:

#### 1. H. Pylori infection tests:

- Non-invasive: Serological antibody tests, Urea breath test, Fecal antigen test.
- Invasive: Biopsy (gold standard) → to rule out malignancy, Culture + Urase test.

#### 2. Fasting serum Gastrin levels: to rule out ZES

- If there's no history of NSAIDs, with -ve h. pylori test.
- If a patient is experiencing recurrent ulcers despite medical treatment.
- If a patient has multiple ulcers or ulcers in unusual sites.

#### 3. Endoscopic biopsy to rule out Gastric Ulcer.



## TREATMENT

### Medical:

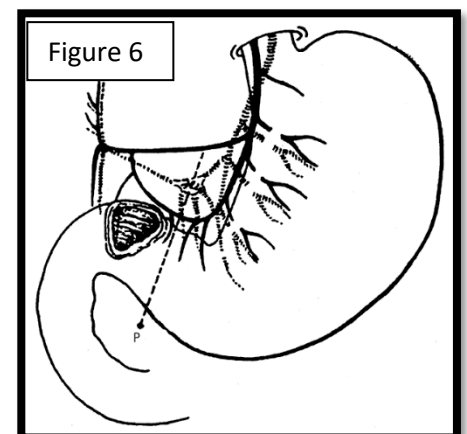
- **H. pylori eradication:** Triple therapy (1 PPI + 2 antibiotics), for 10-14 days
- NSAIDs -associated PUD → **Stop the drug**, then initiate anti-secretory Treatment.
- **Smoking cessation.**
- Follow up with endoscopy

### Surgical:

- Rarely done nowadays, unless PUD is complicated.
- Principles of Surgical treatment:
  1. In treating PUD, we are trying to reduce Gastric acid secretion by cutting the Parasympathetic stimulation (vagus nerve) through surgical vagotomy. Nowadays, the role of surgical vagotomy has decreased as we discovered a way to perform pharmacological vagotomy (PPI or H<sub>2</sub> blockers).
  2. In Vagotomy, the higher level you cut the vagus nerve, the more you paralyze the stomach (especially the antrum) and delay gastric emptying. So in Truncal Vagotomy, it's mandatory to perform a drainage procedure; pyloroplasty, antrectomy, or gastrojejunostomy.
- Surgical options for PUD:
  1. **Highly selective Vagotomy** (figure 6): transection of the vagal fibers to the body of the stomach without interruption of fibers to the pylorus.
    - Advantages: We don't remove any part of the stomach, We don't interfere with the process of emptying (no need for drainage procedure)
    - Disadvantages: high recurrence rate (15%) after 10 years.

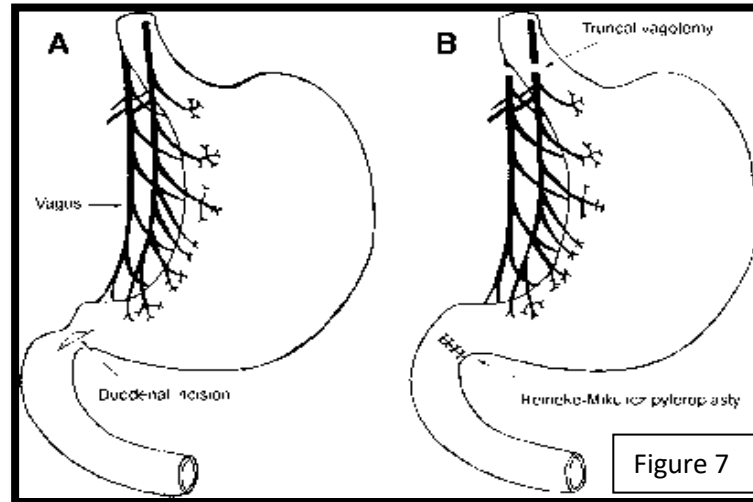
#### ➤ Indications For surgery:

1. Non-healing ulcers.
2. Perforated Ulcers.
3. Bleeding Ulcers.
4. Gastric outlet obstruction.
5. Malignant Ulcers.

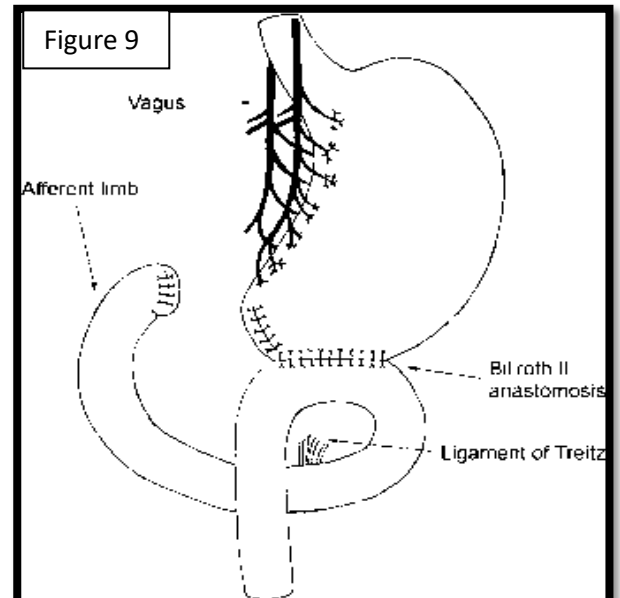
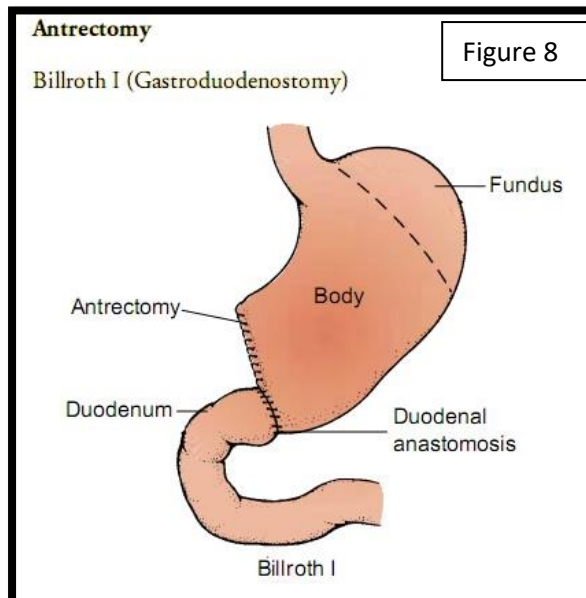


2. **Selective Vagotomy:** here We cut the nerve supply to the whole stomach, except the hepatobiliary and celiac branches.
3. **Truncal vagotomy:** The vagus in nerve is cut, It's mandatory here to perform a drainage procedure.

a) **Truncal vagotomy with pyloroplasty (figure 7):**



- b) **Truncal Vagotomy with antrectomy, and anastomosis:** transection of the vagus nerve trunk, then the distal 40% of the stomach is removed and anastomosed with the duodenum (Billroth I anastomosis- Figure 8) or Jejunum (Billroth II anastomosis- figure 9).



# Complicated Peptic ulcer disease

## 1. Bleeding PUD

### INTRODUCTION

✦ It's the leading cause of death due to PUD.

- Mortality rate is 5-10%
- The most common cause of UGI bleeding.

✦ The most common site of bleeding duodenal ulcer is the posterior wall, typically eroding the gastroduodenal artery.

✦ Signs and symptoms:

- 1- Fresh or coffee-ground hematemesis.
- 2- Melena.

### TREATMENT

✦ Aggressive resuscitation & correction of any coagulopathy.

✦ Then we do endoscopy:

- We may need electrocautery or epinephrine.
- Spontaneous cessation is seen in 70% of cases.
- Findings indicating high risk of bleeding:
  - Large sized ulcer.
  - Visible vessels on a non-bleeding ulcer.
  - Visible clots.

✦ Surgical intervention if medical treatment is failed.

## 2. Perforated PUD

✦ Most commonly seen in the anterior duodenal wall





## DIAGNOSIS

◆ History:

1. Sudden onset of severe abdominal pain (less dramatic in elderly/hospitalized and immunocompromised)
2. Peritonism (Fever/tachycardia and guarding).

◆ investigations:

1. CBC → leukocytosis
2. Abdominal/chest X-ray → air under diaphragm.



## TREATMENT

◆ Stabilize the patient: Aggressive fluid resuscitation, analgesia, broad spectrum antibiotics.

◆ Then we send the patient to the operation room, to do:

1. Graham patch.
2. Graham patch + HSV
3. Graham patch + truncal vagotomy + drainage procedure.

### 3. Gastric outlet obstruction



## INTRODUCTION

◆ It occurs due to:

1. Healing of a circumferential ulcer & fibrosis by scar tissue.
2. Edema & spasm
3. Antral tumors.



## DIAGNOSIS

1. **History:**

- Recurrent vomiting of poorly digested food.
- Dehydration.
- Hypochloremic hypokalemic metabolic alkalosis.

2. **Physical examination:**

- Dilated full stomach.
- Visible peristaltic waves.

- +ve succession splash.

3. **NG tube** will expel a muddy fluid in large quantities



## TREATMENT

⚡ Stabilize the patient → insert NG tube, start IV hydration, Electrolytes correction and anti-secretory medications.

⚡ When the patient is stable → Do endoscopy (to rule out CA\_

⚡ If the cause is scarring, it's usually refractory to medical treatment → surgical treatment.

### **4. Non-healing PUD:**

- Rule out Cancer.
- Look for persistent H. pylori.
- Non-compliant patient.
- Use of NSAIDs.
- Motility disorder.
- ZES.

# Gastric Cancer



## INTRODUCTION

⚡ **Types:**

- **Adenocarcinoma:** The most common type (95%), it's the type that will be discussed in this section, other types will be explained briefly later.
- **GIST**
- **Lymphoma.**
- **Carcinoid.** (Very rare)

⚡ **Epidemiology:**

- It has a low incidence worldwide (10/100000 in USA), but very high incidence in Japan (78/100000).
- Incidence decreased dramatically due to the eradication of H. pylori.
- It's the disease of elderly (>60 years).

⚡ **Subtypes of Gastric Adenocarcinoma:**

### 1. Diffuse type: (30%)

- Arise from lamina propria (no glands).
- More common in proximal parts of the stomach (Especially the Cardia), but could be found anywhere in the stomach.
- Associated with invasive growth pattern with rapid submucosal spread → if the entire stomach is involved, this results in thickening of the stomach “**Linitis plastica**”.
- Less association with the known risk factors.
- Occurs in younger age group.
- Worse prognosis than intestinal type.
- Metastasis are more common in this type, especially by lymphatics.

### 2. Intestinal type: (70%)

- Arise from gastric mucosa.
- In distal parts of the stomach.
- Associated with H. Pylori & other environmental risk factors.
- Well-Formed glandular structure.
- Spreads by invasion and seeding.

## ? ETIOLOGY

#### ⚡ Dietary risk factors:

- Smoked meat.
- High nitrates contents.
- Low fruits and vegetables.
- Smoking.

#### ⚡ Demographic risk factors:

- Male gender.
- Low socioeconomic state.
- Black race.
- Blood Group type A.
- Family history.

#### ⚡ Medical risk factors:

- H. pylori infection.
- Atrophic gastritis.
- Previous partial gastrectomy.
- Ménétrier's disease.
- P53 mutation is found in 50% of cases

## PATHOPHYSIOLOGY

⚡ As any other cancer, Carcinogenesis is a multi-step process, with increased rate of mutations with the persistence of the risk factors, this is mostly true in the case of intestinal type Gastric Adenocarcinoma:

- H. pylori infection → Chronic gastritis → intestinal metaplasia → Dysplasia → Carcinoma in situ → intestinal type Gastric Adenocarcinoma.
- It's important to mention that peptic ulcers don't transform into Gastric CA, but it's thought that Gastric CA present itself as an ulcer.
- Cancers are more common in the lesser curvature.

## CLINICAL FEATURES

⚡ **Symptoms:** Gastric CA generally has non-specific signs & symptoms, so most of the patients present at late stage, remember the acronym "WEAPON":

- **W**ight loss (the most common presentation).
- **E**arly satiety/ **E**mesis.
- **A**norexia.
- **P**ain (epigastric discomfort) → Most common early symptom.
- **O**bstuction → seen in distal lesions, while in proximal ones, **dysphagia** could be seen.
- **N**ausea.

⚡ **Signs:**

- Signs of anemia, and chronic blood loss (Coffee-ground hematemesis, melena, heme-occult)
- Epigastric mass. (in advanced cases).

⚡ **Signs of distant metastases:**

- **Virchow's node:** enlarged supraclavicular lymph node.
- **Sister Marry Joseph's node:** infiltration of the Umbilicus.
- **Blumer's shelf:** fullness in the pelvic Cul-De-Sac (solid peritoneal deposit anterior to the rectum, forming a shelf palpated on PR).
- **Krukneberg's tumor:** enlarged ovaries on pelvic exam (metastases to the ovaries).
- **Hepatosplenomegaly** with ascites and jaundice.

- **Irish's node:** left axillary lymphadenopathy.
- **Cachexia**



## DIAGNOSIS

⚡ **Screening:** endoscopy or contrast studies are only recommended in high risk groups:

- More than 20 years post-Gastrectomy.
- Patients with pernicious anemia or atrophic Gastritis.
- Endemic areas.

⚡ **Investigations:**

1. **Flexible upper endoscopy + Biopsy:**

- It's the investigation of choice.
- Take at least 7 biopsies from the edges of the ulcer → to increase sensitivity.

2. ~~Double contrast barium enema~~ → not used anymore.

⚡ **Staging: (TNM)**

1. **Endoscopic Ultrasound:**

- Used for T staging → Can't detect T2.
- For N staging → regional lymph nodes.
- Can't differentiate the tumor cells from fibrosis after neoadjuvant chemotherapy.

2. **CT-Scan**

- It's complimentary to EUS in T staging.
- Can't differentiate between T1 and T2.
- Used also for Distant metastasis and lymph nodes.
- Can't detect small metastasis (<5 mm).
- Can't tell if an enlarged lymph node is involved or not → Use **PET** scan.

3. **Chest X-ray and LFT.**

4. **Laparoscopy** → To detect peritoneal implants → send peritoneal fluid for cytology → if +ve → it's stage IV .

## ⚡ Staging:

⚡ T staging: <ul style="list-style-type: none"><li>➤ T1 → mucosa/submucosa</li><li>➤ T2 → Muscularis propria</li><li>➤ T3 → Subserosa</li><li>➤ T4 → Whole wall invasion</li></ul>	⚡ N staging: <ul style="list-style-type: none"><li>➤ Nx → Couldn't be determined.</li><li>➤ N0 → No lymph nodes</li><li>➤ N1 → 1-6</li><li>➤ N2 → 7-15</li><li>➤ N3 → &gt;15</li></ul>	⚡ M staging: M1 → if there's metastases or peritoneal implants.
--	--	--

- If T1/T2 → stage 1 → early stage
- If T3/T4 → stage 2 or 3 → late stage
- If there's distant metastases (M1) → it's stage 4



## TREATMENT

⚡ In early stages (stage 1) → we go for curative surgery.

⚡ In late stages (stage 2 or 3) → we give neoadjuvant chemotherapy to down stage the tumor → then we go for curative surgery ± Adjuvant chemo or radiotherapy.

⚡ If the patient is in stage 4, or in stage but unfit for surgery → we go for palliative therapy.

⚡ The curative surgery for gastric CA has two goals:

- 1. Resect the tumor** with clear margins (at least 5cm):
  - If the tumor was proximal or midbody → Do total Gastrectomy.
  - If the tumor was distal → Do subtotal Gastrectomy.
  - Then re-anastomose the stomach; either by Billroth II (not I) or Roux-en-y anastomosis (see bariatric surgery section).
  - In cases of total gastrectomy, Roux-en-y limb is sewed to the esophagus.
  - Splenectomy is done if the tumor directly invades the spleen/splenic hilum/ or there's splenic hilar adenopathy.
- 2. Lymph nodes dissection:** Usually D1 and D2 only
  - D1 → perigastric lymph nodes.
  - D2 → splenic artery LN/ Hepatic artery LN/ Left Gastric LN/ Anterior mesocolonic LN/ Anterior pancreatic LN/ Crural LN.
  - D3 → Paraaortic

⚡ **Prognosis:** 25% of patients are alive 5 years in USA, while in Japan, 50% of people are alive after 5 years.

## Other types of Gastric CA

### 1. Gastrointestinal stromal tumors (GIST)

#### INTRODUCTION

⚡ Gastrointestinal stromal tumors (GIST), previously known as leiomyosarcomas are rare GI tumors arising from mesenchymal component (interstitial cells of Cajal), these are only 3% of gastric tumors.

⚡ sites: GI tract, from esophagus to rectum:

- Most common site → The stomach (60%)
- The second most common sites → the small intestine (30%)
- Rectum (3%)
- Colon (2%)
- Esophagus (1%)

⚡ More common in males, >60 years.

⚡ Usually C-KIT (CD 117) +ve

- So it's the tumor marker for GIST.
- It's a target for chemotherapy.

#### DIAGNOSIS

⚡ **Signs and symptoms:**

- Vague abdominal pain.
- Abdominal mass.
- Nausea.
- Abdominal distention.

⚡ **Investigations:**

- Endoscopy + FNA biopsy.

⚡ **Staging:**

- CT abdomen/ pelvis.
- Chest x-ray.

- PET scan.

## TREATMENT

⚡ Treatment is surgical:

- Laparoscopic resection with 2cm -ve margins.
- No need for lymph node resection.
- Post-operative adjuvant chemotherapy by C-KIT inhibitor (imatinib).

## 2. GI lymphoma

## INTRODUCTION

⚡ Lymphomas are either **Hodgkin** or **non- Hodgkin**.

- Non- Hodgkin lymphomas are either **nodal** (from lymph nodes), 70%, or **extranodal** (30%).
- The most common site of Extranodal lymphoma is the GI tract (50%) of cases.

⚡ **Characteristics of primary GI lymphomas:**

- No lymphadenopathy.
- Normal bone marrow.
- Normal blood smear.
- The disease is confined to a certain affected viscus.
- Absence of hepatic or splenic involvement unless direct extension of primary tumor.

⚡ **Types of GI lymphoma:**

### 1. **Diffuse large B-Cell lymphoma:**

- Most common.
- Seen in the stomach, ileocecum.
- BCL-2, BCL-6.

### 2. **MALToma:**

- Associated with H. pylori.
- Multifocal, distal, lymphoepithelial lesions.
- It has the best prognosis.

### 3. **Burkitt's lymphoma:**

- Younger patients.
- Aggressive.
- Involves the cardia, body and the terminal ileum.



- EBV infection is a risk factor.
- Starry sky appearance on LM.

#### 4. Mantle Cell lymphoma:

- Polyposis in small bowel.
- Tends to compress rather than infiltrate.

#### 5. Enteropathy T-Cell lymphoma:

- Celiac disease is a risk factor.
- Jejunum & ileum.
- Circumferential ulceration.
- Eosinophilic in histology.



## CLINICAL FEATURES

### ◆ Gastric lymphomas:

- The stomach is the most common site of GI lymphoma.
- Most common site → distal stomach.
- Associated with H. Pylori infection.
- HIV infection is also a risk factor.
- Most common type → diffuse large B- Cell lymphoma.
- Symptoms are similar to Gastric adenocarcinoma.

### ◆ Small intestinal lymphoma:

- Second most common site.
- Bimodal age distribution.
- Presentation depends on the site, and may present as intestinal obstruction.
- Will be discussed later.



## DIAGNOSIS

◆ Endoscopy with biopsy ± H. pylori test If MALToma.

### ◆ Staging:

- CT chest/ abdomen/ pelvis.
- Bone marrow biopsy.
- Biopsy of enlarged peripheral lymph nodes.

### ◆ Stages:

- **WHO classification:** low grade Vs High Grade.
- **TNM:** not useful, but could be used for some types of Gastric lymphoma.



## TREATMENT

⌘ Treatment of gastric lymphoma is usually conservative:

- Low grade MALToma → H. pylori eradication.
- High grade MALToma → Chemotherapy/radiotherapy.
- Non- MALToma (Diffuse large B-Cell lymphoma, Burkitt's, etc ..) → Chemotherapy/radiotherapy.
- Indications for surgery: (1) failure of Chemotherapy, (2) emergency cases.

⌘ Treatment of intestinal lymphoma is surgical.

# Obesity & bariatric surgery

## INTRODUCTION

⚡ Obesity is the 2<sup>nd</sup> most common cause of preventable death.

➤ It's a disease with many comorbidities.

⚡ A **Comorbidity**: a condition that resolves with the treatment of the disease.

⚡ Comorbidities that are associated with obesity:

➤ **Respiratory:**

1. Obstructive sleep apnea (OSA): is the most common comorbidity of the obesity, 70%-85% of cases can be cured with bariatric surgery.

➤ **GI:** GERD, Constipation colon CA.

➤ **CVS:** Hypertension, Diabetes mellitus, Heart failure, hyperlipidemia.

➤ **MSS:** osteoarthritis, Disc prolapse.

➤ **Urogenital:** PCOS, Urge/stress incontinence.

➤ **CNS:** pseudotumor cerberi, depression.

➤ **Reduction in all vital capacities.**

⚡ Body mass index (BMI) (**figure 10**) is a good method for obesity staging, thus deciding the best method to lose weight. It equals body **mass (kg)/tall(M)<sup>2</sup>**

BMI (kgm <sup>-2</sup> )	Definition
<18.5	Underweight
18.5-24.9	Ideal Weight
25-29.9	Overweight
30-39.9	Obese
40-49.9 or 35-49.9 with obesity-related comorbidity	Morbidly Obese
50-59.9	Super Obese
60-69.9	Super Super Obese
>70	Hyper Obese

Figure 10



# TREATMENT

⚡ Methods of weight loss:

1- **conservative**: lifestyle modification.

- Once a patient reaches morbid obesity, the medical (conservative) failure rate is 100%.
- Bariatric surgery is the most effective, sustainable, method of weight loss, with a failure rate of 10%

2- **Surgical**, indications for bariatric surgery:

- Morbid obesity (BMI>40)
- Severe obesity (BMI>35) + comorbidities.
- Severe comorbidities.
- Social and psychological implications.

⚡ Types of bariatric surgeries:

- **Restrictive**: decreases the size of the stomach, ex: VBGT, LAGB. LSG.
- **Malabsorptive**: it's better to be called maldigestive, in these surgeries, we are diverting the food away from the duodenum → poor digestion → poor absorption, such surgeries are not done anymore nowadays.
- **Combined**: FOBI, BPD DS.

⚡ Bariatric surgery success rate is rate according to Excess weight loss (EWL), failure of surgery is if EWS <25%.

⚡ Points to be asked for surgical candidate:

- Sweet eater/salt eater.
- Family history.
- Maximum weight reached.
- Minimum weight reached.
- Trails of conservative treatment? Diet? Exercise?
- Symptoms of comorbidities.
- Motivation?

## A. Restrictive surgery:

1- **Vertical Banded GasroPlasty (VBGP)** (figure 11)

- Not Used anymore.
- High failure rate (Dehiscence + Dilation of the gastric pouch)

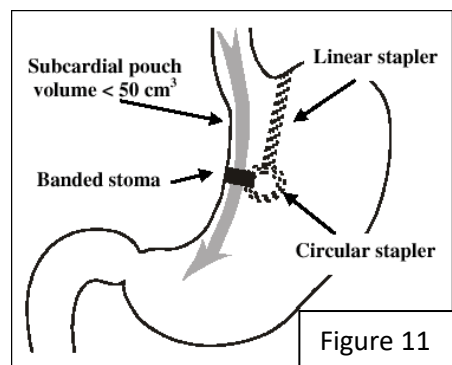
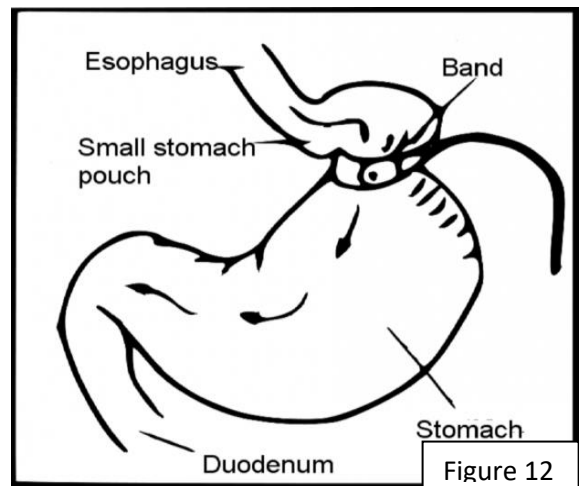


Figure 11

## 2- Laparoscopic adjustable gastric band (LAGB) (figure 12)

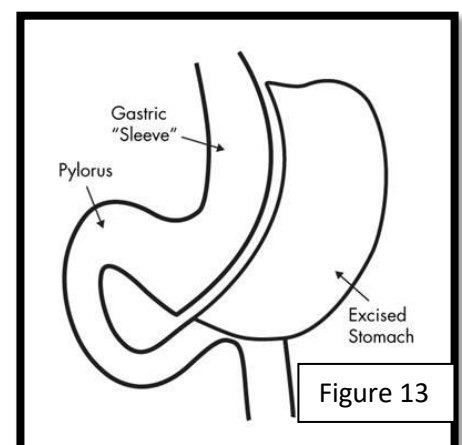
- Laparoscopic procedure, done by placing a silicone band with an inflatable balloon around the proximal part of the stomach, at the angle of His, connected to a port attached to the abdominal wall.
- It's **reversible** (no resection of the stomach) and **adjustable** (inflate the balloon to lose more weight, deflate the balloon to gain weight)



Advantages	Disadvantages
<ul style="list-style-type: none"> <li>➤ No resection of the stomach, less dangerous (no leak, peritonitis)</li> <li>➤ Good for solid eaters, because they need time to pass the food.</li> <li>➤ Reversible, adjustable.</li> <li>➤ Can be used for borderline BMI.</li> <li>➤ Few short-term complications.</li> </ul>	<ul style="list-style-type: none"> <li>➤ Not good for sweet eaters (sweet dissolves)</li> <li>➤ Band may erode through the wall.</li> <li>➤ Band slippage → it's an emergency.</li> <li>➤ Port may reposition (should be fixed to the fascia of the abdominal wall.</li> <li>➤ Side effects: reflux, regurgitation, Vomiting, esophageal dysmotility.</li> <li>➤ The least effective In terms of EWL (50-60%)</li> <li>➤ Relative CO in BMI &gt;50</li> <li>➤ CO in hernia and reflux.</li> </ul>

## 3- Laparoscopic Sleeve Gastrectomy (figure 13)

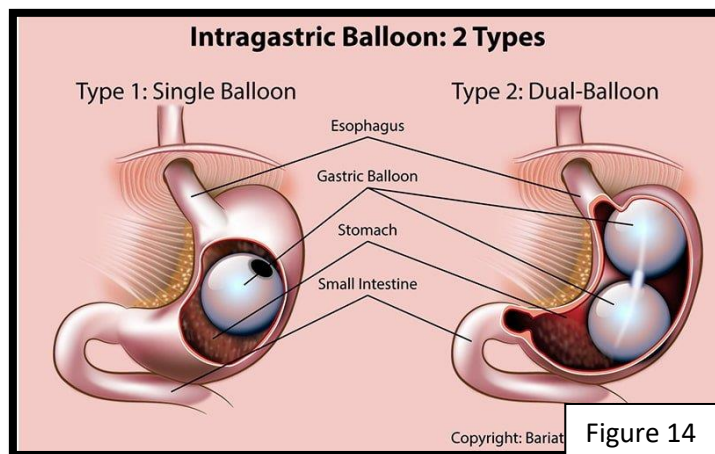
- 85% of the stomach is resected, from the pylorus to the angle of His along the greater curvature.
- By cutting the stomach, the size that's available for food is reduced, moreover, the Ghrelin hormone secretion is decreases → Less hunger.



Advantages	Disadvantages
<ul style="list-style-type: none"> <li>➤ Good EWL (80%)</li> <li>➤ A re-sleeve procedure can be done or a bypass if the original surgery doesn't have satisfactory results.</li> </ul>	<ul style="list-style-type: none"> <li>➤ Not enough long term results.</li> <li>➤ Morbidity is the same as the by-pass</li> <li>➤ Fever is an ominous sign → could indicate leakage.</li> <li>➤ Stenosis could be complication.</li> <li>➤ Nutritional complications due to decreased food intake.</li> </ul>

⚡ LSG could be used as a Bridge procedure for Biliopancreatic procedure.

- A bridge procedure can be done before the “real” surgery to lose weight & make the “real” surgery easier.
- Another bridging procedure is placing an intragastric balloon laparoscopically for very obese patients for 6 weeks preoperatively. (figure 14)



## **B. Combined Surgeries:**

⚡ In these procedures, the stomach is converted to a small pouch (restrictive), then then the stomach is anastomosed to more distal part of the small intestine to by-pass it (malabsorptive). All these procedures have failure due to:

- Dilatation of the pouch.
- Vitamin for life.

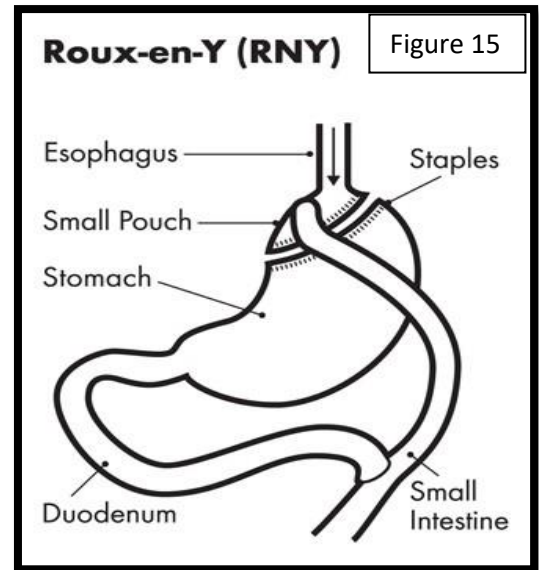
### **1- Roux-en-y gastric by-pass (figure 15)**

⚡ It's the most popular surgery in U.S.A

⚡ 70% success rate

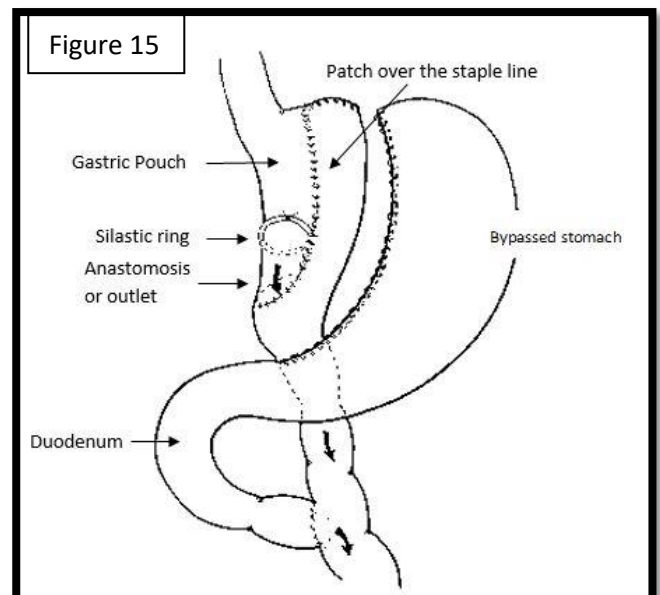
☼ Procedure:

- 1) The stomach is cut into small pouch (connected to the esophagus).
- 2) A 75-150 cm of the small intestine (that's connected to the remainder of the stomach) is cut.
- 3) The remaining small intestine is called Roux limb, the roux limb is anastomosed with the gastric pouch.
- 4) The cut small intestine (that's connected to the stomach) is anastomosed after 75 cm of the Roux limb.



**2- FOBI (banded Gastric bypass) (figure 16):**

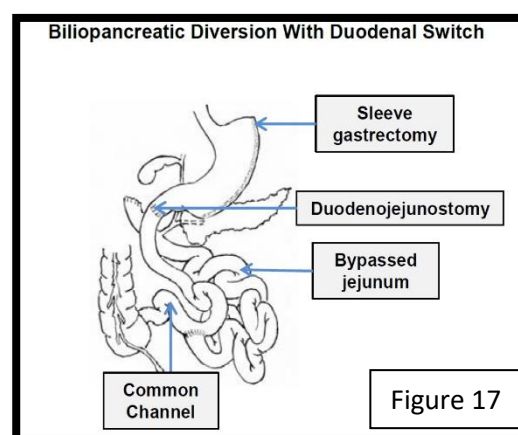
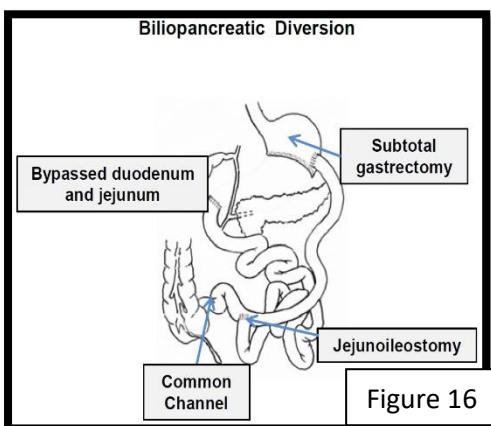
☼ FOBI Is a modification of RYGB, but rather than staples it uses silastic ring around the distal part of the pouch, to simulate pyloric valve, thus prevents stretching and dilation of the bowel under the pouch.



**2- Biliopancreatic Diversion (± Duodenal switch) ( BPD DS) (figures 16 and 17)**

☼ It's combined, but more Malabsorptive.

☼ It has many complications (severe vitamin deficiency, anemia, dumping syndrome.. etc), Less commonly done.



# Gastric syndromes

## 1- Post-Gastrectomy syndromes

### ⚡ **Dumping syndrome:**

- It occurs because the stomach “dumps” the food by fast emptying, this delivers hyperosmolar chyme to the intestine.
- Consists of postprandial vasomotor palpitation, sweating, lightheadedness.
- Types:
  - 1) Early: 30 minutes after eating.
  - 2) Late: >90 minutes after eating, due to hypoglycemia.
- Treatment: restrict sweets & lactose containing food, encourage frequent small meals.

### ⚡ **Blind loop syndrome:**

- Bacterial overgrowth in a loop.
- Usually seen in patients with previous gastrectomy with Billroth II anastomosis.
- Signs and symptoms of fat & vitamin B12 malabsorption.

### ⚡ **Afferent loop syndrome:**

- Seen in Gastrojejunostomy.
- Afferent loop is the portion that was by-passed.
- Signs & symptoms of Abdominal bloating & pain (20 minutes – 1 hour after eating), relieved by vomiting (bile stained)
- Etiology: might be due to incomplete draining afferent loop which fills with biliary & pancreatic secretions.

## 2- Gastroparesis in DM

### INTRODUCTION

⚡ Highly variable gastric emptying patterns is seen in diabetic patients (slow, fast, or normal)

- But long-term DM tend to develop slow gastric emptying (gastroparesis).



# PATHOPHYSIOLOGY

⚡ Blood glucose >200 mg/dl results in:

- 1) Decreased antral mortality.
- 2) Delayed gastric emptying.
- 3) May have direct -ve long term effects on gastric emptying.

⚡ Conversely, gastroparesis itself increases blood glucose (due to delay of insulinemic & glycemetic response).

⚡ So it's a viscous cycle, we try to cut it or at least minimize it by tight glycemetic control.



## DIAGNOSIS

⚡ Symptoms:

- Nausea & vomiting.
- Early satiety.
- Predisposition for bezoars.

⚡ Investigations:

- Requires ruling out obstruction first.
- Then the diagnosis is confirmed by radioisotope-labeled solid meal.



## TREATMENT

⚡ Good hydration.

⚡ low fat diet.

⚡ tight control of blood glucose.

⚡ **Metoclopramide** for long term use.

⚡ Or IV **erythromycin**

- Increase gastric motility (it's motilin analogue).
- It's used in acute sittings, less useful for long term use

### ⚡ Causes of Gastroparesis:

- Diabetic neuropathy.
- Autoimmune dysfunction (amyloid neuropathy).
- Infiltrative process (scleroderma)
- Viral infection.
- CNS disorders (MS, stress, Parkinson, tumor, cord injury).
- Post vagotomy.
- 1/3 to 1/2 of cases are idiopathic.

# Summary & past papers

## Summary

☯ Flexible upper endoscopy, barium Contrast studied and endoscopic ultrasound are the main diagnostic workup used in diagnosing gastric disorders; flexible upper endoscopy (FUE): is the 'gold standard' investigation of the upper gastrointestinal tract.

☯ Peptic ulcer disease (PUD) represents a spectrum of diseases characterized by ulceration of the stomach or proximal duodenum due to imbalance between acid secretion & mucosal defense mechanisms. The most common two causes for PUD are H. pylori infection and NSAIDs, respectively. Other less common causes are increased acid secretion (Zollinger Ellison syndrome) and smoking. PUD is usually asymptomatic. If symptomatic, it may present with burning epigastric discomfort that either relieved (duodenal ulcer) or exacerbated by food (peptic ulcer), nausea, vomiting, Weight loss, upper GI bleeding. ALARM Symptoms (Anemia, Loss of weight, Anorexia, Recent onset of progressive symptoms., Melena/Hematemesis, Swallowing difficulty) may indicate malignancy. Flexible upper endoscopy with biopsy is the gold standard test to diagnose PUD and exclude malignancy. Malignant ulcers are way more common in the stomach compared to the duodenum. Triple therapy (1 PPI + 2 antibiotics) and lifestyle modification is the first line to treat PUD, if failed, or if the patient developed complication, the surgical management is the last resort. Surgical management consists of cutting the vagus nerve at some point ± drainage procedure. The higher

level you cut the vagus nerve, the more you need a drainage procedure.

☯ Complications of PUD are bleeding, perforation and obstruction. Bleeding is the leading cause of death in PUD, it's the most common cause of UGI bleeding as well. The most common bleeding artery is the gastroduodenal artery, due to erosion of the posterior duodenal wall. Bleeding PUD is managed by aggressive fluid resuscitation, and emergent endoscopy when the patient is stable. Spontaneous cessation is seen in 70% of cases. Perforated PUD is most commonly seen in the anterior duodenal wall, it presents with sudden onset of abdominal pain with peritonism. Abdominal X-ray may show air under diaphragm. Management consists of aggressive fluid resuscitation, analgesia, broad spectrum antibiotics and emergent surgical closure. Gastric outlet obstruction (GOO) occurs due to fibrosis of circumferential ulcer, edema or antral tumors. It presents with recurrent vomiting of poorly digested food, Dehydration, Hypochloremic hypokalemic metabolic alkalosis and +ve succession splash. NG tube will expel a muddy fluid. GOO is managed by stabilization and correction of electrolytes imbalance, when the patient is stable endoscopy is done to know the cause.

☯ Gastric adenocarcinoma has two main types; Intestinal and diffuse type. Intestinal type is more common, it develops from gastric mucosa and found in the distal parts of the stomach, it's associated with H. Pylori & other environmental risk factors (Smoked meat, nitrates, low fruits and vegetables., smoking. Male gender, low socioeconomic state, black race, blood

Group A, family history, previous partial gastrectomy). Diffuse type has poorer prognosis and occurs at a younger age group. It arises from lamina propria and is more common in proximal parts, it's associated with invasive growth pattern "Linitis plastica" and has less association with the known risk factors. Gastric Adenocarcinoma presents with weight loss (the most common presentation), anorexia, nausea, early satiety, emesis, epigastric pain (most common early symptom), obstruction, anemia (due to chronic blood loss) and, in late stages, epigastric mass. Gastric adenocarcinoma has some characteristic sites for metastases, these sites are supraclavicular lymph node (Virchow's node), the umbilicus (Sister Mary Joseph's node), anterior to the rectum (Blumer's shelf) and the ovaries (Krukenberg's tumor). Liver metastasis with hepatosplenomegaly ascites and jaundice may occur as well. Flexible upper endoscopy with biopsy is the initial diagnostic workup. Once diagnosed, full staging and metastatic workup should be done (Endoscopic ultrasound, CT, Chest X-ray, LFT, laparoscopy and peritoneal fluid cytology). Prognosis is generally poor, early stages (1) are treated surgically, stages 2 & 3 could be treated surgically only after shrinking the tumor by neoadjuvant therapy, late stages (4) are sent for the palliative care.

☞ Obesity is the 2nd most common cause of preventable death worldwide. Comorbidities that are associated with obesity: obstructive sleep apnea (OSA), GERD, Constipation, colon CA, HTN, DM, HF, hyperlipidemia, osteoarthritis, Disc prolapse, PCOS, incontinence, pseudotumor cerebri and depression. Body mass index (BMI) is a good method for obesity staging, It equals body mass (kg)/tall(M)<sup>2</sup>. lifestyle modification is the first step to lose weight, once a patient

reaches morbid obesity, the medical (conservative) failure rate is 100%. Bariatric surgery is indicated in morbid obesity (BMI>40), Severe obesity (BMI>35) with comorbidities, severe comorbidities and if this condition is causing psychological implications. Bariatric surgeries are either pure restrictive (Vertical Banded GastroPlasty, Laparoscopic adjustable gastric band and Laparoscopic Sleeve Gastrectomy), pure malabsorptive (not done anymore), or combined (Roux-en-y gastric by-pass, FOBI, and Biliopancreatic Diversion± Duodenal switch). Laparoscopic sleeve gastrectomy is one of the most commonly done bariatric surgeries, it has an excess weight loss of 80%. However, it's not suitable for sweet eaters. Roux-en-y gastric by-pass is the most popular surgery in U.S.A, with 70% success rate.

### Past papers

#### 1- Gastroduodenal artery arises from which artery ??

a) Hepatic

#### 2- True about GI lymphoma:

- b) mucosal biopsy will always diagnose.
- c) Treated with surgery or chemotherapy. (not sure)

#### 3- True about gastric bypass surgery:

- a) It's more of a restrictive procedure rather than malabsorptive (wrong)
- b) It causes protein malnutrition (not sure)
- c) It's not good for obese patients with esophagitis (wrong)
- d) Sleeve gastrectomy was found to be better in treating diabetes compared to it (wrong)
- e) It rarely causes iron deficiency (wrong)

4- Not associated with gastric cancer?

- a) blood type O (it's blood type A).

5- out of these, the least effective bariatric surgery in terms of excessive weight loss:

- a) Gastric by-pass
- b) Laparoscopic sleeve gastrectomy
- c) **Gastric banding**

6-Which of the following is false about G.I. secretions?

- a) **Gastric juice is rich in Potassium**

7- Most common cancer that metastasizes to the stomach:

- a) **Melanoma**
- b) Colon

8- Wrong about bariatric surgery:

- a) **Gastric bypass is restrictive not malabsorptive**
- b) bypass is good for sweet eaters
- c) banding is number one on children

9- Bleeding artery in duodenal ulcer is:

- a) **Gastroduodenal artery**

10- About gastrin, true:

- a) **secreted from G cells, stimulate parietal cells**

11- True about type one benign gastric ulcer:

- a) associated with hypergastrinemia
- b) due to increased parietal cell activity
- c) **Due to decreased mucosal defenses**

11- a patient with BMI above 50, sweet eater, comorbidities, best bariatric surgery is:

- a) laparoscopic sleeve gastrectomy

- b) **laparoscopic gastric bypass - vertical banded gastroplasty**
- c) lap adjustable gastric band

12- metabolic changes that are seen in excessive vomiting:

- a) **Hypokalemic hypochloremic metabolic alkalosis**
- b) Hyperkalemic hypochloremic metabolic alkalosis
- c) Hyperkalemic hyperchloremic metabolic alkalosis
- d) Hypokalemic hyperchloremic metabolic alkalosis

13- Which of the following is not part of management of bleeding gastric ulcer:

- a) Fluid resuscitation.
- b) Emergent upper endoscopy.
- c) **NG tube insertion**
- d) Cautery

14- Gastric cancer, what is wrong:

- a) **CEA and some other tumor marker are used as diagnostic tests**
- b) stage 3 is potentially respectable
- c) Proximal gastric tumor might present with dysphagia

15- Bariatric surgery, band ligation, what is wrong:

- a) **Banding shows comparable results with bypass in relation to the extent of weight loss**
- b) Dumping syndrome is not a significant complication
- c) Poor choice for sweet eaters
- d) Results in less leak complications
- e) Something about recurrence

16-All of the following are on the transpyloric plane except:

- a) fundus of the gallbladder
- b) termination of the spinal cord
- c) **dudeno-juenal junction**

- d) neck of the pancreas
- e) **origin of inferior mesenteric artery**

**17-Regarding Gastrin all are true except:**

- a) secreted by G cells in antrum
- b) **decreased by PPI** (PPI results in hypogastrenemia )
- c) responsible for gastric phase of acid secretion
- d) increased in Zollinger Ellison
- e) when elevated causes gastric carcinoid

**18- All are risk factors for stomach cancer except:**

- a) **Vegetables and citrus-Poor socioeconomic status**
- b) H. pylori infection
- c) Adenomatous polyps

**19- bariatric BMI 50, sweet eater, diabetic, hypertensive, with reflux:**

- a) laparoscopic gastric bypass
- b) **jejunoileal bypass**
- c) gastric band
- d) sleeve

**20- which of the following is true about gastrin:**

- a) **inhibited by acid in antrum**

**21- one of the following is not secreted by stomach:**

- a) Lipase
- b) **Glucagon**
- c) Gastrin

**22- gastric cancer, all true except**

- a) PET is a good diagnostic tool
- b) **endoscopic ultrasound can be used in determining T and N**

**23- gastric Ca, not a RF :**

- a) **female sex**
- b) smoking

**24-PUD perforation, which is wrong:**

- a) mostly in the anterior wall
- b) **20% present with pneumoperitoneum**

**25- Which of the following is wrong regarding H. pylori:**

- a) **It is a gram positive organism**

**26-About Gastric cancer, which of the following is wrong:**

- a) **CA cancer screening is warranted and necessary in Jordan. (???)**

**27- All increase gastrin secretion except:**

- a) Antrectomy
- b) **Vagotomy**
- c) Z-E syndrome
- d) atrophic gastritis
- e) achlorhydria

# Pancreas & spleen

- Written by: Nada Hajjaj
- Corrected by: Mohammad Qussay Al-Sabbagh

- pancreas :60
  - introduction: 60
  - Congenital Anomalies Of The Pancreas: 65
  - Acute Pancreatitis: 67
  - Pancreatic pseudocyst 77
  - Chronic Pancreatitis : 81
  - Pancreatic tumors: 85
  - Whipple procedure: 92
  - Summary and past papers: 94
- Spleen 97
  - Introduction: 97
  - Splenectomy: 100
  - Splenic trauma: 7
  - Summary and past papers: 109

# Pancreas

## ❖ Embryology: [Figure 1]

- During the 4<sup>th</sup> week of gestation, the pancreas begins to develop from the duodenal endoderm.
- Two buds form (which then rotate and fuse by the 8<sup>th</sup> week):  
**VENTRAL BUD** (from the convex part of the duodenum) → Uncinate process and part of the head  
**DORSAL BUD** (from the concave part of the duodenum) → Remaining part of the head, neck, body and tail.
- The ventral bud rotates with the duodenum and then migrates posteriorly to fuse with the dorsal part.
- The ventral duct (the bud's duct) will take over and open into the duodenum at the ampulla of Vater → Wirsung duct.
- The dorsal duct may persist and opens into the the duodenum at a minor opening 2 cm medial and above the ampulla of Vater, BUT it usually disappears → Santorini duct.

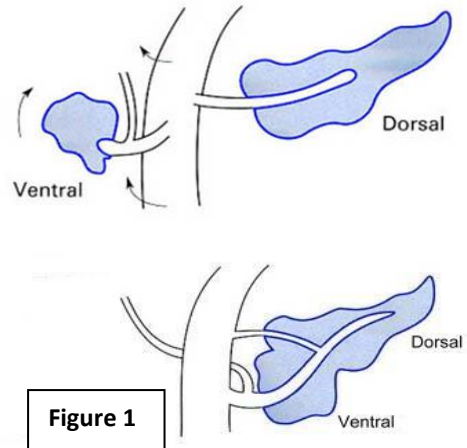


Figure 1

## ❖ Anatomy:

The pancreas is a J-shaped structure that weights approximately 85 g with a usual length of 12-15 cm and runs in an oblique transverse line [Figure 2].

- **Site:**  
 Retroperitoneal structure **at the level of L1-L2**, lies posterior to the stomach, transverse mesocolon and lesser omentum and is covered anteriorly with the visceral peritoneum.

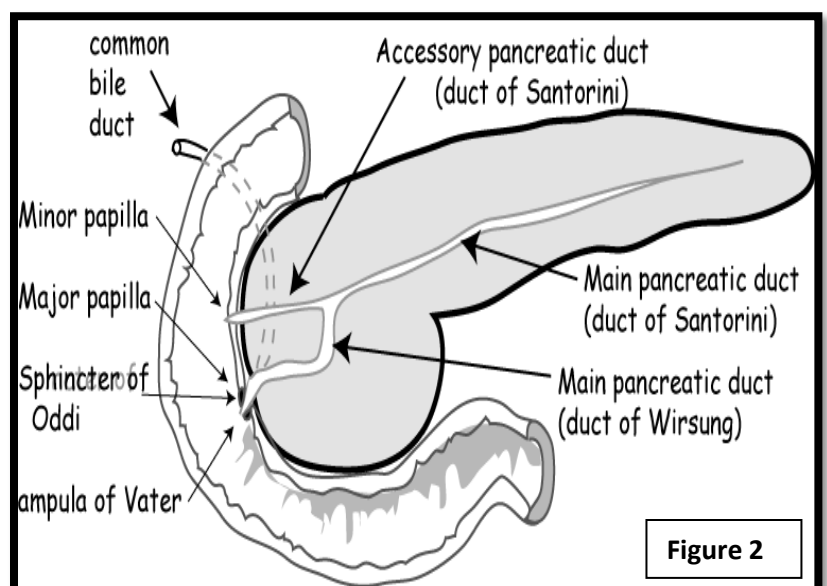
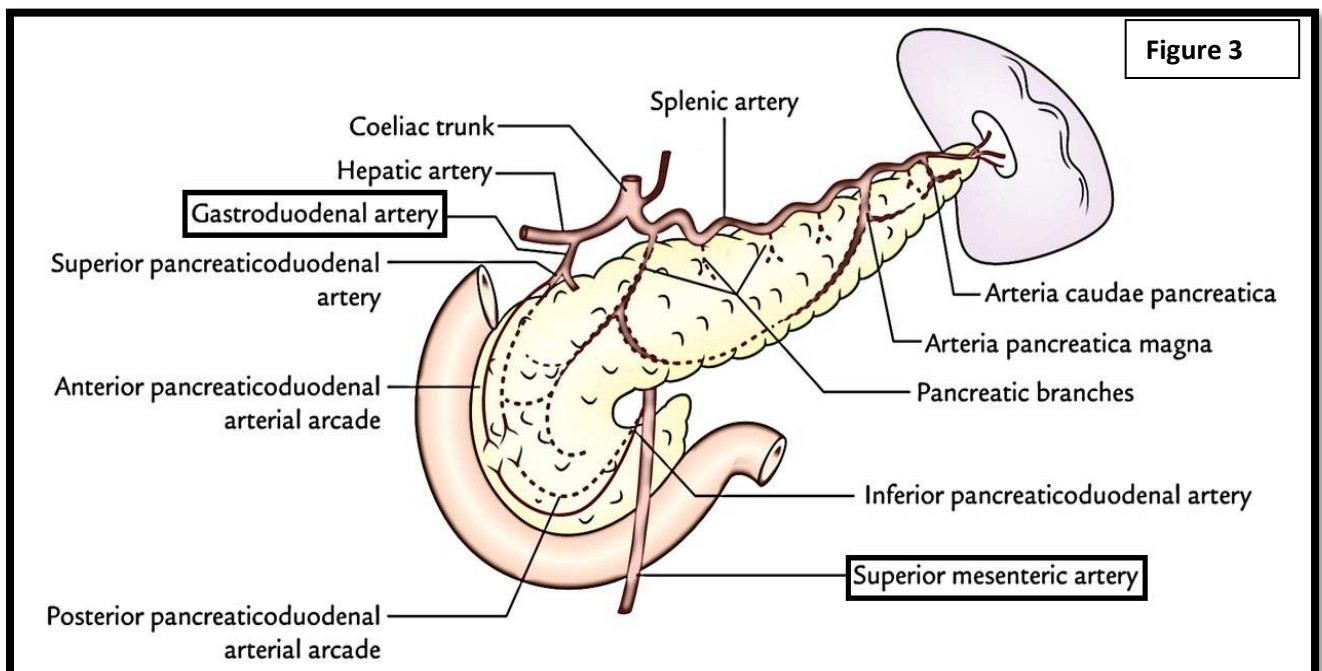


Figure 2

➤ Structures [Figure 2] and relations [Figure 3]:

1. Head
  - Bounded superiorly by the porta hepatus (bile duct, portal vein and proper hepatic artery) and by the pancreaticoduodenal artery.
  - The common bile duct runs superior then posterior and **partially within the head of the pancreas.**
2. Uncinate process
  - Small portion of it lies posteriorly to the superior mesenteric vein.
3. Neck
  - Lies anterior to the SMV, which joins the splenic vein at the superior border of the pancreas to form the portal vein.
4. Body
  - Lies posterior to the stomach.
5. Tail
  - It has a close relation with the splenic hilum (tickles the spleen).



➤ Ducts:

1. Wirsung duct
2. Santorini duct (Small)

➤ Sphincter of oddi: smooth muscles surrounding the ampulla of Vater.

➤ Blood Supply:



Supplies the head.

- Celiac Trunk → gastroduodenal → Ant. Sup pancreaticoduodenal artery + Post. Sup. Pancreaticoduodenal artery.
- SMA → Ant. Inf. Pancreaticoduodenal artery + Post. Inf. Pancreaticoduodenal artery.

Supplies the neck, body and tail.

- Splenic artery → Dorsal pancreatic artery.

**Note: The venous drainage follows the arterial supply.**

Nerve Supply:

- **Sympathatic** : Pain sensation by the celiac plexus and the thoracic splanchnic nerves.
- **Parasympathatic**: for the glands (ducts) by the celiac branch of the vagus nerve.

❖ **Types of pancreatic cells: [Figure 4]**

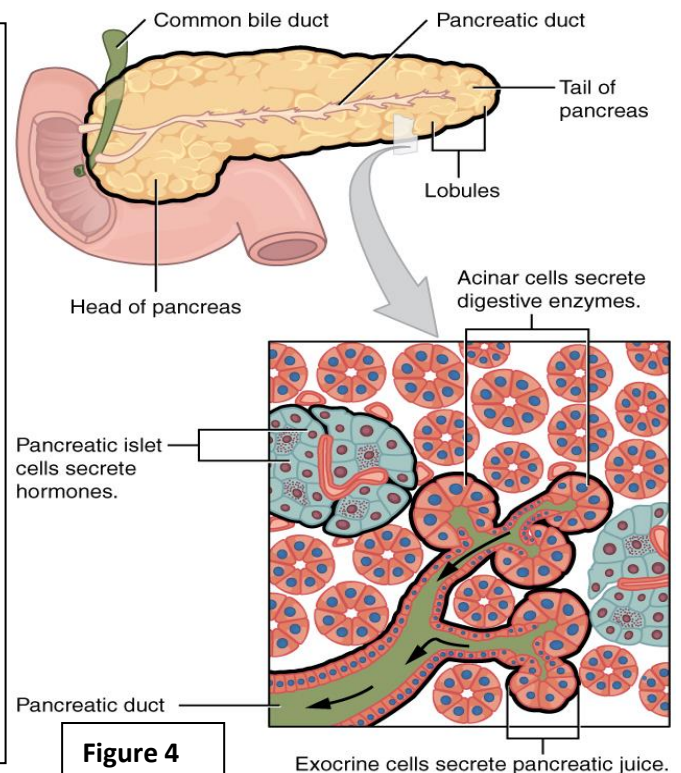
What is the pancreas made of?

QUICK REVISION

**The pancreas is composed of 85% exocrine tissue:** which is organized into lobules. The main pancreatic duct branches into interlobular and intralobular ducts, ductules and, finally, acini. The main duct is lined by columnar epithelium, which becomes cuboidal in the ductules. Acinar cells are clumped around a central lumen, which communicates with the duct system.

**And 2% endocrine tissue:** which is made of Clusters of endocrine cells, known as islets of Langerhans, are distributed throughout the pancreas.

**The rest is extracellular matrix and blood vessels.**



**Figure 4**

1. **Endocrine cells** (islets of langerhans):

- $\alpha$  cells : Secrete glucagon which promotes the conversion of the hepatic glycogen → increases glucose level.
- $\beta$  cells: Secrete Insulin which promotes glucose transport into the cells → decreases glucose level.

- D cells: secrete Somatostatin which inhibits the release of gastric hormones and gastric acid.
  - PP cells: Secrete polypeptides and vasoactive intestinal peptide (VIP).
2. **Exocrine cells** (Acinar, centroacinar and ductal cells):

- Acinar cells: Secrete enzymes {Trypsin, Chemotrypsin, Amylase, Lipase, Carboxypeptidase}.
- Centroacinar and ductal cells: Secrete water and electrolytes ( $\text{Na}^{+2}$ ,  $\text{K}^{+}$ ,  $\text{HCO}_3^{-}$ ,  $\text{Cl}^{-}$ ) in response to **Secretin** stimulation.

The pancreatic enzymes (except for lipase and amylase) are secreted in an inactive form (Zymogens) until they're activated by **enterokinase** in the duodenum

**Secretin** is secreted from the S cells in the duodenum; it is the most potent endogenous stimulant of bicarbonate secretion.

❖ **Main Investigations:**

- **Estimation of pancreatic enzymes in body fluids:** When the pancreas is damaged, enzymes such as amylase, lipase, trypsin, elastase and chymotrypsin are released into the serum.
- **Pancreatic function tests:** Pancreatic exocrine function can be assessed by directly measuring pancreatic secretion in response to a standardized stimulus.
- **Imaging investigations:**
  - **Ultrasound:** It may also define the presence or absence of a mass in the pancreas. However, obesity and overlying bowel gas often make interpretation of the pancreas itself unsatisfactory.
  - **CT scan:** A specific pancreatic protocol should be followed:
    1. An initial unenhanced CT scan is essential to determine the presence of calcification within the pancreas and gall bladder.
    2. Following rapid injection of intravenous contrast, scanning is performed in the arterial and venous phases.
  - **Endoscopic retrograde cholangiopancreatography (ERCP) [Figure 5]:** ERCP is performed using a side-viewing fiberoptic duodenoscope. The ampulla of Vater is intubated, and contrast is injected into the biliary

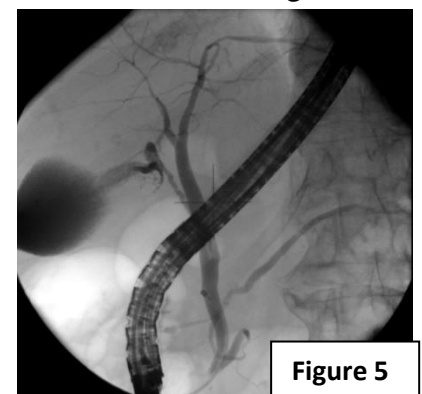
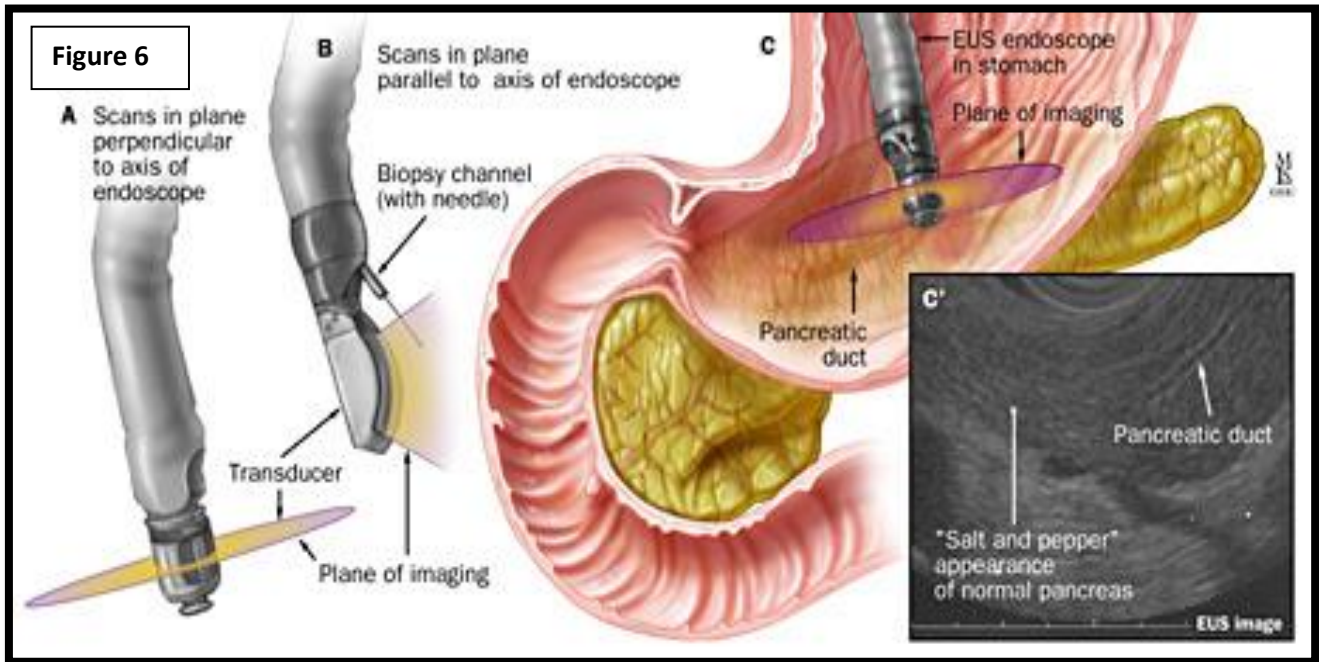


Figure 5

and pancreatic ducts to display the anatomy radiologically.

- **Endoscopic ultrasound (EUS) [Figure 6]:** when the endoscope is in the lumen of the stomach or duodenum, the pancreas and its surrounding vasculature and lymph nodes can be assessed. This is particularly useful in identifying small tumors that may not show up well on CT or MRI.



# Congenital Anomalies Of The Pancreas

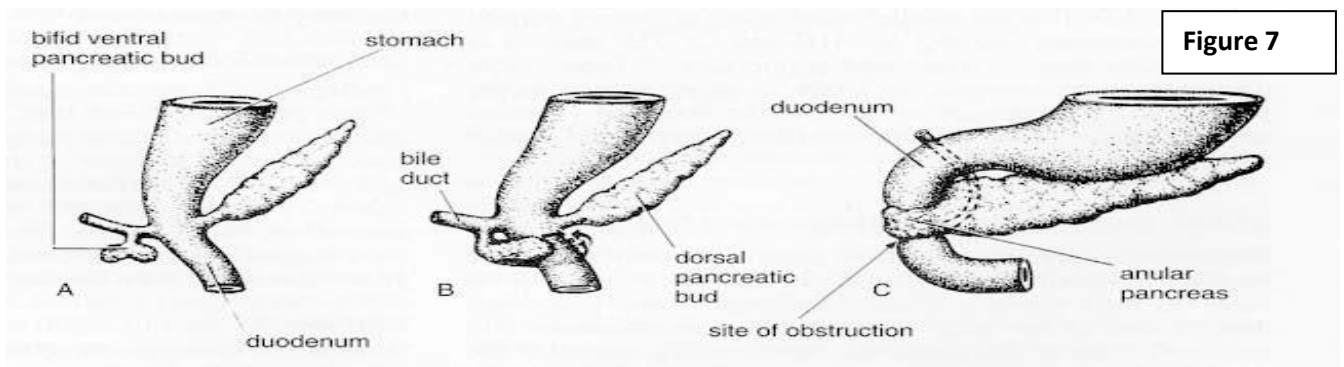
## INTRODUCTION

### ❖ Pancreatic divisum: → the most common

- Embryological failure of the two pancreatic ducts to fuse (the dorsal and ventral).
- The dorsal pancreatic duct becomes the main pancreatic duct and drains most of the pancreas through the minor or accessory papilla.

### ❖ Annular Pancreas: [Figure 7]

- During rotation and migration of the pancreatic tissue, some tissue may be left around the duodenum.
- Although it's congenital → 50% presents in adulthood.



### ❖ Heterotropic Pancreas:

- Islands of ectopic pancreatic tissue can be found in the submucosa in parts of the stomach, duodenum or small intestine (including Meckel's diverticulum), the gall bladder, in the hilum of the spleen and within the liver.

## CLINICAL FEATURES

### ❖ Pancreatic divisum :

- A large volume of secretions flowing through a narrow papilla probably leads to incomplete drainage, which may then cause obstructive pain or pancreatitis [in patients with idiopathic recurrent pancreatitis, pancreatic divisum should be excluded].

### ❖ Annular Pancreas:

- Duodenal obstruction typically causes vomiting in neonates.
- The disease may occur in later life as one of the causes of pancreatitis.



## DIAGNOSIS

### ❖ Pancreatic divisum :

- ERCP and MRCP.

### ❖ Annular Pancreas:

- Abdominal ultrasound and CT scan.



## TREATMENT

### ❖ Pancreatic divisum :

- Endoscopic sphincterotomy and stenting of the minor papilla may relieve the symptoms.
- Surgical intervention can take the form of sphincteroplasty, pancreatojejunostomy or even resection of the pancreatic head.

### ❖ Annular Pancreas:

- Duodenojejunal bypass, we need to bypass the obstruction.

**We do not do resection of the pancreatic tissue because it's almost**

#### READ:

We can't go through congenital anomalies of the pancreas without quickly discussing **Cystic Fibrosis**:

- It's a genetic disease affecting **CFTR gene**, and diagnosed by **increased Cl<sup>-</sup> and Ca<sup>+2</sup> levels in the sweat** (>60mmol/L).
- Cystic fibrosis is a multisystem disorder of exocrine glands that affects the lungs, intestines, pancreas and liver. Most of the organ damage is due to blockage of narrow passages by thickened secretions.
- **Chronic pulmonary disease** arises from plugging of bronchi and bronchioles and at birth. The meconium may set in a sticky mass and produce **intestinal obstruction** (meconium ileus).
- Secretions precipitate in the lumen of the pancreatic duct causing blockage, which results in duct ectasia and fatty replacement of exocrine acinar tissue. Pancreatic **exocrine insufficiency** leads to **fat malabsorption**. Endocrine insufficiency may also take place.
- Treatment is aimed at control of the secondary consequences of the disease; antibiotics for pulmonary infection and pancreatic enzymes oral supplements (Creon).

# Acute Pancreatitis

## INTRODUCTION

**Definition:** it's a reversible inflammation of the pancreas as a result of autodigestion by its own enzymes.

## ETIOLOGY

Remember its causes as **I GET SMASHED**:

Idiopathic

Gallstones

Ethanol (alcohol)

Trauma (usually a penetrating one)

Steroids (it could happen from the first exposure)

Mumps

Autoimmune disease (ex: polyarteritis nodosa [PAN])

Scorpion bite (Rare)

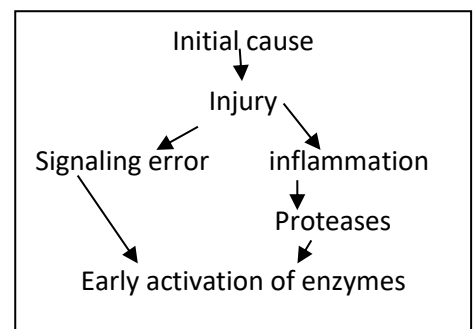
Hyperlipidemia/ Hypercalcemia

ERCP [endoscopic retrograde cholangio-pancreatography] → Iatrogenic

Drugs (diuretics, Isoniazid {INH}, reverse transcriptase inhibitors and Metronidazole).

## PATHOPHYSIOLOGY

- An initial cause causes injury to the pancreatic ductal cells which results in cell membrane trafficking problem (signaling error) that causes the early activation of pancreatic enzymes and thus, destruction of the pancreatic tissue. Also cell



injury causes the release of activated neutrophils which produces proteolytic enzymes and activation of zymogens.

**Remember that:** the inflammatory process includes the production of inflammatory mediators from the macrophages (IL-6, IL-8, TNF $\alpha$ ) which act locally (local inflammation) and systematically (SIRS  $\rightarrow$  hemodynamic instability).

- Cells injury may take place as a result of any cause the was already mentioned (I GET SMASHED), the most common causes is an obstruction by a small **gallbladder stone**, and **chronic alcohol abuse** that causes cell injury by its direct toxicity and alteration of the pancreatic secretion resulting in an actual obstruction. Among patsients who undergo **ERCP**, 1-3% develop pancreatitis as a consequence of duct distruption and the reflux of duodenal enzymes(enterokinase) to the pancreas. **Idiopathic** pancreatitis should not exceed 20% and it may be caused by biliary microlithiasis (stones that are not found) or genes effect which are not yet detected.



## CLINICAL FEATURES

- **Symptoms:**
  1. **Pain:** rapid onset, epigastric pain radiating to the back, progressive and reaching maximum intensity within minutes, continuous persisting hours or days, increases when lying supine and decreases when leaning forward refractory to analgesia.
  2. **Nausea and vomiting.**
  3. **Fever**
- **Signs:**
  1. **Epigastric tenderness**
  2. **Diffuse abdominal tenderness**
  3. **Decrease in bowel sounds (Adynamic ileus)**
  4. **Abdominal distention (due to ileus)**
  5. **Fever**
  6. **Dehydration and shock (due to fluid sequestration)**
  7. **Signs of hemorrhagic pancreatitis (if damage to the blood vessels caused retroperitoneal hemorrhage):**
    - **Cullen's sign** [Umbilical hemoperitoneum]
    - **Grey-Turner sign** [Flank hemoperitoneum]

### Deferential diagnosis (DDX):

1. **Biliary colic/Cholecystitis.**
2. **Gastritis/Peptic ulcer disease (PUD).**
3. **Perforated viscus.**
4. **Small bowel obstruction (SBO).**
5. **Mesenteric ischemia/infarction.**
6. **Inferior MI/ inferior lobe pneumonia.**
7. **Ruptured abdominal aortic aneurysm (AAA).**

➤ **Fox's sign** [bluish discoloration of the inguinal ligament]

- **Complications:**

- **Early:**

1. **Shock and Renal failure**
2. **Pancreatic ascites and pleural effusion**
3. **ARDS and Sepsis**
4. **Severe HYPOcalcemia** (due to fat saponification, in which fat necrotic tissue binds to calcium)
5. **Superior mesenteric/ Splenic/Portal vein rupture or thrombosis.**

Remember that: Inflammation and hemodynamic instability cause a systemic effect in all over the body (Lungs, kidneys ...).

**Note:** Splenic vein thrombosis is a complication of both acute and chronic pancreatitis.

- **Late**

1. **Pancreatic necrosis**
2. **Pancreatic Abscess**
3. **Hemorrhagic pancreatitis**
4. **Infection**
5. **Fistula**
6. **Pseudocyst**
7. **Diabetes.**

Most of these late complications will be explained as separate conditions as we move forward.



## DIAGNOSIS

- **History and Physical exam** (as previously mentioned in the signs and symptoms).

- **Labs:**

- **Amylase and lipase levels:** this is the typical way to diagnose pancreatitis, amylase level increases then decreases after a few days (So if the patient presented after a few days and amylase level where normal, check for lipase.)

**Amylase is more sensitive.**

**Lipase is more specific.**

The increase in amylase level is not proportional to the severity of the pancreatitis.

- **CBC** (increase in WBC : 10,000-30,000)

- **LFT**

- If Alkaline phosphatase was high → think biliary stones.
- If AST > ALT → Think alcohol.



➤ You should also ask for **Ca<sup>2+</sup>** and **lipid** levels.

• **Imaging:**

➤ **Abdominal X-ray (AXR):**

- Gallstones (only 10% are radiopaque)
- Sentinal loop: Air-filled small bowel in LUQ. → m.c sign on X-ray.
- Colon cutoff: Abrupt ending of transverse colon.

**Sentinal loop and colon cutoff** result from localized paralysis of the small and large intestines respectively which resulted from a nearby inflammation.

➤ **RUQ ultrasound (U/S):**

- Swollen pancreas (collection of pus “phlegum” and fluid) may be seen.
- Gallstones or dilated biliary duct may be detected.
- Pseudocysts and ascites can be detected in severe cases.

Ultra sound has a major limitation in that it cannot be performed when excessive bowel gas is present, as occurs with an ileus.

➤ **CT scan:**

- It's not necessary for all patients, it's used to determine prognosis.
- It should be done in severe acute cases to diagnose necrotizing pancreatitis.
- It's used when a localized complication is suspected (Fluid collection or pseudocyst).

**KEEP IN MIND:**

Pancreatic necrosis has two parts:

**Parenchymal** liquafactive necrosis and **fat** necrosis.

➤ **EUS and MRCP:**

- It's not widely available.
- Can detect stones in the CBD along with assessing the pancreatic parenchyma.

➤ **ERCP:**

- Is not routinely indicated for the evaluation of patients during an attack of acute pancreatitis. It has three indications:
  1. Patients with jaundice, suspected biliary pancreatitis, and possible cholangitis who are not clinically improving by 24 hours after admission should undergo endoscopic sphincterotomy and stone extraction.
  2. Patients with no identifiable cause to rule out occult common bile duct stones, strictures, or neoplasms.
  3. Suspected pancreatic ductal disruption, such as with traumatic pancreatitis.

- **Assessing severity:**

- Skin findings:

- Most common finding is erythema of flanks (as a result of focal fat necrosis).
- Cullen's sign, Grey-Turner's sign and Fox's sign.

- CT severity index (CTSI):

- (A) → Normal.
- (B) → Enlargement.
- (C) → Peripancreatic inflammation.
- (D) → Single peripancreatic fluid collection.
- (E) → Multiple peripancreatic fluid collection.

- Severity scoring system:

- **Ranson's criteria:** [not specific nor sensitive]

**\*\*Within 24 hours (GA LAW): [Point for each]**

**Glu >200 mg, Age >55, LDH >350 U/L, AST >250 U/L, WBC >16,000**

**\*\* After 48 hours (C HOBBS): [Point for each]**

**Ca<sup>+2</sup> <8mg/dl, Hct decreased > 10%, O<sub>2</sub> (Arterial PO<sub>2</sub>) < 60mmHg, Base deficit >4meq/L, BUN increased > 5mg/dl, Sequestered fluid >6 L**

**Mortality risks:**

- Point/s → risk
- 0-2 → 1%
- 3-4 → 16%
- 5-6 → 40%
- 7-8 → 100%

- **APACHE II** [good specificity and sensitivity]:

Needs a calculator → If  $\geq 8$  → SEVERE

- **BISAP:** it can be done on bedside with No need for a calculator as APACHE II. [Point for each]:

1) BUN >25    2) Impaired mental status    3) SIRS

4) Age >60    5) pleural effusion.

**Mortality risks:**

- Point/s → risk
- 0-2 → <2%
- 3-5 → >15 %



## TREATMENT

- **Conservative management:** (90% of cases resolve spontaneously)

- NPO
- NG suction may be needed.
- IV hydration
- Analgesia and antiemetic are the only drugs needed, though Somatostatin analogues may help in

- Broad spectrum antibiotics are used ONLY if infection is established

**Remember that: Pancreatitis is a sterile inflammation unless complicated by infection**

- PO2 monitoring.
- **Cholecystectomy** should be required in patients with gallstone pancreatitis.
- **Percutaneous aspiration** of fluid or necrotic collection guided by CT or EUS need to be done only if it has a pressure effect or if complicated with infection (or suspicion of infection).
- **Resection** in acute pancreatitis is very dangerous, but removing the necrotic tissue may be required in patients with deteriorating sepsis. (The surgery has a high mortality rate).

**Once pancreatic necrosis with infection is diagnosed, CT guided aspiration should be tried before resection by surgery is done.**

# Biliary Pancreatitis



## INTRODUCTION

**Definition:** Acute pancreatitis from a gallstone in or passing through the ampulla of Vater and it's the most common cause for acute relapsing pancreatitis.

The stones which cause biliary pancreatitis are small stones (2mm), because the pancreatic duct is small in diameter (1-3.5 mm).



## DIAGNOSIS

- Acute pancreatitis with cholelithiasis or choledolithiasis + NO OTHER CAUSE for pancreatitis (alcohol abuse).
- U/S to look for gallstones.
- CT to look at the pancreatic changes if the symptoms were severe.
- MRCP to look for small stones obstructing the pancreatic duct.



## TREATMENT

- Conservative management until the patient is stable then early interval cholecystectomy (in the same admission) should be done with intraop cholangiogram (IOC) which is needed to rule out persistent choledocholithiasis.
- ERCP should be done if the patient is not fit to surgery, with cholangitis took place or in case of refractory choledocholithiasis to do sphincterectomy with stone extraction.

Early interval cholecystectomy is important to prevent relapsing episodes of acute pancreatitis.

# Pancreatic Necrosis



## INTRODUCTION

Definition: Dead pancreatic tissue usually following acute pancreatitis, it has two components; parenchymal liquefactive necrosis plus fat necrosis.



## DIAGNOSIS

- Abdominal CT with contrast. {Dead pancreatic tissue does **NOT** take up the IV contrast and is **NOT** enhanced on CT scan “does not light up”}



## TREATMENT

- If sterile → Medical management.
- If suspicious of infection → CT-guided FNA.
- If hypotension/ sepsis → Operative debridement.

# Pancreatic Abscess



## INTRODUCTION

Definition: Infected peripancreatic purulent fluid collection.

### Pathogens:

- Gram –ve : (m.c): E-coli, KLebsiella and pseudomonas.
- Gram +ve: S.aureus
- Fungal: Candida



## CLINICAL FEATURES

- Fever.
- Unresolving pancreatitis.
- Epigasrtic mass



## DIAGNOSIS

- **Imaging:** Abdominal CT with needle aspiration → Send to gram stain/ culture.
- **Labs:** Gram stain / culture for bacteria.



## TREATMENT

- **Medical:** Antibiotics with percutaneous drain placement.
- **Surgical:** Operative debridement and placement of drains → maybe needed in very rare situations.

# Hemorrhagic Pancreatitis



## INTRODUCTION

**Definition:** Bleeding into the parenchyma and retroperitoneal structures with extensive pancreatic NECROSIS.

So: if the necrosis was severe to the extent of causing damage to the blood vessels, hemorrhagic pancreatitis takes place.



## CLINICAL FEATURES

- Abdominal pain and tenderness.
- Shock/ ARDS.
- Cullen's sign.
- Grey-Turner's sign.
- Fox's sign.



## DIAGNOSIS

- **Labs:**
  - Decreased Hct.
  - high amylase and lipase levels with low Ca<sup>2+</sup> level (as in acute pancreatitis).

- **Imaging:**
  - CT scan with contrast.



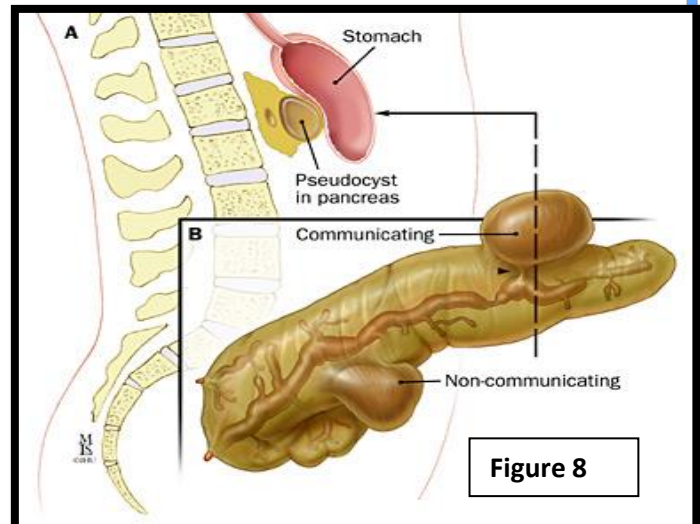
## TREATMENT

- ❖ Treatment involves embolization of the affected vessel or surgery.
-

# Pancreatic Pseudocyst

## INTRODUCTION

- ❖ Definition:
  - Encapsulated collection of pancreatic fluid in the lesser sac.
  - Pseudocyst's wall consists only of the inflammatory response of the neighboring organs (granulation tissue or fibrosis) and not epithelium (That's why it's called PSEUDOcyst).
  - Types [Figure 8]: Communicating (more common) and non-communicating.



## ETIOLOGY

- ❖ Risk factors:
  - Acute pancreatitis → most common cause.
  - Chronic pancreatitis.
  - Pancreatic trauma.

## PATHOPHYSIOLOGY

- Pseudocyst forms as a result of fibrosis, thickening and organization of the organs bordering the collection.
- It's not lined by epithelium.
- Formation of a pseudocyst requires 4 weeks or more from the onset of acute pancreatitis in order to become mature.
- Small pseudocysts may resolve; large pseudocysts with mature organized walls generally do not resolve.
- They are often single but, occasionally, patients will develop multiple pseudocysts.

**By definition, a fluid collection appearing in the first 4 weeks after the onset of pancreatitis is an acute fluid collection; after 4 weeks, it becomes an acute pseudocyst.**

**Pseudocysts that are thick-walled or large (over 6 cm in diameter), have lasted for a long time (over 12 weeks) or have arisen in the context of chronic pancreatitis are less likely to resolve spontaneously.**





## CLINICAL FEATURES

- **Symptoms:**

1. Recurrent or persistent upper abdominal pain.
2. Nausea and vomiting.
3. Mild fever.
4. Weight loss.

Suspect it in a patient with acute pancreatitis with unresolved pain.

- **Signs:**

1. Palpable epigastric mass
2. Tender epigastrium.
3. Ileus.

DDX: Cystadenoma and cystadenocarcinoma

- **Complications:**

- Infection in 5-20% of the cases.
- Enteric fistula can occur spontaneously and usually results in resolution of the cyst.
- Bleeding into the cyst resulting from erosion into surrounding visceral vessels.
- Pancreatic ascites.
- Obstruction: gastric outlet, duodenal or biliary obstruction.
- Rupture occurs in fewer than 3% of cases.



## DIAGNOSIS

- **History and physical examination** (as mentioned earlier).

- **Labs:**

- CBC (leukocytosis).
- Increased Amylase and Lipase levels.
- Increased LFT (if biliary obstruction took place).
- Cystic fluid analysis: low CEA, high amylase level and cytology reveals inflammatory cells in pseudocyst fluid.

- **Imaging:**

- Ultrasound: Fluid-filled mass
- CT scan: It's the diagnostic imaging of choice; it gives information about the wall thickness, calcifications and number of pseudocysts which affect the prognosis.

- **ERCP**: Radiopaque contrast material fills the cyst if communicating (to differentiate between communicating and non-communicating) as well as it allows for the determination of pancreatic duct abnormalities
- **EUS**: it's important if sample is needed, in order to differentiate it neoplasm if there was suspicion.

If there's no access to EUS, FNA is acceptable (Only aspiration without insertion of a drain).



## TREATMENT

Therapeutic interventions are advised if the pseudocyst doesn't resolve spontaneously within 6 weeks. You wait 6 weeks for the pseudocyst's wall becomes mature and firm enough to hold sutures. Approximately 50% resolve within 6 weeks.

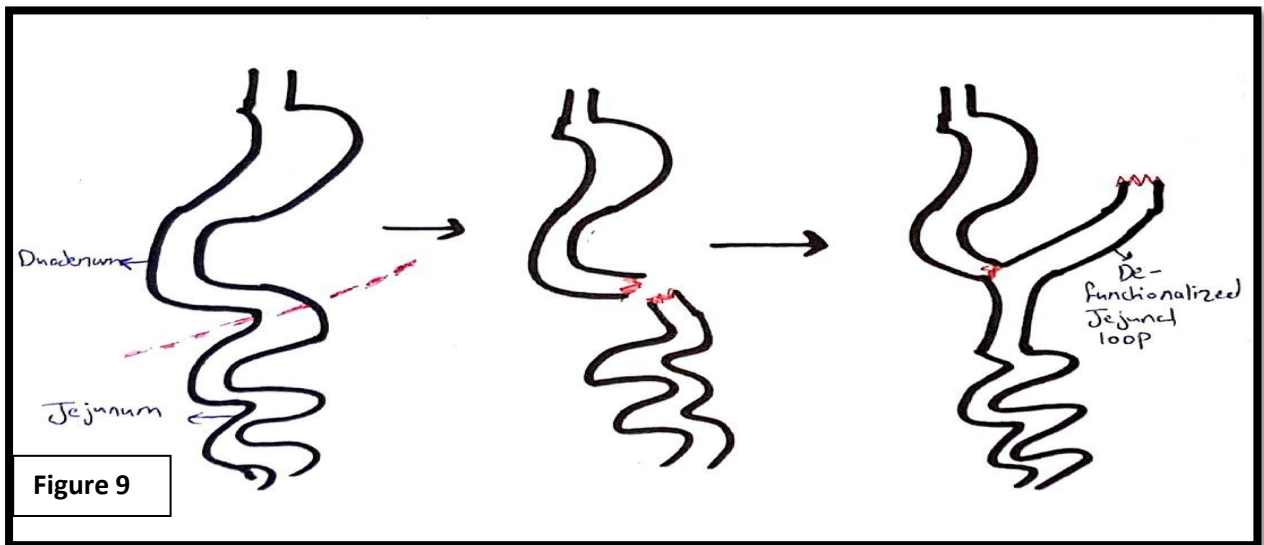
### Indications for treatment:

1. Size > 5cm (because it has higher chance of complications and is less likely to resolve spontaneously).
2. Calcified cyst wall.
3. Thick wall cyst.

- **Percutaneous drainage under radiological guidance**: should be avoided. It carries a very high likelihood of recurrence. Moreover, it is not advisable unless one is absolutely certain that the cyst is not neoplastic and that it has no communication with the pancreatic duct (or else a pancreaticocutaneous fistula will develop).
- **Endoscopic drainage**: usually involves puncture of the cyst through the stomach or duodenal wall under EUS guidance, and placement of a tube drain with one end in the cyst cavity and the other end in the gastric lumen.
- **ERCP and placement of a pancreatic stent across the ampulla (Transpapillary stent)**: It may help to drain a pseudocyst that is in communication with the duct.
- **Operative drainage**:
  - **Internal drainage**: If the the cyst is adherent to the stomach, cystogastrostomy (drainage into the stomach) is done. If the cyst is adherent to the duodenum, cystoduodenostomy (drainage into the duodenom) is done. Drainage into

This is conventionally done through an open incision, but laparoscopic cystgastrostomy is also feasible.

a defunctionalized (Roux-en-Y) loop jejunum [Figure 9]: If the cyst isn't adherent to any organ.



- External drainage: Used if the pseudocyst is not found to be mature and the pseudocyst wall is not safe. The external drainage results in a pancreatic fistula, which usually heals with continued TPN.
- Excision: rare; however, may be indicated if the pseudocyst is small and is located distally in the tail of the pancreas. Resection of the tail of the pancreas maybe done.

# Chronic Pancreatitis

## INTRODUCTION

- **Definition:** Persistent inflammation of the pancreas with **IRREVERSIBLE** histological changes (fibrosis, atrophy or calcification), recurrent abdominal pain and loss of exocrine & endocrine function.
- **Has two subtypes:** 1) Chronic calcific pancreatitis 2) chronic obstructive pancreatitis.

## ETIOLOGY

- **Alcohol** (chronic >10 years) → 60-70% {most common in developed countries}
- **Idiopathic** → 30%
- **Obstructive** → Pancreas divisum, sphincter of oddi dysfunction/mass.
- **Metabolic** → Malnutrition, Hyperlipidemia and hypercalcemia (hyperparathyroidism).
- **Familial.**
- **Trauma.**
- **Iatrogenic.**
- **Gallstones.**

## PATHOPHYSIOLOGY

Can be summarized in 4 steps:

1. Early changes: plugging of small ducts with proteins and eosinophils.
2. With disease progression: multiple calcification and multiple areas of ductal dilatations.
3. End stage of ductal dilatations → Chain of lakes appearance [Figure 10].

**Note:** Common bile duct obstruction and duodenal obstruction: can occur in advanced cases as a result of inflammation in surrounding areas.

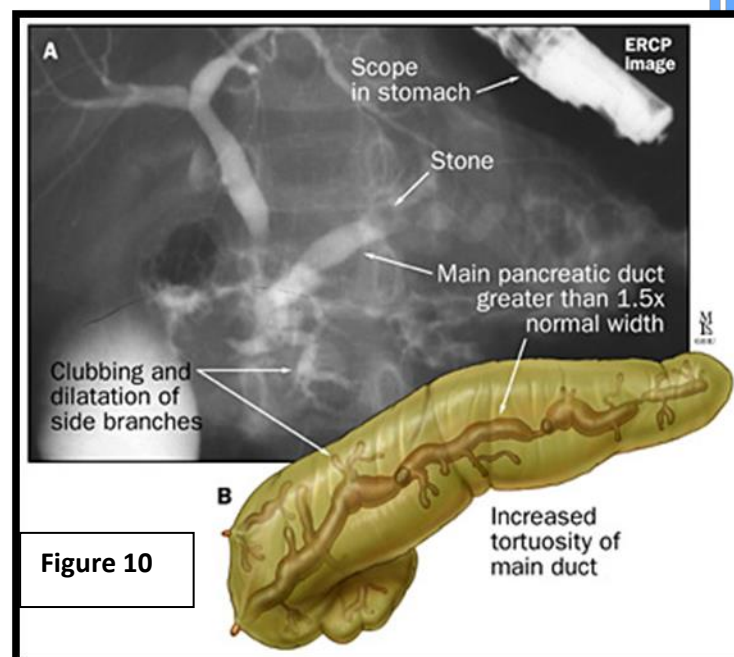


Figure 10

- **Symptoms**

- Epigastric pain: Unrelenting (continuous, doesn't stop) and radiating to the back.
- Weight loss.
- Steatorrhea → Stool floats in the water.

The site of pain depends to some extent on the main focus of the disease. (It's not always epigastric).

Malabsorption

- **Signs:**

- Signs of exocrine insufficiency; malnutrition, steatorrhea (fat malabsorption "Lipase is insufficient")

- **Complications:**

- Severe, prolonged and refractory pain.
- Insulin-dependent DM.
- Steatorrhea and malnutrition especially lipid soluble vitamins deficiencies (K, E, D, A).
- Splenic vein thrombosis → short gastric veins hypertension → gastric varices (in the fundus).
- Biliary obstruction (from pancreatic inflammation and edema or from stricture of the intrapancreatic CBD)
- Duodenal obstruction.
- Pancreaticoduodenal fistulas.
- Pancreatic pseudocyst → becomes an abscess if infected.
- Splenic artery pseudoaneurysm [differs from a true aneurysm in that its wall does not contain the components of an artery but instead consists of fibrous tissue].
- Pancreatic CA (if > 20 years) → 2-4 % risk.



## DIAGNOSIS

- **Labs:**

- Amylase and Lipase.
- Pancreatic secretin stimulation test: high sensitivity and specificity.
- A 72-hour fecal collection for estimation of daily fecal fat (it doesn't play a huge role in the definitive diagnosis for chronic pancreatitis).
- Glucose tolerance test.

Amylase and Lipase are only elevated in the beginning of the disease after that their level will be normal, as a result of extensive pancreatic tissue loss "Burred-out pancreas".

- **Imaging:**

- Abdominal X-ray → Pancreatic calcification may be seen.
- CT and MRI show the outline of the pancreas and the main area of the damage, calcification, masses or pseudocysts may be seen.
- MRCP and ERCP will identify the presence of biliary obstruction and the state of the pancreatic duct (chain of lakes, pseudocysts or stenosis) but as it 3-7% risk of causing acute pancreatitis.
- EUS has come to play a more important role in the diagnosis of biliary obstruction, but it needs a very skilled doctor.



## TREATMENT

- **Life style changes:**

- Stopping alcohol intake and avoiding smoking.
- Decreasing fat intake and adding medium chain triglyceride (MCT).

- **Medical:**

- Analgesia and endocrine supplements when needed.
- Exocrine replacement with pancreatic enzymes(Creon).
- Vitamins K, E, D and A supplements.
- Diabetes initially is responsive to good nutrition and dietary control; however, use of oral hypoglycemic agents or insulin therapy often is required.
- Tube thoracostomy or repeated paracentesis may be required for pancreatic pleural effusions or pancreatic ascites.

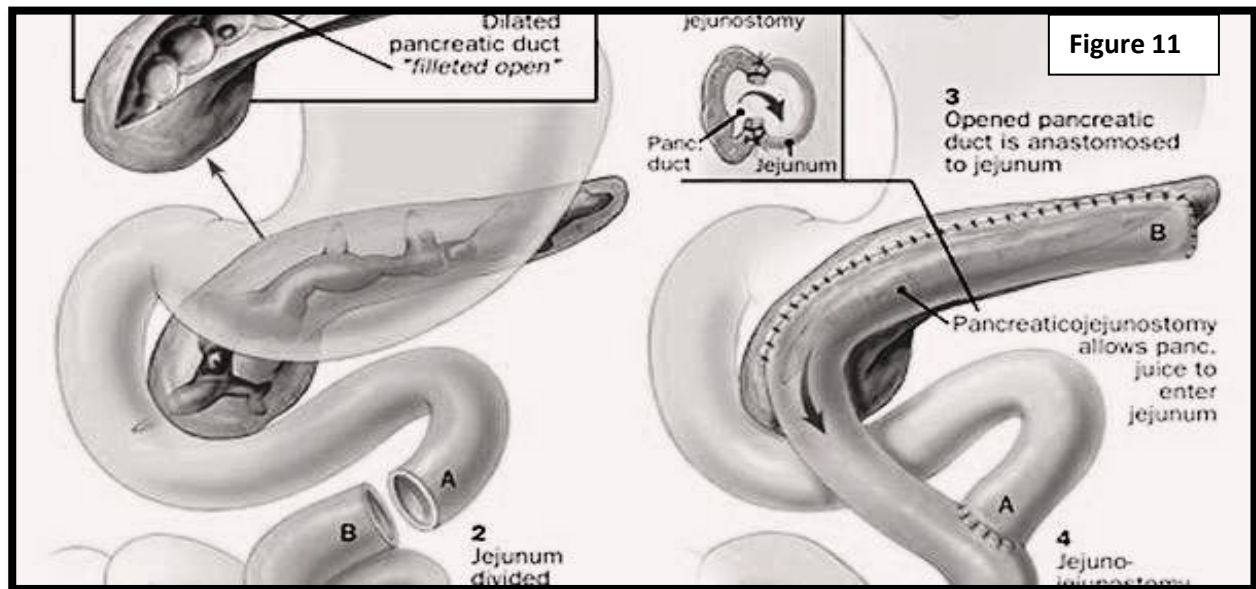
**Creon (pancrelipase):** is a combination of three enzymes: lipase, protease, and amylase.

- **Endoscopy:**

- Endoscopic sphincterotomy, stenting and stone retrieval have all been used with moderate success in the management of patients with ductal complications from chronic pancreatitis.
- Endoscopic celiac plexus block may improve symptoms in patients with severe pain.

- **Surgical:**

- **Puestow operation [Figure 11]** (longitudinal pancreaticojejunostomy): pancreatic duct must be dilated to do this surgery. After draining the



pancreatic duct it is anastomosed with a defunctionalized jejunal loop (Roux-en-y loop).

- **Frey procedure:** longitudinal pancreaticojejunostomy with the resection of the affected parts in the pancreatic head. It's considered better than Puestow operation because the proximal pancreatic duct is also cleared by extensive coring of the head of the gland.
- **The Beger procedure:** Duodenum-sparing pancreatic head resection, it has shown excellent long-term results.

Puestow has often failed because the pancreatic duct in the head of the gland was not drained adequately.

- **Pancreatectomy:**
  - **Pancreaticoduodenectomy (whipple):** is indicated in cases in which the pancreatitis involves the head of the pancreas, the pancreatic duct is of small diameter, or cancer cannot be ruled out in the head of the pancreas.
  - **Distal subtotal pancreatectomy:** used to treat a distal ductal obstruction.
  - **Total pancreatectomy:** is performed only as a last resort in patients whose previous operations have failed

# Pancreatic tumors (in general)

## INTRODUCTION

- Classified into **endocrine tumors** (from islets of langerhans) and **exocrine tumors**, only exocrine tumors will be discussed in this section.
- Majority of pancreatic tumors are **malignancies** arising from the **ductal** system.
- Exocrine tumors are classified into benign, borderline (intermediate), and malignant.

### ➤ Benign:

- Serous cystadenoma (15%)
- Mucinous cystadenoma (40%)
- Intraductal papillary mucinous adenoma (30%)
- Mature cyst teratoma

### ➤ Borderline

- Mucinous cystadenoma with moderate dysplasia.
- Intraductal papillary mucinous tumors.
- Solid pseudopapillary tumors.

### ➤ Malignant:

- Ductal adenocarcinoma
- Mucinous adenocarcinoma.
- Intraductal papillary mucinous tumors.

If they gain malignant characteristics.



## Read if you didn't understand half of the things you've just read:

- ❖ **Mature cell teratoma** (dermoid cyst) is a benign, well-differentiated, extremely rare germ cell neoplasm.
- ❖ **Solid pseudopapillary tumor** is a low-grade malignant neoplasm of the pancreas of papillary architecture with special histopathological (part-solid, part-cystic) features that typically affect young women.
- ❖ Cystic tumors of the pancreas may be serous or mucinous.
- ❖ **Serous cystadenomas** are typically found in older women, and are large aggregations of multiple small cysts, almost like bubblewrap. They are benign.
- ❖ **Mucinous tumors** have the potential for malignant transformation. They include mucinous cystic neoplasms (MCNs) and intraductal papillary mucinous neoplasms (IPMNs). MCNs are seen in perimenopausal women, show up as thick-walled cysts in the pancreatic body or tail and they can be confused with pseudocysts. IPMNs are more common in the pancreatic head and in older men.
- ❖ **Ductal adenocarcinoma** comprises 85% of total pancreatic tumors and they are solid tumors, characterized by neoplastic tubular glands within a markedly desmoplastic fibrous stroma.

\*\* Pancreatic adenocarcinoma will be discussed in details in a separate section.



## TREATMENT

- Serous cystadenoma should be resected if they cause symptoms, become large in size or is suspected to be mucinous.
- Mucinous cystadenoma should be resected because they have the potential to become malignant.
- Solid pseudopapillary tumors should also be resected.

**Mucinous= Malignant**

# Pancreatic Adenocarcinoma

## INTRODUCTION

- **Definition:** It is tumor arising from the pancreatic cells (majority of tumors arise from the ductal cells) and forming a granular-like shape.
- **Types:** Ductal adenocarcinoma (>80%), Cystadenocarcinoma and Acinar cell carcinoma.
- **Classified into:** periampullary tumors, Head of pancreas tumors (66%) and Body and tail tumors (33%)
- **Epidemiology:** it's the fourth leading cause of death in the US, and constitutes 2-3% of all cancers there [75% of the patients die within the first year after diagnosis].

Remember that: in order to name a tumor "adenocarcinoma", it should either originate from glandular cells or from any cells that form histological glandular appearance.

## ? ETIOLOGY

### Risk factors:

1. Male gender (males:females, 2:1).
2. Black gender (black:white, 2:1).
3. **Smoking (increases the chance by 3 times).**
4. Heavy alcohol intake.
5. Chronic pancreatitis (>20 years) especially in familial pancreatitis.
6. Diabetes.
7. Age (>60).
8. Diet [low fiber diet].
9. Familial history of cancer and FAP (familial adenomatous polyposis).

**Mutations in Pancreatic CA:** 10% familial genetic mutations (P53), 80-90% sporadic mutations (Kras, P53). Most of pancreatic CA patients have 3 or more mutated genes

**\*\*Pancreatic CA has precancerous stage (carcinoma in situ) named: Pancreatic intraepithelial neoplasia; it has grades (grade I, II and III) and can end up transforming into cancer. As it progresses it gains several mutations providing it with malignancy potentials.**



## CLINICAL FEATURES

### 1. Periapillary tumors:

- Tumors arising from the ampulla or from the distal common bile duct can present as a mass in the head of the pancreas, and constitute around a third of all tumors in that area.
- Have 4 types; from the ampulla itself, from the duodenum around the ampulla, from the terminal part of the common bile duct near the ampulla and from the head of the pancreas near the ampulla.
- Present as a triad:
  1. Obstructive jaundice (intermittent).
  2. Fluctuating in severity.
  3. Stool +ve occult blood test.

Patients with familial adenomatous polyposis (FAP) can present with multiple duodenal polyps. Malignant transformation in a duodenal polyp is a significant cause of mortality in these patients.

#### Why intermittent jaundice?

Due to central necrosis and sloughing of cells (thus relieving the obstruction).

### 2. Head of pancreas tumors:

Present as:

- Painless jaundice (as a result of CBD obstruction).
- Pruritis.
- Pale stool and dark urine.
- Weight loss and anorexia.
- Although the jaundice is commonly painless, epigastric discomfort with back pain may be present.
- Nausea and vomiting.
- Steatorrhea.
- Diabetes.
- Chronic pancreatitis may be seen due to pancreatic duct obstruction.

Pruritis results from the precipitation of **bile salts** in the subcutaneous fat. (Salts are water soluble).

#### Stool features:

1. **Pale** → obstructive jaundice
2. **Fatty (Steatorrhea)** → Malabsorption

An important sign in pancreatic head CA: **Courvoisier's sign** (in 25% of cases) → palpable painless gallbladder.

### 3. Body and tail tumors:

Present as:

- Weight loss and anorexia (90%).
- Migratory thrombophlebitis (**Trousseau's sign**) (10%): Blood clots felt as small lumps under the skin.
- Jaundice (<10%).
- Nausea and vomiting.

- Fatigue.
- Usually present with back pain due to invasion of neural endings.



## DIAGNOSIS

- **Labs:**

- Direct bilirubin and Alkaline phosphatase (increased due to biliary obstruction).
- Liver function tests.
- Pancreatic tumor markers (CA19-9, CEA) are used only to confirm diagnosis after imaging studies (neither sensitive nor specific).

Pancreatic tumor markers: 1) **CA 19-9** (carbohydrate antigen 19-9) 2) **CEA** (Carcinoembryonic antigen)

- **Imaging:**

- Ultrasound → reveals CBD dilatation in periampullary or pancreatic head tumor.
- CT scan with contrast → is the preferred test for diagnosis.
- Endoscopic ultrasound (EUS) is done:
  1. If CT fails to find a tumor, because it can detect very small tumors which CT cannot.
  2. If tissue biopsy is needed {tissue biopsy is needed if we diagnosed an unresectable tumor, or the tumor is resectable but the patient can't undergo a major surgery and we need to confirm the diagnosis before starting chemotherapy}.
  3. For staging after diagnosis with CT, as it does a better job in assessing the resectability.
- Diagnostic laparoscopy should be done to evaluate distant metastasis; because even after doing CT and EUS, their prediction for resectability is only 80%, so to avoid doing laparotomy to find unresectable tumor, we do diagnostic laparoscopy to increase the prediction to 98%.
- ERCP with stenting and cell biopsy is carried out if the patient is suffering from cholangitis and needs immediate intervention.

IF CT scan or EUS confirmed a resectable tumor, a diagnostic laparoscopy can be done, but tissue biopsy is **NOT** needed.

**\*\*The type of biopsy taken in the ERCP is brush biopsy in order not to cause perforation of the duct.**

- **Staging: It's important in order to determine the following management; it's done by CT, EUS and laparoscopy. It's classified as following:**

EUS does a better job than CT in assessing the resectability of the tumor. (lymph nodes or major vessels involvement).

Stage:	Tumor (T):	Lymph nodes involvement (N):	Metastasis
I A	T1: tumor < 2cm and is confined to the pancreas.	No: no regional lymph nodes involvement)	Mo: No distant mets.
I B	T2: tumor > 2cm and is confined to the pancreas.	No	Mo
II A	T3: tumor extending outside the pancreas without the involvement of the celiac axis or SMA	No	Mo
II B	T1, T2, T3	N1 (regional lymph nodes involvement).	Mo
III	T4 (tumor involves celiac axis or SMA)	No, N1	Mo
IV	Any T	Any N	M1 (distant mets)

- **Unresectable tumors are: (Stages III and IV)**

1. Liver metastasis.
2. Celiac or hepatic hilar lymph nodes involvement (outside of resection area)
3. Peritoneal implants.
4. Invasion of major vessels (Portal, celiac and SMA).

Tumors that:

- 1) Invade of duodenum and distal stomach.
- 2) Involve peripancreatic lymph nodes.

**Are resectable tumors**



## TREATMENT

- **SURGICAL (if resectable):**

- Periapillary or pancreatic head CA → Whipple procedure (pylorus-preserving).

Whipple procedure will be discussed in details in the next section.

1. Body or tail CA → Distal resection (Near-total pancreatectomy).

- **Palliative (if unresectable or if the patient can't undergo surgery):**

- For pain → Narcotics or celiac axis block (sometimes severe pain results from the involvement of nerves in retroperitoneal area).
- For jaundice → Pancreatic stent or choledochojejunostomy.
- For duodenal obstruction (in 20% of cases) → gastrojejunostomy.
- Palliative chemotherapy.

- **Prognosis:**

- Unresectable tumor → 5-year survival is < 5% (they live about 4-6 months).
  - After successful resection → 5-year survival 15-20% (they live about 12-19 months).
- 
-

# Whipple Procedure (Pancreaticoduodenectomy)

## INTRODUCTION

### ❖ Definition:

- Cholecystectomy.
- Truncal vagotomy.
- Antrectomy.
- **Pancreaticoduodenectomy** (removal of the head of pancreas + the duodenum).
- Choledochojejunostomy (anastomosis of the CBD to the jejunum).
- Gastrojejunostomy (anastomosis of the stomach to the jejunum).
- Pancreaticojejunostomy (anastomosis of the pancreas to the jejunum).

“**Pylorus-preserving whipple** (Figure 12a)”: **NO antrectomy** as in the conventional whipple (Figure 12b), involves anastomosis of small part of duodenum with the jejunum.

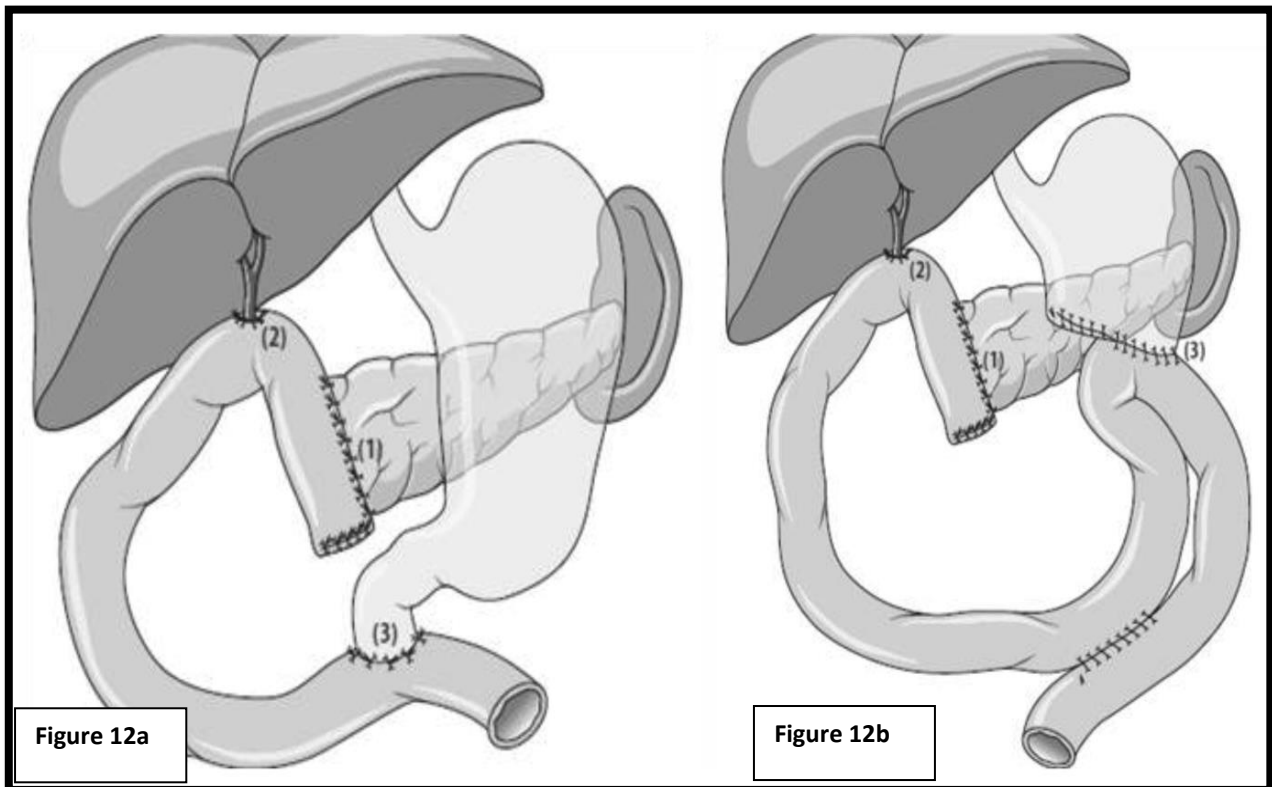


Figure 12a

Figure 12b

### ❖ Indications:

- Carcinoma (Periampullary):
  1. CA of the head of the pancreas.
  2. CA of the duodenum.
  3. CA of bile duct (distal part).
  4. CA of the ampulla of Vater.
- Benign cases (sometimes):
  1. In case of chronic pancreatitis (refractory to medical treatment).
  2. Benign tumors in the head of pancreas.

### ❖ Complications:

- Anastomotic leak (from the bile duct or pancreatic anastomosis).
- Delayed gastric emptying (if antrectomy is performed).
- Pancreatic/ biliary fistula.
- Wound infection.
- Postgastrectomy syndromes.
- Sepsis.
- Pancreatitis.

- ❖ **Mortality rate** associated with Whipple is <5% which is considered very high.
  - ❖ Why must the duodenum be removed if the head of the pancreas is resected? \* Because they share the same blood supply (Gastroduodenal artery).
- 
-



# Summary & past papers

## Summary

- ❖ The pancreas begins to develop from the duodenal endoderm, two buds form, the ventral bud (which forms wirsung duct) rotates with and fuses with the dorsal part which usually disappears but may form santorini duct).
- ❖ It's a **retroperitoneal structure** at the level of L1-L2, lies posterior to the stomach anterior to the CBD and the tail tickles the spleen.
- ❖ It's **supplied** by the superior and inferior pancreaticoduodenal artery and branches from the splenic artery.
- ❖ It's made of 85% **exocrine** and 2% **endocrine** cells, exocrine part is formed of acinar cells which secrete proenzymes which are activated by enterokinase in duodenum and centroacinar cells which secrete fluids and electrolytes in response to secretin.
- ❖ **Pancreatic divisum** is failure of the fusion of two ducts and may result in recurrent pancreatitis which is treated by stenting or surgery, **annular pancreas** is the left of pancreatic tissue around the duodenum resulting in intestinal obstruction and it's treated by bypass surgery.
- ❖ **Acute pancreatitis** is a reversible chemical inflammation resulting from an early activation of the exocrine pancreatic enzymes; it's **caused** most commonly by small gallstones obstructing the pancreatic duct. Other causes include (I GET SMASHED), **presents** as severe epigastric pain radiating to the back relieved by leaning forward, associated by nausea and vomiting, it's **diagnosed** by hx and P/E, amylase (which is more sensitive but doesn't correlates with the severity of inflammation) and lipase (which is more specific) level and U/S and the severity is assessed by Ranson criteria (plus others), it's **treated** conservatively with fluids and NPO and Abx only in case of bacterial infection. **Complications** include hemorrhagic pancreatitis, shock, hypocalcemia, ascites, pleural effusion, pancreatic abscess or necrosis, splenic vein thrombosis (which can be caused by acute or chronic pancreatitis) and pancreatic pseudocyst (which require 4 weeks to be formed).
- ❖ **Chronic pancreatitis** is persistent inflammation with irreversible histological changes, it has calcific and obstructive types, **caused** by alcohol, obstruction or idiopathic. **Presents** with unrelenting epigastric pain and exocrine insufficiency (weight loss and steatorrhea). It's **diagnosed** by amylase and lipase level which may not be elevated (worn out), secretin stimulation test, X-ray (shows calcifications) CT and MRI. It's **treated** by lifestyle modifications, medications (analgesia and enzymatic replacement), endoscopy (stenting) and surgery (bypass or resection). **Pancreatic tumors** can be benign or malignant, mucinous tumors have more potentials than serous tumors to transform into malignancy. Pancreatic adenocarcinoma originates from the ductal cells and it have **very bad prognosis** with smoking being the most important **risk factor** plus alcoholism, chronic pancreatitis and others. It may originate from the head or less commonly the tail or around the

ampulla, **symptoms** range from jaundice, obstructive symptoms, epigastric pain and weight loss. It's **diagnosed** by imaging like U/C, CT with contrast and MRI Plus labs (tumor marker CA19-9, elevated LFT,..) to confirm diagnosis, **staging** should be done to determine the management which either can be curative (surgery) if resectable or palliative (chemotherapy, bypass surgery,..).

### Past papers

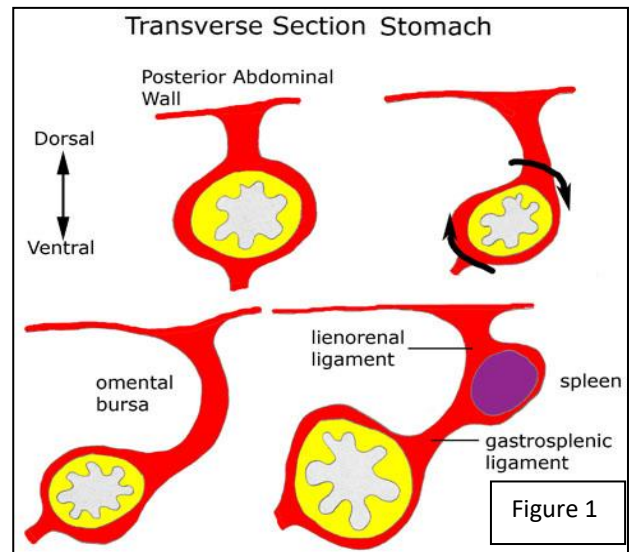
1. Which of the following is the most implicated risk factor in pancreatic cancer?
  - a. **Smoking**
  - b. Obesity
  - c. Alcoholism
2. Activation of trypsinogen as an initial step in acute pancreatitis is conducted by:
  - a. Lipase
  - b. Amylase
  - c. **Enteropeptidase**
  - d. Phospholipase
3. All may cause pancreatitis except:
  - a. **Hyperthyroidism**
  - b. Hyperparathyroidism
  - c. Hyperlipidemia.
  - d. Cardiopulmonary bypass machine
4. Patient with acute appendicitis, the least possible ddx:
  - a. **Acute pancreatitis**
  - b. Ovarian cyst
  - c. IBD
  - d. Meckel's diverticulitis
  - e. Ectopic pregnancy
5. About acute pancreatitis what is wrong:
  - a. Gall bladder stones including microlithiasis is MCC worldwide
  - b. **Alcohol is responsible for 30% of cases in Jordan**
6. All of the following can be considered as investigations for suspected pancreatitis except:
  - a. Abdominal U/S
  - b. Abdominal lavage
  - c. Abdominal CT
  - d. **Neck U/S**
7. Wrong about pancreatitis:
  - a. **Amylase level correlates with the severity of the infection.**
8. Pancreatitis case, initial step in management:
  - a. **Fluids**
9. Anatomy, true:
  - a. **Pancreas is related to medial side of duodenum**
  - b. Liver and GB cover 1st part of duodenum
10. Wrong about the physiology of pancreas:
  - a. Acid in the duodenum and bile secretion stimulates pancreatic secretion
  - b. CCK stimulates enzyme release from the pancreas
  - c. Pancreatic secretions neutralizes the acid in duodenum
  - d. Amylase is secreted in its active form the pancreas
  - e. **Electrolyte and fluids in pancreatic juice are secreted from acinar cells**
11. CA of head of pancreas all except
  - a. Local invasion
  - b. Liver mets
  - c. Back pain
  - d. Jaundice
  - e. **Thombophlebitis**
12. Least common presenting symptom in the carcinoma of the head of pancreas
  - a. Jaundice
  - b. **Hemobilia**

- c. Back pain
- 13. All true about pancreatic cysts except;
  - a. **Solid pseudopapillary occurs in middle aged men and is aggressive**
- 14. Patient on NG tube, which is true?
  - a. **Enteral nutrition activates the biliary pancreatic axis and has trophic effects on the bowel.**
- 15. Pancreatic pseudocyst, false:
  - a. **Infected cyst must be drained internally**
  - b. To drain cyst internally we must wait for maturation of wall
  - c. Size is no longer an indication of surgery
  - d. All symptomatic must be treated
- 16. Pancreatic adenocarcinoma, false:
  - a. 70% in the head
  - b. 90% ductal
  - c. In resectable , 20% 5-yr survival
  - d. P16 mutation is found in more than 90%
- e. **Papillary and mucinous cystadenocarcinoma are worse prognosis**
- 17. Pancreatic ca tumor marker:
  - a. **CA 19-9**
  - b. HCG
- 18. About lipase and amylase, what is wrong:
  - a. **Serum amylase starts to rise 2 hours after pancreatitis**
  - b. Increased amylase can be from other sources than pancreatitis
  - c. If uncomplicated, amylase starts to disappear 3-5 days after
  - d. Hyperlipidemia can affect the assay of lipase
  - e. Lipase is more sensitive to alcoholic pancreatic than amylase
- 19. About causes of acute pancreatitis, all true except:
  - a. caused by hyperlipidemia
  - b. **Caused by CBD stones passed to deudenum.**

# Spleen

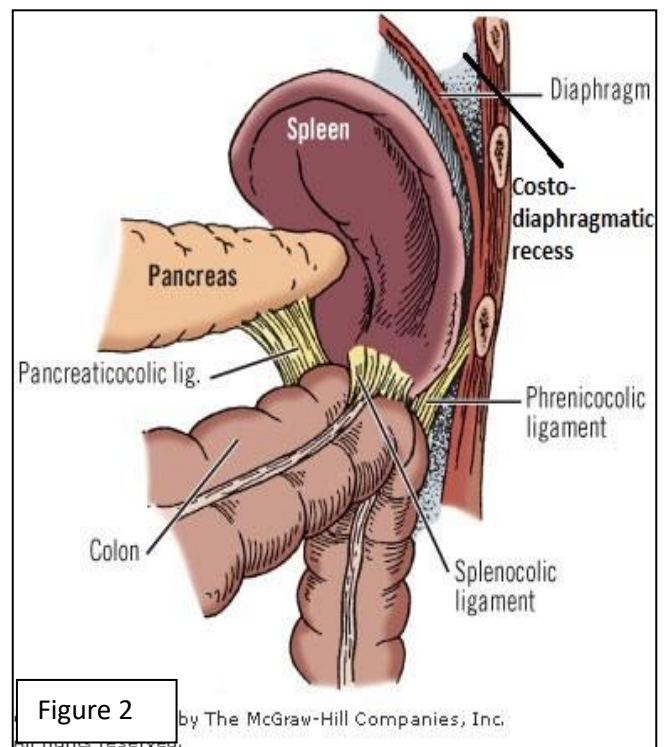
## ❖ Embryology: [Figure 1]

- Spleen develops from condensations of mesoderm in dorsal mesogastrium of the foregut. (The foregut is the only part of GI tracts which attached by dorsal and ventral mesentery which later form lesser and greater omentum respectively).
- As rotation of the foregut takes place, it becomes located in the upper quadrant of the abdomen.



## ❖ Anatomy:

- It's an intraperitoneal structure (except the hilum), separated from the stomach by the greater sac.
- It's located in the LUQ (left hypochondrium) between 9<sup>th</sup> and 11<sup>th</sup> ribs.
- 12-13 cm long, 7-8 cm wide and 2.5-3.5 cm thick.
- Weights about 75-250 grams.
- **Boundaries:**[Figure 2]
  - Costodiaphragmatic recess of the left pleural cavity extends to the inferior border of a normal spleen.
  - Superiorly: left diaphragmatic leaf.
  - Inferiorly: splenic flexure of the colon and phrenocolic ligament.
  - Medially: greater curvature of the stomach and tail of the pancreas.
  - Laterally: 9-11 Ribs
  - Anteriorly: Stomach.



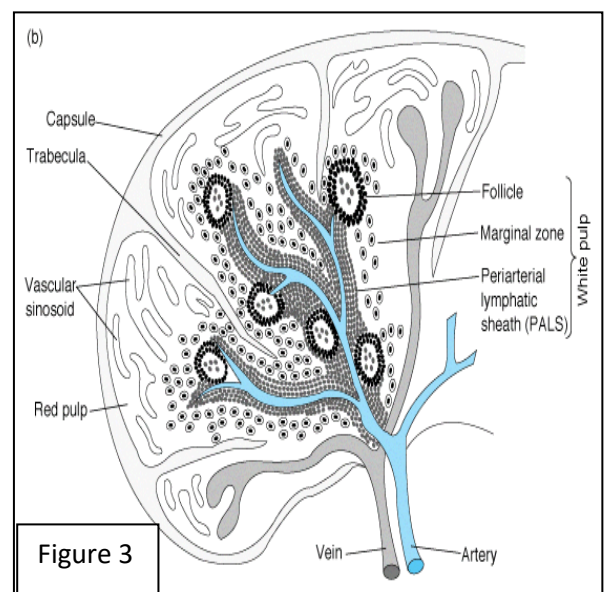
- Posteriorly: Left kidney.
- **Peritoneal reflections (ligaments):**
  - Splenocolic ligament.
  - Splenorenal (Lieno-renal) ligament which contains the splenic veins, the tail of the pancreas and lymph nodes
  - Gastrosplenic ligament which contains short gastric arteries, the left gastroepiploic vessels and lymph nodes
  - Splenophrenic ligament.
- **Arterial supply:**
  - Splenic artery (branch of the celiac trunk) which is tortuous artery to allow the increase in the spleen size, it runs along the upper border of the body and tail of the pancreas
- **Venous drainage:**
  - Splenic vein and left gastroepiploic vein → to the portal vein.
- **Lymphatic drainage:**
  - Nodes at the hilum → retropancreatic lymph nodes → Celiac lymph nodes.
- **Nerve supply:**
  - Sympathetic supply from the celiac plexus supplies the splenic arterial branches.

**Note:** 10-20% of population has accessory spleen, most common site is **the splenic hilum (80% of cases)**, it could also be found in gastrosplenic omentum, along the tail of pancreas or in the retroperitoneum.

Splenic artery gives small branches to the stomach called short gastric arteries.

❖ **Physiology and Histology:** [Figure 3]

- The tissue inside the spleen is called the splenic pulp or parynchema, it's divided into white pulp and red pulp. It's surrounded by a capsule of dense connective tissue.
- **White pulp (20%):** composed of periarterial lymphatic sheath (T-cells), splenic follicles (B-cells) and marginal zone (macrophages and dendrites). It is a lymphatic tissue concerned with fighting infections and controlling immune response.



- Red pulp (80%): composed of splenic cords and sinusoids which are highly vascular structures (RBCs) with macrophages, lymphocytes and plasma cells. It is concerned with the destruction of worn-out red blood cells.

#### ❖ Functions:

- Filtration of RBCs (NOT storage) → by the red pulp.
- Storage of platelets → 33% of the platelets is stored in the spleen.
- Immunity → by the white pulp. (It produces tuftsin, properdin and antibodies, and it's also site of phagocytosis).

Properdin and tuftsin are non-specific opsonins.

#### Extra pieces of information for the love of our spleen: [Figure 3]

- The capsule sends extensions to the spleen called trabeculae.
- The splenic artery gives branches called trabecular arteries which follow the course of trabeculae, as each trabecular artery enters the white pulp it becomes the central artery.
- Periarterial lymphatic sheath (T-cells) surrounds each central artery, with follicles filled with B-cells scattered around them.
- Marginal zone located between white pulp and red pulp and is filled with macrophages and dendritic cells.
- Splenic cords contains all types of cells (lymphocytes, macrophages..) with RBCs and Sinusoids are blood filled spaces with large lumen and large pores within their endothelial cells.
- As the blood enters the spleen via central arteries it's being filtered from foreign antigens using immune cells in the white pulp.
- Central arteries give end-arteries that open to the splenic cords, and then it's translocated to the sinusoids through the endothelial pores. As this happen, damaged RBCs are forbidden from entering through the pores and left to be destructed by the cells in splenic cords.

#### ❖ Main Investigations:

- History and physical exam: very important in the diagnosis of splenomegaly (we look for signs of anemia or portal hypertension).
- Laboratory investigations: important in diagnosis of hemolytic anemia or liver dysfunction.
- Endoscopy: used in the diagnosis of esophageal varices associated with portal hypertension.
- Lymph node biopsy may be required as many diseases that cause splenomegaly are associated with lymphadenopathy.
- Imaging:
  - Plain radiography is rarely done (may reveal calcifications).

- Ultrasound can determine the size and consistency of the spleen.
- CT scan with contrast is **more commonly** done to reveal any splenic pathology.
- Radioisotope scanning is used occasionally to provide information about the spleen.
- The use of technetium-99m ( $^{99m}\text{Tc}$ )-labelled colloid is normally restricted to determining whether the spleen is a significant site of destruction of red blood cells.

## Splenectomy

### INTRODUCTION

- **Definition:** It's the surgical removal of the spleen.
- It can be done via **laparoscopy** or **open surgery**.
- **Contraindications for laparoscopic splenectomy:**
  - **Absolute:**
    1. Portal hypertension
    2. Splenic trauma with an unstable patient.
    3. Massive splenomegaly (>30 cm long).
  - **Relative:**
    1. Morbid obesity.
    2. Splenic vein thrombosis.
    3. Moderate splenomegaly (>20-25 cm long).
    4. Splenic trauma with a stable patient.
    5. Marked uncorrectable cytopenia.
- **Open splenectomy incisions:**
  1. Midline (preferred).
  2. Left subcostal incision.
- **Preoperative consideration:**
  - Vaccinations for encapsulated bacteria two weeks prior to surgery:
    1. Strep Pneumonia.
    2. Haemophilus influenzae type B.
    3. Neisseria meningitides.

**Remember that:** by losing the spleen we are losing its immunogenic role in detecting foreign antigens.

- Antibiotic prophylaxis appropriate to the operative procedure should be given.
- Transfusion consideration, especially in patients with a hematological disease; cross match should be done and fresh-frozen plasma, cryoprecipitate or platelets may be needed.
- Imaging; Ultrasound and CT scan to determine the spleen size. Nuclear imaging can be done to reveal the presence of an accessory spleen.
- Embolization of the splenic artery preoperatively in order to decrease spleen size.

- **Postoperative considerations:**

- Complete response if platelets count more than  $100 \times 10^9/L$ .
- Partial response if platelets count more than  $30 \times 10^9/L$ .
- If platelets failed to increase → look for accessory spleen.
- Abnormal lab tests post-splenectomy:
  - Increase in WBC >50%.
  - Marked thrombocytopenia.
- Abnormal findings on peripheral smear post-splenectomy (these are normal in a person without a spleen):
  - Pappenheimer bodies.
  - Howell-Jolly bodies.
  - Heinz bodies.

**Why does the platelets' level increase post-splenectomy?**

\*Because spleen used to store those platelets (33%).

- **Complications:**

- **Intra-op:**
  - Hemorrhage (due to hilar distention, capsular tear or injury to a blood vessel).
  - Pancreatic injury (especially the tail).
  - Small bowel, colon or stomach injury.
  - Diaphragmatic injury.
  - Pancreatic gastric dilation. (rare)
- **Early:**
  - Left basal pulmonary atelectasis (with pleural effusion) → most common complication.
  - Subphrenic abscess which is usually accompanied with left pleural effusion (treated by percutaneous drainage and IV antibiotics).
  - Wound problems (Hematoma, seroma or wound infection).

**Note:** if suspected injury to the pancreatic tail during surgery, a drain should be placed.



- Thrombocytosis (If > 1 million Aspirin should be given) which can cause splenic or portal vein thrombosis.
- Postoperative ileus.

➤ **Late:**

- Overwhelming postsplenectomy sepsis (OPSS):
  - Increased susceptibility to fulminant bacteremia, meningitis or pneumonia as a result of losing splenic immunogenic role.
  - Incidence < 1% in adults.
  - Increased risk in young patients (< 4 years).
  - Most septic episodes occur within 2 years after splenectomy.
  - Clinical presentation: Fever, lethargy, common cold, sore throat and URTI followed by confusion, coma and death within 24 hours in 50% of patients.
  - Organisms: S.Pneumoniae, H.influenzae and N.meningitides.
  - Prevention: daily prophylactic antibiotics (especially for children and immunocompromised) and vaccinations.
- Splenosis:
  - It's the presence of disseminated intraabdominal splenic tissue.
  - It's not common after laparoscopic splenectomy, but care should be taken during the procedure to avoid bag rupture and spillage of splenic tissue.

## ? ETIOLOGY

### Indications for splenectomy:

- Before starting discussing the indications for splenectomy, we have to differentiate between two terms; Hypersplenism and splenomegaly:

**Splenomegaly:** Enlargement of the spleen.

**Hypersplenism:** is an indefinite clinical syndrome that is characterised by splenic enlargement with any combination of anemia, leukopenia or thrombocytopenia, compensatory bone marrow hyperplasia and improvement after splenectomy.

- Few conditions that cause splenomegaly will require splenectomy as part of treatment.
- In hypersplenism, Careful clinical judgement is required to balance the long- and short-term risks of splenectomy against continued conservative management.

1. **Tauma:** Resulting from an accident (blunt) or during a surgical procedure (iatrogenic).

Splenic trauma will be discussed in details in the next section.

## 2. **Thrombocytopenia:**

### ➤ **Idiopathic thrombocytopenic purpura (ITP):**

- Results from the development of antibodies (IgG) to specific platelet membrane glycoproteins that damage the patient's own platelets.
- Acute ITP in children often follows an acute infection and has a spontaneous resolution within months.
- Chronic ITP in adults and women persists longer than six months without a specific cause being identified.
- Treatment: First line is corticosteroids [only 20% have a sustained response]. If refractory to medical treatment or in patients with intracranial hemorrhage **splenectomy** is indicated (sustained remission in 75% of patients).

ITP is the most common cause for elective splenectomy.

Splenectomy eliminates the primary source of antibodies plus the site of platelets destruction.

### ➤ **Thrombotic thrombocytopenia purpura (TTP):**

- RARE!
- Rapidly progressive and usually fatal.
- Platelets are consumed in the formation of microthrombi and RBCs are sheared as they cross microthrombi causing resulting in hemolytic anemia.
- Diagnostic pentad: **FAT RN**
  - ✓ **F**ever, **A**nemia, **T**hrombocytopenia, **R**enal dysfunction and **N**eurological dysfunction.
- Treatment: First line is plasmapheresis (plasma exchange). **Splenectomy** reserved for patients with relapse or requiring multiple plasma exchanges as a last resort.

Microthrombi formation results from the lack of VHL degradation caused by ADAMTS13 enzyme deficiency.

Transfusion platelets in TTP is thought to "fuel the fire" and exacerbate consumption of platelets and clotting factors resulting in more thrombi in microvasculature. That's why plasmapheresis is the treatment of choice and not transfusion.

## 3. **Anemias:**

### ➤ **Hereditary spherocytosis:**

- It is an autosomal dominant hereditary disorder characterised by the presence of spherocytic red cells.
- spherocytic red cells are going to be filtered by the spleen resulting in anemia.

- **Splenectomy** is curative but should be delayed until the age of 4 to minimize the risk of post-splenectomy infection. But post-splenectomy spherocytes are expected to be there (we only removed the site of elimination of spherocytes not the cause of spherocytosis).

➤ **Autoimmune hemolytic anemia:**

- Caused by autoantibody (IgG and IgM) formation against RBC membrane proteins.
- Antibody coated RBCs (especially with IgG) are destroyed in the spleen resulting in anemia.
- Treatment: first line is medical treatment with corticosteroids (response in 75%). **Splenectomy** can be done in cases refractory to medical treatment (response in 80%).

➤ **Sickle cell anemia:**

- Sickle cell disease is an autosomal recessive haemolytic anemia in which the normal haemoglobin A is replaced by haemoglobin S (HbS).
- The HbS molecule crystallises when the blood oxygen tension is reduced, thus distorting and elongating RBCs.
- The resulting increased blood viscosity may obstruct the flow of blood in the spleen.
- **Splenectomy** is of benefit in a few patients in whom excessive splenic sequestration of red cells aggravates the anemia.
- Autosplenectomy usually occurs secondary to repeated vaso-occlusive events and splenectomy is rarely required.

**HbS results from change of glutamic acid to valine in the sixth amino acid position on the beta chain in hemoglobin.**

➤ **Thalassemia (especially  $\beta$  major “Cooley’s anemia”):**

- Autosomal dominant inheritance characterized by defective hemoglobin( $\alpha$  or  $\beta$ ) synthesis.
- Causes severe anemia and hepatosplenomegaly.
- Blood transfusion may be required to correct profound anaemia.
- **Splenectomy** is of benefit in patients who require frequent blood transfusion.

➤ **Myelofibrosis and myeloid metaplasia:**

- They are incurable myeloproliferative disorders that usually present in patients older than 60 years.
- The condition is characterized by bone marrow fibrosis, leukoerythroblastic anemia, and extramedullary hematopoiesis, which can result in massive splenomegaly.

- Indications for **splenectomy** include symptomatic splenomegaly and transfusiondependent anemias.

#### 4. Malignancies:

- **Hodgkin lymphoma: Splenectomy** used to be part o the staging but is now rarely indicated because the additional information does not alter therapy.k
- **Leukemias or non-Hodgkin lymphoma:** they result in hypersplenism and **splenectomy** may be indicated in select patients to treat hypersplenism and thrombocytopenia.
- **Splenic tumors:** primary, metastasis (isolated splenic mets are rare) or locally invasive tumors.
  - **Splenectomy** indicated for indeterminate or suspicious lesions (to confirm or exclude malignancy).
  - **Splenectomy** for splenic cysts if larger than 5 cm is indicated.
  - Benign, stable hemangiomas contrast enhanced CT do not necessarily require **splenectomy**.

##### Splenic tumors:

- **Benign:** Hemangioma/ lymphoma/ hemartoma/ primary cyst, pseudocyst or echinococcal cyst (hydatid cyst).
- **Malignant:** lymphoma/myeloproliferative disorder or metastasis.

#### 5. Miscellaneous indications:

- Bleeding esophagogastric varices associated with **splenic vein thrombosis**. **Splenectomy** is curative.
- **Gaucher's disease:** It's a lipid storage disease characterised by storage of glucocerebroside in the reticuloendothelial system and in the spleen. **Splenectomy** is indicated only for severe symptoms related to the splenomegaly.
- **Splenic abscess:**
  - Caused by splenic seeding (most commonly from endocarditis), Infection from adjacent structure, hematoma or IV drug abuse.
  - Presented with fever, chills, LUQ tenderness, guarding and splenic mass(not always palpable).
  - Diagnosed by U/S and CT scan.
  - Can be complicated to peritonitis or sepsis if rupture took place.
  - Treatment: treating the underlying cause and percutaneous drainage under radiological guidance. **Splenectomy** only for refractory cases.

\*Most common cause of isolated gastric varices is splenic vein thrombosis

\*Most common cause for splenic vein thrombosis is pancreatitis.

- **Felty's syndrome:** It's the triad of rheumatoid arthritis, leukopenia and splenomegaly. **Splenectomy** produces only a transient improvement in the blood picture, but rheumatoid arthritis may respond to steroid therapy.
  - **Splenic artery aneurysm:** should be repaired if symptomatic, >2 cm or any size in a women in child bearing age (or pregnant female) by either endovascular treatment or open surgery. For aneurysms located in distal splenic artery, **splenectomy** is performed.
  - **Hypersplenism as a result of portal hypertension:** **Splenectomy** would only be required in those patients whose portal hypertension has resulted in symptomatic esophagogastric varices.
  - **Primary hypersplenism:** As a result of a primary disease of the spleen, very rare and a diagnosis of exclusion.
-

# Splenic Trauma

## INTRODUCTION

- **Definition:** Blunt trauma causing injury to the splenic tissue.
- It's graded from grade I-V according to the American Association for Surgery of Trauma, and according to the grade the management can be decided (See table below).

Grading (According to AAST)	Initial management
<b>I</b>	admit for minimum of > 24 hours with serial exams and Hcts
<b>II</b>	admit for minimum of > 24 hours with serial exams and Hcts
<b>III</b>	admit ICU, serial Hcts (every 4 -6 hrs) for a minimum of 3 times and until stable
<b>IV</b>	Splenic artery embolization ASAP with goal to be within 2 hours
<b>V</b>	to OR in most circumstances
I-V that show CT evidence of blush/pseudoaneurysm or extravasation	Splenic artery embolization ASAP with goal to be within 2 hours.

- Previously the first line management of any splenic trauma was splenectomy; nowadays, as you should have noticed, many cases of traumatic splenic injury can be managed nonoperatively

**But it's still one of the most common causes of splenectomy.**

**Most common causes for splenectomy: 1) ITP 2) Trauma**

## ETIOLOGY

- Blunt trauma.
- Iatrogenic trauma (during mobilization of the esophagus, stomach, distal pancreas or splenic flexure of the colon).



## CLINICAL FEATURES

- Major symptom: LUQ pain.
- Signs:
  - Signs of peritoneal irritation.
  - External signs of injury.
  - Kehr's sign (Left shoulder pain from diaphragmatic irritation especially when a person is lying down and the legs are elevated).
  - Ballance's sign (LUQ dullness to percussion).
  - Seagesser's sign (Phrenic nerve compression causing neck tenderness).
  - Hemoperitoneum.
  - Shock.
  - Left sided lower rib fracture.
- Late Complications:
  - Missed splenic injury: those with delay in diagnosis of splenic trauma have a ten-fold increase in mortality. It is therefore important to have a high index of suspicion for this diagnosis when evaluating patients with blunt trauma.
  - Delayed splenic rupture: subscapular hematoma or pseudoaneurysm two weeks after rupture after splenic. Results as shock (Abdominal pain). Signs and symptoms are similar to those of any splenic injury mentioned before).
  - Splenic pseudocyst.



## DIAGNOSIS

- If stable patient → DPL or FAST exam.
- If unstable patient → CT.

DPL= Diagnostic peritoneal lavage (aspiration).

FAST= Focused assessment with sonography for trauma is a rapid bedside ultrasound examination.



## TREATMENT

- If stable patient with an isolated splenic injury without hilar involvement nor complete rupture → Non-operative treatment.
- If unstable patient → Laparotomy with splenorrhaphy or splenectomy.
- Embolization of the splenic artery can be done pre-op in selected patients.

Splenorrhaphy= Splenic salvage operation= Wrapping visceral mesh and adding topical hemostatic agents. partial splenectomy maybe done then suturing of the spleen is persumed.

# Summary & past papers

## Summary

- ❖ Spleen is an **intraperitoneal** structure which is bound medially by the tail of the pancreas (which tickles it), anteriorly by the stomach, laterally by the 9-11 ribs and posteriorly by the left kidney. It's supplied by the **splenic artery** which is a branch of the celiac trunk (It is tortuous artery to allow the increase in the spleen size) it also gives small branches to the stomach called short gastric arteries.
- ❖ The spleen is attached to the left kidney by the **lienorenal ligament** (it contains the splenic vessels, tail of pancreas and lymph nodes) and to the stomach by the **gastrosplenic ligament** which contains short gastric arteries, the left gastroepiploic vessels and lymph nodes.
- ❖ Spleen **filters RBCs** by the red pulp, **fights infection** by the white pulp and **stores 33% of platelets**.
- ❖ **Absolute contraindications for splenectomy** are portal hypertension, splenic trauma with an unstable patient and massive splenomegaly (>30 cm long).
- ❖ **Preoperatively**, vaccinations for strep. pneumoniae, H. influenzae and N. meningitidis must be administered. Antibiotics should also be given and transfusion precautions should be taken.
- ❖ **Complete response** to splenectomy if platelets count more than  $100 \times 10^9/L$  normally on blood film (Post splenectomy) Pappenheimer bodies, howell-Jolly bodies and heinz bodies can be seen.
- ❖ **Early complications** include atelectasis (most common) and thrombocytosis (Aspirin should be given if platelets is >1 million). **Late complications** include Overwhelming postsplenectomy sepsis (OPSS) and splenosis. OPSS occurs in < 1% of cases, increased risk in children < 4 years, mostly occur in the first 2 years, organisms are S. pneumoniae, H. influenzae and N. meningitidis can be prevented by daily Abx and vaccinations.
- ❖ Most common **indications for splenectomy** are **ITP** and **splenic trauma** (Iatrogenic or blunt). Although many cases of traumatic splenic injury can be managed nonoperatively.
- ❖ In **ITP** Splenectomy eliminates the primary source of antibodies plus the site of platelets destruction and results in sustained remission in 75% of patients.
- ❖ In **TTP** the treatment is Plasmapheresis and splenectomy is only as a last resort.
- ❖ In **Heredity spherocytosis**, Splenectomy is curative but should be delayed until the age of 4, but post-splenectomy spherocytes are expected to be there.
- ❖ In **autoimmune hemolytic anemia** and **thalassemia  $\beta$  major** splenectomy only for refractory cases.



- ❖ In bleeding from **esophagogastric varices**, splenectomy is curative.
- ❖ In suspicious **splenic tumor**, splenectomy is indicated.

### Past papers

- 1) The vascular ligament of the spleen is :
  - a) **lienorenal ligament**
  - b) gastrosplenic ligament
- 2) Unlikely injured site to cause hypovolemic shock :
  - a) **Intracranial**
  - b) Spleen
- 3) ITP, false:
  - a) Majority of patients improve after splenectomy
  - b) **Spleen is usually palpable**
  - c) Most cases resolve with immunosuppressant
- 4) High velocity penetrating trauma, transverse abdomen at mid umbilicus, which is likely to be injured:
  - a) **Small bowel**
  - b) Liver
  - c) Kidney
  - d) Spleen
- 5) Which of the following touches the hilum of the spleen:
  - a. **Tail of the Pancreas**
- 6) Regarding Hereditary Spherocytosis, which is wrong:
  - a. Abnormality in spectrin.
  - b. **Splenectomy doesn't treat anemia**
- 7) About splenectomy:
  - a. **1<sup>st</sup> choice in  $\beta$  thalassemia.**
- 8) Most common organ injured in blunt abdominal trauma:
  - a. Liver
  - b. Intestines
  - c. **Spleen**
- 9) Which of the these conditions will not predispose to spontaneous rupture of spleen:
  - a. Malaria
  - b. Kala azar (Visceral leishmaniasis that causes hepatosplenomegaly)
  - c. Leukemia
  - d. **TTP**
- 10) After splenectomy for spherocytosis:
  - a. Thrombocytopenia persists.
  - b. **RBCs still spherocytes**
  - c. RBC osmotic fragility increases
  - d. RBC life span decreases
  - e. Transient leukocytosis
- 11) OPSI, false:
  - a. **Occur in 2% post traumatic splenectomy**
  - b. 50% due to pneumococcus
  - c. Majority occur within first 2 years post op
  - d. Present as non specific flu like
  - e. Mortality is 80%
- 12) Splenic artery:
  - a. **Upper border of the pancreas**
  - b. Lower border of pancreas
  - c. Posterior to stomach
  - d. Uncinate process relation
  - e. Posterior to transverse colon

# Liver & biliary tree

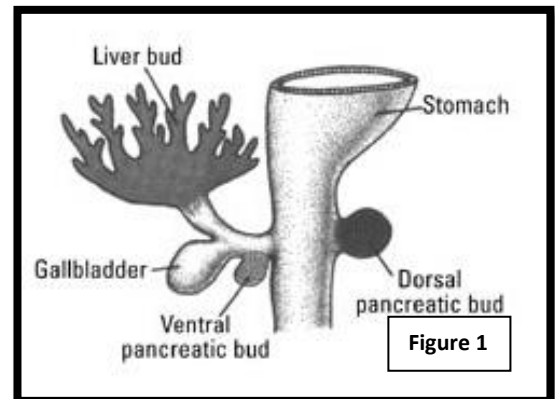
- Written by: Alma Jarkas & Russole Emad

- Liver: 112
  - Introduction: 112
  - Abscesses of the liver: 120
  - Hydatid disease 123
  - Tumors of the liver: 130
  - Haemobilia: 136
  - Portal HTN: 137
  - Summary and past papers: 143
- Biliary tree: 146
  - Introduction: 146
  - Gallstones : 153
  - Acute cholecystitis: 159
  - Choledochal cyst: 163
  - Choledocholithiasis: 165
  - Cholangitis: 168
  - Gallstone ileus: 172 .
  - Biliary system tumors: 173
  - Summary & past papers: 177

# Liver

## ❖ Embryology: [Figure 1]

- It starts as a hepatic duct/diverticulum just proximal to the ampulla of Vater, at the same area where the pancreatic duct arises.
- The hepatic duct arises at the ventral aspect and rotates 90 degrees clockwise, and that's why the liver is on the right.
- The diverticulum divides into:
  1. Cranial part → gives rise to CBD, right and left hepatic duct & the liver.
  2. Caudal part (smaller) → gives rise to the cystic duct and gallbladder.

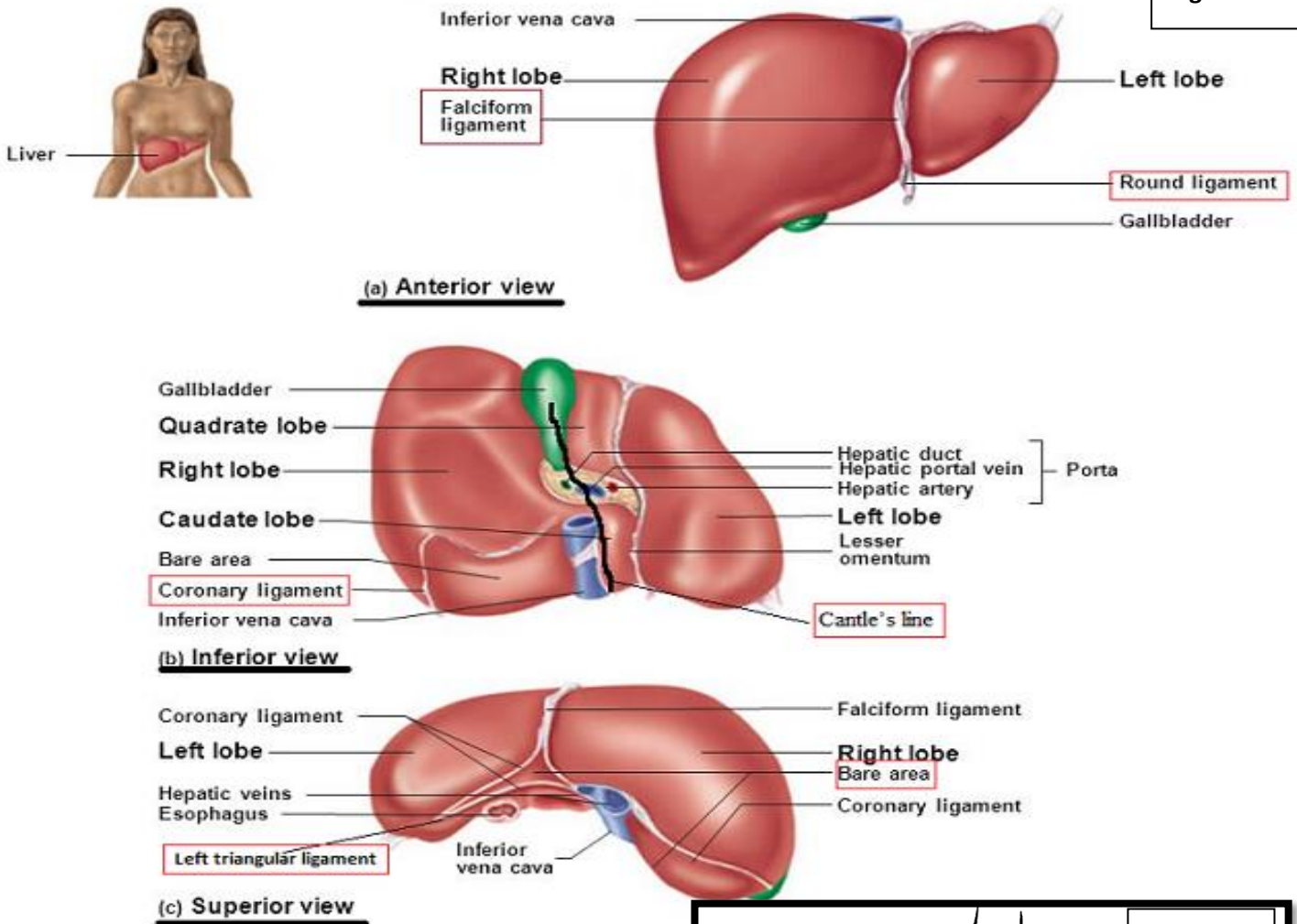


- The liver grows very rapidly, especially during the 5<sup>th</sup> to 10<sup>th</sup> weeks of gestation because the blood is produced from the liver and spleen during this period.
- The liver is relatively very huge, leaving no space in the peritoneal cavity, this will push the small bowel outside, a process called physiologic herniation.

## ❖ Anatomy: [Figure 2]

- **The Bare area of the liver:** the posterior section of the liver against the diaphragm that's "bare" without a peritoneal coverage.
- **Glisson's capsule:** the capsule of the liver.
- **Cantle's line:** line drawn from the gallbladder to a point just to the left of the IVC, which transects the liver into left and right lobes.
- **Falciform ligament:** a ligament that goes from the anterior abdominal wall to the liver and contains ligamentum teres-obliterated umbilical vein.
- **Coronary ligament:** peritoneal reflection on the top of the liver that crowns the liver and attaches it to the diaphragm.
- **Triangular ligament:** right and left lateral extensions of the coronary ligament (which form triangles).

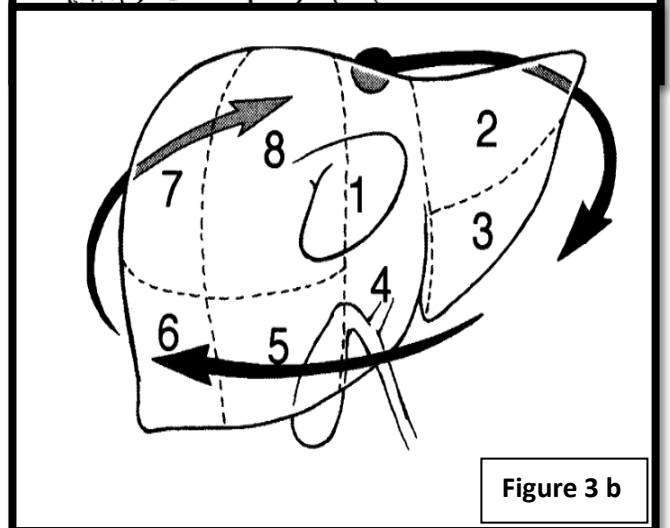
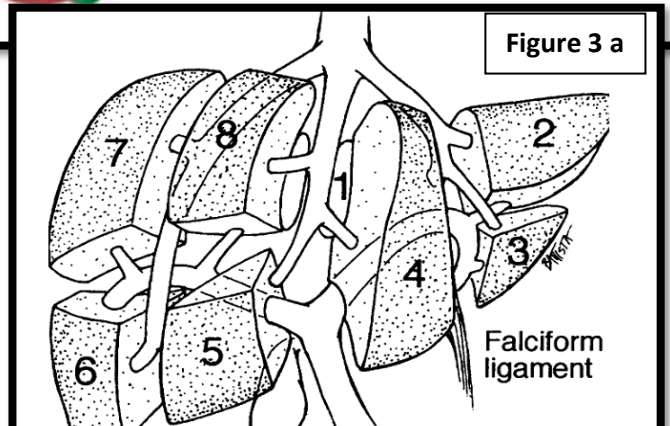
Figure 2



➤ **Segments of the liver** [Figure 3]: the liver is divided into functional Rt and Lt lobes by a line passing from the left of the gall bladder fossa to the left of IVC, this line is known as Cantlies' line:

- Clockwise starting from segment 1
- French system.
- Notice the relation of the gallbladder to the 4<sup>th</sup> and 5<sup>th</sup> segments.

Note that: **segment 1** is the caudate lobe and **segment 4b (lower part of 4)** is the quadrate lobe. [see Figure 2]

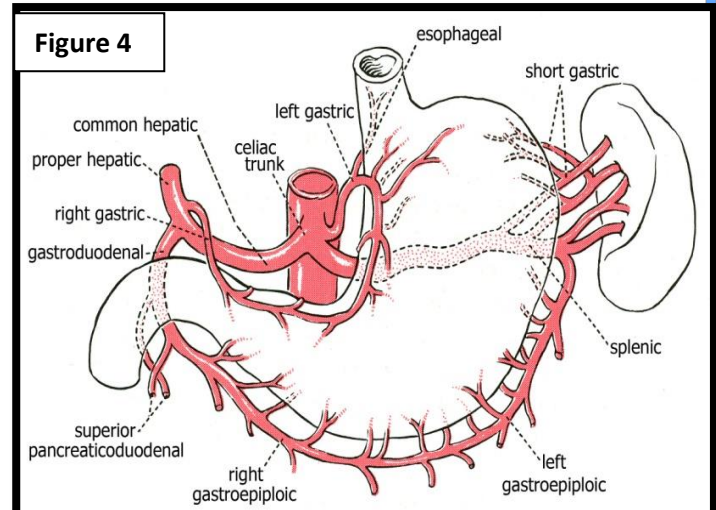


➤ **Arterial blood supply:** [Figure 4]

- Celiac trunk from the aorta.

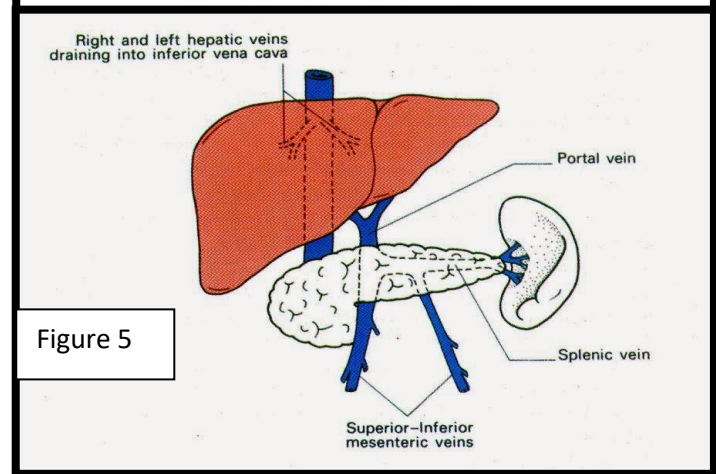
Branches of the celiac trunk:

- The left gastric artery.
- Splenic artery.
- Common hepatic artery.



➤ **Venous drainage:** [Figure 5]

- Portal vein that's formed by the union of the Superior mesenteric vein (SMV) and splenic vein.
- Hepatic venous drainage via the hepatic veins (3 veins: left, middle and right) → drain into IVC.



Notes:

- Sources that provide oxygen to the liver are the portal vein (50%) and the hepatic arterial blood (50%).
- Sources from which the liver receives blood are the portal system (75%) and the hepatic artery (25%).
- The maximum amount of the liver that can be resected while retaining adequate liver function is more than 80%, i.e. if given adequate recovery it will regenerate

❖ **There is two important scores to estimate the hepatic reserve in patients with hepatic failure and mortality rates which are extremely important in the clinical practice:**

1. **Child's classification:**

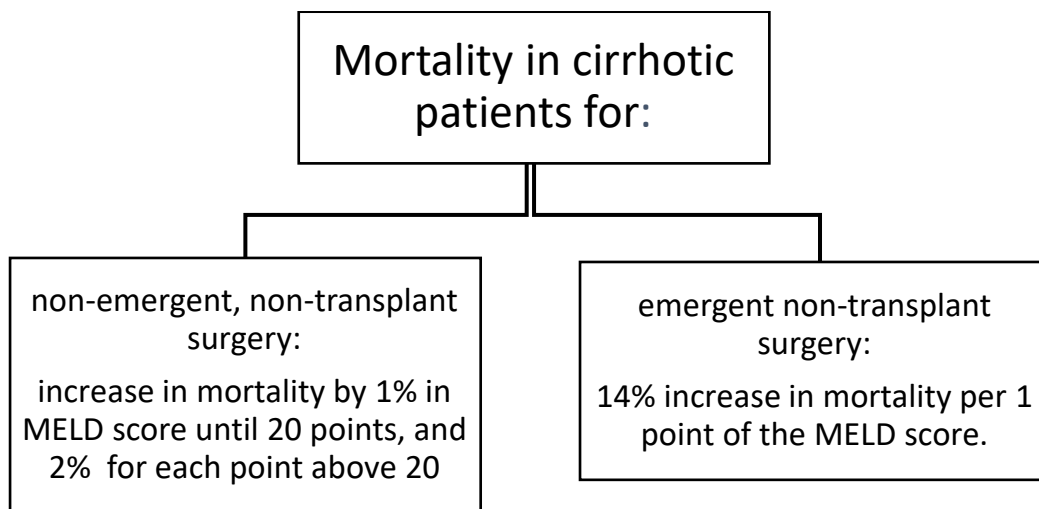
	Ascites	Bilirubin	Encephalopathy	Albumin	INR
A	None	<2	None	>3.5	1.7
B	Mild	2-3	Minimal	2.8-3.5	1.7-2.2
C	Marked	>3	Severe	<2.8	>2.2

**Interpretations:**

- A → Mortality rate of 10%.
- B → Mortality rate of 30%
- C → Mortality rate of 75%

## 2. MELD Score (Model for End-stage Liver Disease):

- Used more than child's because it's more objective [it depends only on lab values].
- It's the formula currently used to assign points for prioritizing position on the waiting list for deceased donor liver transplant, based on INR, bilirubin and creatinine, with extra points given for the presence of liver Ca. You can find a good calculator online.
- Measurements are : INR, total bilirubin, Serum creatinine .



### ❖ Physiology:

- Liver function tests:

#### ➤ AST and ALT:

- They don't really test liver function BUT they are a reflection of hepatocellular injury as they reflect hepatocytes function
- **ALT** is more specific to the **Liver** than AST
- AST also increases in MI, skeletal damage and hemolysis.

#### **Full work up includes:**

Transaminases (ALT,AST) , Alkaline phosphatase, PT/INR, Bilirubin, Albumin, GGT and CBC

	AST	ALT	AST:ALT	MCV
Alcoholic liver disease	↑↑	↑	AST>ALT 3:1 (>2)	↑↑
Viral hepatitis	↑	↑↑	AST<ALT <1	↔
NAFLD	↑	↑↑	AST<ALT	↑ or ↔

\*NAFLD: non alcoholic fatty liver disease.

➤ **Albumin:**

- Decreases in liver disease.

➤ **Alkaline phosphatase:**

- Found in liver, bone, GI, kidneys and placenta.
- It increases in cholestasis.
- It varies with age (It's higher in males) and gender (in children, it's 3 times higher because it correlates with bone growth). And it's two times higher in pregnancy because it's produced by the placenta.

➤ **Gamma Glutamyl Transpeptidase GGT:**

- Rises in parallel with alkaline phosphatase from the liver.
- It should be checked in cases of **raised alkaline phosphatase** with normal bilirubin and transaminases.
- If both alkaline phosphatase and GGT are elevated, then we should perform an abdominal ultrasound to look for dilated bile ducts.
- If only GGT is elevated, then we should investigate the usage of the following drugs:
  - ♣ Barbiturates(CNS depressants used for anesthesia, anxiolysis, hypnosis and anti-convulsants) , Carbamazepine(epilepsy), phenytoin(anti-seizure drug)
  - ♣ Ethanol
  - ♣ Steroids
  - ♣ INH (isoniazid is a TB medication) , rifampicin(antibiotic).

➤ **PT:**

- Detects the Severity of hepatocellular injury, it's the most sensitive test for severity because it's only affected by severe liver diseases not moderate ones.
- PT and serum ammonia reflect the metabolic function of the hepatocytes.

➤ **Bilirubin:**

- It's either:
  - ♣ Conjugated: direct.
  - ♣ Unconjugated: Indirect ( without bilirubinuria).
- Bilirubinuria is an indication of cholestasis.

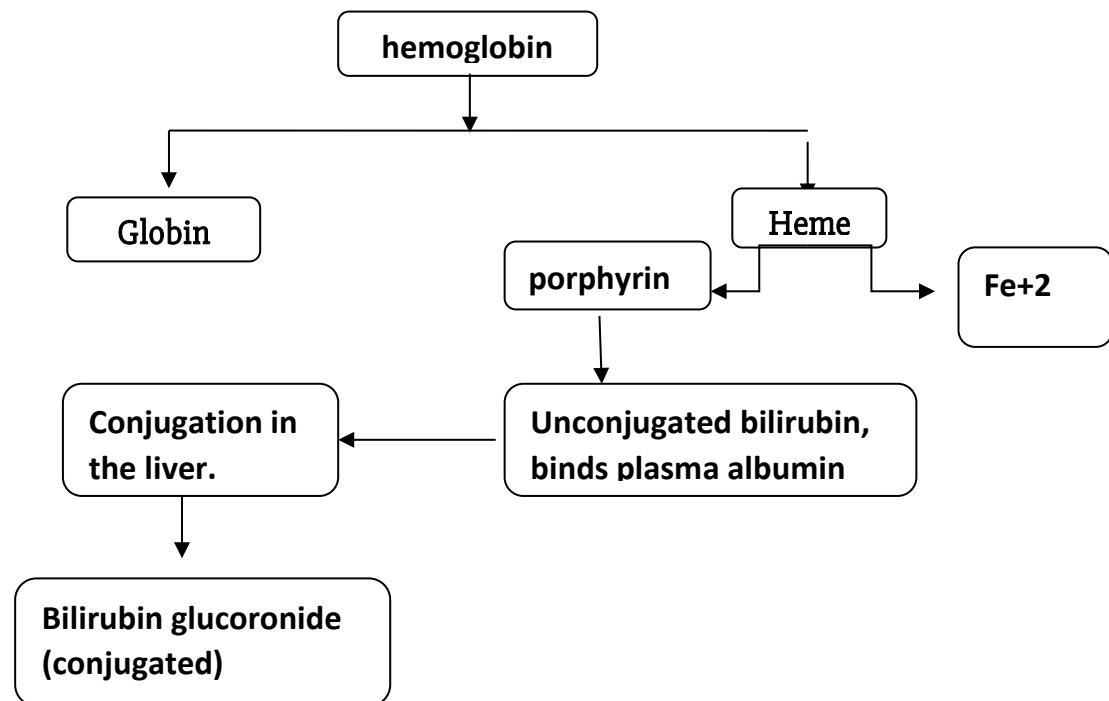
**\*\*Overall\*\*:**

Hepatocytes function	AT, ALT
Synthetic function and metabolism	PT/INR, factor V & VII, albumin, bilirubin
Biliary canalicular function	ALP, 5 Nucleotide, GGT, bilirubin

❖ **Main signs and symptoms of liver disease:**

1-**Jaundice:**

- **Definition:** Yellowish discoloration of the skin and mucus membranes, caused by an excess of bile pigments in the plasma.
- Jaundice is clinically detected when [Bilirubin ]>2.5-3 g/dL.
- The appearance of jaundice depends on the type of bilirubin elevated and the duration.
- **Metabolism of hemoglobin:**

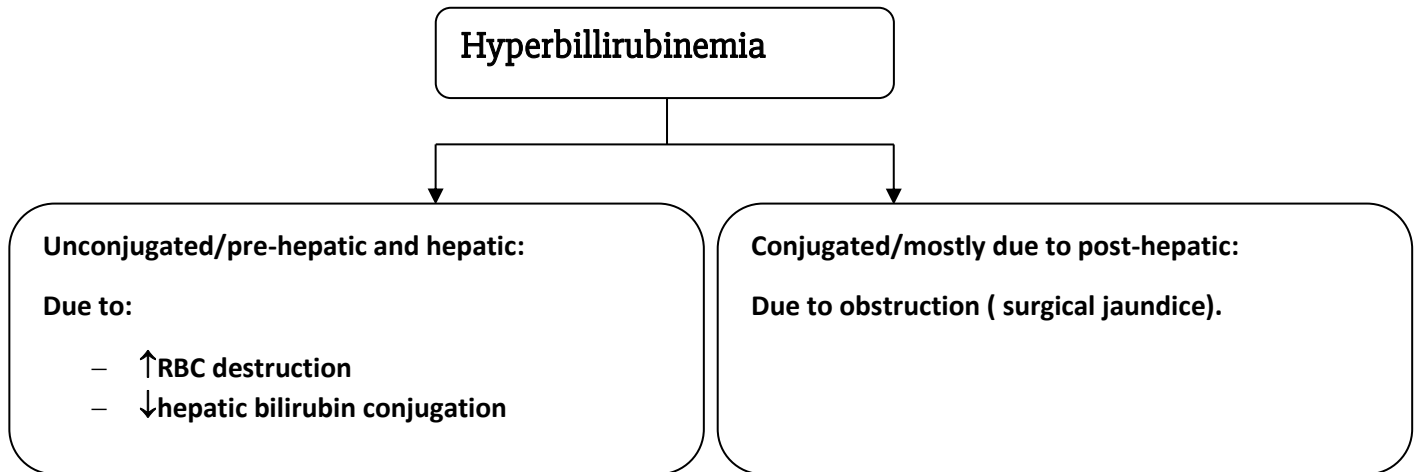


**\*\*In the small bowel, Bilirubin glucoronide is converted to stercobilinogen, by intestinal bacteria, and then into stercobilin, that gives the brown color of stool, and stercobilinogen is also converted in the kidneys into urobilinogen and then into urobilin that gives the urine its color.**



➤ **Causes of increased bilirubin:**

- Overproduction by reticuloendothelial system.
- Failure of conjugation or excretion.
- Obstruction of biliary excretion into intestines.



➤ **Classification of jaundice:**

**1-Prehepatic jaundice:**

➤ Could be due to:

- Excessive production of bilirubin.
- ability of liver to conjugate is overcome.
- increased plasma unconjugated bilirubin.

➤ **Differential diagnosis:**

1-hemolysis, hematoma resorption or multiple blood transfusions.

2-Gilbert syndrome.

3-Criglar-Najjar syndrome.

**2-Hepatic jaundice:**

➤ The defect could be in one of the following processes:

1-uptake. 2-conjugation. 3-secretion.

➤ It reflects liver dysfunction (↑ alkaline phosphatase, ↑↑↑AST/ALT)

**Lab tests indicating hemolysis:**

↑LDH.

↓ serum haptoglobin.

Evidence of hemolysis on

**Gilbert syndrome:**

- An inborn error in liver bilirubin uptake and glucuronyl transferase resulting hyperbilirubinemia (Think Gilbert=Glucuronyl), leading to intermittent asymptomatic jaundice in the 2<sup>nd</sup> or 3<sup>rd</sup> decade of life.
- It's a benign condition affecting up to 7% of the population.
- Affected people may have jaundice after stress or infection.
- So, the cause of unconjugated hyperbilirubinemia in Gilbert syndrome is both ↑RBC production and ↓hepatic conjugation.

➤ **Differential diagnosis:**

- 1-Viral hepatitis.
- 2-Medications: erythromycin/INH/phenytoin/valproate/OCP
- 3-Alcohol abuse.
- 4-cirrhosis.

**3-Post-hepatic jaundice:**

➤ **Characterized by:**

- ↑conjugated bilirubin
- ↑↑alkaline phosphatase & GGT.
- ±AST, ALT.

**Cholestatic syndrome:**

Characteristics:

- Conjugated hyperbilirubinemia (dark urine, pale stool & pruritis)
- Chronic malabsorption of lipid-soluble vitamins.

➤ **Effects of obstructive jaundice:**

- In liver: enlarged green bile stained liver (hydrohepatitis) and dilated intrahepatic biliary tracts. Once intraductal CBD pressure increases the bile secretion from the liver is reduced causing the formation of “white bile “ in CBD. Biliary cirrhosis may develop later.
- In the biliary tree: recurrent inflammation from cholangitis for example causes the fibrosis of biliary tracts.
- In bowel: absence of bile from bowel impairs digestion, reduces fat absorption making feces bulky and fatty. In addition, vit K absorption is reduced causing fall in prothrombin levels and raising PT/ INR.
- Altered coagulation profile and as result hepato renal syndrome and renal failure.

➤ **Causes:**

- Secondary to biliary obstruction (post-hepatic/ surgical).
- Hepatic jaundice (AKA: non-obstructive/medical jaundice).

➤ **Clinical presentation:**

1. jaundice
2. pale color stool (due to absence of fecal bilirubin)
3. Dark urine (↑conjugated bilirubin)
4. Itching.

➤ **Diagnostic test of choice is ultrasound.**

### Differential diagnosis for proximal bile obstruction:

- 1-Gallbladder stones.
- 2-Gallbladder cancer.
- 3-Cholangiocarcinoma.
- 4-Benign bile duct tumor.
- 5-Primary sclerosing cholangitis.
- 6-Parasites.
- 7-Metastatic tumor.
- 8-Metastatic tumor.
- 9-Lymphadenopathy.

### Differential diagnosis for distal bile obstruction:

- 1-Choledocholithiasis
- 2-Benign bile duct tumor
- 3-Ampullary cancer
- 4-Pancreatic cancer or pancreatitis
- 5-Pseudocyst
- 6-Lymphadenopathy or lymphoma
- 7-Post-operative stricture.
- 8-Parasite.

## Abscesses of the liver

### INTRODUCTION

- **Definition:** a collection of pus in the liver parenchyma.
- **Types:**
  - Pyogenic (bacterial)
  - Parasitic (amebic)
  - Fungal.
- Most common site is the right lobe.

### ETIOLOGY

- **Sources:**
  - 1- Direct spread from biliary tract infection.
  - 2- Portal spread from GI infection (example: appendicitis, diverticulitis).
  - 3- Systemic source (bacteria).
  - 4- Liver trauma ( example: liver gunshot wound).

5- Cryptogenic (unknown source)

➤ **the two most common types are :**

- ♣ bacterial (most common in USA).
- ♣ amoebic (most common worldwide).

### 1. **Bacterial liver abscess:**

• The most common pathogens are gram negative bacteria: E.coli, Klebsiella and proteus.

• **Causes:**

- ♣ Cholangitis
- ♣ Diverticulitis
- ♣ Liver Ca/ metastasis

### 2. **Amebic liver abscess:**

➤ **Pathogens :**

Entameba Histolytica ( typically reaches the liver via portal vein from intestinal amebiasis).

➤ **Spread:** feco-oral transmission.

➤ **Risk factors :**

- Patients from south American borders.
- Institutionalized patients.
- Homosexual men.
- Alcoholic patients.



## **CLINICAL FEATURES**

### 1. **Signs and symptoms for Bacteria Abscess:**

- Fever and chills
- -RUQ (right upper quadrant) pain
- Jaundice
- weight loss
- ↑WBC
- ↑LFT
- sepsis

## 2. Sign and symptoms for Amebic abscess:

- RUQ pain.
- Fever (chills are much less common with amebic abscess than pyogenic).
- Diarrhea.
- Hepatomegaly (Most common site is the right lobe)



## TREATMENT

### 1. Bacterial Abscess:

- **Medical:** IV antibiotics (triple antibiotics with metronidazole)
- **Surgical:** percutaneous drainage with CT or U/S guidance.
- **Indications for operative drainage:**
  - Multiple/loculated abscesses
  - When multiple percutaneous attempts have failed.

### 2. Amebic Abscess:

- **Medical:**
  - Metronidazole.
- **Surgical:**
  - Percutaneous drainage is done in the following cases:
    - ♣ refractory to metronidazole.
    - ♣ bacterial co-infection.
    - ♣ peritoneal rupture.
  - Possible complication of large left lobe abscess : Erosion of pericardial sac (potentially fatal).

#### \*\*Diagnosis of Amebic abscess:

- Labs (Indirect hemagglutination titers for Entamoeba antibodies in 95% of patients and ↑ LFTs).
- U/S and CT.

# Hydatid disease of the liver

also known as echinococcosis or echinococcal disease

## INTRODUCTION

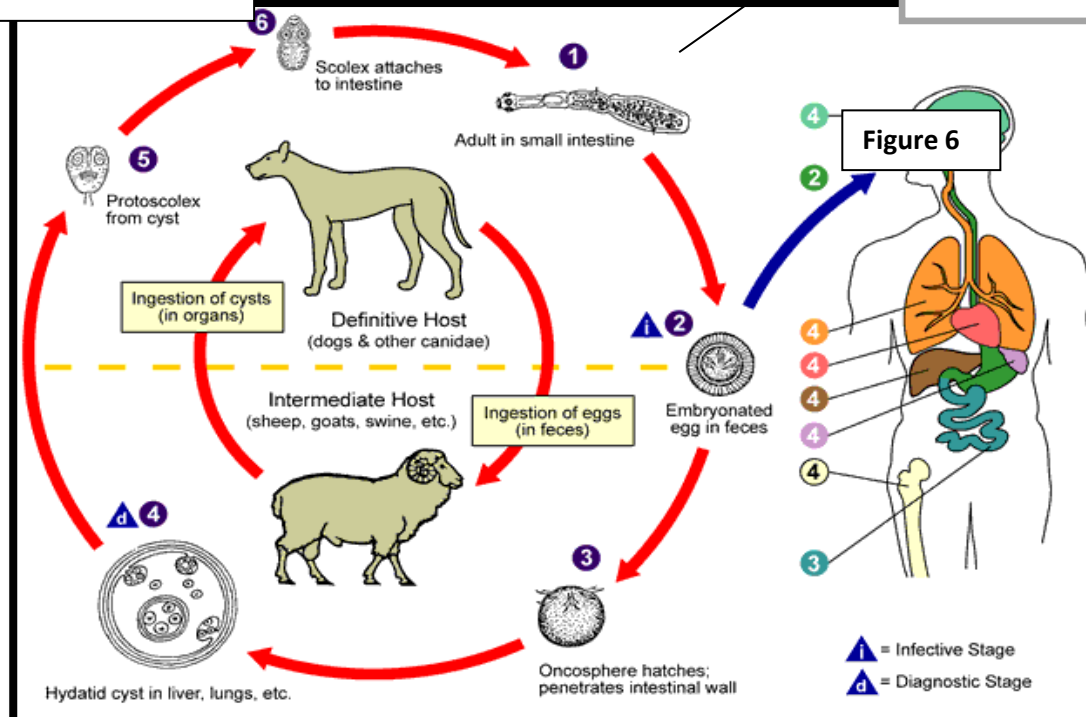
- ✓ It is a parasite disease of dog tape worm (Echinococcus), which affects humans in 2 forms depending on the larval stage:
  - I. Cystic Echinococcus : most common caused by Echinococcus granulosus
  - II. Alveolar Echinococcus : caused by Echinococcus multilocularis
- ✓ The disease affects both humans and animals like: dogs, pigs, camels, sheep, rodents, and horses.
- ✓ Life cycle: [Figure 6]

A year after the infection of dogs protoscolices are produced.

Morphology:

Head (scolex) → 2 rows of hooks, 4 suckers.

Body → 2-6 proglotid.



### Notes:

- The major (most common) intermediate host is the sheep (also pigs, horses, and camels).
- The major definitive host is the DOG (also foxes, and wolves)
- Infection of the intermediate host occurs after the ingestion of food contaminated with eggs containing embryos (oncospheres) passed from feces of the definitive host.
- Humans are infected via 2 ways: 1) direct contact with dogs 2) eating products contaminated by the feces of the definitive host, but never by eating infected intermediated host!!
- Humans are intermediate host if the dog ate human infected organs however this is not common so humans are considered end hosts.

✓ distribution of the disease:

I. Endemic areas are: Mediterranean countries, middle east, Asia, turkey, south America, Newzeland, and Africa.

II. Uncommon in USA and most of central Europe.

## ? ETIOLOGY

-The intermediate host (human) ingests the embryonated egg → the eggs which contain embryos (onchspheres) hatch and penetrate the wall of the intestines → the embryos reach the liver via the blood stream → the embryos may pass via the blood to other organs (mostly the lungs)

Once the embryos settle in an organ they form cysts.

Notes:

I. The liver is affected (diseased) in 60% of the cases while the lungs are affected in 30% of the cases. In 90% of the cases there is single organ involvement.

II. The Right lobe of the liver is mostly affected in 80% of the cases when the liver is affected, and in third of the cases the cysts are multiple.

### ➤ Components of the cyst:

- The cavity is filled with Hydatid fluid.
- The cyst has got 3 layers covering it from outside to inside →
  - I. Outer adventitial layer (pseudocyst) is an inseparable fibrous tissue due to reaction of the liver to the parasite. (coming from the host)
  - II. 2 inner layers coming from the parasite:
    - ♣ Outer laminated membrane (ectocyst) contains Hydatid fluid and can be readily peeled from the adventitia.
    - ♣ Inner germinal epithelium (endocyst) the only living part lining the cyst, this layer :synthesizes the laminated layer which is a mucopoly sacccharide –protein –lipid complex, and secretes the Hydatid fluid which is clear and similar to interstitial fluid .
- Sometimes a small cyst within the cyst exists, if this cyst was attached to the germinal layer it is called brood capsule, but if it was floating in the Hydatid fluid it is called daughter cyst.

- The Hydatid fluid or the rood capsule or the daughter cyst contain scolices which are heads of future worms.

#### Notes:

- The time required of Echinococcus granulosus to become mature (ready to infect humans or dogs) varies from 10 to 20 minutes
- Daughter cyst: also known as degenerated or secondary cyst have fragment of germinal layer and can develop by 2 ways:
  1. Develop within the primary cyst (as above)
  2. Develops separately
- Commonly the cysts in the liver after 5-10 years begin calcifying , the complete calcification indicates an old cyst but not necessarily a dead cyst .

#### ➤ Risk factors of infection:

- I. Travel.
- II. Exposure to dogs, and (sheep & cattle: although that we mentioned above that they are not infective).



## CLINICAL FEATURES

#### ➤ Signs and symptoms:

- Most of the times the cyst remain uncomplicated and the symptoms they induce are related to the pressure or mass size (when the size is > 10cm) they exert on the liver, so the signs and symptoms are:
  1. RUQ pain: most common symptom.
  2. Liver enlargement or palpable mass : 1-5 cm increase in size per year
  3. Jaundice and pressure symptoms.
  4. Sometimes the cyst ruptures or leaks some of its contents (suppuration) which may cause anaphylactic reactions which can be fatal or subclinical manifestations.
    - The rupture or suppuration may occur into:
      1. Biliary tree
      2. Thorax
      3. Peritoneum
      4. Vascular structure
      5. GI tract



➤ **Diagnosis:**

1. Blood tests:

- ♣ Most cases have limited eosinophilia due to the chronic presence of the parasite, or absent eosinophilia.
- ♣ If there was biliary communication: increased liver function tests.

2. Serology:

- ♣ for detection of anti Echinococcus antibodies (AKA indirect hemagglutination test).
- ♣ Antibodies detection is more sensitive than detecting serum antigens (IHA detection by ELISA)
- ♣ More informative in Echinococcus multilocularis than granulosis
- ♣ PCR technology is used in this test.

3. Imaging:

- ♣ Plain X ray.
- ♣ Ultra sound: shows➔
  1. Simple pyogenic cyst vs paracytic cyst.
  2. Abscess , neoplastic masses vs parasitic cyst: by detecting the membranes of the cyst.
  3. Detects Hydatid sand sign ( scolices appear as sand) : this sign is diagnostic in most cases
  4. Active vs. inactive: water lily sign.
  5. Eggshell appearance in calcified cyst.

Classification upon ultra sound findings

Hassan Gharbi classification:

- type I. Cyst with pure fluid collection
- type II. Cyst with variable morphology, detached membrane or split wall (water lily sign)
- type III. Multiple septa and/ or daughter cyst
- type IV. High internal heterogenous echos

WHO classification: depends on ➔

- Final state of the parasite: active / inactive/ transitional
- Size: small <5cm / medium 5-10 cm/ large>10 cm

♣ CT:

- Sensitivity reaches 100%.

- Determines size, location, number, and presence of intrahepatic lesions.
- More sensitive in detecting minimal calcifications.
- BUT !! U/S is more informative regarding wall cyst changes.

- ♣ MRI
- ♣ MRCP/ERCP



## TREATMENT

### 1. Chemotherapy:

- Alone is not useful, so it should be combined with other modalities of treatment.
- Albendazole (ABZ) and ABZ sulfoxide (the active metabolite) are the most effective adjuvant chemotherapy.

ABZ alone can cure 10-30% of cases, and causes degeneration of the cyst in up to 92% of the cases, so it should be combined with percutaneous drainage or surgery)

#### ➤ Indications of medical treatment:

- ♣ Inoperable or unfit patient.
- ♣ patients with multiple cysts in more than 2 organs
- ♣ Multiple small liver cyst or cysts deep in the liver.
- ♣ Peritoneal cyst.
- ♣ Patients following incomplete surgery or relapses.
- ♣ Prevention of secondary of echinococcal infection following percutaneous rupture or aspiration of the cyst.

### 2. Percutaneous drainage:

- Some studies show that percutaneous drainage in combination with chemotherapy is SAFE and EFFICIENT / LOWER COMPLICATIONS/ and BETTER POST OP RECOVERY.

BUT!! In surgical recall , it is mentioned that you should never do percutaneous drainage due to the risk of leakage into the peritoneal cavity (anaphylaxis).

### 3. surgery: the mainstay of treatment

#### ➤ Principles or characteristics:

1. Eradicates the parasite in > 90% of cases.
2. Avoids spillage.
3. Obliterates the residual cavity.

➤ Indications:

1. Superficial cyst with risk of rupture
2. Large cyst >10 cm with many daughter cysts
3. Cystobiliary communication
4. Mass effect on vital organs
5. Infected cyst
6. Any extrahepatic localized cyst

➤ Surgical options:

Radical approach:  
includes➔

- ♣ Cystectomy
- ♣ Pericystectomy
- ♣ Liver resection

\*Less recurrence

Conservative approach: includes➔

- ♣ External drainage.
- ♣ Wide roof excision.
- ♣ Evacuation and sterilization of the cavity.
- ♣ Capitannage.
- ♣ Marsipulization.
- ♣ Partial cystopericestectomy.
- ♣ Near total percystectomy.

Easy to perform and less operative risk, but higher recurrence rate 10-50%

In conservative approach consider: if there was a wide communication  
➔ do: biliary bypass / sphincteroplasty/ ERCP & endoscopic sphincteroplasty/ CBD exploration and T- tube insertion.

➤ The surgery can be laparoscopic or open:

During surgery there is toxic irrigation with scoliocidal agents before cyst removal to prevent recurrence, the agents used are➔

1. Hypertonic saline 10-20% for 5-10 minutes.
2. Peroxide solution 10%.
3. Chlorhexidine.
4. cetrimide

➤ Contraindications of laparoscopic surgery:

1. Cholangitis due to communication.
2. Liver cirrhosis
3. Recurrent cyst

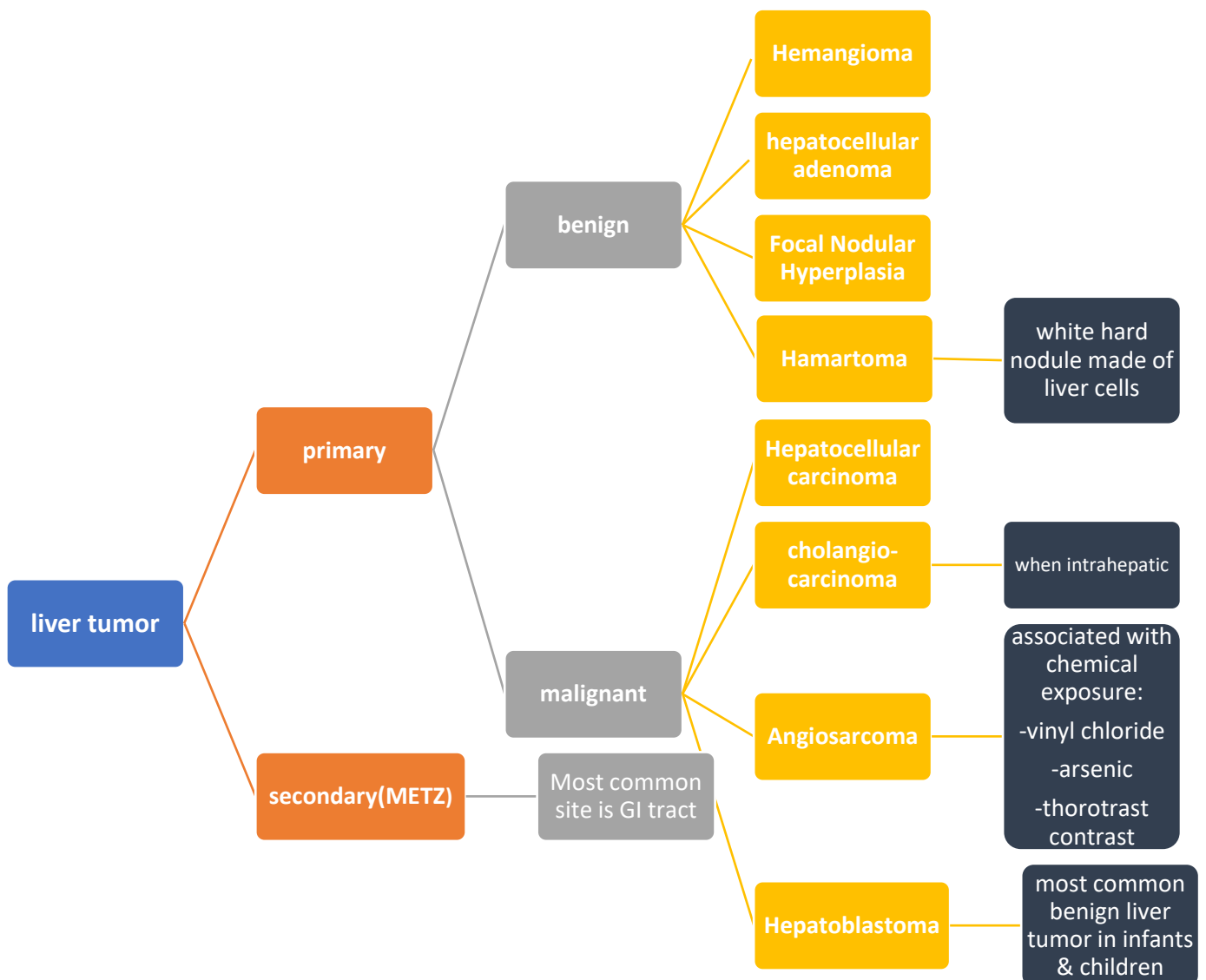
4. Complicated cyst with rupture or infection
5. Deep intraperitoneal cyst
6. Cyst in the posterior segment
7. Cyst close to major vessel
8. >3 cysts
9. Thick calcified wall cyst

➤ Post op complications:

1. Infection of the residual cavity.
  2. Intra abdominal abscess.
  3. Anaphylactic reactions.
  4. Spillage of parasite material → 2ry echinococcosis.
  5. Biliary fistulation.
  6. Sclerosing cholangitis.
-

# Tumors of the liver (In general)

- Most common liver CA is METZ ( it is way more common than primary tumors of the liver 20:1 and the primary of metz site is usually the GI tract)
- Most common primary malignant liver tumor is hepatocellular CA (also called hepatoma or HCC)
- Most common primary benign liver tumor is hemangioma
- Right hepatic lobectomy: removal of the right lobe of the liver , i.e.: removal of all liver tissue to the right cantles line.
- Lt hepatic lobectomy: removal of left lobe of the liver, i.e.: removal of all liver tissue to the left of cantles line.
  - Trisegmentectomy: removal of all liver tissue to the Right of the falciform ligament.
- Study the following diagram carefully:



# Primary benign tumors

## 1. Hemangioma

### INTRODUCTION

- The most common primary benign liver tumor (up to 7% of the population)
- It is a benign vascular tumor of the liver.

### CLINICAL FEATURES

➤ **Signs & symptoms:**

*Asymptomatic in 85%.*

1. RUQ pain/ mass.
2. Bruits.

➤ **Complications:**

1. Pain.
2. Congestive heart failure due to AV shunt.
3. Coagulopathy due to sequestration of platelets.
4. Gastric outlet obstruction due to compression over gastroduodenum
5. Kasabach-Meritt syndrome:  
hemangioma+thrombocytopenia+fibrinogenopenia+ *disseminated intravascular coagulation ??*
6. Hemorrhage

➤ **Diagnosis:**

1. CT scan with IV contrast
2. Tagged red blood scan
3. MRI
4. Ultra Sound

Note: biopsy shouldn't be performed due to risk of hemorrhage with biopsy.

### TREATMENT

- Observation in >90% of cases.
- Resection if:
  - Symptomatic.

- Hemorrhage.
- Cannot be diagnosed depending on the previous investigations.

## 2. Adenoma



### INTRODUCTION

- This tumor histologically consists of normal hepatocytes without bile duct or *kupffer cells*
- Risk factors:
  1. Female : male ratio = 9:1
  2. Birth control pills (think ABC = Adenoma Birth Control)
  3. Anabolic steroids.
  4. Glycogen storage disease.



### CLINICAL FEATURES

- Signs & symptoms:
  1. RUQ pain/ mass/ fullness
  2. Bleeding
- Complications:
  1. Rupture with bleeding.
  2. Necrosis.
  3. Pain.
  4. Risk of hepatocellular carcinoma.
- Diagnosis:
  1. CT.
  2. Ultra Sound.
  3. ±biopsy but rule out hemangioma with tagged red blood cells scan first.



### TREATMENT

- If small → stop pills → it may regress  
→ If didn't regress → surgical resection is necessary.
- If large (>5 cm)/ bleeding/ painful/ rupture → surgical resection.
  - ❖ Note: average age: 30-35 years of age.

# 3. Follicular Nodular Hyperplasia (FNH):



## INTRODUCTION

- It is hyperplasia of liver containing all components of liver in disorganized pattern so histologically the tumor consist of normal functioning liver tissue with bile ducts.
- Second most common benign liver tumor.
- **Risk factors:**
  1. Female
  2. Birth control pills, however they are more associated with adenomas than with FNH.



## CLINICAL FEATURES

- **Diagnosis:**
  1. Nuclear Technetium -99 study.
  2. Ultra Sound.
  3. CT scan, the findings are: liver mass with central scar.
  4. Angiogram.
  5. Biopsy.
- **Complications:**
  1. Pain.
  2. Hemorrhage, very rare.
  3. No risk of CA, unlike adenoma.



## TREATMENT

- If symptomatic → resection or **embolization**.
  - Why does embolization work with FNH?
  - Because this tumor is usually fed by one major artery.
- If asymptomatic → follow up if diagnosis is confirmed + stop birth control pills.
  - ❖ Note: average age is around 40 years of age.



# Primary malignant liver tumors:

## 1. Hepatocellular carcinoma (HCC)

AKA: hepatoma.



### INTRODUCTION

- Most common malignant primary liver tumor, the incidence is 80% of all primary malignant liver tumors.
- **High risk areas: Africa & Asia.**
- **Risk factors:**

Most important risk factors

1. Hepatitis B
2. Cirrhosis: 5% of patients with cirrhosis will develop HCC.
3. Aflatoxin (fungi toxin of *Aspergillus Flavus*).
4.  $\alpha$ 1 -antitrypsin deficiency
5. Hemochromatosis.
6. Liver fluke.
7. Anabolic steroids.
8. Polyvinyl chloride.
9. Glycogen storage disease.



### CLINICAL FEATURES

- **Signs & Symptoms:**

1. Dull RUQ pain
2. Hepatomegaly
3. Abdominal mass
4. Weight loss
5. Paraneoplastic syndrome
6. Signs of portal hypertension
7. Ascites
8. Jaundice
9. Fever
10. Anemia
11. Splenomegaly

Classic presentation: painful hepatomegaly

- **Investigation:**

1. Tumor marker: increase in  $\alpha$ -feto protein.

2. Ultra Sound.
3. CT.
4. Angiogram.
5. tissue biopsy with CT / Ultra Sound/ or laproscopic guidance : the most common way to diagnose HCC



## TREATMENT

- Surgical resection: if possible , ex: lobectomy.
- Liver transplant, the indications are listed in the adjacent box.

### Indications for liver transplant:

- Cirrhosis and no resection candidacy as well as no distant lymph node mets and no vascular invasion.
- The tumor must be single and less than 5 cm or have three nodules with none larger than 3 cm.

### **Extra super important note:**

#### **Fibrolamellar hepatoma:**

- Is a rare histologic variant of HCC. However, there is considerable evidence that FLC is distinct from HCC in its epidemiology, biology, and prognosis.
- Males and females are equally affected, commonly at a younger age (20 to 40 years old).
- It is uncommon for FLC to be associated with underlying liver disease such as cirrhosis.
- The histology of FLC strongly resembles that of FNH, but any etiologic association between them remains unproven. FLC appears as a hypoattenuated, well-defined, solitary mass on nonenhanced CT scan. On contrast-enhanced CT, the cellular portion enhances homogeneously; the central scar usually does not enhance, unlike the scar of FNH.
- $\alpha$  Fetoprotein is often not elevated in FLH
- FLC is best treated with complete surgical resection, which is possible in 80% of patients.
- Resectable FLC is associated with a better prognosis than HCC, with a 5-year survival rate greater than 70%. Late recurrence occurs in more than two-thirds of cases, and repeat resection of local disease should be considered.
- Liver transplantation is an option for unresectable but nonmetastatic lesions.

# Hemobilia

## INTRODUCTION

- Bleeding commonly from the liver or occasionally from the gallbladder into the Biliary tract, it indicates abnormal communication between a blood vessel and a bile duct or any part of the Biliary tree. This blood is drained via CBD into the duodenum.
- **Causes:**
  - Medical interventions (PTC, ERCP) → most commonly
  - Trauma with liver laceration
  - Vascular disease of the hepatic artery
  - Tumors: malignant ones being more common in causing hemobilia than benign.
  - gallbladder and bile duct stones, biliary parasites (eg, *Ascaris lumbricoides*), , biliary varices, pancreatitis, and hepatitis.

## CLINICAL FEATURES

- **Signs and symptoms** : Sandblom/ Quincke's triad:
  - RUQ colicky pain
  - Obstructive jaundice
  - Hematemesis and melena(Guaiac +ve)
- **Diagnosis:**
  - Based on signs & symptoms.
  - Investigations ,which are:
    - endoscopy (upper GI scopy) : finding of blood out of the ampulla of vater
    - Angiogram : test of choice in detecting bleeding site

All three symptoms of triad are seen only in 20% of cases but:

- RUQ pain occurs in 70% of cases
- Obstructive jaundice occurs in 60% of cases
- hematemesis occurs in 60% of cases, & melena occurs in 90% of cases.

\*just understand the idea; don't memorize the percentages of symptoms.

## TREATMENT

- The aim is to stop bleeding and to relieve Biliary obstruction and the best intervention is → Angiogram with embolization of the bleeding vessel also called: Trans Arterial Embolization (TAE).

# Portal hypertension

## INTRODUCTION

- It is a sustained elevation of venous portal pressure more than 10 mmHg.
- Note: the normal portal pressure is < 10 mmHg.
- Anatomy of the portal vein :

[Figure 7]

- Inferior Mesenteric Vein (IMV) drains in the splenic vein → the splenic veins unite with the Superior Mesenteric Vein (SMV) to form → the portal vein.
- There are 6 potential routes of portal –systemic collateral blood flow (areas of communication):
    1. Umbilicus: between paraumbilical vein and anterior abdominal vein.
    2. Lower end of esophagus: between (left gastric and short gastric) with azygos vein.
    3. Retroperitoneal veins (veins of Retzius) which communicate with the systemic venous circulation via the lumbar vein
    4. Diaphragm veins (veins of sappey).
    5. Lower end of rectum: between superior hemorrhoidal vein and (middle and inferior hemorrhoidal veins and then to the iliac vein).
    6. Splenic vein to the short gastric vein.

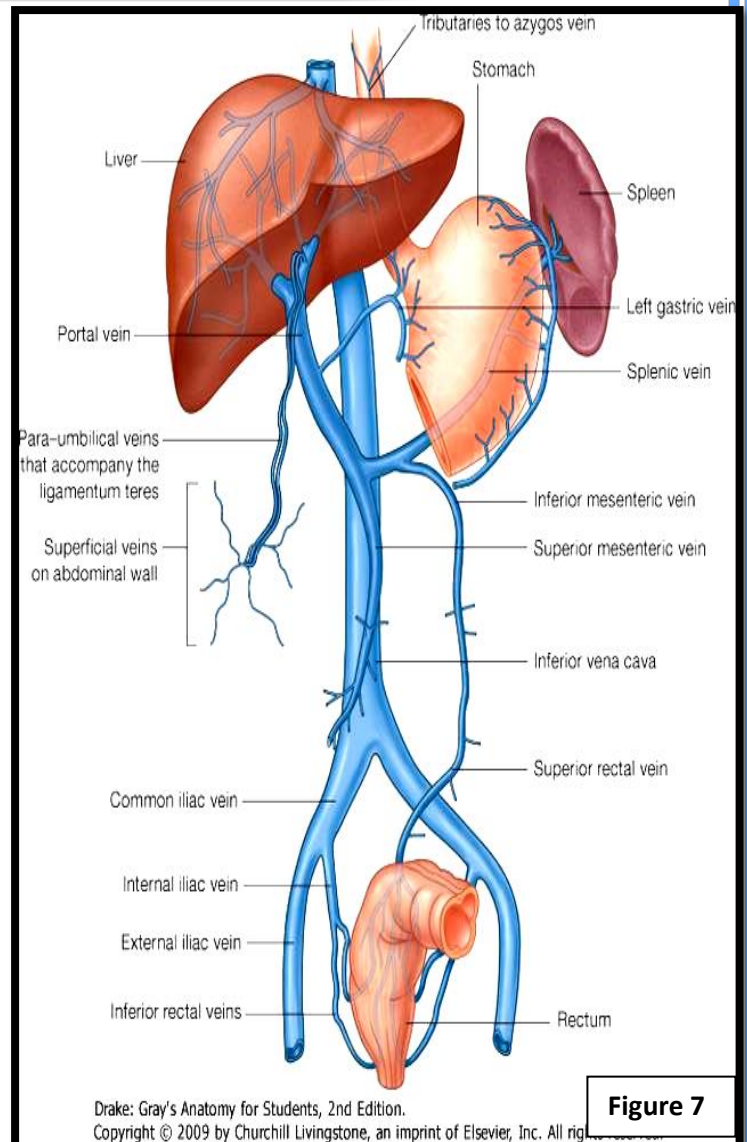


Figure 7

## PATHOPHYSIOLOGY

### ➤ Pathophysiology of portal hypertension:

Increased resistance to portal flow → results in increased portal venous pressure, this increased resistance may be:

I. Prehepatic: due to blockage of the portal vein before the liver can be due to → portal vein thrombosis, splenic vein thrombosis, or atresia of portal vein

II. Hepatic: due to distortion of the liver architecture which can be caused by → cirrhosis (distortion of normal liver parenchyma by degenerating hepatic nodules), Hepatocellular Carcinoma, or hepatic fibrosis

♣ Note: 2/3 of patient with cirrhosis develop portal hypertension.

III. Post-hepatic: due to venous blockage outside the liver (rare).

caused by → prolonged severe right heart failure with tricuspid incompetence, constrictive pericarditis, veno occlusive disease (like: Budd-Chiari syndrome: see the adjacent box)

**Budd-Chiari syndrome:** a syndrome due to obstruction to the venous outflow of the liver owing to occlusion of the hepatic vein. In one third of the cases the cause is unknown, but specific causes include hypercoagulability states, thrombophilia, tumors like: renal or adrenal tumors.

## CLINICAL FEATURES

### ➤ signs & symptoms:

1. splenomegaly: the most common physical finding in patients with portal hypertension.
2. esophageal varices: engorgement of the esophageal venous plexus due to backing up of blood (increased collateral blood flow) from left gastric vein (also called coronary vein) and short gastric vein into the systemic venous system via the Azygos vein.
3. Caput medusa: due to backing up of blood from the paraumbilical vein via the falciform ligament into the epigastric veins (also called anterior abdominal veins).

4. Hemorrhoids: due to blood backing up from the superior hemorrhoidal vein which drains into the inferior mesenteric vein into the systemic venous system via the middle and inferior hemorrhoidal veins.
5. Signs and symptoms of liver cell failure or chronic liver disease: spider angioma, palmer erythema, ascitis , truncal obesity and , confusion and drowsiness due to neuropsychiatric complications (portosystemic encephalopathy), asteraxis (hepatic flap).

**Portosystemic encephalopathy:**

Pathophysiology: accumulation of toxic metabolites which should have been metabolized by the liver in the brain

2 types :

- ➔ chronic neuropsychiatric syndrome secondary to : cirrhosis
- ➔ acute which is secondary to acute hepatic failure , in patients with portal hypertension due to spontaneous shunting or in those with surgical or TIPS shunts (TIPS & surgical shunts are discussed below)

6. Jaundice.

- ❖ Note: retroperitoneal varices may appear as a result of blood backing up into the systemic venous system via the lumbar vein.

In addition to the symptoms mentioned above (drowsiness & confusions), signs may include:

- feto hepaticus
- asterixes

➤ **Complications:**

- The most feared complication is bleeding from esophageal varices, the mortality rate from acute esophageal variceal bleeding is 50%.
- The diagnosis of esophageal varices is based on: signs and symptoms + confirmed by endoscopy



## TREATMENT

- Treatment of esophageal varices :
  - ♠ Management can be divided into the active bleeding episode, the prevention of rebleeding, and prophylactic measures to prevent the first hemorrhage.
    - ♣ Initial management of active bleeding episode:
      - I. **Resuscitation:**
        - IV line insertion ( 2 large bore cannulas)
        - IV fluid
        - Foleys catheter
        - Obtain blood for grouping and crossmatching
        - Send labs: liver biochemistry and blood cultures
        - Correct coagulopathy: use vit K and fresh frozen plasma
        - ±intubation to protect from aspiration
      - II. **Urgent endoscopy:** both diagnostic and therapeutic

**Diagnostic:** to confirm the diagnosis of varices, it also excludes other causes of bleeding such as bleeding gastric ulcer

**Therapeutic:** used in 2 ways to stop the bleeding:

Injection sclerotherapy: a needle is passed down the biopsy channel of the endoscope and a sclerosing agent is injected into the varices , this may arrest bleeding by producing vessel thrombosis.

Variceal banding: the varices can be banded by mounting a band on the tip of the endoscope, sucking the varix just into the tip of the scope and dislodging the band over the varix using a tip wire mechanism.

### III. Other measures available:

- Medical treatment: Vasoconstrictor therapy, the main use of this is for emergency control of bleeding while waiting for endoscopy and in combination with endoscopic techniques. Vasoconstrictors reduce bleeding by restricting portal blood flow by splanchnic (mesenteric) arterial constriction.

Agents used: somatostatin (octreotide) / IV vasopressin called Terlipressin which should be given with nitroglycerine in patients with ischemic heart disease as a result of the generalized vasoconstriction it causes.

- Balloon tamponade: if bleeding continues

#### IV. **Additional management of acute episodes:**

\*If sclerotherapy and conservative methods failed to stop the variceal bleeding or bleeding recurs:

- Repeat sclerotherapy/ banding & treat conservatively
- Transjugular intrahepatic portocaval shunt (TIPS):

Used when bleeding cannot be stopped after 2 sessions of endoscopic therapy within 5 days.

A guidewire is passed from the jugular vein into the liver and an expandable covered metal shunt is placed over it to form a channel between the systemic (hepatic vein) and the portal circulation (portal vein).

Advantages: it reduces the portal vein pressure by creating a total shunt and doesn't have the risk of general anesthesia and surgery.

Disadvantages: increased risk of portosystemic encephalopathy.

- **Surgical shunt:**

Used when other methods fail or if TIPS is not available and particularly when the bleeding is from gastric fundal varices.

Types:

1. Partial shunt: shunt that directly decompress the portal vein but only partially
2. Selective shunt (Warren): distal splenorenal shunt with ligation of the coronary vein (left gastric vein). It is associated with decreased incidence of portosystemic encephalopathy, however it is contraindicated in patients with ascitis.

#### **Notes:**

1. The most common perioperative cause of death following shunt procedure is hepatic failure secondary to reduced blood flow
2. Major postop morbidity after shunt procedure is: increased incidence of hepatic encephalopathy (portosystemic encephalopathy) because of



reduced portal blood flow to the liver and decreased clearance of toxins / metabolites from the blood.

3. What lab value roughly correlates with the degree of encephalopathy?  
Serum ammonia level, note that it is thought to correlate with encephalopathy but not as a cause of encephalopathy.
4. Treatment of hepatic encephalopathy (portosystemic encephalopathy):
  - a) Lactulose (oral): an osmotic purgative that reduces the colonic pH and limits ammonia absorption. Please note that we said that ammonia is not a cause of encephalopathy.
  - b) ± neomycin (oral): the latest recommendations recommend avoiding neomycin and giving Rifaximin or metronidazole → the source is Kumer and Clark's clinical medicine 7<sup>th</sup> edition

♣ **Prevention of rebleeding:**

Using a combination of medical measures (e.g. no selective beta blockers), endoscopic measures (e.g. variceal banding at 2 weekly intervals which leads to obliteration of the varices), and surgical measures (e.g. surgical shunts).

♣ **Prophylactic measures to prevent the first bleed:**

Patients with cirrhosis and varices that have not bled should be prescribed non-selective beta blockers, this reduces the chances of upper GI bleeding, may increase survival, and is cost effective.

# Summary & past papers

## Summary

- Hepatic diverticulum just proximal to the ampulla of Vater same area as pancreatic duct. It arises at the ventral aspect and rotates clockwise. The liver is covered by peritoneum except for the bare area of the liver, it's also covered by fibrous capsule which is sensitive for visceral pain. It's segmented into 8 segments with different blood supply for surgical causes. 25% of blood supply comes from the celiac trunk (delivers 50% of oxygen), and 75% of blood supply comes from the portal vein (delivers 50% of oxygen).
- **Child's and MELD scores** are used to estimate hepatic reserve in liver injury.
- **LFT** include **AST** (also elevated in MI and skeletal damage) and **ALT** (more specific) → from liver parenchyma, **ALP** (phosphatase) (also from bone and placenta) and **GGT** → from bile cells, **PT**, **bilirubin** and **albumin**.
- **Clinical jaundice** when bilirubin is >2.5 g/dl, it's either direct (hepatic or posthepatic) or indirect (prehepatic).
- **Abscesses of the liver** are either **bacterial** (e coli, klebsiella, proteus from cholangitis or diverticulitis or unknown origin) with symptoms like those of cholecystitis but with ill looking patient treated by IV abx and percutaneous drainage and surgical when indicated. Or **amebic** (entamoeba histolytica by fecal-oral transmission) where it has similar symptoms of bacterial with more chills and diarrhea, treated with metronidazole (90% will resolve) if refractory percutaneous drainage is done.
- **Hydatid disease of the liver** (caused by tapeworms which invade the human liver as an end host when transferred with dog feces), the lung is the second most common organ affected after the liver. The cyst is calcifications indicates old cyst. Symptoms are RUQ pain with pressure symptoms and is diagnosed by serology and imaging (x-ray, U/S, CT and MRI), treated with Albendazole and drainage or surgery when indicated. Complications of hydatid cyst include rupture (most common), infection and anaphylaxis.
- **Tumors** of the liver are benign or malignant, primary or secondary. M.c benign liver tumor is hemangioma, m.c primary malignant tumor is HCC but most common malignant tumor is mets. **Hemangiomas** present as RUQ pain/mass diagnosed with CT with contrast and shouldn't be biopsied because hemorrhage may happen, it should be observed or resected if indicated. **Hepatic adenomas** are benign tumors with risk for CA transformation, OCPs and anabolic steroids are RF, diagnosed by imaging or biopsy, if small stop OCP and resect only if persistent, if large (>5cm), bleeding or ruptured do resection. **Focal nodular hyperplasia** is also benign in >40 yrs also associated with OCPs with no risk of CA transformation, diagnosed as adenoma, treated with resection or embolization (as it's supplied by one major artery). **HCC**

risk factors include Hep B, cirrhosis, aflatoxin and others. Presents as RUQ pain and hepatomegaly, tumor marker is  $\alpha$  fetoprotein, m.c site of mets is the lung, diagnosed with needle biopsy with CT or U/S and treated by surgical resection or transplant as indicated.

**Fibrolamellar hepatoma** is variant of HCC in younger age groups, with better prognosis and often not elevated  $\alpha$  fetoprotein.

- **Hemobilia** is blood draining via CBD into the duodenum, presents as RUQ pain, jaundice and Guaiac +ve. Caused most commonly by medical interventions (PTC, ERCP), trauma, tumors and bile stones. Diagnosed by endoscopy, treated with A-gram with embolization of the vessel.
- **Portal HTN** caused by prehepatic causes (portal vein thrombosis), hepatic (cirrhosis), posthepatic (budd-chari syndrome). M.c complication is esophageal varices.

### Past papers

1. True about fibrolamellar HCC
  - a. **The rest of the liver is normal (high AFP is not a characteristic of this HCC type).**
2. The most common complication of hydatid cyst of the liver is?
  - a. Cyst infection
  - b. **Rupture into the biliary tree**
3. Liver tumor in patient who was taking OCPs for long time:
  - a. **Adenoma**
4. Not part of MILAN criteria for liver transplantation:
  - a. **4 small tumors < 4 cm**
  - b. No extrahepatic manifestations
  - c. No vascular invasion
5. Most common incidental solid liver tumor is:
  - a. **Hemangioma**
  - b. Hepatic adenoma
6. one of the following is true about hydatid cyst
  - a. **IHA-scrology is the most specific**
7. Not an indication for hydatid cyst resection
  - a. **A total calcification**
8. Protein not synthesized in the liver
  - a. Factor II
  - b. Transferrin
  - c. Ferritin
  - d. **Von Willebrand factor**
9. Liver adenoma 6 cm for a female taking OCP:
  - a. Stop OCP
  - b. **Surgical excision**
  - c. Observe
10. Not in child criteria for liver cirrhosis:
  - a. **AST**
11. all are true about liver embryology except :
  - a. bile synthesis start by 12th wk
  - b. **liver comes from dorsal segment of mesentery that rotate counterclockwise**
12. in liver transplant, one is wrong:
  - a. **the most common indication is hepatocellular CA (It's chronic hep c)**
  - b. one donor can give several transplant
  - c. liver transplanted in heterotopic location
  - d. liver mets is relative contraindication to transplant
13. All can cause hyperglycemia except
  - a. corticosteroids
  - b. **liver disease**
  - c. acute MI
  - d. TPN
14. All are correct regarding Carcinoid Except:
  - a. **Carcinoid of the liver is associated with the syndrome**
  - b. Small intestinal carcinoid is associated with the syndrome
15. Pyogenic liver abscess cause, all except
  - a. RUQ pain
  - b. **Diarrhea**
  - c. Fever
  - d. Anorexia
  - e. Tenderness
16. Gastroduodenal artery from which artery??
  - a. **Hepatic**
17. One is true regarding the orientation of CBD, hepatic artery and portal vein ??
  - a. **K8CBD right, hepatic artery left. portal vein posterior**
18. Neonatal jaundice 6 hour after birth can be caused by:
  - a. biliary atresia
  - b. neonatal hepatitis
  - c. **hemorrhagic disease of newborn**
19. Hepatocellular carcinoma tumor marker is:
  - a. **AFP**

20. a case of female patient evaluated was found to have hepatic adenoma > 7cm , she is on OCPs , what to do:
- Stop OCPs
  - Observe and follow up in the next month
  - Excision of adenoma**
21. HCC (hepatocellular carcinoma) all are true except:
- It follows geographical distribution of HBV
  - Increased by smoking and alcohol
  - Commonly metastasizes to lung, bone and peritoneum
  - Percutaneous biopsy is done for suspected lesion if operative intervention will be done**
22. All the following involve the extrahepatic duct except
- Allaigle disease(it's a disease of intrahepatic bile duct)**
23. Hepatic encephalopathic is precipitated by all except
- infection
  - narcotics
  - occlusion of porto systemic shunt**
  - hypokalemia

# Gall bladder & biliary tree

## INTRODUCTION

### ➤ **Anatomy:** [Figure 1]

- It is a pear shaped reservoir located in a fossa in the inferior surface of the liver.
- Fundus of the gallbladder is in the transpyloric plane (L1).
- The ampulla of Vater opens in the 2<sup>nd</sup> part of the duodenum.
- Both gall bladder neck and cystic duct contain mucosal folds called valves of Heister.
- Ducts of Luschka: small ducts that drain bile directly into the gallbladder from the liver, it has clinical importance as the leakage from these unligated ducts post-cholecystectomy may result in post-op epigastric pain. (Surgeons don't ligate them during surgery because of their small size).
- 10% of people have accessory cystic artery.

### ➤ **Callot's triangle:** [Figure 2]

#### ♣ **Boundaries (3 C)**

1. Cystic duct
2. Common hepatic duct
3. Cystic artery

#### ♣ **Contents:** calot's node

#### ♣ **Clinical importance:** used as a guide for cystic artery and duct during surgeries.

### ➤ **Physiology:**

#### ➤ **Function:**

- Storage of bile and secreting bile in response to CCK(cholecystokinin) and vagal response.
- Bile = cholesterol + leicithin +bile acid+ bilirubin
- Bile emulsifies fat.

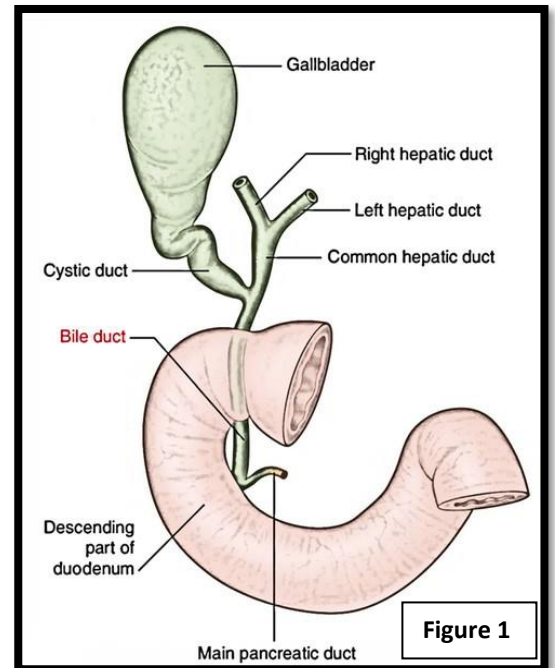


Figure 1

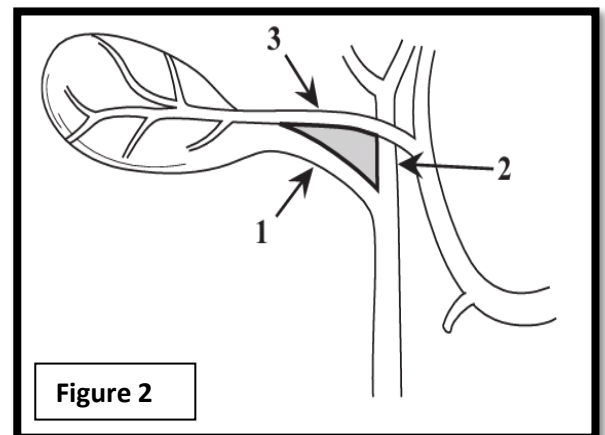


Figure 2

- Mainly produced by the liver. It's secreted to the intestines (from the 2<sup>nd</sup> part of the duodenum) and reabsorbed mainly to the terminal ileum
- CCK is secreted from duodenal mucosal cells as a response to fat (mainly), amino acids, proteins and HCl.
- CCK is inhibited by Trypsin and Chemotrypsin, which are secreted from the pancreas.
- Functions of CCK
  1. GB emptying
  2. Opening of ampulla of Vater
  3. Slowing gastric emptying
  4. Pancreatic acinar cell growth and release of exocrine pancreatic products.

➤ Enterohepatic circulation:

[Figure 3]

-Circulation of the bile acids from the liver to the intestines and back to the liver.

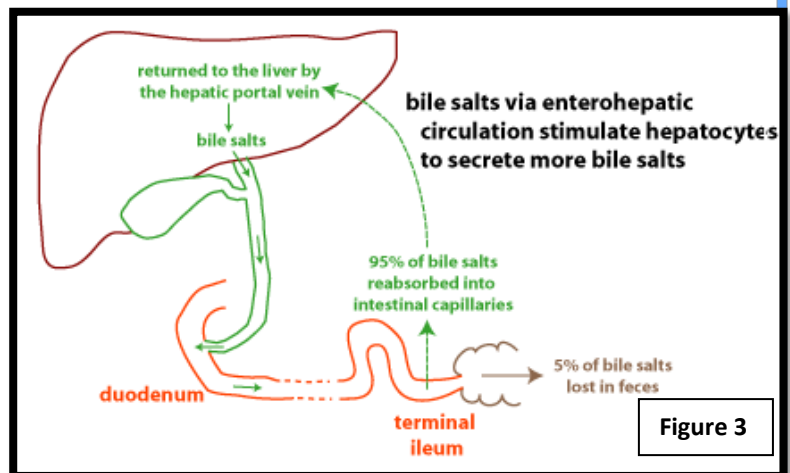


Figure 3

## ⚡ PATHOPHYSIOLOGY

- When total bilirubin > 2.5 → clinical detection of jaundice.
- The 1<sup>st</sup> anatomic location where jaundice appears is under the tongue.
- The bile duct epithelium is the source of alkaline phosphatase so we expect it to be raised in the case of bile duct obstruction.

➤ Definitions:

- **Cholelithiasis:** gallstones in GB.
- **Choledocholithiasis:** stones in the CBD.
- **Cholecystitis:** inflammation of GB.
- **Cholangitis:** infection of the biliary tract.
- **Cholangiocarcinoma:** adenocarcinoma of the bile duct.
- **Klatskin's tumor:** cholangiocarcinoma at the site of junction of the right and left hepatic ducts.
- **Biloma:** intraperitoneal bile fluid collection.
- **Choledochojejunostomy:** anastomosing the CBD and the jejunum.

- **Hepaticojejunostomy:** anastomosing the hepatic ducts or CBD to jejunum
- **Biliarycolic:** pain from gallstones (usually from stone in the cystic duct), located in the RUQ/epigastrium or right subscapular region of the back. Lasts minutes to hours but eventually goes away, and it's often postprandial( after meals, esp. Fatty food).
- **Hydrops GB:** Complete obstruction of the cystic duct by gallstones with filling of GB with sterile fluid from GB mucosa.
- **Mucocele:** sterile collection of secretions.
- **Biliary sludge:** viscous mixture of mucin glycoproteins, calcium bilirubinate and cholesterol crystals inside the GB or the biliary tree. (Can produce the same symptoms produced by the stone).
- **Nucleation:** the precipitation of cholesterol crystals from saturated bile.



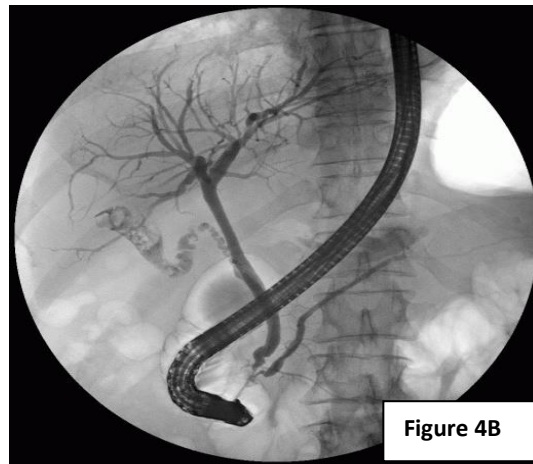
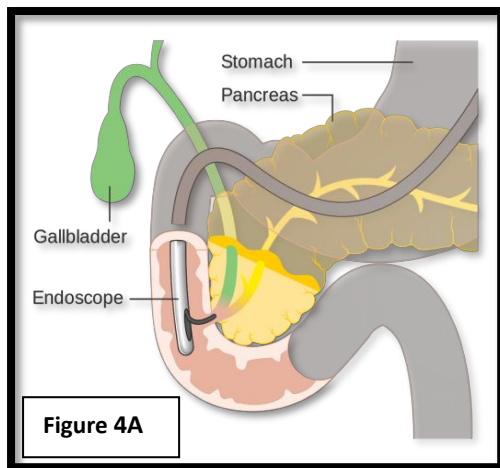
## DIAGNOSIS

### **\*\*Signs and symptoms of obstructive jaundice \*\***

- 1) Jaundice.
- 2) Tea-colored urine.
- 3) Clay-colored stool.
- 4) Pruritis( i.e. itching, due to deposition of bile salts (not bilirubin) in the dermis).
- 5) Loss of appetite.
- 6) Nausea.

### **\*\*Diagnostic studies\*\***

- I. **Endoscopic Retrograde Cholangio-Pancreaticography (ERCP):** [Figure 4]  
Through a side viewing gastro duodenoscope, sphincter of Oddi is cannulated, and dye is injected. Biliary and pancreatic trees are visualized.



- **Indications:**
  - a. Malignancy: appears as irregular filling defect.
  - b. Chronic pancreatitis: chain of lakes appearance.
  - c. Congenital anomalies.
  - d. Stones.
  - e. Stricture of biliary tree.
  - f. Choledocal cyst.
  - g. For sampling of biliary and pancreatic juices for analysis and cytology.
  - h. Brush biopsy from tumor site.
- ERCP can be therapeutic and used in the following cases:
  - a. Extraction of stone from biliary tree.
  - b. Nasobiliary drainage.
  - c. Stenting of tumor in the CBD or in the pancreas.
  - d. Dilatation of the biliary stricture.
  - e. Endoscopic papilotomy.
- **Complications:**
  - a. Pancreatitis
  - b. Duodenal injury, perforation.
  - c. Cholangitis.
  - d. Bleeding from pancreaticoduodenal artery.
  - e. Sphincter stenosis.
- **Relative contraindications:**
  - a. Acute pancreatitis
  - b. Previous gastrectomy (The anastomosis done makes ERCP difficult to be done).



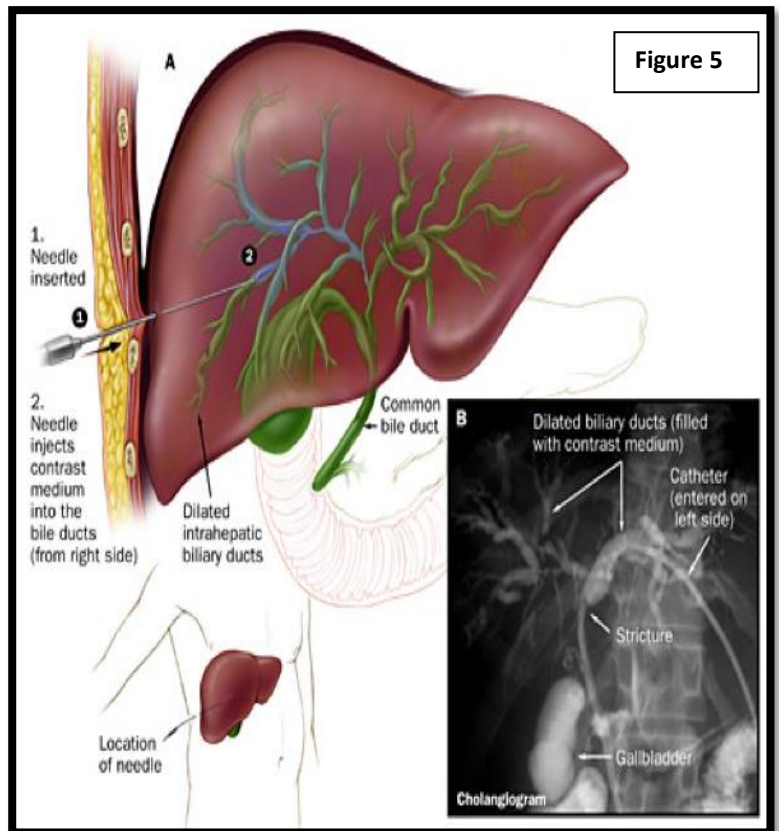
## II. Percutaneous Transhepatic Cholangiography (PTC): [Figure 5]

With the help of fluoroscopy (c-arm)/ US/ CT a long, flexible, thin, blunt needle is passed into the liver through right 8<sup>th</sup> intercostal space in midaxillary line, once the needle is in the dilated biliary tree, bile is aspirated and sent for culture, cytology, and analysis. Then a water soluble dye is injected so as to visualize the biliary tree.

PTC can be therapeutic when used to stent the biliary tree.

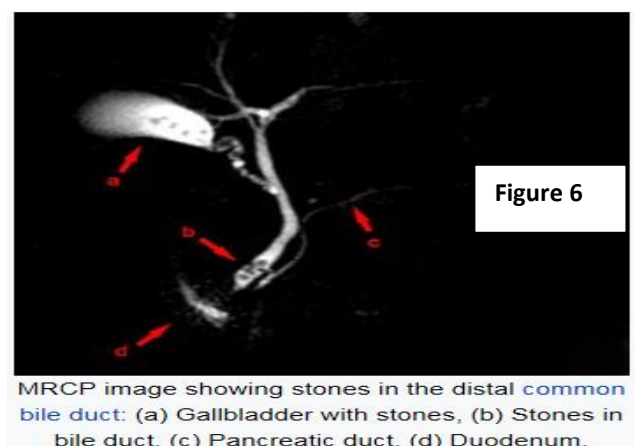
### ○ Indications:

- a. Failure of ERCP
- b. High biliary strictures
- c. Klatskin tumor
- d. Stenting in high tumors

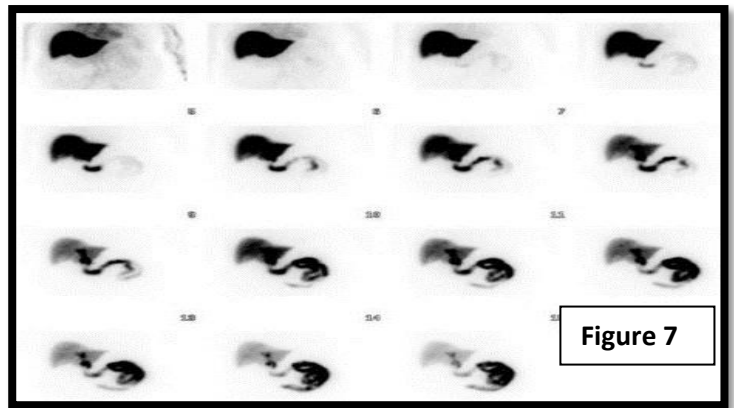


## III. Magnetic Resonance Cholangio-Pncreaticography (MRCP): [Figure 6]

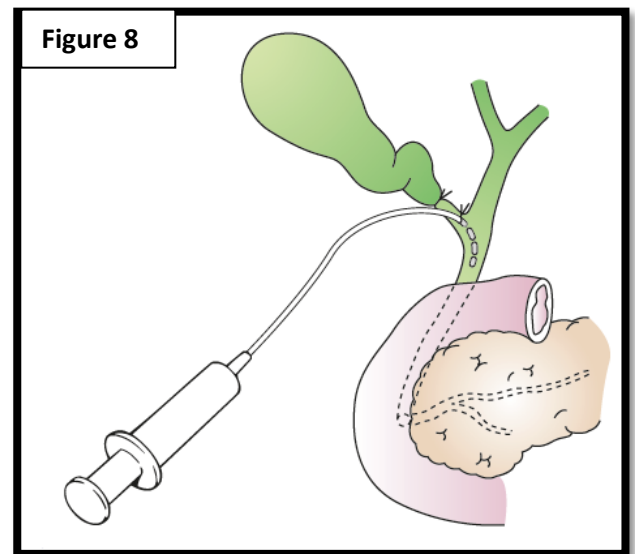
It is a non contrast non invasive **imaging** method, better than ERCP as diagnostic tool in biliary and pancreatic diseases.



- IV. **Radioisotope scan study (HIDA & PIPIDA) [Figure 7]:**Very useful in diagnosing acute cholecystitis and other biliary disorders like biliary atresia.



- V. **Peroperative Cholangiogram [Figure 8]:**  
During open or laparoscopic cholecystectomy, a catheter can be placed in the cystic duct and contrast injected directly into the biliary tree. The technique defines the anatomy and in the main is used to exclude the presence of stones within the bile ducts.  
Complications: infection & bile leak.  
Precautions: air should not be present in the syringe, as it may mimic stones.



- VI. **Postoperative T-Tube Cholangiogram:**

After choledochotomy, T-tube is inserted in CBD for 14 days and then water soluble dye is injected into the tube and X-ray is taken. Complete free flow of dye into the duodenum indicates that there is no blockage by stones. T-tube can then be removed safely.

### **\*\*Biliary surgeries\*\***

- **Cholecystectomy:** removal of the GB, whether laparoscopically or open.
  - **Lap Chole:** laparoscopic cholecystectomy.
  - **Complications of lap chole:**
    - 2-CBD injury
    - 3-Rt hepatic duct or artery injury
    - 4-Cystic duct leak
    - 5-Biloma
    - 6-Bowel injury

- One of the complications of laparoscopic cholecystectomy is biloma, which is intraperitoneal bile fluid collection which presents as epigastric pain.
  - Treatment of post op biloma:
    1. Percutaneous drainage of bile collection.
    2. ERCP with placement of a biliary stent past leak (usually cystic duct remnant leak).
  - ✓ Another complication is major CBD injury after lapchole, which is treated by: choledochojejunostomy.
  - Kocher incision: right subcostal incision.
  - Sphincterectomy: (AKA: papillotomy) a cut through the sphincter of oddi to allow the passage of gallstones from CBD (most often done in ERCP).
-

# Gallbladder stones (Cholelithiasis)

## INTRODUCTION

- **Incidence:** 10% of USA population will develop gallstones.
- **Types of stones:**
  - **Mixed (80% of stones):**
    - ♣ The most common type of gallstones.
      - ♣ Content: cholesterol content 50-80%
      - ♣ Various shapes and sizes.
      - ♣ Usually small, multiple stones of faceted surface.
      - ♣ Radiolucent.
  - **Pure cholesterol (10% of stones):**
    - ♣ Content: cholesterol 100%.
    - ♣ Pale yellow.
    - ♣ Usually large and solitary.
    - ♣ Radiolucent.
  - **Pigmented (10% of stones):**
    - ♣ Cholesterol content less than 20% of their weight.
      - **Black stones:**
        - ♣ Causes: hemolysis (any haemolytic disease is a risk factor) and cirrhosis.
        - ♣ Content mainly Calcium-bilirubinate.
        - ♣ Homogenous, brittle.
        - ♣ Small multiple stones.
        - ♣ Radiopaque 75%.
      - **Brown stones:**
        - ♣ Causes: after biliary infection (most common causative organism is Klebsiella).
        - ♣ Content: mainly calcium palmitate.
        - ♣ Small, multiple, soft stones.
        - ♣ Radiolucent.

## ? ETIOLOGY

- **Risk factors:**
  - 5 F's:
    1. Female (twice the risk) → Hormonal effect

2. Fat (three times the risk in obese, and increases with fatty diet)
3. Forty.
4. Fertile (multiparity and usage of OCP).
5. Fair

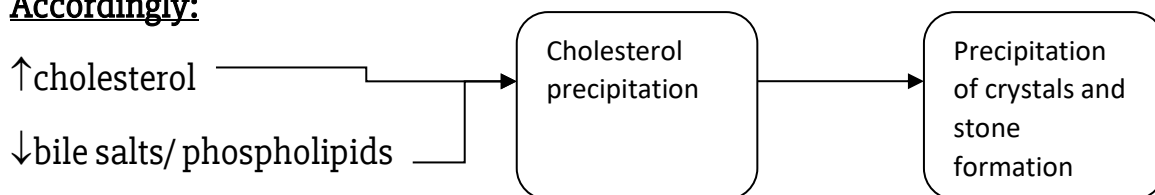
➤ **Less common risk factors:**

1. Advanced age.
2. Infection
3. Bile stasis
4. Cirrhosis
5. IBD
6. Chronic hemolysis
7. OCPs, somatostatin treatment.
8. TPN (the effect of the CCK is put off to rest since there's no food in the duodenum, so no contraction of the gallbladder or the biliary tree).
9. Hyperlipidemia (but hypercholesterolemia is not a risk factor)
10. Hyperlipidemia could be familial or acquired.
11. Obesity
12. High caloric diet (it increases the secretion of cholesterol into gall bladder)
13. Rapid weight loss
14. Bypass surgery / terminal ileal resection (due to interruption of enterohepatic circulation which leads to supersaturated bile).
15. Vagotomy.
16. Native Americans.
17. Spinal cord injury due to denervation and biliary stasis.
18. Medications, examples are:
  - a. Antipyretics (Ceftriaxone [Rocephin]) which is widely used by in paediatrics patients, long term use might lead to formation of gallstones.
  - b. Somatostatin analogue (octreotide), somatostatin is a universal anti-secretory hormone, so it suppresses the secretion of all hormones. In surgery it's used to treat gastrointestinal fistulae (duodenal, pancreatic, biliary fistulae) by suppressing the secretions from the biliary tree and the pancreas, so prolonged use might lead to gallstones formation.

## i. Metabolic causes (disturbed cholesterol: bile salts or lecithin ratio):

- Exogenous cholesterol represents about 30% of cholesterol in our body. Cholesterol is mainly produced by the liver, with little contribution of the dietary sources.
  - Chylomicrons and LDL, are taken up by receptors, converted to cholesterol esters, then by the enzyme hydrolase are converted to free cholesterol, this free cholesterol is either re-esterfied or hydrolised to bile salts or excreted in the hepatic biliary canaliculi.
  - 10-20% of adult population in USA have gallstones.
  - They are 3 times more in females than males because of hormonal effect, estrogen and progesterone affect the saturation of cholesterol in bile.
  - As age increases, the incidence of gallstones also increases.
  - Most lipid lowering enzymes increase the excretion of cholesterol in bile, and that's why these people might develop gallstones.
  - At the level of hepatocytes, what come from food is chylomicrons.
  - Major organic solute in the bile is bilirubin, bile salts, phospholipids and cholesterol.
- The way to keep cholesterol from precipitation is the complexes (micelles and vesicles), so the aim of complexes is solubilisation of cholesterol, micelles are carriers of cholesterol. Micelles can be simple, mixed, multilamellar or vesical.

### Accordingly:



### ➤ Pathogenesis of gallstones :

#### 1. Supersaturation of bile with cholesterol:

- ↑↑ secretion of cholesterol.
- ↓bile salts and lecithin.

#### 2. Nucleation:

- Formation of solid crystals from bile saturated with cholesterol.
- Nidus (calcium-bilirubinate) is another mechanism.
- Promoters of nucleation (mucus glycoproteins) are important risk factors.

### 3. Growth:

- Individual growth of each crystal.
- Promoters (calcium and mucus glycoproteins) act as frameworks for crystal formation.
- 1-2 mm per year (so they increase in size and don't go away).

### ii. **Bile stasis:**

- It occurs due to estrogen therapy, pregnancy, vagotomy, and in patients who are on long term IV fluids or TPN.

### iii. **Infections and infestations (pathogenesis of pigmented brown stones):**

- Bacteria like E.coli and Salmonella and parasites like Ascaris act as a nidus for stone formation.
- The stones are typically found in the bile duct as primary stones
- Bacteria that have the enzyme glucorinidase will cause the hydrolysis of soluble conjugated bilirubin into unconjugated bilirubin that precipitates with calcium. Another bacterial enzyme is phospholipase which hydrolyzes lecithin into palmitate.

*"A gall stone is a tombstone erected to the memory of the organism within"*

### iv. **Increased bilirubin production (Pathogenesis of pigmented black gallstones):**

- ↑Load of unconjugated bilirubin → precipitate with calcium.
- Not associated with infected bile.
- Almost exclusively in the gallbladder



## CLINICAL FEATURES

### Signs and symptoms :

#### i. **In the gall bladder**

80% of patients are asymptomatic.

#### If symptomatic:

- ♣ Biliary colic (misnomer; not really a colic); usually last for hours and is characterized by:

### **\*\*Differential diagnosis of biliary colic\*\***

- 1-Cholelithiasis.
- 2-Acute cholangitis.
- 3-Liver diseases.
- 4-PUD (peptic ulcer disease).
- 5-Renal colic
- 6-GERD.
- 7-Inferior wall MI.
- 8-Right lower lobe pneumonia.
- 9-IBS.

1. RUQ pain that radiates to the back /epigastrium/ LUQ, the pain worsens after eating especially fatty meals .
2. ± Nausea and vomiting the body trying to prevent fatty food from reaching the duodenum.
3. No jaundice.
4. Boas' sign: referred right subscapular pain of biliary colic.

**Differential diagnosis for pain radiating to the back:**

- 1-Cholelithiasis.
- 2-Acute cholecystitis.
- 3-Pancreatitis.
- 4-Penetrating PUD (not perforating).
- 5-Ruptured aneurysm
- 6- disk prolapsed.

**\*\*Referred pain vs. Radiated pain\*\***

- Radiated pain occurs via direct irritation of the nerve root.
- Referred pain occurs at the level of the cortex when the brain receives signals from the viscera and thinks it's from the dermatome supplied by the same

- ♣ Acute cholecystitis.
- ♣ Chronic cholecystitis.
- ♣ Empyema gall bladder:  
A type of acute cholecystitis wherein the gall bladder is filled with pus.
- ♣ Perforation causing biliary peritonitis or pericholecystic abscess.
- ♣ Mucocele of gall bladder.
- ♣ Gall bladder carcinoma.

**ii. In the CBD:**

- ♣ Cholelithiasis: The stone may move from the gall bladder and get obstructed in the CBD (secondary CBD stone): explained later
- ♣ Cholangitis : explained later
- ♣ Oriental cholangiohepatitis.(**It's an endemic disease in Southeast Asia, is characterized by recurrent attacks of abdominal pain, fever, and jaundice. Pathologically, the intra- and extrahepatic ducts are dilated and contain soft, pigmented stone and pus.**)
- ♣ Gall stone Pancreatitis
- ♣ Mirizzi syndrome : explained later

**iii. In the intestines:**

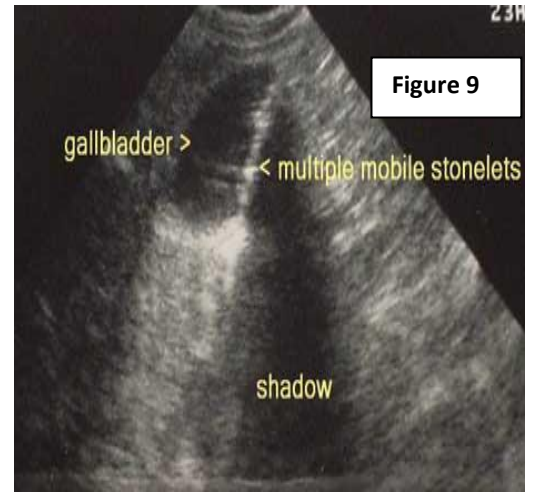
- ♣ Gall stone ileus: explained later.





## DIAGNOSIS

- History and physical exam.
- Ultrasound [Figure 9]: detects stones in >98% of cases in gallstones, while it only detects 33% in choledocholithiasis, so it's not a very good diagnostic tool for choledocholithiasis.
- **Findings:** acoustic shadow.
  - Abdominal x-ray detects only 15% of gallstones.



## TREATMENT

- If symptomatic or complicated stones → cholecystectomy (surgical or lapchole).
- Medical treatment: ursodeoxycholic acid.
- For pain management we give pethidine not morphine because morphine causes contraction of the sphincter of oddi.
- If asymptomatic > no treatment except: in the following cases:
  - Porcelain GB (due to risk of CA).
  - Pediatric pts (relative indx).
  - Sickle cell disease.
  - Imuunosuppression.
  - DM.
  - Others: females predicting pregnancy.
  - Incidental finding intraoperatively.
  - GB polyp (increased risk of CA).
  - Risky jobs (Pilots and astronauts).
- After the removal of the gall bladder bile stones may recur, if it recure after 2 years post cholecystectomy then it's primary stone of the bile ducts if it recur <2years post cholecystectomy then it's a slipped stone (a small stone which is missed) during the removal of gall bladder .

### Does the gallbladder have a role in stone formation?

Yes, when we remove the gallbladder rarely stones reoccur, so the removal is a symptomatic treatment, we are removing the site where most stones are formed.

The epithelium of the gallbladder has an absorptive and a secretory capacity(mucin), so once there is alteration in either capacities or increase/decrease motility of the gallbladder, stones are formed.

Dysmotility of the gallbladder could develop spontaneously, postoperative or due to a disease. (denervation of the gallbladder).

Hypermotility of the gallbladder leads to shrinkage of the pool of bile acid.

# Acute cholecystitis:

## ♠ Types:

- a) Calculous cholecystitis.
- b) Acalculous cholecystitis.
- c) Emphysematous cholecystitis.
- d) Xanthogranulomatous cholecystitis.

## PATHOPHYSIOLOGY

- Obstruction of cystic duct leads to inflammation of the gallbladder, 95% due to stone and 5% is acalculous, so pain is continuous (more than 3 hours).
- Risk factors: gallstones.

## CLINICAL FEATURES

### ➤ Signs and Symptoms:

- more continuous and severe symptoms than Cholelithiasis, unremitting RUQ pain or tenderness
- Fever
- Nausea, vomiting and anorexia
- Positive Murphy's sign: arrest of inspiration during deep palpation of the RUQ
- Painful palpable GB in 33% of patients.
- Mild jaundice (if severe, you should think of CBD stone)
- Right subscapular pain/ epigastric discomfort. (referred pain)

### ➤ Complications:

- 1- Empyema.
- 2- Abscess formation.
- 3- Perforation.
- 4- Gangrene.
- 5- Cholecystenteric fistula.
- 6- Choledocholithiasis.
- 7- Gallstones ileus.

### Difference between acute cholecystitis and biliary colic:

- Biliary colic has temporary pain, while acute cholecystitis has a pain that doesn't resolve.
- Cholecystitis has elevated WBC, fever and signs of acute inflammation on U/S

- 8- Mirizzi syndrome [Figure 10]. (Defined as common hepatic duct obstruction caused by an extrinsic compression of an impacted stone in the cystic duct or Hartmann's pouch of the gallbladder).

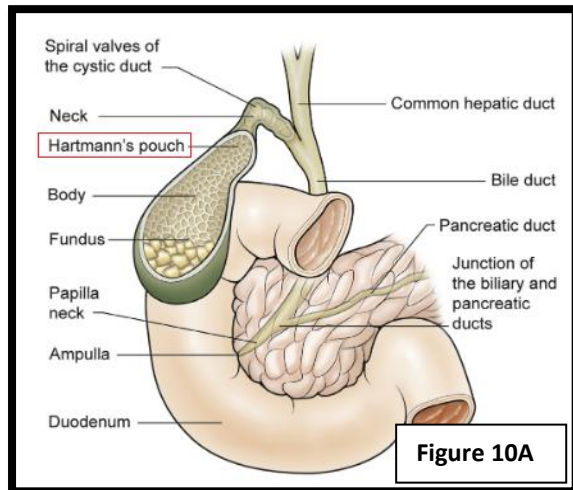


Figure 10A

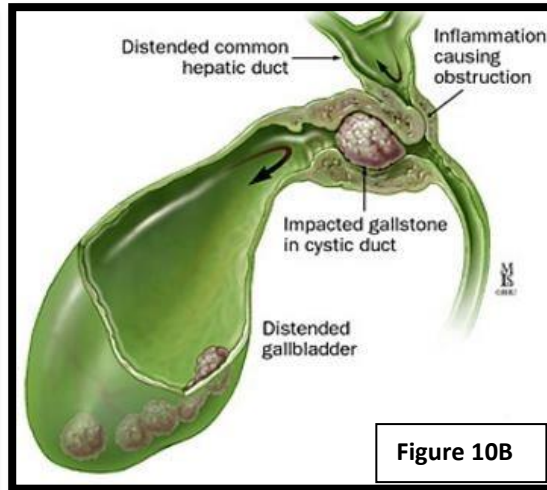


Figure 10B



## DIAGNOSIS

- **Investigations:**

- **Labs:**

- a. CBC:

- 1. WBC (but could be normal)
      - 2. Alkaline phosphatase ↑ LFTs, ↑ total bilirubin.
      - 3. Slightly ↑ amylase.

- **Imaging:**

- The diagnostic tool of choice is ultrasound.

- Findings on ultrasound:

- 1- Thickened gallbladder wall > than 3 mm.
        - 2- Pericholecystic fluid.
        - 3- Distended gallbladder (> 7mm)
        - 4- Gallstones or cystic stones.
        - 5- Sonographic Murphy's sign.

- HIDA scan is the most accurate.
    - CT scan, less sensitive.

- In Acute cholecystitis → Palpable painful mass.
        - In GB cancer → Palpable painless mass.



## TREATMENT

- 1- admit the patient
- 2- IV fluids
- 3- IV antibiotics (piperacillin/ Tazobactam).

Acute cholecystitis is classified into mild, moderate and severe according to

**Tokyo guidelines:**

**1-Mild (grade 1):**

- a. Mild inflammation.
- b. No organ dysfunction.

**2-Moderate (grade 2):**

- a. Leukocytosis.
- b. Palpable tender mass.
- c. Duration >72 hours.
- d. Marked inflammation.

**3-Severe (grade 3):**

- a. Multi-organ failure MOF
- b. Hypotension.
- c. Respiratory failure.
- d. Renal failure.
- e. Altered mental status.

- If mild → early cholecystectomy within 24-48 hours
- If moderate → early vs. delayed cholecystectomy after 6 months, but recent studies showed that early is better regardless of the degree.
- If severe (or the patient has a severe medical illness/ very old or can't tolerate general anaesthesia) → percutaneous cholecystectomy

## Acalculous cholecystitis:



### INTRODUCTION

- It's acute cholecystitis without the evidence of stones.
- Mortality rate is 30%.
- You can think of it as a deterioration that happens to ICU patients.



### PATHOPHYSIOLOGY

- It's believed to be due to biliary sludge, GB diseases and biliary stasis (secondary to absence of cholecystokinin stimulation which leads to decreased function of GB).
- Risk factors:
  1. Prolonged fasting
  2. TPN
  3. Trauma
  4. Multiple transfusions
  5. Dehydration
  6. Prolonged post-op. Setting or ICU patients (critically ill), especially with history of hypotension.
  7. Sepsis or MOF.
  8. Burns.

**Theories of pathophysiology:**

1. Sludge
2. Thickening of mucosa
3. Ischemia, as in ICU patients



## DIAGNOSIS

### Investigations:

- Labs:  
↑WBC, ↑amylase, abnormal LFTs.
- Imaging:
  - a. U/S
  - b. HIDA scan is the most accurate, we find non-filling of GB
  - c. CT ( has the same sensitivity as U/S).

#### Limitations to ultrasound:

- Overlying bowel gas
- Concomitant abdominal wounds or dressings.



## TREATMENT

- If the patient is stable>>>do cholecystectomy.
  - If unstable, we decompress the GB percutaneously via cholecystectomy tube then we do cholecystectomy.

## Emphysematous cholecystitis

- By gas-forming bacteria (E.coli)
- Usually in diabetic patients, males and elderly and has a high morbidity and mortality rate.
- Often results in perforation of gallbladder.
- If gas is present in:
  - ♣ Biliary tree→Think of fistula.
  - ♣ In gallbladder wall→think of emphysematous GB.

## Xanthogranulomatous cholecystitis

- A rare inflammatory disease of the gallbladder characterized by a focal or diffuse destructive inflammatory process.
- A foreign body-giant cell reaction that leads to formation and accumulation of xanthoma cells.
- Its importance lies in the fact that it is a benign condition that may be confused with carcinoma of the gallbladder.

# Choledocal cyst

## INTRODUCTION

- **Definition:** a congenital dilatation of extra or intrahepatic biliary tree, usually in CBD.
- **Causes:** there are more than one theory about its cause, the most common 2 are➔
  - I. pancreaticobiliary maljunction (there is along common channel more than 2 cm) , Babbit theory suggests that : reflux of pancreatic juice into the bile duct which causes enzymatic destruction of the bile duct wall , ductal wall weakening and dilatation.
  - II. During embryogenesis, there is abnormal early canalization of the bile duct with distal obstruction causing increased proximal pressure, weakening and ductal dilatation.

- **Types:** [Figure 11]

- type I. Fusiform/ diffuse dilatation, represents 75% of cases.
- type II. Isolated sacular diverticulum .
- type III. Choledococoele/ cyst: localized dilatation with intradudenal part of CBD.
- type IV. Multiple cystic dilatations inside and outside liver.
- type V. Single/ multiple lesions only intrahepatic (e.g.: caroli's disease, read the box below )

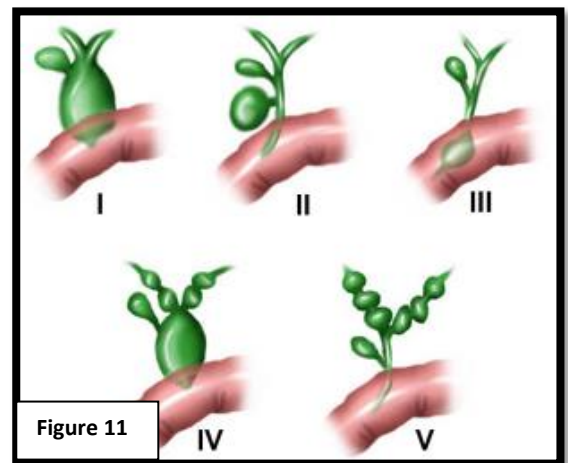


Figure 11

**Caroli's disease:** it is a congenital non familial multiple, irregular dilatations of the intrahepatic ducts with stenotic segments in between, it is associated with congenital liver fibrosis and medullary sponge kidney. It is considered a subtype of type 5 choledocal cyst .

- Notes:

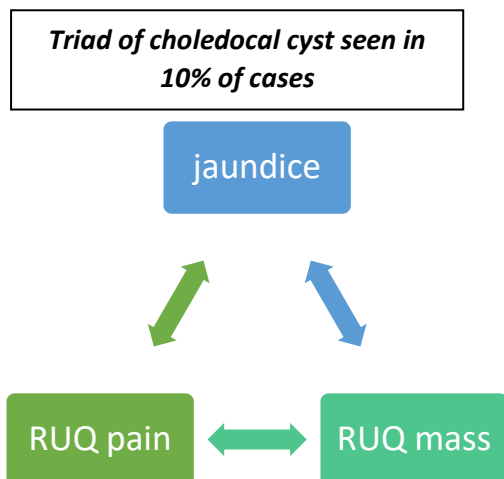
- I. 60% of cases present before the age of 10 years.
- II. 3 times more common in females.



## CLINICAL FEATURES

### ➤ Signs & symptoms:

1. Obstructive jaundice in 80% of cases
2. RUQ pain
3. Cholangitis
4. Abdominal mass: RUQ mass , soft, not moving with respiration ,not mobile and resonant.
5. Failure to thrive in children



### ➤ Complications:

1. Choledocolithiasis: stones in CBD.
2. Cholangitis.
3. Portal hypertension secondary to biliary cirrhosis which results from prolonged obstruction of ducts.
4. Cholangiocarcinoma: the risk is 30%, and usually develops in the 4<sup>th</sup> decade of life.
5. Rupture of cyst and peritonitis.
6. Diagnosis:
7. History and physical examination.
8. Ultra Sound or CT

[Figure 12].

Figure 12A

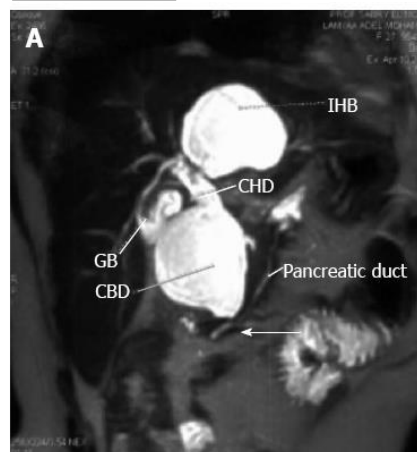
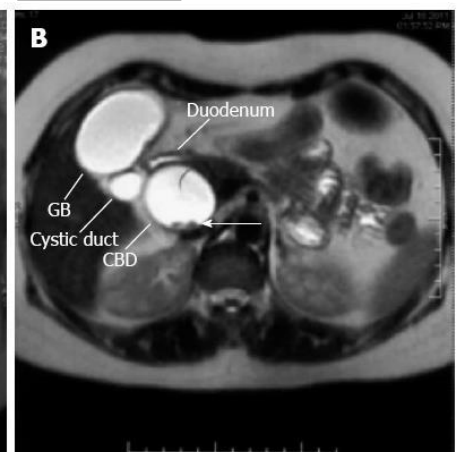


Figure 12B



## TREATMENT

- **Treatment:** according to the type →
  - Type I & IV: hepatojejunostomy.
  - Type II: cyst excision.
  - Type III: cyst unroofing and sphincteroplasty.
  - Type V: hemihepatectomy.

*Complete excision of the cyst is important due to the increased risk of Cholangiocarcinoma!*

## Choledocolithiasis

### INTRODUCTION

- it is stones in the CBD
- **classification:**
  - I. **Primary:** rare, they are formed in CBD and biliary tree itself, causes of its formation are:
    - biliary stasis, biliary dyskinesia, benign biliary stricture, sclerosing Cholangitis
    - choledocal cyst
    - Infections and infestations like ascariasis
 The stones are brown pigment stones.

**Note:**

After cholecystectomy the stones formed in the biliary tract are cholesterol stones mostly.

- II. **Secondary:** common, the stones are formed in the gall bladder (gall stones), these stones pass through the cystic duct to the CBD and get impacted in the CBD most commonly in the supraduodenal portion of CBD, here CBD is otherwise normal.
 

The stones are either black pigment stones in 15% of cases or cholesterol stones in 75% of cases.

**Notes:**

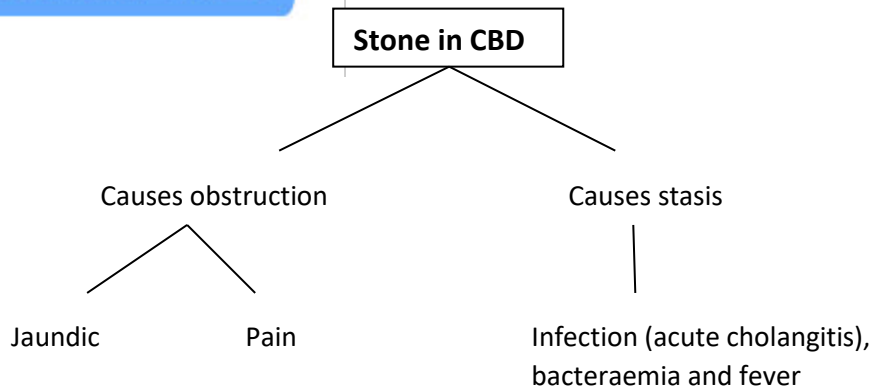
The incidence of Choledocolithiasis is found to be in 5-15% of patients with acute calculus cholecystitis and in 1-2% of patients with acalculus cholecystitis

- **Signs & symptoms:** the pathophysiology behind the signs and symptoms of Choledocolithiasis is demonstrated by the following diagram →





## CLINICAL FEATURES



So the signs and symptoms are;

1. Jaundice (if bilirubin > 2.5), with icterus (yellowish  
a. Discoloration of the sclera).
  2. Epigastric /RUQ pain: it may be biliary colic pain  
a. , non specific abdominal pain, pain of ascending  
b. Cholangitis, pain of pancreatitis.
  3. Fever with chills and rigors.
- } Charcot's triad of acute cholangitis

The stone may move proximally and floats on the bile , so obstruction is relieved and symptoms subside (intermittent features), but when there is pus production in the biliary tree these previous signs will be persistent and will be associated with toxic shock and altered mental status (Reynolds pentad of acute Cholangitis).

4. Steatorrhoea and darkening of urine.
5. Pruritus.

➤ **Complications:**

1. Liver dysfunction and biliary cirrhosis with resulting portal hypertension
2. White bile formation: it is a misnomer; it is neither white nor bile but rather it contains mucous , it signifies severe obstructive jaundice due to which secretion of bile from liver is stopped. The mucous is derived from biliary tree lining.
3. Pancreatitis: if CBD stone is near sphincter of Oddi which blocks the drainage of bile and pancreatic duct.



## DIAGNOSIS

1. Labs: raised alkaline phosphatase / raised LFT/ raised total bilirubin and direct bilirubin
2. ERCP: the gold standard for diagnosis , it is also therapeutic.
3. PTC (Percutaneous Transhepatic Cholangiography): done when ERCP fails, it is also therapeutic.



## TREATMENT

- ERCP (85-90% successful): involves endoscopic sphincterotomy with extraction of the CBD stones with a basket.
  - If ERCP fails then the CBD is opened surgically and stones are removed. A T-tube is placed so bile can be drained externally; this tube is removed 2-3 weeks later on an outpatient department basis.
  - Other treatment options: lap chole and intraoperative cholangiogram (IOC) blind passage of balloon catheter or stone basket.
-

# Cholangitis

## Overview:

- It is inflammation of the biliary tree.
- 3 types:
  - I. ascending Cholangitis
  - II. suppurative cholangitis : severe inflammation with sepsis ( pus under pressure), it will be discussed with ascending cholangitis.
  - III. sclerosing Cholangitis

## ❖ Ascending Cholangitis:

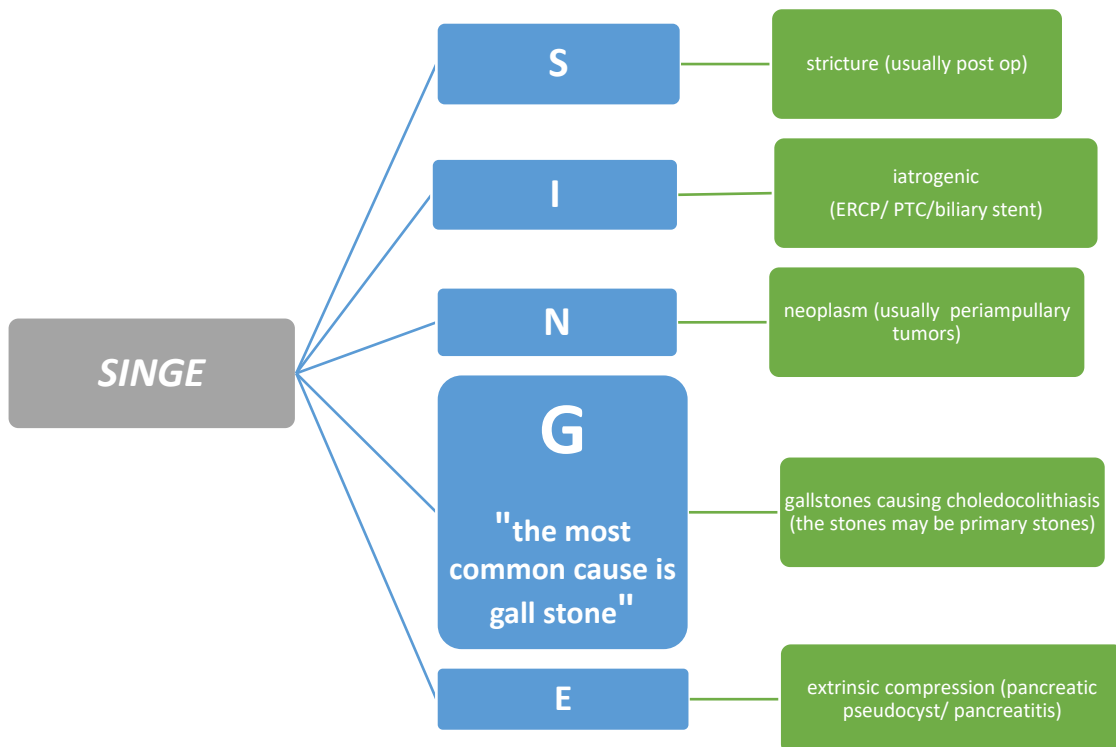
### ? ETIOLOGY

- Biliary infection of the biliary tract caused by complete /partial obstruction. It is potentially life threatening!! Causes: any cause of obstruction



The pathogens which will cause the infection as a result of the obstruction are:

- Commonly: bacterial →
  - I. Gram negative: E-Coli/ Klesbsiella/ Pseudomonas/ Enterobacter.
  - II. Gram positive: Enterococci .
- Less common:
  - I. Anaerobes : B-Fragills.
  - II. Fungi: Candida (the least common).





## CLINICAL FEATURES

### ➤ Signs & symptoms:

- Charcot's triad in 50-70% of cases of ascending cholangitis (non –suppurative cholangitis):
  - I. Fever/ chills
  - II. RUQ pain
  - III. Jaundice
- If there was pus production (causing severe infection with sepsis)→ suppurative cholangitis which is more common in elderly, the signs and symptoms are the following (when all of them are present they are called **Reynolds pentad**):
  - I. Charcot's triad.
  - II. Altered mental status.
  - III. Shock [hypotension] .



## DIAGNOSIS

- Labs: ↑WBC , ↑alkaline phosphatase , abn'2ormal LFT, ↑ bilirubin.
- Ultra Sound:
  - I. Should be the initial study
  - II. Findings: dilatation of common bile duct and intrahepatic ducts along with gall stone and thickened edematous gall bladder wall.
- ERCP / PTC (percutaneous Transhepatic cholangiogram): provides definitive diagnosis and can also be therapeutic.
- Bile cultures.



## TREATMENT

- If non suppurative: IV fluid + IV antibiotics+ difintive treatment later which is: lap cholecystectomy ± ERCP
- If suppurative:
  - I. IV fluids+ IV antibiotics
  - II. Decompression by: → ERCP with sphincterotomy.
    - or PTC with catheter drainage.
    - or laparotomy with T- tube placement.

Abx used needs to have broad spectrum of action to cover:

1. Anarobes
2. Gram +ve
3. Gram -ve

# Primary sclerosing cholangitis (PSC):

## INTRODUCTION

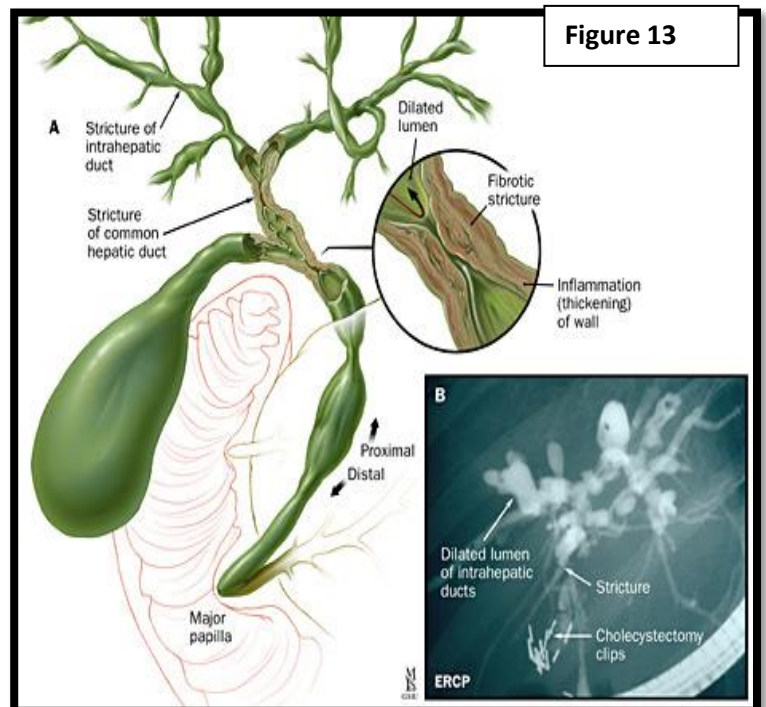
- Autoimmune progressive fibrous obliteration of the bile duct (multiple inflammatory fibrous thickening of the bile duct walls resulting in biliary stricture).
- **Complications:**
  - I. progressive obstruction possibly leading to cirrhosis and liver failure
  - II. 10% will develop cholangiocarcinoma
  - III. Cholangitis
  - IV. Obstructive jaundice
- ✓ **Major risk factor:**
  - IBD: 60% of ulcerative colitis patients develop PSC (in young and middle aged male).

## CLINICAL FEATURES

- **Signs and symptoms:**
  - Usually asymptomatic for years (up to 15 years)
  - Symptomatic: the symptoms include: RUQ pain/ jaundice/ hepatosplenomegaly/ itching (pruritis) /dark urine/ clay colored stool/ malaise/ weight loss.

## DIAGNOSIS

- ERCP or PTC [Figure 13]: shows beads on a string which is characteristic of PSC, the beads on a string represents diffuse irregular narrowing of



the entire biliary tree and annular strictures.

- **Labs:** ↑alkaline phosphatase, +ve PANCA in 80% of the cases.
- If liver biopsy was taken it will show: periductal concentric fibrosis around the macroscopic bile duct, if the hepatic ducts were viewed it will show that the hepatic ducts bifurcation is most severely involved.



## TREATMENT

- Endoscopic balloon dilatation for strictures and stent placement after dilatation
- Liver transplant: the definitive treatment; especially if PSC was primarily intrahepatic or if there was cirrhosis.
- If primarily extrahepatic ducts are involved: hepatoenteric anastomosis and resection of extrahepatic ducts due to risk of cholangiocarcinoma.
- Prognosis: 10-12 years

### Notes:

- Close follow ups are important due to risk of cholangiocarcinoma.
- Elevated Ca 19-9 suggests carcinoma.

### Oriental cholangiohepatitis (also known as recurrent pyogenic hepatitis):

Overview:

- it is a result of infestation with parasites (ascaris) that cause: bacterial overgrowth and infection of the hepatic ducts / stricture of the ducts and stasis of bile/ brown stone formation in the intra hepatic and extrahepatic ducts
- it is one of the complications of cholelithiasis
- more common in the far east
- The Lt hepatic duct is more affected than the Rt.

Treatment: dilation of biliary stricture by stents and biliary drainage.

# Gall stone ileus

## INTRODUCTION

- A small bowel obstruction from a large gall stone (>2.5 cm) that has eroded through the gall bladder into the duodenum/ small bowel, gall stone ileus accounts for 1% of cases of SMALL bowel obstruction.
- Site of obstruction :
  - I. Just proximal to the ileocecal valve: the classical site of obstruction
  - II. Duodenum
  - III. Sigmoid colon
- Risk factors: female >70 years.

## CLINICAL FEATURES

- Signs and symptoms:
  1. Signs and symptoms of small bowel obstruction:  
RUQ pain, distention, vomiting and hypovolemia.

## DIAGNOSIS

1. Clinical features
2. Abdominal x ray: shows →
  - I. Reveals radio opaque gall stone in the bowel (most commonly near ileocecal valve)
  - II. 40% of patient show AIR in the biliary system (air in the hepatic ducts)
  - III. Small bowel distention
  - IV. Air –fluid levels secondary to ileus
3. Upper GI series
4. Abdominal CT : shows →
  - I. Reveals air in the biliary system
  - II. Features of small bowel obstruction
  - III. ± gall stone in the bowel.

## TREATMENT

- Surgical → enterotomy with removal of stone ± interval (delayed cholecystectomy).

# Biliary system tumors

“gall bladder carcinoma & bile duct tumors”

## ➤ Gall bladder carcinoma:

### INTRODUCTION

- Malignant neoplasm arising in the gall bladder, It is a very aggressive tumor.
- Incidence: 1% of all gallbladder specimens (rare!)
- Risk factors are:
  - I. Common in females (female: male= 3:1) and elderly.
  - II. Gall stones: 90% of carcinoma of gallbladder is associated with gallstones, however only 3% of gallstones with cholecystitis will develop carcinoma of the gall bladder.
  - III. Porcelain gallbladder: it is a calcified gall bladder seen on abdominal X-ray, results from chronic cholelithiasis/ cholecystitis with calcified scar tissue in gallbladder wall. 50% of patients with porcelain gallbladder will develop gallbladder carcinoma.

It is indicated to perform cholecystectomy when there is porcelain gall bladder.

- IV. Cholecystenteric fistula: a communication between the gallbladder and the GI tract most commonly the small intestines specifically the duodenum.
- **Site:** most common in the fundus of the gallbladder (60%).
  - **Types:**
    - I. Types according to the gross view:
      - a. Polypoid/papillary: better prognosis
      - b. Scirrhous/ nodular.
      - c. Proliferative/ infiltrative.
    - II. Types according to the histology:
      - a. Adenocarcinoma: 90%
      - b. Squamous cell carcinoma.
      - c. Adenosquamous.
      - d. Carcinoid tumor.
  - **Prognosis:** 5% is the 5 year survival, due to the fact the most of the cases are unresectable at the time of diagnosis. However, cases detected at T1 (the tumor invaded lamina propria or muscular layer) has a 5 year survival rate of 95%.
  - **Route of spread:** contiguous spread to the liver is the most common route.



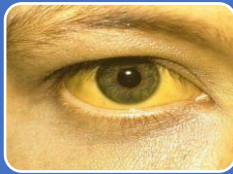

## CLINICAL FEATURES

### ➤ Signs & symptoms:

- Most patients are asymptomatic with: late biliary colic / weight loss / anorexia.
- Some patients might present with acute cholecystitis.
- Jaundice: as a result from invasion of the common bile duct or compression by involved choledocal lymph node.
- RUQ mass.
- Courvoisier's sign or law: "in a patient with jaundice, if there is a palpable gall bladder it is not due to stones".
- In malignancy, like carcinoma of the head of the pancreas or periampullary carcinoma, gall bladder will be distended, palpable and non tender.

Clinically, patients present with one of the following three scenarios:



clinically obvious type with pain, obstructive jaundice, and mass.



early gallbladder carcinoma mimics gall bladder stone disease.



atypical as unusual features.



## DIAGNOSIS

1. Ultra Sound.
2. Abdominal CT.
3. ERCP.



## TREATMENT

- Depends on the extent of tumor involvement.
- Tumor confined to gall bladder mucosa → cholecystectomy
- Tumor reached muscular layer or serosal layer → radical cholecystectomy: cholecystectomy+ wedge resection of overlying liver+ lymph node dissection+ chemo/radio therapy

Note: The main complication of lap cholecystectomy for gall bladder carcinoma is trocar (laparoscopic instruments) site tumor implants; so if gall bladder carcinoma is suspected preoperatively open cholecystectomy is indicated.

### ➤ Tumors of the biliary tree:



## INTRODUCTION

### ➤ Two types:

#### I. Benign:

- Most commonly they are adenomas which are rare neoplasms, arise from ductal glandular epithelium, Polypoid (polyps) and < 2 cm in diameter.
- The most common sites are:
  - Ampulla (first most common site)
  - CBD (second most common site)
- Signs and symptoms: intermittent obstructive jaundice + RUQ pain
- Treatment: complete resection of the tumor with a margin, if only simple curettage of the polyp was done there is a high recurrence rate.

The signs and symptoms can be confused with Choledocolithiasis

#### II. **Malignant** (also known as Cholangiocarcinoma): it is a malignancy of the intrahepatic or extrahepatic ducts, note that we are explaining primary bile duct cancer.

- Almost all of cholangiocarcinomas are adenocarcinomas when studied histologically.
- Average age of presentation: 65 year old
- Female: male = 1:1

- e. Most common site: proximal bile duct specifically at the junction of the Lt and Rt hepatic ducts.

**Klatskin tumor: (type 2)**  
cholangiocarcinoma arising at the junction of the Rt and Lt hepatic ducts.

f. **Risk factors:**

1. Choledocal cyst
2. Primary sclerosing cholangitis
3. Ulcerative colitis
4. Radiation exposure
5. Toxin exposure
6. Parasitic infection

- g. Cholangiocarcinomas have been **classified** according to the site into:

- 1) Intrahepatic : 20% of the cases
- 2) Upper extrahepatic (klatskin): 40% of the cases

- 3) Lower extrahepatic : 40% of the cases

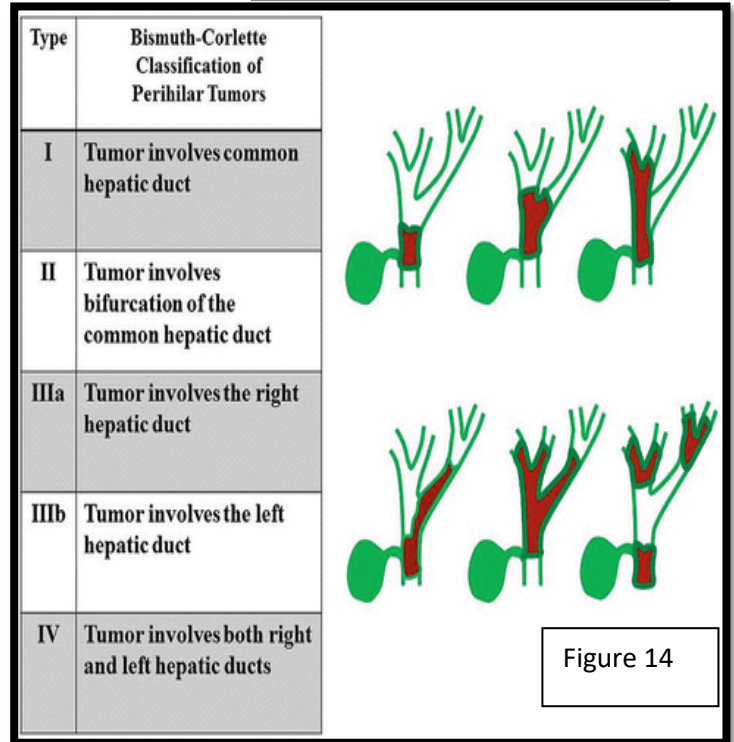


Figure 14

Note: see [Figure 14] for the detailed Bismuth-Corlette classification:

h. **Diagnosis:**

- 1) Ultra Sound
- 2) CT scan
- 3) ERCP/ PTC with biopsy or brushing for cytology
- 4) MRCP

i. **Treatment:** depends on the site:

- A. Proximal → resection with Roux-en-Y hepaticojejunostomy ± unilateral hepatic lobectomy.
- B. Distal → whipple procedure.

j. **Prognosis:** depends on :

- a) Location and extent
- b) Portal vein invasion
- c) Hepatic lobar atrophy

5 year survival rate is 15-20%

# Summary & past papers

## Summary

- The gall bladder is **anatomically** located on the inferior surface of the liver with the fundus being in the transpyloric plane (L1). It stores and secretes bile in response to CCK stimulation which is drained via the cystic duct to the duodenum.
- **Hydrops GB** is obstruction of cystic duct by gallstones with filling of GB with sterile fluid. **Empyema** if it becomes infected.
- **Gallstones** are either cholesterol (large, solitary), pigmented (black [hemolysis and cirrhosis and are the only one which appear radiopaque] or brown [infection] or mixed (small and multiple). **Risk factors** are 5 Fs (female, fat, forty, fertile, fair). **Caused** by metabolic causes; increase lipids, drugs (ex: lipid lowering agents), Bile stasis, Infection or increase in bilirubin (hemolysis). It **manifests** depending on the location if in gall bladder (as biliary colic with nausea, vomiting without jaundice. It may also manifest as acute/chronic cholecystitis or empyema), if in bile (as cholangitis, mirizzi syndrome or pancreatitis), if in the small bowel (ileus=SBO and it's usually large stone >2.5 cm] and treated with enterotomy and delayed lap chole). **Diagnosed** by ultrasound (98%). And if symptomatic **do lap chole**.
- **Acute cholecystitis** is inflammation of the gall bladder, either as a result of a **stone** causing obstruction (in 95% of cases) or **Acalculus** (sludge formation caused by stasis [TPN, sepsis, ischemia] common in ICU patients with mortality rate of 30%.), **presents** as continuous RUQ pain, referred to the right subscapular region, associated with nausea and vomiting (and sometimes jaundice). On **PE** it's painful and impalpable (painless and palpable if CA). **Diagnosed** by U/S (thick wall, distended gall bladder, stone, +ve murphy) with labs indicating inflammation with elevated LFT. But HIDA scan is the most accurate [especially if acalculus]. It's classified by Tokyo classification to determine management. Can be **complicated** to empyema, perforation or Mirizzi syndrome (stone impaction in Hartman pouch causing hepatic duct obstruction). **Emphysematous cholecystitis** in DM male elderly, caused by gas forming bacteria with high mortality and morbidity, can cause perforation. **Xanthogranulomatous cholecystitis** is benign inflammation CA resulting in formation of xanthoma cells it may be confused with GB carcinoma.
- **Choledolithiasis** is the presence of stones in the CBD, either primary or secondary (from GB). After cholecystectomy the secondary stones can be formed up to 2 years. **Presents** as obstructive jaundice and RUQ pain. Diagnosed by ERCP (this is also therapeutic). It can be complicated to acute cholangitis which is potentially life threatening, presents as charcot's triad (fever, RUQ pain and jaundice) or more severe as Reyanoid's pentad (add altered mental status and hypotension). All cases need ERCP in the first 24 hours as **diagnostic and therapeutic** tool and should not be delayed. **Broad spectrum antibiotics** should also be used to cover (anaerobes, gram +ve and -ve). **GB carcinoma** (90% is adenocarcinoma) is rare malignant tumor which most commonly arises in the fundus, RF include porcelain GB and gallstones. Presents as Palpable GB, jaundice, weight loss and biliary pain.

Diagnosed by imaging studies. Has very bad prognosis. Surgical treatment if resectable. **Biliary tumors** are either benign (Adenoma; similar symptoms to choledolithiasis, treated by resection with high recurrence rate) or malignant (cholangiocarcinoma) which are adenocarcinomas most commonly in the proximal bile duct, RF include choledocal cyst, PSC, UC and radiation. Diagnosed by imaging studies. If proximal resection with anastomosis but if distal do whipple. It's classified via bismuth classification depending on the site (type 2 is **Klastkin tumor=birfurcation**).

### Past papers

1. Highest risk for cholangiocarcinoma?
  - a. **PSC**
  - b. Choledochal cyst
  - c. Hepatolithiasis
  - d. Caroli disease
2. Male with IBD presents with jaundice?
  - a. **PSC**
3. The type of cholecystitis that mimics gallbladder carcinoma is:
  - a. **Xanthogranulomatous cholecystitis**
4. Add 38-year-old female presented with RUQ with for 12 hrs and mild tenderness with no rigidity. She used to have a similar pain following fatty meals, diagnosis?
  - a. **Acute cholecystitis**
5. Wrong about gallstones:
  - a. black stones are associated with hemolysis
  - b. black stones occur exclusively in the gallbladder
  - c. brown stones associated with biliary tract infections
  - d. pure cholesterol stones → solitary
  - e. **brown stones associated with increased calcium bilirubinate**
6. Wrong about cholecystitis:
  - a. **Emphysematous cholecystitis is treated conservatively**
7. Regarding gallstones, all are correct except:
  - a. black stones occur due to cirrhosis
  - b. brown stones found in bile duct
  - c. **primary gallstones occur in one year postcholecystectomy**
8. Risk for cholangiocarcinoma:
  - a. **Primary sclerosing cholangitis**
  - b. Choledocal cyst
  - c. Caroli's disease
  - d. small stones are associated with increased risk of acute pancreatitis
  - e. large stones are associated with increased risk Mirzzi syndrome
9. wrong about acute cholecystitis:
  - a. **U/S can differentiate between calculus and acalculus**
  - b. U/S has 97 % diagnostic accuracy
10. Not a risk factor of gallbladder carcinoma?
  - a. Choledochal cyst
  - b. Porcelain bladder
  - c. Dysfunction in the sphincter of Oddi
  - d. **Anomalous insertion of the pancreatic duct in the CBD**
11. One feature that doesn't different between calculus and acalculus cholecystitis:
  - a. **Sign and symptoms**
  - b. Mortality
  - c. Age
12. Gallstone ileus:
  - a. Recurrent cholangitis.
  - b. **SBO.**
  - c. acholic stools.
  - d. Air in biliary tree.
  - e. Stone on imaging.
13. Gallbladder function all true except:
  - a. Absorption of water
  - b. Absorption of H
  - c. **Absorption of Na**
  - d. Absorption of Cl
  - e. Secretion of glycoprotein
14. all of the following are on the transpyloric plane except:
  - a. Fundus of the gallbladder
  - b. Termination of the spinal cord
  - c. Dudeno-juenal junction
  - d. Neck of the pancreas
  - e. **origin of inferior mesenteric artery**
15. Gall stone, which is wrong?
  - a. **Primary gall stones are from stasis and infection**
16. About black pigments gallstones, WRONG:
  - a. Asccocited with hemolysis
  - b. With cirrhosis
  - c. **With infected bile**
17. Most useful way to diagnose gall stones
  - a. **Ultrasound**

# Acute abdomen, Appendix & small intestine

- Written by: Mohammad Daas
- Corrected by: Mohammad Qussay Al-Sabbagh

- Acute abdomen: 180
- Appendix: 185
- Small intestine: 191
  - Introduction: 191
  - Small intestinal obstruction: 194
  - Small intestinal tumors: 198
  - Fistulae: 203
- Summary & past papers: 206

# Acute Abdomen

## INTRODUCTION

✦ **Definition:** A sudden, severe abdominal pain, it's in many cases a surgical emergency, requiring urgent and specific diagnosis or surgical treatment.

- Causes range from self-limiting to severe life-threatening diseases.

## ? ETIOLOGY

8.42 Common non-traumatic causes of the acute abdomen		
Pathology	Organ	Disease
Inflammation	Appendix	Acute appendicitis
	Gallbladder	Acute cholecystitis
	Colon	Diverticulitis
	Fallopian tube	Salpingitis
	Pancreas	Acute pancreatitis
Obstruction	Intestine	Intestinal obstruction
	Gallbladder/bile duct	Biliary obstruction
	Ureter	Ureteric obstruction
	Urethra/bladder	Urinary retention
Ischaemia	Intestine	Strangulated hernia Volvulus Thromboembolism
	Ovary	Torsion of ovarian cyst
Perforation	Duodenum	Perforated peptic ulcer
	Stomach	Perforated ulcer/cancer
	Colon	Perforated diverticulum Perforated cancer
	Gallbladder	Biliary peritonitis
Rupture	Fallopian tube	Ruptured ectopic pregnancy
	Abdominal aorta	Ruptured aneurysm



# DIAGNOSIS

## ◆ Assessment:

### 1. Initial impression/ observation:

- Does the patient look ill, septic or shocked?
- lying still (peritonitis)? /rolling around in agony (intestinal, biliary or renal colic)?
- Assess and manage **Airway**, **Breathing** and **Circulation** as a **priority**.
- In an emergency department setting: if there are signs that the patient is **shocked** or **acutely unwell** assess quickly but carefully and arrange any early investigations.

### 2. Hx & PE



#### 8.43 Typical clinical features in patients with an 'acute abdomen'

Condition	History	Examination
Acute appendicitis	Nausea, vomiting, central abdominal pain which later shifts to the right iliac fossa	Fever, tenderness, guarding or palpable mass in the right iliac fossa, pelvic peritonitis on rectal examination
Perforated peptic ulcer with acute peritonitis	Vomiting at onset associated with severe acute onset abdominal pain, previous history of dyspepsia, ulcer disease, NSAIDs or corticosteroid therapy	Shallow breathing with minimal abdominal wall movement, abdominal tenderness and guarding, board-like rigidity, abdominal distension and absent bowel sounds
Acute pancreatitis	Anorexia, nausea, vomiting, constant severe epigastric pain, previous alcohol abuse/cholelithiasis	Fever, periumbilical or loin bruising, epigastric tenderness, variable guarding, reduced or absent bowel sounds
Ruptured aortic aneurysm	Sudden onset of severe, tearing back/loin/abdominal pain, hypotension and past history of vascular disease and/or high blood pressure	Shock and hypotension, pulsatile, tender, abdominal mass, asymmetrical femoral pulses
Acute mesenteric ischaemia	Anorexia, nausea, vomiting, bloody diarrhoea, constant, abdominal pain, previous history of vascular disease and/or high blood pressure	Atrial fibrillation, heart failure, asymmetrical peripheral pulses, absent bowel sounds, variable tenderness and guarding
Intestinal obstruction	Colicky central abdominal pain, nausea, vomiting and constipation	Surgical scars, hernias, mass, distension, visible peristalsis, increased bowel sounds
Ruptured ectopic pregnancy	Premenopausal; delayed or missed menstrual period, hypotension, unilateral iliac fossa pain, pleuritic shoulder tip pain, 'prune juice'-like vaginal discharge	Suprapubic tenderness, periumbilical bruising, pain and tenderness on vaginal examination (cervical excitation), swelling/fullness in the fornix on vaginal examination
Pelvic inflammatory disease	Sexually active young female, previous history of sexually transmitted infection, recent gynaecological procedure, pregnancy or use of intrauterine contraceptive device, irregular menstruation, dyspareunia, lower or central abdominal pain, backache, pleuritic right upper quadrant pain (Fitz-Hugh–Curtis syndrome)	Fever, vaginal discharge, pelvic peritonitis causing tenderness on rectal examination, right upper quadrant tenderness (perihepatitis), pain/tenderness on vaginal examination (cervical excitation), swelling/fullness in the fornix on vaginal examination





## 8.44 Clinical signs in the 'acute abdomen'

Sign	Disease associations	Examination
Murphy's	Acute cholecystitis Sensitivity 50–97% Specificity 50–80%	As the patient takes a deep breath in, gently palpate in the right upper quadrant of the abdomen; the acutely inflamed gallbladder contacts the examining fingers, evoking pain with the arrest of inspiration
Rovsing's	Acute appendicitis Sensitivity 20–70% Specificity 40–96%	Palpation in the left iliac fossa produces pain in the right iliac fossa
Iliopsoas	Retroileal appendicitis, iliopsoas abscess, perinephric abscess	Ask the patient to flex the thigh against the resistance of your hand; a painful response indicates an inflammatory process involving the right psoas muscle
Grey–Turner's and Cullen's	Haemorrhagic pancreatitis, aortic rupture and ruptured ectopic pregnancy (see Fig. 8.28)	Bleeding into the falciform ligament; bruising develops around the umbilicus (Cullen) or in the loins (Grey–Turner)

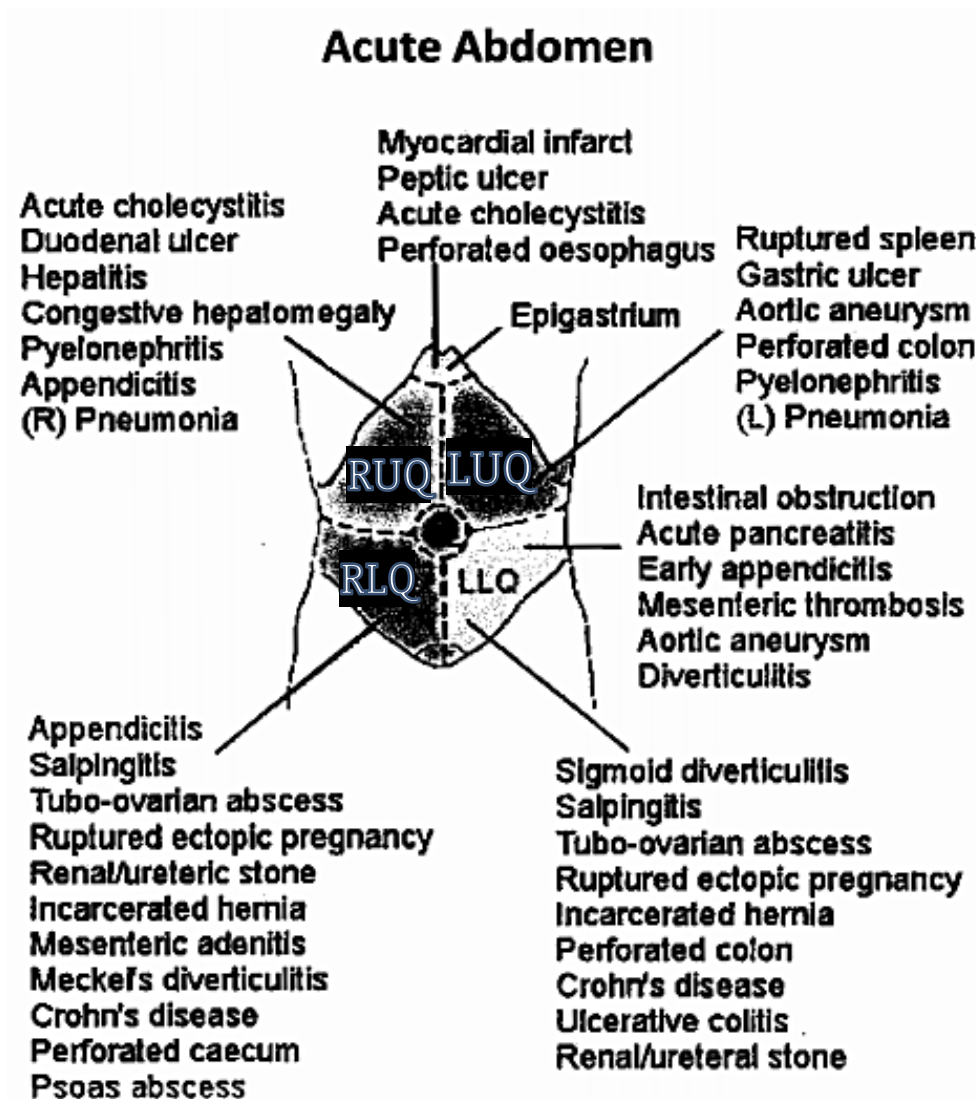
⚡ Abdominal signs may be masked in patients:

- Steroids
- Immunosuppressant
- anti-inflammatory drugs
- alcohol intoxication
- altered states of consciousness

⚡ Notes:

- Check lower limb pulses if there could be an abdominal aortic aneurysm.
- Dipstick urine and send for culture if appropriate.
- **In a woman of childbearing age, assume that she is pregnant until proven otherwise - perform a pregnancy test.**
- Examine any other system that might be relevant, eg respiratory, and CVS.

⚡ Differential Dx According to site:



**TREATMENT**

⚡ Prehospital/Emergency department care of suspected acute abdomen:

- Keep patient nil by mouth **NPO**
- Apply **oxygen** as appropriate.
- **Intravenous (IV) fluids**: set up immediately if the patient is shocked and the equipment is available. Send blood for group and save/crossmatch and other blood tests as appropriate.
- Consider passing a nasogastric (**NG**) **tube** if there is severe vomiting, signs of intestinal obstruction or the patient is extremely unwell and there is danger of aspiration.

- **Analgesia:** → the previous practice was to withhold analgesia until surgical review, but a surgical abdomen is very painful and is likely only to be adequately relieved by parenteral opioids, eg morphine. One recent review showed that opioid administration may alter physical examination findings, but these changes result in no significant increase in management errors. Another study showed that morphine safely provides analgesia without impairing diagnostic accuracy.
- **Antiemetic:** avoid using this as a symptomatic treatment without considering a diagnosis in a community setting.
- **Antibiotics:** if systemic sepsis, or peritonitis, or severe urinary tract infection (UTI) is suspected. IV cephalosporin plus metronidazole are commonly used in acutely unwell patients in whom peritonitis is suspected.
- Arrange **urgent surgical/gynaecological review** as appropriate.
- Arrange **investigations** such as **ECG** if a medical cause is likely.
- **Admit:** if surgery is considered likely, if the patient is unable to tolerate oral fluids, for pain control, if a medical cause is possible or if IV antibiotics are required.

# Appendix

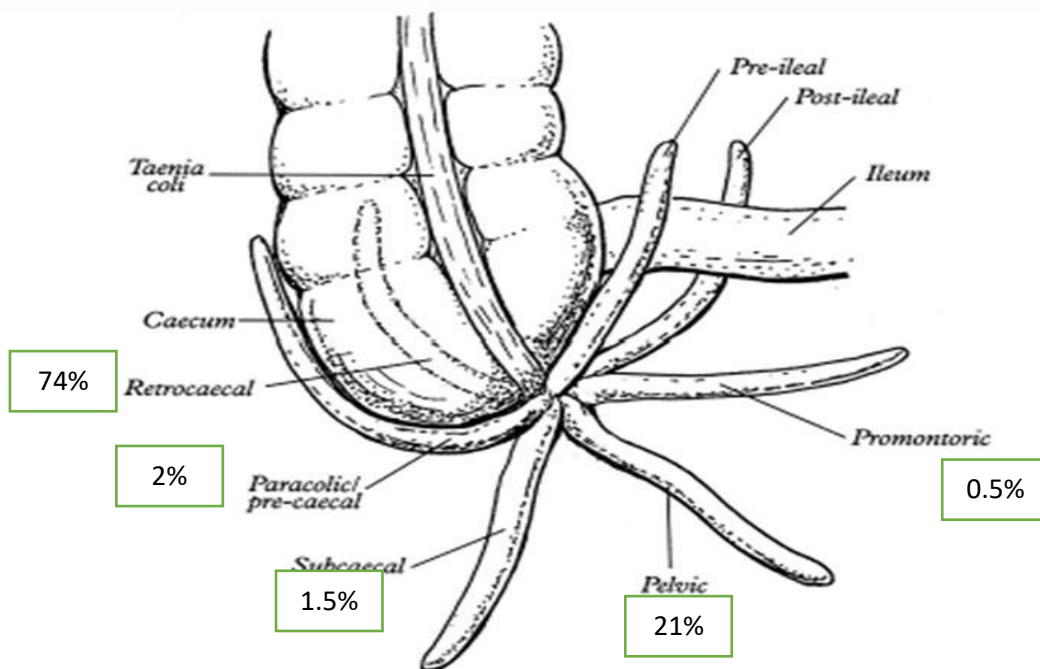
✦ **Embryology:** "intra-peritoneal structure"

- begins as a (bud off) from the cecum at around the 6<sup>th</sup> week of embryological development. **The base of the appendix remains in a fixed position** with respect to the cecum, whereas **the tip can end up in a various positions**

✦ **Anatomy**

- It's length range from 2 to 3 cm (avg. 6-9)

## Variations in position Vermiform Appendix



- the base of the appendix is **fixed in position** while its tip is in various position.
- Most common site → **Retrocecal (~74%)**
- 2<sup>nd</sup> m.c site → **Pelvic (~21%)**
- Appendix lumen capacity = 1 ml.
- To locate the appendix → locate the cecum → follow the 3 taenia coli until they converge at the base of the appendix

- Blood supply → appendicular artery "end artery" ( a terminal branch of the ileocolic artery that pass behind the terminal ileum and through the mesoappendix "the mesentery of the appendix")

⚡ **Physiology:** An immunological organ that secretes IgA  
"not essential organ & can be removed"

## Acute Appendicitis

### INTRODUCTION

⚡ **Definition:** inflammation of the appendix caused by obstruction of the appendiceal lumen, producing a closed loop with resultant inflammation that can lead to necrosis & perforation

⚡ **Epidemiology:**

- life-time Incidence → 7% of population
- Avg age → 20 – 30 years

### ETIOLOGY

⚡ **Causes:**

- Fecalith → 40% "most common"
- Hypertrophy of lymphoid tissue
- Tumor e.x. (carcinoid)
- Vegetable / fruits seeds
- Intestinal parasites / worms
- Inspissated barium from previous X-ray

Most common pathogens:  
- Ecoli  
- bacteroids fragilis

⚡ Acute appendicitis is usually misdiagnosed in females & elderly

⚡ Rare in extreme of age (if it happens → life threatening due to uncontrolled sepsis)

### PATHOPHYSIOLOGY

⚡ Obstruction → distention (increased intraluminal pressure) → venous congestion → impaired blood supply → bacterial accumulation → inflammation → Necrosis & perforation



## CLINICAL FEATURES

### ☪ Symptoms: "بالترتيب"

- 1) -Diffused pain (periumbilical area)"referred pain"  
- intermittent of cramps
- 2) Nausea / vomiting (After pain)  
due to Neural stimulation + presence of ileus
- 3) Anorexia
- 4) pain that migrates to RLQ  
(constant & intense pain) usually <24 hours  
due to peritoneal irritation

### ☪ Signs:

- 1) usually normal V/S
- 2) signs of peritoneal irritation :
  - Guarding / muscle spasm
  - Rebound tenderness
  - Obturator of psoas sign
  - Low-grade fever (high grade → if perforated)
  - RLQ Hyperesthesia

### ☪McBurney's Point :

point 1/3 from the ASIS to the umbilicus  
( often point of maximal tenderness)

### ☪Complications:

#### A) Of Appendicitis:

- \* Pelvic / liver abscess
- \* Portal pylethrombophlebitis
- \* perforation & peritonitis
- \* Gangrene

#### B) Of Appendectomy:

- \* Small bowel obstruction ( X4 more with perforation)
- \* Enterocutaneous fistula
- \* increase incidence of Rt inguinal hernia
- \* Stump abscess
- \* Wound infection
- \* Infertility with perforation in females

### Obturator sign

pain upon internal rotation of the leg to the hip & knee flexed (seen in pts with pelvic appendix)

### Rovsing's sign

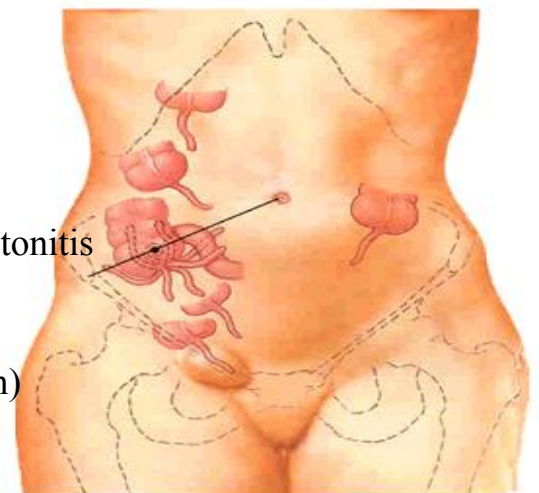
palpation / rebound pressure of LLQ resulting in pain in the RLQ (seen in appendicitis)

### Psoas sign

pain elicited by extending the hip with knee extended on by flexing the hip against resistance (seen in retro cecal app.)

### Valentino's sign

RLQ pain (peritonitis) from succus draining down to RLQ from a perforated gastric or duodenal ulcer



### Appendicitis in Pregnancy:

- Incidence → 1/1500
- chief complain → RUQ pain
- Risk of Fetal loss → 4%
- Risk of preterm labor → 7%
- \*\* it's the most common procedure done during pregnancy
- \*\* the only Abnormal finding is → Left shift



## DIAGNOSIS

◆ History & physical

◆ Investigations :

### 1. Labs

A) CBC : increased WBC (> 10,000 in 90%) most often with a **left shift**

B) U/A "urine analysis" : To rule out UTI (if +ve you can't rule out appendicitis):

- you may have abnormal U/A with appendicitis → **Pyuria & mild hematuria** are common in "appendicitis with pelvic inflammation" → resulting in inflammation of the ureter

C) also do  $\beta$ -hCG / BUN / Cr / electrolytes

### 2. Imaging

A) X-ray → to rule out other pathologies.

- CXR → to rule out pneumonia & free air

- AXR → calcified fecalith present in 5% of appendicitis cases "non-specific"

findings on AXR :

1. Fecalith (5% of cases)
2. Sentinel loops
3. Scoliosis away from the right (due to pain)
4. mass effect (abscess)
5. Loss of psoas shadow
6. Loss of preperitoneal fat stripe
7. free air (if perforated) "rare"

B) CT findings:

- periappendiceal fat stranding
- appendiceal diameter <6 mm
- periappendiceal fluid
- Fecalith

C) MRI (we use it in pregnant females)

D) Graded compression sonography (U/S)

→ most sensitive

#### ALVERADO SCORE :

used to assess the probability  
mnemonic ( **MANTRELS**)

**M:** migration of pain to RLQ  
(1)

**A:** Anorexia (1)

**N:** Nausea & Vomiting (1)

**\*\* T:** Tenderness in RLQ  
(2)

**R:** Rebound tenderness (1)

**E:** Elevated Temperature (1)

**\*\* L:** Leukocytosis (>10,000) (2)

**S:** Shift to the left (1)

**\*\* 2 points for T & L    \*\* 1 point for others**

**SCORE :**

### ⚡ Differential diagnoses:

1) Acute Abdomen :

Meckel's diverticulum , Peptic ulcer disease, Crohn's, Urological causes , Gastroenteritis

2) Acute Mesenteric Adenitis : (in children), M.C organism → **Yersinia enterocolitica**

3) Gynae: PID, Ruptured ovarian cyst/ graafian follicle, Ectopic pregnancy



## TREATMENT

### A) PRE-OP :

- Rehydration with IV fluid (Ringer lactate)
- Pre-op antibiotics with anaerobic coverage ( cefoxitin / cefotetan / ciprofloxacin / flagyl)

### B) OP :

⚡ If not perforated:

- prompt appendectomy → to prevent perforation
- 24 hours of antibiotics "anaerobic coverage"
- discharge home usually on postop day 1

⚡ If perforated (Ruptured):

- 25% of rupture → after 24 h, 75% → after 48 h.
- IV fluid resuscitation & prompt appendectomy
- All pus is drained
- postop antibiotics (broad spectrum) for 3-7 days
- wound is left open in most cases of perforation after closing the fascia → 2ry intention or delayed 1ry closure.

⚡ If appendiceal abscess:

- percutaneous drainage of abscess
- antibiotics to fight possible peritonitis
- Elective appendectomy → 6 weeks later

⚡ Notes:

- If normal appendix is found upon exploration → (take it out, even in Crohn's UNLESS the base is involved).
- After removing the appendix, it should be sent for pathological evaluation.



- Dx of ruptured appendix:
  - Fever (>39)                      - increased WBC                      -Rebound tenderness
  - U/S → periappendiceal fluid collection.
- Appendectomy is the most common cause of **emergent** abdominal surgery
- Open vs. laparoscopic appendectomy :
  - \*\* Open is more cost effective & time saving , less pain , less risk of wound infection & better anesthesia
  - \*\* contraindication of laparoscopic:
    - extensive adhesions   - severe portal tension   - coagulopathies   -1<sup>st</sup> trimester preg.
- Atypical presentations of appendicitis are not uncommon, and they depend on the location of the appendix, So pelvic appendix may present with UTI symptoms, pre-ileual & post- ileual may present with Intestinal obstruction, etc ....
- McBurney's vs. Rocky Davis incision:
  - McBurney's → angled down "oblique"
  - Rocky Davis incision → Straight across, "transvers"
- during surgery electrocautery is used → to avoid Mucocele
- Layers Cut during surgery:
  - Skin → Subcutaneous fat → Scarpa's fascia → Ext. oblique → Int. oblique
  - transversus abdominis → Transversatis fascia → Preperitoneal fat → peritoneum

### **Tumors of the Appendix:**

**CARCINOID**: "Most common"

- <5% malignant

- treatment:

If <1.5 cm → Appendectomy

If >1.5 cm → Right hemecolecotomy

- DDX:

\* Carcinoid   \* Adenocarcinoma

\* Malignant Muroid Adenocarcinoma

# Small Intestines

- The longest part of the GIT and extends from the pyloric orifice of the stomach to the ileocecal fold. This hollow tube which is 6-7 meters in long consists of the Duodenum, Jejunum and the ileum. Its function is (Digestion + Absorption)

## **Embryology:**

Foregut → esophagus to upper duodenum

Midgut → lower duodenum to proximal 2/3<sup>rd</sup> of transverse colon

\*\* the junction b/w the foregut & Midgut is immediately distal to the opening of CBD.

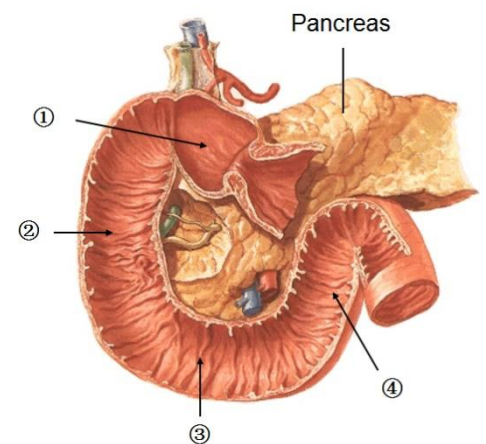
Hindgut → distal 1/3<sup>rd</sup> of transverse colon to anal canal above pectinate line

## **Anatomy:**

Ligament of trietz → marks the end of duodenum & the beginning of the jejunum.

### ❖ **Duodenum:**

- Extends from pylorus to the duodenojejunal junction.
- It's Retroperitoneal except the 1<sup>st</sup> 2cm
- Parts:
  - 1) 1<sup>st</sup> part (Superior) → 5cm , Duodenal bulb "site of most ulcers"
  - 2) 2<sup>nd</sup> Part (Descending) → 10 cm, curves around the head of pancreas.
  - 3) 3<sup>rd</sup> Part (Transverse) → 10 cm, crosses anteriorly to the aorta & IVC & posteriorly to SMA & SMV
  - 4) 4<sup>th</sup> Part (Ascending) → 5 cm, ascends past left side of aorta then curves anteriorly to meet DJ Junction suspended by ligament of trietz.
- Blood Supply:
  - **Proximal** part (up to ampulla of vater) → **Gastro duodenal art.** "br of proper hepatic art" it bifurcates into ant. & Post. Superior pancreatic duodenal art.
  - **Distal** Part (beyond the ampulla of vater) → **inf. Pancreatic duodenal art** "br. Of SMA" also bifurcates into Ant & Post art.
- Venous Drainage:
  - Ant & Post pancreatic duodenal vein, drain into → SMV (which joins



splenic v. to form portal vein.)

- Prepyloric vein of Mayo → it's a landmark for pylorus.

### ❖ Jejunum & Ileum:

- No anatomic boundaries b/w them
- Jejunum is the proximal (40% of small intestines) → "distal to ligament of trietz"
- Ileum is the distal (60% of SI).
- Mesentery tethers the jejunum & ileum to post. Abd. Wall
- Difference b/w them:
  - Jejunum →  
Long vasa recta + Large plica circularis + Thicker wall
  - Ileum →  
Short vasa recta + Smaller plica circularis + Thinner wall
- Terminal ileum absorbs → **B12**, fatty acids and bile salts.
- Blood supply:  
branches of SMA (which runs in the mesentery)  
arteries loop to form **arcades** that give rise to straight arteries → **vasa recta**.
- Venous Drainage → SMV

#### **Plica circularis:**

the circular folds of mucosa in small intestines lumen

**AKA** (valvulae conniventes)

**plica = folds**

### ❖ Lymphatics:

- Bowel wall → mesenteric nodes → lymphatic vessels → Cisterna chily → thoracic duct → Lt subclavian vein

### ❖ Innervation:

- Parasympathetic → originates from Vagus & celiac trunk + motility
- Sympathetic → originates from ganglion cells that reside at the base of SMA
- + motility
- Enteric Nervous system → Meissner plexus

### **Physiology:**

90% of digestion & Absorption

Digestion in duodenum → food is mixed with (bile from liver, pancreatic juice + intestinal juice "Succus entericus")

## Investigations:

☸ It is difficult to examine the whole small bowel because of its length so we need different tests and investigations to get the whole picture:

- **Contrast study:** the patient swallows barium or the contrast material then we follow the contrast with series of X-rays until the contrast reach the colon.
- **Enteroclysis:** is mostly the same procedure but the difference here is that we inject the contrast material through a tube in the stomach.
- **Endoscopy:** classically we do upper GI endoscopy for the stomach and duodenum but there is certain techniques which help in examining the whole intestines such as:
  1. **Double balloon enteroscopy (DBE)** (also known as "push-pull enteroscopy) or the "double-bubble": is a new endoscopic technique that allows pan-enteric (complete) examination of the small bowel.
  2. **Push endoscopy** (also referred to as push enteroscopy): is a procedure that allows diagnosis and treatment of diseases in the upper small intestine. Push endoscopy reaches further into the small intestine than the standard upper gastrointestinal endoscopy.
- **MRI/CT enterography:** uses CT imagery and a contrast material for a better view of small intestine by examining it loop by loop (most commonly used).
- **Angiography:** to examine the blood supply for a tumor as an example.
- **Capsule endoscopy:** is a camera that images the entire GI tract down to the colon and look for any lesion, it is an expensive test and we have to make sure that there is no narrowing in the intestines before doing it. It is done to certain patients whose signs and symptoms are not clear.

# Small Bowel Obstruction

## INTRODUCTION

### Definition:

Interruption in the normal flow of intestinal contents along the intestinal tract  
SBO accounts for **20%** of all acute surgical admissions

\*\* Ileus → when the obstruction is functional "it mimics the SBO"

## ETIOLOGY

**Risk factors:** check the table.

### Causes:

- **Intraluminal:**
- Fecal impaction "immobile bulk"
- Foreign bodies
- Bezoars "solid mass of indigestible"
  - **Trichobezoars** → a hair bolus occurring in young females with long hair & psychiatric disorder
  
- Gall stone ileus "usually due to fistula"
- **Intramural:**
- Strictures → they are due to :  
ischemia, inflammation " such as crohn's",  
RTX, Surgical "iatrogenic or trauma".
- CA
- Diverticulosis
  
- **Extramural:**
- Hernia (internal / external) → **m.c.c world wide**
- Adhesions → fibrinous or fibrous (M.C.C in developed world)
- Volvulus
- Intussusception

### Common causes of alimentary tract obstruction, by age

#### Neonates

Atresia (duodenum, ileum)  
Meconium obstruction  
Volvulus neonatorum

#### 3 weeks

Congenital hypertrophic pyloric stenosis

#### 6-9 months

Intussusception

#### Teenage

Inflammatory masses (appendicitis)  
Intussusception of Meckel's diverticulum or polyp

#### Young adult

Hernia  
Adhesions

#### Adult

Hernia  
Adhesions  
Inflammation (appendicitis, Crohn's disease)  
Carcinoma

#### Elderly

Carcinoma  
Inflammation (diverticulitis)  
Sigmoid volvulus

The most prominent Gas found in SBO → is **N<sub>2</sub>** because it's an absorbable gas

The M.C.C of colonic obstruction:  
1<sup>st</sup> Colon CA  
2<sup>nd</sup> Volvulus  
3<sup>rd</sup> Diverticulosis

acronym "GIVES BAD CRAMPS":

Gallstone ileus

Intussusception

Volvulus

External compression

SMA syndrome

Bezoars, Bowel wall hematoma

Abscesses

Diverticulitis

Crohn's disease

Radiation enteritis

Annular pancreas

Meckel's diverticulum

Peritoneal adhesions

Stricture

- **Causes of functional obstruction:**
- Postop Ileus → Normally resolves in 3-5 days
- Electrolyte abnormalities → hypokalemia
- Peritonitis, sepsis, shock
- Drugs (opiates/ anticholinergic)
- Hemoperitoneal/ Retroperitoneal hemorrhage

## ⚡ PATHOPHYSIOLOGY

### Mechanism

- **Increased peristalsis** → Abd colic, increased bowel sounds, & borborygmi
- **Proximal bowel distension** → third space losses, electrolyte imbalance, air-fluid levels:
  - Increased secretion and decreases absorption → fluid accumulation
  - Swallowed air accumulation
- **Bacterial overgrowth and translocation**
- **Increased wall tension compromise of circulation**

### Classifications:

- Mechanical vs. Functional (pseudo-obstruction, Adynamic, Paralytic ileus)
- Complete vs. partial

#### Complete vs. partial

**Complete** → usually no passage of stool & flatus (obstipation) + increased risk of strangulation

**Partial:** some passage of flatus.

\*\* We differentiate using CT with oral contrast + small bowel follow through

- Simple vs. complicated (strangulated)
- Small bowel (distal / proximal) vs. Large bowel obstruction
- Acute vs. chronic
- Closed loop vs. open loop
- Gangrenous vs. non-gangrenous

## 🔍 CLINICAL FEATURES

### Signs and Symptoms:

- Colicky **pain** → if proximal then time b/w attacks is LESS than distal obst.
- **Vomiting** → Proximal > Distal  
its color → watery/ bile stained "green"/ feculent if distal "brown + smelly"

- **Constipation** → Distal > Proximal  
\*\*in distal there is no passage of flatus while in early proximal there can be.
- **Distention** → Distal > Proximal  
\*\*in distal we might see visible peristalsis + visible right iliac fossa bulge "caecum" if there was a competent ileocecal valve.
- Diarrhea → in certain cases like partial obst, colon CA, GB obstruction
- Increased bowel sounds + visible peristalsis.

#### Signs of strangulated bowel with SBO:

- **Fever/ Severe & continuous pain**
- **Tachycardia**
- Hematemesis
- **Shock/ Acidosis/ Peritoneal signs**
- Gas in the bowel wall or portal vein /Abdominal free gas

#### Complications:

- Bowel ischemia → necrosis
- Perforation.
- Sepsis
- Intra-abdominal abscess
- Wound dehiscence
- Aspiration
- Short-bowel syndrome (as a result of multiple surgeries)
- Death (secondary to delayed treatment)



## DIAGNOSIS

### ⚡ History and physical Examination

#### ⚡ Labs:

**CBC / Electrolytes / Creatinin/ BUN/ Urine analysis**

#### ⚡ Imaging:

- **Plain AXR:**
  - Erect → multiple air-fluid level (non-specific)
  - Supine → Distended Bowel  
- Duodenum → hollow tube

#### By Supine abd X-ray:

- \*Confirm Dx
- \*Detect if proximal or distal
- \*Detect type of intestine involved

\*\* Presence of any gas in Small intestine is indicative of obstruction.

**UNLIKE** colon, which normally contain gas

- Jejunum → Plica circularis "coins like"
- Colon → Haustration
- Gas in intramural space → infarction
- Gas under diaphragm → Perforation
- **Enteroclysis / CT / Ultrasound.**



## TREATMENT

### Management:

#### Initially

- NPO
- NG tube
- IV fluid
- Foley catheter

#### Then

- If complete obstruction:
  - lysis of adhesions (adhesiolysis)
- If partial obstruction:
  - initial management + conservative treatment + close observation + NGT decompression

### Medically:

→ Non-operative treatment "dr. qudah slide 29"

### Surgical:

**Open surgery** is frequently used for patients with

- strangulating adhesive SBO
- after failed conservative management
- in appropriate patients, a laparoscopic approach using an open access technique is recommended.



# Small Bowel Tumors



## INTRODUCTION

- ✦ It is only about 1-2% of the GI tumors, Same in males and females.
- Benign lesions are more common distal, while carcinomas are more common proximal.



## ETIOLOGY

### ✦ Risk factors:

- Familial adenomatous polyposis.
- HNPCC.
- Peutz-Jeghers syndrome.
- Crohn's disease.
- Celiac disease.
- Biliary diversion



## CLINICAL FEATURES

### ✦ Clinical presentation:

- Age: 6<sup>th</sup>/7<sup>th</sup> decades of life.
- Found incidentally.
- Vague symptoms (nausea, dyspepsia, epigastric discomfort, weight loss, hemorrhage).
- Other presentations: Mass, fistula, perforation, intraperitoneal hemorrhage.



## DIAGNOSIS

✦ Contrast studies, special types of upper endoscopy, angiography, CT/MR enterography ..

✦ The tumors are classified into a benign, malignant and a carcinoid which we can't tell if the tumor is definitely benign or definitely malignant:

## **1- Adenoma (benign tumors)**

⚡ The benign are adenomas which are polyps, 20% are in duodenum 30% are in jejunum and 50% are in ileum, and as more distal the polyp is the more benign it is, villous adenomas are more common in duodenum and as more villous structure there the more potential to be pre-Malignant.

- Because it is benign, it's commonly asymptomatic, may present with obstruction, bleeding (mainly upper GI bleeding that due to a polyp in the jejunum).
- Malignant changes increase with increased size, site (Adenomas involving the ampulla transform to malignancy more often than do lesions found elsewhere in the duodenum and small intestine).
- Patient's with FAP have increased risk to develop duodenal polyps, and polyps elsewhere in the GI tract. The interesting thing that developing polyps in the colon has a 100% risk to develop cancer, but that of the small bowel, the risk of developing cancer is 2-12%.
- It is treated by surgical excision and follow up

⚡ Other benign tumors:

- fibromyoma, lipoma, leiomyomas and other vascular tumors.

## **2- Malignant tumors:**

⚡ Always produce symptoms, the most common presentation is weight loss and pain, other presentations are obstruction, bleeding, adhesions and diarrhea.

### **a) Carcinoid tumor**

⚡ It originates from the enterochromaffin cells.

- It may present in the foregut, midgut and the hindgut.
- It is the most common cancer of the appendix and it is found accidentally (after appendectomy) so it is painless.
- The most common site of the Carcinoid is the terminal ileum.
- Carcinoid increases the risk of developing adenocarcinoma of the colon by 10-20% causing obstruction, fibrosis, and ischemia.
- It is a slow growing, yellow tumor that can metastasize to the nearby LN which they are around vessels, fibrosis may occur there so it will cause ischemia in a segment of the small bowel, and that is what we found during surgery; a yellow tumor and an ischemic segment of the small bowel.

⚡ So, the Carcinoid may metastasize to nearby lymph nodes and to the liver, where it will cause ulceration, obstruction and jaundice.

- Carcinoid of the Terminal ileum seems to be more aggressive than that of the appendix.
- The risk of metastasis increases with increasing size, so if the tumor size is more than 2 cm, the risk of metastasize more and more. If the metastasis happens toward the liver this increases the risk of developing the Carcinoid syndrome, where serotonin (secreted by the tumor) can bypass the liver and cause diarrhea and flushing.
- By logic, the prognosis becomes more and more dismal if the metastasis occurs.
- There is a correlation between Carcinoid and increasing levels of acetic acid; Since 5-HIAA is a metabolite of serotonin, testing is most frequently performed for the diagnosis of carcinoid tumors of the enterochromaffin (Kultschitzsky) cells of the small intestine, which release large amounts of serotonin. Values greater than 25mg per 24 hours (higher if the patient has malabsorption) are strong evidence for carcinoid. (The normal range is 2 to 6 mg per 24 hours)
- About 30% of Forgut Carcinoid patient lack the enzyme that convert L-5 hydroxytryptophan to serotonin, so we check it if we suspect the patient to have forgut Carcinoid.

⚡ Treatment of carcinoid:

- **Surgical resection** with the involved lymph node if we cannot resect all tumor we do **tumor debulking “cytoreduction”** (remove part of tumor+ give Cryotherapy).
- Radiofrequency ablation: Two probes is placed inside the tumor, the radiofrequency waves passing through the probe increase the temperature within tumor tissue and results in destruction of the tumor and stop the tumor.
- Embolization of hepatic artery.
- Chemoembolization.
- Somatostatin or its analog (systemic therapy).
- No Chemotherapy in Carcinoid.

#### **b) Adenocarcinoma:**

⚡ More common in proximal small bowel, Usually in older people

⚡ Present with nonspecific symptoms.

⚡ Treatment: Resection with involved lymph node.

## ☼Notes:

- The more proximal the tumor in small bowel the more malignant, and adenocarcinoma is more common in proximal small bowel.
- In proximal small bowel tumors, we can't do major resection in the upper small bowel because wherever we get proximal in small bowel we get closer to the root of mesentery which is superior mesenteric artery that we cannot resect because it's the main supply to the small bowel.
- So we do wedge resection with the involve lymph node.
- The 5-year survival is worse if we have lymph node involvement.
- **Exception:** Crohn's disease and adenocarcinoma:
  - Patients with Crohn's which occurs mostly in terminal ileum have increased risk of adenocarcinoma in terminal ileum.
  - Usually in younger patients.
  - More in males.
  - Prognosis is poor because there is other disease (there are two diseases; Crohn's and the cancer).
  - We diagnose Crohn's disease by biopsy. But in some situations we treat patients based on our clinical findings, Always be careful in diagnosis because in Crohn's disease you will give the patient immunosuppressant →if the patient had a tumor →it will grow faster.

### c) Gastrointestinal lymphoma

☼We talked about GI lymphomas in Chapter 1, here we'll concentrate on the small intestine.

- The 2<sup>nd</sup> most common site for GI lymphoma is the small intestine.
- It can present with obstructing, bleeding, anorexia or weight loss.
- Usually seen in older people.
- More common in ileum because it contains more lymph nodes.
- Associated with celiac disease and immunosuppression (AIDS).
- Treatment is medical unless complicated.
- Complications are perforation, hemorrhage, obstruction, and intussusception.

### d) Gastrointestinal stromal tumors (GIST):

- Usually arise from connective tissue cells
- Could be benign or malignant.
- The risk of malignancy is related to the size of the tumor.

- More common in stomach compared to small bowel and usually in older people.
- There is no lymphatic spread but it can metastasize to peritoneum and liver.
- Prognosis depends on tumor size and mitotic figures on pathology.
- Treatment: surgery with clean margins.

# Fistulas

## INTRODUCTION

⚡ **Definition:** Abnormal communication between 2 epithelized organs

### ⚡ Classification

- External "most common " (drains to the skin) vs. Internal (between two organs).
- Proximal vs. Distal
  - Proximal:
    - usually high output
    - associated with dehydration/ malnutrition/ electrolytes disturbances.

**LOW OUTPUT = < 200**

**MODERATE OUTPUT = 200-500**

**HIGH OUTPUT = > 500**

## ? ETIOLOGY

### ⚡ Causes (HIS FRIEND)

- High output fistula (> 500 cc/day)
- Intestinal destruction (> 50% of circumference)
- Short segment fistula (< 2.5 cm)
- Foreign body (e.g., G-tube)
- Radiation
- Infection
- Epithelization (e.g., colostomy)
- Neoplasm
- Distal obstruction

## ⚡ PATHOPHYSIOLOGY

### Types

- ❖ **Enterocutaneous Fistula** → from GIT to skin (entero – cutaneous = bowel to skin)
  - Causes
    - Anastomotic leak.
    - Trauma/ iatrogenic.
    - Infections → Abscess/ TB/ Amebiasis.
    - Crohn's disease.
    - Diverticulitis (m.c.c of colovesical fistula).

- Inflammation.
- Inadvertent suture into the bowel.
- Vascular compromise.
- Complications
  - High output fistula
  - Malnutrition
  - Skin breakdown
- Investigations
  - CT scan → to rule out abscess/ inflammation
  - Fistulogram
  - Endoscopy
- Management
  - NPO/ TPN
  - Drain the abscess
  - Rule out or correct the underlying cause
- Treatment
  - 50% → resolves spontaneously after 4 weeks of sepsis & adequate nutrition support.
  - 50% → Need surgery (considered dirty surgery)
  - Long fistulas heals faster
  - Resection & primary anastomosis
  - Vacuum assisted closure device

#### Cholecystenteric Fistula:

- ➔ Connection b/w GB & duodenum or other loop
- due to large erosion, often result in SBO as the gallstone lodges the ileocecal valve (gallstone ileus)

#### Gastrocolic Fistula:

- ➔ Causes by penetrating ulcers, gastric or colonic cancer, crohn's
- ➔ Complications are malnutrition & severe enteritis

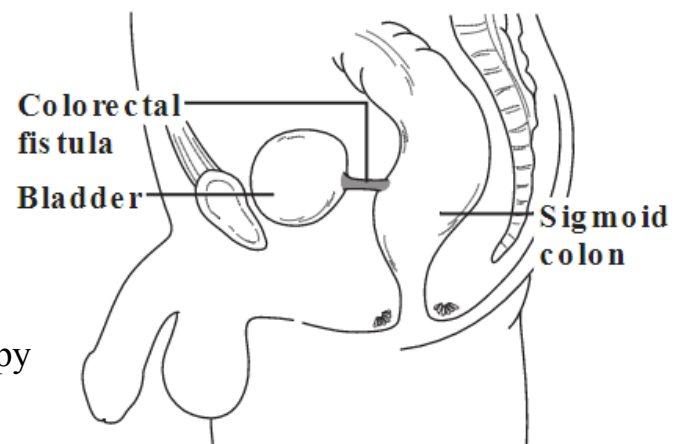
#### Factors increase rate of closure:

- Decrease output
- Long tract > 2 cm
- Small orifice < 1 cm

#### ❖ Colonic Fistula

Colovesical (m.c) → presents with recurrent UTI  
Colocutaneous / Colovaginal / Coloenteric

- Causes
  - Diverticulitis (m.c)
  - Foreign body
  - Cancer
  - IBD
  - RTX "irradiation"
- Diagnosing
  - Barium enema or Cystoscopy



- Treatment
  - Surgery → segmental resection & primary anastomosis & repair/resection of the involved organ

#### ❖ **Pancreatic Enteric Fistula**

→ Decompression of a pseudocyst or abscess into adjacent organ, (usually done surgically or endoscopically to treat a pancreatic pseudocyst).

#### ➔ **External Pancreatic Fistula**

Pancreatico-cutaneous fistula → drainage of pancreatic exocrine secretions into skin ( usually through drain/tract/wound).

- Diagnosing → **ERCP**
- Management & Treatment
  - NPO/TPN/Skin protection
  - Octreotide → somatostatin ( decrease the output of the fistula)
  - If refractory "doesn't resolve with conservative medical Mgt"
    - \*\* if in the **tail** = tail resection,
    - \*\*if in the **head** = pancreaticjejunostomy.

#### ➔ **Bladder Fistula**

- Types
  - Vesicoenteric → 50% to sigmoid diverticulitis  
signs: Pneumaturia/ Fecaluria
  - Vesicovaginal → secondary to gynecological procedures  
Signs: Urinary leak through vagina

➔ **Fistula In Ano** → from rectum to anal skin (see chapter 5)



# Summary & past papers

## Summary

⚡ Acute abdomen is a sudden, severe abdominal pain, it's in many cases a surgical emergency, requiring urgent and specific diagnosis or surgical treatment. Surgical causes result from inflammation (appendicitis, cholecystitis, diverticulitis, salpingitis, acute pancreatitis), obstruction (intestinal, biliary, or ureteric), ischemia (intestinal or ovarian), perforation (of PUD, diverticulum, cancer or the gallbladder), and rupture (of fallopian tube or abdominal aorta). In emergency settings, patient should be NPO, two large bore cannulas should be set immediately (for IV fluids + blood group/crossmatch and other blood tests), NGT placement in cases of severe vomiting or intestinal obstruction. Consider giving analgesia and antibiotics if needed. Avoid using antiemetics as a symptomatic treatment without considering a diagnosis in a community setting. Then arrange urgent surgical/gynaecological review as appropriate.

⚡ Acute Appendicitis is the inflammation of the appendix, caused by obstruction of the appendiceal lumen, producing a closed loop with resultant inflammation that can lead to necrosis & perforation. It's most commonly seen in young adults (20-30 years). It presents classically with periumbilical pain, intermittent of cramps, nausea, vomiting, anorexia and pain that migrates to RLQ, sequentially. Signs of peritoneal irritation (Rebound tenderness, Obturator sign and psoas sign) could be evident. Labs may show leukocytosis with left to the shift. Ultrasound is the most sensitive imaging technique. Atypical presentations of appendicitis are not uncommon, and they depend on the location of the appendix, the most common site for the appendix is retroceally. Appendicitis is treated with prompt appendectomy after stabilization of the patient, with oral antibiotics for 24 hours. If the patient has ruptured appendix, all pus should be drained intraoperatively, and the patient should

be hospitalized for 3-5 days with broad spectrum antibiotics. After appendectomy, the appendix should be sent for pathology immediately.

⚡ It is difficult to examine the whole small bowel because of its length so we need different tests and investigations to get the whole picture, such as contrast study, enteroclysis (similar to contrast study, but the Double balloon enteroscopy and push endoscopy), MRI/CT enterography, angiography and capsule endoscopy.

⚡ Intestinal obstruction is an interruption in the normal flow of intestinal contents along the intestinal tract. It's classified into small and large bowel obstruction. Most common causes of small bowel obstruction (SBO) are hernias (most common worldwide), intra-abdominal adhesions (most common cause in developed world), malignancy, and volvulus. While most common causes of large bowel obstruction are colon CA, volvulus and diverticulosis, respectively. Bowel obstruction presents, in general, with colicky pain (frequency is more in distal obstruction), Vomiting (Proximal > Distal), constipation (Distal > Proximal), and abdominal distention. Bowel sounds could be increased, and peristaltic waves may be visible. Presence of severe fever, continuous pain, tachycardia, hematemesis, peritoneal signs and gas in the bowel wall or portal vein may indicate strangulation or perforation. Patients with intestinal obstruction are dehydrated as well due to 3<sup>rd</sup> spacing. Once intestinal obstruction is suspected, abdominal X-ray should be done, it can demonstrate the site of obstruction, and the presence of infarction or perforation. In the ER settings, all patients with suspected intestinal obstruction should be NPO and may require NGT to decompress the bowel. Rehydration is important as well. The patient is managed then conservatively or surgically according to the cause.

Small bowel tumors consist only about 1-2% of the GI tumors. Benign lesions are more common distally, while carcinomas are more common proximally. Small intestinal tumors usually present with nonspecific signs and symptoms (nausea, dyspepsia, epigastric discomfort, weight loss, hemorrhage). The tumors are classified into a benign, malignant and a carcinoid which we can't tell if the tumor is definitely benign or definitely malignant. Adenomas are benign tumors, most commonly found in the ileum (50%) are in ileum. Carcinoid tumor originates from the enterochromaffin cells. It is the most common cancer of the appendix and usually found incidentally (after appendectomy), the most common site for carcinoid, however, is the terminal ileum. Carcinoid of the Terminal ileum seems to be more aggressive than that of the appendix. Carcinoid produces 5-HIAA, which may lead to carcinoid syndrome (flushing and diarrhea, right sided heart failure, emesis and bronchoconstriction). Adenocarcinoma is more common in proximal small bowel, usually in older people. The only exception to this is Chron's disease; patients with Chron's disease have increased risk of adenocarcinoma in terminal ileum. The small intestines are the 2nd most common site for GI lymphoma (after the stomach), and found most commonly in the ileum; because it contains more lymph nodes. Small intestinal lymphomas are associated with celiac disease and immunosuppression (AIDS). Gastrointestinal stromal tumors (GIST) arise from connective tissue cells (intestinal cells of Cajal) and are C-Kit positive. They are more common in stomach compared to small bowel.

A fistula is an abnormal communication between 2 epithelized organs. Fistulas are classified into external (drains to the skin) or Internal (between two organs), Proximal or distal, and high output (> 500 cc/day) or low output (>200 cc/day). Risk factors for fistula formation and persistence are: High output fistula, short segment fistula (< 2.5 cm), presence of foreign body, radiation, Infection, Intestinal destruction, epithelization and neoplasms.

## Past papers

### 1. What is wrong about intestinal obstruction??

- a) most adhesive SBO are treated conservatively
- b) you shouldn't give analgesia because it will mask the symptoms**

### 2. True about small bowel carcinoma?

- a) more in young
- b) more in terminal ileum
- c) Crohn's is a risk factor**

### 3. True about the peritoneum:

- a) visceral peritoneum is heavily innervated.
- b) secretes fibrinolytics.**
- c) Parietal peritoneum is poorly innervated
- d) It's surface area is double that of skin
- e) It cannot absorb large amounts of fluids

### 4. True about the appendix?

- a) Contains lymphoid follicles in the submucosa**

### 5. What predicts earlier spontaneous closure of enterocutaneous fistula?

- a) long tract**

### 6. in which part of the small intestine does absorption of most nutrients occur?

- a) Jejunum**

### 7. About carcinoid what is false?

- a) Most of the appendiceal carcinoid are malignant**
- b) Syndrome is due to 5-HIAA
- c) Bronchial carcinoids usually associated with carcinoid syndrome
- d) carcinoid is part of MEN 1

### 8. Pseudo-obstruction syndrome (ogilvie's), all true except:

- a) Increased sympathetic tone and decreased parasympathetic tone.
- b) More on the left side**

c) Risk of perforation is 15%

**9. GIST arise from:**

a) **Cells of Cajal**

**10. Wrong about appendicitis:**

a) **Mainly in pediatrics**

**11. After performing Appendectomy, nurse giving you the tissue you removed, MANS:**

a) **Carefully label and send to histology.**

**12. Right iliac fossa pain with anorexia. MANS:**

a) **Arrange for theatre since surgery is the management.**

**13. Which of the following locations of carcinoid is most likely to mets:**

- a) Appendix
- b) **Ilium**
- c) Rectum

**14. About GI lymphoma, false:**

- a) most common site of extra nodal involvement
- b) most are NHL B cell type
- c) 5 year survival more than 50 %
- d) **can't be treated with chemotherapy and radiotherapy**

**15. false about small bowel tumors?**

a) **Seen in younger age group**

**16. Question about UC and crohn's, which is wrong:**

- a) **Crohn's 50% associated with caseating granuloma**
- b) Cryptitis and crypt abscess is pathognomonic for UC

**17. Indications for surgery in UC EXCEPT:**

- a) Toxic megacolon
- b) Massive bleeding
- c) Obstruction
- d) **Primary sclerosing cholangitis (PSC)**
- e) Sepsis related colitis

**18. in small intestinal cancer what's wrong :**

- a) Celiac disease is associated with Gilymphoma
- b) Crohn's is associated with Gladenocarcinoma
- c) **wrong answer**
- d) Peutz-Jegher syndrome is hamartomatous
- e) juvenile polyps are hamartomatous

**19. All are true regarding carcinoids except:**

- a) **most common site is the appendix**
- b) ileal carcinoids are rarely multicentric
- c) usually associated with other tumors of the GI
- d) of differing histology
- e) tumor originates from enterochromaffin cells
- f) ileal carcinoid follow a more malignant Course

**20. A patient underwent GI surgery in which the Ileum was resected, one of the following is affected:**

- a) Fe
- b) **B12**

**21. Wrong about peritonitis**

- a) is inflammation of peritoneum
- b) most common surgical cause is secondary bacterial contamination
- c) can be septic or aseptic
- d) **primary peritonitis is more common in adults than in children**

**22. Not dangerous in intestinal obstruction:**

- a) **crampy abdominal pain**
- b) fever
- c) rigidity
- d) absent bowel sounds
- e) feculant vomitus

**23. CT findings of appendicitis, all except:**

- a) halo or target sign
- b) **diameter of 3-5 mm**
- c) fecalith
- d) fat streaking

**24. intestinal obstruction, wrong:**

- a) intussusception in an adult could cause it due to a pathological cause behind it
- b) **hernia is the m.c.c in children'**
- c) tumors obstruction due to peritoneal mets is a leading cause in adults

**25. All are associated with malignant transformation in small intestine except**

- a) **Scleroderma**
- b) Crohn's disease
- c) FAP
- d) Puets j eghers syndrome

**26. one is false about appendicitis with elderly:**

- a) **WBC is normal**
- b) Fever is not always present
- c) 50% are ruptured at presenting

**27. one is false about abdominal wall mets:**

- a) Associated with hematogenous spread of malignancy
- b) Seeding at site of laparoscopic entry.
- c) **Present as painful peritoneal Mass**

**28. one is false about crohn's**

- a) Mostly at 4th and 5th decades
- b) can be associate with cancer in the long run
- c) **megacolon and rupture is rare**

**29. GIST all true except**

- a) **mets to the lymph nodes is common**

**30. most common extraintestinal manifestation in crohns :**

- b) Ankylosing spondylitis
- c) Arthritis
- d) **erythema nodosum**

- e) iritis

**31. appendicitis in pregnant lady ... which is true:**

- a) risk is the same with normal ladies
- b) risk is highest in the 1st 2 trimesters
- c) **if suspected acute appendicitis then remove it as early as possible**

**32. not indication for surgery in UC:**

- a) toxic mega colon
- b) massive GI hemorrhage
- c) refractory to medical
- d) **responsive to medical but persisted more than 7 years.**

**33. Wrong about chron's :**

- a) bleeding per rectum
- b) fistulas
- c) skip
- d) **commonly involved rectum**

**34. Crohn's disease associated fistula all are true except:**

- a) **colovesical is associated with acute UTI caused by single organism**
- b) colovesical is associated with pneumaturia
- c) colointestinal may be asymptomatic
- d) colovaginal associated with feces and flatus through vagina
- e) colocutaneous associated with secretion to the skin

**35. Mcc of mechanical intestinal obstruction in adult population is:**

- a) internal hernia
- b) **adhesions after surgery**



# Colon, Rectum & anus

- Written by: Mohammad Karajeh & Yousef Al-As3d
- Corrected by: Mohammad Qussay Al-Sabbagh & Nada Hajjaj

- Colon: 212

- Introduction: 212
- Colonic polyps: 216
- Colorectal CA: 219
- Surgical management of colorectal cancer: 224.
- Diverticular disease: 227
- Volvulus: 232
- Summary & past papers: 235

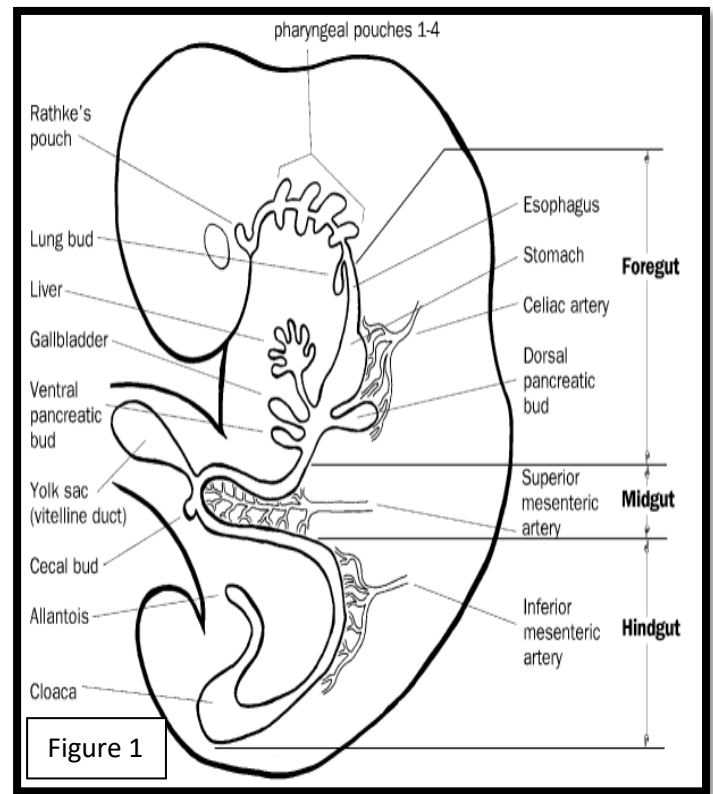
- Anorectum: 239

- Introduction: 239
- Hemorrhoidal diseases: 244
- Anal fissure: 248
- Perianal suppuration: 255
- Other anaorectal conditions: 257.
- Anal CA: 260
- Summary & past papers: 263

# The Colon

## ❖ Embryology: [Figure 1]

- The embryonic midgut (Endoderm) gives rise to the ascending colon and 2/3 of the transverse colon.
- The embryonic hindgut (Endoderm) gives rise to the rest of the colon, rectum and the proximal anus.
- In the development of the midgut loop, it rotates 270° counterclockwise around the axis of SMA. (Development anomalies include malrotation or failure of the right colon to elongate).
- The ectoderm gives rise to the distal anus.
- The dentate line (in the anal canal) marks the transition between the hindgut and the ectoderm.



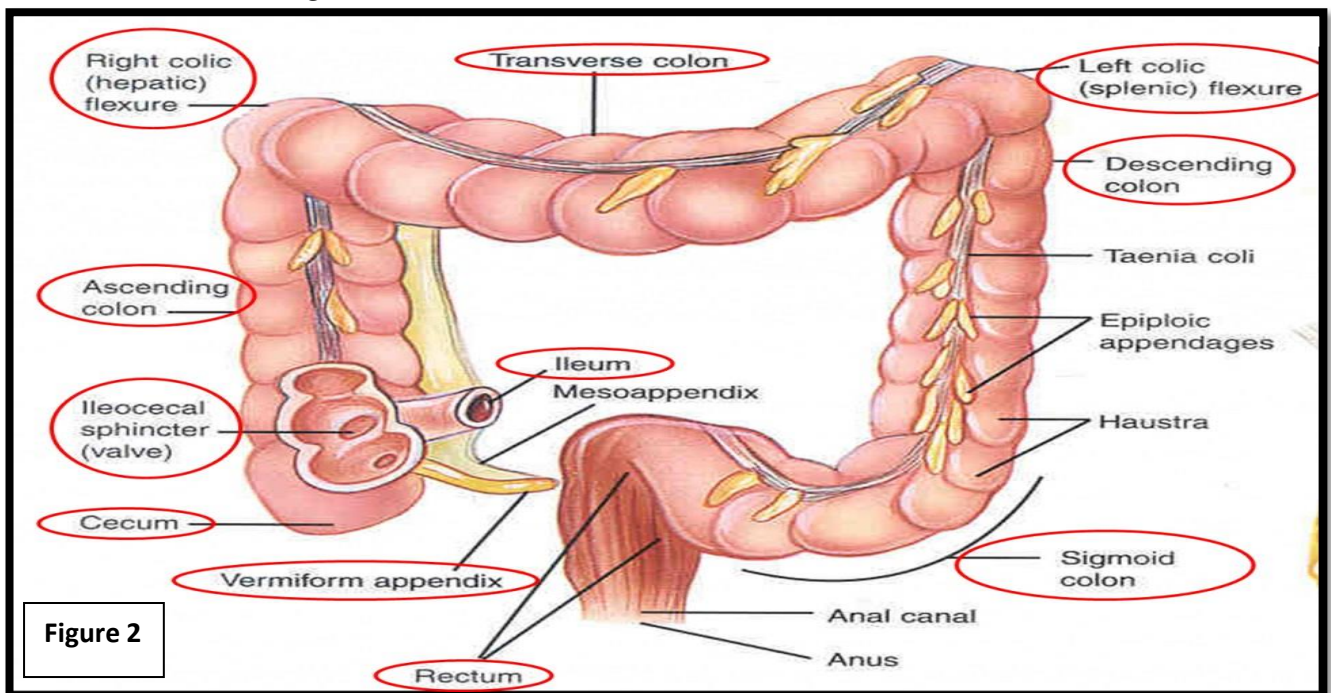
## ❖ Anatomy: [Figure 2]

- The colon is approximately **1.5 m long.**
- The colon begins at the ileocaecal valve and extends to the rectum.
- It includes: **Cecum** [7 cm], right (**ascending**) colon [20 cm], **transverse** colon [45 cm], left (**descending**) colon [30 cm] and **sigmoid** colon [40 cm].
- Between the ileum and the cecum there's an ileocecal valve which prevent the reflux of bowel content from the cecum back to the ileum.
- The cecum is the widest, the colon progressively narrows distally.
- The colon has **taenia coli**, **haustra** and **appendices epiploicae** (fat appendages that hang off antimesenteric side of the colon).

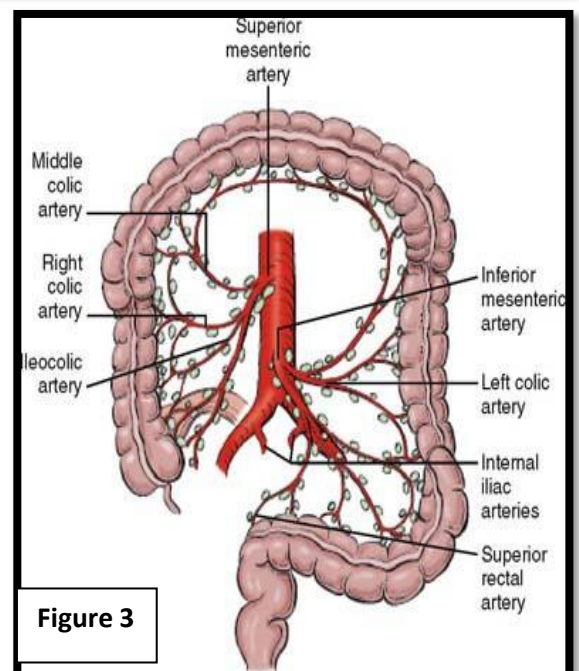
**Despite the length of the colon, the cecum can be reached with as little as 70 cm of colonoscope.**

- **Taenia coli** are three distinct bands of longitudinal muscle which converge at the appendix and spread out to form the longitudinal muscle layer at the proximal rectum.
- **Haustra** are sac-like segments which appear after contractions of the colon.
- Retroperitoneal structures: Ascending colon and descending colon.
- Intraperitoneal structures: Cecum, Transverse colon and sigmoid colon.

**Note: the only parts of the GI tract which are not covered by serosa are: the esophagus, middle rectum and distal rectum.**



- **Blood supply:** [Figure 3] Superior mesenteric artery gives three branches:
  1. Ileocolic artery → Supplies the cecum.
  2. Right colic artery → Supplies the ascending colon.
  3. Middle colic artery → Supplies the proximal 2/3 of the transverse colon.
- Inferior mesenteric artery gives three branches:





1. Left colic artery → Supplies the distal 1/3 of the transverse colon.
  2. Sigmoidal artery → Supplies the sigmoid.
  3. Superior rectal artery → Supplies the superior third of the rectum.
- The anastomosis between the terminal branches of the SMA and IMA forms a continuous arterial circle or arcade along the inner border of the colon called **“the marginal artery of the colon”**.
  - **The splenic flexure** represents a **“watershed” area** between areas that are supplied by SMA and IMA, and it’s particularly **susceptible to ischemic injuries** as seen in ischemic colitis.
  - The venous drainage of the colon is through the SMV (drains the cecum, ascending and descending colon) and IMV (drains the descending, sigmoid and proximal rectum).

**Both SMV and IMV drain the colon before joining the splenic vein.**

- **Lymphatic drainage:** It follows the arterial supply.
- **Histology:**
  - Mucosa → Submucosa → innercircular muscular layer → outer longitudinal muscular layer (forming taenia coli).
  - The mucosal layer consists of epithelium, lamina propria and muscularis mucosa.
  - The submucosal layer contains the **Meissener plexus** (submucosal plexus) which is part of the enteric nervous system (ENS) and it controls colon secretions.
  - Between the circular and longitudinal muscular layers there’s the **Myenteric plexus** (Auerbach plexus) which is part of the enteric nervous system (ENS) and it controls colon motility.

- **Innervation:**
  - Derived mainly from the autonomic nervous system (ANS):
    1. Sympathatic → inhibits peristalsis and secretion.
    2. Parasympathatic → stimulates peristalsis and secretion.

**The ANS can control the GI tract independently and through the enteric nervous system**

### ❖ **Microbiology:**

- The colon is sterile at birth.
- Normal flora is established shortly after birth.
- Normal flora includes:
  - 99% Anaerobic (Predominantly Bacteroides fragilis).

- 1% Aerobic (Predominantly E.coli).

### ❖ Physiology:

The main physiological functions of the colon are:

- Absorptions and Secretions:

- The principal function of the colon is absorption of water.
- Sodium and chloride absorption also take place in the colon.
- Active excretion of Potassium takes place.

- Motility:

- Colonic motility is variable.
- Two types of contractions take place:
  1. Segmentation → Mixing contractions which are responsible for the appearance of haustra.

**Note: Constipation is the inability to pass stool with the ability to pass flatus, while obstipation is the inability to pass stool and flatus.**

2. Contractions resulting in mass movement → 1-3 times/day.

- Storage of feces.

# Colonic polyps

## INTRODUCTION

☼ polyps are classified into 4 types:

- **Inflammatory:** associated with inflammatory bowel disease; Crohn and Ulcerative colitis.
- **Metaplastic or Hyperplastic:** Hyperplasia of the epithelium.
- **Hamartomatous:** related to certain syndromes example is *Peutz Jegher syndrome* which is very rare and is associated with perioral pigmentation (macules and melanosis) with benign hamartomatous polyps. Another example is *Juvenile Polyposis Syndrome*.
- **Neoplastic:** The one which we are concerned with mostly, results from abnormality in the glands. Examples including adenoma, carcinoma and carcinoid.

☼ Colonic polyps can be benign or malignant, and as we mentioned they result from gland abnormality.

- Neoplastic colonic polyps are also known as adenomas and have different growth patterns therefore they have been classified into:
  1. *Tubular adenomas*
  2. *Tubulovillous adenomas*
  3. *Villous adenomas*
- Also, polyps can vary in morphology; they can either be sessile or pedunculated.

## PATHOPHYSIOLOGY

☼ Most of colon cancer develops from polyps (adenoma-carcinoma sequence) so the removal of the polyps reduces the risk of cancer.

- If you discover a polyp in a patient, you need to complete your colonoscopy because there are probably much more polyps and could be on the other side.

☸ Factors that determine the risk of malignancy:

- **Degree of dysplasia**; the more the dysplastic the polyp, the higher the grade, and the higher risk of malignancy.
- **Size of the polyp**; the larger the polyp (>1cm), the higher the risk of malignancy.
- **Histological type**: Villous has a higher risk for cancer than tubular.
- **The location of the polyps**; if it's proximal, it has higher risk of malignancy.
- **Number of polyps**.

☸ Guidelines for screening adenoma:

<b>Findings</b>	<b>colonoscopy</b>
1 or 2 small tubular adenoma with low grade dysplasia	Repeat colonoscopy 5-10 years after polypectomy
3-10 adenomas or 1 adenoma > 1 cm or any villous feature or high grade dysplasia	Repeat colonoscopy in 3 years
>10 adenoma	Repeat in <3 years
Patients with sessile adenomas that are removed	Repeat in 2-6 months to verify complete removal

- **Note**: hyperplastic polyps if <1 cm (except those with hyperplastic polyposis) have the same follow up as no polyps

☸ Malignant potential related to the size of the polyp:

	<b>&lt;1 cm</b>	<b>1-2 cm</b>	<b>&gt;2 cm</b>
<b>Tubular</b>	1%	10%	35%
<b>Mixed</b>	5%	10%	45%
<b>villous</b>	10%	20%	55%

⚡ Most of the colonic polyps are sporadic, however, there are some familial syndromes.

### 1- **Familial Adenomatous polyposis:**

- **Familial adenomatous polyposis (FAP):** It is an autosomal dominant inherited disorder.
- There is a mutation on APC gene on chromosome 5.
- Hundreds of colonic polyps are found (100 or more polyps for diagnosis), and also polyps may be found in other parts of the GIT (Eg. Duodenal polyps). This disorder is associated with 100% risk of colon cancer. There are many extra-colonic manifestations most commonly:
  1. Upper GI adenoma (95%): duodenal polyps, and fundic gland polyps.
  2. Connective tissue: Desmoid, Osteomas, and Epidermoid cyst (80%); it's called **Gardner syndrome** in these cases.
  3. CNS: CHRPE (75%).
  4. Endocrine: papillary thyroid cancer.
  5. Hepatobiliary: biliary tract carcinoma, hepatoblastoma.
- APC gene mutations in 80% of cases, 20% will have new mutations; in milder forms we will have attenuated FAP.
- **Screening:** If the patient has a family history of FAP, we do clinical surveillance starting at 13-15 years of age if no polyps are present we start at 20 (by endoscopy), or we do genetic testing.
- **Prophylactic treatment:** total colectomy + restorative surgery, upper GI surveillance at age of 30 and looking for duodenal polyps every 2 years. **Sulindac and Celecoxib** causes regression of polyp but require frequent examination.

2- **Juvenile Polyps:** another syndrome, the patient develops multiple hamartomatous polyps (50-200) at the age of 4 years in various sites (rectum, colon, stomach), autosomal dominant but it's rare with 30-50% risk of cancer.

3- **Peutz-Jeghers syndrome:** Multiple hamartomatous polyps and melanotic pigmentations on lips and buccal mucosa

- increase risk of cancer (the risk is 50% by age of 60).
- Most common symptom is abdominal pain due to intussusception or bowel obstruction by large polyp.

#### 4- Turcot syndrome:

- Autosomal recessive
- Polyps + cerebellar meduloblastoma and glioblastoma.

## Colon cancer

### INTRODUCTION

- 2<sup>nd</sup> most common cancer in Jordan, more common in sigmoid.
- There is screening for colon cancer since more people are being affected.
- The overall survival is 45% and this number is improving.
- It's a major problem in the Western World.
- Males and females are affected equally.
- Sigmoid more common than cecum, but rectum is more common than sigmoid.

### ? ETIOLOGY

#### ⌘ Environmental & dietary risk factors:

- Smoking.
- Alcohol.
- Lack of fiber in diet
- Excess fat in the diet
- Lack of exercise.
- Bile acids (as carcinogens after cholecystectomy, so calcium is protective since it binds free bile acids.)

#### ⌘ Predisposing conditions:

1. Age >50
2. Adenomatous polyps
3. longstanding IBD.
4. gastrectomy, vagotomy and uretero- sigmoidostomy.
5. Obesity
6. Acromegaly

## 7. BRCA 1 mutation.

# PATHOPHYSIOLOGY

⚡ Most GI cancers arise from adenomas, the change from benign to malignant cancer involves 2 stages, mutations that convert normal mucosa into adenoma, then, mutations that convert a benign tumor to a cancer.

- The series of this mutations is called Adenoma carcinoma sequence.
- APC → K-RAS → DCC → P53.

⚡ Aspirin and colon cancer:

- COX enzyme is thought to be related to the pathogenesis of colon CA.
- Low dose (81mg) causes mild decrease risk of recurrent adenomas but no decrease risk of colon cancer.
- Full dose aspirin decrease the risk of colon cancer
- Protective effect of aspirin is related to:
  1. dose of ASA.
  2. frequency of use.
  3. duration of use

⚡ Inherited colon cancer:

1. **Polyposis**; FAP, Gardner syndrome, Tarcot syndrome, peutz-jeghers syndrome, discussed earlier.
2. **Non polyposis** ; hereditary non polyposis colon cancer (lynch syndrome)
  - Patients don't have familial polyps
  - **Diagnostic criteria (Amsterdam Criteria)**: It's the occurrence of colon cancer in at least 3 1<sup>st</sup> degree relatives over at least 2 generations with at least 1 person diagnosed < age of 50.
  - Females with HNPCC have increased risk of ovarian and endometrial cancers (also renal/ureteral , stomach and pancreas)
  - Start screening at age 25.

⚡ Pattern of spread :

- **Direct**: circumferentially bowel wall – abdomen
- **Hematogenous**: portal system to liver / systemic to the lung
- **Lymphatic**: transepithelial and intraluminal
- Metastasize always to the liver first via portal circulation but if it invades only the rectum it will bypass portal circulation



## CLINICAL FEATURES

⚡ General symptoms:

High risk:

1. Rectal bleeding with change in bowel habits especially in older age.
2. Persistent bleeding without anal symptoms.
3. Palpable right sided abdominal mass.
4. Palpable rectal mass (not pelvic).
5. Unexplained iron deficiency anemia.
6. Change in bowel habit without bleeding (>6weeks, especially with old age).

Low risk:

1. Rectal bleeding with anal symptoms such as pain, prolapsed hemorrhoid.
2. Rectal bleeding with obvious external cause e.g. anal fissure
3. Change in bowel habit in young people.
4. Abdominal pain.

⚡ Despite the fact that most Colorectal cancers have the same biology, they differ in their presentation according to the site of the tumor:

- **Right sided tumors:** right side of the bowel has a large diameter, so a tumor may attain a large size before causing problems, so it presents with IDA, occult melena, hematochezia, postprandial discomfort & fatigue.
- **Left sided tumors:** left side of the bowel has smaller diameter with semisolid content, so it presents with change in bowel habits, colicky pain & signs of obstruction.
- **Rectal tumors:** presents usually with hematochezia, mucus discharge, tenesmus & feeling of rectal mass.

⚡ Note: endocarditis caused by strep bovis or C.septicum is often associated with colon cancer so do GI workup in these patients



## DIAGNOSIS

⚡ History: diagnostic flags:

- Weight loss / anorexia.
- Fever



- Positive heme stool
- Anemia
- Change in bowel habits esp nocturnal stool
- Onset of sx after age 45.

⚡ **Colonoscopy:** it is a diagnostic test that could be therapeutic by removing polyps but carries risk of bleeding and perforation.

- If we find a tumor on one side there is a 3-5% probability to have another one on the other side (synchronous tumors), so we need to do colonoscopy to the whole colon.

⚡ **Barium enema:** it is only diagnostic using X-Ray imaging.

⚡ **CT colonography:** it requires exposure to radiation, and contrasts that may damage the kidneys. It is only diagnostic.

⚡ **Fecal occult blood test:** looking for blood in the stools, used for screening purposes. So we don't use it for patients with obvious rectal bleeding.

⚡ **Staging of colon cancer: (TNM)**

- Stage I T1(submucosa) or T2 (muscularis ) / No / Mo
- Stage II T3 ( to the tissue ) or T4 (visceral peritoneum ) / No / Mo
- Stage III T1-4 (any) / N1 / Mo
- Stage IV any T / any N / M1

⚡ **Screening for colon cancer :**

- Fecal occult blood testing (fobt)
- **Colonoscopy** (or flex sigmoidoscopy + barium enema )
- CEA

Index for colonoscopy:

- 1)Occult blood
- 2)Abnormal barium enema
- 3)Adenomatous polyp
- 4)FP syndrome / HNPCC
- 5)History of colon cancer
- 6)1st degree relative with colon cancer
- 7)Unexplained IDA
- 8)Gross lower GI bleeding ( except if bright red in young patient )
- 9)IBD
- 10)Strept.bovis or C. septicum bacteremia
- 11)4-8 weeks after new onset diverticulitis ( to rule out cancer )
- 12)Persistent diarrhea with negative blood test and not meeting the criteria for diagnosis of IBS

**Tests that detect adenomatous polyps and cancer:**

- 1) Colonoscopy / 10 years
- 2) Or flexible sigmoidoscopy / 5 years
- 3) Or double contrast barium enema / 5 years
- 4) CT colonography / 5 years

**Tests that detect cancer :**

- 1) Annual rectal immunochemical test
- 2) Annual guaiac based fecal occult blood
- 3) Stool DNA test

- If the polyp is benign repeat every 3 years.
- Any positive test (other than colonoscopy) should be followed up by colonoscopy with biopsy of any polyp / adenomatous.

⚡ **FOBT: annually**

- Positive in about 2% (varies with age ; >5% after age of 60) and about 2% of these have colon cancer.
- Poor screening test but quick and cheap also least invasive ; negative in up to 66% of patients with colon cancer !! it can miss 1/3 of advanced colon cancer !
- Full FOBT series use 6 hemoccult , even if only one FOBT is positive do colonoscopy (or flex sigmoidoscopy + barium enema but is less desirable)

⚡ **Colonoscopy:**

- Have the highest yield of finding polyps and cancer
- It is the screening procedure of choice

⚡ **CEA (carcinoembryonic antigen) :**

- Good only in checking for recurrence of cancer
- CEA also increase in smokers , patients with benign biliary disease , PSC or IBD .

⚡ **The 10 years rule :**

- **High risk patients:** colonoscopy should be at age 40 years or 10 years before age at which index case is diagnosis



## TREATMENT

### ☼ surgical resection:

- 1<sup>st</sup> option.
- Surgeries could be curative or palliative (after the staging always remember to discuss options with the patient and to assess the patient's status before doing surgeries, to prevent death during the operation).
- recurrence happens due to micrometastases.
- Hepatic resection increase survival with solid liver metastasis

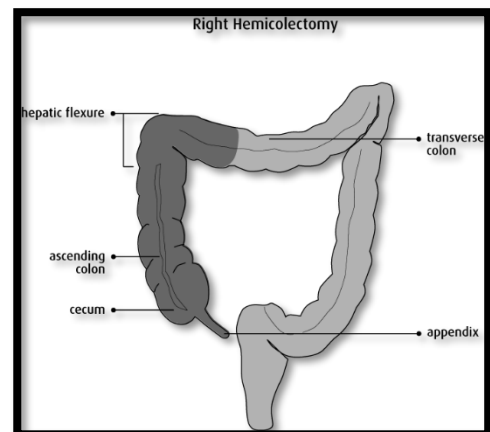
☼ **Adjuvant chemotherapy:** 5-FU effective only stage III or locally advanced stage II

☼ RTX (prior to surgery) is helpful for rectal lesion only.

## Surgical management of colorectal cancer

### ☼ Right hemicolectomy:

- resected material: terminal ileum + cecum + ascending colon + proximal transverse colon
- Plus, resection of right colic artery + ileocecal artery +- middle colic artery
- Plus, removal of fat and lymph node
- indications: right colon cancer / cecum cancer

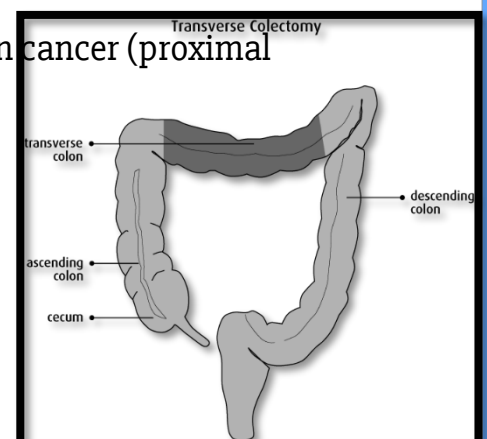


### ☼ Extended right hemicolectomy:

- resected material: same as right hemicolectomy + remainder of transverse colon and splenic flexure + resection of right colic artery, ileocecal artery and middle colic artery
- indications: hepatic flexure cancer / transverse colon cancer (proximal mid)

### ☼ Transverse colectomy:

- Resected material: transverse colon + middle colic artery
- indication: transverse colon cancer



☯ **left hemicolectomy:**

- Resected material: descending colon + left colic artery
- indications: splenic flexure cancer / left colon cancer

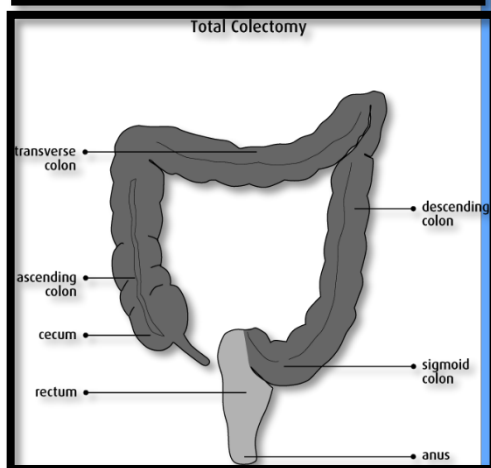
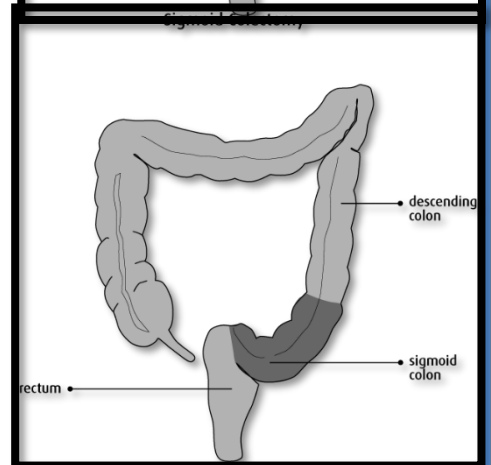
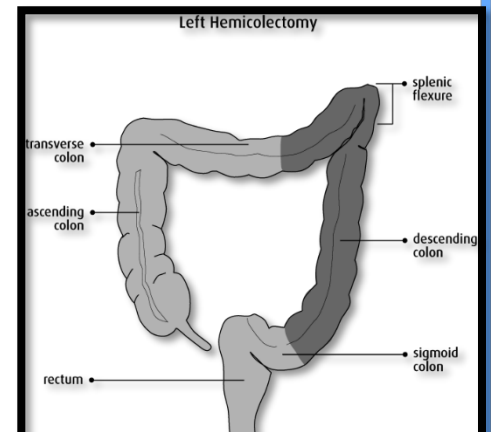
☯ **Sigmoid colectomy:**

- Resected material: sigmoid colon + sigmoid artery.
- indications: sigmoid / rectosigmoid cancer.

☯ **Total colectomy:** removal of the entire colon without the rectum

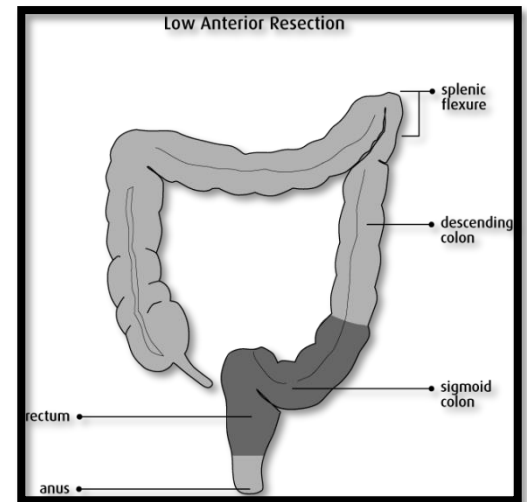
☯ **Proctocolectomy:** removal of the entire colon and rectum

☯ **Subtotal colectomy:** removal of part of colon / all of the colon without complete resection of the rectum



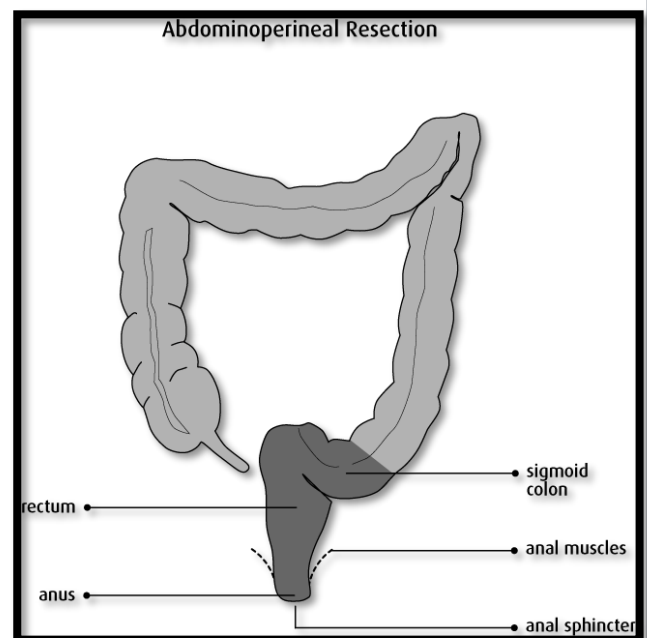
### ☯ Low anterior resection(LAR):

- resection of low rectal tumors through an anterior approach.
- Indications: proximal rectum cancer
- criteria:
  1. Tumors >4 cm from anal verge ( with distal intramural spread <2 cm )
  2. must be able to get 2 cm margin
- If a rectal tumor doesn't meet these criteria, we have to do the radical (and bad) surgery; abdominoperineal resection, but in some cases, we may give neoadjuvant chemotherapy to down stage the tumor, then we do LAR
- includes total mesorectum excision
- Complications: incontinence , urinary dysfunction , sexual dysfunction , anastomotic leak(5-10% ) , stricture (5-20%)
- **Hartmann's procedure:**
  1. proximal colostomy.
  2. distal stapled off colon/rectum that is left in peritoneal cavity.



### ☯ Abdominal perineal resection (APR) :

- Removal of the rectum and sigmoid colon through abdominal and perineal incisions (patient is left with a colostomy).
- indications: distal rectum cancer / anal cancer
- done in tumors not fitting criteria for LAR
- the anus is closed
- permanent colostomy (due to removal of the anus)
- complications: stenosis , retraction or prolapse of ostomy , perianal wound infections



# Diverticular diseases

## INTRODUCTION

⚡ Colonic diverticula are false diverticula in which mucosa and submucosa protrude through the muscularis propria (not all the layers).

- Diverticulosis is just the presence of outpouching without inflammation, diverticulitis is if they become inflamed.
- Acquired herniations of mucosa through the muscle wall between the mesenteric and antimesenteric taenia.
- Most common structural abnormality of the bowel.
- The sigmoid colon is MC affected due to decreased luminal diameter and increased luminal pressure.

### Incidence:

- < 40 yr = 5%
- > 85 yr = 85%
- **Sigmoid colon is involved in over 95%** of patients affected with diverticulosis
- In western countries left-sided diverticulitis predominates with right-sided diverticulitis occurring in only 1.5%
- 10-25% of pts will develop diverticulitis

## ? ETIOLOGY

- 1) Low fiber diet
- 2) Elderly
- 3) Chronic constipation
- 4) Family history
- 5) Decreased physical activity, obesity.
- 6) Smoking.

# Diverticulosis

- Most common cause of lower GI bleeding.



## CLINICAL FEATURES

### Symptoms:

- Asymptomatic (80% of cases ).
- Bleeding. (and may be massive because the media of perforating artery adjacent to the colonic diverticulum may become attenuated and eventually erode). Bleeding is bright red and not associated with previous melena or chronic blood loss and most often from left colon.
- Diverticulitis and complications.



## TREATMENT

- 1) If asymptomatic → High fiber diet is recommended.
- 2) If bleeding → Although it may be massive it is usually self-limited (80% spontaneously stop), resuscitation with fluids
- 3) Perform colonoscopy 6 weeks after the attack (but not during attack due to risk of perforation) to rule out colon cancer as a cause of bleeding.

### Surgical indications:

- 1) Elective resection of the affected colon segment:
  - Patients with recurrent bleeding
  - Need for long term anticoagulation
  - Excessive blood loss cannot be tolerated
- 2) Urgent resection of the affected colonic segment:
  - Active ongoing bleeding (> 6 units packed RBCs / 24 hours)

# Diverticulitis

## INTRODUCTION

**Definition:** Infection or perforation of a diverticulum.

**Epidemiology:** Occur in 10-25% of patients with diverticula (90% left sided , 10% right).

## PATHOPHYSIOLOGY

Obstruction of the diverticulum by a fecalith leading to inflammation and micro-perforations leading to fecal extravasation and subsequent peri-diverticular and pericolic inflammation.

### Classification:

- 1- Uncomplicated diverticulitis (75%): only inflammation (LLQ), usually resolve without surgery, classical triad (localized tenderness, fever and leukocytosis) → Its called left sided appendicitis because it has the same features.
- 2- Complicated diverticulitis: diverticulitis with abscess, obstruction, diffuse peritonitis, fistulas. **Hinchey classification** used to assess severity.

## CLINICAL FEATURES

### Presentation:

1. Lower left quadrant(LLQ) pain may radiate to suprapubic area, left groin or back, cramping or steady pain.
2. Fever, altered bowel habits (diarrhea), urinary urgency or dysuria, nausea and vomiting.
3. P/E : Varies with the severity of the disease but the most common is LLQ tenderness. a mass may suggest abscess or phlegmon.

### Complications:

#### 1. Diverticular abscess:

- Usually identified on CT scan.
- A percutaneous drain should be placed under radiologic guidance – which avoids immediate operative drainage, and allows time for the inflammatory phlegmon to be treated.



- Treat with IV antibiotic
- Thus, one-stage procedure can be done (instead of 2 or 3 stages).

## 2. Generalized peritonitis:

- Rare; result from diverticular perforation leading to widespread fecal contamination.
- In most cases, resection of the diseased segment is possible and a Hartman procedure is done, the colostomy later closed (2-stages procedure).
- Another option for a patient without significant fecal contamination: Sigmoidectomy + Colonic lavage + Colorectal anastomosis +/- loop ileostomy.

## 3. Fistulisation:

- Fistulas between colon and other organs may occur secondary to diverticulitis.
- **Colovesical fistulas are the most common and diverticulitis is the most common cause of colovesical fistulas.**
- Colovaginal and colovesical fistulas usually occur in women who have previously undergone hysterectomy.
- Colocutaneous and coloenteric fistulas are uncommon.
- Colonoscopy should be done after 6 weeks to rule out other causes of fistulas.



## DIAGNOSIS

- 1- CT scan : may find segmental colonic thickening , swollen edematous wall, focal extraluminal gas, helpful to diagnose abscess formation.
- 2- CBC: high WBCs.
- 3- Sigmoidoscopy (not indicated due to risk of perforation), contrast enema (not indicated due to risk of barium / fecal peritonitis).



## TREATMENT

**Management:** depends on whether it is an uncomplicated or complicated attack, and whether it is a first attack or not.

- First uncomplicated attack of diverticulitis should be treated conservatively, while complicated attacks (abscess, fistula, peritonitis, perforation, obstruction) need operative management according to each complication.

### **- Conservative:**

- 1- Bowel rest
- 2- Clear liquids for 2-3 days then advance diet as tolerated
- 3- IV fluids
- 4- Antibiotics:
  - IV antibiotics that cover G-ve / anaerobes for 3-5 days then switch to oral to complete 10-14 day course.
  - Either monotherapy: Ticarcillin-Clavulanate or Piperacillin-Tazobactam or Ampicillin-Sulfabactam.
  - Or Rocephin (Ceftriaxone) + Flagyl (Metronidazole).
- 5- May include percutaneous drainage of abscess.

After successful conservative treatment of 1<sup>st</sup> episode, 1/3 have a second attack, and 1/3 of those who have a 2<sup>nd</sup> attack have third attack.

### **Surgery indications:**

1. After first or any complicated diverticulitis attack
2. After 2 or more episodes of uncomplicated

(Management is always individualized according to patient, these are general guidelines)

### **Hinchey classification:**

To assess severity, degree of peritoneal contamination (which determine pre-op antibiotics and appropriate intervention), the Hinchey classification (and in 1999, modified Hinchey classification) was developed.

- 1) Stage 1: Pericolic or mesenteric abscess.
- 2) Stage 2a: Distant abscess. / Stage 2b: Complex abscess and fistula.
- 3) Stage 3: Generalized purulent peritonitis.
- 4) Stage 4: Generalized fecal peritonitis.

Stage 1 & 2 can be treated conservatively during attack, with percutaneous drainage of abscess. After the attack has resolved, an elective laparoscopic resection of diseased segment with primary anastomosis and stoma. This is followed by colostomy closure three months later.

# Colonic Volvulus

## INTRODUCTION

Definition: Twisting of colon on itself about its mesentery → resulting in obstruction and – if complete – vascular compromise with potential necrosis, perforation or both.

Types:

1. Sigmoid volvulus (most common) 75%
2. Cecal volvulus 25%
3. Transverse volvulus (rare )

## Sigmoid Volvulus

## ETIOLOGY

**Risk factors:**

- High fiber diet
- Elongated colon
- Chronic constipation
- Laxative abuse
- Pregnancy
- History of abdominal surgery or distal colon obstruction

## CLINICAL FEATURES

**Signs and Symptoms:**

- Acute abdominal pain
- Progressive abdominal distention
- Anorexia
- Obstipation
- Cramps
- Nausea and vomiting

### Signs of strangulation:

1. **Discolored / hemorrhagic mucosa on sigmoidoscopy**
2. **Bloody fluid in rectum**
3. **Frank ulceration / necrosis at the point of twist**
4. **Peritoneal signs**
5. **Fever / hypotension / increased WBC**

Signs of **necrotic bowel in colonic volvulus (in X-ray): Free air / Pneumatosis (air in bowel wall).**



## DIAGNOSIS

- Sigmoidoscopy or radiographic exam.
- Abdominal X-ray findings: distended loop of sigmoid colon, classic **omega sign / coffee bean sign**, with loop aiming toward right upper quadrant.
- With gastrografin enema if sigmoidoscopy and plain films fail to confirm diagnosis → bird's beak is pathognomonic seen on enema contrast study



## TREATMENT

- Initially --non-operative:  
If there are no strangulation → **sigmoidoscopic reduction** is successful in approx. 85% of cases (enema will reduce only 5%), **recurrence is approx. 40% !!!**
- **Indications of surgery (resection):** if strangulation is suspected / unsuccessful reduction.
- Most patients undergo resection after successful non-operative reduction due to high recurrence rate (~40%).

## Cecal Volvulus



## ETIOLOGY

- Idiopathic
- Poor fixation of the right colon
- History of abdominal surgery



## CLINICAL FEATURES

### Signs and symptoms:

1. Acute onset of abdominal colicky pain (starting in right lower quadrant and progressing to a constant pain)
2. Vomiting
3. Obstipation
4. Abdominal distention
5. Small Bowel Obstruction



## DIAGNOSIS

- Abdominal X ray: dilated ovoid colon with large air-fluid levels in right lower quadrant (**coffee bean sign**) with apex toward epigastrium / left upper quadrant (must rule out gastric dilation with nasogastric aspiration).
- Water soluble contrast study – if diagnosis can't be made on abdominal X ray.



## TREATMENT

- Emergent surgery → **Right colectomy** with primary anastomosis or ileostomy and mucus fistula (1ry anastomosis may be done in stable patients).

### -Notes:

- Patients with cecal volvulus require surgical reduction while the vast majority of patients with sigmoid volvulus undergo initial endoscopic reduction of the twist.
- Transverse volvulus is very rare.
- Gastric volvulus can occur.

# Summary & past papers

## Summary

⚡ Colonic polyps are classified into inflammatory, metaplastic (or Hyperplastic), hamartomatous: and neoplastic (adenoma, carcinoma and carcinoids). Neoplastic colonic polyps are also known as adenomas, the risk of malignancy of an adenoma depends on the degree of dysplasia (the more the dysplastic the polyp, the higher risk of malignancy), size of the polyp (larger polyps carries higher risk of malignancy), histological type (Villous has a higher risk for cancer than tubular), its location (proximal has higher risk of malignancy, and the number of polyps. Most of the colonic polyps are sporadic, however, there are some familial syndromes that are associated with polyps; Familial Adenomatous polyposis is an autosomal dominant inherited disorder, resulting from a mutation in APC gene on chromosome 5. This disorder is associated with 100% risk of colon cancer, It may be associated with other tumors as well. Gardner syndrome is FAP with connective tissue tumors. If the patient has a family history of FAP, we do clinical surveillance starting at 13-15 years of age. if no polyps are present we start at 20 (by endoscopy), or we do genetic testing. Patients with FAP are treated with prophylactic total colectomy + restorative surgery with upper GI surveillance at age of 30 and looking for duodenal polyps every 2 years. Other syndromes that are associated with colonic polyps are: Juvenile Polyps ( hamartomatous polyps), peutz-jeghers syndrome, (hamartomatous polyps and melanistic pigmentations on lips and buccal mucosa) and Turcot syndrome (polyps +cerebellarmeduloblastoma and glioblastoma).

⚡ Colorectal cancer is 2nd most common cancer in Jordan, and more common in sigmoid. it's associated with smoking, diet (high fat, low fibers diet, and alcohol consumption), lack of exercise, bile acids, adenomatous polyps, longstanding IBD, gastrectomy, vagotomy, uretero-sigmoidostomy, obesity, and acromegaly.

Most cases of CRC arise from Adenoma-carcinoma sequence (APC→ K-RAS→ DCC→P53), either due to familial cause (FAP) or, most commonly, due to sporadic mutations. Patients with hereditary non-polyposis colon cancer (Lynch syndrome), however, develop CRC without preexisting adenoma. Even though most Colorectal cancers have the same biology, they differ in their presentation according to the site of the tumor; Right sided tumors present with IDA, occult melena, hematochezia, postprandial discomfort & fatigue; Left sided tumors present with change in bowel habits, colicky pain & signs of obstruction; and rectal tumors present usually with hematochezia, mucus discharge, tenesmus & feeling of rectal mass. CRC is diagnosed with colonoscopy, Barium enema, CT colonography and Fecal occult blood test. surgical resection is the 1st option in treating CRC.

⚡ Colonic diverticula are acquired false diverticula in which mucosa and submucosa protrude through the muscularis propria, they are the most common structural abnormalities of the bowel and found most commonly on the sigmoid colon. Diverticulosis is just the presence of outpouching without inflammation, diverticulitis is if they become inflamed. The risk for developing diverticulosis increases with age, it's also associated with low fiber diet, chronic constipation, family history, decreased physical activity, obesity, smoking. Diverticulosis is usually asymptomatic, if it was symptomatic; it may present with lower GI bleeding (it's the most common cause of lower GI bleeding) or diverticulitis. Asymptomatic diverticulosis is managed by dietary modification (high fiber diet). Although diverticular bleeding may be massive, it is usually self-limited, so it's managed by fluid resuscitation. Colonoscopy should be scheduled 6 weeks after the bleeding to rule out colon cancer.

Diverticulitis presents with the classical triad of localized tenderness, fever and leukocytosis (left sided appendicitis). CBC usually shows leukocytosis and CT scan findings may help in the diagnosis as well. Sigmoidoscopy and contrast enema are contraindicated. First uncomplicated attack of diverticulitis should be treated conservatively, while complicated attacks (abscess, fistula, peritonitis, perforation, obstruction) need operative management according to each complication.

☚ Colonic Volvulus is the twisting of colon on itself about its mesentery, resulting in obstruction and vascular compromise with potential necrosis, perforation or both. Sigmoid volvulus is the most common type of colonic volvulus, it's associated with high fiber diet, elongated colon, chronic constipation, laxative abuse, pregnancy and history of abdominal surgery. It presents with acute onset of abdominal pain, progressive abdominal distention, anorexia, obstipation, cramps, nausea and vomiting. As any intestinal obstruction, the first step in diagnosing Colonic volvulus is Abdominal X-ray, which may show distended loop of sigmoid colon, classic omega sign/coffee bean sign (loop aiming toward right upper quadrant). In uncomplicated colonic volvulus, sigmoidoscopic reduction is the first step in management, then elective surgical correction is scheduled. In cases of unsuccessful reduction or strangulation, surgery resection is the treatment of choice. Cecal Volvulus results usually from poor fixation of the right colon after abdominal surgery, Abdominal X ray shows dilated ovoid colon with large air-fluid levels in right lower quadrant (coffee bean sign) with apex toward epigastrium/left upper quadrant. Unlike sigmoid volvulus, cecal volvulus is managed by emergent right colectomy with primary anastomosis or ileostomy and mucus fistula (1ry anastomosis may be done in stable patients).

### Past papers

**1. which of the following syndromes has Hamartomatous polyps?**

- a) Juetz pegher syndrome

**2. All are part of management of diverticulitis except?**

- a) Colonoscopy after 3 weeks
- b) CT scan
- c) IV abx
- d) Fluids
- e) NPO

**3. true about volvulus**

- a) cecum is more common than sigmoid
- b) higher in females
- c) **high fiber diet**
- d) Surgery is 1st line treatment
- e) Chronic constipation is the usual presentation

**4. Best prognostic factor after CRC:**

- a) **lymph node involvement**
- b) transmural involvement

**5. Most common site of lymphoma in the colon**

- a) **Cecum**

**6. False about diverticular disease:**

- a) **considered pre-cancerous**

**10. Not a risk factor of colon cancer?**

- a) **Young age**

**11. True about FAP?**

- a) **Osteoma is an extra-intestinal manifestation that can be associated with it.**

**12. Which of the following does not increase the risk of colon cancer?**

- a) **Hyperplastic polyp**

**13. No need for chemo after rectal resection if:**

- a) Positive nodes
- b) Lympho-vascular invasion
- c) **Tumor >3 cm (size does change our decision regarding chemo)**

**14. About diverticular disease which is wrong:**

- a) **60% develop diverticulitis\* (it is 10-25%)**
- b) Most common cause of Massive bleeding

**15. Which is true about FAP:**

- a) mutation on ch15
- b) 75% will develop into malignancy
- c) Polyps in late adulthood
- d) **Panproctocolectomy with pouch is curative\***

**16. False statement about volvulus:**

- a) Theory is redundant sigmoid with short mesentery and dysmotility
- b) More common in west
- c) Sigmoid is the most common
- d) **Surgery is not recommended after successful de rotation**

**17. Wrong about diverticulitis:**

- a) **Endoscopy is the test of choice to diagnose acute diverticulitis. (it is CT)**

**18. Genetic defect associated with HNPCC:**

- a) APC
- b) **MLH1/MSH2**
- c) P53

**19. True about colon cancer:**

- a) It is rare for right colon cancer to present as anemia
- b) **75% from polyps**

**20. Diverticulosis, false:**

- a) **bleeding most often from right colon**
- b) mortality is 10-20%

**21. Volvulus wrong:**

- a) **Ischemia occurs with 180 degree rotation**
- b) Is a common cause of intestinal obstruction in Jordan
- c) You should attempt sigmoidoscopic derotation if no signs of bowel necrosis
- d) If bowel necrosis or gangrene immediate laparotomy

**22. one of the following scenarios has increased risk for colorectal CA:**

- a) rectal bleeding with anal symptoms
- b) **unexplained iron deficiency anemia**
- c) Change in bowel habit without rectal bleeding, 50 years old
- d) change in bowel habit in the last 3 weeks
- e) abdominal pain with no change in bowel habit

**23. Wrong about diverticular disease:**

- a) **Barium is diagnostic in acute diverticulitis**
- b) Its not premalignant
- c) Surgery is indicated after the 2nd attack

**24. wrong about colo-rectal cancer:**

- a) **Mutations in tumor suppressor genes or DNA repairing genes are observed in familial colorectal cancer and NOT the sporadic ones**

**25. Peutz-Jeghers syndrome, which is not true:**

- a) associated with mucocutaneous lesions and hyperpigmentation.
- b) Autosomal dominant
- c) associated with anemia
- d) **Small bowel contains adenomatous polyps**

**26. Adenocarcinoma of the colon management**

- a) **liver mets PRECLUDES resection of tumor**

**27. diagnosis of acute diverticulitis (to exclude it):**

- a) U/S
- b) **CT**
- c) Colonoscopy
- d) barium

**28. Regarding FAP, which is wrong**

- a) polyps are adenomatous
- b) **all patient will have cancer at some point**



- c) **clinically present in teens**
- d) mostly the surgery is, colectomy with ileorectalanastomosis

**29. Polyps in Rectum**

- a) **most common type is tubulovillous**
- b) villous is most dysplastic

**30. A 65-year-old comes with an attack of diverticulitis in the sigmoid, is managed**

**conservatively and gets better. What's the next step in management?**

**a. Offer surgery on 2nd attack**

**31. one is wrong about HNPCC:**

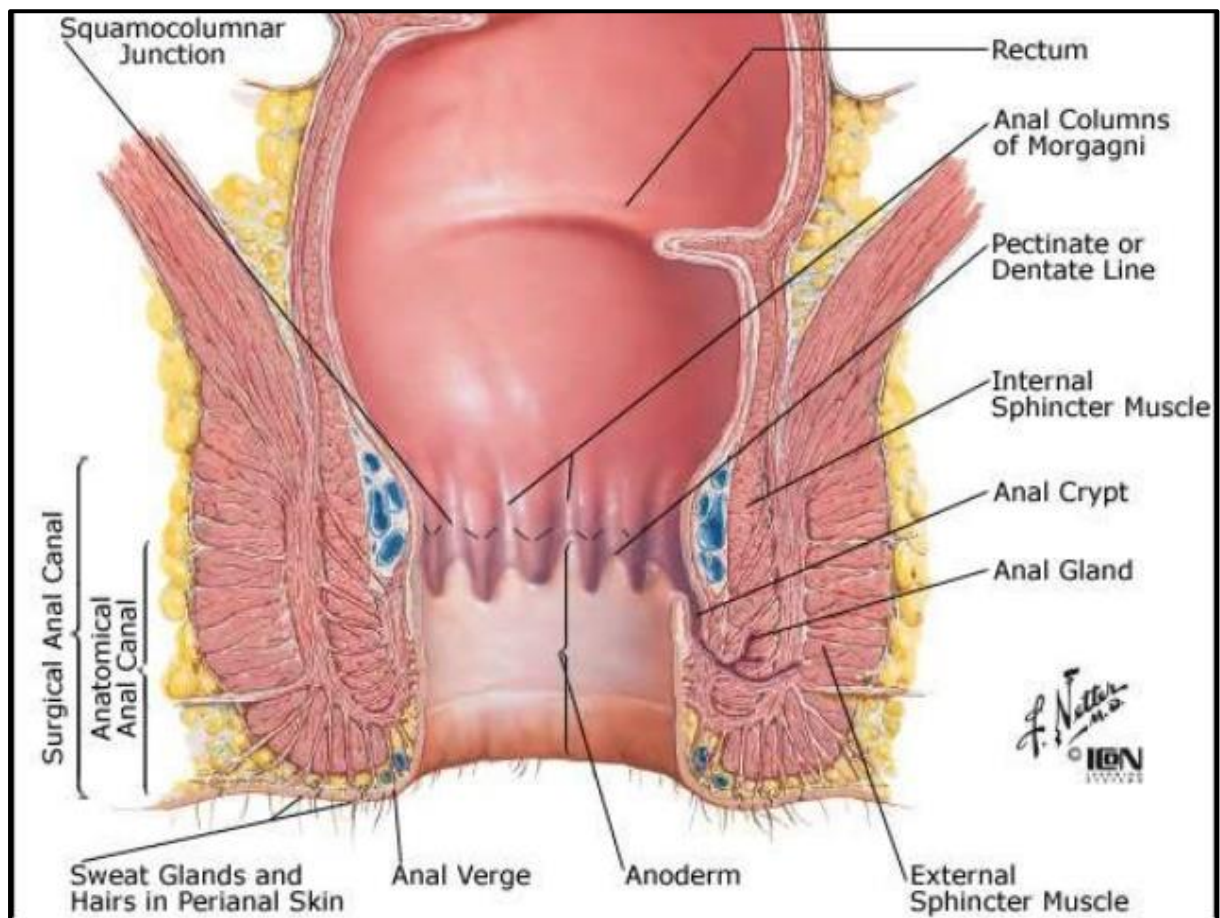
- a) **Autosomal recessive mutation**
- b) negative genetic testing in a highly suspected subject rules out the dx & the person is dealt with as any one else from the general population

# Anorectum

## Embryology:

The rectum and the proximal anus are hindgut organs, so they are derived from **Endoderm**. Distal anus is derived from **ectoderm**.

## Anatomy:



## Rectum:

12-15 cm. Divided into upper, middle and lower thirds.

Upper third is covered by peritoneum anteriorly and laterally.

Middle third is covered by peritoneum anteriorly.

Lower third is extraperitoneal.

Fascia in front of the lower third is called Denovillier's fascia.

Waldeyer's fascia (rectosacral fascia): Condensations of presacral fascia in the lower part of the sacrum (S4).

Lateral ligaments: From the rectum to the sides of the pelvis. Contain middle rectal vessels.

### Anus:

Anatomical anal canal: From anal verge to the dentate line (3 cm) (One embryonic and anatomical structure).

Surgical anal canal: From anal verge to the anorectal ring (5 cm).

Anal verge: The opening of the anus on the surface of the body. Or it is the transitional zone between the moist, hairless, modified skin of the anal canal and the perianal skin.

Dentate line (Pectinate line): A mucocutaneous line that separates proximal, pleated mucosa from distal, smooth anoderm (1–1.5 cm above anal verge)

Formed by series of cusps. The spaces within the cusps are called crypts, into which the ducts of mucus secreting anal glands open.

It is considered a watershed area because it separates two embryonic structures that differ in their epithelium, sensation, blood supply and lymphatic drainage.

Anal mucosa proximal to dentate line lined by columnar epithelium; mucosa distal to dentate line is a specialized form of skin (squamous) that is devoid from skin appendages. It is called the anoderm.

The transitional area (a.k.a. Cloacogenic area) is the actual mucocutaneous junction (not the dentate line). It is 1 cm above the dentate line. This area is lined by columnar, squamous or any type of epithelium.

Columns of Morgagni: 12–14 columns of pleated mucosa superior to the dentate line separated by crypts.

### Anal glands:

- 8 – 12 in number.
- Lay in the intersphincteric plate.
- Their ducts open in the crypts.
- Most of them are located in the anterior part of the anus.

Anal sphincters: Internal and External.

The internal sphincter: specialized rectal smooth muscle (from inner circular layer); involuntary, contracted at rest, responsible for 80% of resting pressure.

The external sphincter: Striated muscle. A continuation of puborectalis muscle; responsible for 20% of resting pressure and 100% of voluntary pressure.

3-loop theory:

- a- Subcutaneous part
- b- Superficial part (attached to the coccyx).
- c- Deep part (attached to the pubis).

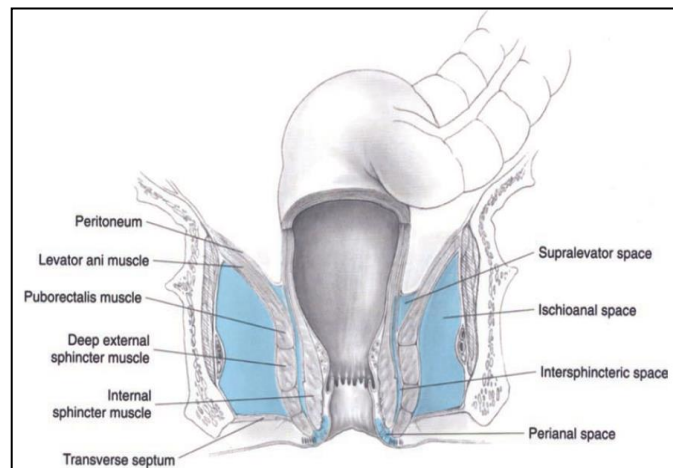
Anorectal ring: Formed by deep part of internal sphincter, deep external sphincter and puborectalis muscle

Important in continence mechanism; it maintains a right / acute angle.

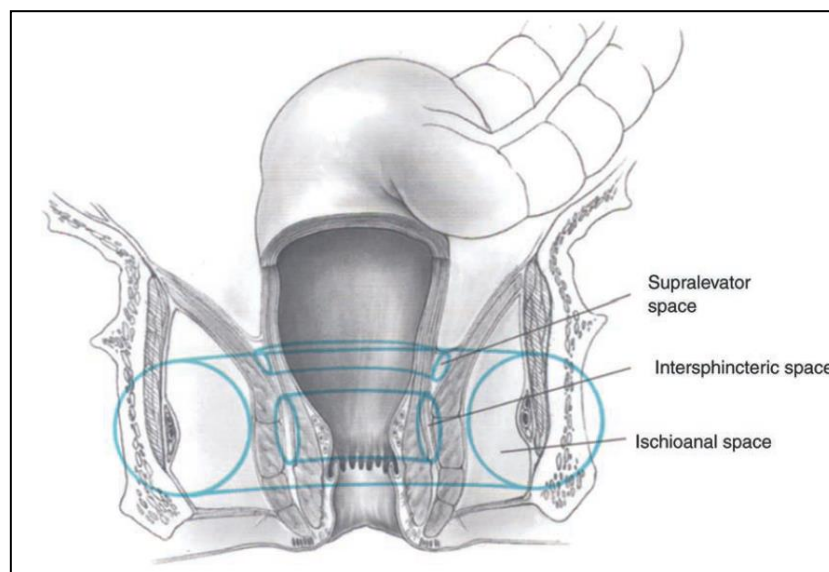
Ptosis in the anorectal ring will cause rectal prolapse.

Perianal spaces:

- Perianal space proper.
- Ischioanal fossa.
- Intersphincteric space.
- Supralelevator space.



The anorectal spaces connected in a horseshoe-shape:



Blood supply:

Arterial:

- Rectum: **Porto-systematic:**
  - 1- Superior rectal arteries from IMA – Portal.
  - 2- Middle and Inferior rectal arteries from Internal Iliac – Systematic.
- Anus: **Systematic:** Internal pudendal artery (from internal iliac).

Venous:

Drains to IMV, Internal iliac vein, internal pudendal vein and hemorrhoidal plexuses.

Hemorrhoidal plexuses: Three complexes within the anus (Internal; contains highly oxygenated blood) that drain into the superior rectal veins and one external complex that drains into the pudendal veins.

Lymphatic drainage:

- Perirectal lymphatics → Mesenteric (mostly) and internal iliac nodes.
- Anal lymphatics → Superficial inguinal nodes.

Note: Anal canal above dentate line drains to inferior mesenteric nodes or to internal iliac nodes. Lower anal canal drains to inguinal nodes.

Nerve supply:

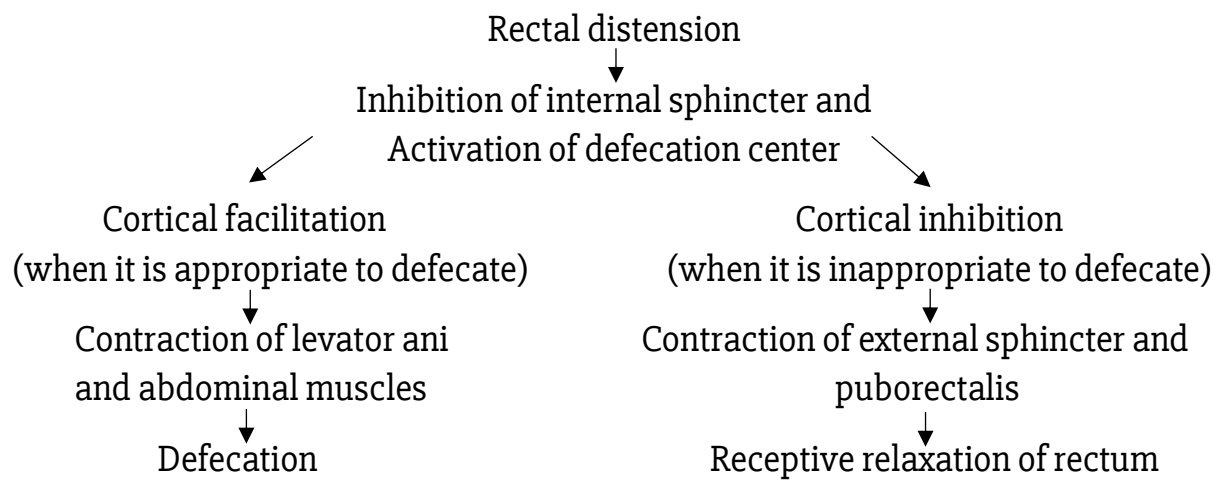
- Sphincters:
  - 1- Internal: Sympathetic (L1-L3) and parasympathetic (s2-s4) [Hypogastric plexus a.k.a. presacral plexus]
  - 2- External: Internal pudendal nerve (S2-S4).
- Anus: Internal pudendal nerve (S2-S4) [sensory and motor].
  - Below dentate → Sensitive to pain.
  - Above dentate → Insensitive to pain.

Notes:

- Internal sphincter is a smooth muscle; involuntary and has tonic activity. It does not fatigue.
- External sphincter is a skeletal muscle; voluntary and has somatic supply. Fatigues easily.

## Physiology:

Defecation:



Receptive relaxation: It allows volume expansion without increment in the pressure (so when urge comes and no defecation occurs → dilation of rectum → urge will disappear).

# Hemorrhoidal Disease

## INTRODUCTION

☼ Hemorrhoids are normal structures (anal cushions) that play a minor role in continence. When hemorrhoids enlarge, prolapse or bleed then they become hemorrhoidal disease.

- **Normal function of anal cushions:** Compliant and conformable plug. Account for approximately 15%–20% of the anal resting pressure. Give sensory information **that enables individuals to discriminate between liquid, solid, and gas.**
- **Definition:** It's a degenerative disease of the connective tissue.
- **40% of patients will develop symptoms.**
- Prevalence rate of 4.4%, peak between age 45 and 65 years.
- Hemorrhoidectomies are performed 1.3 times more commonly in males than in females (equal incidence).
- Divided into **internal** (above the dentate line) and **external** (below the dentate line).

☼ External hemorrhoids comprise the dilated vascular plexus that is located below the dentate line and covered by squamous epithelium. Internal hemorrhoids are the symptomatic, exaggerated, submucosal vascular tissue located above the dentate line and covered by transitional and columnar epithelium.

☼ Note: Hemorrhoids are **not only vessels**, they are composed of blood vessels, smooth muscle (Treitz's muscle), and elastic connective tissue in the submucosa. They are located in the upper anal canal, from the dentate line to the anorectal ring.

Note: Hemorrhoids is a recurrent disease!

## ETIOLOGY

☼ Risk factors:

- Constipation / Straining.
- Pregnancy.

- Increased pelvic/abdominal pressure (ascites / tumors).
- Diarrhea
- Heredity
- Erect posture
- Absence of valves within the hemorrhoidal sinusoids.
- Aging (deterioration of anal supporting tissues).
- Internal sphincter abnormalities.
- Portal HTN (**hemorrhoids are no more common in patients with portal hypertension than in the population at large**).

## PATHOPHYSIOLOGY

⚡ Thomson concluded that a sliding downward of the anal cushions is the correct etiologic theory (shearing).

- Hemorrhoids result from disruption of the anchoring and flattening action of the musculus submucosae ani (Treitz's muscle) and its richly intermingled elastic fibers. Hypertrophy and congestion of the vascular tissue are secondary.

## CLINICAL FEATURES

⚡ **Signs & Symptoms:**

- **Painless bleeding** (Usually fresh blood) – **Major symptom** [not spontaneous, but is due to trauma i.e. related to defecation]. The patient complains of blood dripping or squirting into the toilet bowl. The bleeding also may be occult, resulting in anemia, which is rare, or guaiac-positive stools.
- Pain **when complicated**. (Hemorrhoids are PAINLESS unless they are complicated e.g. inflamed or thrombosed).
- Anal mass / prolapse.
- Itching.
- Excoriation of the perianal skin
- Mucous and fecal leakage
- Soiling can occur specially if the hemorrhoids are always outside and some minimal incontinence can occur (specially of mucus) – which leads to pruritic as it makes the area wet. So one of the common presentations is pruritic ani.



⚡ **Complications:** Thrombosis / Ulceration / Infection.

Note: Always rule out colon CA with lower GI bleeding and hemorrhoids (hemorrhoids could be 2ry to colon CA).

⚡ **Sites:** (When examined in the left lateral position)

- Right anterior (11 o'clock).
- Right posterior (7 o'clock).
- Left lateral (3 o'clock).

⚡ Not all patients present like this, but the configuration is remarkably constant and apparently bears no relationship to the terminal branching of the superior rectal artery. Smaller discrete secondary cushions may be present between the main cushions.

⚡ **Classification:** (of internal hemorrhoids)

- **Grade 1:** Not prolapsed.
- **Grade 2:** Prolapse with defecation & return spontaneously.
- **Grade 3:** Prolapse with defecation and must be reduced manually.
- **Grade 4:** Prolapsed and irreducible.

⚡ **Thrombosed external hemorrhoids:** an abrupt onset of an anal mass and pain that peaks within 48 hours. The pain becomes minimal after the fourth day. If left alone, the thrombus will shrink and dissolve in a few weeks.

Occasionally, the skin overlying the thrombus becomes necrotic, causing bleeding and discharge or infection, which may cause further necrosis and more pain. A large thrombus can result in a skin tag.



## DIAGNOSIS

⚡ By history, physical examination (Inspection + PR), and anoscopy / proctoscopy / sigmoidoscopy.

**Differential diagnosis:**

- Anal melanoma / carcinoma
- Hypertrophied anal papillae
- Rectal polyps / Rectal prolapse
- Fissure / Intersphincteric abscess



## TREATMENT

**Medical;** 1st and 2nd degree. **Minor procedures;** failed medical Rx 1st and 2nd degree, some 3rd degree. **Surgery;** 3rd and 4th degree.

**Grade 1-2:**

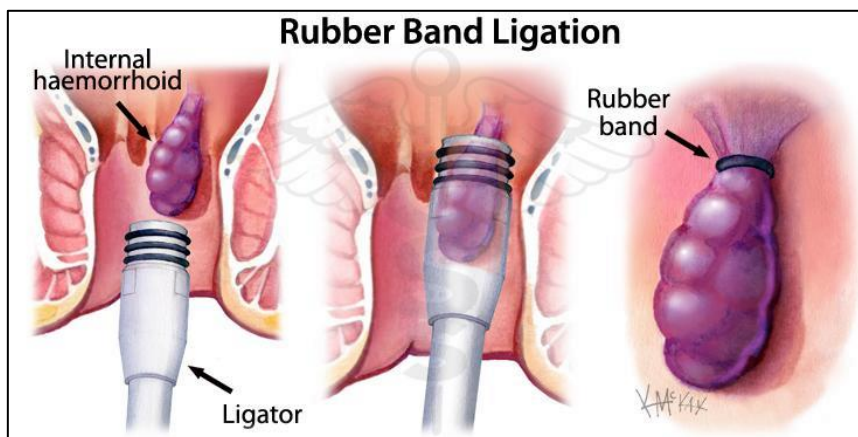
**Conservative:**

- High-fiber diet / Bulk forming agents and laxatives.  
(to decrease shearing and trauma → decrease bleeding)
- Topical hygiene.
- Ointments, creams, gels, suppositories, foams, and pads.
- Sitz baths (warmth relaxes muscles).
- Vasoconstrictors, Protectants, Astringents, Antiseptics, Keratolytics, Analgesics, Corticosteroids.

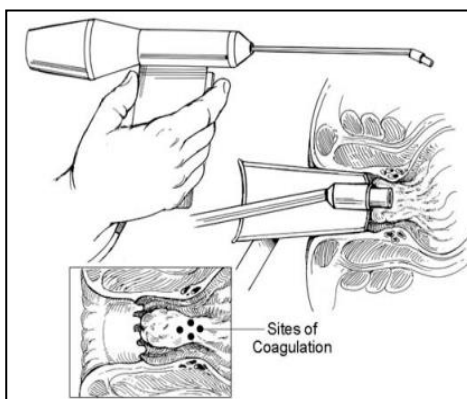
**Outpatient procedures:** (If refractory to medical treatment)

- Rubber band ligation (picture 1).  
(usually anesthesia is not required for internal hemorrhoids)
- Injection sclerotherapy.
- Cryotherapy.
- Infrared coagulation (picture 2).
- Doppler guided hemorrhoidal artery ligation (picture 3).

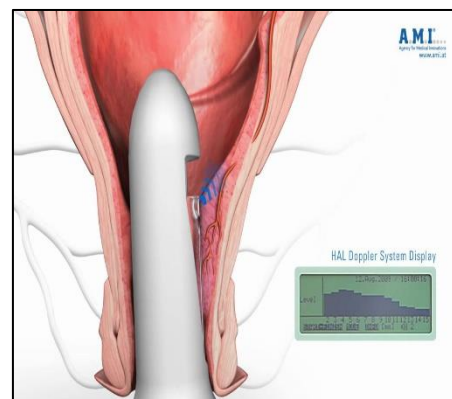
1



2



3



Grade 3-4:

Surgical:

- Anal dilatation (not used anymore).
- **Hemorrhoidectomy:**
  - Closed (sutures mucosa) or open (leaves mucosa open).
  - Whitehead Hemorrhoidectomy
  - Laser Hemorrhoidectomy
  - Stapled hemorrhoidectomy

Complications:

- 1- Exsanguination – Bleeding may pool proximally in the lumen of colon without any signs of external bleeding.
  - 2- Pelvic infection – May be extensive and potentially fatal!
  - 3- incontinence: Injury to the sphincters.
- Hemorrhoidectomy is contraindicated in Crohn's disease (higher complications).
- Removing too much skin may cause anal fibrosis and stenosis.

## Anal Fissure



### INTRODUCTION

⚡ **Definition:** Tear or fissure in the anal epithelium (Anoderm).

- Younger and middle-aged adults but also may occur in infants, children, and the elderly. Fissures are equally common in both sexes.



### ETIOLOGY

- Hard stool passage (constipation).
- Hyperactive sphincter (**Primary fissures**).
- Disease process (e.g. Crohn's disease, HIV, anatomic problem [e.g. postpartum]) (**Secondary fissures**).

## ⚡ PATHOPHYSIOLOGY

⚡ **Hypertonic (hyperactive) internal sphincter** is the usual primary pathology, aided by other mechanisms (e.g. trauma by hard stool [constipation]).

- This will go into vicious circle: Pain → Spasm → Constipation

## 🔍 CLINICAL FEATURES

⚡ Anal fissure is located at the anoderm; so it is a **very painful** condition and this pain is due to stimulation by feces.

- **Site:** Most common posteriorly. Anterior fissures are seen in females more than males but it's less common than posterior fissures.
- Lateral fissures are usually seen in patients with Crohn's / US / TB.

### ⚡ Symptoms:

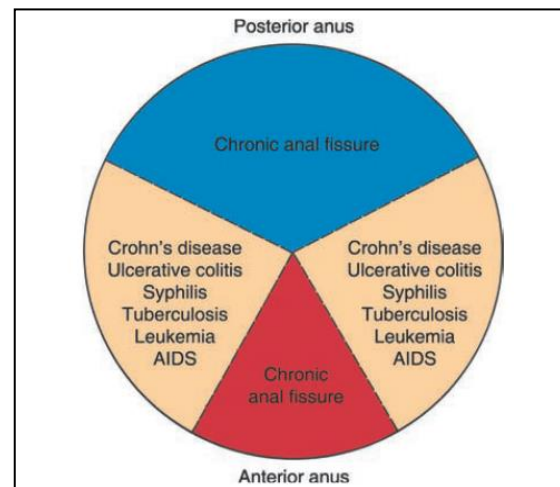
- Pain in anus during and after defecation.
- Rectal bleeding (usually minimal / appears as streaks in acute phase).
- Constipation; cause and consequence.
- Discharge.

### ⚡ signs:

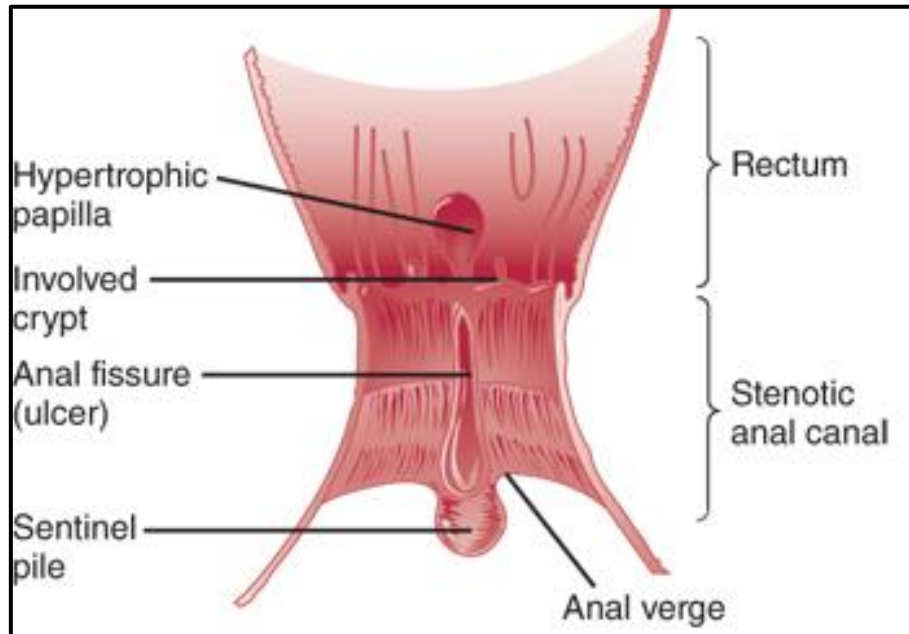
- Blood on toilet tissue after bowel movement.
- Sentinel tag/pile.
- Tear in the anal skin.
- Painful PR exam.
- Hypertrophic papilla.

⚡ Acute fissure is a tear. Chronic fissure is an ulcer. The time needed for an acute fissure to become chronic is  $\approx$  1 month. Signs of chronicity: 1- Sentinel Pile 2- Hypertrophic anal papilla 3- Fibrosis 4- submucous fistula.

Note: Constipation is related to anal fissure because the patient will be afraid to go to the toilet.



Note: Chronic fissure is a cause of submucosal fistula which is **not cryptogenic** (and managed in a different way i.e. is not treated by fistulotomy & sphincterotomy).



## DIAGNOSIS

**Anal fissure triad for chronic fissures:**

- 1- Fissure / hypertrophic sphincter.
- 2- Sentinel pile.
- 3- Hypertrophic anal papilla.

Diseases that must be considered with a chronic anal fissure:

- IBD.
- Anal CA.
- Aids / STDs.



## TREATMENT

→ **Acute:**

**Conservative:** High fiber diet, stool softeners and laxatives, local analgesia, Sitz bath, anal hygiene.

**Pharmacologic Sphincterotomy:** Glyceryl Trinitrate, Calcium Channel Antagonists, Botulinum Toxin.

## Surgical: Sphincterotomy.

### → Chronic:

**Conservative;** same as acute.

### Surgical:

- Lateral internal sphincterotomy (**LIS**) [lateral partial].
- V-Y Anoplasty (Advancement Flap Technique).
- Classic Excision.
- Finger Anal Sphincter Stretch (not used anymore).
- Controlled intermittent anal dilatation.

**LIS:** cut the internal sphincter to release it from spasm + Piles excision if present.

Indications of sphincterotomy: Fissure refractory to conservative treatment.

Contraindications: IBD.

Role of 90% for anal fissures:

- 90% occur posteriorly.
- 90% heal with medical treatment.
- 90% of patients who undergo surgery heal successfully.

## Perianal suppuration

### 1) Anorectal abscess:

#### INTRODUCTION

**Definition:** Obstruction of anal glands ducts or the crypts with resultant bacterial overgrowth and abscess formation within the potential spaces.

**Potential spaces (types):** Perianal / Ischiorectal / Intersphincteric / Supralevator.

#### ETIOLOGY

**Cryptogenic** (unknown) or **cryptoglandular**.

**Risk factors:**

- Constipation / Diarrhea / IBD.

- Immunocompromise.
- History of recurrent surgery / trauma (impalement, enemas, prostatic surgery, episiotomy, hemorrhoidectomy).
- History of colorectal CA.
- History of previous anorectal abscess.



## CLINICAL FEATURES

### Symptoms:

- **Acute pain** often of sudden onset / throbbing / continuous / Pain occurs with sitting or movement and is usually aggravated by defecation and even coughing or sneezing.
- **Swelling.**
- Drainage of pus.
- Preceding bout of diarrhea
- Bleeding
- Fever / Chills / Malaise.

### Signs:

- Tender induration.
- Pus may be seen exuding from a crypt.
- Examination under anesthesia is not only justified but also indicated.
- Supralelevator abscess: a tender mass in the pelvis may be diagnosed by rectal or vaginal examination. Abdominal examination may reveal signs of peritoneal irritation.

Note: In severely diabetics, horrible necrotizing soft tissue infection may follow; Watch them closely!

Diagnosis by: Physical examination, Examination under GA, MRI.



## TREATMENT

### Surgical drainage.

### Complications of surgery:

- May extend upward.

- **Fistula!** (50% of patients with abscess will develop a fistula in ano within 6 months after surgery).

Indications of postop IV antibiotics:

- Recurrence.
- Deep and local spread.
- Cellulitis.
- DM / Immunocompromised / SIRS.
- Valvular heart disease.
- Sepsis.
- Leukocytosis.

## 2) Anorectal fistula:

### INTRODUCTION

**Definition:** Epithelial communication between the anal canal and perianal skin.

Men predominate in most series with a male-to-female ratio varying from 2:1 to 7:1.

Age distribution is spread throughout adult life with a maximal incidence between the third and fifth decades.

Could be:

- **Complex;** more than one tract (branching).
- **High;** the main tract or a branch passes to the level of anorectal ring.
- **Horse-shoe;** the tract passes on both sides of the midline.

### ETIOLOGY

Usually after perianal crypt / gland infection (perianal abscess).

The patient's history will reveal an abscess that either burst spontaneously or required drainage. Or a small discharging sinus.

**Risk factors:** Same as abscess.





## CLINICAL FEATURES

External opening usually can be seen as a red elevation of granulation tissue with purulent serosanguinous discharge on compression. Opening is sometimes so small that it can be detected only when palpation around the anus expresses a few beads of pus.

**An external opening adjacent to the anal margin may suggest an inter-sphincteric tract. A more laterally located opening would suggest a trans-sphincteric one.**

**The further the distance of the external opening from the anal margin, the greater is the probability of a complicated upward extension.**

Crypt of origin is often retracted into a funnel by pulling the fibrous tract leading to the internal sphincter; this state is called the funnel, or “herniation sign” of the involved crypt.

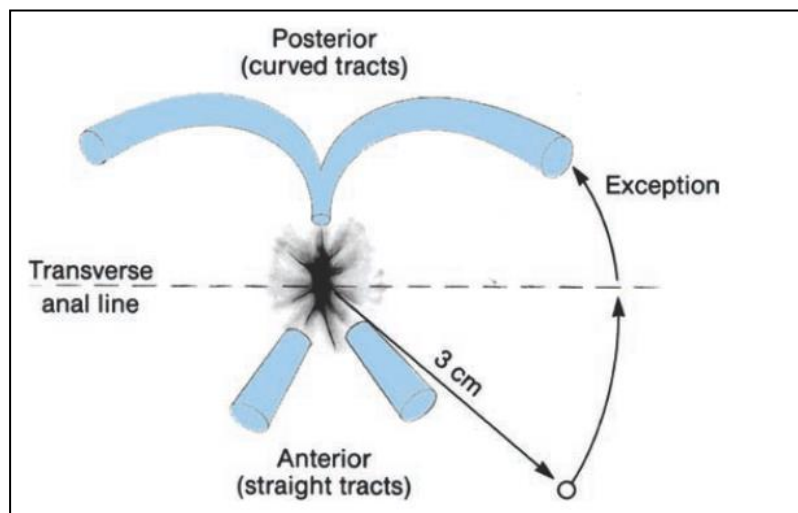
### Signs and Symptoms:

- Perianal drainage.
- Recurrent abscess.
- Diaper rash / itching.

Note: The primary tract of a fistula may have secondary tracts arising from it.

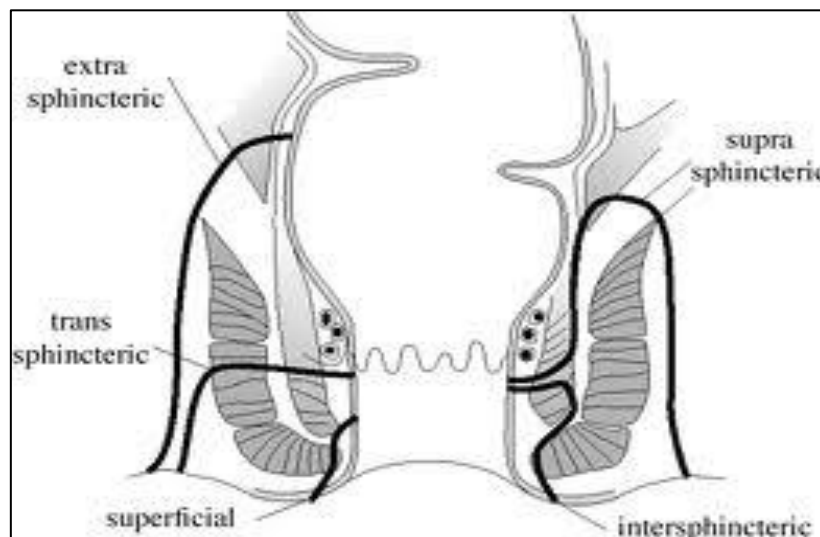
### Goodsall's Rule: (Important)

Fistulas originating **anterior** to a transverse line across the anus will course **straight** ahead and open anteriorly in the anal canal. Whereas **posterior** fistulas have a **curved** tract and open in the posterior midline in the anal canal. (This rule works within 3 cm. from the anus. Fistulas lying more than 3 cm. from the anus may have a curved tract and open in the posterior midline of the anal canal).



## Classification of anorectal fistulas (Park's classification):

- 1- Intersphincteric: 70%
  - Most common.
  - Does not cross the external sphincter.
- 2- Trans-sphincteric: 23%
  - Crosses both internal and external sphincters.
- 3- Supra-sphincteric: 5%
  - Very rare.
  - Usually iatrogenic.
  - Difficult to distinguish from high-level trans-sphincteric (but mangment is similar).
- 4- Extrasphincteric: 2%
  - Runs without specific relation to the sphincters and usually results from pelvic disease or trauma.



## DIAGNOSIS

Physical (PR) and Proctoscope.

### Investigations:

- Anoscopy and sigmoidoscopy.
- Fistulography.
- Endoanal Ultrasonography.
- Magnetic Resonance Imaging.
- Endoanal Magnetic Resonance Imaging.



## TREATMENT

### Surgical:

Rules: Define the anatomy. The primary opening of a tract must be identified. The relationship of the tract to the puborectalis muscle must be established. Division of the least amount of muscle in keeping with cure of the fistula should be practiced. Side tracts should be sought. The presence or absence of underlying disease should be determined.

Procedure: **Fistulotomy** (with marsupialisation).

+ Wound care: routine sitz baths and dressing changes.

+ Seton placement if fistula is through the sphincter muscle.

Seton: thick suture placed through fistula tract to allow slow transection of sphincter muscle; scar tissue formed will hold the sphincter muscle in place and allow for continence after transection.

Sitz baths: Sitting in a warm bath (usually done after bowel movement).

Marsupialization: is the surgical technique of cutting a slit into an abscess or cyst and suturing the edges of the slit to form a continuous surface from the exterior surface to the interior surface of the cyst or abscess. Sutured in this fashion, the site remains open and can drain freely. This technique is used to treat a cyst or abscess when a single draining would not be effective and complete removal of the surrounding structure would not be desirable.

Other procedures:

- Advancement rectal flap.
- Dermal Island Flap Anoplasty.
- Fistulectomy and Primary Closure.
- Video assisted anal fistula treatment.
- Cutting Seton.
- Fibrin Glue.
- Anal Plug.
- Lift Technique.
- Ablation (laser).

Note: Kindly see the doctor's last 20 slides of the procedures.

# Other Anorectal Diseases

## 1) Pilonidal disease:

### INTRODUCTION

**Definition:** a spectrum of clinical presentations, ranging from asymptomatic hair-containing cysts and sinuses to large symptomatic abscesses of the sacrococcygeal region that have some tendency to recur.

Pilo: Hair / Nidus: Origin; Indicating that it's associated with hair follicles.

Most common in **young males (20's-30's)**.

### ETIOLOGY

Pilonidal disease is acquired, not congenital, and involves loose hair and skin and perineal flora.

### PATHOPHYSIOLOGY

It has been postulated that hair penetrates into the subcutaneous tissues through dilated hair follicles, which is thought to occur particularly in late adolescence, though follicles are not found in the walls of cysts. Upon sitting or bending, hair follicles can break and open a pit. Debris may collect in this pit, followed by development of a sinus with a short tract, with a not clearly understood suction mechanism involving local anatomy, eventually leading to further penetration of the hair into the subcutaneous tissue. This sinus tends to extend cephalad, likely owing to mechanical forces involved in sitting or bending. A foreign body-type reaction may then lead to formation of an abscess. If given the opportunity to drain spontaneously, this may act as a portal of further invasion and eventually formation of a foreign body granuloma. Infection may result in abscess formation.

In summary, 3 pieces are instrumental in this process: (1) the invader, hair; (2) the force, causing hair penetration; and (3) the vulnerability of the skin.



## CLINICAL FEATURES

### Signs & Symptoms:

Either presents **acutely** as abscess (fluctuant mass), or **chronically** as a draining sinus with pain at the top of the gluteal cleft.



## TREATMENT

**I&E (incision and drainage).** Under local anesthesia with removal of involved hair.

### 2) Anal / Perianal warts:



## INTRODUCTION

**Definition:** Warts (small, rough, and hard growths that are similar in color to the rest of the skin) around anus / perineum.

They are part of genital warts (Condyloma Acuminatum).



## ETIOLOGY

Human Papilloma Virus (HPV).



## PATHOPHYSIOLOGY

Cells of the basal layer of the epidermis are invaded by human papillomavirus (HPV). These penetrate through skin and cause mucosal microabrasions. A latent viral phase begins with no signs or symptoms and can last from a month to several years. Following latency, production of viral DNA, capsids, and particles begins. Host cells become infected and develop the morphologic atypical koilocytosis of condyloma acuminatum.



## CLINICAL FEATURES

**Signs and Symptoms:** In most cases, there are no symptoms of HPV infection other than the warts themselves. Sometimes warts may cause itching, redness, or discomfort, especially when they occur around the anus. Although they are usually without other physical symptoms.



## TREATMENT

If small → Topical Podophyllin.

If large → Surgical resection or laser ablation.

# Anal Cancer

## INTRODUCTION

### Types of anal cancers:

They are classified into:

- Anal skin cancers (a.k.a Anal margin tumors) [Anal verge out 5cm. onto the perianal skin].
- Anal canal cancers (epidermoid and malignant melanoma) [Proximal to anal verge up to the border of the internal sphincter].

Collectively, the types are:

- 1- Squamous cell carcinoma (most common – 80%).
- 2- Cloacogenic (transitional cell).
- 3- Adenocarcinoma.
- 4- Melanoma.
- 5- Mucoepidermal.

It is a **rare** cancer; 1% of colon cancers incidence.

SCC in situ is called **Bowen's disease**.

Adenocarcinoma in situ is called (**perianal**) **Paget's disease**.

## ? ETIOLOGY

### Risk factors:

- HPV / Condyloma / Herpes.
- HIV.
- Smoking.
- Immunosuppression.
- Chronic inflammation (fistula / Crohn's).
- Multiple sexual partners / Anal intercourse.



## CLINICAL FEATURES

### Signs and Symptoms:

- Anal bleeding (Most common symptom).
- Pain, mass, mucus per rectum, pruritus.

**25% of patients are asymptomatic.**

**Sites of metastasis:** L.N, Liver, Lung and bone (Remember, lymphatic drainage below the dentate line is to inguinal L.N.).



## DIAGNOSIS

- History and physical (PR, Proctoscope and Colonoscopy).
- Surgical biopsy with histopathologic evaluation.
  - Histology: - Anal margin: SCC / BCC / Bowen's / Paget's disease.
  - Anal canal: Epidermoid (SCC or Transitional) and Melanoma.
- Abdominal / pelvic CT scan, trans-anal U/S.
- Chest X-ray / LFTs (for metastasis).

**Clinical staging:** History / Physical / Proctocolonoscopy / Abdominal or pelvic CT or MRI / CXR / LFTs / Transanal ultrasound.

**Most patients are diagnosed late, and diagnosis is often missed!**



## TREATMENT

Based on **NIGRO protocol**.

- If anal canal epidermal CA → Chemotherapy + Radiotherapy + Scar biopsy (6-8 w after RTX).
  - 90% of patients have complete response.
  - 5-year survival = 85%.
  - If local recurrence happened after NIGRO → Repeat CTX/RTX or Salvage APR (Abdominoperineal resection).
  - Note: In anal canal tumors, local excision is not an option! – CTX & RTX are often successful. APR is done only if follow up biopsy indicates residual tumor.



➤ If anal margin CA → Smaller than 5 cm: Surgical excision with 1 cm margin.  
Bigger than 5 cm: CTX.

➤ If anal melanoma → WLE (wide local excision) or APR (especially if large)  
+/- postop RTX/CTX.

5-year survival = <10%.

Note: 1/3 of melanoma patients have amelanotic (not dark in color) tumor; making diagnosis difficult without pathology.

# Summary & past papers

## Summary

☼ Hemorrhoids are normal structures (anal cushions) that play a minor role in continence. When hemorrhoids enlarge, prolapse or bleed then they become hemorrhoidal disease, they are divided into internal (above the dentate line) and external (below the dentate line). Hemorrhoidal disease is a degenerative disease of the connective tissue that's associated with constipation/Straining, pregnancy, Increased pelvic/abdominal pressure, diarrhea, erect posture, absence of valves within the hemorrhoidal sinusoids, aging, Internal sphincter abnormalities and Portal HTN. It presents with painless bleeding ( blood dripping or squirting into the toilet bowl), anal mass/prolapse, itching, excoriation of the perianal skin, Mucous leakage and Soiling. Complicated Hemorrhoids (Thrombosis / Ulceration / Infection) may cause pain. hemorrhoidal disease is classified into 4 grades (Grade 1: Not prolapsed/ Grade 2: Prolapse with defecation & return spontaneously/ Grade 3: Prolapse with defecation and must be reduced manually/ Grade 4: Prolapsed and irreducible). Grade 1 and 2 are managed conservatively (High-fiber diet, Bulk forming agents, laxatives, topical hygiene, Ointments, creams, gels, suppositories, foams, pads, Sitz baths). Stages 1 and 2, If refractory to medical treatment are managed by outpatient procedures. Stages 3 and 4 are managed surgically.

☼ Anal fissure is a tear or fissure in the anal epithelium (Anoderm), most commonly posteriorly. It results from the vicious circle of Pain, Spasm and Constipation. Anal fissures present as Pain in anus during and several hours after defecation, rectal bleeding (usually minimal / appears as streaks in acute phase), Constipation and discharge. Signs of chronicity are sentinel Pile, hypertrophic anal papilla, fibrosis and submucosal fistula. The first line in treating anal fissures (acute or chronic) is conservative (high fiber diet, stool softeners and laxatives), pharmacologic

sphincterotomy (Glyceryl Trinitrate, Calcium Channel Antagonists, Botulinum Toxin) may be used as well. Surgical sphincterotomy (Lateral internal sphincterotomy) is the last resort for refractory cases.

☼ Anorectal abscess results from obstruction of anal glands ducts or the crypts with resultant bacterial overgrowth and abscess formation within the potential spaces. It presents with acute pain (often of sudden onset / throbbing / continuous / Pain occurs with sitting or movement and is usually aggravated by defecation and even coughing or sneezing), Swelling, drainage of pus, bleeding, Fever, Chills, and malaise. Anorectal abscesses are treated by surgical drainage, with 50% risk of fistula formation after the surgery. Anorectal fistula is epithelial communication between the anal canal and perianal skin, it results, usually from perianal crypt/gland infection (perianal abscess). Anorectal fistula could be Intersphincteric (most common), trans-sphincteric, Supra-sphincteric or Extrasphincteric. It presents with perianal drainage, recurrent abscess and diaper rash/itching. Fistulas are treated by Fistulotomy (with marsupialization). Seton placement could be used as well, especially if the fistula passes through the sphincter muscle.

## Past papers

**1. 40 y/o BPR, rectal mass 6 cm from anal verge all part of management except?**

- a) FOB test
- b) family hx
- c) Assess for surgery

**2. False about rectal anatomy:**

- a) superior rectal artery arises from the internal iliac artery

**3. True about hemorrhoids?**

- a) Internal hemorrhoid lies above the dentate line and below the anorectal ring

**4. wrong about hemorrhoids:**

- a) Peak at age 45-65
- b) most common symptom is pain**
- c) Hemorrhoids are normally cushions found in everyone and aid in continence
- d) Internal are covered by mucosa, external by skin
- e) Stage 3 and 4 corrected surgically

**5. Wrong about anal fissures:**

- a) Anterior fissures are more common than posterior fissures**
- b) Sentinel pile → chronic fissure
- c) Usually hyperactive internal sphincter

**6. Wrong about anal fistula:**

- a) Intersphincteric → most common
- b) Seton is associated with negligible incontinence**

**7. About hemorrhoids, which of the following is incorrect:**

- a) 20% of continence is contributed for by hemorrhoids
- b) surgery is indicated only in grades III and IV
- c) Blood mixed with stool**

**8. Patient presented with hemorrhoids grade II treated with medical management and failed, your management:**

- a) rubber band ligation**

**9. All are true in regard to PNS except:**

- a) Hair has minimal role in pathogenesis**

**10. wrong about anal fissure :**

- a) in males, most commonly ant median**

**The end of the dossier**

## References

- Bhat M, S. (2016). *Srb's manual of surgery*. Jaypee Brothers Medical P.
- BLACKBOURNE, L. (2017). *SURGICAL RECALL*. WOLTERS KLUWER.
- Burnand, K., & Browse, N. (2015). *Browse's introduction to the symptoms & signs of surgical disease*. Boca Raton, FL: CRC Press, Taylor & Francis Group.
- Doherty, G. (2002). *The Washington manual of surgery*. Philadelphia: Lippincott Williams & Wilkins.
- Gaith, S. (2016). *GI surgery Dossier*. University of Jordan, Faculty of medicine.
- Kumar, P., & Clark, M. *Kumar & Clark's clinical medicine*.
- Latest Medical News, Clinical Trials, Guidelines – Today on Medscape*. (2018). *Medscape.com*. Retrieved 2017, from [http://www.medscape.com/lectures & seminars](http://www.medscape.com/lectures&seminars). (2017). University of Jordan, faculty of medicine.
- Smarter Decisions. Better Care..* (2018). *UpToDate*. Retrieved 2017, from <https://www.uptodate.com/>
- Williams, N., O'Connell, P., & McCaskie, A. *Bailey & Love's short practice of surgery*.