

HYDATID CYST OF THE LIVER

Salam Daradkeh

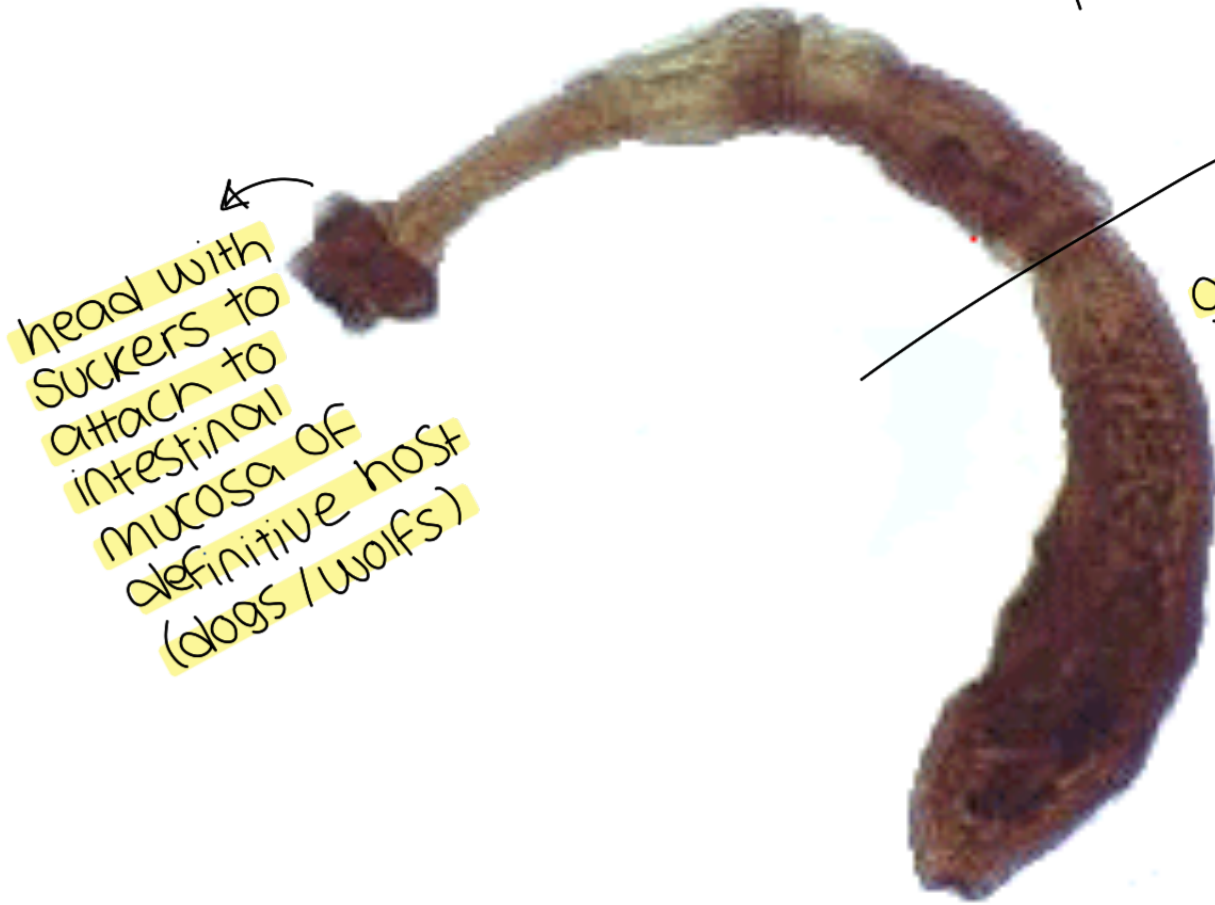DEPARTMENT OF GENERAL
SURGERY



Echinococcus granulosus

adult

microscopic parasite



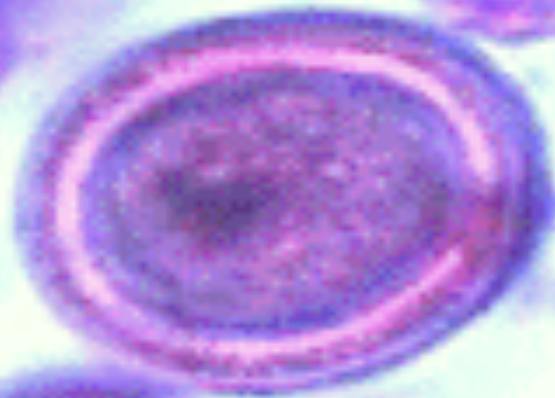
head with suckers to attach to intestinal mucosa of definitive host (dogs / wolfs)

gravid segment filled w/ scolesis (detached from parasite & eliminated w/ feces)

(By P.W. Pappas and S.M. Wardrop; original by P. Darben)

Echinococcus granulosus

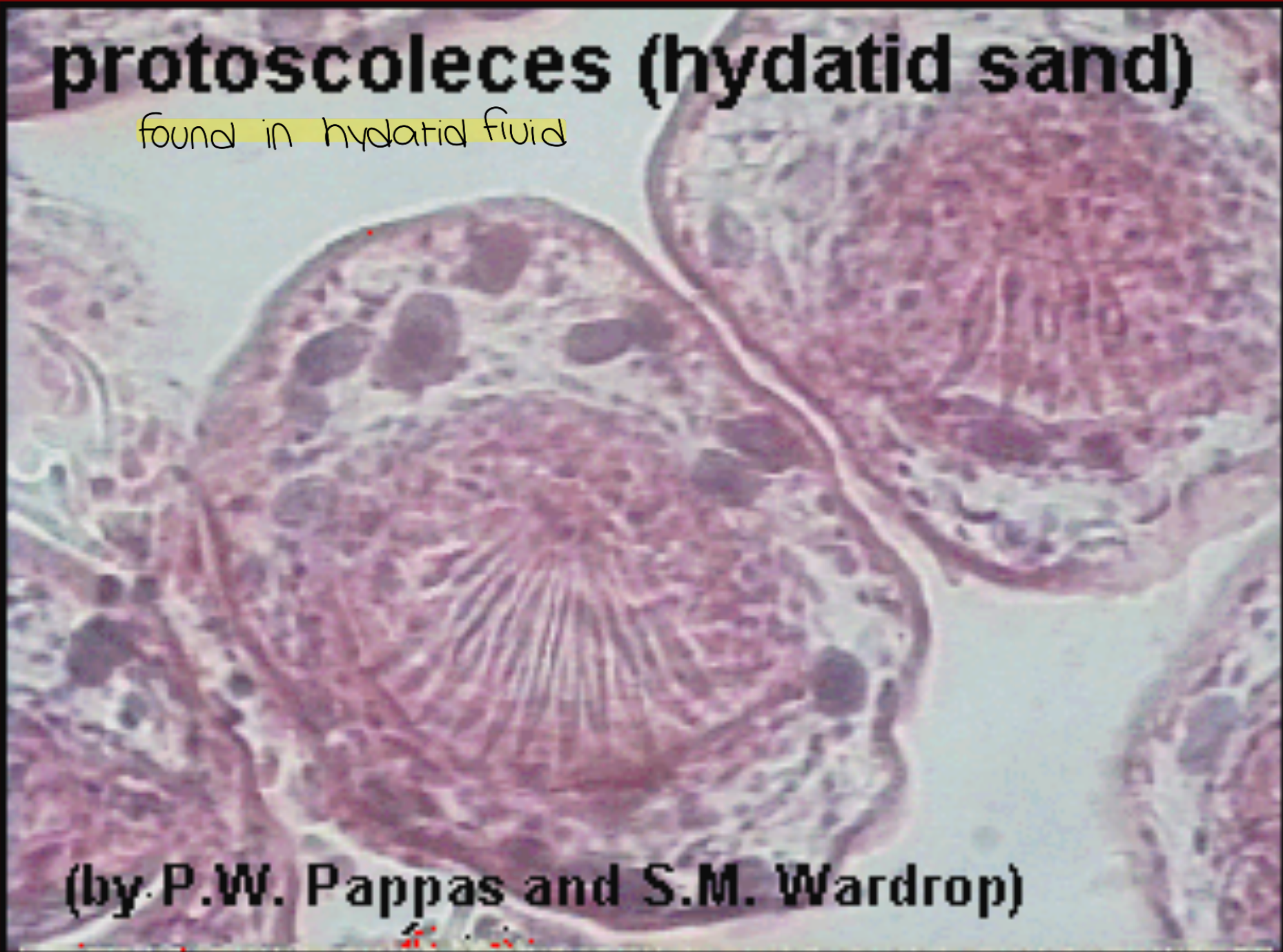
egg → found in gravid segment



**(By P.W. Pappas and S.M. Wardrop;
original by P. Darben)**

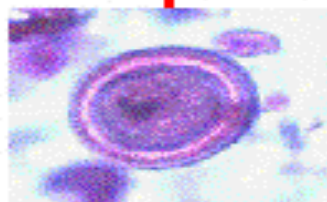
protoscoleces (hydatid sand)

found in hydatid fluid



(by P.W. Pappas and S.M. Wardrop)

The adult tapeworm is found in the small intestine of the canine (definitive) host.



Eggs are passed in the host's feces.

The eggs are ingested by an intermediate host. Many species of warm blooded vertebrates can be infected.



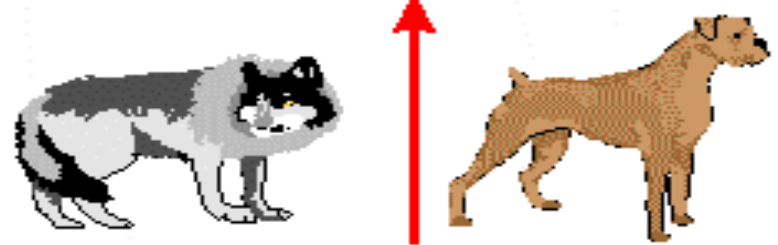
mostly liver then lung
HO

dogs eat diseased sheep

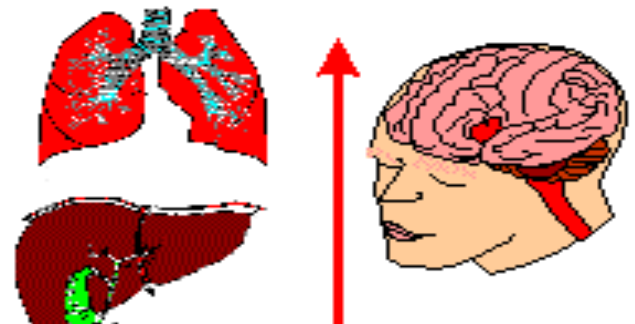
The protoscolex attaches to the host's intestine and develops into a tapeworm.



The definitive host is infected when it ingests the hydatid cyst (protoscolecies).



The larva develops into a hydatid cyst.



histopathologically:

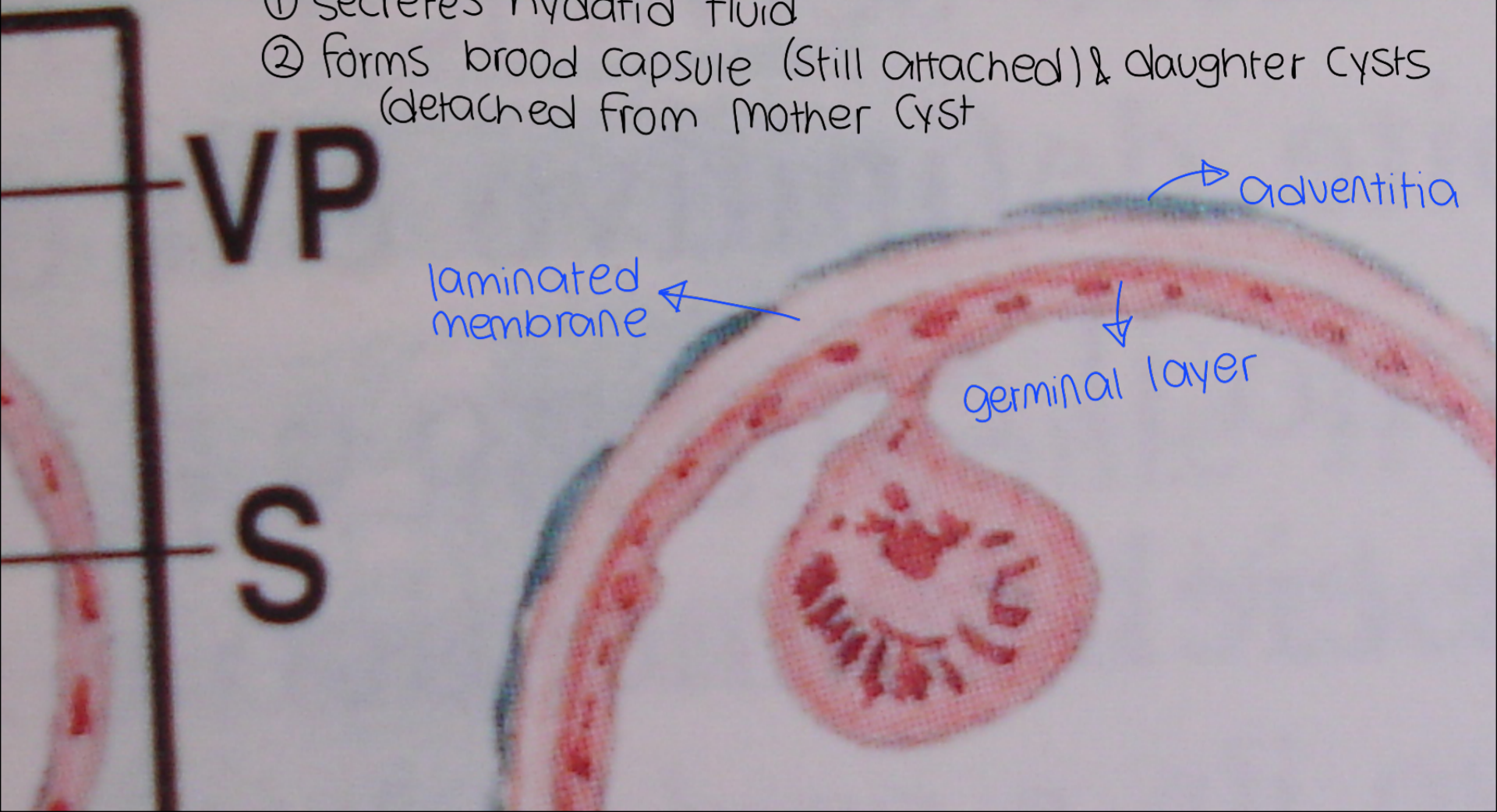
ectocyst (pericyst) → adventitia (fibrous capsule, rxn w/ host organ)

endocyst → laminated & germinal layer

germinal layer: single epithelium (living parasite)

① secretes hydatid fluid

② forms brood capsule (still attached) & daughter cysts (detached from mother cyst)



CLINICAL FEATURES

→ incidental finding

- ◆ **LATENCY**(Asymptomatic, Abdominal pain).
- ◆ **SUPPURATION**: 11%-27%. E.COLI (complicated by infxn)
- ◆ **PRESSURE EFFECTS**: LIVER TISSUE, HILUM, HEPATIC VEINSetc.

Clinical Features

◆ RUPTURE:

- **Obscure:** rupture of the endocyst. (within ectocyst)

- **Communicant Rupture:** biliary tree, bronchial tree. (when cyst develops near tree → increased pressure in tree causes erosion & fistulization)

- **Free Rupture:** free body cavities or adjacent organs. (1-4%) ↪ peritoneal

↪ hollow viscous colon, Small bowel, Stomach

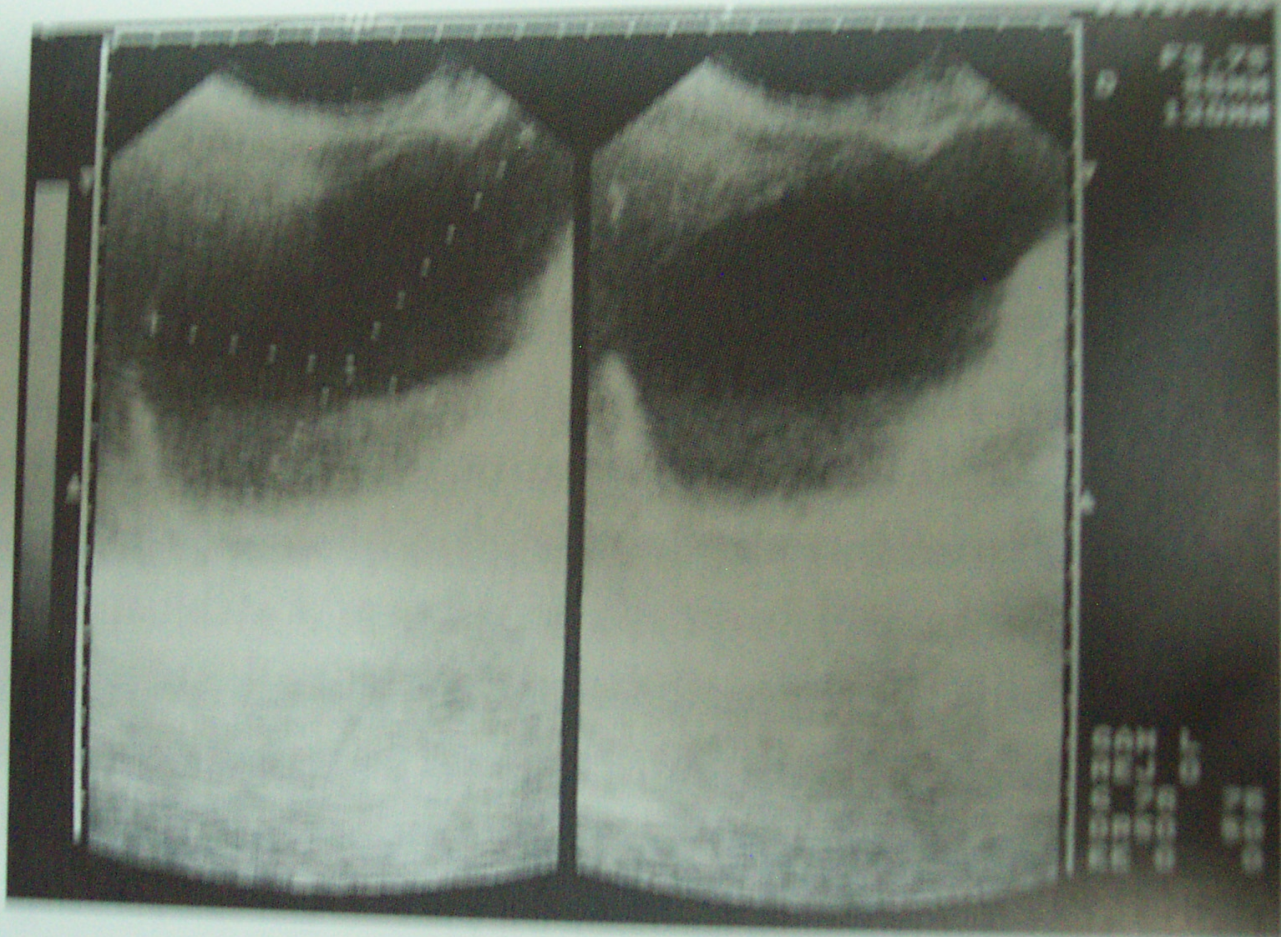
* rupture into pleura can cause pleural & pericardial effusion

DIAGNOSIS- IMAGING

- ▶ not used
 - ▶ arciform
 - ▶ pathognomonic in abdominal cysts (lung hydatid cysts dont calcificate)
- ◆ **PLAIN X-RAY: CALCIFICATION.**
 - ◆ **ULTRASONOGRAPHY: H.Gharby 1981**
classification:
 - 1- simple hydatid cyst.(budding + h.sand)
 - 2- fluid collection with a split wall(Water-lily)
 - 3- fluid collection with septa(Honeycomb).
 - 4- heterogeneous appearance.▶ with hypo/hyper dense, hypo/hyper equiv, calcifications
 - 5- reflecting thick wall.
(active Cyst)

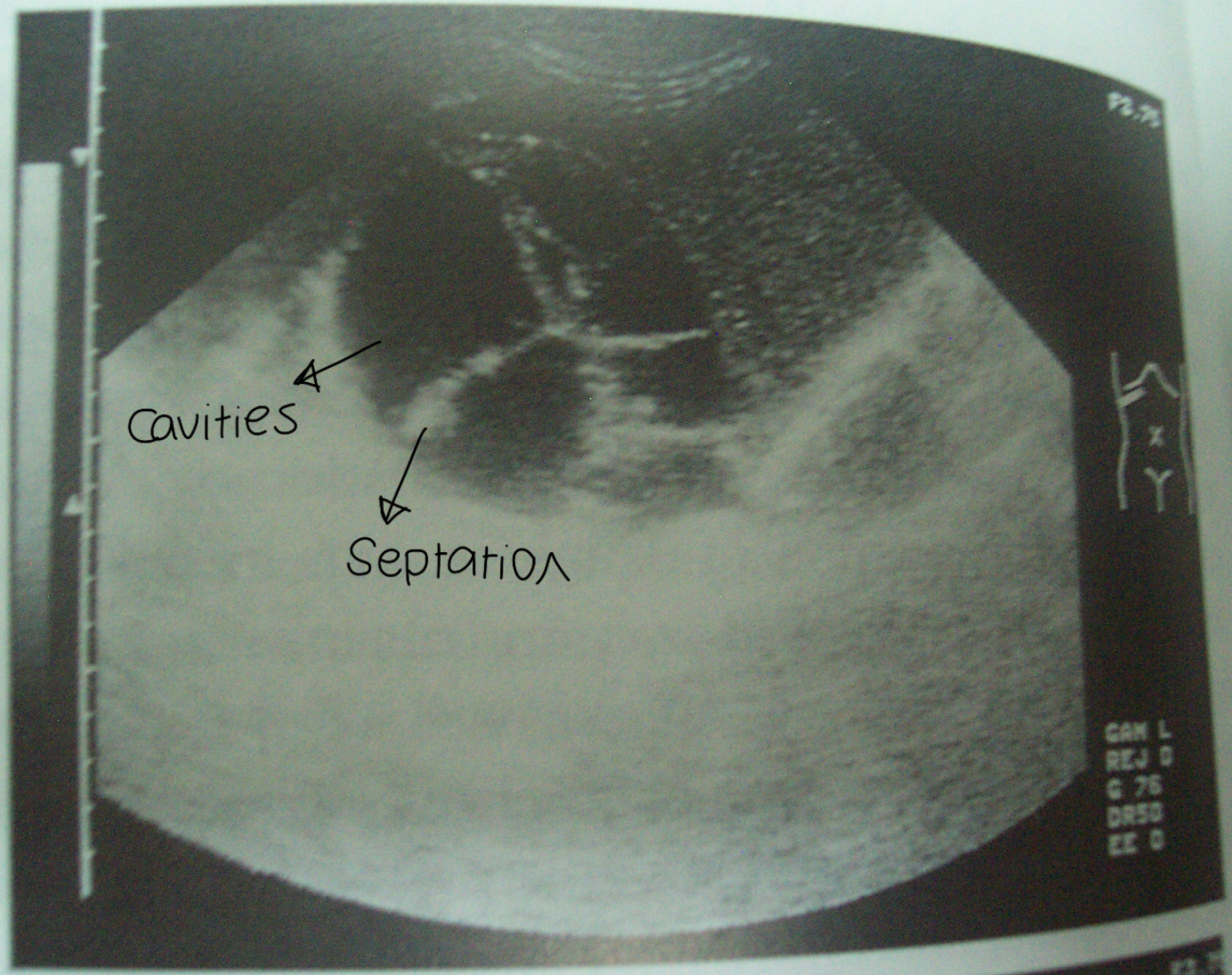
1179

Liver and biliary



(A)

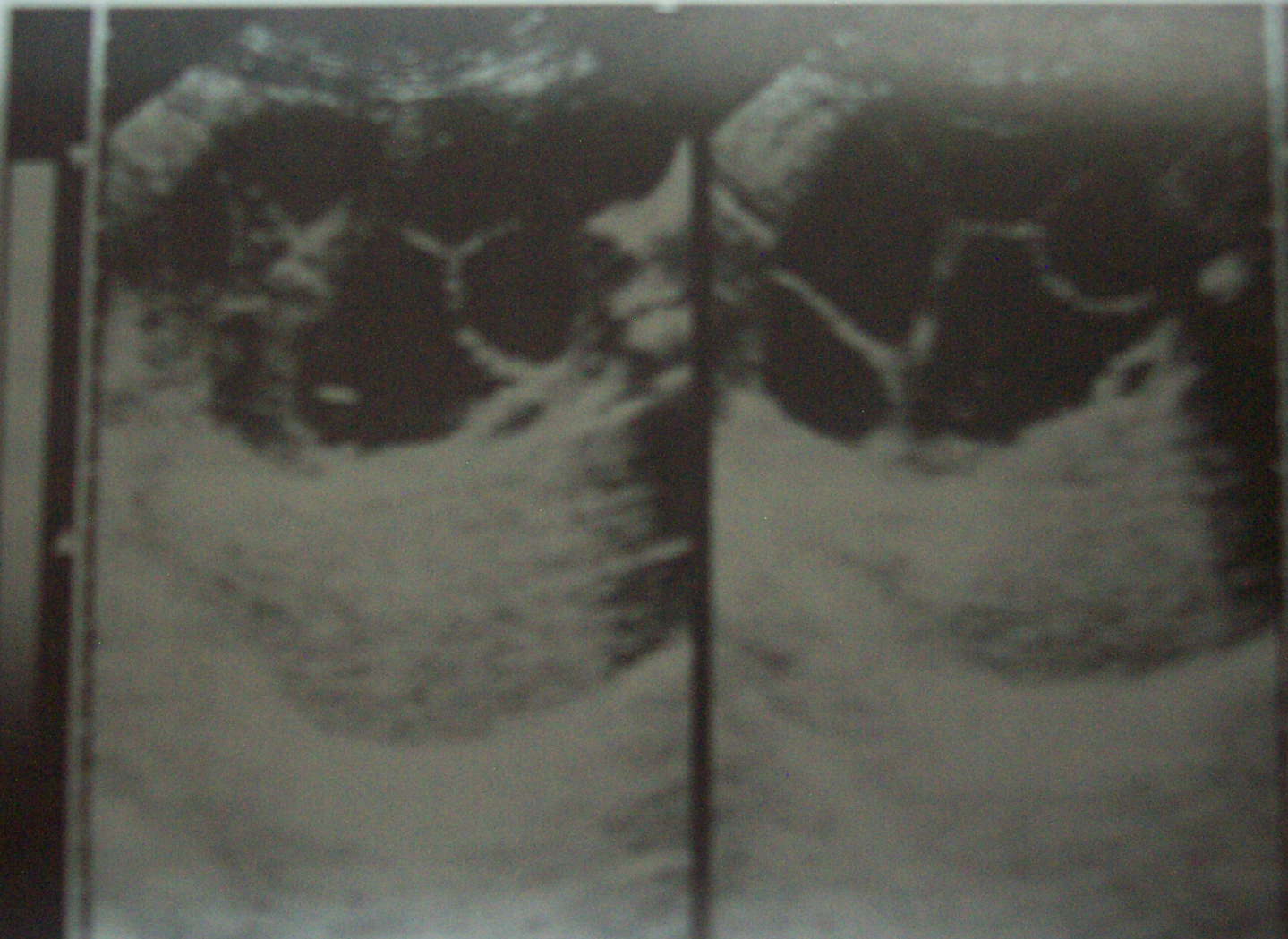
honey comb appearance



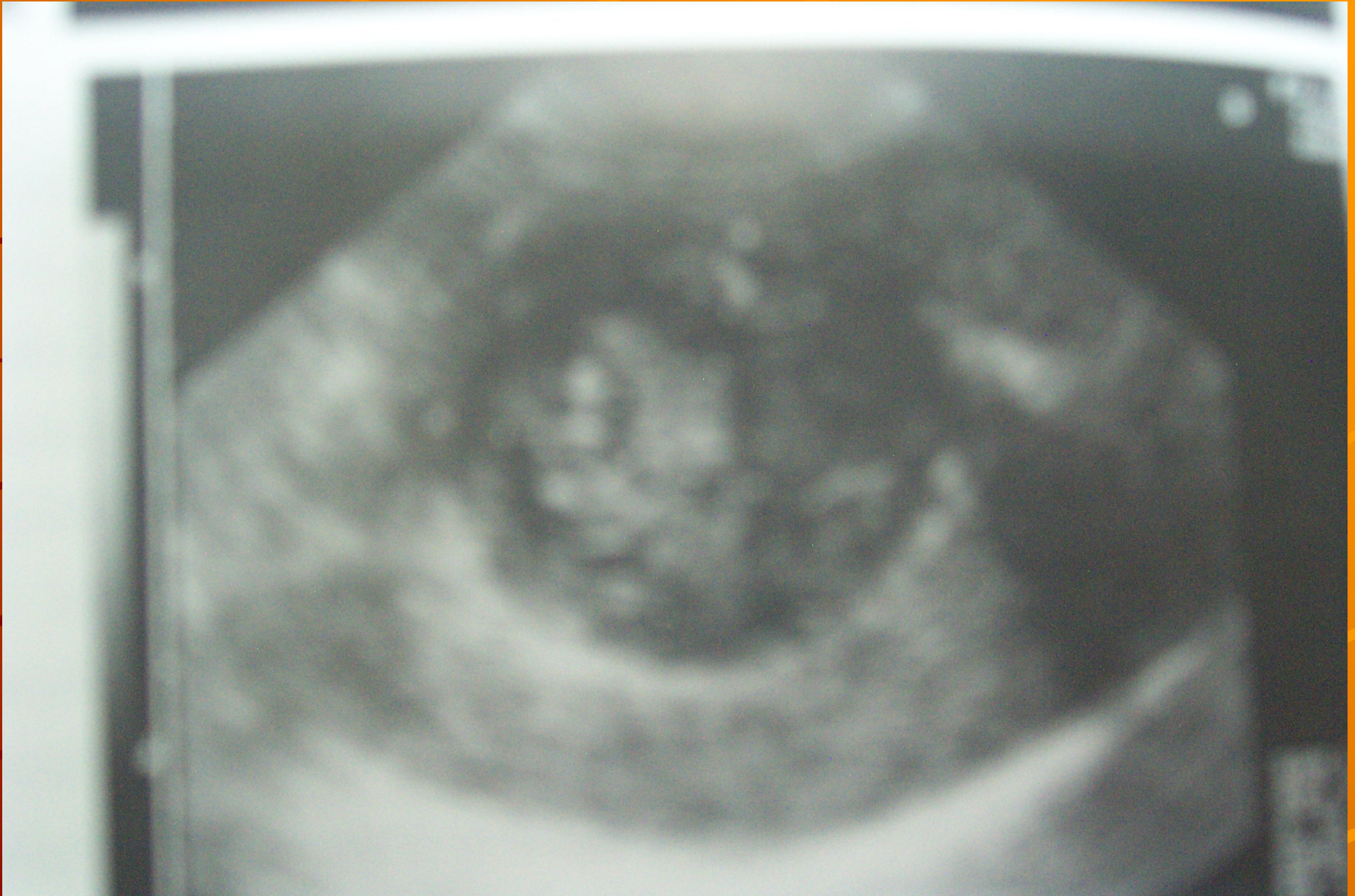(B)



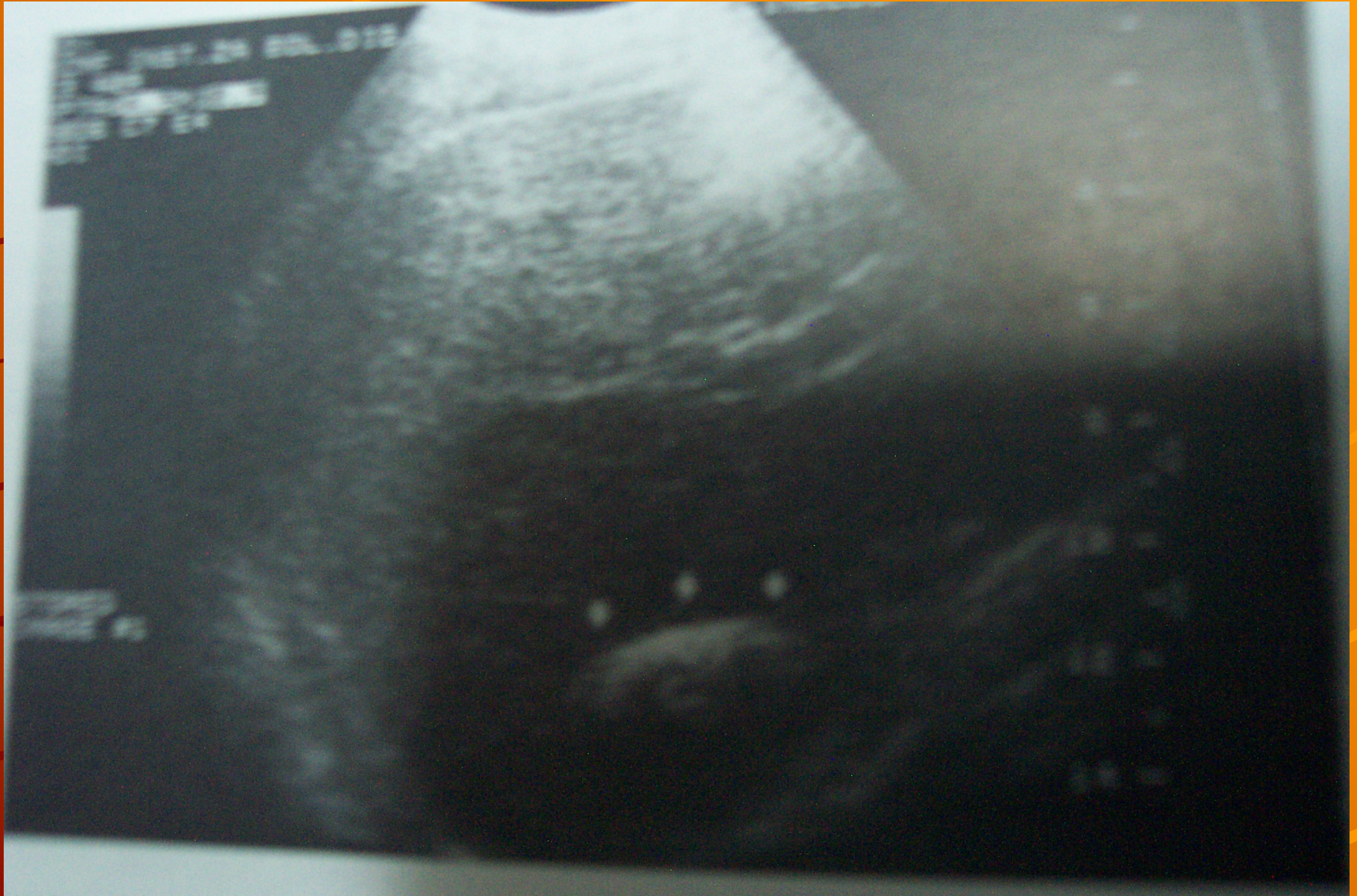(A)



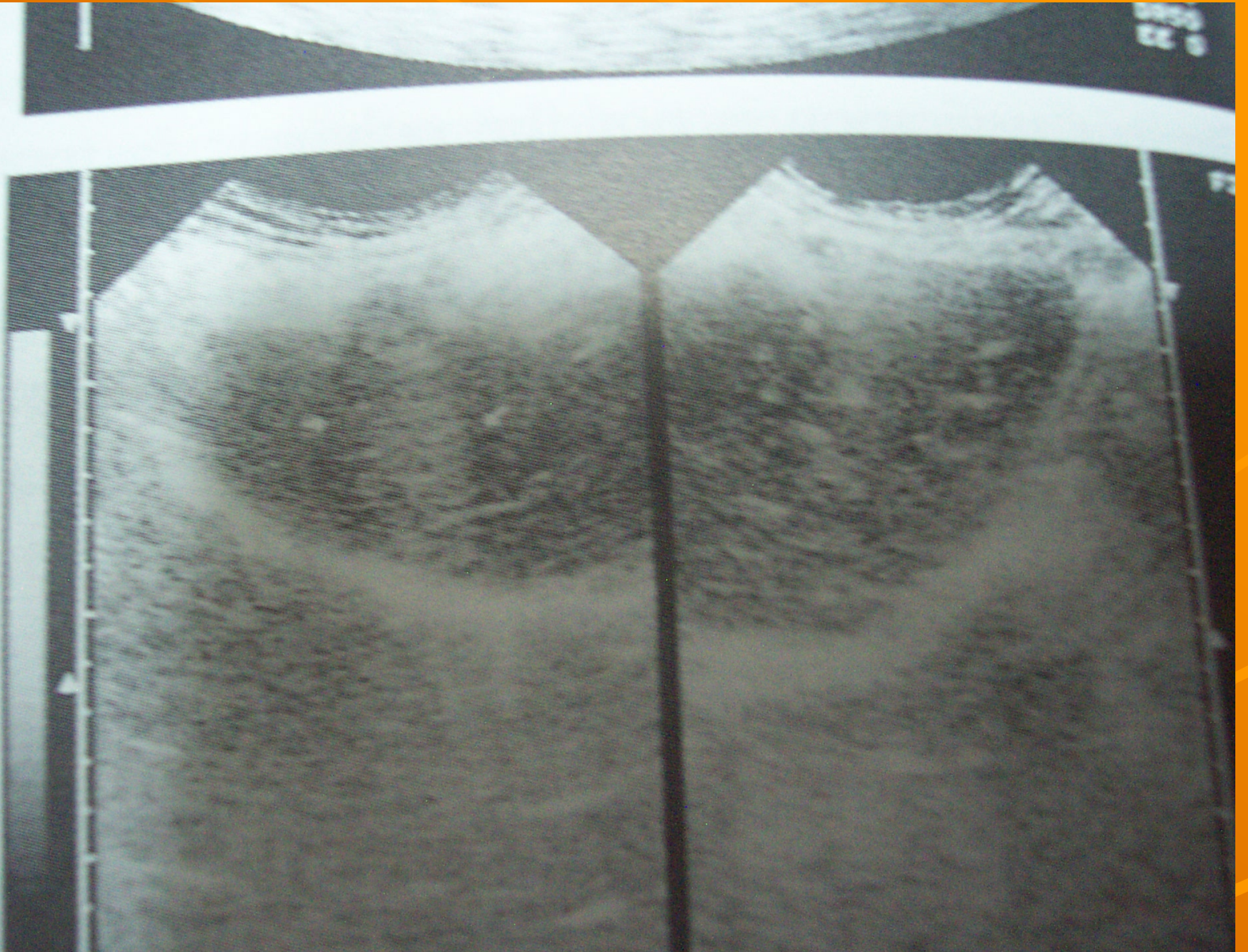
heterogenous



reflecting thick wall



(D)



Diagnosis-Imaging

◆ CT SCAN:

→ typical, good to diagnose hypodense lesions, locate cyst, size, number, presence of daughter cysts & signs of rupture, nearest vessel & duct

◆ MRI.

→ MRCP detects rupture of biliary tree

◆ ERCP.

→ diagnostic & therapeutic in communicating duct (inject sclerosing agent then empty content)

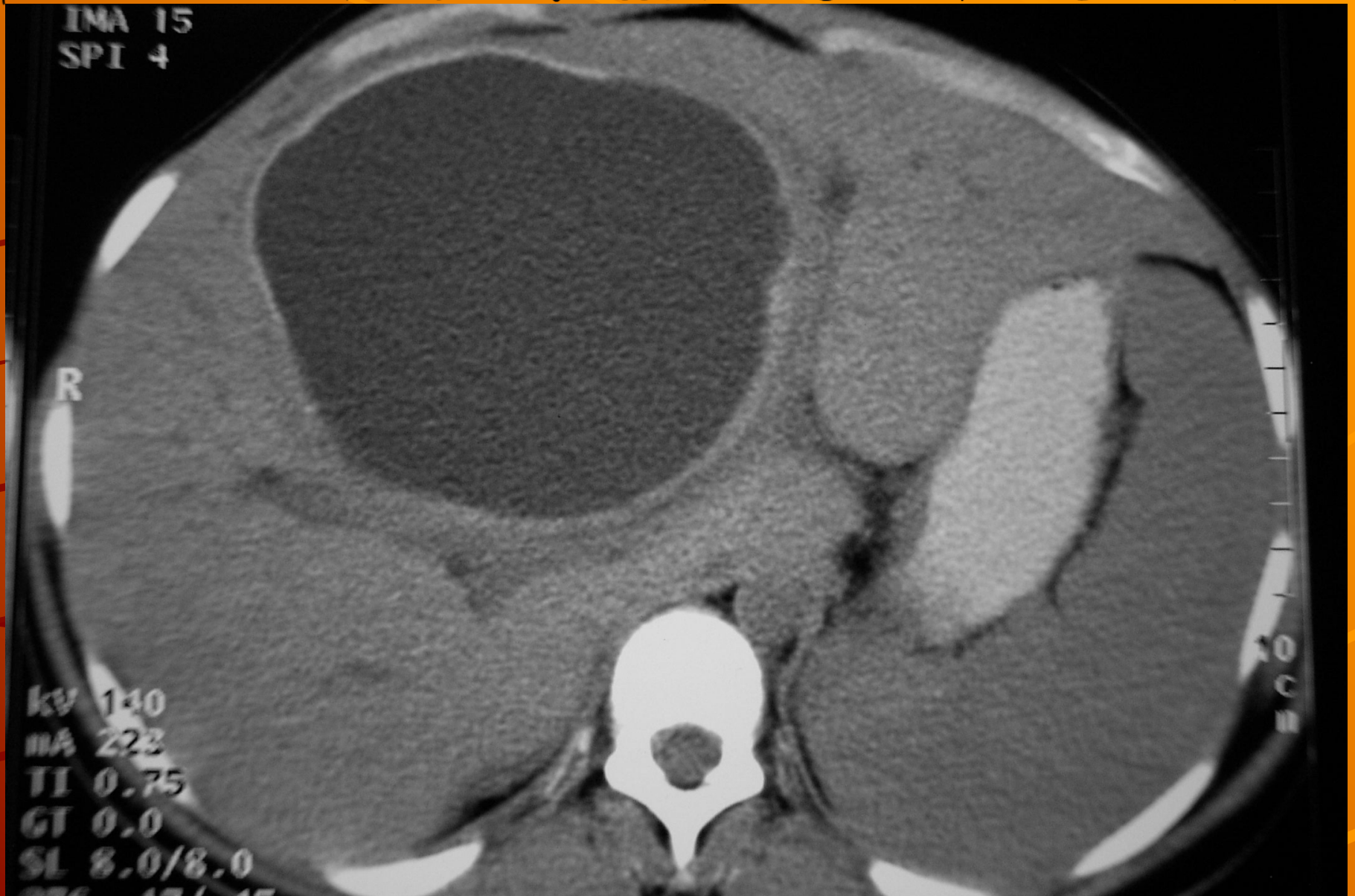◆ PTC.

◆ ANGIOGRAPHY.

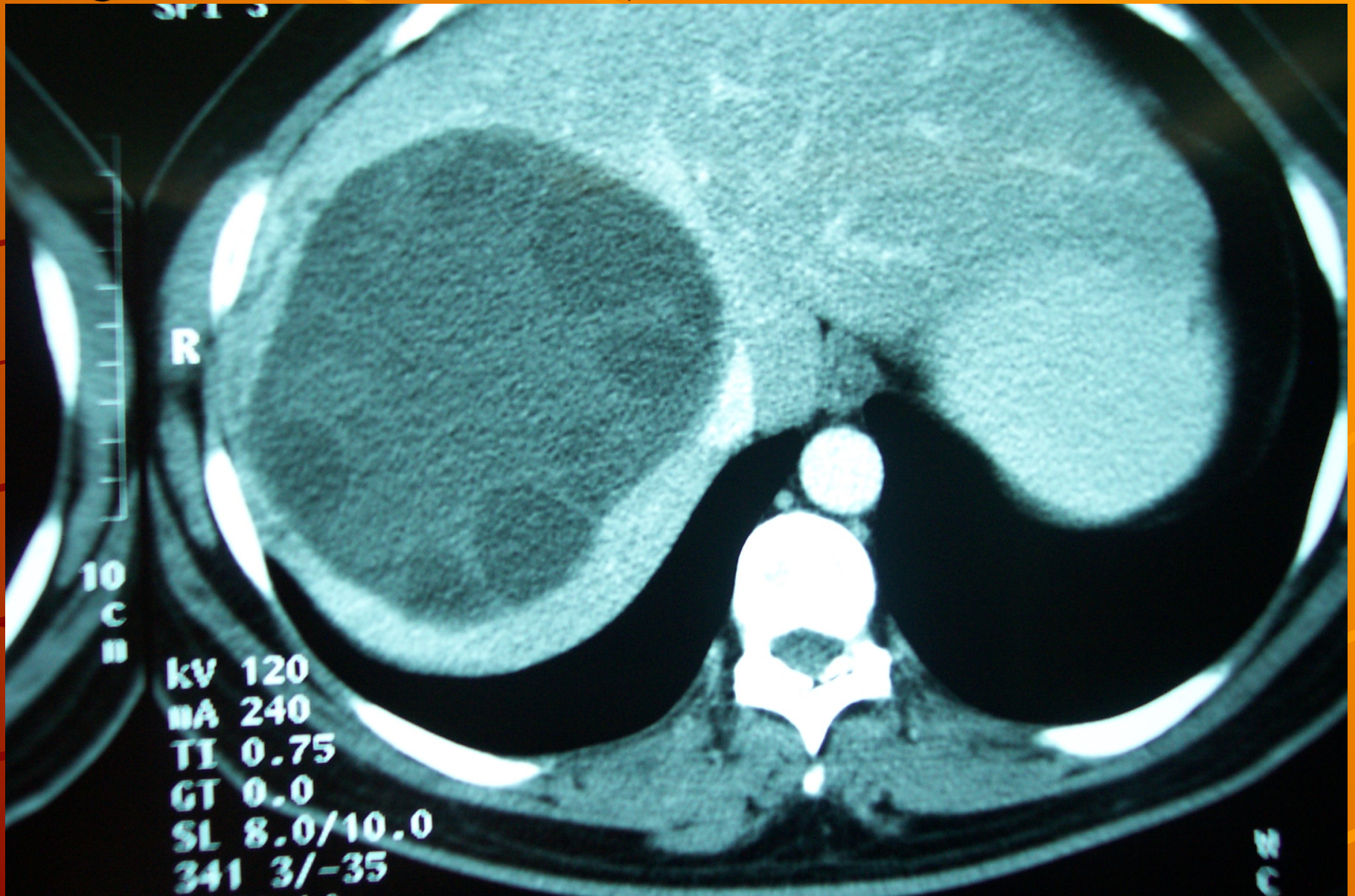→ Not used



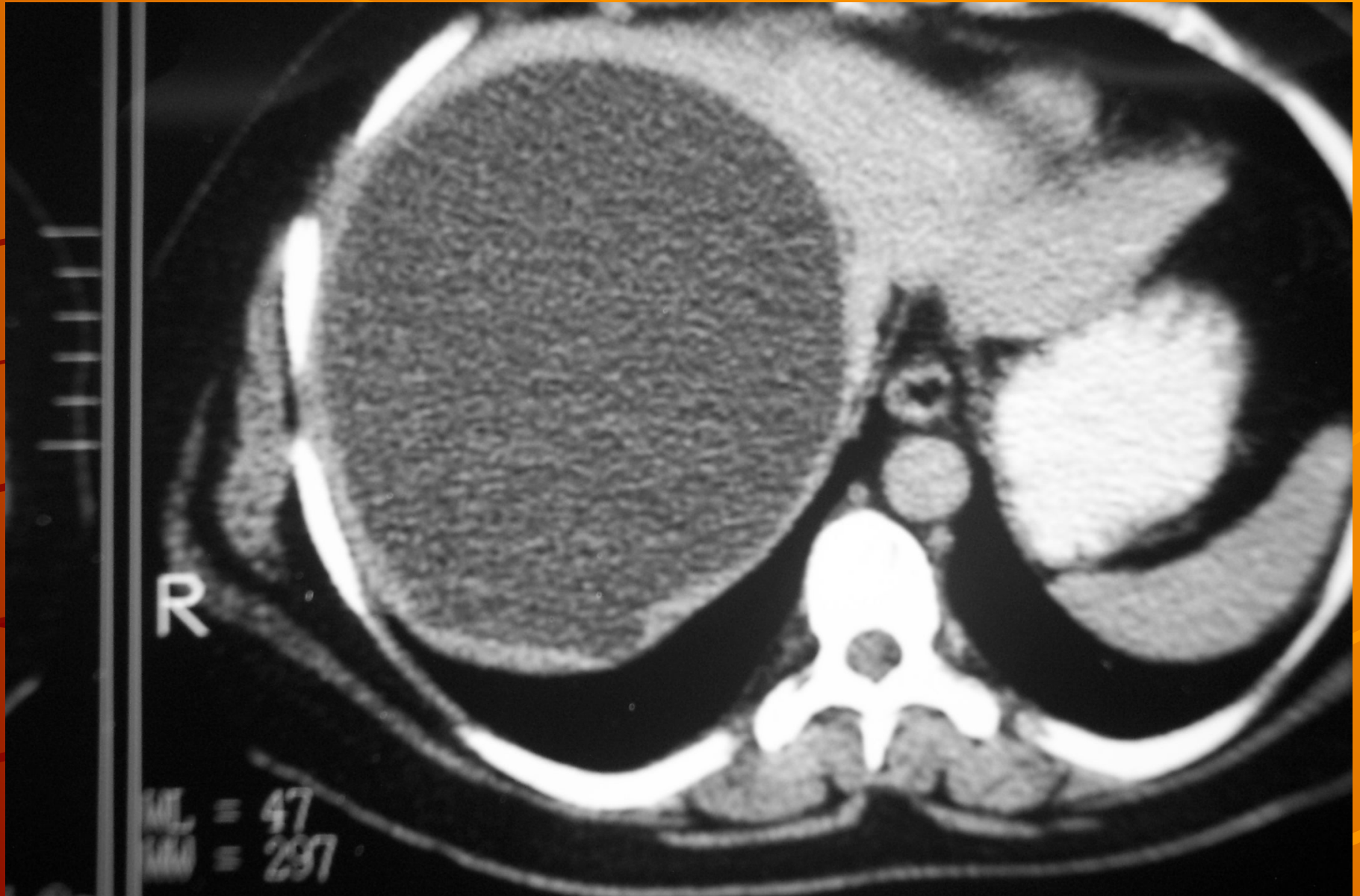
Simple cyst (unilocular, thick wall), Compressing portal vein causing portal HTN & esophageal varices / homogenous / daughter cyst



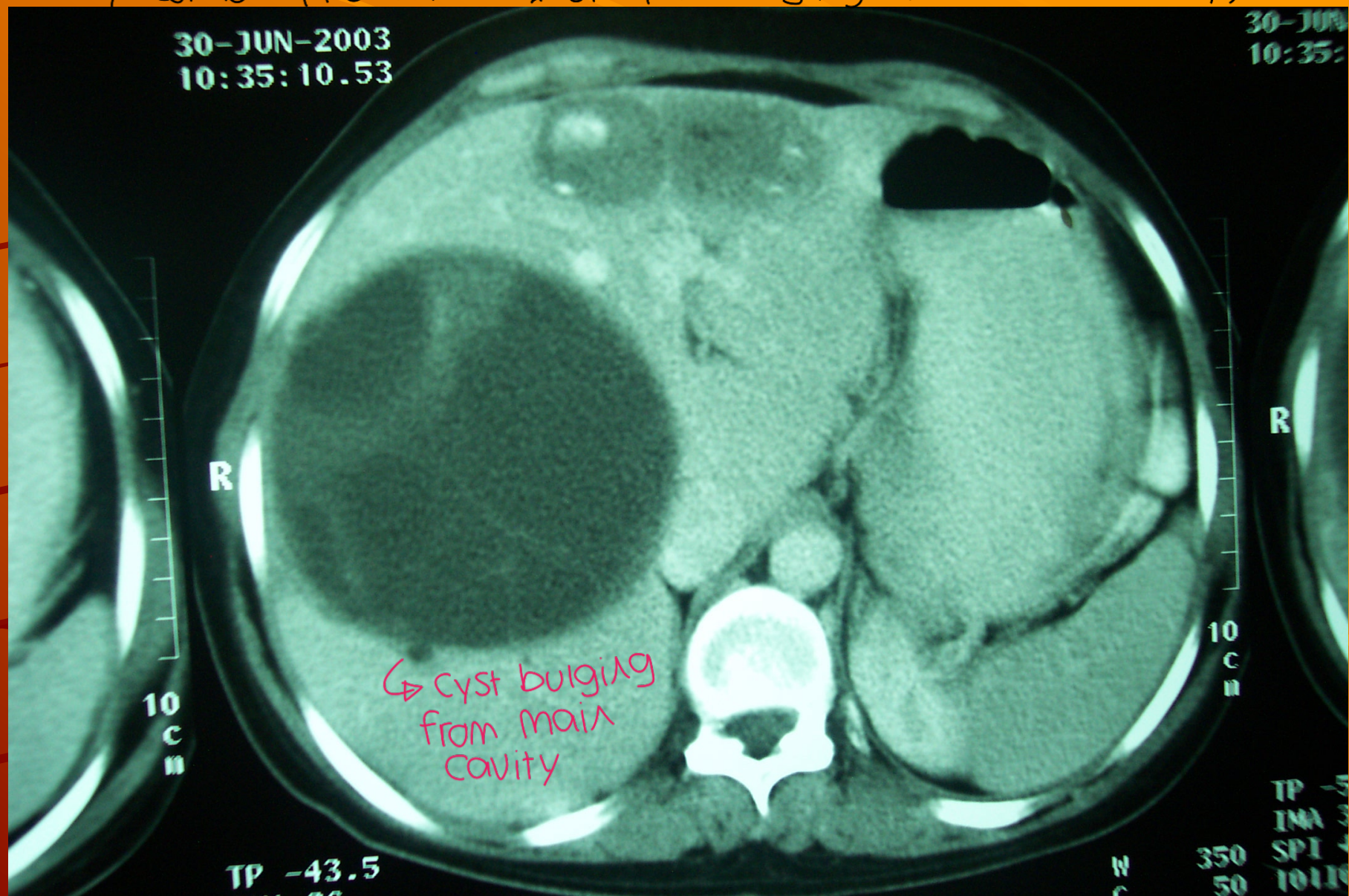
typical CT of hydatid cyst (big hypodense lesion with smaller daughter cysts (cog wheel appearance))



Simple Cyst occupying whole rt lobe



Multi hydatid cysts of liver with calcifications, septations, honey comb appearance & a cyst bulging from main cavity



DIAGNOSIS- IMMUNOLOGY

◆ IHA.

◆ CFT.

◆ LA.

◆ IEF.

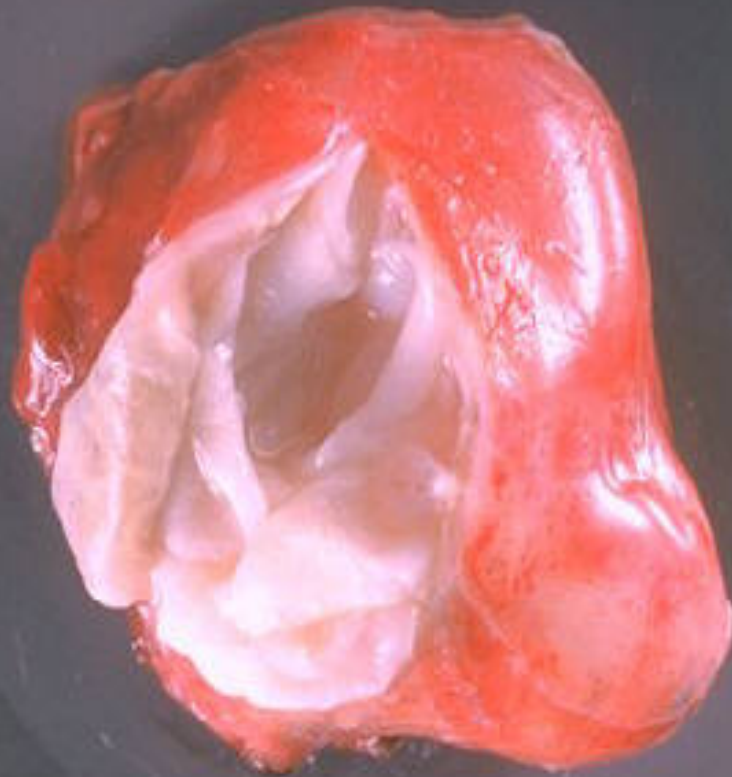
◆ CIE.

◆ ELISA.

We look for Serum antibodies
Against echinococcus granulosus

→ Negative test doesn't exclude presence
of hydatid cyst

hydatid cyst removed totally
from lung by inflating lung
so cyst comes out



Treatment of Hydatid Disease

Medical

Ideal: not yet completely efficient

Radiological

Selective

PAIRS

percutaneous aspiration
instillation reaspiration

(ideal for a deep cyst
> 2cm deep)

risk of spillage &
complications

SURGICAL

Attractive
Laparoscopic

Radical
conventional

better vision, deal w/
biliary fistulae, access



Medical treatment

- ◆ Antimony, Arsenic, Thymol derivatives, Iodides & Mercury.
 - ◆ Mebendazole. → antihelmintic
 - ◆ Albendazole: 10-14mg/kg/day, three 28 courses separated by 2 weeks rest.
 - ◆ Praziquantel. → antimalarial
- We can combine but this increases toxicity

Albendazole Tx of hydatid diasease

author	yr.	no.	duration (mo)	cure	'success'
Nahmias	'94	68	4	41	57
Horton	89	253	1-12	29	
Davis	89	46	1-3	--	39
DeRosa	90	46	3	9	--
Todorov	92	35	4	--	43

success = marked improvement

albendazole Tx of hydatid disease (Italy)

Franchi, CID, 1999;29:304-9

- ◆ n = 323 patients
- ◆ Tx: 440 liver, 57 abdom., 143 lung cysts
- ◆ albendazole 10 mg/kg/d x 3-6 mo.
- ◆ assessment: degeneration by CXR, U/S, CT, MRI q 6-12 mo.
- ◆ f/u: 2 yrs. (1-14 yrs)

Long-term evaluation of albendazole Tx of hydatid disease: results (Franchi)

- Post Tx degeneration in:
 - 82% liver, 67%, abd. 88% lung
- long-term: + 22%
- 25% relapsed
- 78% relapses occurred < 2 yrs

CID 1999;29:304-9

albendazole + praziquantel vs. alb. alone

Cobo et al. Trop Med Int H 1998;3:462-66

◆ **RT pre-op in Spain, x 1 month (no controls)**

◆ **groups: I (12) albendazole 10 mg/kg/d**

II (14) albendazole 10 mg/kg/d

III (21) alb. (10 mg/kg) + praz. 25 mg/kg

◆ **viability: supravital staining,**

Table 2. Cyst response to Albendazol (Adrien, MD)
World J. Surg. 25(1) 2001.

Data source	Evaluable cysts	Cure	Improved	No change	Worse
European data	435	160 (35.2%)	187 (41%)	102 (22.4%)	6 (1.3%)
Publication	2912	663 (22.8%)	1418 (48.7%)	831 (28.5%)	
Total	3347	823 (24.6%)	1605 (48%)	919	

Table1. Clinical response to Albendazol(Adrien G.Saimot MD)

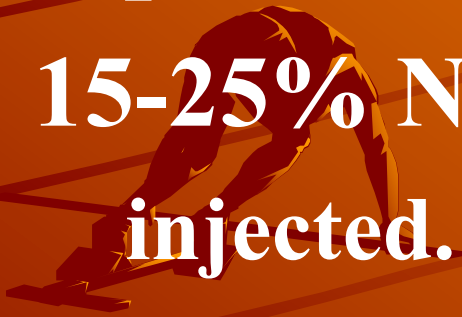World J.Surg.25(1)2001

Data source	No of patients	Cured	Improv ed	No change	Worse
European data	253	72(28.5%)	129(51%)	46(18%)	6(2.4%)
publication	1116	372(33.5%)	469(42%)	275(24.6%)	
Total	1369	444(32.4%)	598(43.7%)	327(23.9%)	

Techniques used for PAIR

1. Percutaneous puncture: + aspiration & injection

- 18 g Seldinger needle
- aspirate 25-35% est. volume
- 15-25% NaCl = ~10% aspirated vol.
injected. (kill in 5 min,)
- wait (10 min.) for pericyst separation
- reaspirate



Techniques used for PAIR

2. Catheterization: leave it for 24 hrs to empty content then inject Sclerocidal Agent

- as above
- 6F catheter inserted
- wash out with hypertonic saline
- drain x 24 hrs. (<10 cc/24 hr = no bile connection)
- cystogram
- 95% alcohol (25-35% vol.)
- reaspirate & withdraw catheter

Percutaneous (PAIR) Tx of liver cysts

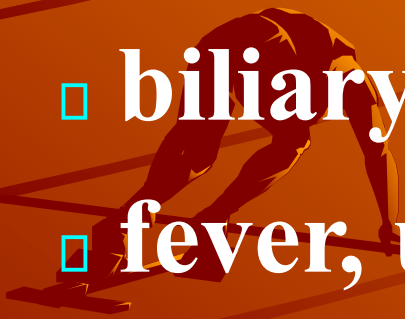Akhan, Eur J Radiol 1999;32:76-85

1. Hydatid liver disease: 14 studies

- 13 studies (641 cysts) 1 Chinese study (996 cysts)
- 1,637 cysts in 1,000 pts
- instillation of alcohol or hypertonic saline
- f/u 1-3 years (1 yr)


1. Liver hydatid disease: results

- cure or significant change: 90-100%
- recurrence 0 - 4%
- complications: ~ 10%
 - ▣ biliary fistula: ~ 5-10% (7 studies)
 - ▣ fever, urticaria: 10-20%
 - ▣ cyst cavity infection: ~ 3%
 - ▣ death: 0.1 - 0.2%



PAIR: In a literature review


Table3: review of recent experience(1994-1998).(Iskende Sayek)



Finding	Surgically treated	Percutaneously drained
Total	46(37%)	79(63%)
Solitary cysts	29	55
Types	III-V:34(74%)	I-III:65(82%)
Complications:	2	11
Minor		
Complications:	6	9
Major		
Cavity infection	5	8

Table 3.....

continue



Finding	Surgically treated	Percutaneously drained
Biliary drainage	1	1
Wound infection	2	-
Patients requiring surgery	-	2

Laparoscopic

- ◆ Minimal invasive.
- ◆ Stands in the midway between PAIR&conventional surgery.
- ◆ Risk of spillage. → decrease risk by Sterilizing Cyst by medical treatment before Surgery or put a gauze (w/ w/ w) w/ Sclerosant Agent around Cyst before removing it
- ◆ Radicality?
- ◆ No enough randomized studies to come up with a conclusion.

Types of surgery

◆ Marsupialization. (old technique, suture edges of cyst to skin)

◆ Cystectomy plus.

- Pericystectomy- partial ↪ resect apparent part → empty → deal w/ residual

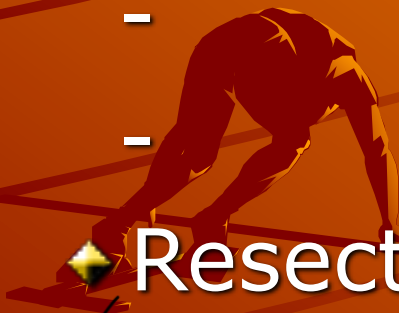- Pericystectomy- subtotal.

- Pericystectomy- Total. ↪

◆ Resection: segmental, lobar, total+transplantation.

can cause bleeding, fistulization, biliary tree injury, difficult for multi cysts

↪ not preferred since it's a benign disease (get rid of parasite & liver will be normal)



Remaining cavity

↳ accumulation of blood & bile in it leads to infxn & abscess or deep suppuration so we need to deal w/ remaining cavity

◆ Primary closure. not used

◆ Simple drainage.

◆ Capitonage. (ligating walls)

◆ Introfexion. (suturing edges inside (not used))

◆ Omentoplasty.

↳ Fill it w/ omentum (most significant & used)

* internal drainage (suture cavity to small bowel or stomach to drain it there) → maximizes surgery without a different outcome



Ahmet et al in a study of 304 cases concluded that: "For management of hydatid cyst of the liver . Capitonnage , omentoplasty, cyst excision, cystenterostomy are all superior to tube drainage."

Source: *Arch.Surg.vol 134 Feb.1999.*

N.B:However 35/122 patients with tube drainage had infected cysts.



Cysto-Biliary Cmmunication: 171cases Milicevic

- ◆ Suture 115
67.25%
- ◆ Suture+T-tube 15
8.77%
- ◆ T tube only 16
9.34%
- ◆ Roux-en-y jej. 4
2.34%
- ◆ Intracavitary reconstruction 2
1.17%

Post-operative complications

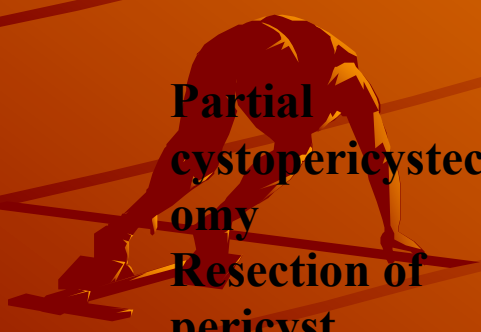
◆ Wound infection 13.5%	111
◆ Chest problems 5.14%	42
◆ Subphrenic abscess 5.26%	43
◆ Biliary leakage 4.89%	40
◆ Liver abscess 2.45%	20

Results of surgical treatment


- ◆ Def. of recurrence: controversy.
- ◆ Amir Jahed 1975: 0.9%
- ◆ Dugalic 1982: 1.7%
- ◆ Pitt 1986: 10%
- ◆ Magistrelli 1991: 10.8%
- ◆ Little 1988 : 22%

Table 4. Postoperative morbidity & mortality in a series of 298 patients. (Anaceleto Cirenei, MD, Innocenzo Bertoldi MD)

Treatment	No.	Morbidity	Mortality
Conservative methods	134	12(12.6%)*	8(5.9%)**
Marsupialization	20	8(40%)	6(30%)
Partial cystopericystectomy	114	9(7.9%)	2(1.7%)
Resection of pericyst & subtotal pericystectomy	85	6(7.1%)	2(2.3%)
By peeling the pericystium	29	3(10.3%)	--



**Table4. Continue
World J.Surg25(1) 2001.**



Treatment	No	Morbidity	Mortality
Radical methods	164	9(5.5%)	3(1.8%)
Total pericystectomy	132	5(3.7%)	3(2.2%)
Liver resection	32	4(12.5%)	--
Total	298	26(8.7%)	11(3.6%)

**P* $<$ 0.05,
P**=NS.**

**hydatid cyst of the liver with a large biliocystic fistula.(Abeljelil Zaouche et al)
World J.Surg 25 (1)2001.**

Procedure	No
Radical treatment	24(9.8%)
<i>Left lobectomy</i>	7
<i>Pericystectomy</i>	17
Conservative treatment	220(90.2%)
<i>Internal transfistulary drainage</i>	52
<i>Deroofing procedure</i>	140

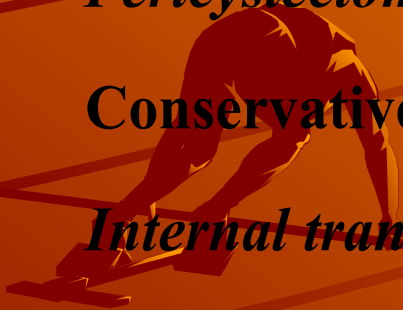

Table 5.....continue

Procedure	No
<i>Respected fistula</i>	20
External drainage	10
<i>External drainage +omentoplasty</i>	8
<i>External drainage +capitonnage</i>	2
<i>Sutured fistula</i>	93
<i>External drainage</i>	49

Table 5. continue

Procedure	No
<i>External drainage+omentoplasty</i>	28
<i>External drainage +capitonnage</i>	16
Direct fistulization	27
Transcholedochal evacuation	28

Personal experience(1993-2000)

- ◆ Number of cases: 82
- ◆ males: 36(43.9%), Females:46(56.1%).
- ◆ **Anatomical distribution:**
- ◆ RT lobe: 35 (42.6%).
- ◆ LT lobe: 23 (28%).
- ◆ Both lobes: 22 (26.8%).
- ◆ Central : 2 (2.4%).
- ◆ Involvement of other organs: (12.1%).
- ◆ Associated pathology: Pregnancy(2), Cirrhosis(2).

Technique

Standard surgical principles were applied:

- ◆ Complete isolation of the operative field.
- ◆ Two powerful suctions.
- ◆ Aspiration- Suction(after stopping breathing)infusion-Reaspiration.
- ◆ Opening of the cyst, evacuation & Irrigation-suction.(scolicidal agent).
- ◆ Unfoldindg of the pericyst.
- ◆ Mobbing of the cavity.
- ◆ Dealing with cystobiliary communication if present.
- ◆ *Abdominal approach was exclusively used.Scolicidal agent:Sterimide0.5%-1%.*

Surgical procedures Adopted

- ◆ The procedure of choice was: Cystectomy+(partial/subtotal) pericystectomy+ Drainage of the remaining cavity: 69 cases(84.1%).
- ◆ Other procedure, Capitonage, Omentoplasty, Hepatectomy, Exploration of CBD, Transduodenal sphincteroplasty&total pericystectomy.
- ◆ Cholecystectomy performed in 22 patients(26.8%).

Management of cysto-Biliary Communication:32/82(39%)

- ◆ **Simple fistula 22/32:** Respected+drainage, Cannulation with small tubes,Draining the cavity, direct suturing of the fistula.
- ◆ **Frank Rupture 10/32:** Daughter cyst in CBD 8/10, Preoperative **EPST**+intraoperative trans duodenal sphincteroplasty+ T-tube drainage of CBD. 5/10 , Internal transfistulary drainage of CBD+Postoperative **EPST**. 3/10.
- ◆ **Fistula > 5mm** - Internal transfistulary drainage. 2/10 . **Noticeably:** In the same patient- Multiple cysts tend to have communication with the biliary tree, regardless to their number or size.

Results

- ◆ **Operative Mortality:**
0/82
- ◆ **Mortality rate:**
2/82 (2.4%) multiple infected cyst(1), biliary peritonitis(1)
- ◆ **Infection of the remaining 8 cavity:**
7/82(8.5%)
- ◆ **Persistent bile leakage through the drain:**
3/82(3.6%)
- ◆ **Encysted bile collection:**
1/82
- ◆ **Simple liver cyst:**
1/82

Follow-up

- ◆ **Clinically : OPD.**
- ◆ **Radiological : U/S, CT Scan.** to make sure there is no recurrence
- ◆ **Serological: ELISA, IHA.**
echinococcus titer
may persist for months



CONCLUSION

- ◆ **Treatment of liver hydatid cyst is not as simple as just draining a cysts.**
- ◆ **Calcified cysts(partially/Totally)should be approached very carefully.**
- ◆ **Central cysts(portahepatis) with biliary involvement more difficult to deal with.**
- ◆ **With more experience in liver & biliary surgery it's easier to deal with complicated hydatid cyst.**
- ◆ **Treatment of Hydatid cyst of the liver should be a multidisciplinary approach.**
(surgeon,gastroenterologist,radiologist,parasitologist,immunologist)