

Soft tissue coverage

Samir Jabaiti, MD, FRCS(Edin.)

**Consultant and Associate Professor of Plastic
Surgery
School of Medicine
University of Jordan**

Plastic surgery is divided into:

- **Aesthetic surgery:** deals with improving the beauty of clients!

- **Reconstructive surgery:** deals with return of lost tissues and repair of congenital and acquired defects.

→ skin, subcutaneous tissue, fascia and muscles

- In our course we deal with basic principles of reconstructive surgery.

تحويل
الأنسجة
للصحة

Soft tissues that are dealt with by the reconstructive surgeon are:

- Skin
- Subcutaneous tissues,
- Fascia
- Muscles.

Wounds: discontinuity of epithelium.

- Due to trauma or to pathological causes (ulcers).
- They may be partial thickness (involving the epidermis and part of the dermis) or full thickness (involving the epidermis and the whole dermis).
- Partial thickness wounds heal usually by regeneration (as second degree burns) they are treated conservatively.
- Full thickness Wounds (tissue loss or defects as called by plastic surgeons) they vary from simple as incised skin wound or to complex wounds which results from major loss of many tissues as that resulting from excision of malignant tumors.

Causes of soft tissue defects that are dealt with by plastic surgeon

CONGENITAL:

Cleft lip and palate, hypospadias, microtia and anopia, syndactyly, vascular anomalies, and other soft tissue congenital anomalies.

AQUIRED:

- Inflammatory: defects that follow soft tissue infections as abscesses, necrotizing fasciitis.
- Neoplastic: resulting from tumors as following mastectomy and skin and soft tissue cancers.
- Metabolic: as in diabetic foot.
- Ischemic: following peripheral vascular diseases and pressure sores.
- Traumatic: that follows burns, frost bites, radiation injury and soft tissue injury.
- Iatrogenic: as in extravasation injury.

*Saga of the plastic surgery

Causes of S.T.D

- ① - Congenital → cleft lip for example
- ② - Aquired →
 - ⊖ Inflammatory
 - ⊖ Neoplastic
 - ⊖ Metabolic
 - ⊖ Ischemic
 - ⊖ Traumatic
 - ⊖ Iatrogenic

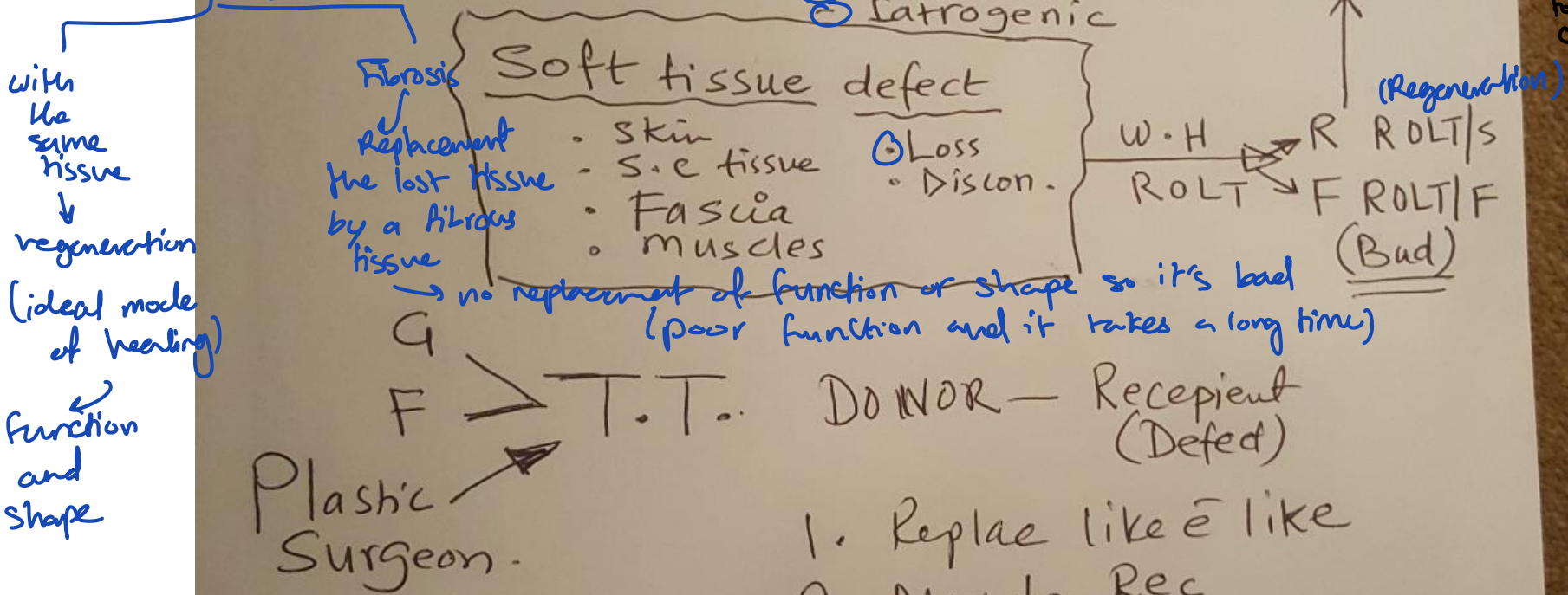
*Any defect → healing, this is called wound healing (replacement of lost tissues)

in Human
only certain tissues can regenerate

- Epith
- Hepatocytes
- Bone

not the total liver because it's made from hepatocytes and CT

(healing by fibrosis for liver means cirrhosis and it leads to death)



*Skin is made of epidermis and dermis

epithelium and it is replaced by regeneration

it's not epithelium so it heals by fibrosis

1. Replae like ē like
2. Max-to Rec
3. Min. harm to Donor
4. Safe.

*Regeneration & ...

* For plastic surgeons any area that healed or would heal by fibrosis → we do tissue transfer

SOFT TISSUE DEFECTS

* We take part of the patient's tissue from an area called donor area

What are the soft tissues?

1. Skin. 2. Sub. cutan. Tissues. 3. Fascia. .Muscle

Causes of STD

- CONGENITAL
- ACQUIRED:

Inflammatory, Neoplastic, Metabolic, Ischemic, Traumatic, Iatrogenic.

❖ STD heal (wound healing) by replacement of lost tissues (ROLT):

There are two modes of wound healing:

1. REGENERATION: ROLT by the same lost tissues.

The ideal mode: ideal return of function and shape.

2. FIBROSIS: ROLT by fibrous tissues.

Bad healing: No return of function, bad shape, takes long time.

- In human: Reg. is limited to (epith., hepatocytes, bone).
- 1. To avoid the negative results of fibrosis, PLASTIC SURGEON covers the defect by tissues donated from the body (DONOR).
- This is called tissue transfer (skin grafts and flaps).

Criteria of good tissue transfer:

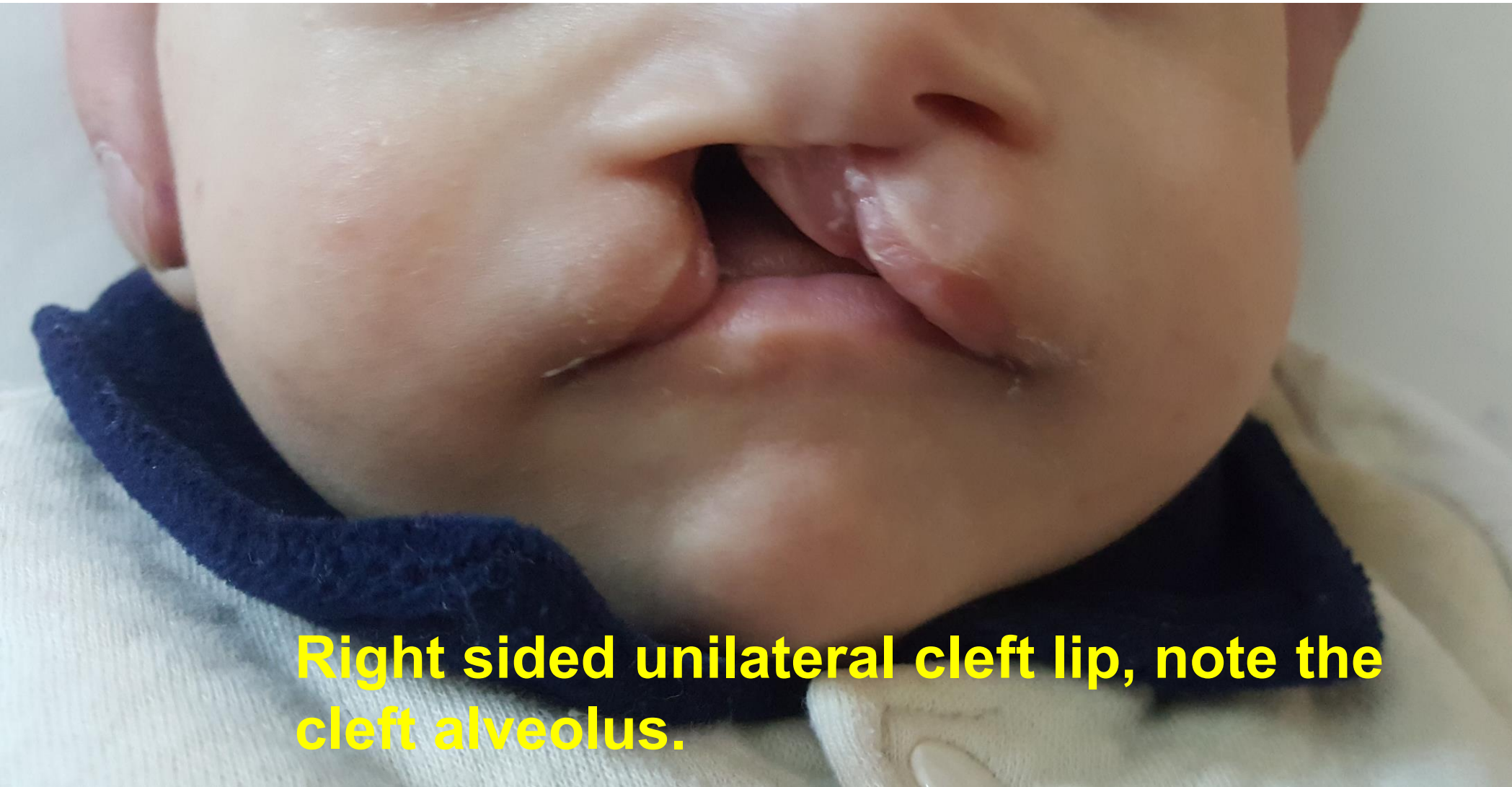- ☒ Like with like
- ☒ Max. benefit to recipient.
- ☒ Min. harm to donor
- ☒ Safe

forms granulation tissue with time it becomes fibrous tissue

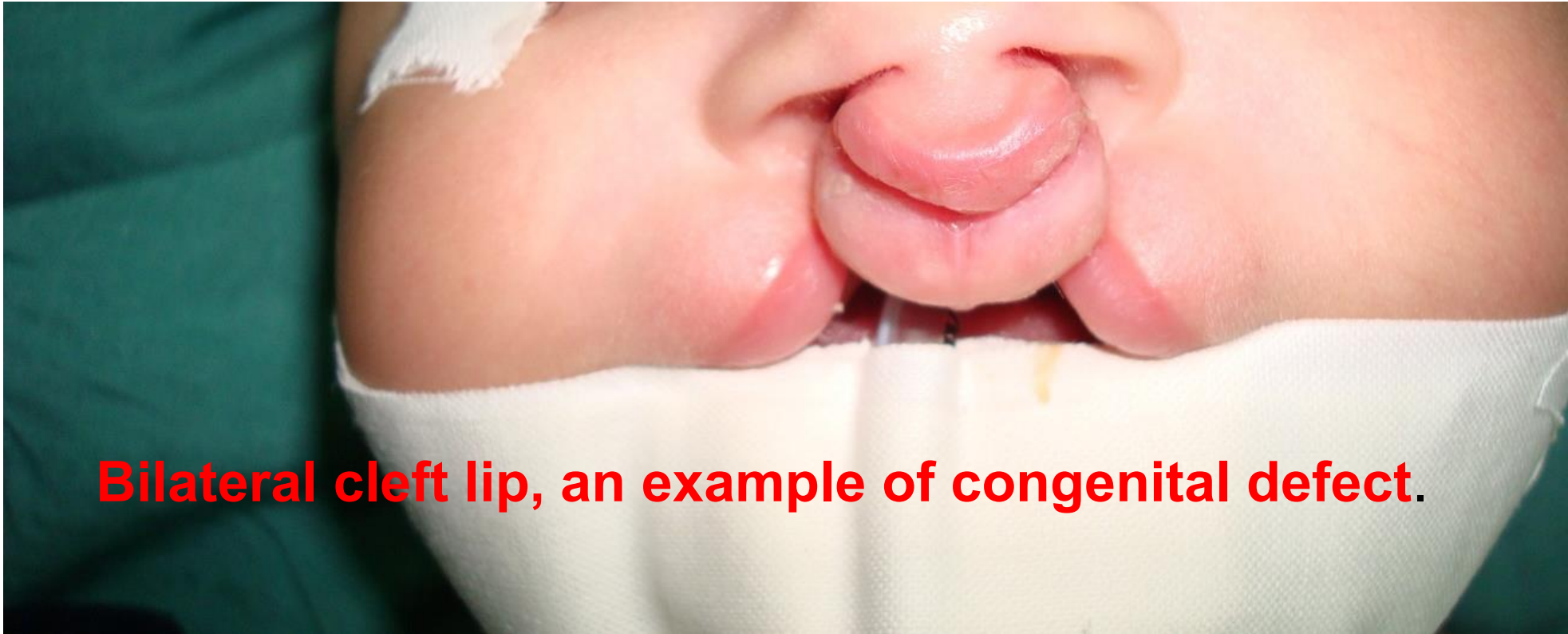* The process of fibrosis is made up of 2 stages:

① Fibroplasia: multiplication of fibroblasts from adjacent tissue → migration → producing collagen

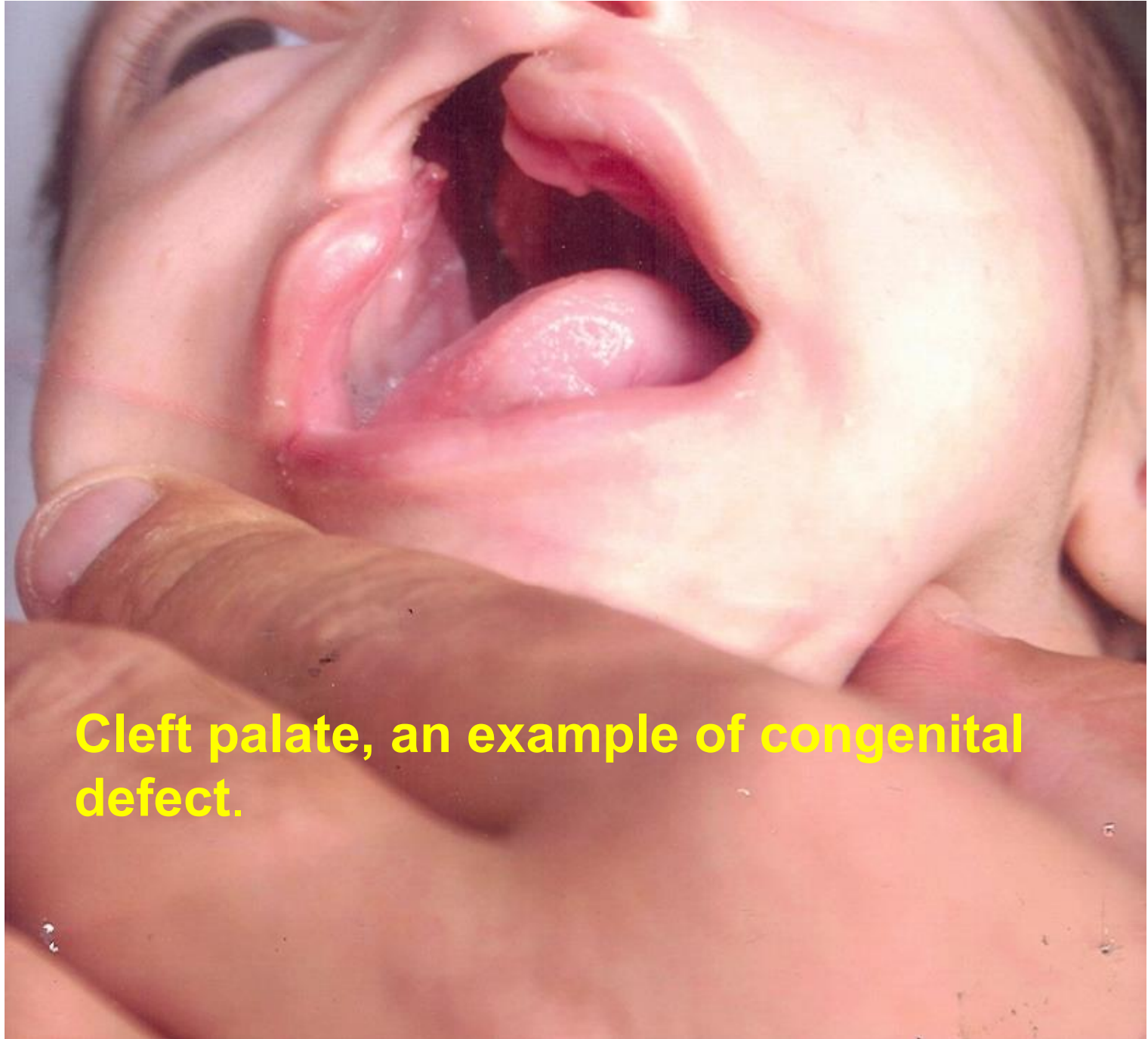② Angiogenesis → formation of the blood vessels



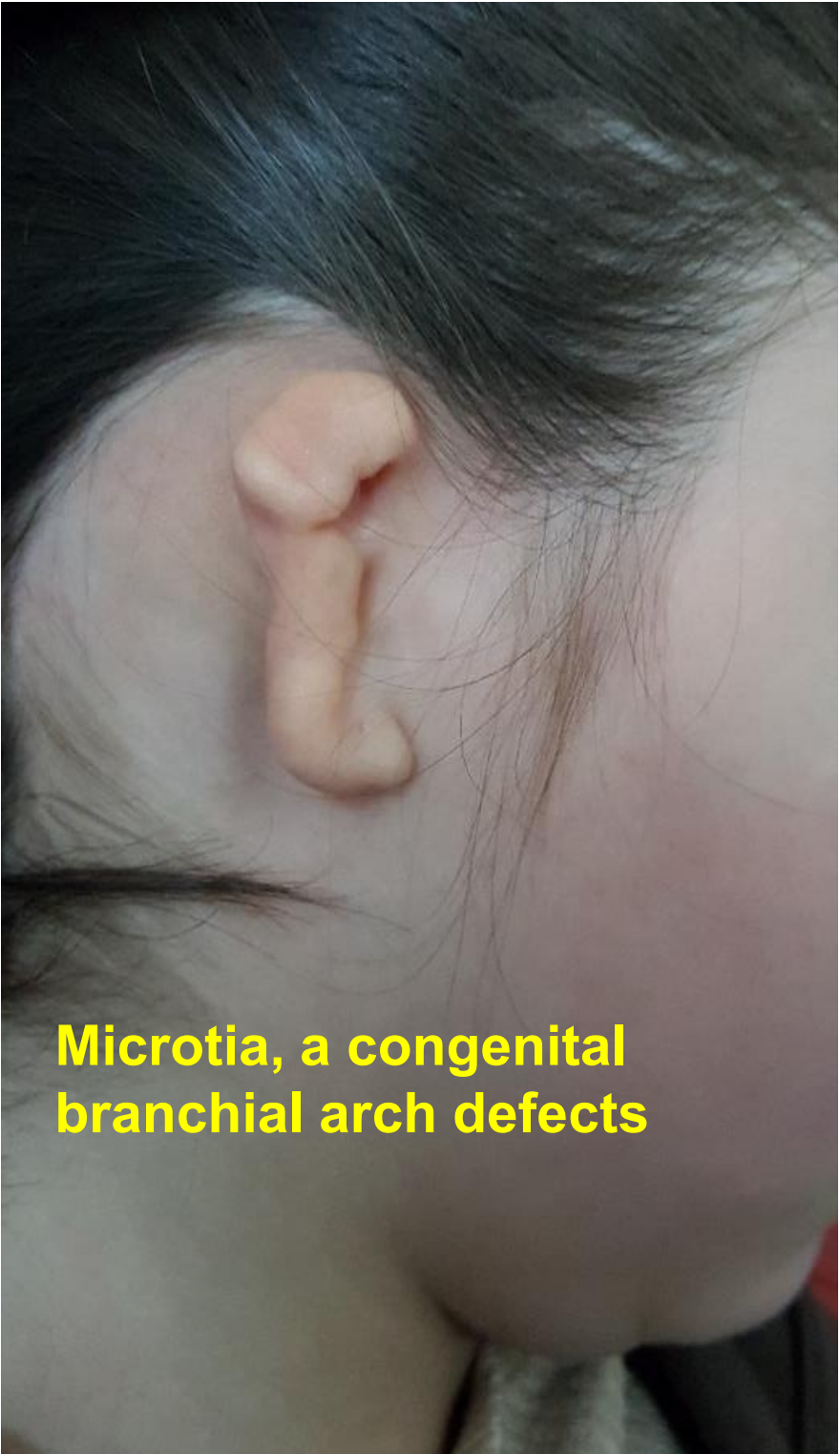Right sided unilateral cleft lip, note the cleft alveolus.



Bilateral cleft lip, an example of congenital defect.

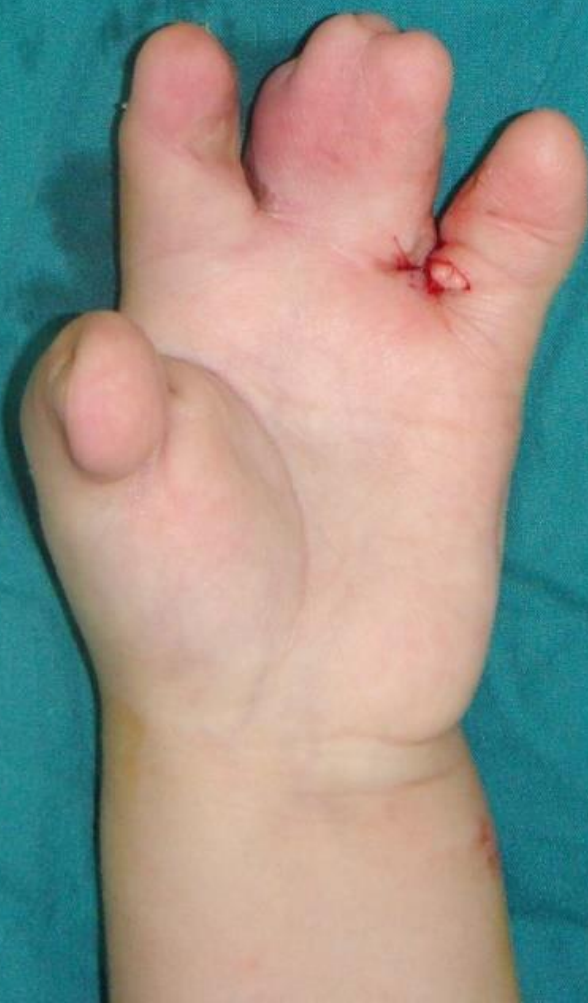

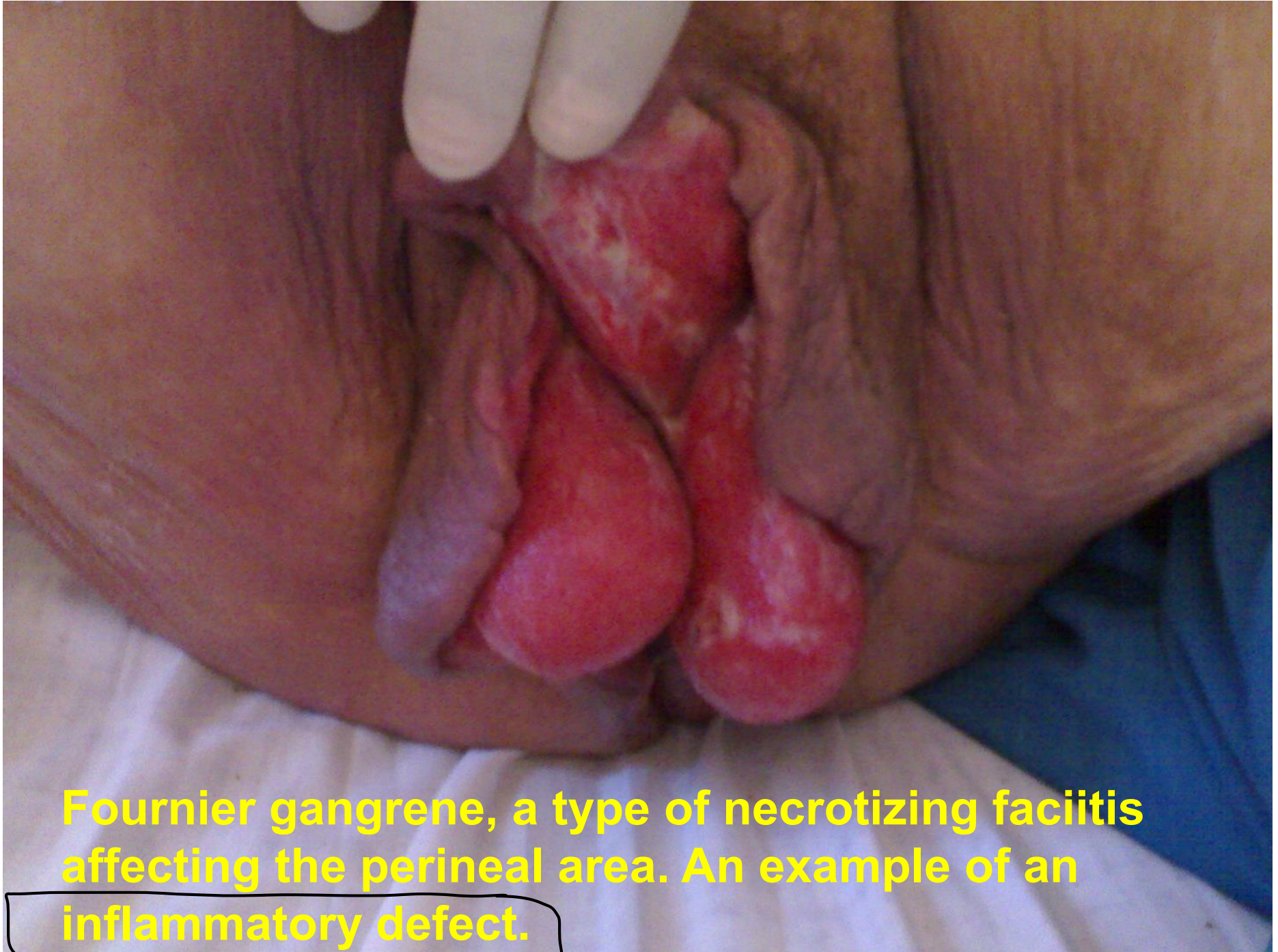Cleft palate, an example of congenital defect.



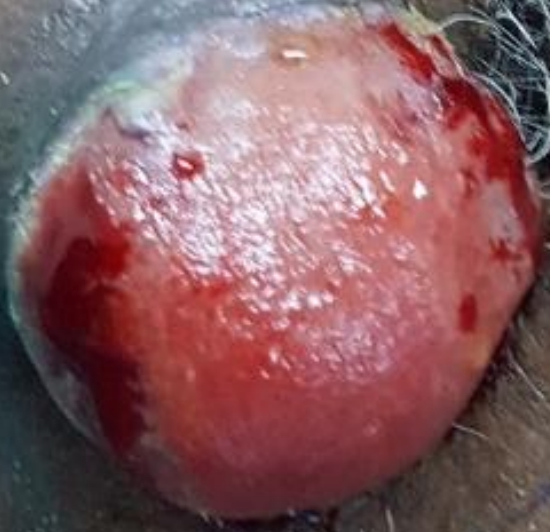**Microtia, a congenital
branchial arch defects**

Congenital hand defect

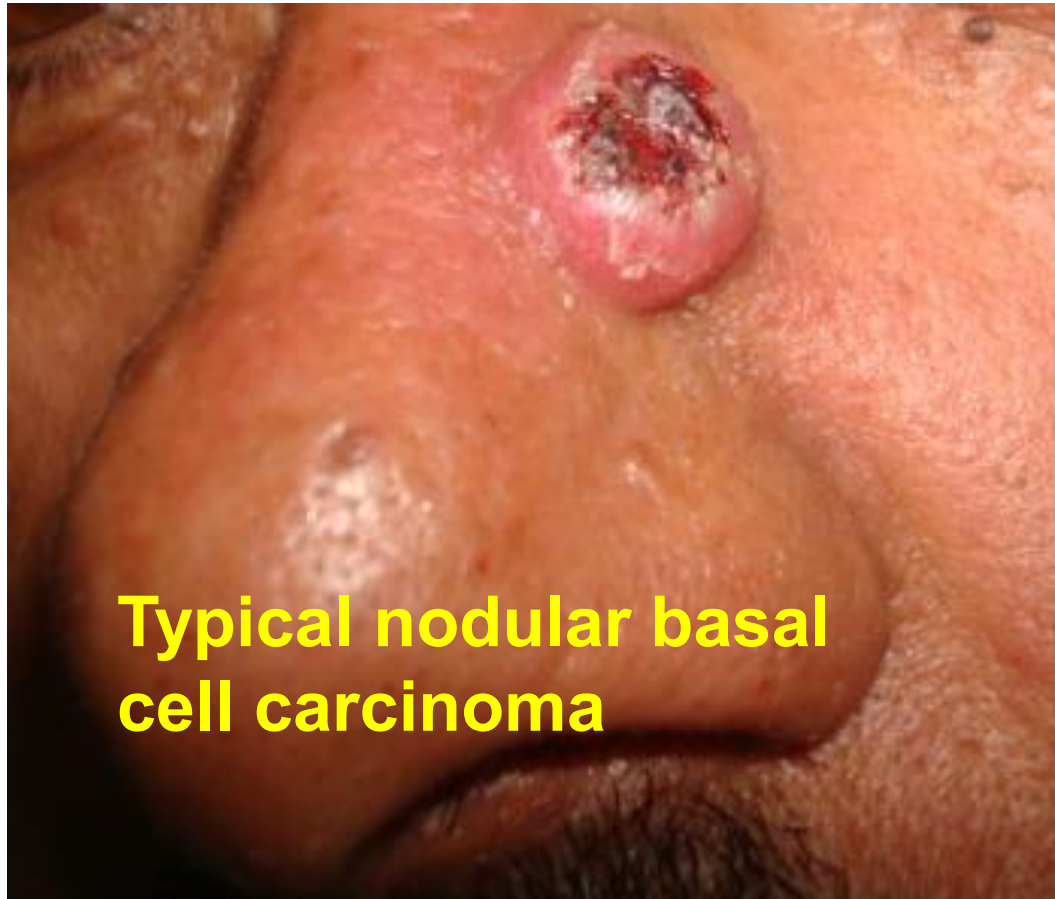



Fournier gangrene, a type of necrotizing fasciitis affecting the perineal area. An example of an inflammatory defect.



**Facial squamous cell carcinoma,
An example of a neoplastic defect**

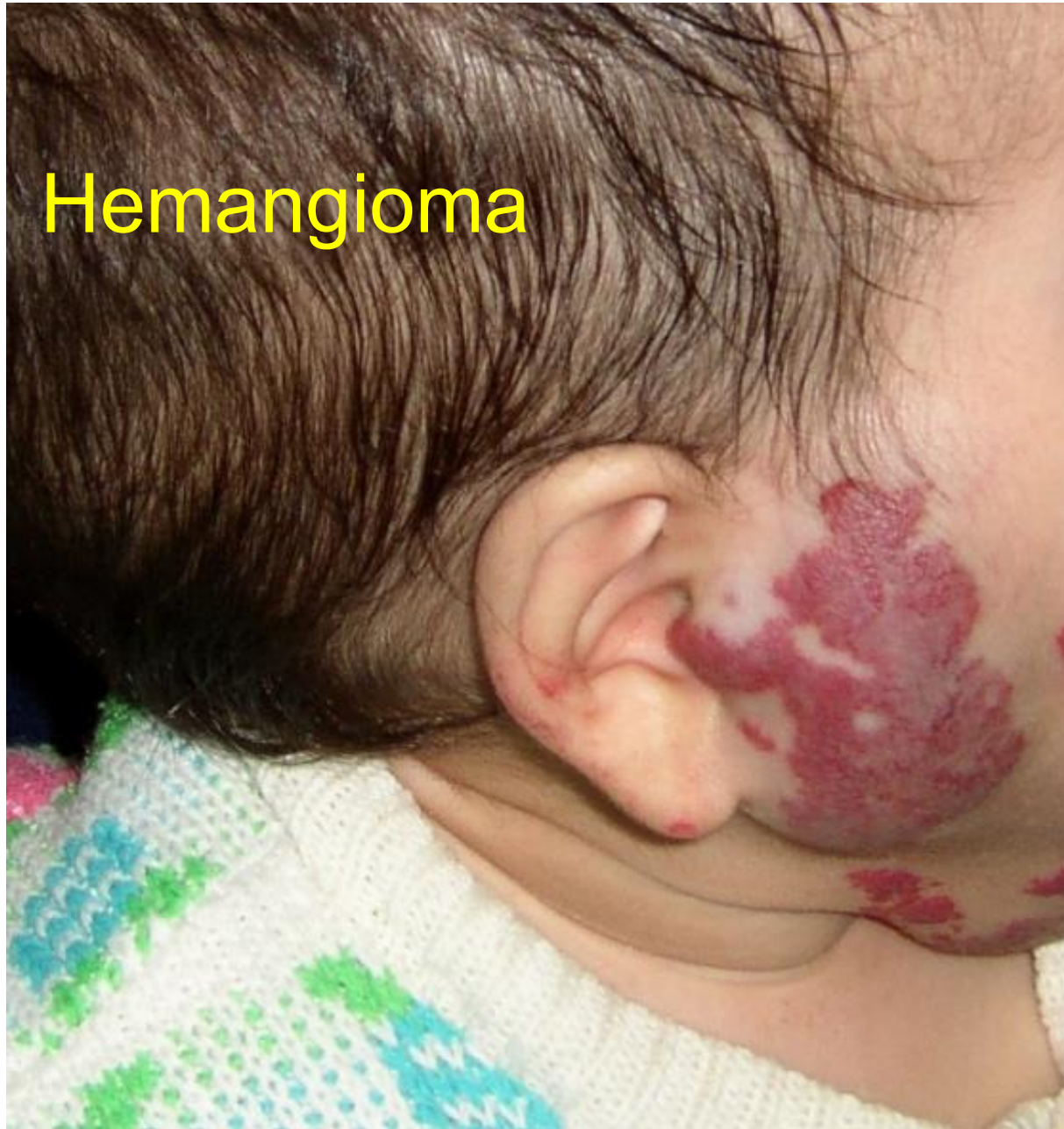

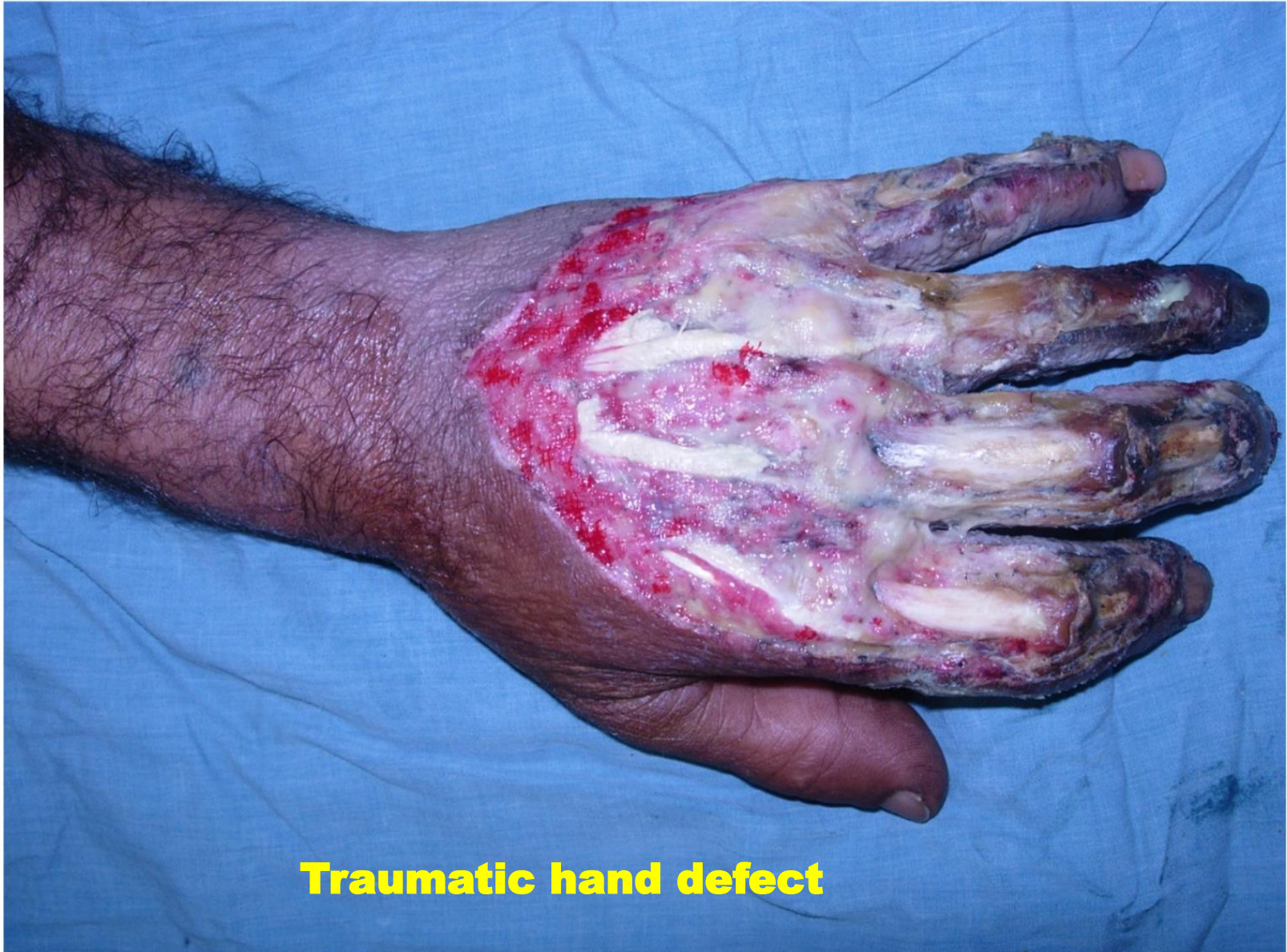**Typical nodular basal
cell carcinoma**

A photograph of a person's lower leg and ankle, showing a large, circular, chronic venous ulcer. The ulcer is characterized by a central area of bright red, moist, and granular tissue, surrounded by a thick, yellowish-white crust. The surrounding skin is discolored, appearing brownish and mottled, with some areas of discoloration extending up the calf. The leg is positioned against a white, wrinkled fabric background.

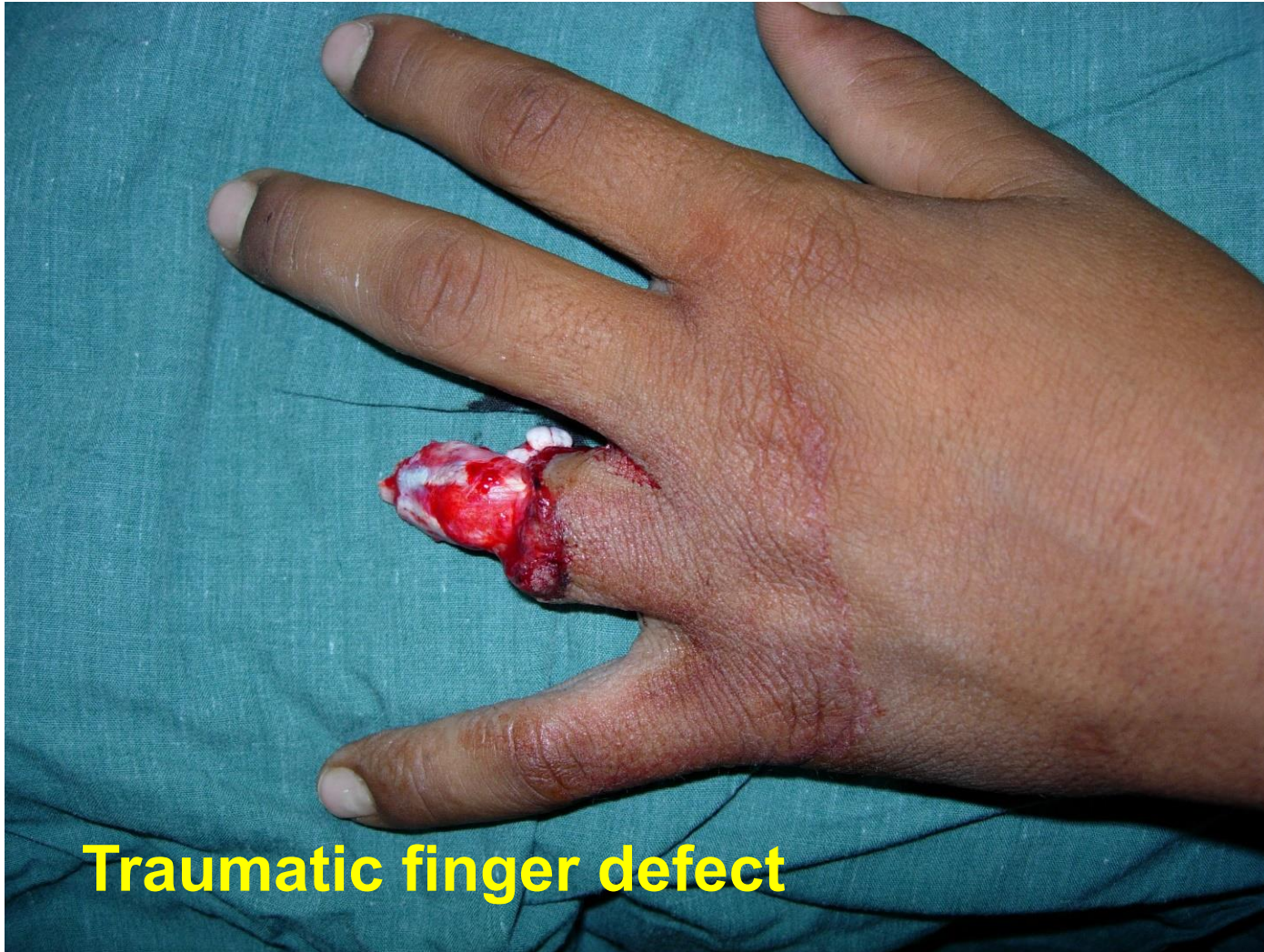Chronic venous ulcer

Hemangioma

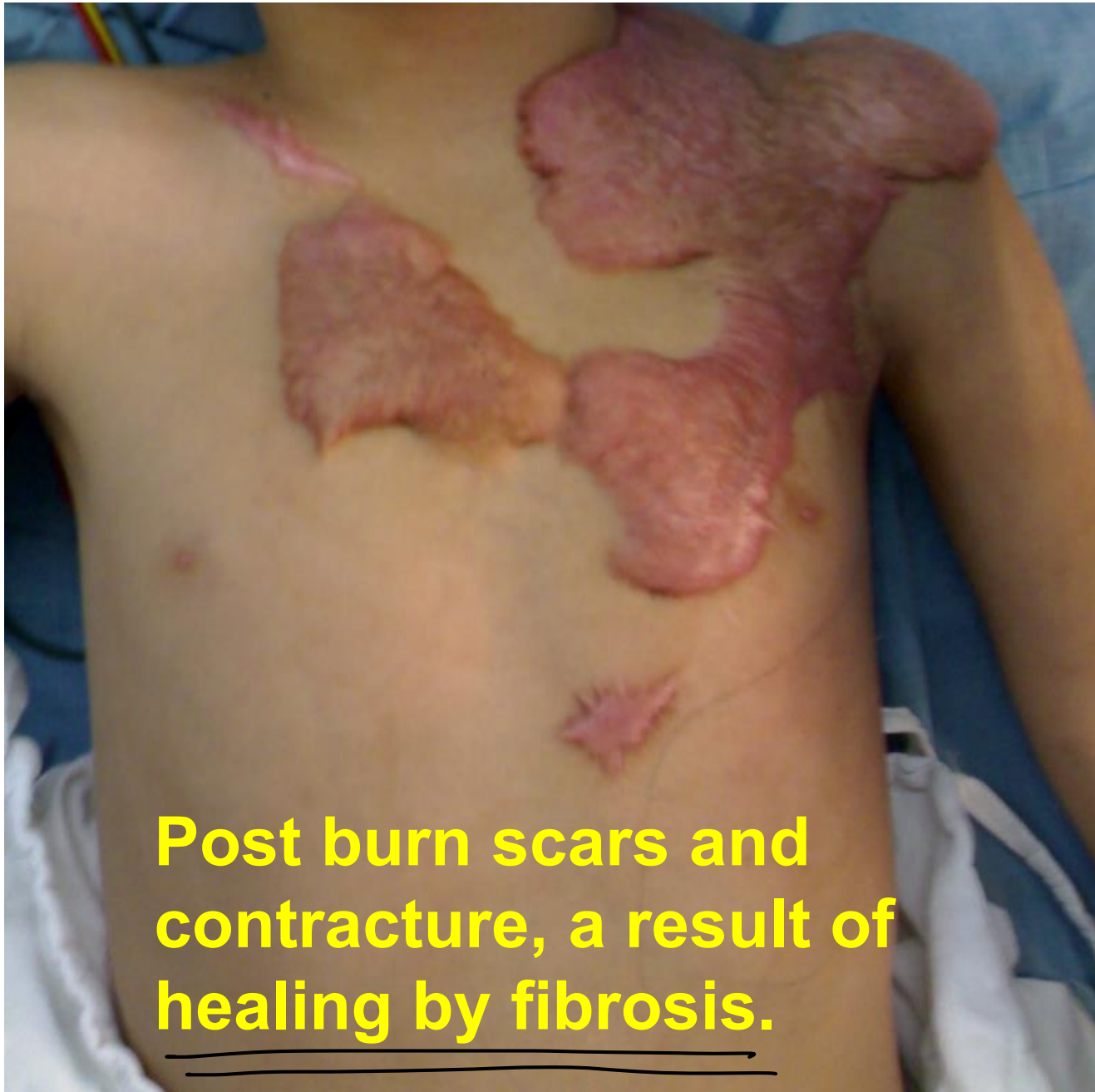



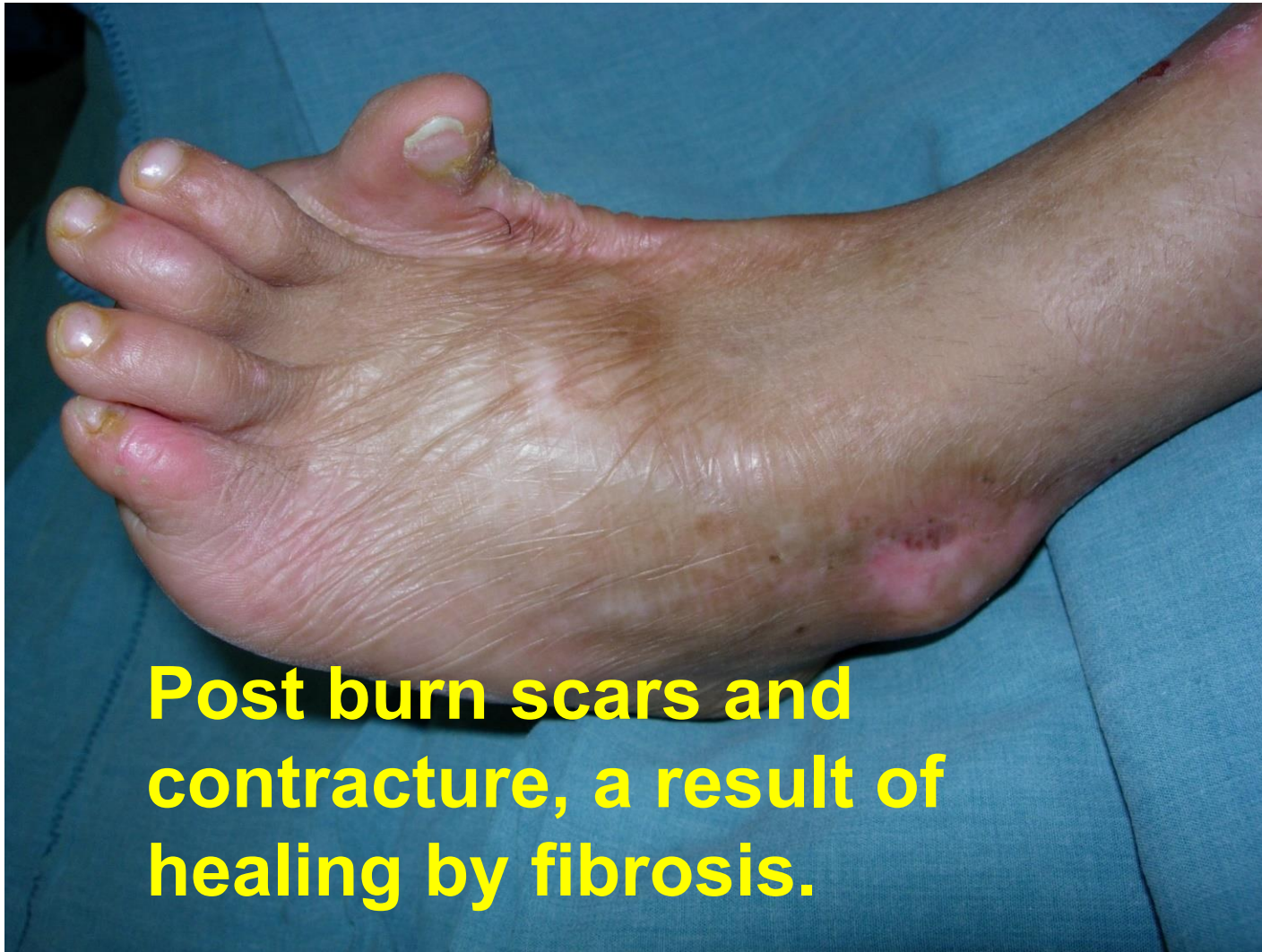Traumatic hand defect



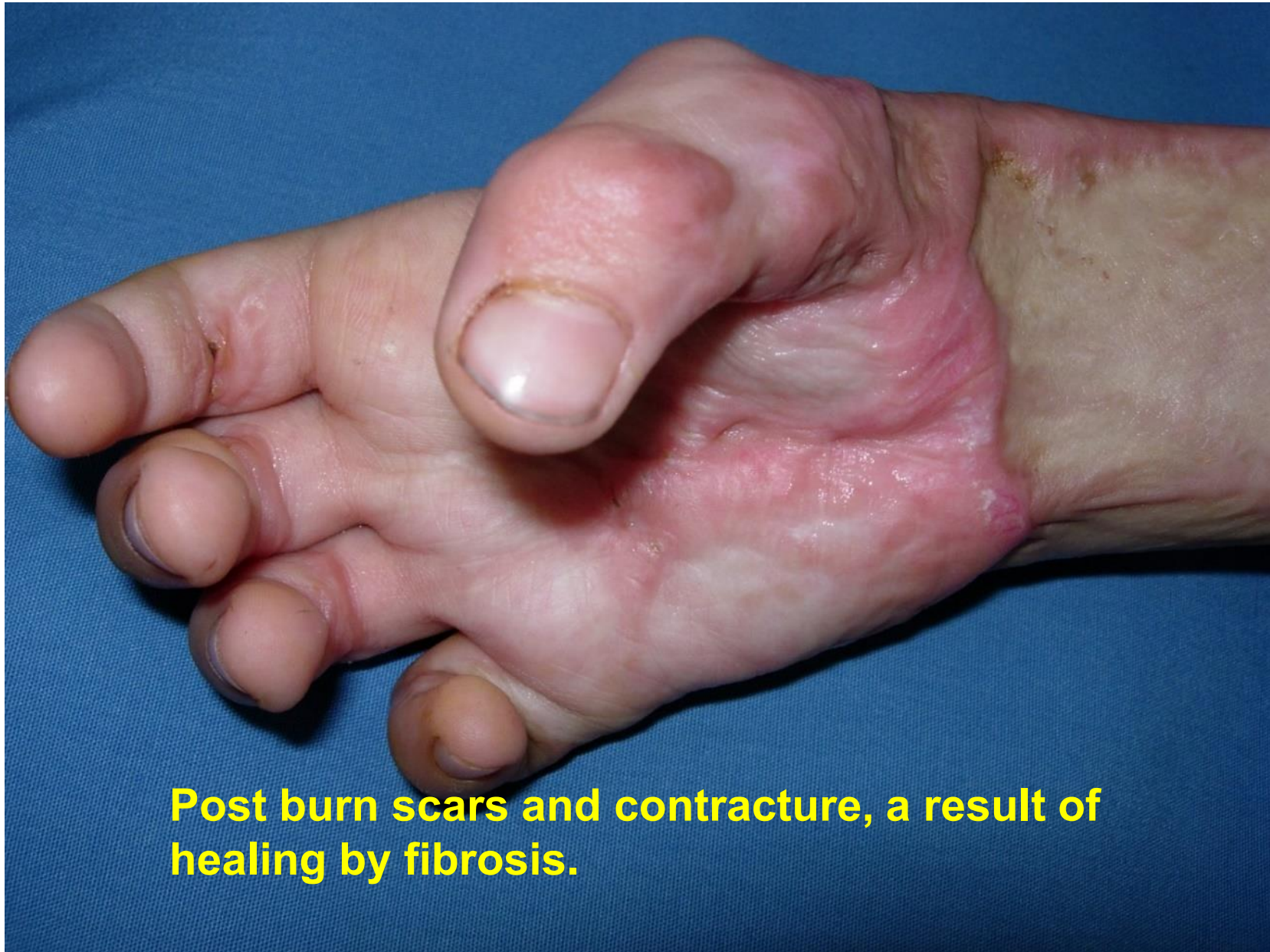Traumatic finger defect



Post burn scars and contracture, a result of healing by fibrosis.



Post burn scars and contracture, a result of healing by fibrosis.



Post burn scars and contracture, a result of healing by fibrosis.

WHY DO WE NEED RECONSTRUCTIVE SURGERY?

The body can deal with Defects(tissue loss or discontinuity) by wound healing: which is simply: replacement of lost or discontinued tissue(ROLT).

There are two modes of wound healing:

Regeneration: replacement of lost or discontinued tissue(ROLT) by the same lost tissue: This is the ideal mode of healing with maximal functional and cosmetic recovery.

Fibrosis: replacement of lost or discontinued tissue(ROLT) by fibrous tissue: the fibrous tissue lacks the function and form of the lost tissue. So healing with fibrosis is a bad mode of healing.

Unfortunately healing by regeneration in human beings is limited to simple tissues:

- **Epithelium**
- **Hepatocytes**
- **And bone**

Some lower creatures as salamanders can heal organs as limbs by regeneration.

The role of plastic surgeon:

To cover defects that would heal by fibrosis by tissue transfer trying to avoid the fate of fibrosis.

Our goal is to protect
the donor (الناحية سليمة)
عزيمانه جابري سيروا صنفين

TISSUE TRANSFER:

The donor area donates tissues to the defected area (recipient area).

* لازم نأكد إنه المنطقة جابري احدها صير فيها مشكلة او صير مشكلة
خفيفه

■ **The result of tissue transfer is better than fibrosis but less than the ideal regeneration.**

■ **In future stem cells (regenerative medicine) would hopefully be able to deal with lost tissues.**

~~***~~ The ideal tissue transfer (graft or flap) should achieve the following criteria:

- **Replace like with like: the transferred tissues should be as similar as possible to the lost tissues in the defect.** for example: facial skin loss should be replaced by something similar some or fat...
- **Maximum benefit to the recipient area.**
- **Minimal donor site morbidity: minimal harm to donor area.**
- **Tissue transfer should be safe to patient.** يعني ما يحوت

→ We're trying to create an tissue that's similar to the original one from multiple sites

YOU RUB PETER TO PAY PAUL, PETER
SHOULD BE ABLE TO AFFORD IT.

METHODS OF SOFT TISSUE CLOSURE (RECONSTRUCTION)

There are different methods of closure of wounds, which vary in complexity, depending on the defect, and whether there is tissue loss or not. The hierarchy of methods includes:

1. Direct closure.
2. Healing by secondary intention.
3. Skin grafts: split thickness, or full thickness.
4. Flaps. Local or distant.

WHEN TO CLOSE A DEFECT?

NOW OR IMMEDIATE: ^{}When the wound is clean .**

LATER OR DELAYED: ^{}when the wound is not clean .**

When do we close the wound?

When it is clean: means that the wound should be free of contamination, infection and dead tissue .

Clean: means **minimal bacterial load (contamination and infection)** , and **minimal necrotic tissue** , this depends on two factors:

MECHANISM OF INJURY , AND INSTRUMENT USED: Crushing injuries , and injuries inflicted by blunt instruments are usually associated with a degree of contamination and tissue damage .

TIME ELAPSED FROM INJURY TO PRESENTATION: if this time is more than 6 hours , then the wound is considered contaminated , an exception to this rule is the face , in which primary closure could be done within 24 hours , this is due to the excellent vascularity of the face .

HOW: Wounds are closed by one one of 5 methods :

1. Direct closure.
2. Healing by secondary intention.
3. Skin grafting; split thickness, or full thickness.
4. Flaps. Local or distant.
5. Prosthesis

Direct closure :

- **Used when there is no or minimal tissue loss so we can approximate the wound edges without tension.**
- **Edges of the wound are approximated usually with suture materials, however other methods may be used as, staplers, tissue glue, or adhesive tape (steristrips)**

Classification of wounds:

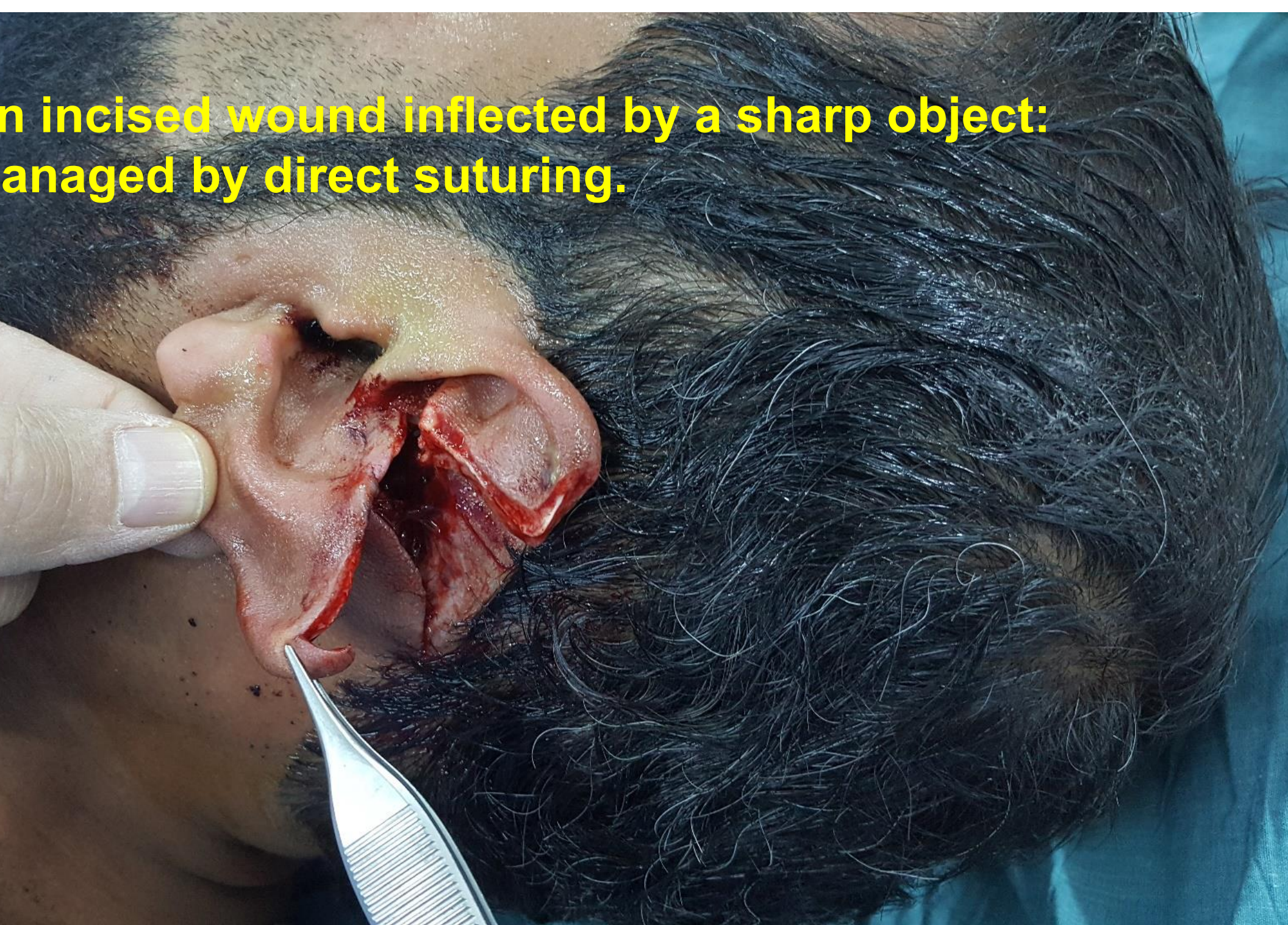Depending on the degree of tissue necrosis and contamination, wounds are classified into:

Incised wound: caused with sharp, relatively clean instruments, have minimal necrosis and contamination, are closed primarily.

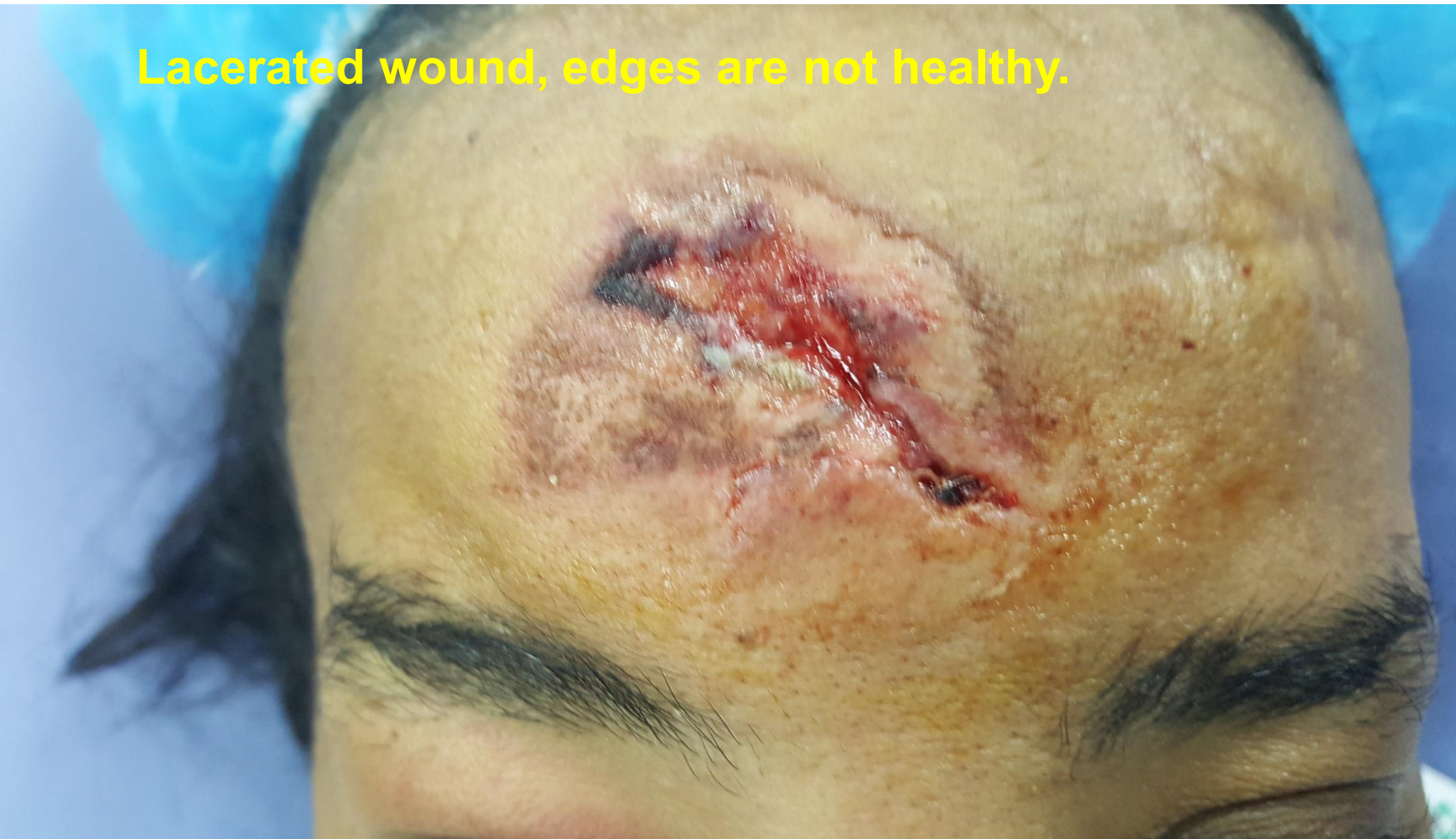Lacerated wounds: characterized by jagged edges, caused with blunt instruments, associated with moderate degree of necrosis and contamination, are managed by wound excision, (to transform it into an incised wound) and then direct closure.

Crushed wounds: seen in industrial and severe road traffic accidents, associated with heavy contamination and severe tissue devitalization.

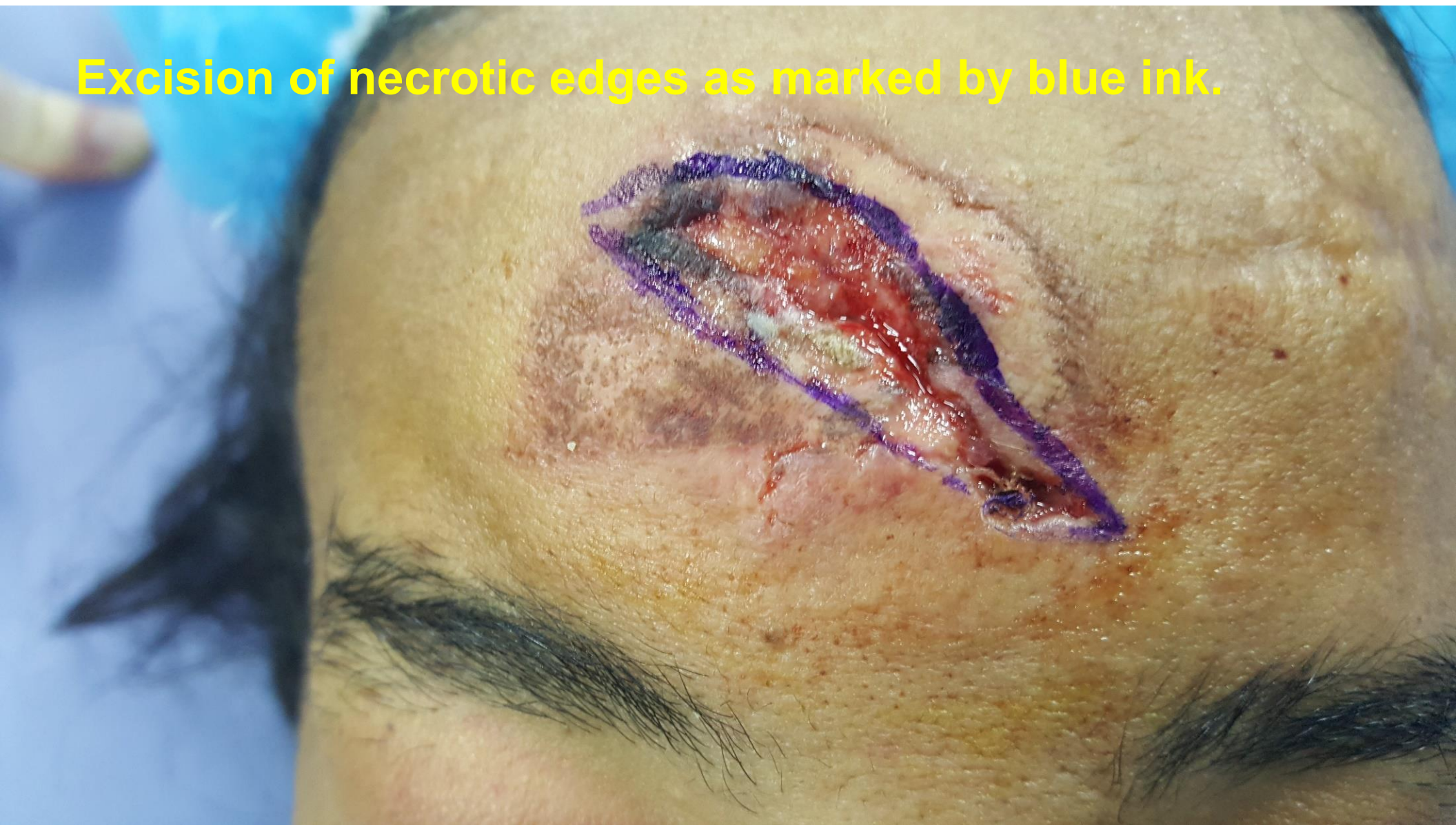**An incised wound inflicted by a sharp object:
managed by direct suturing.**

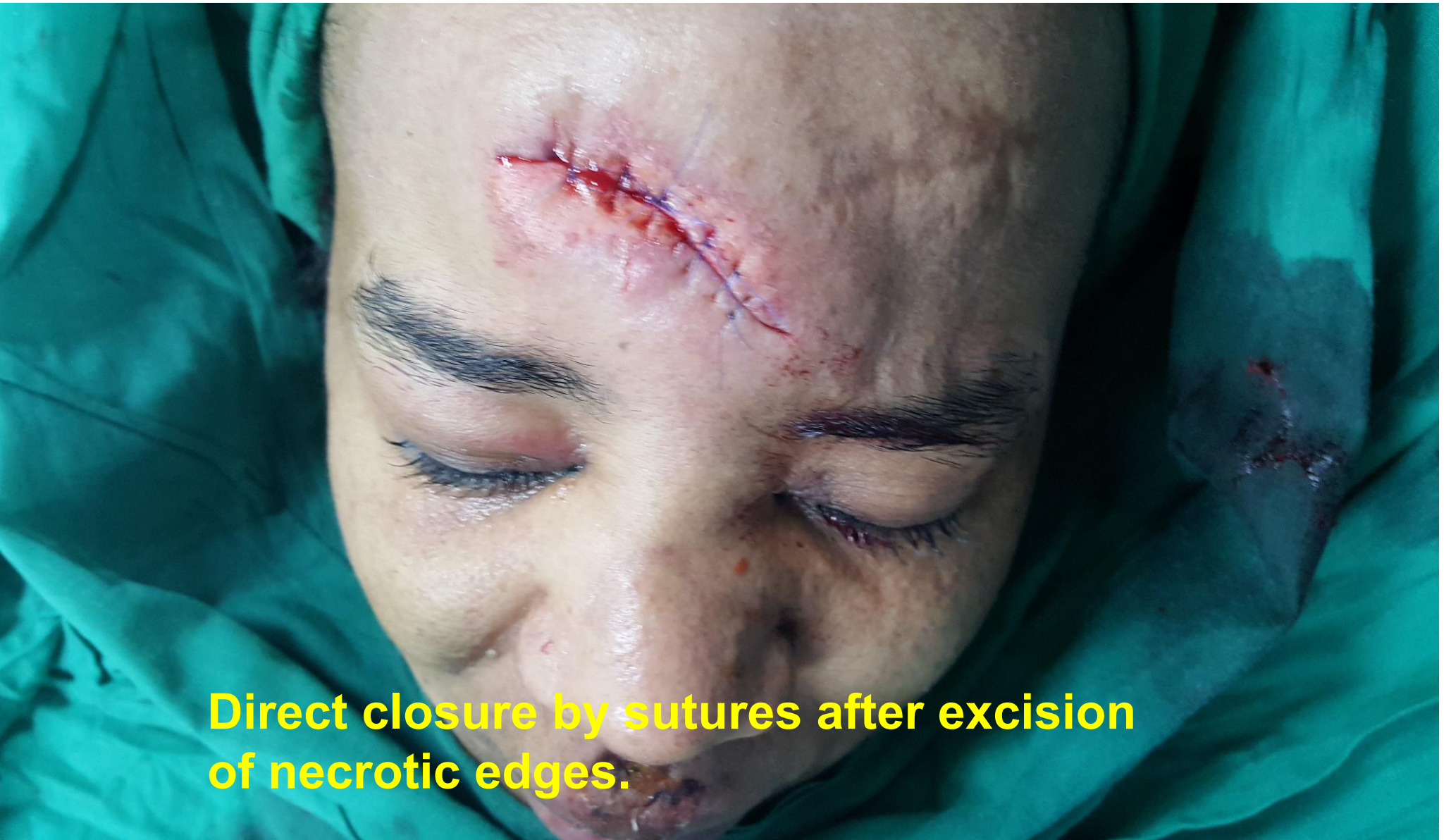

Lacerated wound, edges are not healthy.

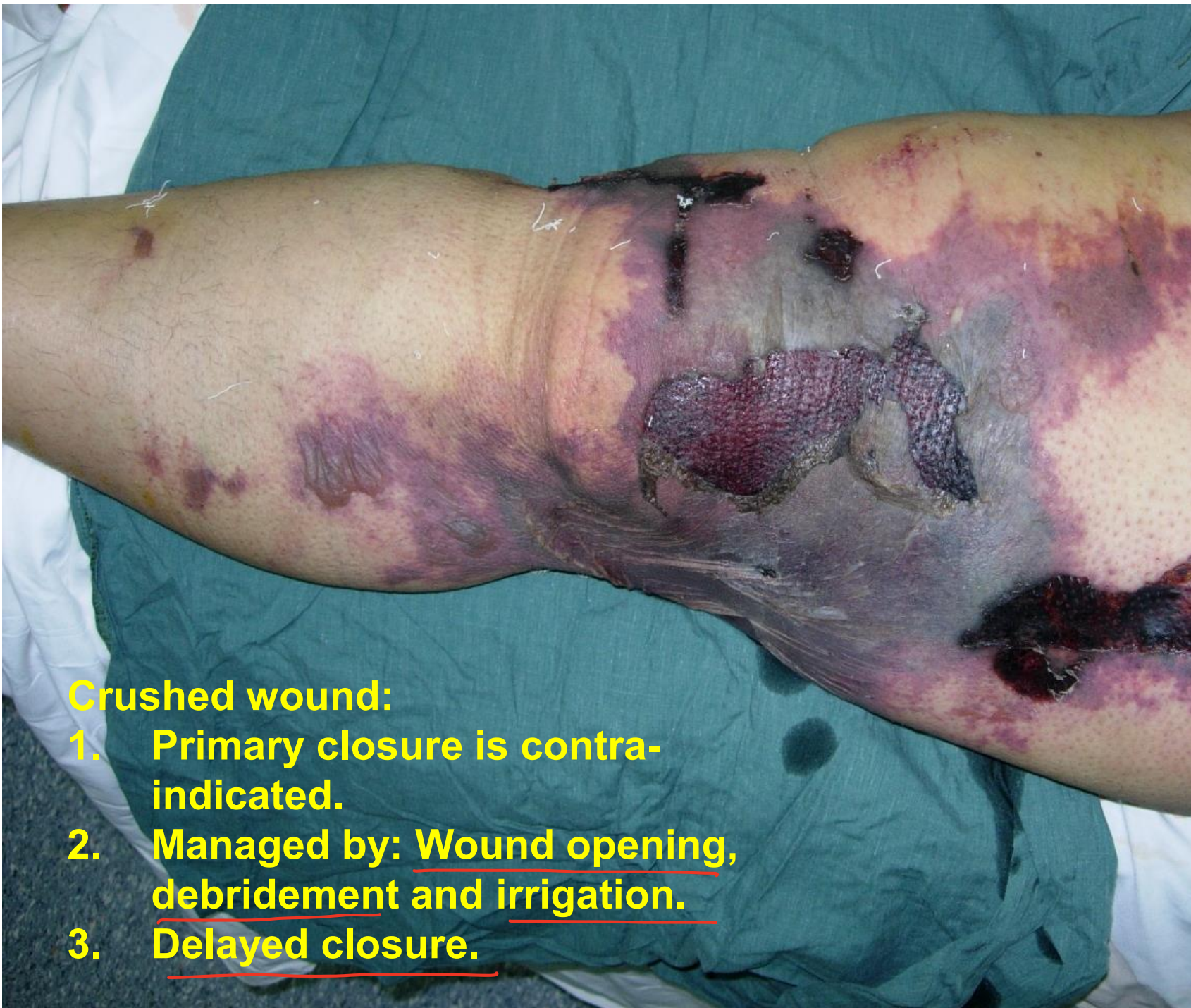

Excision of necrotic edges as marked by blue ink.





Direct closure by sutures after excision of necrotic edges.



Crushed wound:

- 1. Primary closure is contra-
indicated.**
- 2. Managed by: Wound opening,
debridement and irrigation.**
- 3. Delayed closure.**

Management of crush wounds:

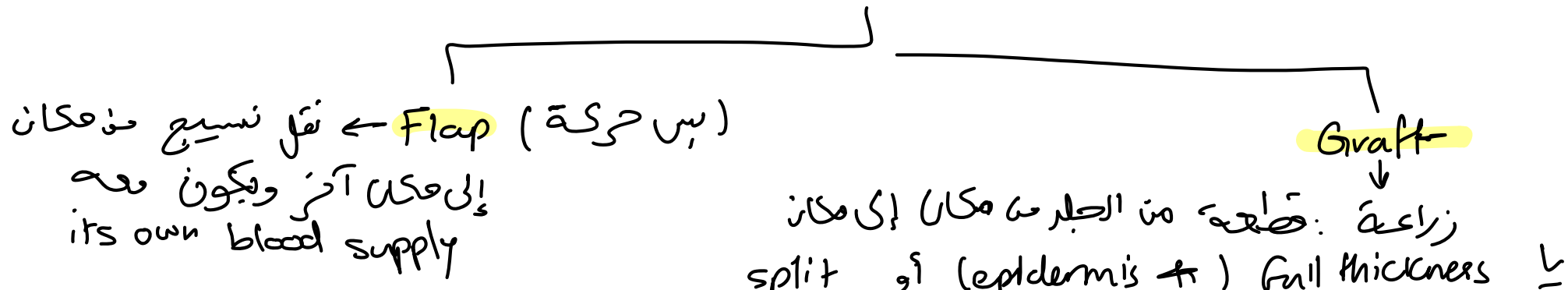
Managed by wound opening, and daily cleaning, irrigation and adequate debridement (excision of necrotic tissue) till the wound becomes clean, then it can be closed.(delayed closure)

Primary closure is contra-indicated in crushed wounds, as the dead tissue, contamination, and the tissue tension due to inflammatory edema will predispose to infection, especially gas gangrene and tetanus.

Wounds with tissue loss:

When there is tissue loss, so the wound could not be closed directly without tension, other alternatives should be thought of to deal with the wound.

- Healing by secondary intention.
- Skin grafts
- Flaps.



thickness dermis
(epidermis + dermis is جز)

Healing by secondary intention:

→ left open healing by itself

This option is good for, **small defects**, **when the area is of no functional or cosmetic importance**, or when other operative methods like grafts or flaps are not safe.

SKIN GRAFTS

1. Split thickness skin grafts (STSG)

- Epidermis and part of the dermis
- Donor area heals by regeneration (similar to the healing of superficial second degree burn).
- The same donor area can be re-harvested after healing.
- Almost any area of the body may be used as a donor site, so large areas of skin defects may be covered with STSG.

Full thickness skin grafts (FTSG) **Better in color and shape**

Consists of the whole skin (epidermis and dermis)

Taken from areas of loose skin as the donor area is closed by approximation of the edges (direct closure), due to this fact, only small areas could be covered by FTSG.

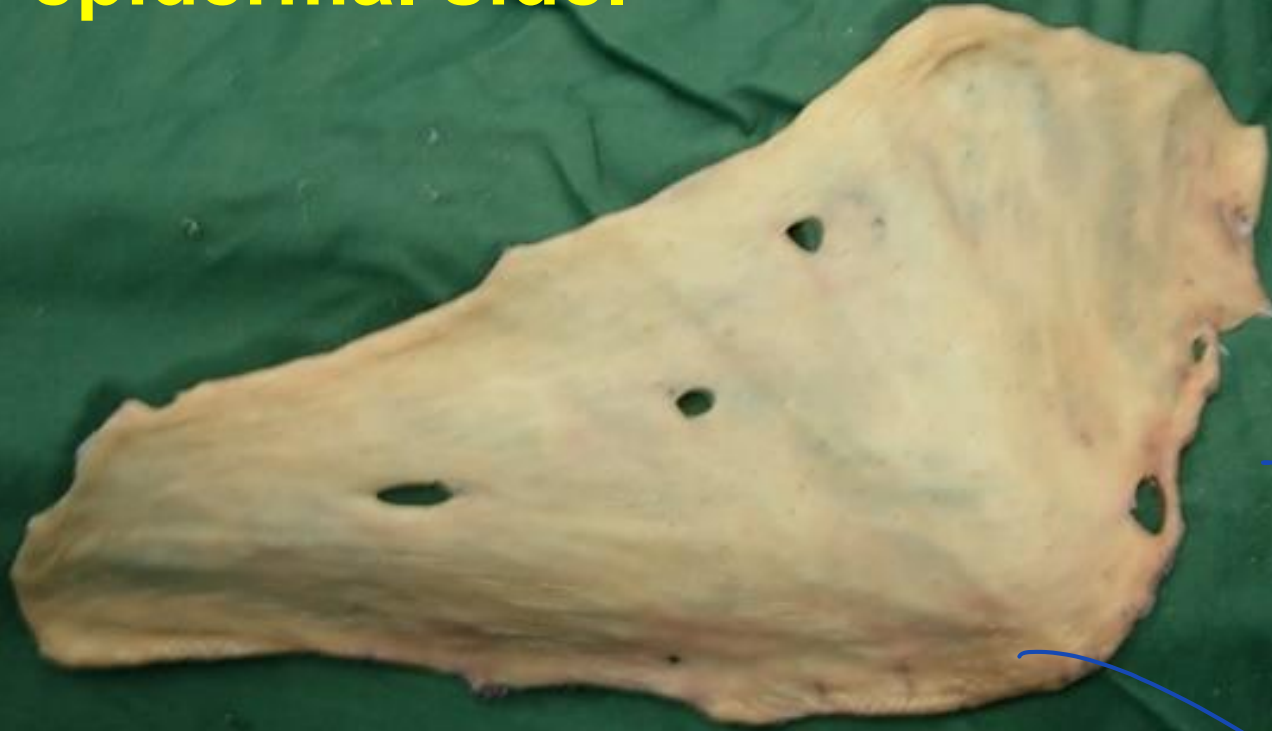FTSG is superior to STSG from functional and cosmetic aspects: Better texture, better color matching with less pigmentation problems, more durable, less wound contraction; they have better sweat and sebaceous glands function, it grows with the child, and they have better final innervation.

Although FTSG are better they have 2 drawbacks: they are less available to cover large areas, and they are more difficult to take.

بخصوص انك انما منيعة وطبق عيشه
لازم ينزل عليها طري
(We call it graft take)

بذستخدها مناطق صغيرة
حتى يغطيها حتى جوده اصبحت

Full-thickness skin graft : the epidermal side.

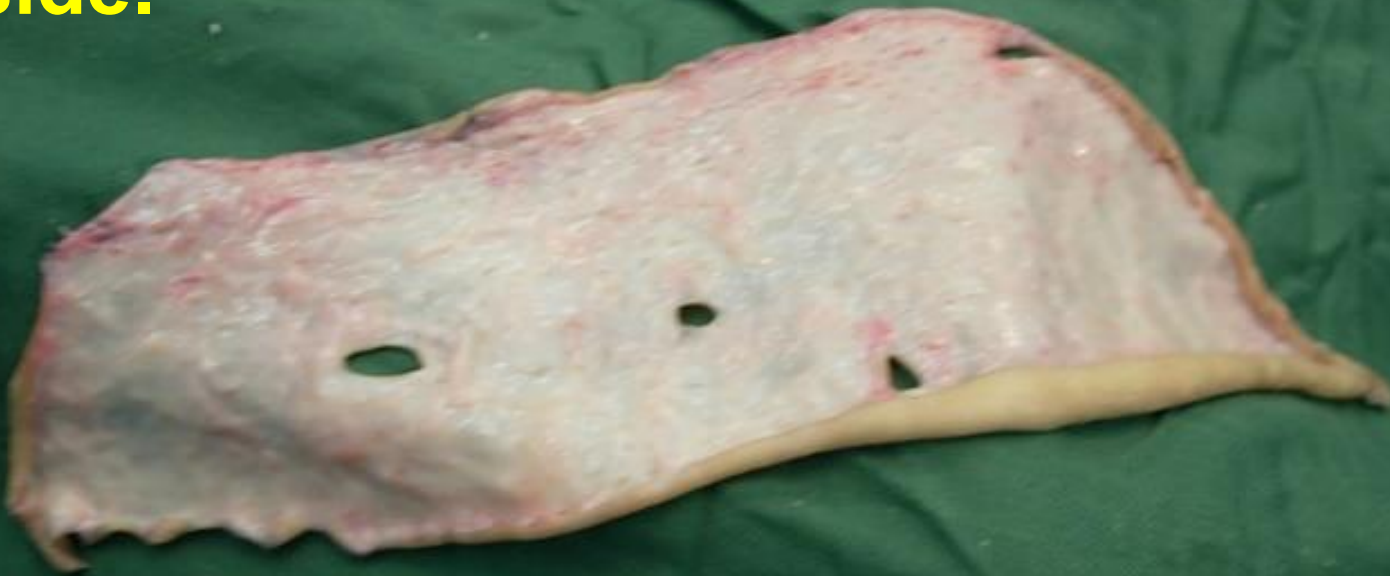

ياضفا
فتلا
عن
ورا
الاذن

س
لازم

استورها directly من split. بتركها regeneration

Full-thickness skin graft : the dermal side.



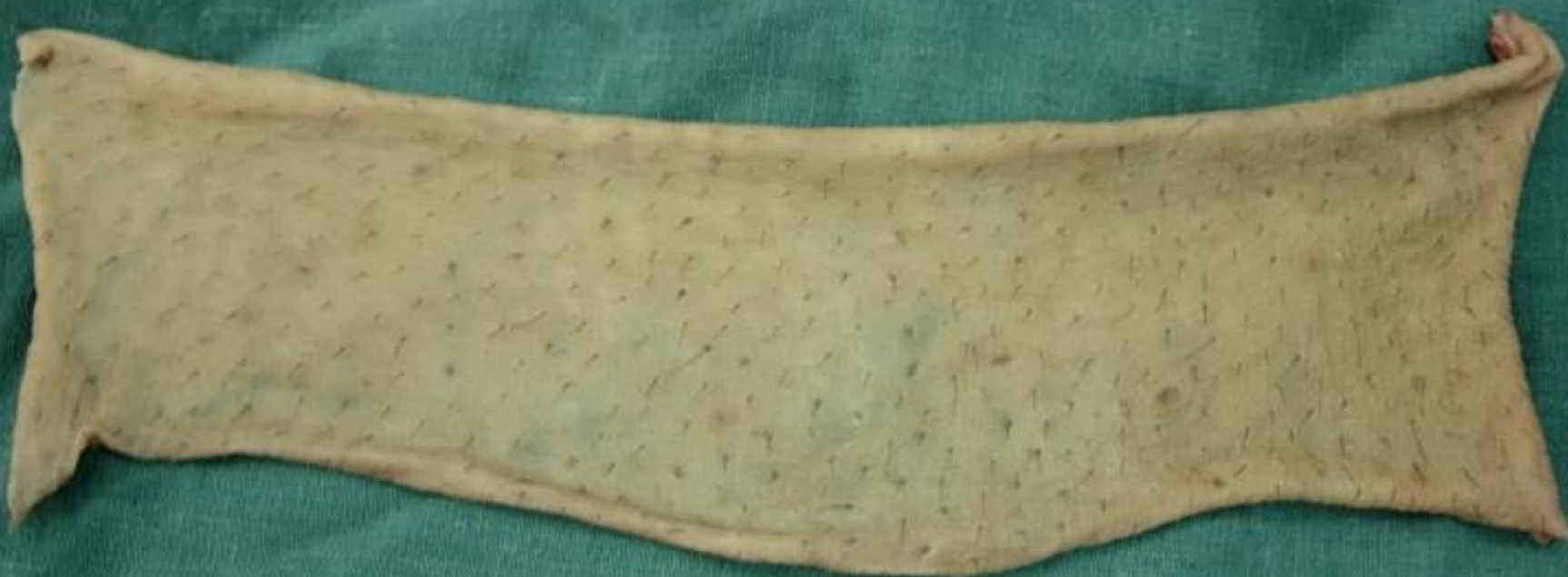The dermatome:
used to harvest split-thickness skin graft



↓
taking epidermis and part of the dermis
(بِقِيس)

*the remaining white tissue because I'm cutting through the dermis

Split-thickness skin graft, the epidermal side. Note the rectangular shape of the graft, that goes with the shape of the dermatome.



→heals by regeneration

**Split-thickness skin graft, the dermal side.
Note the white color of dermis.**



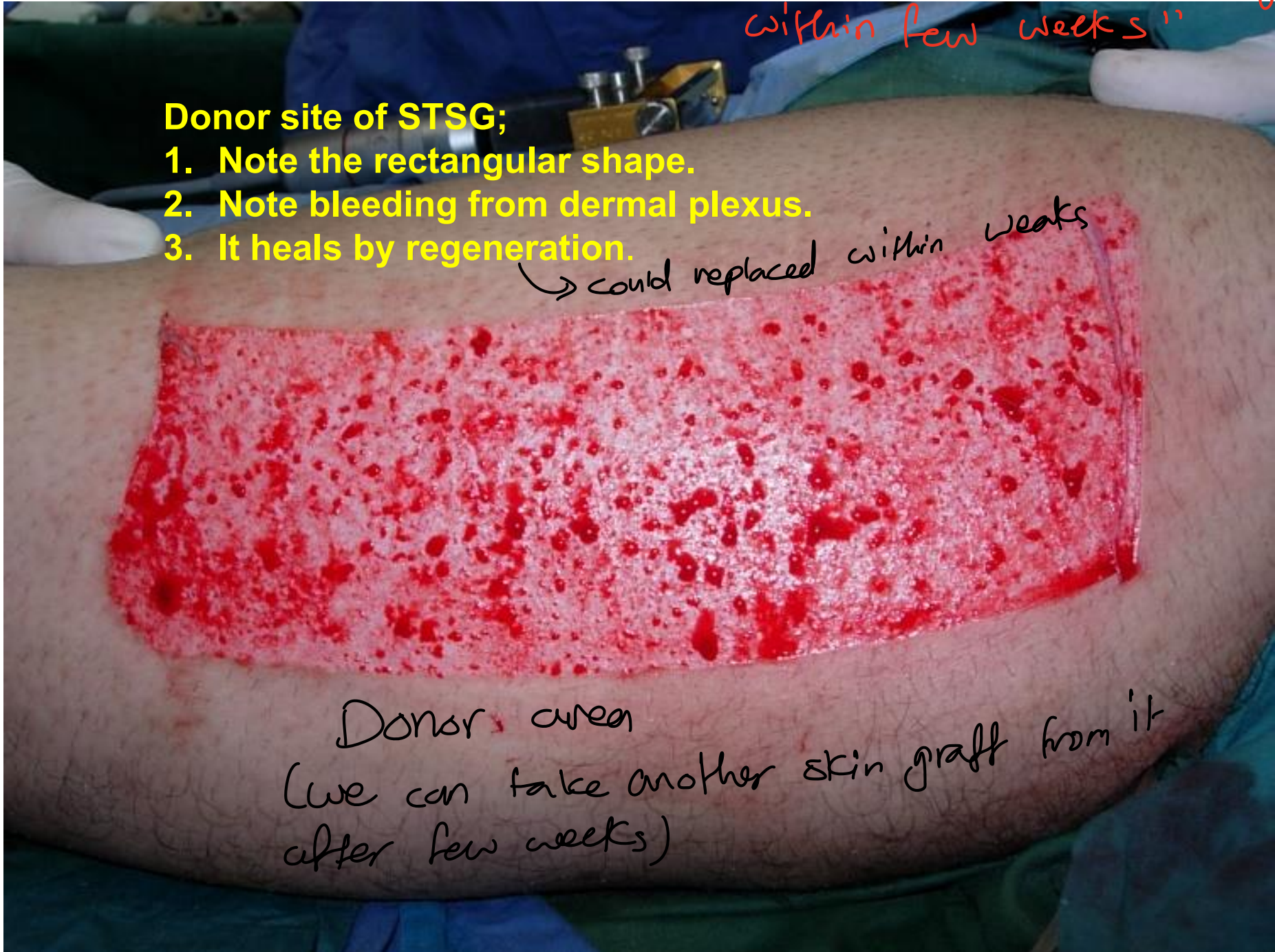"Reharvest the donor area again
within few weeks"

Donor site of STSG;

1. Note the rectangular shape.
2. Note bleeding from dermal plexus.
3. It heals by regeneration.

↳ could be replaced within weeks

Donor area
(we can take another skin graft from it
after few weeks)



Which is better for recipient area?

FTSG is superior to STSG from functional and cosmetic aspects: Better texture, better color matching with less pigmentation problems, more durable, less wound contraction; they have better sweat and sebaceous glands function, it grows with the child, and they have better final innervation.

*Always in full thickness use an area that is loose so that we can replace it easily
→ for example from the abdomen (lower abdomen) because it's a loose area

**Although FTSG are better than STSG,
they have 2 drawbacks:**

- 1. They are less available to cover large areas.**
- 2. And they are more difficult to take.**

Graft take: → ① Pink because of Hb
② Blanching → by pressing on it, it turns white

The process by which the graft is integrated in the recipient site and acquires new blood supply.

HOW DOES (SKIN GRAFT TAKE) OCCURE

Skin graft take passes through two stages:

1. PLASMATIC CIRCULATION: in the first 1-2 days, the graft is nourished from the underlying recipient site by the process of imbibition or diffusion (plasmatic circulation).

2. NEOVASCULARIZATION: within 2-3 days, the graft blood vessels are joined with the recipient site vessels, the latter process is called .

SIGNS OF SKIN GRAFT TAKE

- The graft is adherent to the recipient site.

- The graft is pink in color.

- The graft blanches with pressure, denoting vascularity.

→ turns into white

Factors affecting take:



- 1. Vascularity of the recipient site**, this is the most important factor. Skin graft take is poor on avascular areas, such as cortical bone bared of its periosteum, cartilage devoid of its perichondrium, tendons bared of its paratenon, and over irradiated areas, graft take does not take place on prosthesis.
- 2. Bacterial load(contamination and infection)** hinders graft take especially that is caused by streptococcus, group A.
- 3. Presence of barriers between the graft and the recipient area**, as hematoma, seroma, debris, or foreign materials.
- 4. Immobilization**, the graft should be fixed to the recipient site, as graft mobility hinders imbibition and neovascularization.

What type of skin graft to use, STSG or FTSG?

- When the area to be covered is small and needs good durable skin as on the hand and joints, or needs good cosmesis, as on the face then FTSG is used.
- But if we need to cover large areas, as in major burns, then STSG is the logic choice.

*Graft is a parasite depends on its living on the recipient area

Remember:

The thicker the graft, the better.

**But: less available, and more
difficult to take!!!!!!!**

FLAPS

A **FLAP** is a piece of tissue carries its own blood supplies that is moved from its original site, to cover a defect.

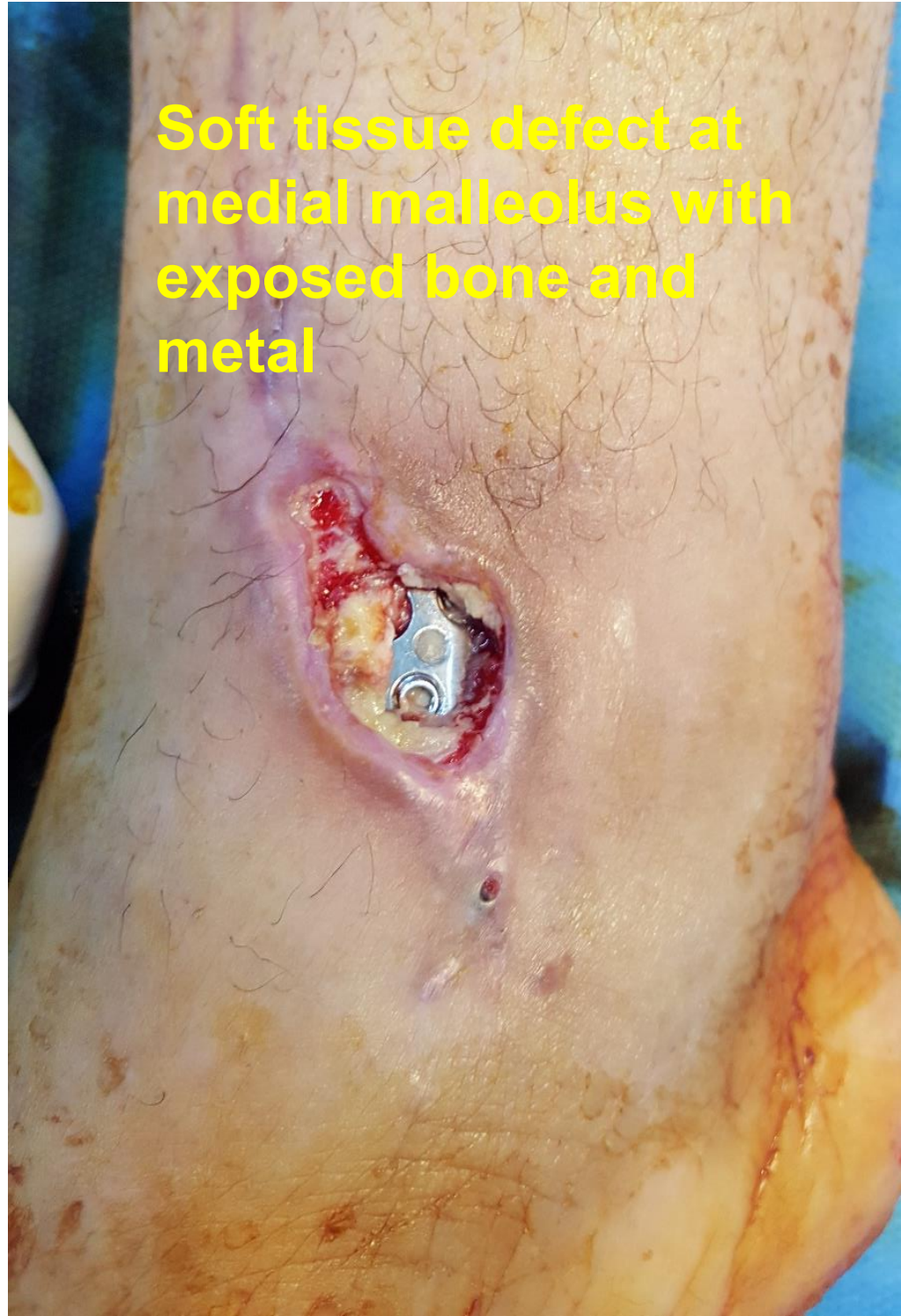Flap composition

Flaps vary in their composition to suit the need of the recipient area, it may be composed of; skin and subcutaneous tissue (skin flaps), skin and muscle (myocutaneous flaps), muscle alone (muscle flaps), skin, fascia and bone (Osseofasciocutaneous flaps)

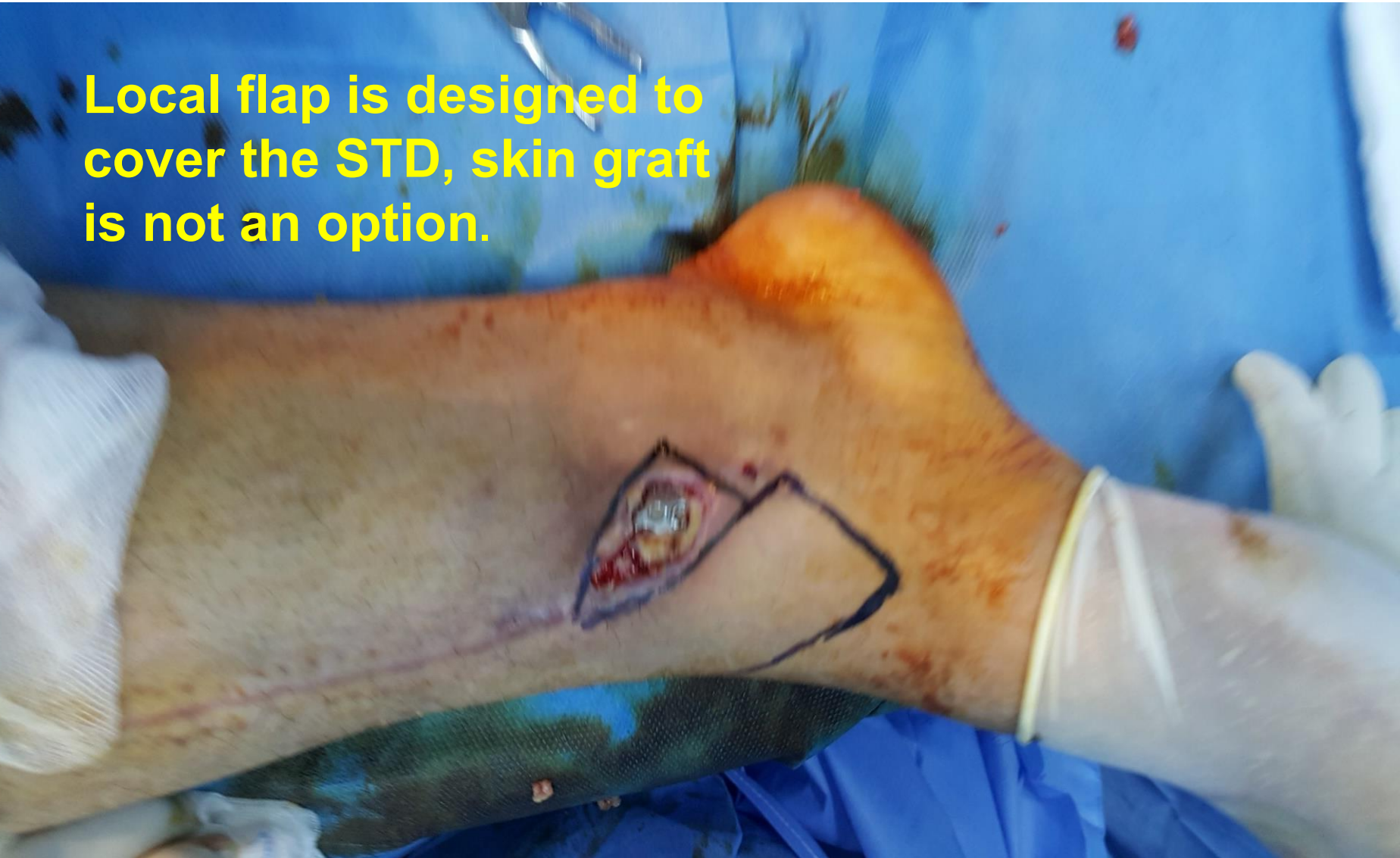Difference between skin grafts and flaps:

1. Skin graft is thin while flaps are bulky.
2. Skin grafts depend on the vascularity of the recipient site for their survival, flaps on the other hand bring their blood supply with them.

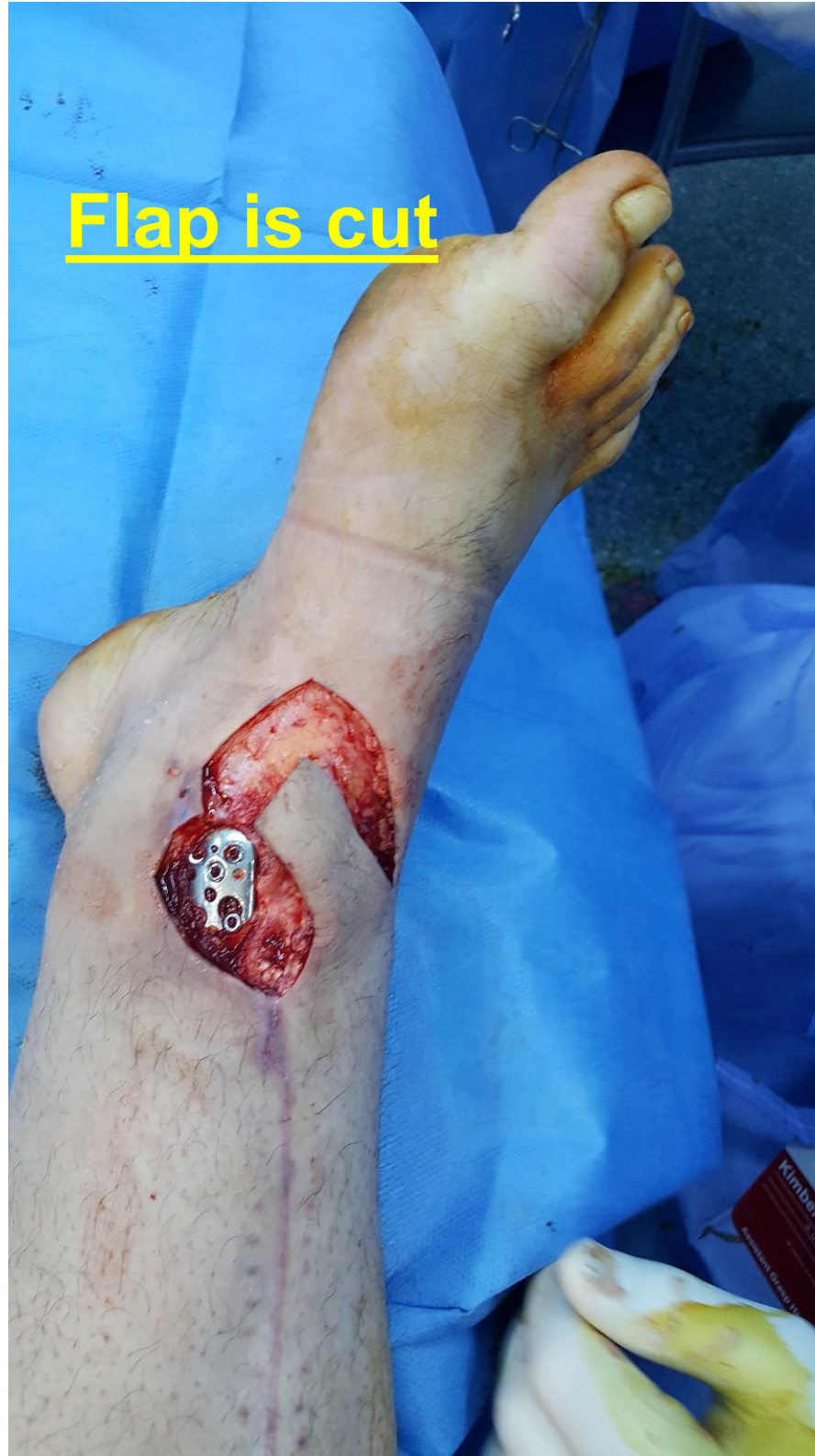**Soft tissue defect at
medial malleolus with
exposed bone and
metal**



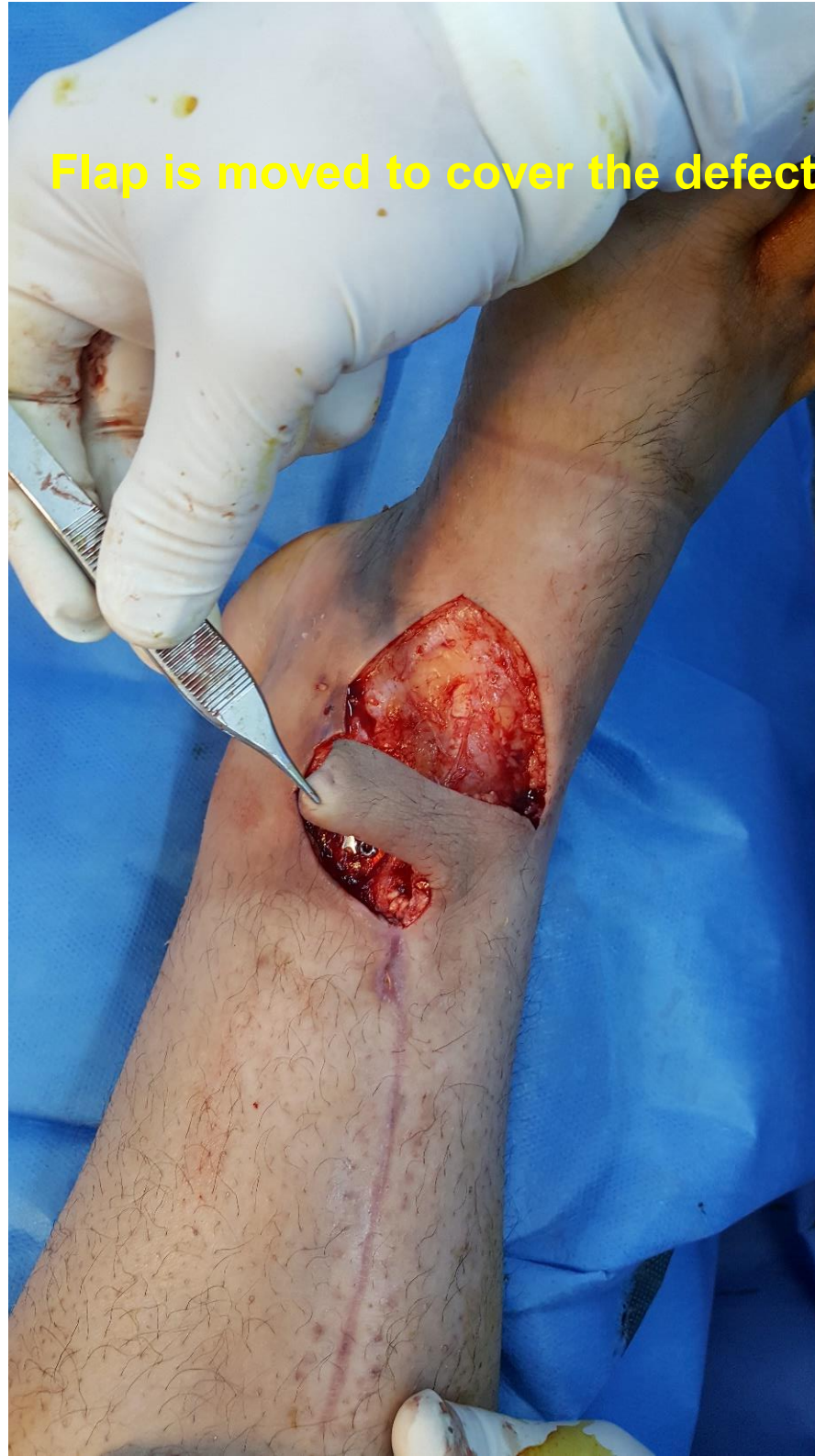Local flap is designed to cover the STD, skin graft is not an option.



Flap is cut

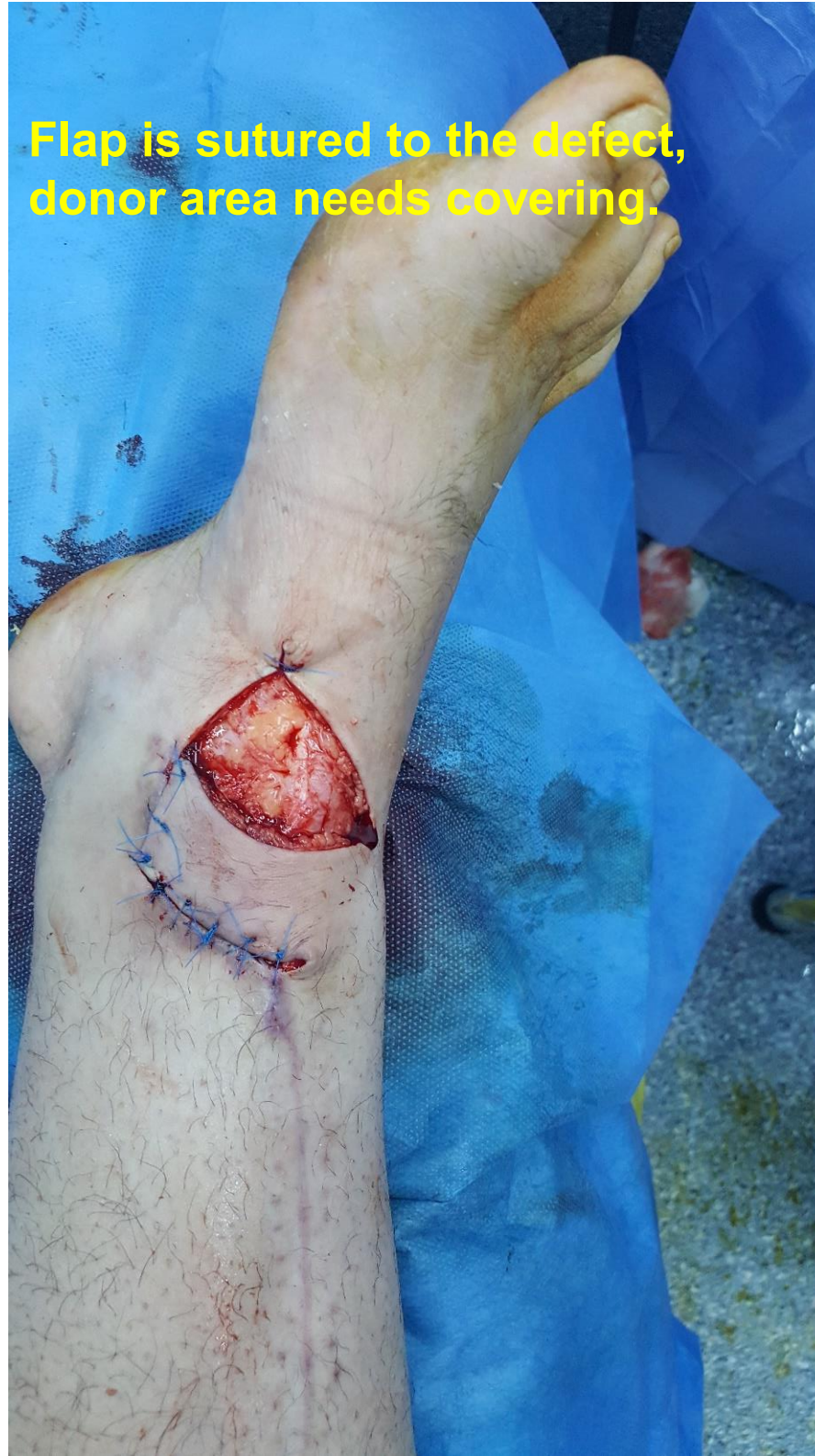

Flap is moved to cover the defect

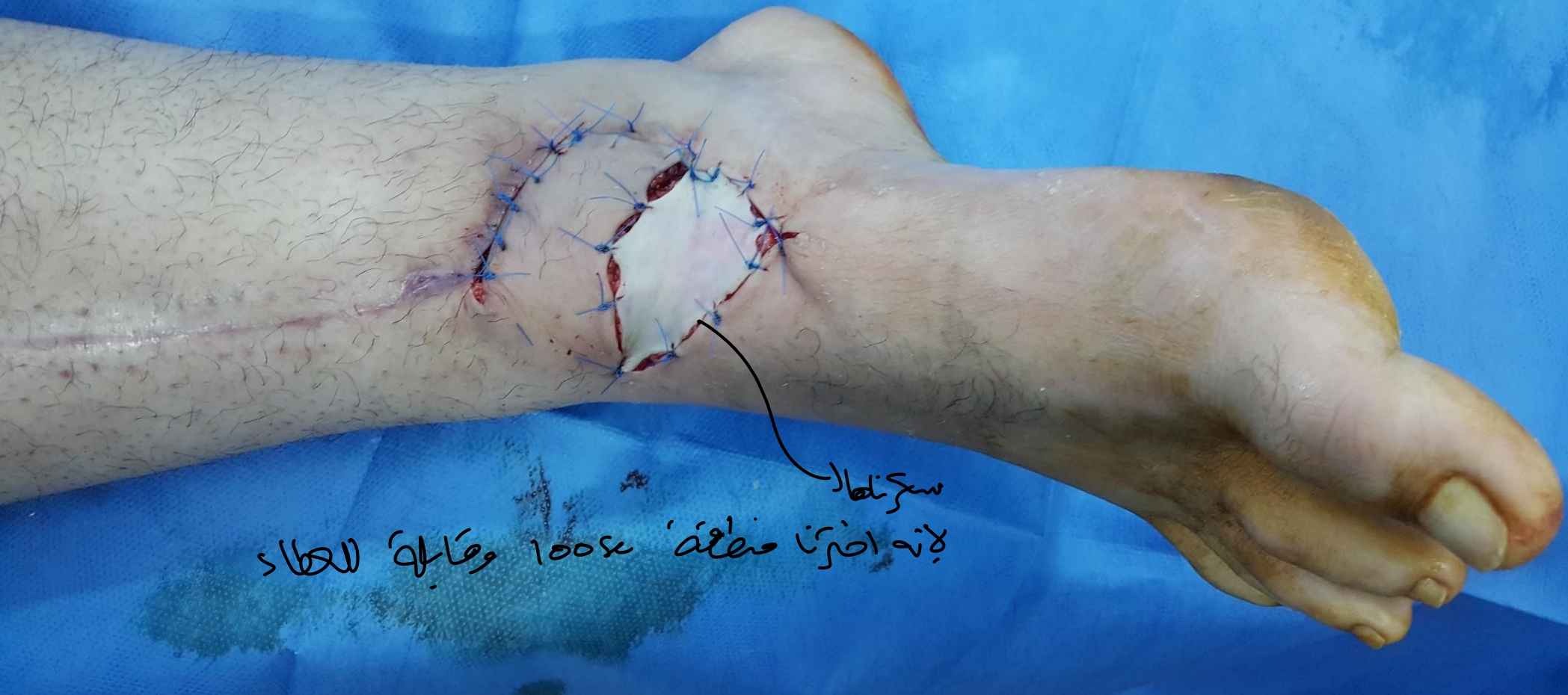


→ We only cut
it and move it
with its blood
supply

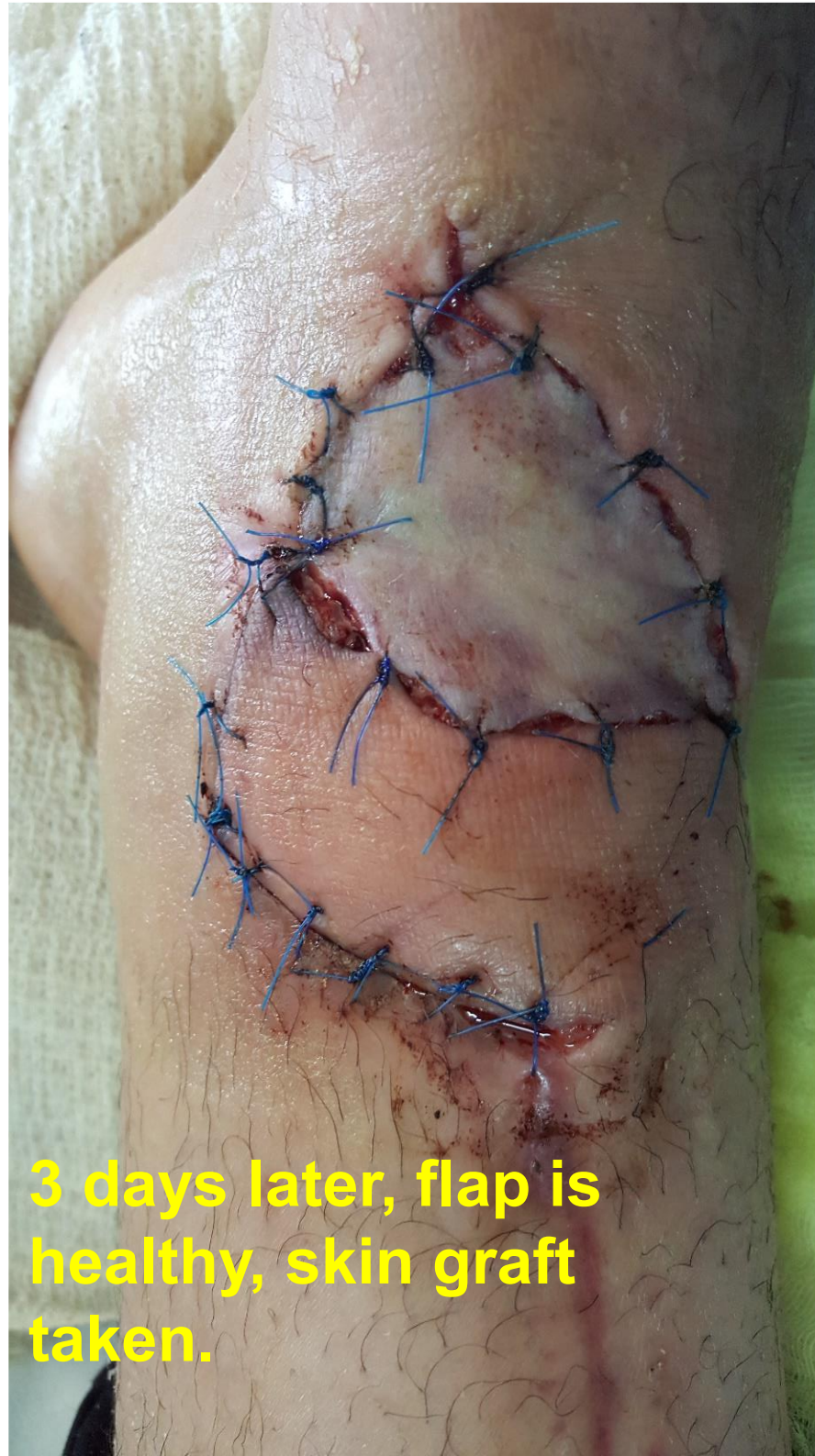Flap is sutured to the defect,
donor area needs covering.



Flap covers the defect, the donor area is covered by skin graft.



سگینا
لایه اجرتنا صلیفہ 100x100 و قیاقہ لکھنا



3 days later, flap is healthy, skin graft taken.