

Musculoskeletal Infections

OM & SA - - both are emergency
If treated- - totally normal
If not-- lifelong handicap

Principles of Bone & Joint Infections

- **Osteomyelitis (OM)** is an infection of bone and bone marrow.
- **Symptom** may include pain in a specific bone with overlying redness, hotness, swelling, fever, and weakness.
 - Deposition of granulation tissue on walls of lacuna (bone marrow)
-> isolate it from bloodstream (chronic)
Antibiotic not effective
Needs debridement
- **Onset** may be sudden or gradual.
 - SA: irritation of nerve endings
 - In superficial bone
 - OM: buildup of pressure (1-2 days)
- The long bones of the arms and legs are most commonly involved in **children**
- while the feet, spine, and hips are most commonly involved in **adults**.
 - Diabetic foot, direct spread not hematogenous
- The **cause** is usually a bacterial infection and rarely a fungal infection.

-
- **Risks** for developing osteomyelitis include diabetes, intravenous drug use, prior removal of the spleen, and trauma to the area.
 - **Diagnosis** is typically suspected based on **symptoms**. This is then supported by **blood tests**, medical **imaging**, or bone **biopsy**.
 - **Treatment** often involves both antimicrobials and surgery.

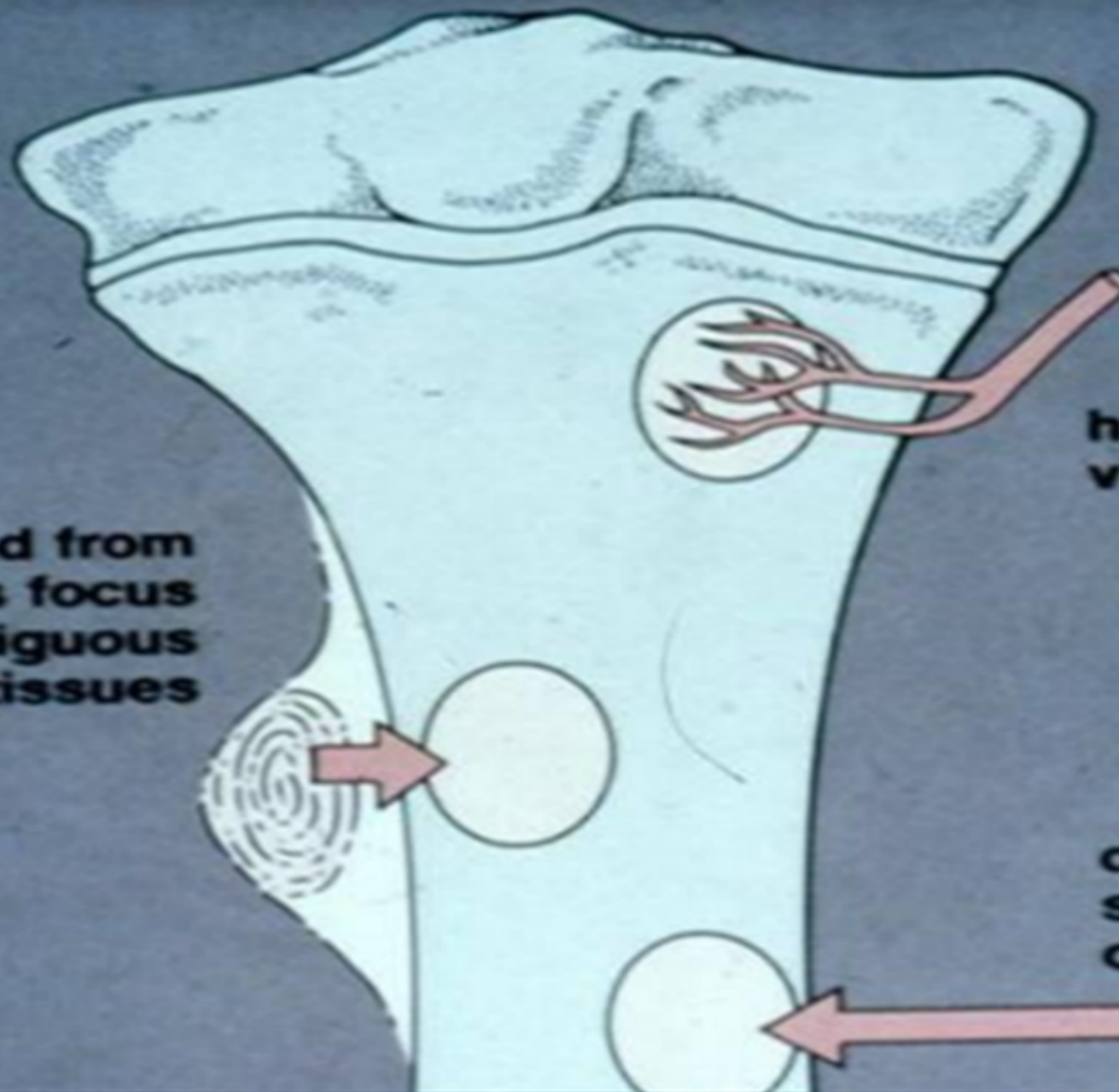
Any chronic medical illness increase risk of infection

It may occur **via** spread from the blood or from surrounding tissue

Routes of infection

- Hematogenous (most commonly. After a remote infection) URTI mc
- Direct inoculation: Skin open fractures, post surgical
- Direct spread: diabetic foot, pressure sore

**spread from
infectious focus
in contiguous
soft tissues**



**hematogenous route
via nutrient arteries**

**direct implantation
secondary to trauma
or surgery**

Bone highly vascular

Nutrient artery

Ascending and descending branches

Reach GP- يعكس اتجاهه stagnant

Speed=0--> sinusoid

Concentration can reach infective dose

Bone infections:

1-Acute pyogenic infections (*staph. Aureus*):

- Pus formation mainly as an abscess
- May spread via lymphatics/blood

Chronic

2-~~Acute~~ non-pyogenic infections (TB):

- formation of cellular granulomas

3-Chronic infection:

- after an acute one, or start as a chronic
- formation of granulation tissue & fibrosis will take place

classifications

Based on the duration and type of symptoms

- Acute : < 2 weeks
- Chronic : > 2 weeks

Acute Hematogenous Osteomyelitis

Usually is a disease of children

Peds distal femur & Proximal tibial metaphyses
Adults spine

Causal organisms

- *Staph. Aureus* (M.C. in both adults and children .)
- *S. pyogenes* (found in chronic skin infections)
- *S. pneumoniae*
- *H. influenzae*
- Gram –ve
- Anaerobes
- **Salmonella** especially in **sickle cell** disease

Neonates: *S. aureus*, GBS, *E. Coli*/klipsella, listeria
monocytogens
1-3 yo: *S. aureus* Hib, pneumococci, GAS
>3yo: *S. aureus*
All sensitive to amoclan

بتيجي بالامتحان

Pathophysiology: Hematogenous Progression of Disease

Infection (regardless site) leading to inflammation and exudation
increase intra-osseous pressure and decrease in perfusion pressure
decrease in blood supply leading to ischemia
thrombosis from pus formation that digests the vessels wall in addition to stasis
from its accumulation
Elevation of periosteum also will lead to decreased blood supply

Throbbing pain
With every systole
Distention of compartment

✓ all these changes lead to decrease in blood supply leading to :-

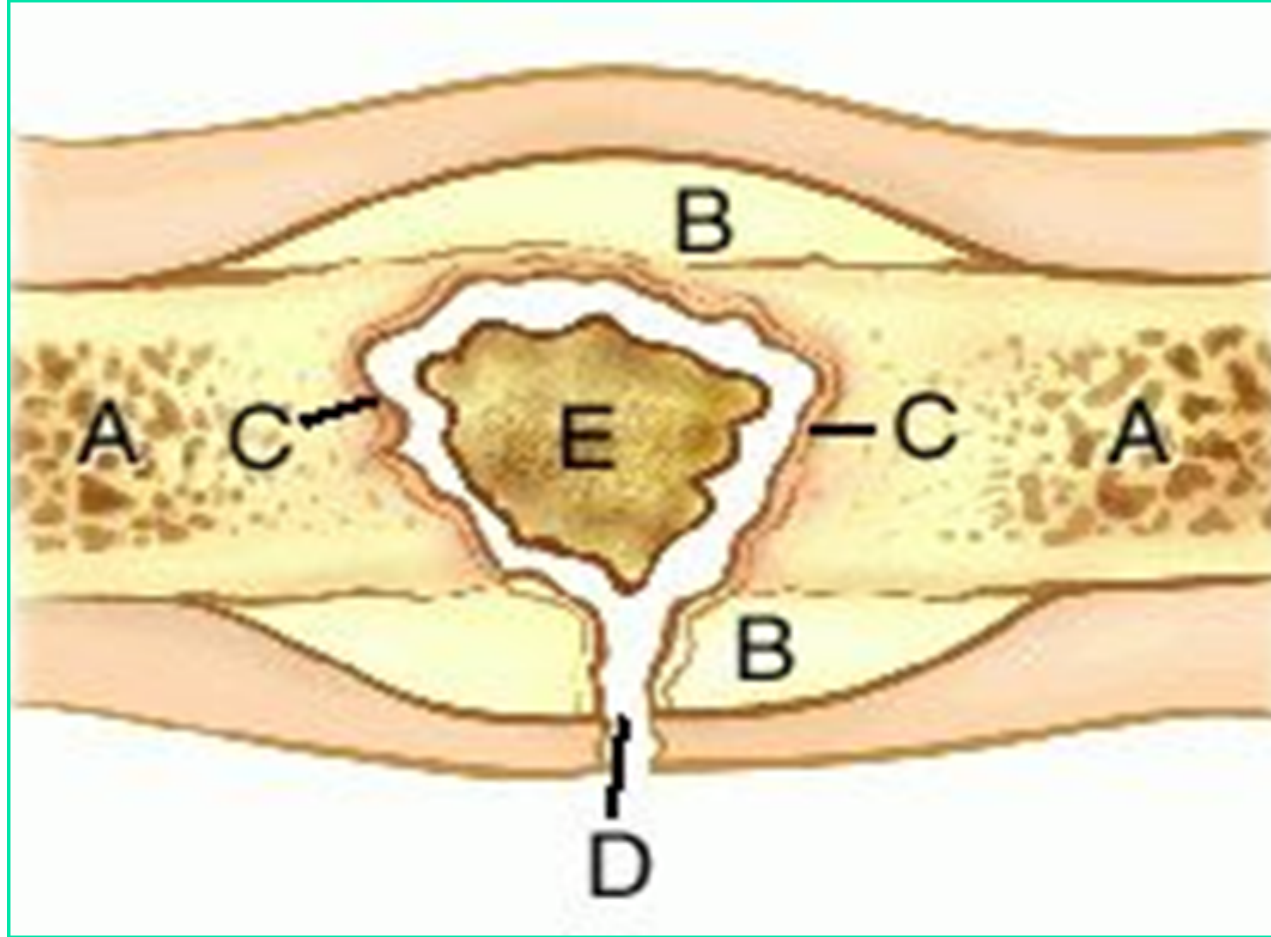
-ischemia and necrosis > **sequestrum** (dead bone) **hyper dense** collapsed trabeculae

New bone formation (the body reacts to the elevation of periosteum as if its a fracture)

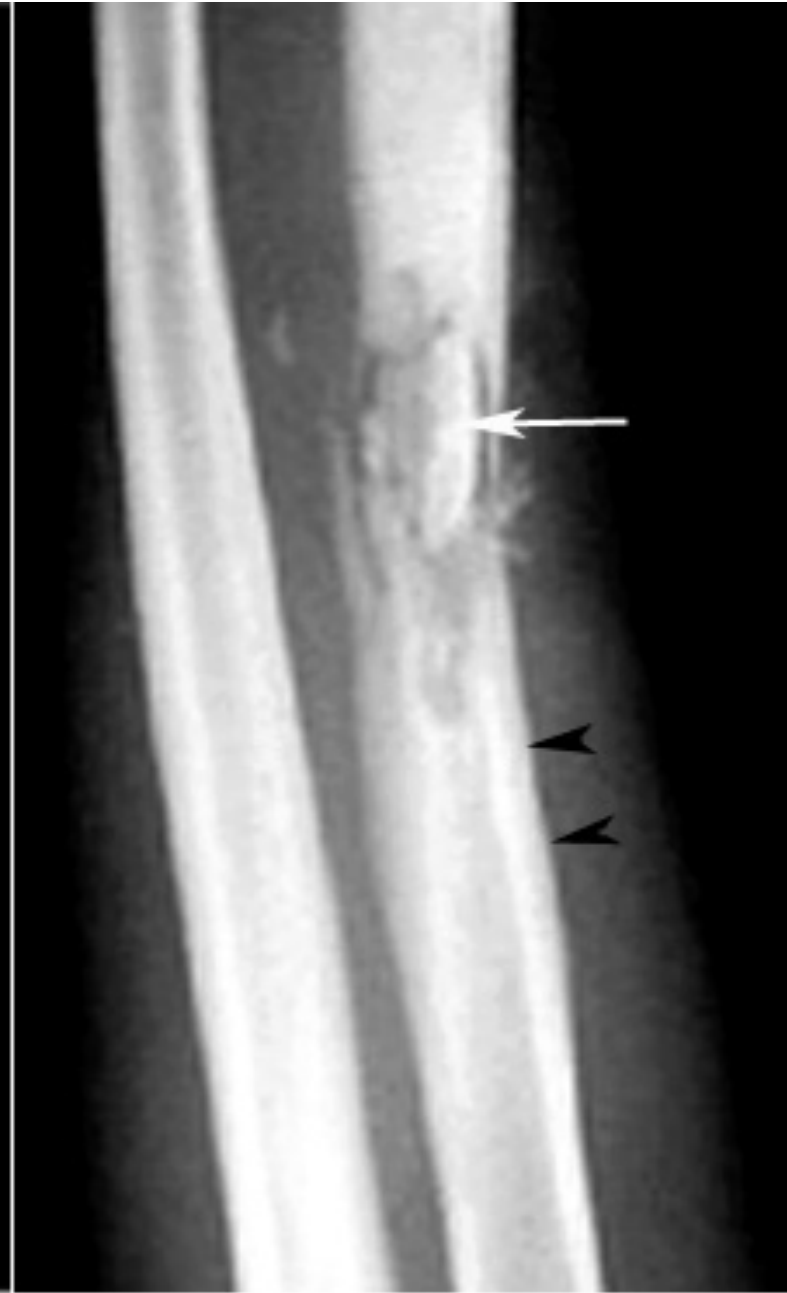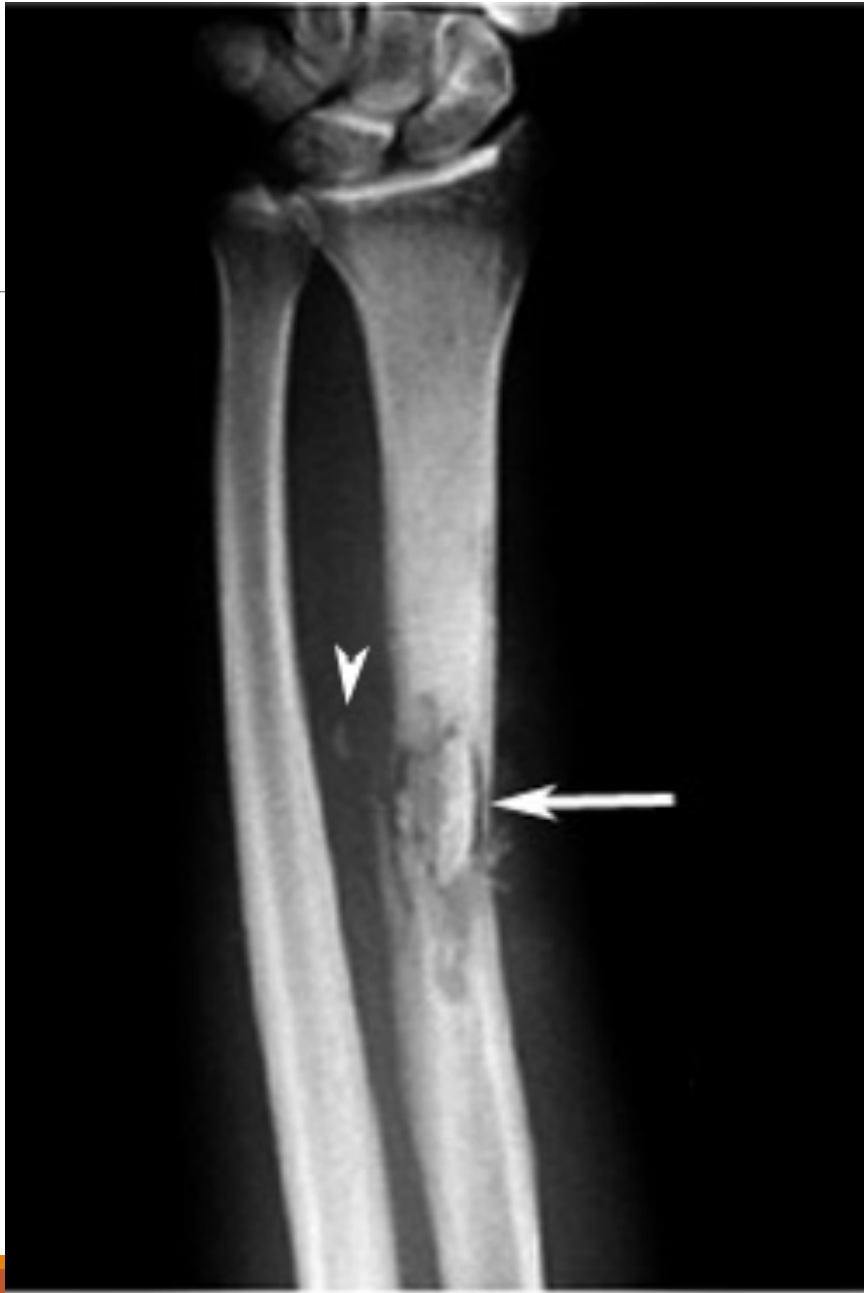1st x ray findings 2 wks

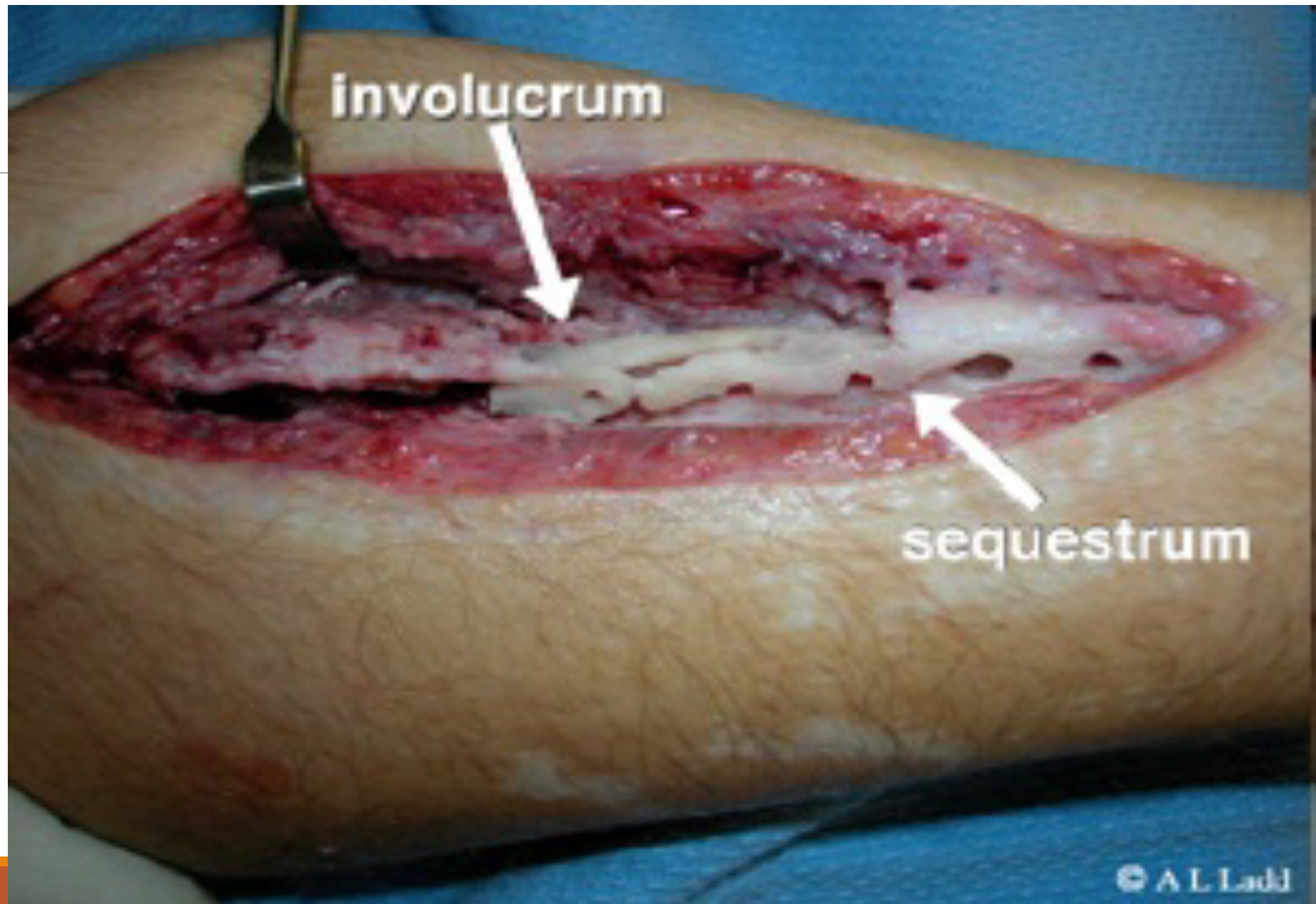
-The new bone formed is called **involucrum**, (**perioseal reaction**)

- The increased blood flow will lead to hypo dense areas called **rarefaction**.



- (A) bone
- (B) new bone (involucrum)
- (C) granulations lining involucrum
- (D) cloaca
- (E) sequestrum. No poles





Clinical Presentation

History (usually a child)

- Pain (Gradual), malaise, fever. Acute
- History of a preceding URTI/ UTI, skin lesion. Surgery, trauma, open fracture

P/E

- Very tender limb
- Redness, warmth and edema
- Limited Range of motion (due to pain) SA no range of motion

Clinical presentation in

- Infants (failure to thrive, irritable, tender, refuse feeding, decrease range of motion)
- Adults (back pain mainly)

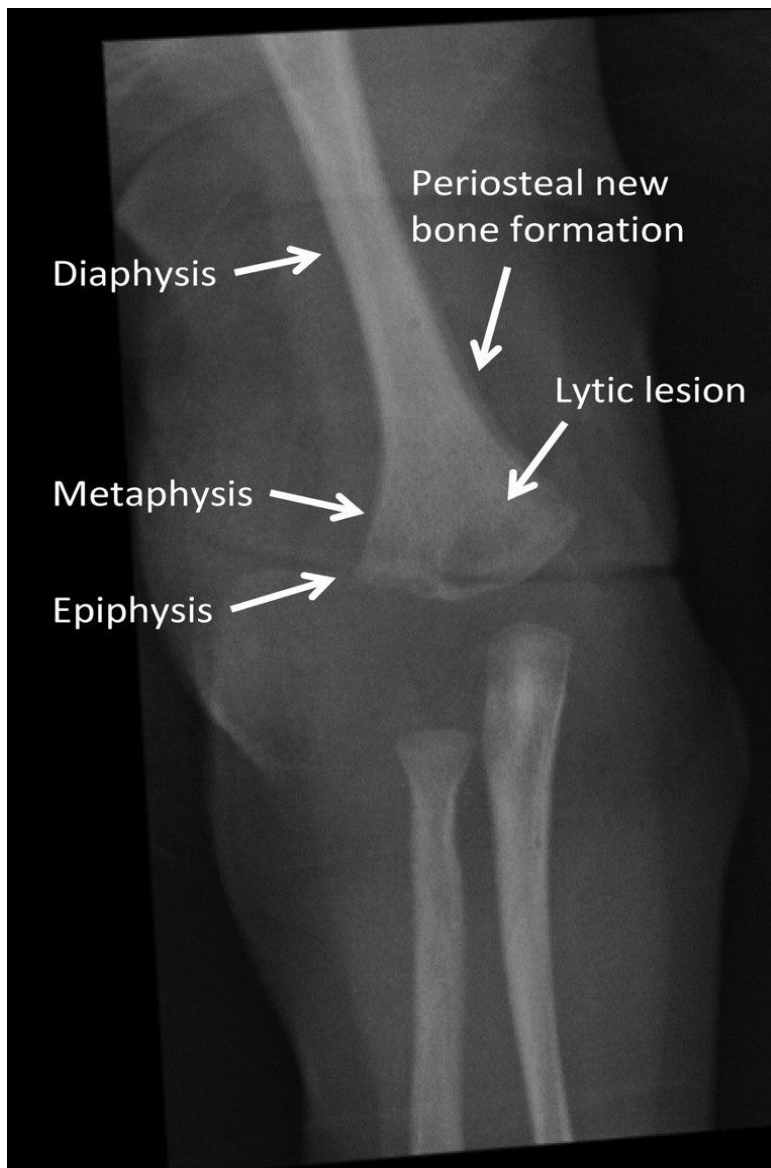
Imaging

➤ X-ray

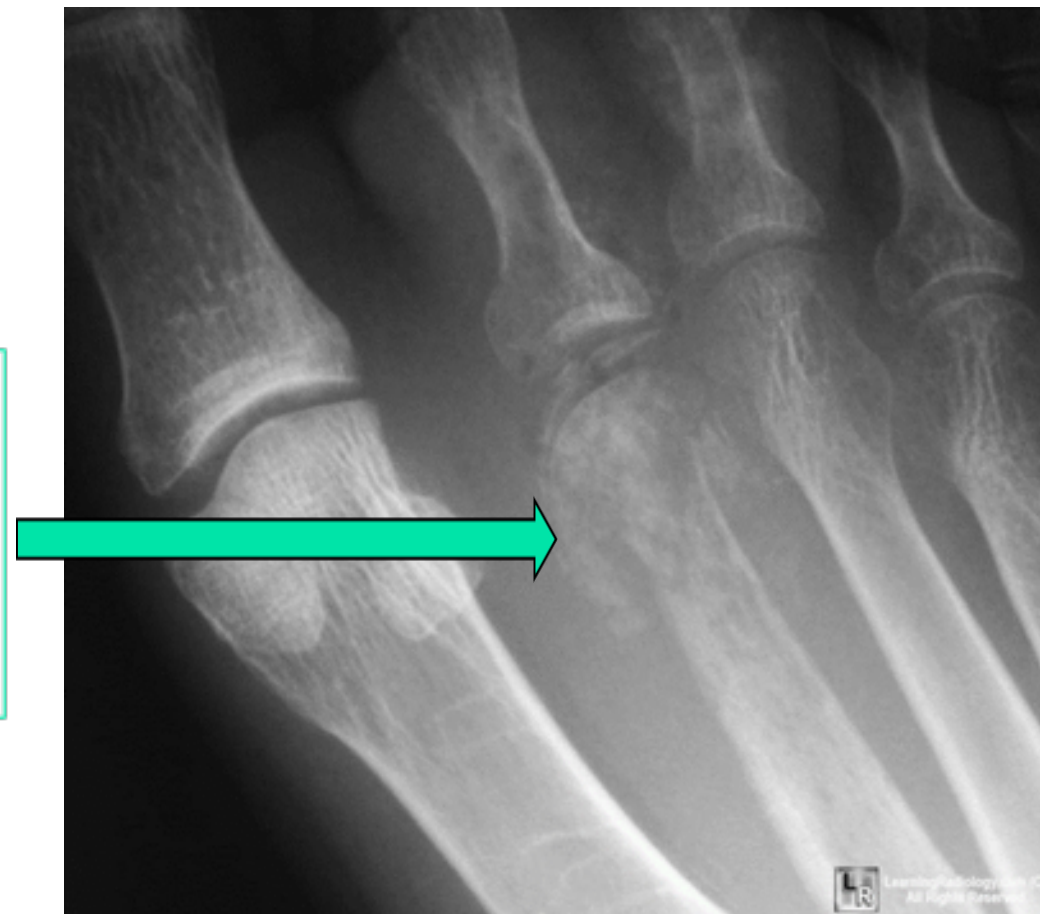For the first 10 days X-ray is normal : no bone findings (bone edema can be detected early via MRI , there is only soft tissue edema

- Periosteal reaction on X-ray which is the earliest sign of CHRONIC O.M.
- The sequestrum appears a bit whiter than normal bone on x-ray; because of the loss of normal bone structure

-
- MRI (bone vs soft tissue infection) 100% Sensitive (-ve MRI can rule out O.M) but not specific
 - FNA : To confirm Dx (not performed if MRI is done)
 - U/S: presence of an abscess

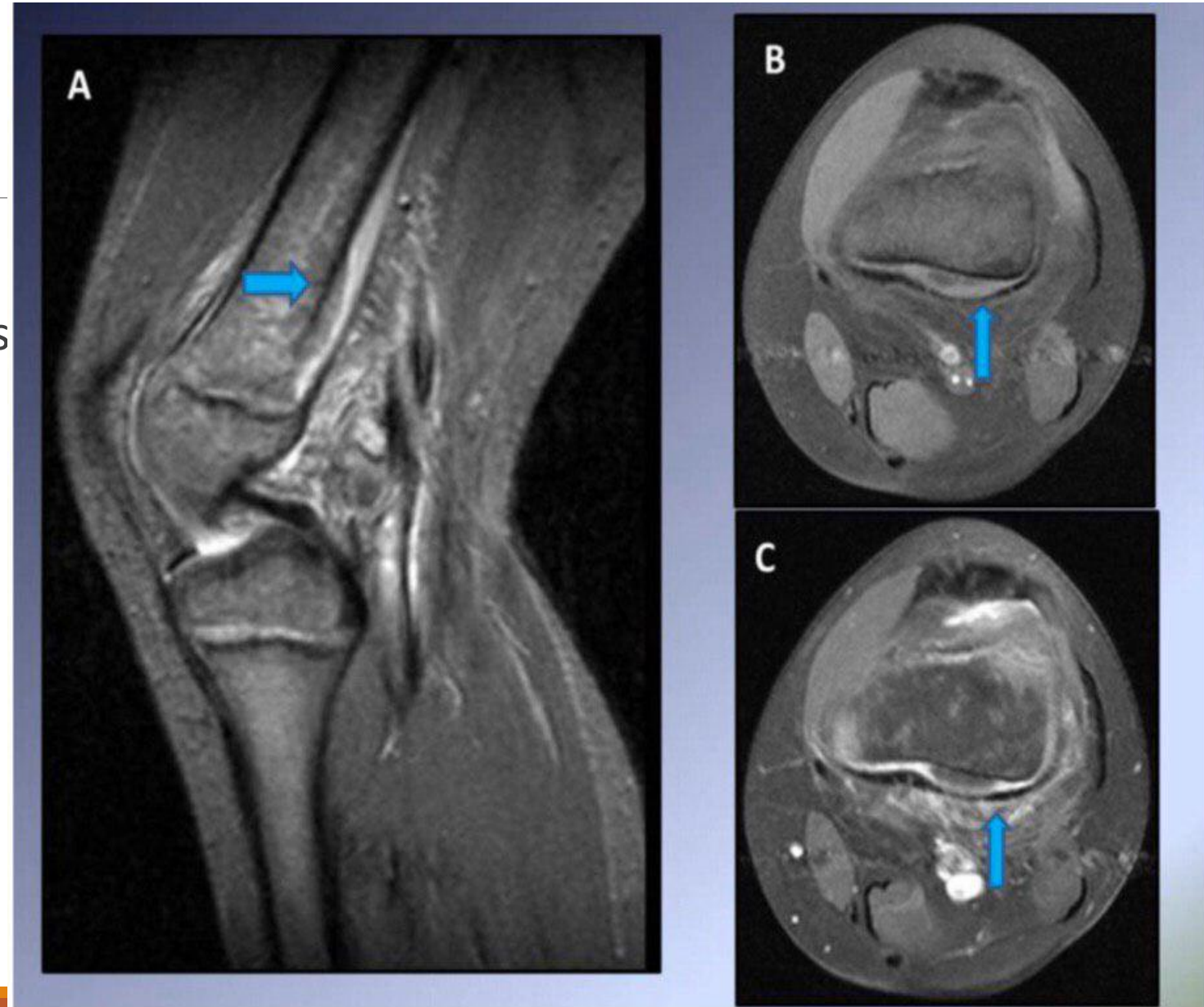


Bone destruction of head of 2nd metatarsal with periosteal new bone formation characteristic of osteomyelitis



-subperiosteal abscess

-This represented early Staphylococcus
osteomyelitis



Investigations

1. CBC: leukocytosis
2. CRP, ESR: elevated 99% sensitive
3. Blood culture (+ve 30% of cases) Before giving AB
4. Aspiration Biopsy (Good, only 10-15% false negative) painful, preferably do an MRI before
5. Bone Biopsy for Culture (Definitive diagnosis of osteomyelitis)
6. Anti-staphaylococcus antibodies

Differential Diagnosis

Cellulitis : mcc is streptococcus pyogen

Septic arthritis

Streptococcal necrotizing myositis

Acute suppurative arthritis

Acute rheumatism 1st attack

Sickle cell crisis

Gaucher's disease

Treatment

- Systemic IV Antibiotic → Augmentin for 6 weeks, covers most of the bacteria (two thirds) that causes acute osteomyelitis, the other $\frac{1}{3}$ needs surgical debridement.
- Oral antibiotic have no role in bone infections Bone bioavailability less than soft tissue
- In ER → Cannula : Blood culture (+ve in 30% of cases) , IV fluids then IV ANTIBIOTICS

Surgical Indications:

No pain relief, fever, CRP remains high, abscess formation

- 1- Failure to respond to antibiotics within 48 to 72 hrs, the patient comes with: Persistence of symptoms, Patient is still febrile, CRP is still elevated.
- 2- Chronic osteomyelitis.

Complications

Chronic osteomyelitis

Septic arthritis

Growth disturbance

Septicemia

DVT

Pulmonary embolism

Subacute Hematogenous Osteomyelitis

Relatively mild (less virulent organism or patient resistant)

staph

Common sites:

- Distal femur
- Proximal and distal tibia/ fibula
- Distal radius

Clinical picture ...child ..dull aching pain for several weeks(>3 months), localized pain , near a large joint often nocturnal , alleviated by aspirin

ما يعرف بنام
مش بنام وبصحي من الوجع

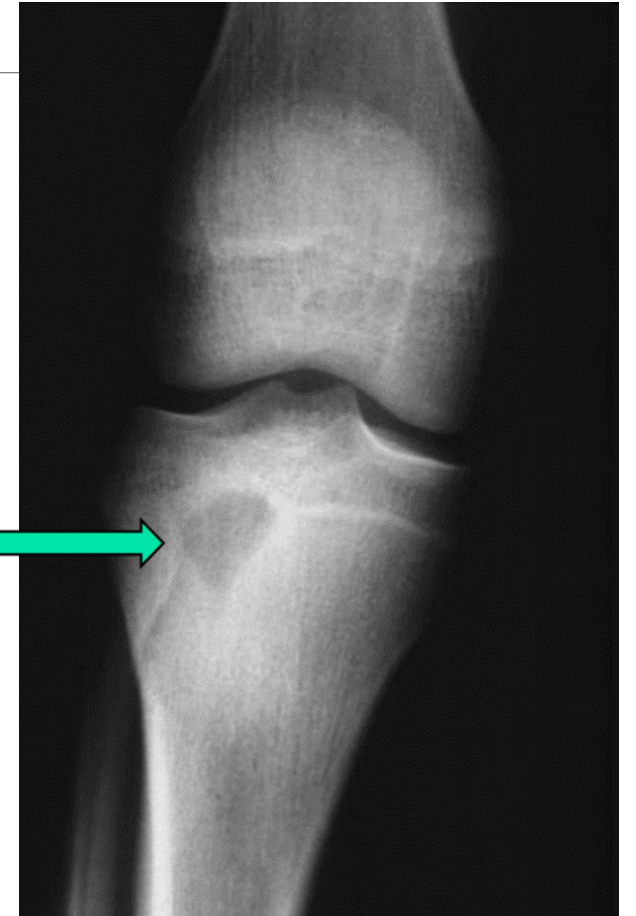
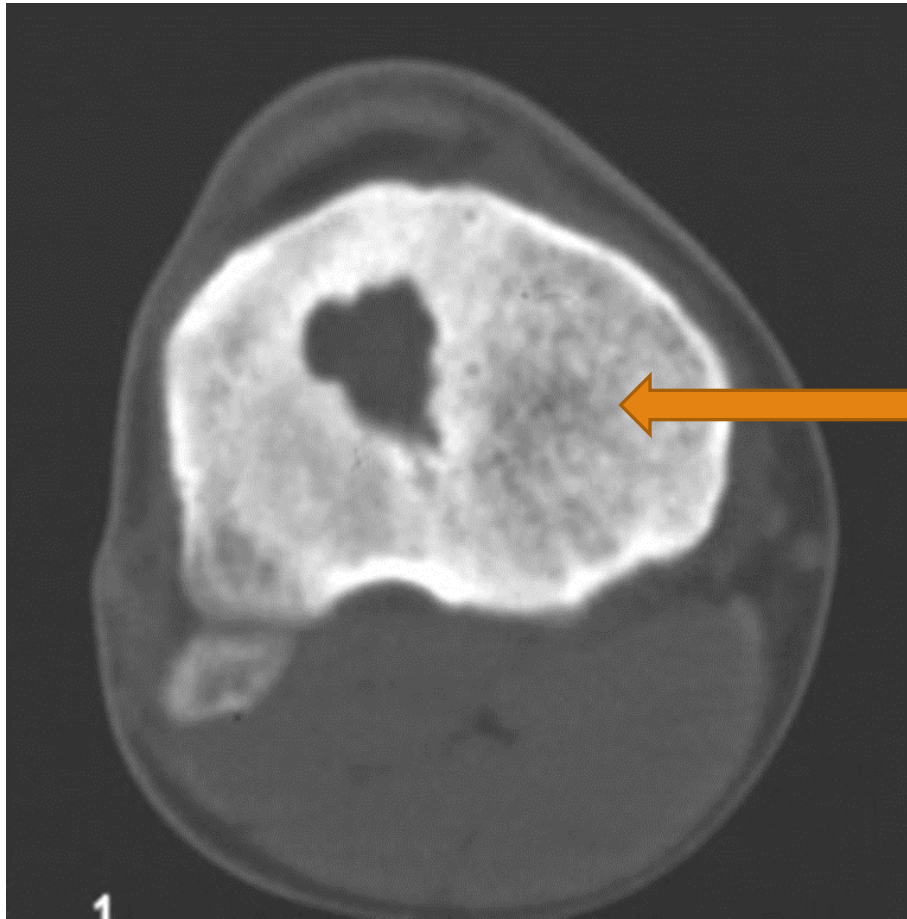
Brodie's abscess

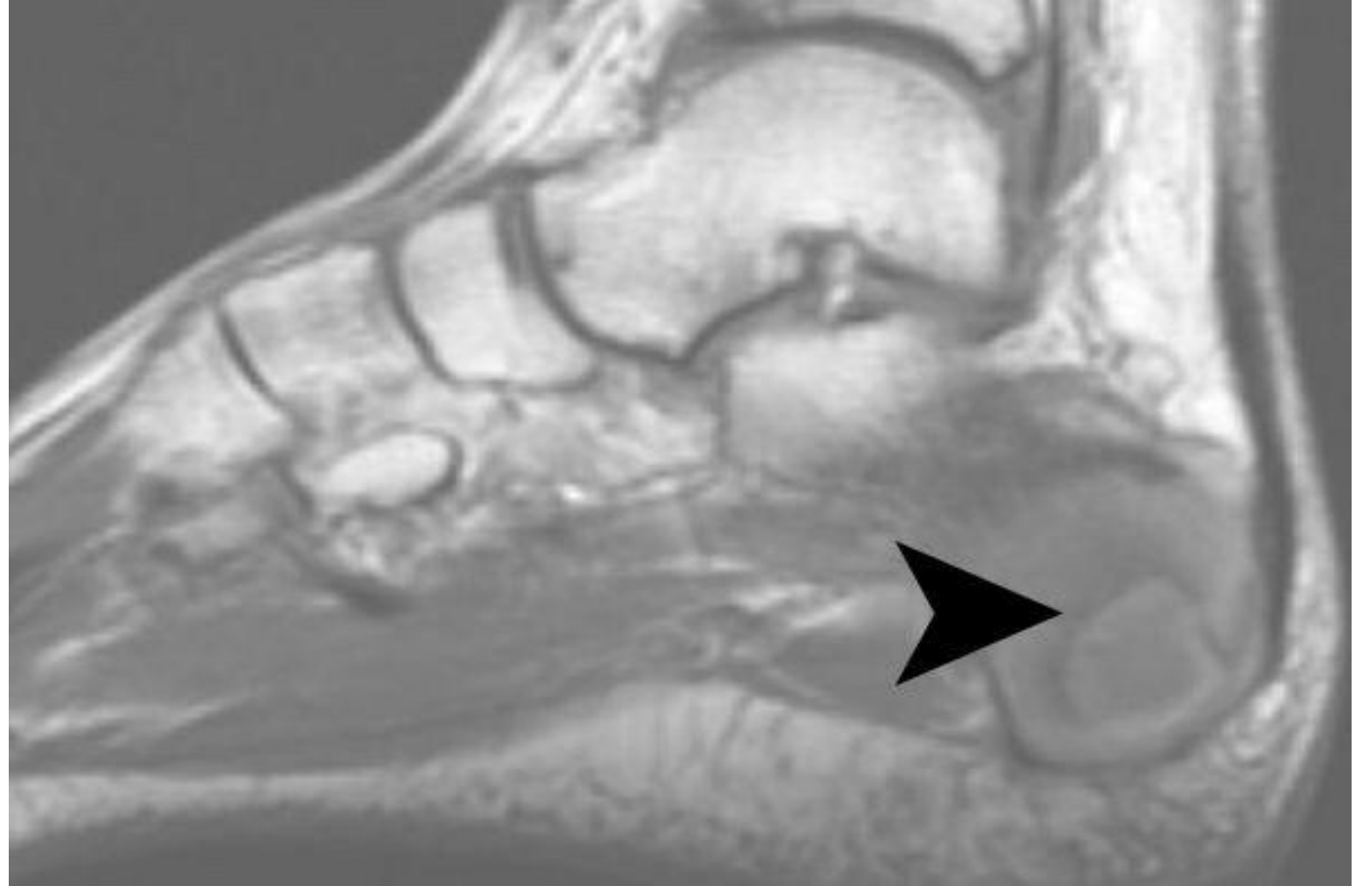
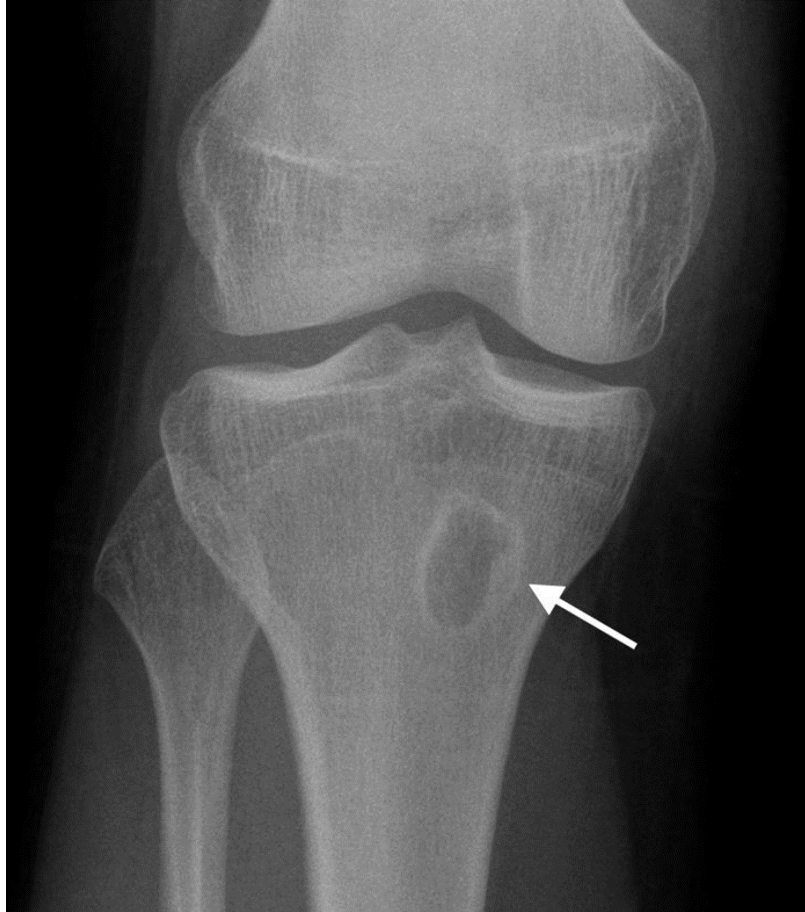
- A subacute OM, may persist for years before converting to a frank osteomyelitis (may present after conversion of a draining abscess extending from the tibia out through the shin)
- Occasionally acute osteomyelitis may be contained to a localized area and walled off by fibrous and granulation tissue

Brodie's abscess

- Circumscribed, round or oval cavity 1-2 cm in diameter
- Most often seen on the tibial or femoral metaphysis
- Confused with Osteoid osteoma (less than 1 cm)
- Treatment :- mainly surgery
- Imaging: CT

Brodie's Abscess





investigations

WBCs: generally normal.

ESR : elevated in only 50% of patients.

Blood culture: usually negative.

Plain radiographs and bone scans: positive

Chronic Osteomyelitis (>3wks)

Fibrin deposition

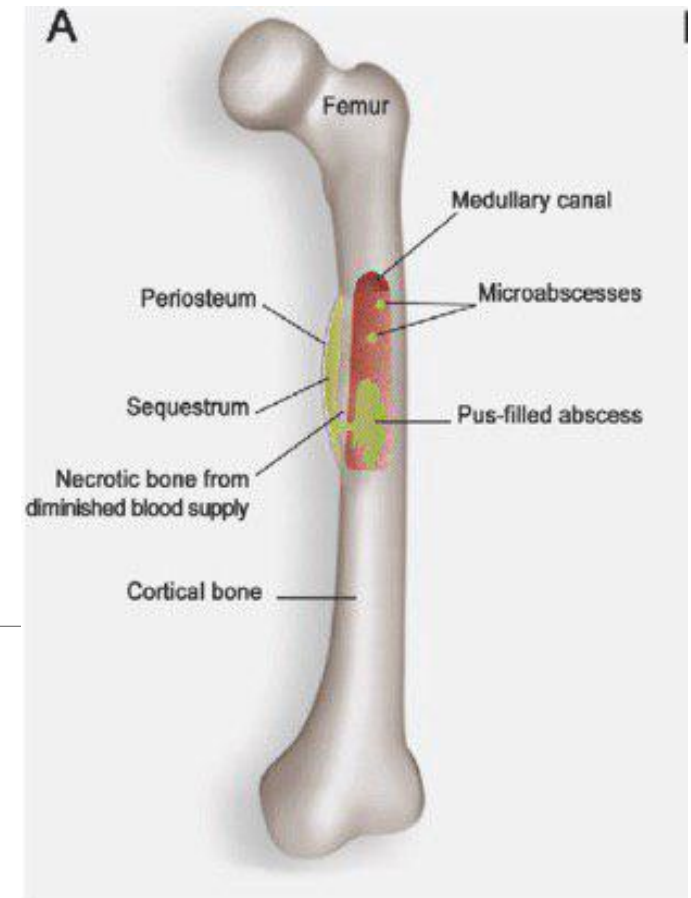
- Follows acute infection
- Chronic from the start

M.C. Organism: **Staph. Aureus** Mixed

Sequestra are usually present (**pathognomonic** of chronic osteomyelitis)

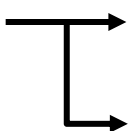
Caused by:

- Acute osteomyelitis
- Open fracture
- Operation



Chronic Osteomyelitis

Organisms

- Most common: **mixed** (non healthy bone can attract different bacteria) → 50% S. Aureus
 - Staph epidermis → metal or screw implant with chronic presentation
 - Post op 
 - acutely → Staph S. Aureus 5 days-2 wks
ما في Infection اقل منه ايام
 - a year later → Staph epidermis
- Endolent
Less vurelent microorganism
Chronicde novo
3 months - 2 yrs
- S pyogens and shigella dysentery
More vurelent
2 days to cause infection

Chronic Osteomyelitis

Clinical Presentation:

- Recurrent bouts of pain, redness and tenderness.
- Healed and discharging sinuses.
- X-ray Bone rarefaction (↓ density) surrounded by dense sclerosis and cortical thickening.
- Sequestrum.
- Bone scan : reveal hidden foci with inflammatory activity .

Chronic Osteomyelitis

Treatment

Depends on the frequency of relapsing flare-ups.

Surgical

- Sequestrectomy
- Muscle flap transfer
- Ilizarov method (external fixation)

Antibiotics following surgery, not before to avoid altered cultures

Posttraumatic Osteomyelitis

Open fractures

Staph. Aureus m.c.o

Prophylaxis

- Irrigation with normal saline or derivatives (3litres in GA I, 6 litres in GAII, 9 litres in GAIII)
- Sterile dressing
- Analgesia (narcotics)
- Splint
- Antibiotics (Augmentin till GA type II add gentamycin)

Or cefiroxim

ATS- anaphylaxis

TT

Ringer Lactate

3 carbon atom, bacteria can feeds from it

War conditions

Tap water

Postoperative Osteomyelitis

- *S. epidermidis* is common
-
- High affinity to metal
Biofilm 4 before start of infection

Predisposing factors:

- Debility
- Chronic disease
- Previous infection
- Steroid therapy
- Difficult or long operations
- Hematoma formation
- Wound tension
- Tight dressings or plasters
- Use of foreign material.

Treatment (Removal of implants, Abx ttt, revision for arthroscopy)

Acute Suppurative Arthritis (Septic arthritis)

Microbiology

- *Staph. aureus*
- *H. influenzae* (Common in children <4yrs)

Peds hip
Adults knee

Hip position
Flexion external rotation abduction

Clinical presentaion

- Acute pain and swelling in a single large joint

Knee
Semiflexed 15°

Shoulder
Adduction internal rotation

Decrease tention of capsule

Local signs:

- Superficial joints (tenderness, erythema, swelling)
- Pseudoparesis (restricted movement due to pain and spasm)
- Picture of septicemia in infants.

Septic arthritis

most common site in paediatrics is the hip

in adults, the knee.

Hematogenous

Diabetic foot more than knee

It's a TOP MEDICAL EMERGENCY! Needs to be operated within 8 hours

Route of infection:

- Hematogenous
- Dissemination from acute osteomyelitis focus
- Dissemination from acute soft tissue infection
- penetrating injury.
- iatrogenic

Septic arthritis

Imaging

- **X-ray**
 - Soft tissue swelling, widened joint space, periarticular osteoporosis
 - Narrowed joint space. Lysis of articular cartilage
Pus 1 wk-- whole epiphysis loss
 - Bone destruction
- **MRI**
- **Bone scan**

Investigations

- Joint aspiration (confirmatory)
- Blood culture (+ve in 50%)
- CBC, ESR, CRP (not diagnostic)

Septic arthritis

Acute infective synovitis

Treatment & Complications

Treatment

- Drainage
- Antibiotics
 - Augmentin
 - 3rd generation cephalosporin

Complications :

- Dislocation (due to tense effusion)
- Epiphyseal destruction (Tom Smith's dislocation)
- Growth disturbance ذاب ال joint
- Ankylosis (late)

Kocher Criteria to differentiate between septic arthritis and reactive arthritis

Groin pain with

1- inability to bear weight (most important)

2- $T > 37.8$

3- $ESR > 40$ or $CRP > 20$

4- White Blood Cell Count > 11.8

If all More than 90 % septic arthritis

If nil Less than 10% septic arthritis

If in doubt Deal as septic

Parvovirus 5th disease
RA like pic

Joint aspiration criteria for infection Adults only

White cell count > 50 000 diagnostic of infection >25000 suggestive

Neutrophils > 90% diagnostic >80% suggestive

Bacteria on gram stain diagnostic

Positive culture is pathognomonic

Other causes >50000

Gout (needle shaped orange - ve birefringes)

Leukemic infiltrate

Foreign body rxn

Tuberculosis

Bones and joints are affected in 5% of TB patients.

TB meningitis and military TB
Prevented by vaccine

Vertebral bodies & large synovial joints mainly affected

Pathology

- Caseating granuloma
- Cold abscess

Vertebral TB

- Anterior part of vertebral body
- Gibbus On single vertebrae

Joint TB

- Chronic monarthrititis of a large joint.
- Ankylosis

Tuberculosis

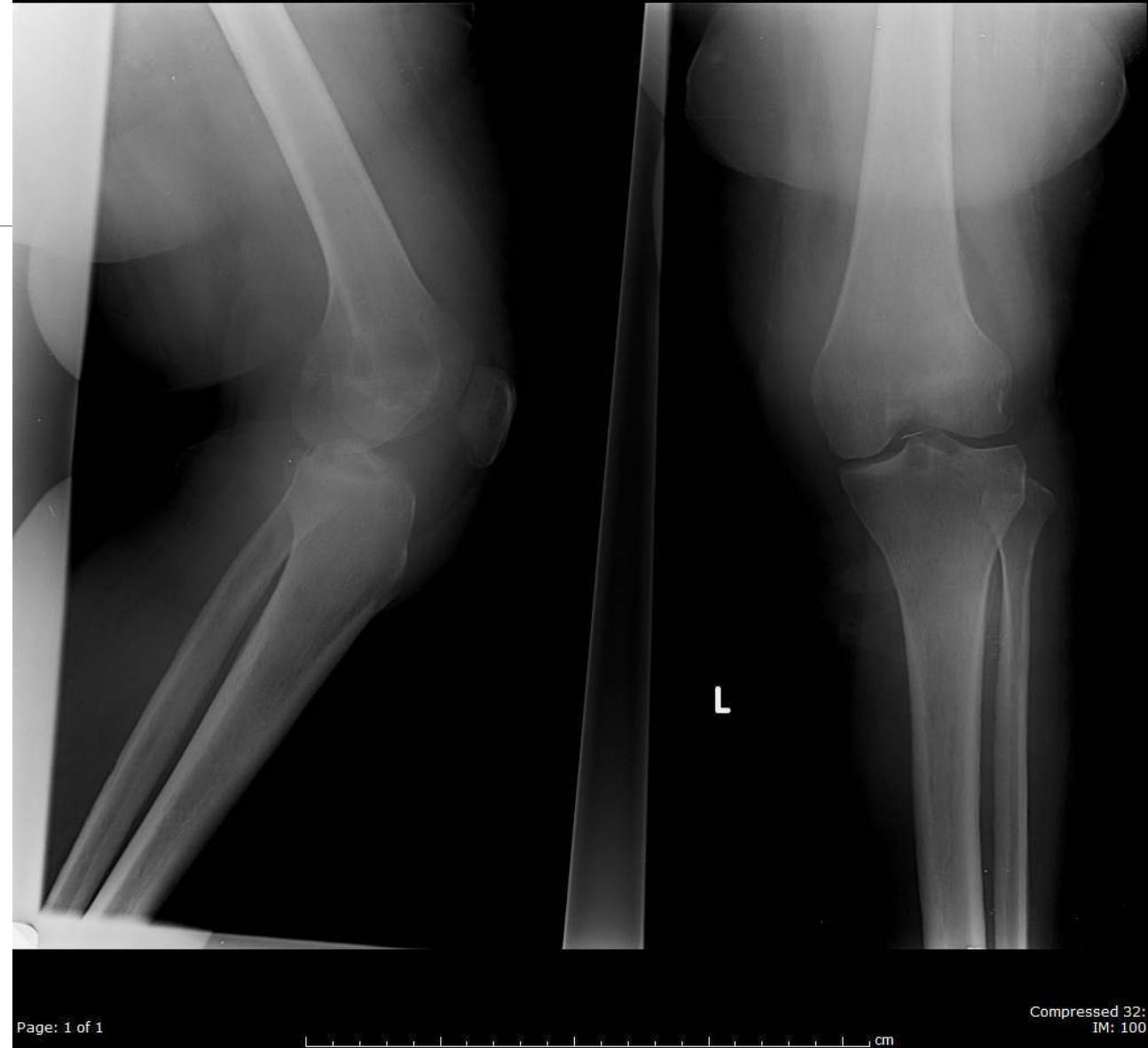
Clinical Features

- Joint TB Chronic de novo
 - Pain & swelling
 - Muscle wasting Knee vastus medialis
Shoulder infraspinus fossa
 - Synovial thickening
 - Movement limitation
- Spine TB Ant: groin abscess, lat: motor and sensory deficit of a nerve root, post: transection of spinal cord-Potts paraplegia & incontinence
 - Localized kyphosis
 - Weakness/ sensory deficit (when pus opens in the spinal canal)
 - Pott's paraplegia (if ttt is delayed)

Tuberculosis

X-Rays

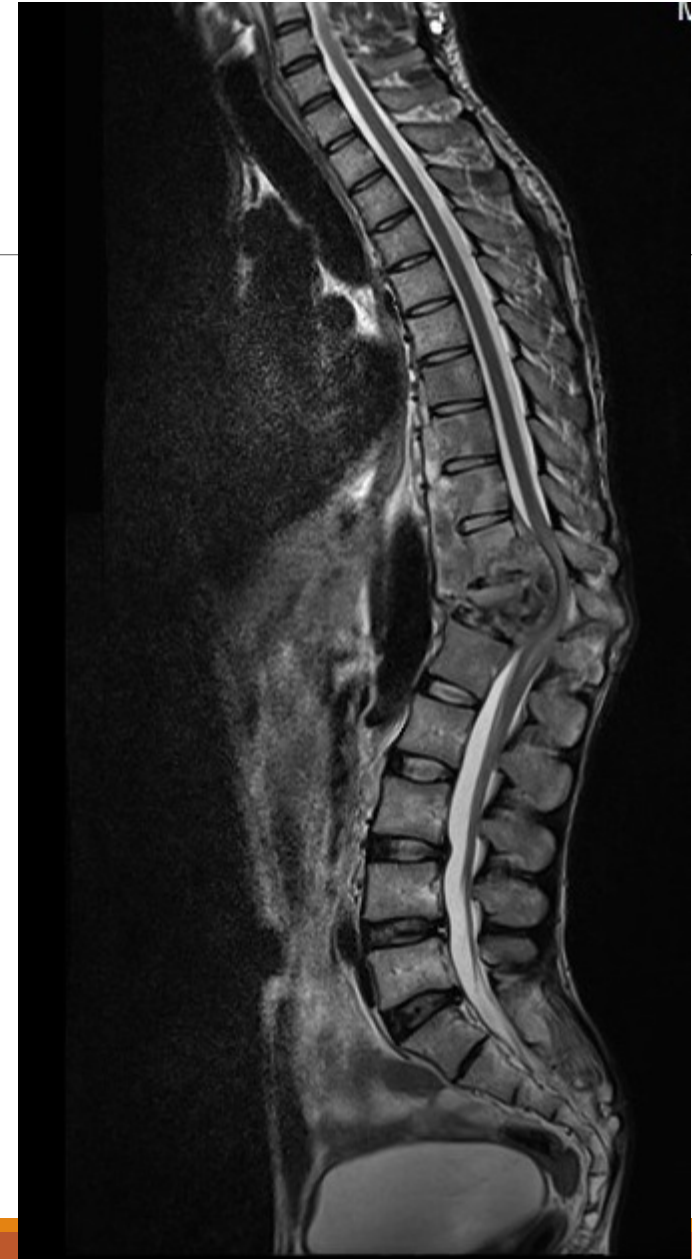- Tuberculous arthritis
- Soft tissue swelling
- Rarefaction of the bone
- Narrowed, irregular joint space
- Bone erosion.
- Cystic lesions



Tuberculosis

X-Rays

- Tuberculous spondylitis:
- Localized bone erosion
- Collapse in an intervertebral disc
- Soft-tissue trace of paravertebral abscesses.



Tuberculosis

Treatment

Antituberculosis chemotherapy

- Rifampicin, Isoniazid & ethambutol (or pyrazinamide)
 - for 2 months

Optic neuritis

Peripheral neuropathy & hepatotoxicity
- Rifampicin & isoniazid
 - for 4 months

Local measures:

- Rest, traction, and occasionally operation

Infective bursitis
S aureus
Drainage of pus
Antibiotic

Thank You