



MEDICAL UNIVERSITY
OF VIENNA



THE UNIVERSITY OF
JORDAN



ARAB SCHOOL
OF UROLOGY

Bladder cancer

Mohammad Abufaraj

Associate Professor of Urology

The University of Jordan

Adjunct Professor of Urology

Medical University of Vienna

Co-Editor

Arab Journal of Urology



MEDICAL UNIVERSITY
OF VIENNA



THE UNIVERSITY OF
JORDAN



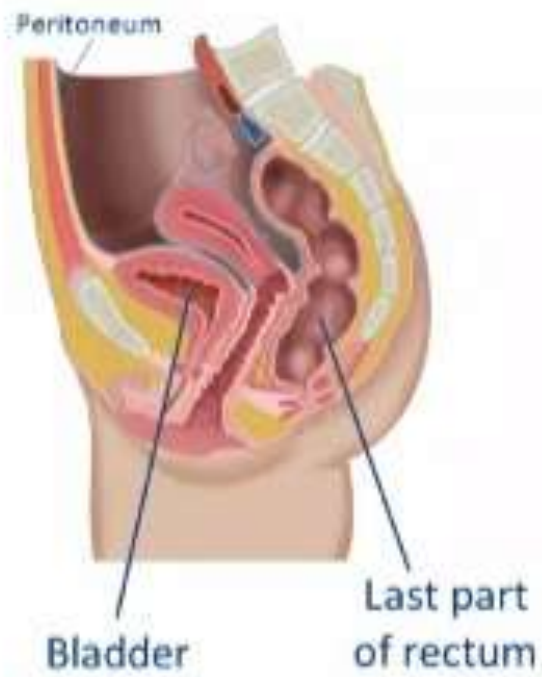
ARAB SCHOOL
OF UROLOGY

Bladder cancer

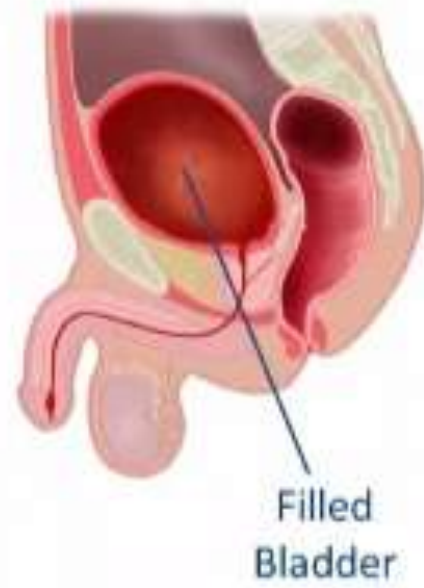
Mohammad Abufaraj

mohammed A

Subperitoneal



Preperitoneal

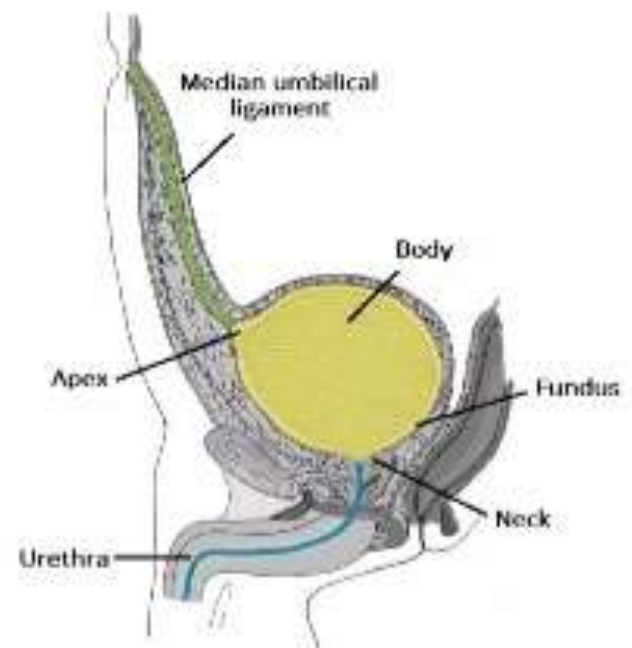


© 2008 Elsevier Inc. All rights reserved. www.sciencedirect.com



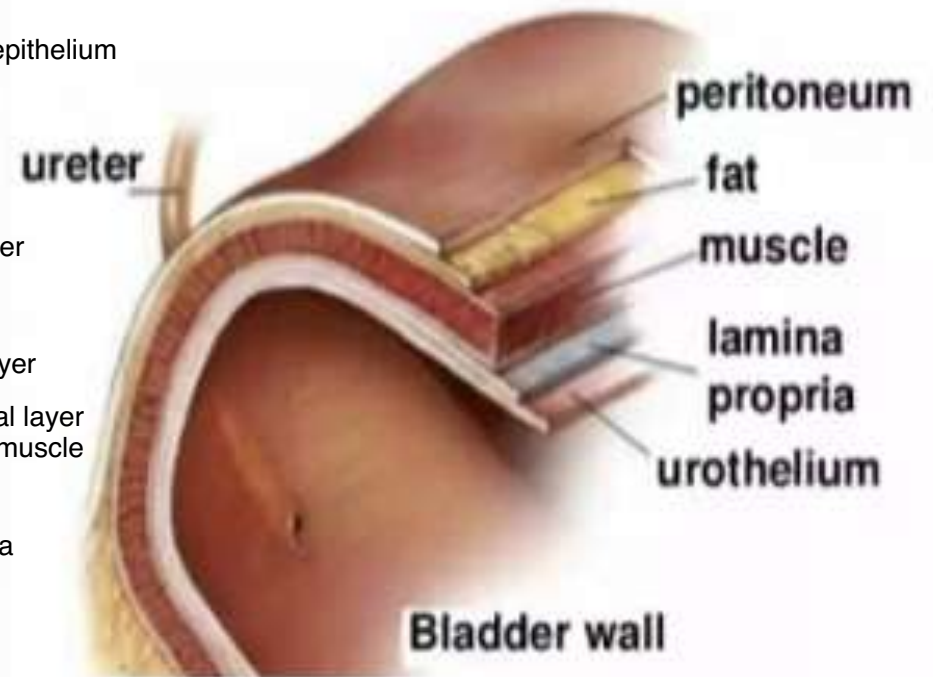

❖ *Parts of the Urinary Bladder:*

- **Apex** (attached to median umbilical ligament which connects bladder with umbilicus)
- **Body** (resevoir for urine)
- **Neck** (narrow portion leading to urethra)
- **Fundus** (located in the posterior wall of the bladder, contains the trigone)



r

Layers of the Bladder Wall



Epidemiology

- Male
- Affect men more than women 4-3:1
- Higher incidence in whites than in African Americans
- In middle-aged and older adult males, bladder cancer is the second most prevalent malignancy after prostate cancer
- Age: average age is 65

- Risk Factors

- Smoking; 50% of cases: 3-fold increased risk relative to non-smokers (aromatic amines, arsenic, polyaromatic hydrocarbons (PAHs), aldehydes)
- Aromatic amines exposure: in rubber, plastic, dyes, paint, metal and leather industries

- Almost all bladder cancers are epithelial in origin:
 - **More than 90% are transitional cell carcinomas (urothelial carcinoma).**
 - 5% of bladder cancers are squamous cell carcinomas
 - 2% are adenocarcinomas.
 - Non-urothelial primary bladder tumors are rare;
(SCC, carcinosarcoma, primary lymphoma, sarcoma)

Histological subtype

- Urothelial carcinoma

- Squamous cell carcinoma

Persistent inflammation due to long-term indwelling Foley's or bladder stones.

In underdeveloped countries, associated with *Schistosoma haematobium* (Bilharzia) bladder infection "Egypt".

Prognosis for bilharzial better than for non bilharzial.

- Adenocarcinoma

Glandular phenotype (Urachal and non-urachal adenocarcinoma)

bladder exstrophy

remnant of urachal

long history of cystitis

cystoplasty.

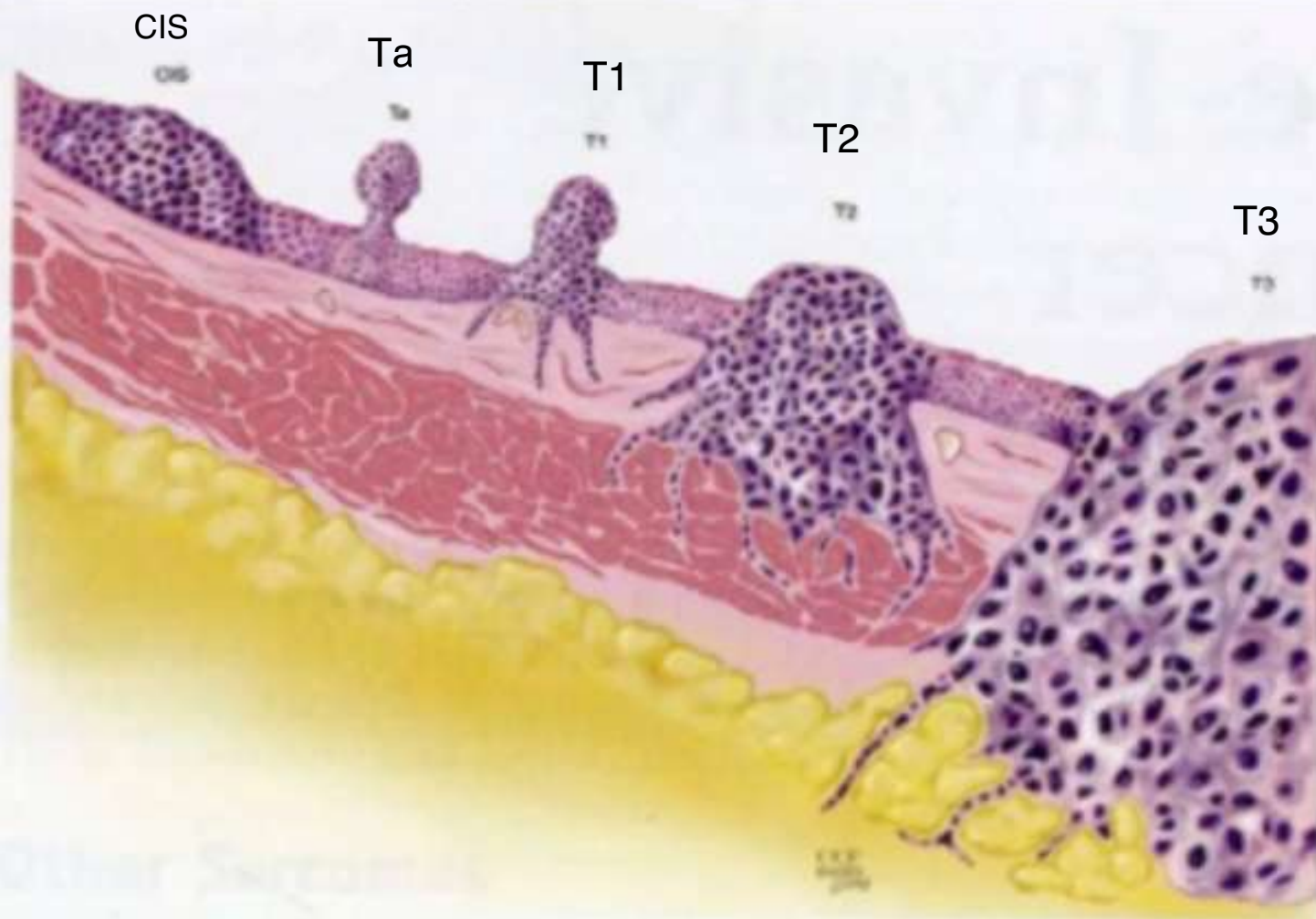


Figure 76-1. CIS is a high-grade, flat malignancy confined to the urothelium. Papillary tumors confined to the urothelium are Ta, whereas papillary tumors invading lamina propria are T1. The T1 tumor here intertwines with the wispy fibers of the muscularis propria but by definition does not invade the smooth muscle fibers of the detrusor. T2 tumors invade the detrusor muscle, and T3 tumors are into extravascular fat as shown.

Presentation

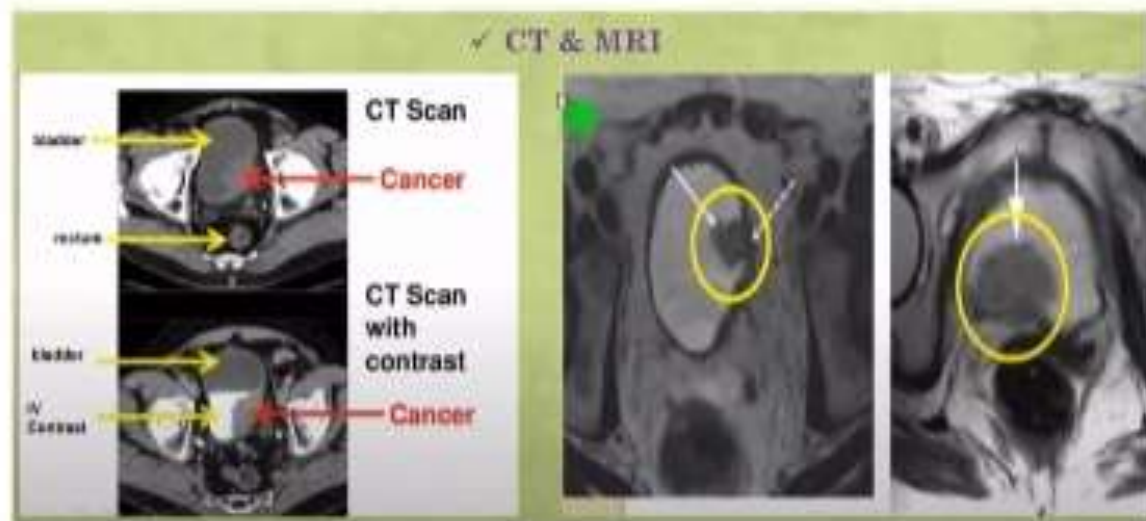
- Painless gross hematuria
- Irritative voiding symptoms
- Urine retention due to a clot
- Incidentally

Unremarkable in most patients, but may find:

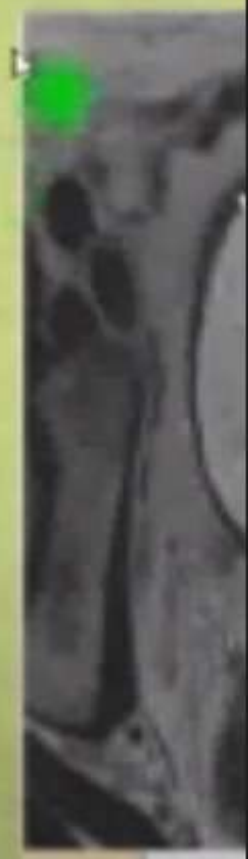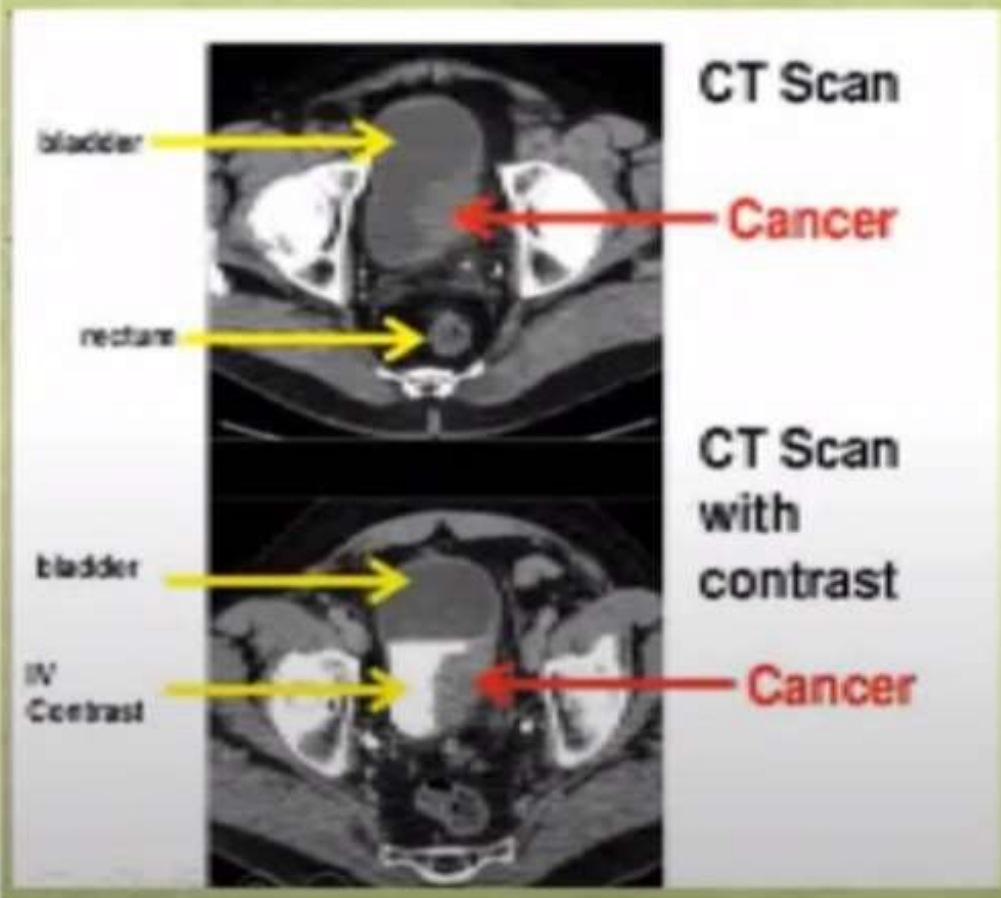
- Induration of the prostate gland can sometimes be felt on DRE (bladder neck ca invading the prostate).
- A solid pelvic mass may be felt in advanced cases.
- Nodularity in the periumbilical region can be seen in advanced lesions involving the dome of the bladder. (urachal cancers)
- Enlarged para-aortic lymph nodes or hepatic metastases

Diagnostic workup

1. Cystourethroscopy
2. Urine cytology
3. UTCT (unenhanced)
4. Urinary biomarkers



✓ CT & MRI



✓ CT & MRI

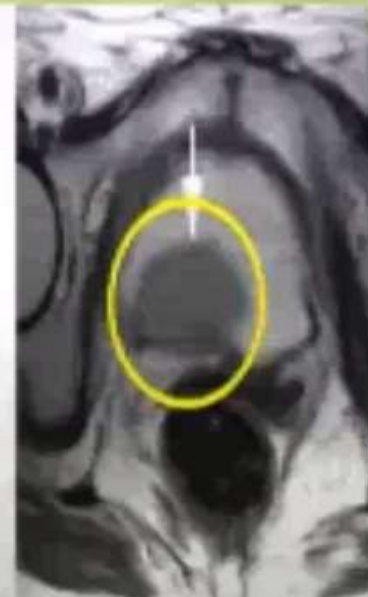CT Scan

Cancer

CT Scan

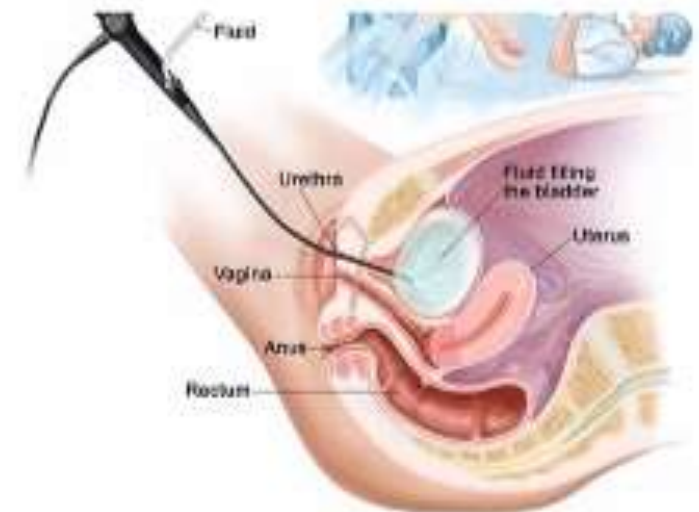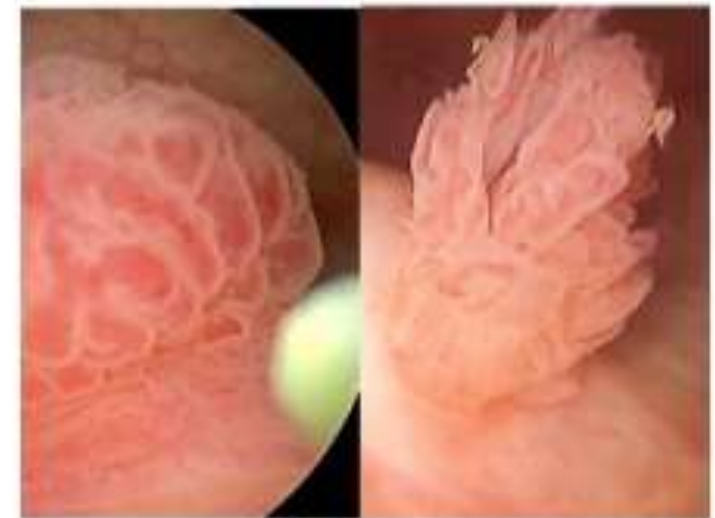with
contrast

Cancer



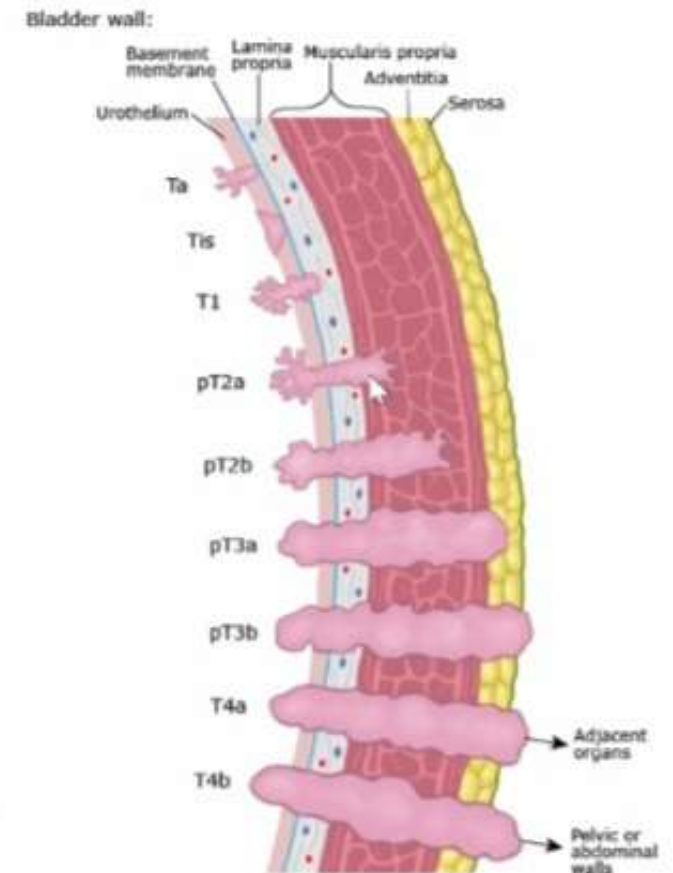
Cystourethroscopy

- Gold standard for
 - - initial diagnosis and staging
 - - to determine the histology and depth of invasion
- Definitive diagnosis made on biopsy taken by rigid cystoscope
- EAU recommends Fluorescent cystoscopy for CIS detection.



Pathological Staging (TNM classification)

- Ta: non-invasive (papillary) exophytic lesions
- Tis: carcinoma in situ
- T1: invasion of lamina propria or submucosa
- **T2: invasion into muscle**
- T3: extend beyond muscle into perivesical fat
- T4: extending into adjacent organs
 - T4a: extend into prostate, vagina, uterus, bowel
 - T4b: fixed to abdominal or pelvic walls



Management

- Treatment of urothelial tumors depends on many factors including the presence of muscle invasion, metastasis (staging) and grading, among others. *(Non-muscle-invasive vs muscle-invasive tumors)*
- Treatment modalities include:
 - Transurethral resection of bladder tumor (TURBT)
 - Intravesical chemotherapy (mitomycin or gemcitabine)
 - Intravesical BCG
 - **Bacillus Calmette Guerin** – A live attenuated mycobacterium that stimulated immune cells at site of injection. Activated immune cells can target and kill tumor cells
 - Radical cystectomy
 - Palliative systemic chemotherapy (systemic disease)
- Treatment of non-urothelial carcinomas (squamous, adenocarcinoma) is mainly surgical.

- Non-muscle invasive (Ta, Tis, T1) treatment: TURBT + intravesical therapy
- Intravesical therapy: 1) intravesical chemotherapy (mitomycin and gemcitabine) for low or intermediate-risk tumors or 2) intravesical immunotherapy (BCG) for high-risk patients (e.g., Tis)

Management: Muscle-invasive ($\geq T2$):

- Radical Cystectomy
- Males: Radical cystoprostatectomy with pelvic lymph node dissection
- Females: Anterior pelvic exentration of uterus, fallopian tubes, ovaries, bladder, urethra and segment of anterior vaginal wall.
- After radical cystectomy, urinary diversion is needed. This can be achieved via:
 - Ileal conduits
 - Cutaneous continent reservoir (e.g., Indiana pouch)
 - Orthotopic neobladder
- Neoadjuvant Chemotherapy (regimens include MVAC (methotrexate, vinblastine, doxorubicin, cisplatin) or gemcitabine + cisplatin)

Urinary diversion

