

FORENSIC & TOXICOLOGY SUMMARY

Done by Shahed Atiyat

Edited by dr. Farah

Death and postmortem changes

- ✓ Study of death in all its aspects is known as **thanatology**.
- ✓ **Cause** of death: injury or disease (stab wound, adenocarcinoma, ...).
- ✓ **Mechanism** of death: physiologic derangement produced by the cause of death (hemorrhage, acidosis, ...).
- ✓ **Manner** of death: how the cause of death came (natural, accidental, homicide, suicide or undetermined).
- ✓ **Mode** of death: the abnormal physiologic state that pertained at the time of death (coma, syncope, or asphyxia).
- ✓ **Agonal period**: the time between a lethal occurrence and death.

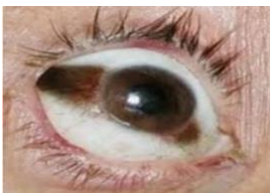Postmortem changes (Immediate, early & late):

Immediate changes (Somatic death)

1. Irreversible cessation of the function of brain (earliest sign). Flat EEG
 - Loss of motor and sensory functions, loss of muscle tonicity, loss of reflexes, dilated pupils.
2. Irreversible cessation of respiration (>4 min). No breath sounds
3. Irreversible cessation of circulation (>3-5 min). Flat ECG

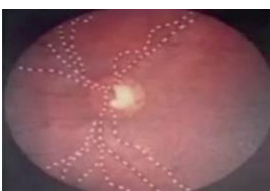Early changes (Molecular death)

1. Facial pallor and loss of skin elasticity.
2. Primary relaxation and flaccidity of the muscles (the muscles still alive), due to the loss of muscle tone, **1 h after death**.
3. Contact flattening and pallor.
4. Changes in the eyes:
 - ❖ Loss of corneal and pupillary reflexes.
 - ❖ Pupils: constricted (was dilated in immediate changes).
 - ❖ Tache noire.
 - ❖ Kevorkian sign
 - ❖ Loss of intraocular pressure (from 10-22 mmHg to zero **within 4-8h**).
5. Algor mortis. "cooling"
6. Livor mortis. "postmortem staining/lividity/hypostasis"
7. Rigor mortis. "stiffness"



Tache noire

- Starts as red triangles in sclera then yellow >> brown >> black.
- Happen due to incomplete closure of the eyelids which results in **drying** and **deposition** of cellular debris, mucus (**3-4h** after death).



Kevorkian sign

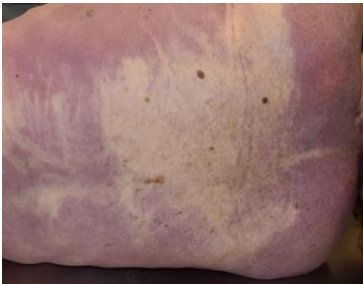- Retinal vessels appear segmented (cattle trucking or shunting).
- Happens within **seconds to minutes** and **persists for about an hour**.
- It happens in all the vessels in the body.

Algor mortis

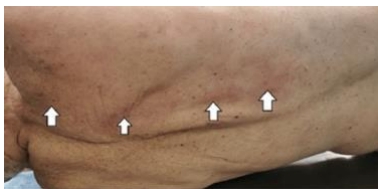- ❖ **Cooling of the dead body**, where the body temperature equilibrates with its environmental temperature due to cessation of the energy production and inactivity of the heat regulating center.
- ❖ Rate of cooling depends on: age, clothing, posture, cause of death (temperature can raise postmortem in case of hyperthermia or sepsis [caloricity] environment temperature [the most important], mode of death, body size.
- ❖ The average rate of fall of the body temperature is 0.4-0.7°C/h [in the slide it is 1 °C/h] and the body attains environmental temperature in **16-20 h** after death.
- ❖ **Rapid cooling delays the rigor mortis and decomposition.**

The measurement of the inner core temperature (**rectally, esophageal or subhepatic**) is more reliable than the outer surface temperature

Livor mortis

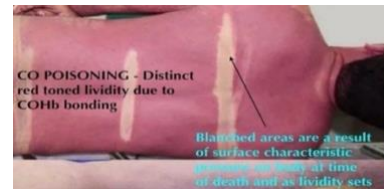

- Normal color is **bluish or purplish-red** discoloration.
- Cause: Gravitational settling of the blood in the toneless vessels.
- Site: Undersurface of skin in the superficial layer of the dermis.
- The non-stained areas are called **contact pallor (due to the pressure)**.
- **Starts immediately after death, appears after 30 min to 1 h as small patches fully developed in 5-6h. If the body is undisturbed, it will be fixed in 8-12h and persist until putrefaction.**



Pale/ not well-developed Livor mortis

Seen in **anemia, hemorrhage**, young or old age

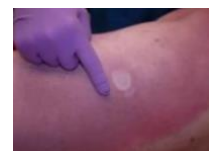
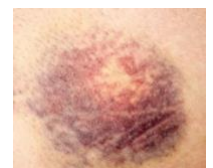
Cherry red Livor mortis

Seen in **CO poisoning & cyanide poisoning** (less intense than CO)

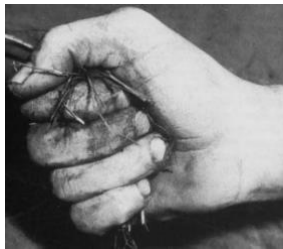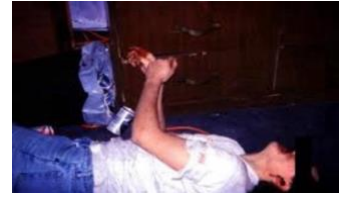Difference between Livor mortis and bruises:

Livor mortis	Bruises
Dependent area, purplish blue color	Any where, color depends on its age
Well defined edges	Ill defined edges
Intact capillaries	Ruptured capillaries
Blanchable	Unblanchable
Superficial	Deep into the skin
Incision: blood flows from cut vessels (washable)	Incision: blood coagulate in the tissue
No swelling	May be with swelling
Same level on surface	Raised



Rigor mortis

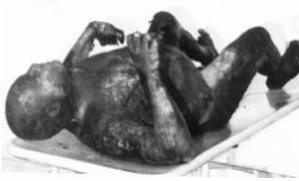- ❖ **Muscle stiffening & rigidity** with some degree of shortening.
- ❖ Caused by persistent attachments of actin filaments to myosin due to the lack of ATP along with the loss of muscle softness and elasticity.
- ❖ **Starts 1-2 h after death (after primary relaxation), takes 9-12h to develop from head to foot, persists for 12h and takes 12h to pass off.**
- ❖ **Develops faster in case of electrocution, running (faster ATP depletion), high temperature.**
- ❖ Start in the all muscles at the same time, but first seen in the small muscles, primarily the eyelid (orbicularis oculi), jaw & neck >> the cause is the number of the muscle fiber.
- ❖ Among voluntary muscles develops **sequentially & descending** pattern.
- ❖ The rigidity disappears in the same order in which it has appeared and ends due to the muscle fibers autolysis (secondary flaccidity).



Cadaveric spasm

The muscles were contracted immediately **before** death and continue to be so after death **without passing through primary relaxation.**

Happens in highly emotional deaths the cause is not completely understood, happens in small muscle group, much stronger than rigor mortis.



Heat stiffening

The body is subjected to a heat exposure > 65 °C. There will be **coagulation of the muscle protein**, flexors affected more >> *pugilistic attitude* of the body.



Cold stiffening

The body is exposed to freezing temperature for a reasonable period, the tissue become frozen and stiffed stimulating rigor. There will be a **freezing of body fluids and harding of the subcutaneous fatty tissue.**

Late changes

1. Decomposition / putrefaction

- ❖ Breaking down of complex organic tissue into simpler inorganic compounds due to autolysis or action of saprophytic microorganisms.
- ❖ Clostridium Welchii is the main organism in putrefaction.
- ❖ External signs: 4 Ds (Discoloration, Distention [gas accumulation], Degradation, Dissolution).
- ❖ Internal signs: Organ decomposition, uterus and prostate being the last organs to decompose.
- ❖ **Degradation:** loss of integrity of skin (skin slippage, degloving & loosening of hair and nails).
- ❖ **Dissolution:** occurs with progressive decomposition that leads to liquefaction and disappearance of tissue and organs and eventual skeletonization.
- ❖ **Putrefaction occurs earlier in hot, air, humidity, infection or septicemia before death.**
- ❖ **Decomposition starts immediately after death but appears as discoloration in 36-48 hours.**

Table 9.6: Order of putrefaction

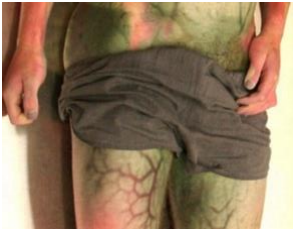Early putrefaction	Late putrefaction
i. Larynx and trachea	i. Heart, lungs, kidneys
ii. Stomach, intestines	ii. Esophagus, diaphragm
iii. Spleen	iii. Blood vessels
iv. Liver	iv. Bladder
v. Brain	v. Prostate, uterus (non-gravid)
vi. Gravid uterus	vi. Skin, muscle, tendon

Decomposition of Submerged Body

Casper's dictum states that rate of decomposition in air is twice as rapidly as in water, and eight times as rapidly in deeply buried bodies, i.e. 1 week of putrefaction in air = 2 weeks in water = 8 weeks in soil at similar temperature, but this dictum is not useful practically.³²⁻³⁴ The deeper a body is buried, the better its preservation during an elapsed period of time.

The process of decomposition in water is slow due to:

- Exclusion of air
- Protection by clothes
- Early cooling of the body

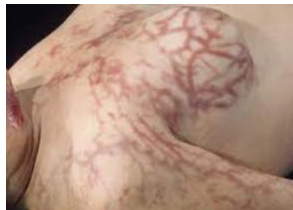

Discoloration

The first external sign of decomposition.

Greenish discoloration in the right iliac fossa; due to the reaction between H₂S and deoxygenated Hb. Internally, this is seen under the surface of the liver.

Clostridium Welchii is most abundant in the iliocecal zone.

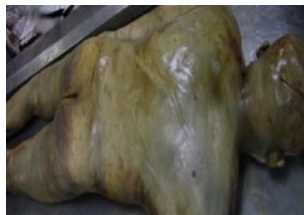

Marbling of skin

First appear in the shoulders, roots of limbs, thigh, sides of abdomen, chest and neck. It marks the passage of bacteria in the vessels; happens due to decomposition of Hb to **sulphmethemoglobin** in the inner wall of superficial vessels.

Onset: In summers, it is seen in 36-48 h after death.

2. Adipocere (Saponification)



- The **surest** sign of death.
- Occur in the fatty tissue and it is a modification of the decomposition.
- **In hot and moist environment, it may occur by the end of 1 week. In temperate countries, it starts in 3 weeks and completes in about 3 months.**
- **Favorable factors: hot, humid anaerobic environment &, moist & water.**

3. Mummification



- **Onset: 3-12 months after death.**
- It is a modification of decomposition (dry decomposition).
- Rapid dehydration of the dead body with preservation of the natural features of the body. The body loses weight and becomes thin, stiff and odorless.
- **Favoring factors: hot, dry & free air environment, poisoning (chronic arsenic and antimony poisoning).**

Notes

- ✓ Skin and bone remains metabolically active for many hours and can be successfully cultured days after somatic death.
- ✓ Nervous tissues die rapidly, the vital centers of the brain die in 3-7minute, muscles survive up to 1-2 hours.
- ✓ **Suspended animation**: vital signs of life (HR & RR) are not detected by routine clinical methods; the metabolic rate is greatly reduced & the requirement of the cells for oxygen is satisfied by dissolved oxygen in body fluids. May be **voluntary** (yoga) or **involuntary** (hypothermia, drowning, electrocution, poisoning by opiates & barbiturate, newborn, post-anesthesia, cholera, shock, heatstroke, burn).
- ✓ In the primary relaxation the muscle is still alive and respond to electrical stimulus but when the rigor mortis happens this indicated a molecule death of that muscle.
- ✓ Rigor mortis in the uterus of the pregnant will not cause expulsion of the fetus.
- ✓ Postmortem pupil constriction is unreliable indicator of toxic or neurological condition.
- ✓ If the rigor mortis involve the whole body this indicates that the time of death between 12-24h back.
- ✓ Maceration it is a aseptic autolysis of the dead fetus in the uterus.
- ✓ In the decomposition, organs that composed of more muscular and fibrous tissue resist putrefaction longer than parenchymatous organ except the stomach and intestines which decompose rapidly.
- ✓ Livor mortis mostly help in determining the position of the dead body.

	Somatic death	Molecular death
Onset	Proceeds molecular death	Succeeds somatic death (1-2 hours after stoppage of vital functions)
Tissue and cells of the body	Alive and functioning	Dead and non-functioning with no metabolic activity
Response to external stimulus	Muscles respond to thermal, electrical or chemical stimulus	Does not respond
Confirmation	Flat ECG and EEG and absent breath sound	Rigor mortis, algor mortis, postmortem staining & putrefaction
Resemblance	Suspended animation, coma, hypothermia	Dose not resemble any condition

Burn

Types of burns:

1. Contact burns: contact with hot object.
2. Flame burns: contact with flam.
3. Scald burns: contact with hot liquids.
4. Radiant heat burns: caused by heat waves; a type of electromagnetic wave.
5. Ionizing radiant burns: caused by x-ray, radium or UV rays.
6. Chemical burns: caused by acids or alkalis.

Classification of burns:

	First degree	Second degree	Third degree
Depth	Epidermis	Epidermis & dermis	Deeper to dermis
Color	Red or pink	Dark red	White, gray, black
Pain to stimuli	Painful & tender	Very painful	Painless
Blanching	Yes	Yes, but slow	No
Appearance	Dry	Moist	Dry/lethargy
Blisters	Not present	Present	May or may not
Healing time	3-6 days	3 weeks	Skin grafting
Scar	No	Yes	Yes
Medico-legally	Simple	Grievous	Grievous

Causes of death:

Immediate causes:

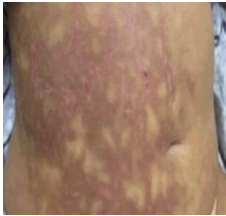
1. Primary or **neurogenic shock** due to pain or fright.
2. **Asphyxia** (CO poisoning is an important cause, COHb >50% is confirmatory).
3. Smoke-or heat-induced **laryngospasm**, respiratory arrest, Vagal reflex-induced cardiac arrest.

Delayed causes:

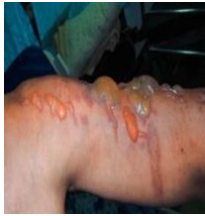1. **Hypovolemic shock** (death within 24-48h); decrease cardiac output >> multi organ failure.
2. **Acute edema of glottis**, respiratory failure (death within 3 days); due inhalation injury, pneumonia, or ARDS.
3. **Toxemia** due to absorption of toxic products (death within 3-4 days).
4. **Sepsis**: (death within 4-5 days), pseudomonas, S.Aureus. **The most important.**
5. **Infective complications**; bronchitis, bronchopneumonia, enteritis.

External funding of burns:

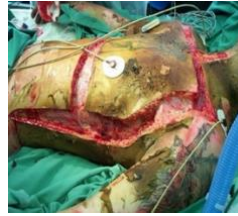1. Face: distorted and swollen, protruding tongue, burnt or singed hair
2. Skin: hyperemia, blisters, veins stand out, marbled skin.
3. Blisters: may be ruptured or filled with fluid.
4. Degloving/ destocking.
5. Pugilistic attitude (boxing, fencing or defense attitude), not medico-legaly significant.
6. Heat ruptures: splits in the skin due to tissue concentration >> incised or lacerated wounds.



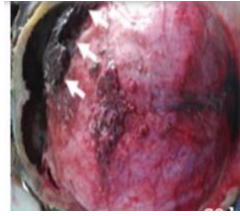
Marbled skin



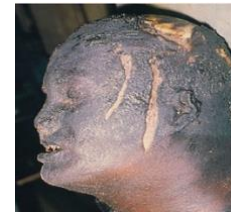Blisters



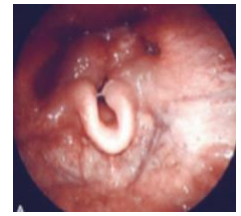Escharotomy



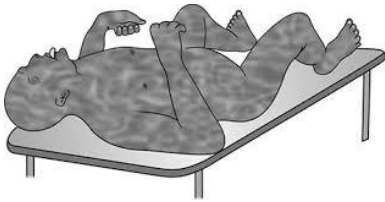
Heat hematoma



Heat rupture



Laryngospasm



Pugilistic attitude (also called heat contracture) – flexion of the elbow, wrist, fingers, hip, knee

Happens due **heat stiffening**; due to coagulation of proteins of the muscles and dehydration which cause muscle contraction >> may lead to heat rupture (splits in the skin).

Sequelae of burns:

- ❖ Scars, keloid, marjolin's ulcers, curling ulcer (1st part of duodenum), joint deformity, ankylosis.
- ❖ Corneal capacity, obliteration of external auditory meatus.

Differentiation between heat ruptures wound and lacerated wounds:

	Heat rupture	Lacerated wound
Cause	Exposure to heat	Blunt force
Site	Fatty tissue	Anywhere
Vessels and nerves	Intact	Torn
Bruising around the margins	Absent	Present

Internal findings of burns:

1. Skull: heat hematoma (resemble extradural hematoma), skull fractures.
2. Brain: congested, swollen with widening and flattening of guri and obliteration of the sulci.
3. Neck: hemorrhage in the root of the neck and tongue.
4. Larynx, trachea and bronchioles: carbon & soot particles, congested mucosa with frothy mucus secretion (**the surest sign of antemortem burns**) which is due to gases inhalation.
5. Pleural: congested and inflamed with serous effusion.
6. Lungs: congested and edematous, may be shrunken.
7. Heart: chambers full of blood with cherry red in color due to CO inhalation.
8. Spleen: enlarged and softened.
9. Liver: cloudy swelling, fatty liver, cell necrosis, jaundice may occur.
10. Kidney: nephritis, thrombosis, infection, enlarged and congested adrenals.

Remember 💡

Livor mortis will be cherry red due to CO poisoning.

Heat artifacts: any body changes occur after exposure to the heat (like slit wound, blisters, EDH, pugilistic attitude).

Note: When burn surface involves 1/3rd of body surface area or more (30-50% of body surface) the result is nearly always fatal.

Differentiation between epidural hematoma (EDH) due to burns and blunt force:

	EDH due to burn	EDH due to blunt force
Cause	Intense heat	Blunt force
Site	Anywhere	Usually adjacent to sylvian fissure
Position	Usually bilateral	Usually unilateral
Distribution	Diffuse	Localized
Characteristics	Evenly distributed or sickle-shaped; honeycomb appearance; soft, granular, foamy, friable clot; chocolate brown in color (pink, if CO is present)	Disc shaped; uniform, smooth, rubbery; reddish-purple color
Skull fracture	Eggshell fracture, elliptical or circular defect seen above temple not radiating lines	Fracture line radiating from a skull defect present in temporal area
Crossing suture lines	May cross	No
Injury to CNS	Absent	Maybe
CarboxyHb level	Present	Absent

Differentiation between antemortem and postmortem burns:

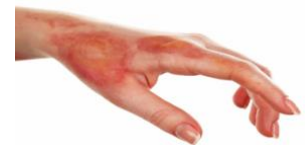	Antemortem burns	Postmortem burns
Line of redness	Present	Absent
Vesicles	Serous fluid rich in albumin, chloride , polymorphs	Air, if fluid is present, it contains little albumin
Base of vesicles	Red & inflamed	Dry, hard, yellow
Soot in URT	May be present	Absent
Inflammation & repair	Present along with pus and slough	Absent
Healing	Present	Absent
Carboxyhemoglobin	Present	Absent
Enzyme reaction	Increase at periphery of burn	No such increase

Scaled burns

Result from application of liquid $>60^{\circ}\text{C}$, involving only the superficial layers of skin.

Types:

1. Immersion burns: accidental, homicide or deliberating (like child abuse).
2. Splash or spill burns: usually accidental.
3. Steam burns: by superheated steam.



Classification (3 degrees):

1. Erythema caused by vasoparalysis.
2. Vesication and blister formation caused by increased capillary permeability.
3. Necrosis of the dermis when deeper layers of the skin are involved.

Electrocution

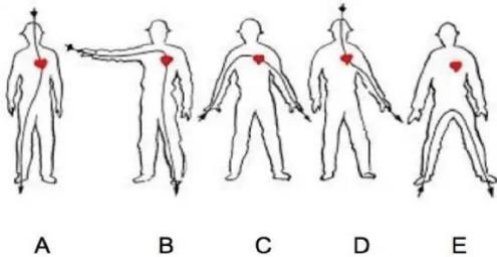
Death or severe injury happens due to the passage of electric current through the body.

Sources of electricity:

1. Domestic, 240 volts (the most common source).
2. Industrial, up to 40000 volts.
3. Lightning, up to 300 million volts.

Factors that affect the degree of injury/ damage in the electrocution:

- ❖ Current strength and voltage.
- ❖ Resistance (more resistance = less conduction but severe injury).
 - Bone (highest) > fat > tendon > skin > muscle > nerve > blood (lowest).
 - The skin has a variable resistance (higher when dry, lower when wet).
- ❖ Duration of contact.
- ❖ Type of current (Alternating current [AC] or Direct current [DC]).
 - AC is worse; it cause prolonged muscle contraction make it harder for a persons to release the electrical source & it disrupt the normal heart rhythm (ventricular fibrillation).
- ❖ Pathway through the body.
- ❖ Surface area & site of contact.
- ❖ Environmental conditions (humidity, metal, ...).
- ❖ Personal factors (age, medical illnesses like heart disease).



Pathways of electrocution

The more vital organs/tissues passing through = the more dangerous the electrocution is.

“A” considered the **most** dangerous (the current passed through the **heart, brain & diaphragm**).

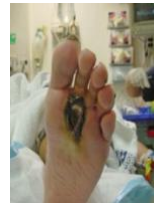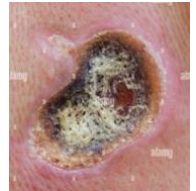
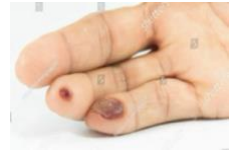Causes of death in electrocution:

1. Ventricular fibrillation (cardiac arrest) – the most common cause.
2. Asphyxia – due to respiratory muscles paralysis or damage of brain stem (respiratory arrest).
3. Thermal injury – in case of high voltage exposure.
4. Multi-organ failure & CNS damage.
5. Secondary trauma – like falls, infection, septicemia (due to burn).

Electrocution marks:

Local effects

- **Joule burn** burn due to thermal effects caused by electrical energy (more in low-voltage). When the current passes through the body, the body's tissues resist the flow of current, and this resistance generates heat.
 - Blisters, redness, superficial-deep thermal burn at the site of contact.
- **Catastrophic injury**: usually seen in case of the high-voltage electrocution:
 1. Center zone: charred black and necrotic tissue.
 2. Intermediate zone: damaged tissue with coagulative necrosis (not completely dead tissue).
 3. Outer zone: hyperemia and inflammation due to increased blood flow.
- **Exit wound**: Larger and more irregular. May have a charred edges with extensive tissue necrosis. The electrical current exits the body with greater force than it enters leading to extensive damage. In high-voltage current, the exit often appears as a 'blow-out' type wound.
- Flash or spark burn.
- Wounds (lacerated or punctured wound with contusion at the margin).



Systemic effects

- CNS damage.
- Eye (cataract).
- With recovery there may be muscular pain, fatigue, headache, irritability.
- Immediate death.

Autopsy findings:

External findings:

1. Electrocution marks.
2. Burned clothes and body hair.
3. Fractured ribs (due to severe convulsions).
4. Extensive ecchymosis.
5. **Rigor mortis develops early** with blue-red livor mortis is well-developed.
6. Suspended animation.
7. Joule burn at the site of entry is diagnostic.

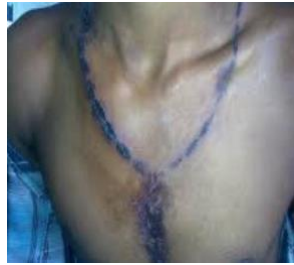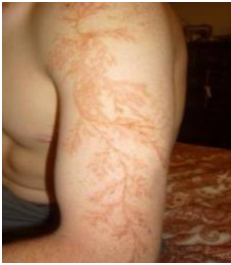Internal findings:

1. Ocular congestion with dilated pupils.
2. Pulmonary edema.

3. Petechial hemorrhage (brain, pleura, pericardium).

Clinical features of lightning injury:

1. Clothing: torn/ singed.
2. Skin:
 - Superficial burn, **Lichtenberg** burn “lightning flower” (**pathognomonic for lightning**).
 - Metallization.
3. Cardiac: arrhythmia (V. Fib).
4. Neurological:
 - Immediate: pupil dilation/anisocoria (asymmetric pupil size), LOC, amnesia, seizures.
 - Delayed: myelopathy, complex regional pain syndrome.
5. Vascular: spasm.
6. ENT: tympanic membrane rupture (blast injury).
7. Ocular: cataract, retinal detachment.



Lichtenberg

Metallization

Notes:

- ❖ The **mode** of death in electrocution is syncope.
- ❖ The most common **cause** of death is arrhythmias.
- ❖ The **manner** of death is accidental.

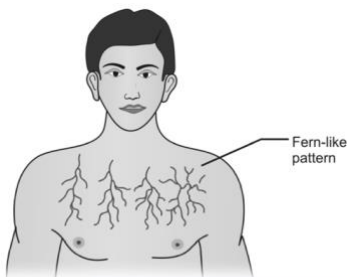


Fig. 14.8: Lichtenberg flowers/Filigree burns

Wounds

Factors influencing causation of wounds:

1. Nature of object / weapon.
2. Amount of energy discharged during impact (determined by the object mass & velocity).
3. Conditions under which the energy is discharged.
4. Nature of tissue affected (skin, subcutaneous tissue, muscle, bone,...).
5. Area of the affected part.

Types of wounds:

1. Abrasions

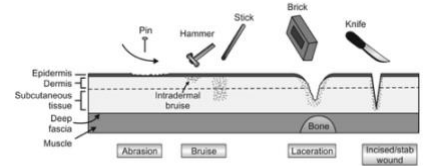


Fig. 11.1: Mechanical injuries caused by blunt and sharp objects

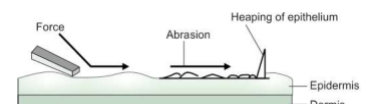
- ❖ **Rough blunt** force injury result in loss of superficial layer of skin.
- ❖ It is involve the epidermis >> so usually no (or low) bleeding, no scar formation.
- ❖ Mechanism of production:
 1. Compression force: imprint abrasion and pressure abrasion (non-imprint).
 2. Tangential force (sliding or friction): linear abrasion and graze abrasion.

❖ Types:

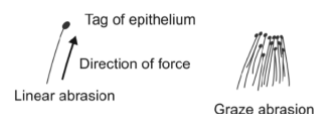
1. Linear abrasion "scratch abrasion"	<ul style="list-style-type: none"> ○ Skin damage in a line-like pattern. ○ It's the result of a sharp, pointed object.
2. Graze abrasion "sliding or brush abrasion"	<ul style="list-style-type: none"> ○ Caused by making contact with or dragging across a rough surface. ○ They show a parallel lines (furrows or grooves). ○ When the friction force is great, grazed area appears like burn injury and it is called in such cases the brush burn.
3. Imprint abrasion "pattered abrasion"	<ul style="list-style-type: none"> ○ Result from a force applied perpendicularly to the skin leading to direct impact of the force to the skin causing stamping of skin with the force. ○ The wound matches the size and shape of the object.
4. Pressure abrasion "crushed abrasion"	<ul style="list-style-type: none"> ○ Result form prolonged pressure from blunt force (like ligature in strangulation). ○ When the pressures abrasion resemble the shape of the object it is called now imprint abrasion :)

- ❖ Heaping of the epithelium: skin tags appear in the case of abrasions and this help in determining the direction of the force

(يعني إنه صار في زوائد جلدية عند جهة معينة فبداية الجرح بتكون من الاتجاه المعاكس)

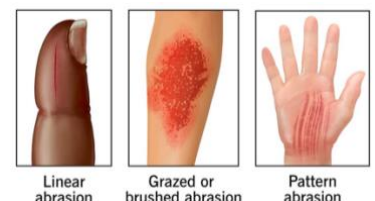
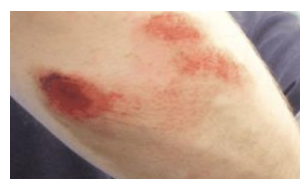
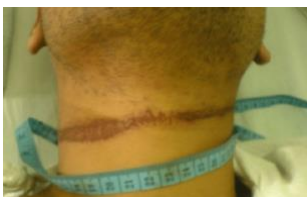- ❖ Medicolegal importance: site, type of the offending object & time of the crime can be determined.



- ❖ Bite mark is an patterned abrasion.

- ❖ Abrasion wound can be fabricated (but less common than insicied wound).



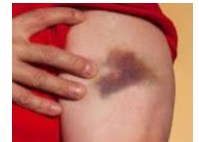Differentiation between antemortem and postmortem abrasion:

	Antemortem abrasion	Postmortem abrasion
Site	Anywhere	Bony prominence
Color	Bright red	Pale & dry
Covering	Scab composed of coagulation of blood & lymph	No such scab
Signs of inflammation	Present	Absent
Microscopy	Coagulation & vital reaction present	No

Age of abrasions:

Red , no scab	Fresh
Dark red scab	12 - 24 hours
Reddish brown scab	1 - 2 days
Dark brown	3 - 5 days
Blackish scab shrinks & falling begin from the margin	5 - 7 days
Scab fall of leaving hypo-pigmented area	7 - 10 days

2. Contusion



- ❖ Extravasation or collection of blood due to rupture of blood vessels caused by **blunt** nature without loss of continuity of tissue.
- ❖ If the contusion is visible throughout the skin or subconscious tissue you can call it bruises.
- ❖ Subcutaneous bruises is the most common type.
- ❖ Ecchymosis and petechiae are caused by pathological disorder such as bleeding tendency.
- ❖ Factor affecting contusion: condition of tissue, body part, situation of bruise, condition of blood vessels, presence of disease, sex, age, color of skin, optical character of skin.

Age of contusion:

Shifting bruises...

Color	Age	Caused by
Red	Fresh	Extravasation of blood
Bluish	1 - 3 days	Deoxyhemoglobin
Bluish dark to brown	4 days	Hemosiderin
Greenish	5 - 6 days	Hematoidin
Yellow	7 - 12 days	Bilirubin
Complete disappearance	2 weeks	-

❖ **Complication:**

- If inflicted on vital parts (e.g. neck, heart), the contusions may cause death.
- Multiple contusions may cause death by shock and hemorrhage.
- The contusions are painful lesions.
- Multiple contusions of intestine may cause ischemia or gangrene.
- The collected blood in contusion may lead to proliferation and multiplication of bacteria.
- Pulmonary fat embolism; due to fat expressed from fat cells and then liquid fat entering the injured and torn blood vessel may lead to pulmonary fat embolism.

Differentiation between contusion & postmortem lividity:

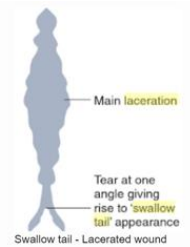
	Contusion	Postmortem lividity
Cause	Extravasation of blood due to blunt trauma	Stasis of blood in the vessels
Site	Anywhere (including internal organs)	Dependent sites
Surface	Elevated due to swelling	Not elevated
Color	Variable; depend on the age	Purplish blue
Edges	Ill-defined	Well-defined
Signs of inflammation	Present	Absent
Incision	Extravasation of blood in the surrounding & can't be washed out	Shows blood in the vessel & can be washed out

Differentiation between contusion & congestion:

	Contusion	Congestion
Caused by	Blunt force	Pathological condition
Color	Variable, depend on the age	No changes in the color
Edges	Ill-defined	Well-defined
On dissection	Extravasation of blood	Engorged vessels with blood

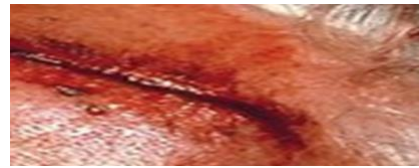
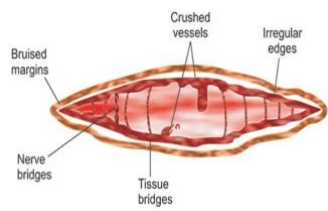
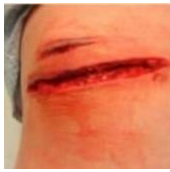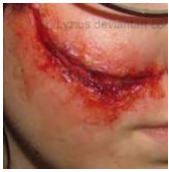3. Lacerated wound

- ❖ Slitting or tearing of tissues caused by **blunt force** (involves the whole skin thickness).
- ❖ The most common type of wound seen in the ER.
- ❖ Commonly seen at bony prominences.
- ❖ **Irregular ragged & uneven edges**
- ❖ There may be bruising and crushing of the margins.
- ❖ Hair follicles are crushed.
- ❖ Swallow tails which are small tears at the angle of the main lacerated wound.
- ❖ Bleeding from lacerated wound is less compared to incised wound; the vessels are torn and crushed >> capable of retracting and undergo thrombosis >> less hemorrhage.
- ❖ **Some tissue, nerves, and blood vessels remain intact at the base of the wound represented as "tissue /structure bridging" and it is a characteristic sign (vs. incised wound).**
- ❖ Usually heal with scar formation.
- ❖ Medicolegal importance: the cause, nature, age, direction, manner of injury can be determined.
- ❖ Undermined edge, slopped side and adjacent contusion shown by physical examination is often the side which force was directed.



Differentiation between antemortem and postmortem lacerated wounds:

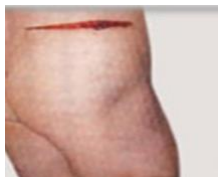	Antemortem lacerated wound	Postmortem lacerated wound
Extravasation of blood	Present	Absent
Coagulation of the blood	Present	Absent
Signs of healing	Present	Absent
Increased enzyme activity	Present	Absent
Pus / infection	Present	Absent



4. Incised wound

- ❖ Caused by drawing or striking the edge of **sharp object** on the skin and underlying tissues.
- ❖ Broader than the edge of the weapon causing it because of retraction of the divided tissues.
- ❖ Spindle-shaped and gaping.
- ❖ **The length is greater than the depth, shallow & superficial.**
- ❖ **Clean, well defined edges mostly everted but maybe inverted & no bruises.**
- ❖ Hemorrhage is more in comparison with lacerated wound.
- ❖ Direction of application of force can be known by the “tailing”, it is the end point.
- ❖ Medicolegal importance: the cause, nature, age, manner, direction of injury can be determined.

Self-inflicted wounds (fabricated wound)	Defense wounds
Injuries on accessible part of the body, superficial, minor, regular, multiple & similar in shape, parallel or grouped together, handedness, old scar may be seen, psychiatric disorder.	When the victim tries to defend himself, mainly on the palm and ulnar aspect of the hand.



Notice the tailing in the left so the direction of the offending force from the right to the left.

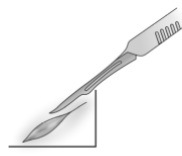
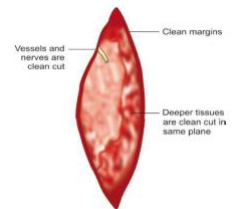
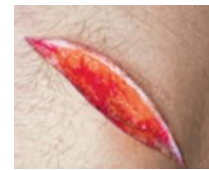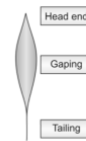
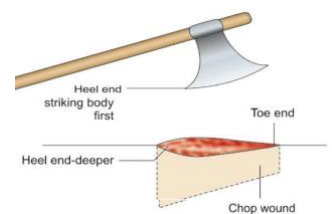


Fig. 11.8: Incised wound



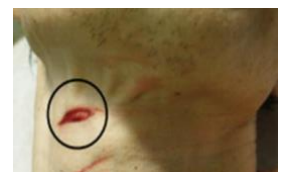5. Chop wound

- ❖ Type of incised wound made by hacking or chopping motion with fairly **sharp and relatively heavy weapon** such as axe.
- ❖ Wounds are wider and deeper than incised wounds but not so sharp.
- ❖ **Two parts in the chop wounds may be identified:**
 - The part of wound nearer to the assailant, known as heel end of the chop, is deeper than distal part from the assailant, known as toe end of the chop.
- ❖ Medicolegal importance: relative position of the assailant, type of weapon, age of injury can be determined, the manner usually homicidal, accidental injury may happen.



6. Stab wounds

- ❖ Wound produced by mechanical force along the long axis of a **narrow or pointed object**.
- ❖ **Types of stab wounds:**
 - Penetrating wounds: entry wound without exit wound.
 - Perforating wounds: entry and exit wounds.
- ❖ Entry point is larger and inverted, the exit point is smaller and everted.



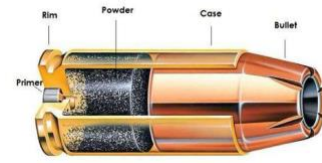
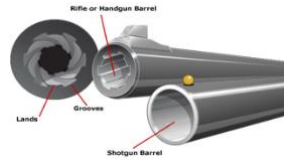❖ **The depth of stab wound is more than length and width.**

- ❖ Length of the wound >> width of the weapon.
 - ❖ Depth of the wound >> length of the weapon.
 - ❖ Width of the wound >> thickness of the weapon.
-
- ❖ Hit mark >> contusion that happens when the handle of the weapon hits the skin (full length of the blade is inside)
 - ❖ One sharp edge |>
 - ❖ Two sharp edges <>

Firearm injuries

Firearms are broadly classified into two categories depending on the type of barrel:

1. Rifled weapons.
2. Smooth bores rifled (shotgun).



Anatomy of a Cartridge

Types of gunpowder:

- Black powder: it produces flame, smoke and heat, and consists of granular.
- Ingredients, like sulfur, charcoal and saltpeter (potassium nitrate).
- Smokeless powder: more effective than black powder as it burns more efficiently and produces much less smoke, resulting in less blackening and tattooing around the entry wound.

Factors responsible for the injurious effects of missile:

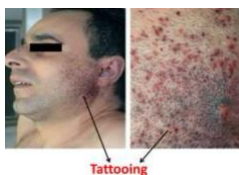- Speed of the bullet.
- Size and shape of the bullet.
- Character of the missile's movement in flight.

Characteristics of firearm wounds depend on:

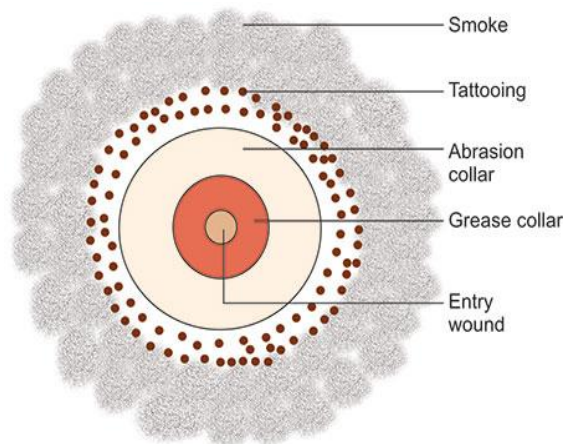
- Nature of the firearm, whether shotgun or rifle.
- Shape and composition of the missiles.
- Range (distance) of firing.
- Part of the body struck (head or trunk).
- Direction of firing.

Grease collar: black colored narrow ring of skin, lining the defect and is sharply outlined from the removal of substances from the bullet as it passes through the skin. Seen at any distance.

Tattooing: Appear as **reddish-brown** punctate abrasions surrounding the wound **entrance**. Caused by partially burned powder and metal particles (seen in near distance)

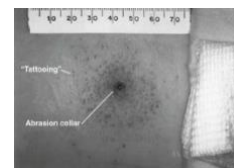


Tattooing



Abrasion collar: **reddish-brown ring around a bullet entry wound**, caused by the bullet stretching and rubbing against the skin before penetration. Seen at any distance.

Blackening "شحبار": appears as **black-gray** discoloration surrounding the wound **entrance**. Caused by completely burned particles (seen in close distance >> flame range).

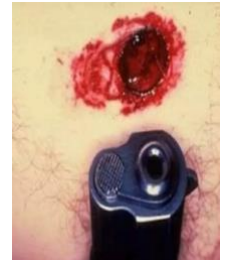

Tattooing (stippling)	Blackening
It consists of unburnt or partially burnt powder particles that are embedded in and under the skin.	It consist of burnt powder particles that are expelled from the firearm
Appear as reddish-brown punctate abrasions surrounding the wound entrance	Appear as black or gray discoloration around the wound entrance
Can't be wiped off	Can be wiped off

What is Muzzle/recoil imprint mark?

A **muzzle imprint mark** refers to the distinctive pattern or injury left on a person's skin when the muzzle (the end of the barrel) of a firearm is in direct contacts the skin at the time of discharge.

“يعني شكل فوهة السلاح بطبع على الجلد و هاد دليل إنه السلاح ملامس لسطح الجلد”



What is Blowback phenomenon?

Blowback is the **backward movement** of **blood, tissue, hair, or fibers** into the barrel of a firearm after a **contact or close-range gunshot wound**.

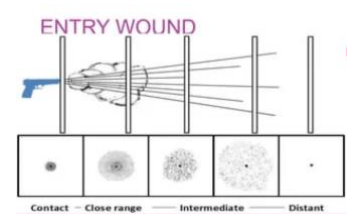
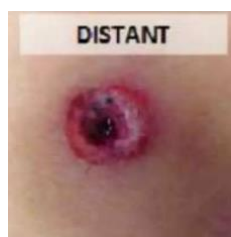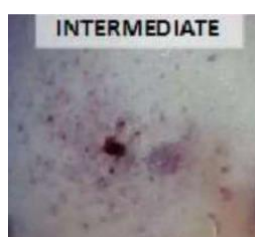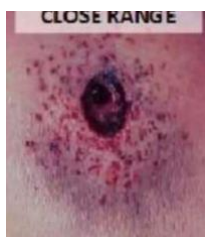Classification of gunshot wounds:

1. Penetrating wounds: entry wound only.
2. Perforating wound: entry and exit wounds.

Entry wound appearance:

الأرقام من الكتاب

Contact shot 0 cm	<ul style="list-style-type: none"> ○ Muzzle Imprint is seen. ○ Blowback effect. ○ Stellate (Star-Shaped) wound with everted margins happens if is over a bony surface (skull).
Close shot Up to 15 cm (6 inches)	<ul style="list-style-type: none"> ○ Small, circular wound with inverted margins. ○ Blackening is present. ○ Grease collar & abrasion collar.
Near shot (intermediate) 15 - 60 cm (6 - 24 inches)	<ul style="list-style-type: none"> ○ Tattooing is present, but blackening disappears. ○ Wound size: similar to the bullet caliber. ○ Abrasion collar still visible.
Distant shot Beyond 60 cm	<ul style="list-style-type: none"> ○ Only the bullet penetrates, no blackening or tattooing. ○ Wound is clean-cut, round or oval with an abrasion collar. ○ No surrounding burns, marks, or muzzle imprints.



Exit wound appearance:

- Exit wounds, regardless to the distance, all have the same general characteristics.
- In contact wounds and very close range, exit wound is smaller than entry wound due to elastic nature of the skin. However, **as range increases, the size of exit wound also increases.**
- Exit wounds do **not show burning, blackening, tattooing**, abrasion or contusion collar. The edges are **everted**, torn or puckered with pieces of contused, hemorrhagic subcutaneous fat or muscle protruding out of the defect.

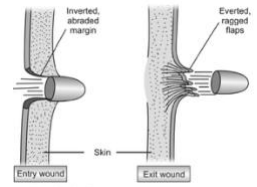


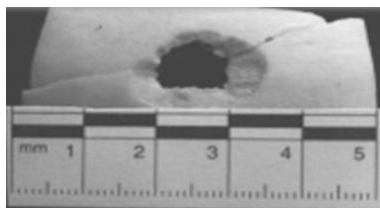
Fig. 12.18: Firearm entry and exit wounds

Differentiation 12.2: Suicidal, accidental and homicidal firearm injury			
Feature	Suicide	Accident	Homicide
Site of entry wound	Head or heart	Any area	Any area
Shot distance	Contact or very close range	Close or very close	Any range, usually distant
Direction	Upward or backward	Any direction	Usually upward
Number of wounds	Usually one	One	Any number
Powder residue on hand pressing trigger	Present	Present	Absent
Cadaveric spasm	May be seen with the weapon firmly grasped	Not so	Not so
Weapon at scene	Found	Found	Not found
Scene	Usually his house	In his house or while hunting/handling	Any place, evidence of struggle
Sex	Usually males	Usually males	Any sex
Motive	Insanity, illness, financial loss	Nil	Game feuds, robbery, revenge

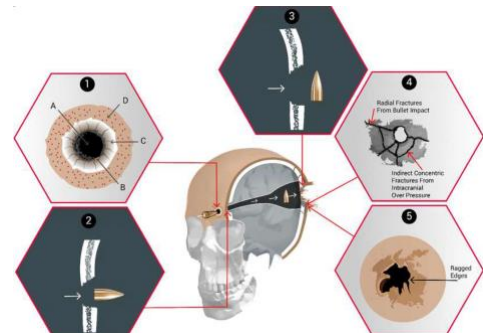
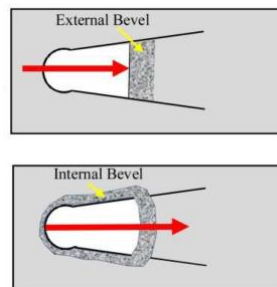
Differentiation 12.1: Entry and exit wound (Fig. 12.18)		
Feature	Entry wound	Exit wound
Size	Smaller than the diameter of the bullet (except contact shot)	Bigger than the bullet
Edges	Inverted	Everted, puckered
Skull	Clean cut on outer table and beveled in the inner table	Beveled in the outer table and clean cut on inner table
Bruising, abrasion and grease collar	Present	Absent
Burning, blackening, tattooing	May be seen	Absent
Bleeding	Less	More
Fat	No protrusion	May protrude
Wound track	May be cherry-red due to carboxyhemoglobin	No color change
Fibres of clothes	Turned in	Turned out
Radiological/micro-chemical examination	Lead ring may be seen	Absent
Spectrograph	More metal is found	Not so

Skull wound due to firearm:

- In perforating gunshot wounds to the head, entrance and exit wounds show a typical feature called beveling, distinguishing between entrance and exit.
- Beveling is a sort of cone shaped bone erosion in the direction of the bullet path through the cranial vault.
- Entrance wounds can be round / oval or stellate in shape and show an internal beveling.
- Exit wounds are usually irregular and show an external beveling.
- Even if the bullet does not penetrate into the cranial cavity, its energy is still transferred to the bone and central nervous system, resulting in fractures and severe damage.



External beveling



- Internal beveling >> inner table.
- External beveling >> outer table.

Asphyxia

Exactly the word asphyxia means 'absence of pulsation', yet it is commonly used to describe lack of oxygenation either partial (hypoxia) or absolute (anoxia).

Types of anoxia:

1. **Anoxic anoxia:** failure to deliver oxygen from environment.
 - a. Ambient: decreased oxygen content in the atmosphere (e.g. high altitude, irrespirable gases like CO₂, N₂).
 - b. Central: depression of respiratory center (e.g. opioids and barbiturates poisoning).
 - c. Peripheral: paralysis or spasm of respiratory muscles (e.g. overdose of succinylcholine, botulism, OPP)
 - d. Mechanical (violent asphyxia).
2. **Anemic anoxia:** decreased oxygen carrying capacity of blood due to:
 - a. Abnormal hemoglobin (e.g. COHb in CO poisoning).
 - b. Hemolysis (e.g. Incompatible blood transfusion).
3. **Stagnant anoxia:** decreased blood flow to the tissue and organs (e.g. HF, anaphylactic shock).
4. **Histotoxic anoxia:** diminished ability of cells to use oxygen (e.g. cyanide poisoning or cold exposure).

The classical stages of asphyxia:

1. Stage of **dyspnea**; stimulation of respiratory center due to lack of oxygen in blood.
2. Stage of **convulsions**; cerebral irritation due to anoxia and hypercapnia.
3. Stages of **paralysis**; irreversible brain damage.

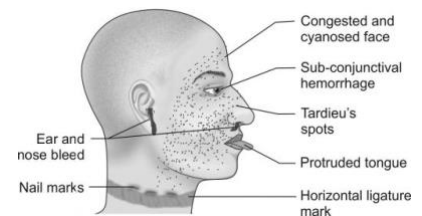
Classical signs of asphyxia:

A. External signs:

- Cyanosis.
- Facial edema and petechial hemorrhage (Tardieu's spots).
- Prominent eyeball (due to retro-orbital edema) with subconjunctival hemorrhage.
- Protruded tongue and ear & nasal bleeding.
- Dark blue hypostasis.

B. Internal signs

- Congestion of the viscera and the mucosa of air passages with bloody froth.
- Petechial hemorrhage "Tardieu's spots".
 - ✓ They are caused by an acute rise in venous pressure >> causes over distention and rupture of thin-walled peripheral venules.
- Salivary spots: shiny grey spots appear sub-pleural due to increased intra-alveolar pressure during convulsion phase >>> rupture of the superficial unsupported sub-pleural alveoli.



Types	Definition & mechanism of death	Postmortem signs
<u>Smothering</u>	Manual obstruction of the external respiratory orifices (mouth & nose) by hands or soft object. * Mechanism of death: Mechanical anoxia.	A. General: 1. External & internal asphyxia signs. 2. Ventral hypostasis in cot death. B. Local: 1. Pallor around the mouth & nostril. 2. Semilunar nail abrasions & bruises at external respiratory orifices. 3. Bruises & contusion in the inner aspect of the lips, cheeks and gum.
<u>Choking</u>	Blockage of the internal respiratory passages at level of pharynx, larynx, or trachea. * Mechanisms of deaths: 1. Asphyxia (due to FB obstruction + laryngeospasm or ↑ mucous secretion). 2. Reflex cardiac inhibition (RCI) Café coronary: The obstructing foreign body will wedge into laryngopharynx & stimulate vagal nerve endings resulting in reflex cardiac arrest.	A. General: External & internal signs of asphyxia B. Local: Foreign body in air passages. In an epileptic, tongue may show bite marks or bruising.
<u>Gagging</u>	Fabric or adhesive tap occludes the mouth, nasal opening remain patent but later blocked by mucus and/or edema may lead to death.	
<u>Suffocation</u>	Reduction of the oxygen concentration in the atmosphere. * Mechanism of death: Hypoxia or reflex cardiac inhibition.	The classical signs of asphyxia are almost always absent with negative autopsy findings.
<u>Throttling</u>	Neck is constricted forcibly by the hands . Pressure must be applied for <u>at least 2 minutes</u> to cause death. Mugging is application of pressure to the neck by the arm * Mechanism of death: 1. Mechanical anoxia (chief cause). 2. Reflex cardiac inhibition. 3. Cerebral anemia (compressor carotid artery). 4. Delayed edema of glottis.	A. General: External & internal signs of asphyxia B. Local: 1. Semilunar nail abrasions & bruises on the front & sides of the neck. 2. The most significant internal sign: extravasating of blood in subcutaneous tissue underneath the external marks. 3. The most diagnostic finding: inward compression fracture of hyoid bone 4. Damaged larynx and fracture or split of the thyroid cartilage. 5. Fracture of cricoid cartilage (pathognomnic for throttling).
<u>Strangulation</u>	Neck is constricted by a rope or any ligature * Mechanism of death: 1. Mechanical anoxia. 2. Reflex cardiac inhibition. 3. Delayed edema of the glottis.	A. General: External & internal signs of asphyxia B. Local: 1. Ligature marks; formed of abrasions and contusions and surrounded by congestion, petechiae and hyperemia ○ Transverse & complete circle.

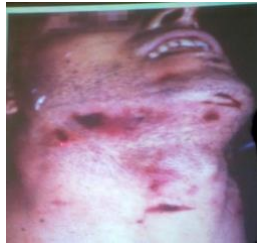		<ul style="list-style-type: none"> ○ Below laryngeal prominence. <ol style="list-style-type: none"> 2. Scratches and abrasions on either side of the neck as a sign of resistance. 3. Fracture of thyroid cartilage and hyoid bone with inward displacement (less severity than throttling). 															
<p><u>Hanging</u></p>	<p>Suspension of the body from the neck by a ligature. The constricting force is produced by the body weight.</p> <p><u>Based on degree of suspension:</u></p> <ol style="list-style-type: none"> 1. Complete: The body does not touch the ground at any point. 2. Incomplete: If any part of the body touches the ground. <p><u>Based on knot position:</u></p> <ol style="list-style-type: none"> 1. Typical: the knot is centrally located over the occiput. 2. Atypical: the knot is anywhere other than on the occiput. <p>Mechanism of death:</p> <p>The most common cause of death is combination of venous congestion and mechanical asphyxia due to backward displacement of the base of the tongue.</p> <p>Tearing of the medulla: following fracture dislocation of the cervical vertebrae. Common with “Judicial hanging” due to the long drop of more than two meters. The knot is placed below the chin.</p>	<p>A. General:</p> <ol style="list-style-type: none"> 1. External & internal signs of asphyxia. 2. Hypostasis of the lower parts of the body (lower limbs, hand, lower abdomen, genitalia) – gloves and stocking hypostasis. 3. Engorged genitalia with ejaculation in males. <p>B. Local:</p> <ol style="list-style-type: none"> 1. Ligature marks: <ul style="list-style-type: none"> ○ Incomplete circle, oblique. ○ Located high up in neck. ○ Asymmetrical: deepest opposite the point of suspension and fades gradually upwards to be absent at the site of the knot. 2. Dribbling of saliva due to pressure on the submandibular gland (surest sign of antemortem hanging). 3. Transverse untimely rupture of carotid arteries. 4. Outward fracture of the hyoid bone or posterior horn of the thyroid cartilage. <p>* Fracture dislocation is most common between C2-C3 >> Hangman's fracture.</p> <table border="1" data-bbox="954 1417 1485 1591"> <thead> <tr> <th>Ligature mark</th> <th>Strangulation</th> <th>Hanging</th> </tr> </thead> <tbody> <tr> <td>1- Site</td> <td>Low below larynx</td> <td>High above larynx</td> </tr> <tr> <td>2- Shape</td> <td>Complete circle</td> <td>Incomplete circle (except running noose/ double turns).</td> </tr> <tr> <td>3- Direction</td> <td>Transverse</td> <td>Oblique</td> </tr> <tr> <td>4-Compression</td> <td>Symmetrical</td> <td>Asymmetrical</td> </tr> </tbody> </table>	Ligature mark	Strangulation	Hanging	1- Site	Low below larynx	High above larynx	2- Shape	Complete circle	Incomplete circle (except running noose/ double turns).	3- Direction	Transverse	Oblique	4-Compression	Symmetrical	Asymmetrical
Ligature mark	Strangulation	Hanging															
1- Site	Low below larynx	High above larynx															
2- Shape	Complete circle	Incomplete circle (except running noose/ double turns).															
3- Direction	Transverse	Oblique															
4-Compression	Symmetrical	Asymmetrical															
<p><u>Traumatic</u></p>	<p>Fixation of the chest and abdomen by external mechanical compression preventing respiratory movements.</p> <p>Mechanism of death:</p> <ol style="list-style-type: none"> 1. Mechanical asphyxia. 2. Injury of vital organs. 	<ol style="list-style-type: none"> 1. Blue congestion of the face, neck and upper chest & pallor at compression site. 2. Conjunctiva is congested and hemorrhagic. 3. Local bruises and abrasions of chest wall, may be with fractured ribs or sternum / ruptured heart or lungs. 4. Lungs are dark with Tardieu’s spots. 															

Sexual

Death in sexual asphyxia is accidental self-induced; that happens suddenly during attempts of inducing hypoxia to reduce the blood supply to the brain; which appear to produce auto erotic hallucinations in some persons during the course of solitary sexual activity.

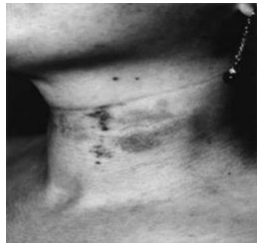

Smothering



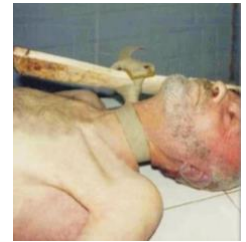Throttling

- *Contusions/ Manner: Homicide.
- *Inward Hyoid bone fracture is suspected.



Strangulation

- * Pressure contusions
- * Complete, transverse circle

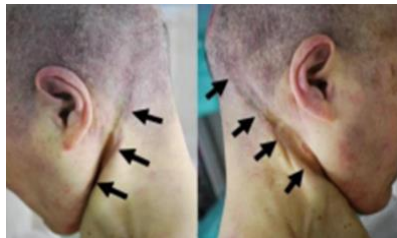

Strangulation

- * Suicidal

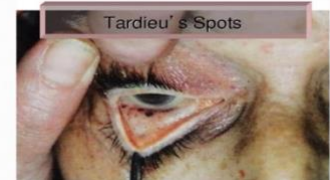
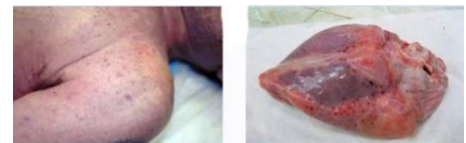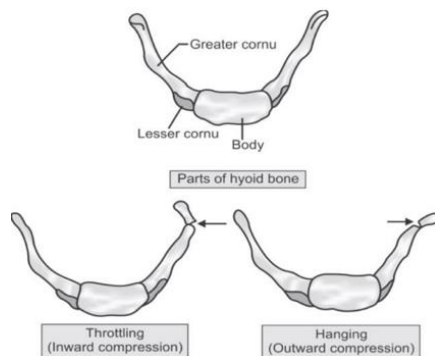

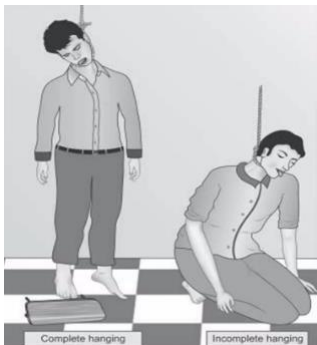
Mugging



Hanging

- * Imprint abrasion.
- * The constricting force is the body weight.
- * Mostly the manner of death in hanging is suicidal.



Differentiation 10.1: Antemortem and postmortem hanging			
S.No.	Feature	Antemortem hanging	Postmortem hanging
1.	Salivary dribbling mark	Present	Absent
2.	Fecal/urinary stains	May be present	Absent
3.	Ligature mark <ul style="list-style-type: none"> • Direction • Continuity • Level in the neck • Parchmentization • Vital reaction 	Oblique Non-continuous Above thyroid Present	Circular Continuous At or below thyroid Absent
4.	Knot	Single, simple, on one side of neck	Multiple, granny or reef type on occiput/chin
5.	PM staining <ul style="list-style-type: none"> • Above ligature mark • In lower limbs • Glove-stocking like 	Present Present Present	Absent Absent Absent
6.	Evidence of injury <ul style="list-style-type: none"> • Self-inflicted • Struggle • Tear of carotid artery intima • Imprint abrasion 	Present Absent Present Present	Absent Present Absent May/may not be present
7.	Elongation of neck	Present	Absent
8.	Cyanosis	Deeply positive	Absent or faintly present
9.	Emphysematous bullae on lungs	Absent	Present
10.	Point of suspension	Compatible with self-suspension	Not so

Drowning

- ❖ The dominant manner of death is accidental.
- ❖ **Water composition (less important than the quantity):**
 - ✓ Temperature – cold water cause ventricular dysrhythmia.
 - ✓ Tonicity – if hypertonic or hypotonic.
 - ✓ Contamination – high load of pathogens increase the risk of infection & sepsis.

- ❖ Aspiration of 1 to 3 mL/kg of liquid compromises the function of surfactant and leads to respiratory compromise and hypoxemia.

❖ Classification:

- Typical:

1. **Fresh water drowning (hypotonic)** (fatal period is 4-5 min)
2. **Salt water (sea water) drowning (hypertonic)** (fatal period is 8-12 min)

- Atypical:

1. Dry drowning:

- Water does not enter the lungs due to **laryngospasm** (blocks air entry).
- Cardiac arrest induced by small amounts of water entering the larynx.
- Negative autopsy findings & dry lungs.

2. Immersion syndrome/cold water drowning:

- Vasovagal reflex that leads to cardiac arrest due to sudden immersion in cold water (less than body temperature by 5 degree). [Hydrocution]
- The resultant **loss of consciousness leading to secondary drowning**.
- Common among middle-aged alcoholic men.

3. Near drowning (post-immersion syndrome):

- The patient died beyond 24h due to **complication** (ARDS, DIC, hypoxemia-induced encephalopathy).

4. Shallow water drowning:

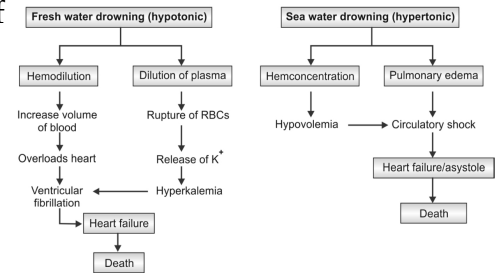
- Submersion of the **unconscious** (alcoholics, drugged, epileptic) in shallow water.

❖ Phases of drowning:

1. Breath holding >> hypercapnia >> breath center activation.
2. Water swallowing >> scape of air remaining in the lungs replaced by water.
3. Profound unconsciousness >> gasping >> respiratory standstill >> heart failure >> irreversible changes in the brain >> death.

❖ Causes of death:

1. **Asphyxia – the most common cause.**
2. Ventricular fibrillation – in fresh water drowning.
3. Cardiac arrest/asystole – in sea water drowning & immersion syndrome.
4. Laryngospasm – in dry drowning.
5. Vagal inhibition.
6. Concussion and head injury.
7. Apoplexy – SAH from the rupture of berry aneurysm or cerebral hemorrhage by the rupture of cerebral vessels.



8. Secondary causes – septic aspiration pneumonia & sudden bursting of aneurysm.

❖ **Fatal period & treatment:**

- ✓ Symptoms: mental confusion, auditory & visual hallucinations, tinnitus, vertigo / chest pain (in dry drowning).
- ✓ Treatment: artificial respiration with closed chest cardiac massage, defibrillator when there is ventricular fibrillation.
- ✓ Fetal period: 4-5 min in fresh water drowning, 8-12 min in sea water drowning.

❖ **Postmortem findings (external):**

1. Face: Pale, cyanosed, bloated.
2. Eyes: half closed half open.
3. Tongue: swollen, may be protruded.
4. Froth: white & odorless, mixture of air, water & mucus due to forcible respiration.
5. **PM staining:** in the dependent areas (face, neck, front of upper part of chest, upper and lower limbs as the body usually floats face down) with **light pink color**.
6. **Rigor mortis: appear early.**
7. **Cadaveric spasm:** with mud, sand, grass, gravel. (**vital proof of antemortem drowning**)
8. Injuries.
9. Goosebumps (also called Cutis anserina): skin appears granular with hair standing on the end; due to spasm of erector pili muscles.
10. Washerwomen hand: wrinkling, thickening of the skin & white in color.
11. Degloving – 2 weeks.

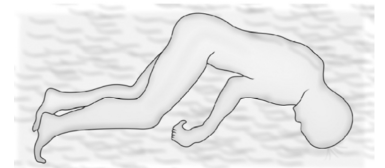
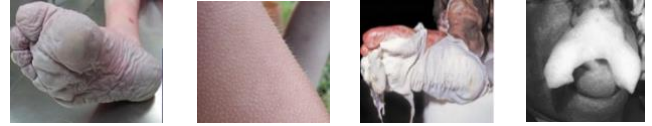
Fig. 10.16: Position of a submerged dead body

❖ **Postmortem findings (internal):**

1. lungs are voluminous, distended and show ballooning.
2. Rib imprints may be present on the surface of lungs.
3. Paltauf's hemorrhage: mottled areas of red and gray distended alveoli (reflects intra-alveolar hemorrhages).
4. Heart and blood vessels: like in other forms of asphyxia, left side of heart will be usually empty; the right heart will be full with the venous system engorged with dark blood.
5. Gettler test: normally, the **chloride** content of the right and left side of heart is nearly same. If difference is 25 % or more, it is **suggestive of antemortem drowning**.
6. Stomach filled with water in 70%.
7. Hemorrhage in the middle ear and mastoid air cells.
8. The presence of **diatoms** in the lung substance, bloodstream, brain, liver, kidneys, bone marrow of femur (best site for analysis) or humerus or in the skeletal muscle has been claimed to be **suggestive proof of antemortem drowning**.
 - They are aquatic unicellular plant.
 - Acid digestion technique is used to extract them.

Differentiation 10.4: Antemortem drowning and postmortem submersion³⁶

S.No. Feature	Antemortem drowning	Postmortem submersion
1. Froth over mouth and nostrils	Fine, lathery froth, appears spontaneously	Absent, even if present, it is coarse, not spontaneous
2. Cadaveric spasm in hands	Aquatic vegetations, mud may be present	Not observed
3. Trachea and bronchioles	Presence of algae, mud along with frothy mucus	Absent
4. Lungs	Ballooned up, bulky, edematous, bear indentations of ribs	Collapsed, decomposed
5. Mud and algae in stomach and small intestine	May be present	Absent
6. Diatom and Gettler tests	Positive	Negative
7. Injuries	If present, need to be consistent with drowning	Injuries inconsistent with drowning
8. Other suggestive signs	Water in middle ear, retracted genitals, cutis anserina, washer-woman's hands, wet clothing, mud and sand	Water is never present in middle ear; others are not valuable and corroborative findings

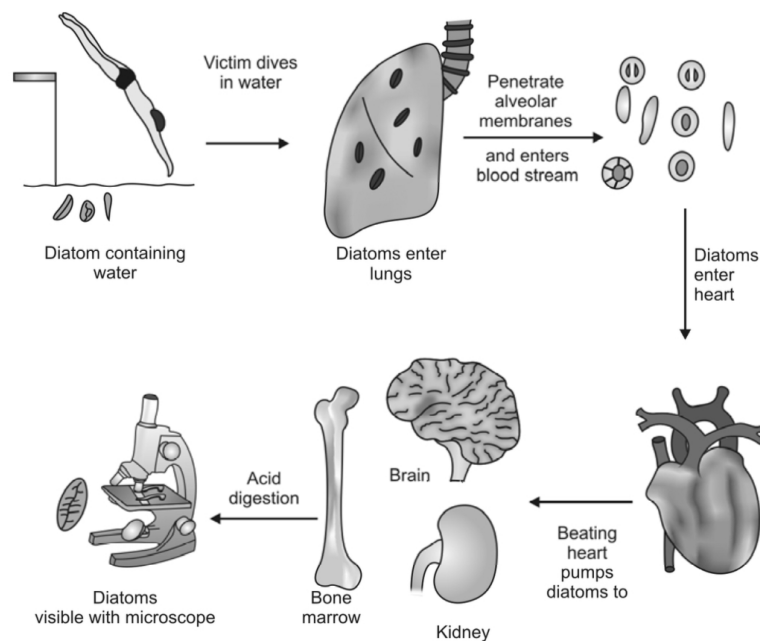


Fig. 10.18: Principle of diatom test

Sudden Death

Death occurring instantaneously or within one hour of the onset of morbid symptoms (as per WHO 24 h is the limitation period).

✓ The autopsy is necessary to obviate the possibility of death due to foul play.

Causes:

1. Cardiovascular (44-50% of cases): Cardiovascular disease, particularly coronary artery atherosclerosis is the most common cause of sudden death.
2. Respiratory system (15-23% of cases).
3. Central nervous system (10-18% of cases).
4. Gastrointestinal system (6-8% of cases).
5. Genitourinary system (3-5%).
6. Endocrine
7. Iatrogenic like drug abuse.

Special Causes in Children:

1. Cot deaths or SIDS.
2. Mongols and others with congenital or mental abnormalities.
3. Concealed puncture wounds.

Coronary Atherosclerosis:

- The most common cause of death from cardiovascular disease is coronary atherosclerosis.
- Almost all adults show atherosclerotic plaques scattered throughout the coronary arterial system. However, significant stenotic lesions that may produce chronic myocardial ischemia show more than 75% (three- fourth) reduction in the cross-sectional area of a coronary artery or its branch.
- Acute occlusion of coronary artery may result from thrombosis or hemorrhage within the wall of the artery.
- The frequency of occlusion of the coronary arteries is:

Coronary artery	Percentage (%)
Left anterior descending	40-50
Right coronary artery	30-40
Left circumflex artery	15-20

- The location of myocardial infarction (MI) is determined by the site of the vascular occlusion and by the anatomy of the coronary circulation.
- Most infarcts occur in the left ventricle in the anterior wall. Right ventricle is involved in < 10% of cases.
- Occlusion of the left anterior descending coronary artery typically causes an infarct in the anterior and apical areas of the left ventricle and the adjacent interventricular septum (anteroapical MI).
- Occlusion of the right coronary artery is responsible for most infarcts involving the posterior and basal portions of the left ventricle.
- Myocardial infarcts which involve the entire thickness of the ventricular wall are referred to as transmural infarcts, while those restricted to the inner one-third of the myocardium are called subendocardial infarcts.
- Fresh thrombi are dark-brown and are attached to the vessel walls. Old thrombi appear as homogeneous yellowish or gray, firm plugs blocking the vessels.
- Significant obstruction of the coronary artery lumen (with 75% narrowing of the lumen) without MI or thrombosis may lead to sudden death.

Postmortem Examination

- No naked eye change is seen for the first 12-18 h. The appearance of a myocardial infarct is determined primarily by its age. It is generally accepted that at least 12-24 h of survival postinfarction must occur for the earliest recognizable change to evolve in the heart.
- The essential sequence of events consists of coagulation necrosis and inflammation, followed by the formation of granulation tissue, resorption of the necrotic myocardium, and finally organization of the granulation tissue to form a collagen-rich scar. These events occur in a fairly predictable pattern, allowing one to estimate the age of a given infarct from its gross and microscopic appearance

Anaphylactic Deaths

- Most anaphylactic deaths seen by forensic pathologist are caused by insect bites, drugs or foods.
- Signs and symptoms: Faintness, itching of the skin, urticaria, tightness in the chest, wheezing, respiratory difficulty and collapse.
- A typical anaphylactic reaction results in acute respiratory distress or circulatory collapse.
- In anaphylactic deaths, the onset of symptoms is usually immediate or within the first 15-20 min
- Death usually occurs within 1-2 h.


Vagal Inhibition (Vasovagal Shock/Reflex Cardiac Arrest/Nervous Apoplexy)

- Sudden death occurring within seconds or minutes as a result of minor trauma or harmless peripheral stimulation may be caused by vagal inhibition.
- Pressure on the baroreceptors situated in the carotid sinuses, carotid sheaths and the carotid body (located in the internal carotid artery and situated near the angle of mandible) causes an increase in blood pressure in these sinuses with resultant slowing of the heart rate, dilatation of blood vessels and fall in blood pressure.
- **Causes:**
 1. Pressure on the carotid sinuses, as in hanging or strangulation.
 2. Unexpected blow to the larynx, chest, abdomen and genital organs.
 3. Impaction of food in the larynx or sudden inhalation of fluid into the upper respiratory tract.
 4. Sudden immersion of body in cold water.
 5. The insertion of an instrument into the bronchus, uterus, bladder or rectum.
 6. Puncture of a pleural cavity producing a pneumothorax.
 7. Sudden evacuation of pathological fluids, e.g. ascitic tap.

Postmortem examination:

There are no characteristic postmortem findings. The cause of death can be inferred only by exclusion of other pathological conditions and from the observation of reliable witnesses, history and clinical findings concerning the circumstances of death.

Dr. Farah said you need to know about the rest of the systems and the causes of death **فارجعوا للمحاضرة**

Notes: 

- **The most common cause of sudden death in a young patient after exercise is:**
Ruptured berry aneurysm then hypertrophic obstructive cardiomyopathy (HOCM).
- **Most common cause of unexplained death in adult females:**
Ischemic heart disease
- **Gordon's clarification of death signifies:**
Mode of death

Child and domestic abuse

Child abuse

There are 4 major subtypes of child abuse:

1. Physical abuse.
 2. Psychological & emotional abuse.
 3. Sexual abuse.
 4. Neglect.
- The majority of deaths are caused by either hitting or beating with the hand, shaking, throwing, dropping and -less often- by burning or suffocation.
 - The most common mode of death is **head injury** then rupture of an abdominal viscus.
 - Child abuse syndrome (or battered baby syndrome): a neonate or child suffers from a repetitive physical injuries from the parents or another caregiver in circumstances that exclude accident.
 - Most of the fatal victims are young and about the 2/3 of them are below 3 years of age.

How to know if there is a child abuse?

1. History: disexplanation, delay in seeking treatment, changing the history overtime (discrepancy).
2. Physical examination:
 - ✓ Soft tissue: multiple injuries with different site & age, **bruises** (especially in the cheeks, upper limb and buttocks).
 - Multiple bruises with different color and sites indicate multiple episodes of physical abuse.
 - ✓ Oral injuries: lip contusion & abrasion, frenulum tearing.
 - ✓ Eye injuries: black eye, retinal hemorrhage.
 - ✓ Head injuries: the shaken baby syndrome triad (brain swelling, retinal hemorrhage, subdural hematoma).
 - ✓ Skeletal injuries: bucket handle fractures, rib fractures, spiral fractures.
 - ✓ Thermal injuries: scalded burn (emersion, splashing, tap water), dry burn (contact, cigarette).

Child abuse outcomes:

- Failure to thrive.
- Psychomotor skills.
- Learning difficulties.
- Death :(

Notes:

- Neonaticide: killing of a newborn (within the first 24 hours of life) by the mother.
- Infanticide: killing of an infant (under 1 year of age) by the mother.
- Filicide: killing of a child above 1 year of age (by a parents or caregiver).

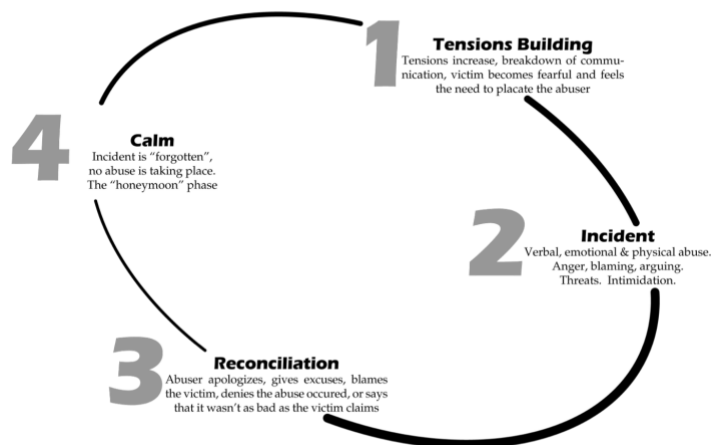
Domestic Abuse

An incident or pattern of abusive behavior directed by one family or household member against another.

Types of Domestic Abuse:

- **Physical abuse**
 - ✓ Indicators: Bruises, broken bones, head injuries.
 - ✓ Physical abuse also includes forcing drug/alcohol use.
- **Emotional and psychological abuse**
 - ✓ Indicators: Anxiety, depression, low self-esteem, PTSD, difficulty sleeping, social isolation, substance abuse, lack of appetite.
 - ✓ Stalking refers to a repeated, unwanted attention and harassment directed at a person, causing them to feel fear, distress, or concern for their safety. It can involve physical following, surveillance, communication, or threats.
 - ✓ Cyberstalking refers to online action or repeated emailing that lead to emotional distress in the recipient.
- **Sexual abuse**
 - ✓ Indicators: Physical signs of trauma, STDs, pregnancy, psychological distress.
- **Financial abuse**
 - ✓ Indicators: Unexplained lack of financial autonomy, dependence on abuser.
- **Neglect**
 - ✓ Indicators: Malnutrition, untreated medical conditions, poor living conditions.

Cycle of Abuse



Medical reports - By Insaf Alammouri

fill able to do basic activities

المرحلة الأولى لتقييم مدة التعطيل : نوع الإصابة

أقصى مدة التعطيل (incapacity period)

* العريضة بأخذ مبلغ مالي عن أيام الإجازة

* تسيير القضية حسب مدة التعطيل ← 2-10 days ← إذا العريضة تنازل بسبب الحق العام

← 10-20 days ← إذا العريضة تنازل بسبب الحق العام (عزامة / حبس)

← >20 days ← جنائية

incapacity period → depends on type of injury & how much it takes to heal
(سواء من حيث مدة السكوت = مدة التعطيل)

* Simple wounds → up to 1 wk

* laceration on joint (limitation of movement) → 2 wks

* upper limb # → 6-8 wks

* lower limb # → 12-16 wks

* clavicle # (rotator cuff muscles motion affected) → 4-8 wks

* Metacarpal, metatarsal, Nasal, Maxillary → 2-4 wks

* Mandible → depends on location (may require fixating jaw so pt can't eat → long time)

* burns → days to months (depends on degree & surface area)

* flat bones non displaced (pelvis, skull, scapula) → 4-6 wks
(faster healing, highly vascular)

* flail chest, open book #, depressed skull # → 2-3 mo.

* vertebral # → 2-3 mo.

* SAH → 2-4 mo.

كيف نقيّم الحالة العامة للعريضة؟ (Status of the pt)

① جيدة ← لا علامات خطيرة الحياة Stable vitals

② متوسطة ← حالة خطيرة لكن علاجاً مستجوب مع التدخل الطبي (معدن vitals (لحم أسوأ فجأة)

③ سيئة ← علاجاً مستجوب Unstable vitals

كافة دائمة (disability)

تسوية حسيمة ، فقد علمت او جزء من علمت ، الإصابة تؤدي لفقدان الوظيفة او جزء منها (permanent) او اي الإصابة تؤدي لاستبدال شيء مثل knee replacement سواء عطلت او بعد كم سنة

من الناحية القانونية يفرق لو كان علمت ظاهر او لا

مثلاً : Splenic injury ← Splenectomy (يحتاج لتحويل عن العجز العفود)

eye injury ← فقد بصره لهما العين + منظرها من حلو (التحويل عن العجز + المنظر)

المساجران

> 20 days ← دائماً جنانية

في حالات برلنو جنانية حتى لو اقل من 20 يوم :

- ① شروع بالقتل حتى لو كانت الهامة بسيطة
- ② نسبت لعاهة (مدلة لو فقد (سبع مدة التقطيل اسبوع لكنها جنانية)
- ③ insised wound عالوجه او الرقبة ← لسجن 3-7 سنين حتى لو تنازل المرلن عن حقه

التقارير

* تقرير اوى (primary) ← يكتبه اول دكتور لسببوه (طواري، جراحة) بس لازم يكون صريح مزاوله مهنة دالة (مسئول طب امتياز)

* تقرير قلبي (final) ← بعد الشفاء سو ما كانت مدته

← فقط يكتبه الطبيب الشرعي

* تقرير لاحق (follow up) ← بين الاوى والقلبي بالحالات القلنية (ما يقدر نستنى لحد ما يستنى) مثل :

- ① growth plate injury in a child (بزحاج نسبة علاقر)
- ② pregnant ما يدا تقدرن لاسعة
- ③ neural or brain injury
- ④ anyone whom we suspect will have a disability (عاهة)

eg. : laceration on parietal area (صيد ممان ييجي السؤال)

* 2-3 mo. (depressed #) ← مدة التقطيل

* after 1 mo. what report would be written? تقرير لاحق (follow up)

* true or false : pt will mostly have a disability : true

notes:

hanging → hyoid # outwards

threatening (خنق / manual strangulation) → hyoid # inwards

pathognomic # → Cricoid

strangulation → thyroid #

most important characteristic of incised wound : length > depth

gunshot → laceration wound.

تقرير طبي

اسم المستشفى: الجامعة الأردنية
رقم الوصل الطبي: 2544987
هاتف المستشفى: 5353444/06
عنوان المستشفى: شارع الجامعة
تاريخ صدور: ساعة صدور: 10 صباحاً

ظروف الحادث (مشارجة/حادث سير/خوفك القوي):
.....

اسم المصاب من أربع مقاطع: نور احمد محمود الحمد
رقم الهوية/جواز السفر: TRF88726 العمر: الجنس: الجنسية: أردنية
عنوان المصاب: شارع الطير / عمان
مكان الحادث: شارع مكة
تاريخ الكشف: ساعة الكشف: 10 صباحاً

مكان الكشف: طوارئ مستشفى الجامعة الأردنية
أنا الموقع أثناء الدكتور: التخصص: طب قلب - الجامعة الأردنية

قامت بالكشف على المذكور أعلاه وقد وجدت ما يلي:
الشكوى حسب إزعاء المصاب:
.....

الحصن الجسدي حسب المعالجة (يشار فيه إذا هناك أصابت قديمة بعلم منها المذكور):
.....

نتائج الفحوصات والإجراءات التشخيصية:
.....

الإجراءات العلاجية:
.....

الحالة العامة للمصاب: حسنة متوسطة سيئة
تسبب الطبيب (يشار فيه إلى طلب الإخلاء للمعالجة أو المراقبة):
.....

اسم الطبيب: توقيع الطبيب: التاريخ:

→ 1° report

Jordan University Hospital
مستشفى الجامعة الأردنية
Forensic Medicine Dept. قسم الطب الشرعي
ت: 2843/5353444 Ext: ص ب 13046 عمان-الأردن

اسم:
رقم التقرير:
رقم الوطني/الشخصي: التاريخ: 2025/1/29
العمر: 48 سنة الساعة: 1.02 مساءً
العنوان: صويلح
ظروف الإصابة: حادث سير مشاورة إصابة عمل غير ذلك:

بناء على طلب محكمة شمال عمان كتاب رقم 2024/8167 الصادر بتاريخ 2025/1/29 والمتضمن تزويد المذكور
أعلاه بتقرير طبي قطعي وبالاطلاع على التقرير الطبي القضائي الأولي الصادر عن مستشفى الجامعة الأردنية
بتاريخ 2024/8/20 والمتضمن ان المذكورة أعلاه حضرت الى الطوارئ اثر تعرضها لحادث دهس وكنت تشكو من
الم في الفخذ الأيمن والمرفق الأيمن والرسغ والركبة اليمنى وبالفحص السريري كتبت العلامات الحيوية مستقرة ومستوى
الوعي 15/15 وأنتبهت بوجود ألم وإيلام في أرسغ الأيمن والفخذ الأيمن والركبة اليمنى مع وجود تورم وخدوش على المرفق
الأيمن وخدوش على باطن اليد اليمنى ومقدم الركبة اليمنى ووجود جرح سطحي في الإبهام الأيسر على السلامة الطرفية
وتم عمل اللازم من الإجراءات تشخيصية وعلاجية وكانت الحالة العامة للمصابة حسنة ما لم تحدث مضاعفات وبالاطلاع
على الاستشارة الطبية الصادرة عن الدكتور جهاد العجلوني بتاريخ 2024/9/5 والمتضمنة ان المريضة لا تزال تشكو من
الم في الركبة وبحاجة الى المتابعة وأخذ المسكنات وقد تمتاح الى صورة رنين مغناطيسي وافلتت المريضة اليوم بتاريخ
2025/1/29 انها بحالة جيدة ولا تشكو من أي ألم في الركبة.

المعالجة الطبية اليوم: المريضة بحالة عامة حذرة ولا تشكو من شيء ولا يوجد أي اثر لأي إصابات أو جروح وبالفحص
السريري كتبت حركات الركبة اليمنى كاملة وضمن الحدود الطبيعية.

النتيجة: إقرار مدة التعطيل الإجمالية بأسبوع من تاريخ الإصابة الأولية

تقرير قطعي.

اسم توقيع الطبيب:
Page 1

→ final report